[redacted]

A team of experts in Diagnostics

[redacted]

IP NO: 1454

Visit ID	: **RC124746**	Registration	: 04/Feb/2026 01:37PM
UHID/MR No	: RC1.0000021954	Collected	: 04/Feb/2026 01:37PM
Patient Name	: [redacted] **IPD**	Received	: 04/Feb/2026 01:37PM
Age/Gender	: 75 Y 0 M 0 D /F	Reported	: 04/Feb/2026 02:17PM
Ref Doctor	: [redacted]	Status	: Final Report
Client Name	: [redacted]	Client Code	: 315
Client Add	:	Barcode No	: 10082987

DEPARTMENT OF IMMUNOLOGY - SEROLOGY

Test Name	Result	Unit	Bio. Ref. Range	Method
HCV Rapid Card Antibody Qualitative				
Sample Type : SERUM				
HCV ANTIBODY QUALITATIVE Rapid	NON-REACTIVE		NON-REACTIVE	Immunochromatography

INTERPRETATION:

-The HCV Tri-dot is a rapid, sensitive and qualitative in-vitro diagnostic test for the detection of antibodies to hepatitis C Virus in human serum or plasma.
-False reactive result may occur due to non-specific binding of the sample to the membrane.
-The presence of Anti-HCV does not imply a hepatitis C infection but may be indicative of a recent or a past infection by HCV.
-Patients with Autoimmune liver disease may show falsely reactive results.

LIMITATIONS:

-The HCV Tri-Dot detects anti-HCV in human serum or plasma and is only a screening test. All reactive samples should be confirmed by supplemental assays like HCV RNA testing or RIBA. Therefore for a definitive diagnosis the patients clinical history, symptomatology as well as serological data should be considered. A non-reactive result does not exclude the possibility of HCV infection.

[redacted]

MBBS,DCP
Consultant Pathologist

[redacted]

Clinical correlation is essential for final diagnosis | If test result are unsatisfactory please contact personally or on phone. This report is for perusal of doctors only.

[redacted]

A team of experts in Diagnostics

[redacted]

Name	[redacted]	Patient ID	[redacted]
Accession No	109	Age/Gender	[redacted]
Referred By	[redacted]	Date	07 Feb 2026

X - RAY -RIGHT KNEE AP VIEW

OBSERVATION:

- **There is total knee replacement prosthesis seen in situ, which is normally oriented.**
- Lower end of the Femur, Patella and Upper ends of the Tibia and Fibula appear normal.
- Alignment is normal.
- No obvious abnormality is seen in the soft tissues.

IMPRESSION:

- **There is total knee replacement prosthesis seen in situ, which is normally oriented.**

Please correlate clinically

[redacted]

[redacted]

(MBBS M.D (Consultant Radiologist))
MCI /09-34285

Disclaimer-It isan online interpretation of medical imaging based on clinical data. All modern machines/procedures have their own limitation. If there is any clinical discrepancy, this investigation may be repeated or reassessed by other tests. Patients identification in online reporting is not established, so in no way can this report be utilized for any medico legal purpose. In case of any discrepancy due to typing error or machinery error please get it rectified immediately

Name	[redacted]	Patient ID	[redacted]
Accession No	111	Age/Gender	[redacted]
Referred By	[redacted]	Date	07 Feb 2026

X - RAY – RIGHT FOREARM AP & LATERAL VIEWS

OBSERVATION:

- Fracture seen at the distal shaft of radius and ulna noted with ortho-fixation metallic plate and screw seen in situ.
- Rest of the visualized bones and joints are normal.
- No sclerotic or lytic lesion is seen in the bones.
- No obvious soft tissue swelling is seen.

IMPRESSION:

- Fracture seen at the distal shaft of radius and ulna noted with ortho-fixation metallic plate and screw seen in situ.

Please correlate clinically

[redacted]

[redacted]

(MBBS M.D (Consultant Radiologist))

MC[redacted]

Disclaimer-It isan online interpretation of medical imaging based on clinical data. All modern machines/procedures have their own limitation. If there is any clinical discrepancy, this investigation may be repeated or reassessed by other tests. Patients identification in online reporting is not established, so in no way can this report be utilized for any medico legal purpose. In case of any discrepancy due to typing error or machinery error please get it rectified immediately

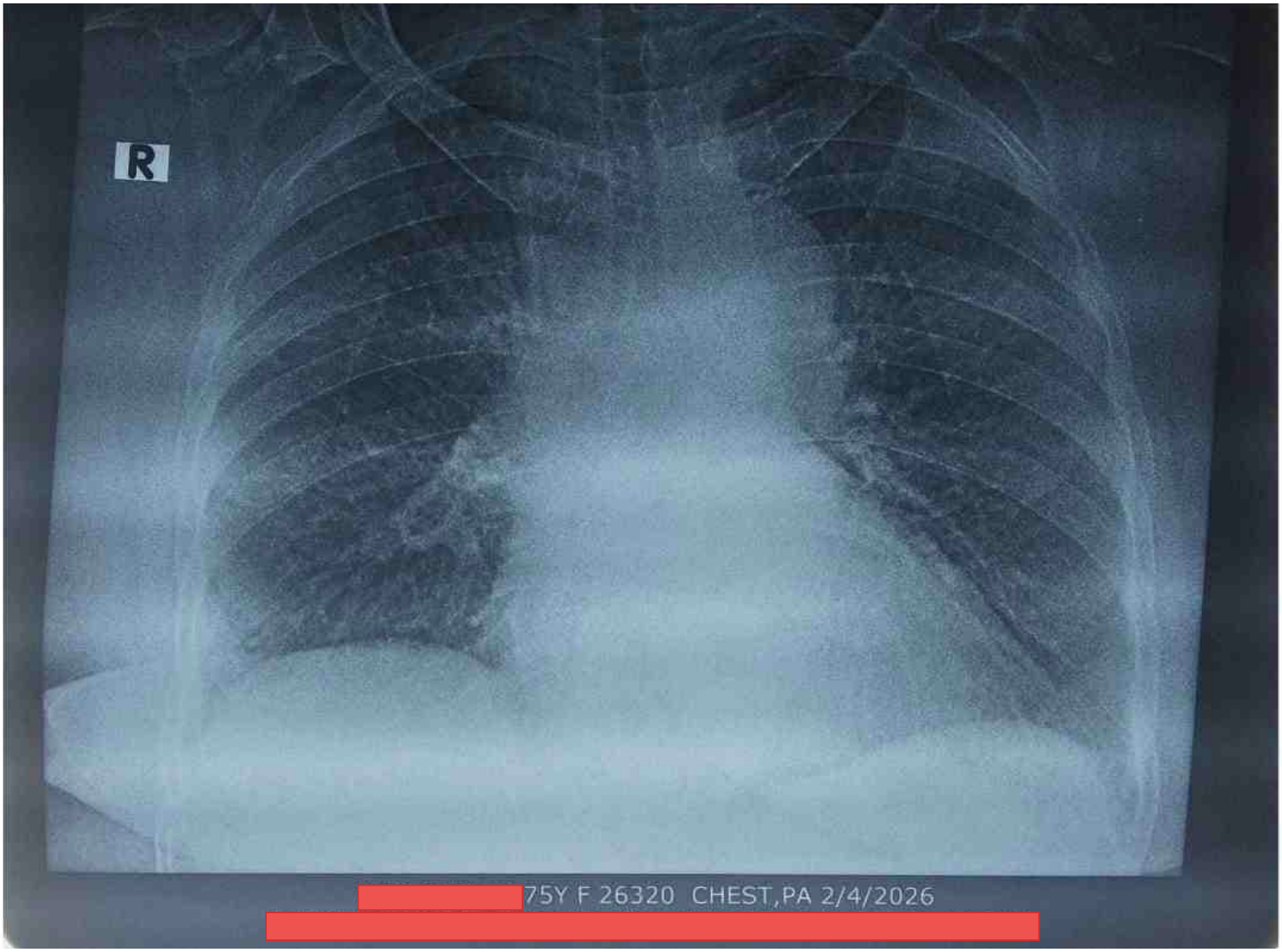
R
[redacted] 75Y F 26320 CHEST,PA 2/4/2026
[redacted]

R
[redacted] 75Y F 26320 SKYLINE / B/L KNEE- LAT 2/5/2026
[redacted]

R
[redacted] 75Y F 26320 B/L KNEE JNT,AP 2/5/2026
[redacted]

R
[redacted] 75Y F 26320 KNEE JNT,AP 2/7/2026
[redacted]

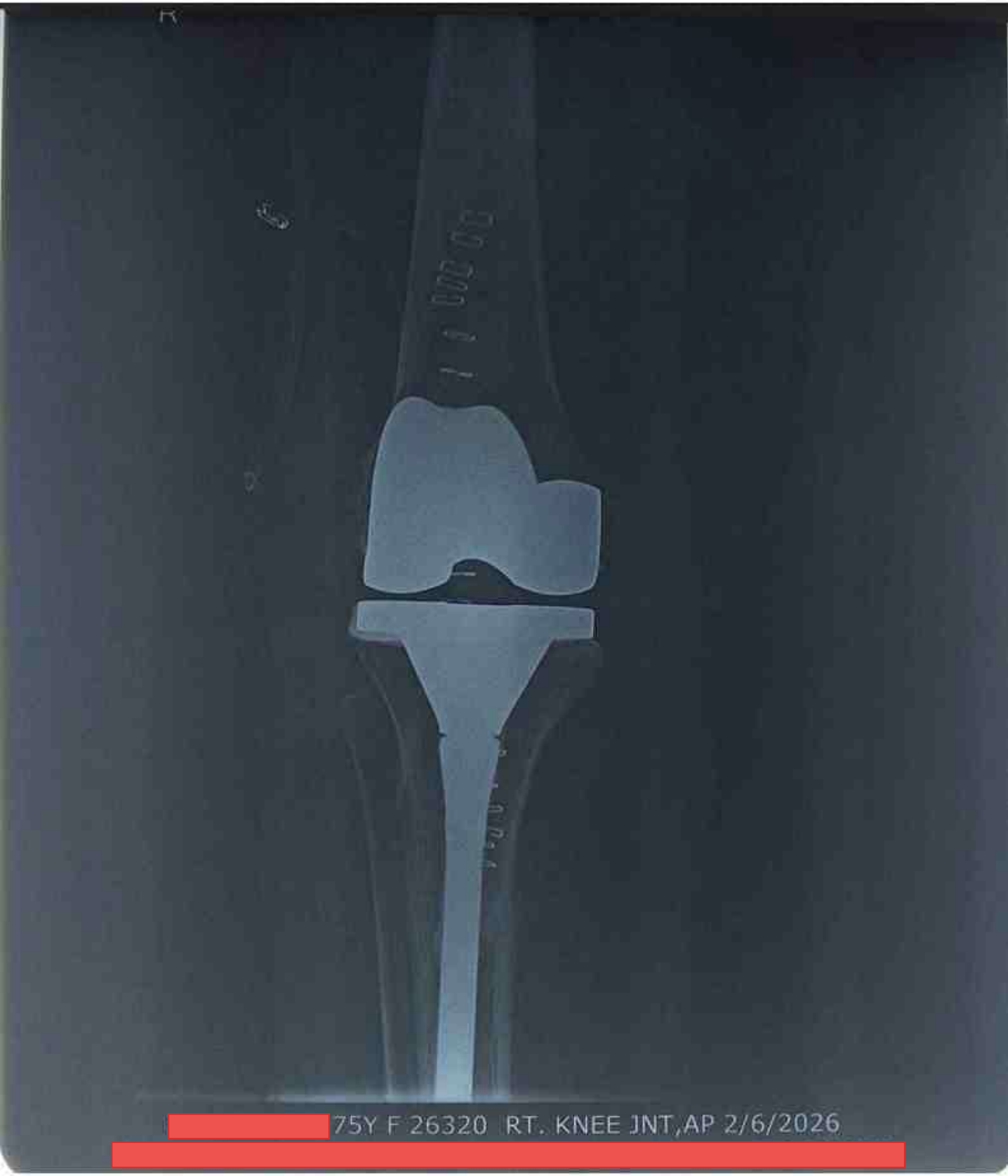
R
[redacted] 75Y F 26320 RT. KNEE JNT,AP 2/6/2026
[redacted]

GPS Map Camera
Google
Plus Code : 7JWVM525+PC
Tuesday, 10/02/2026 10:31 AM GMT +05:30

GPS Map Camera
Google
Plus Code : 7JWVM525+PC
Tuesday, 10/02/2026 10:32 AM GMT +05:30

GPS Map Camera
Google
Plus Code : 7JWVM525+PC
Tuesday, 10/02/2026 10:32 AM GMT +05:30

GPS Map Camera
Google
Plus Code : 7JWVM525+PC
Tuesday, 10/02/2026 10:36 AM GMT +05:30

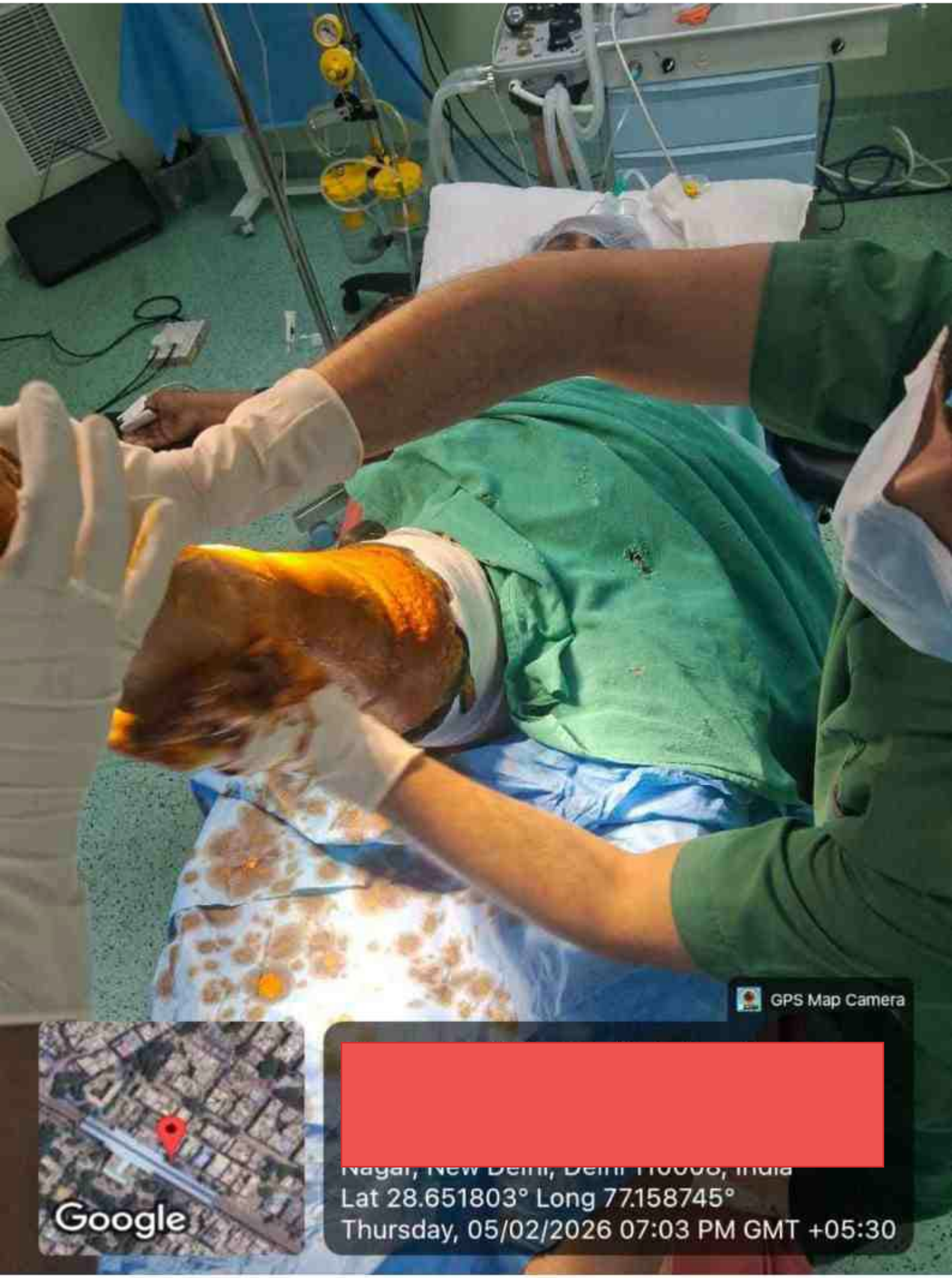
GPS Map Camera
[redacted]
Nagar, New Delhi, Delhi 110008, India
Lat 28.651803° Long 77.158745°
Thursday, 05/02/2026 07:03 PM GMT +05:30
Google

GPS Map Camera
Google
Thursday, 05/02/2026 07:06 PM GMT +05:30

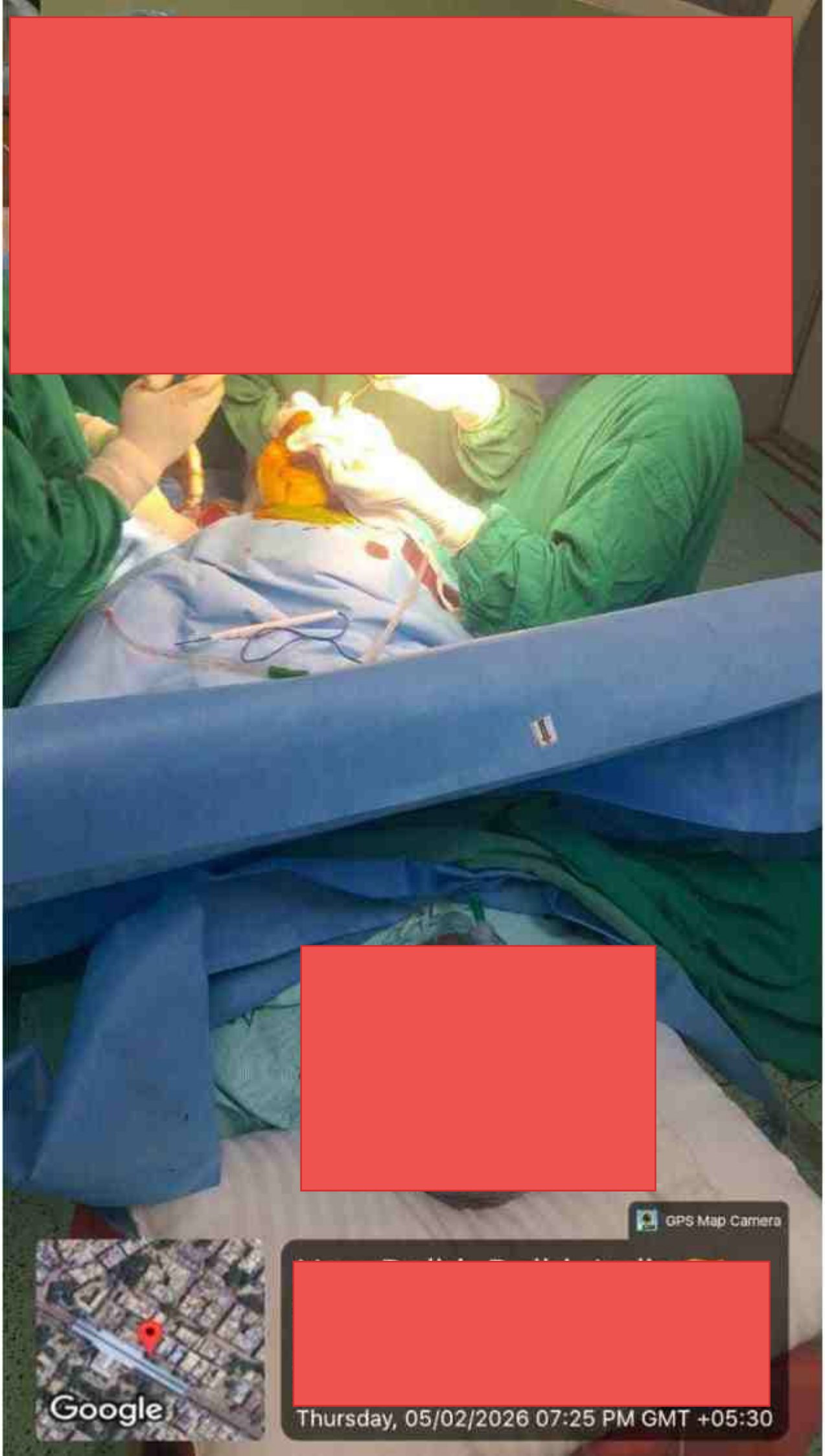
GPS Map Camera
Google
Thursday, 05/02/2026 07:25 PM GMT +05:30

GPS Map Camera
Google
Thursday, 05/02/2026 07:35 PM GMT +05:30

GPS Map Camera
Google
[redacted]
Thursday, 05/02/2026 08:01 PM GMT +05:30

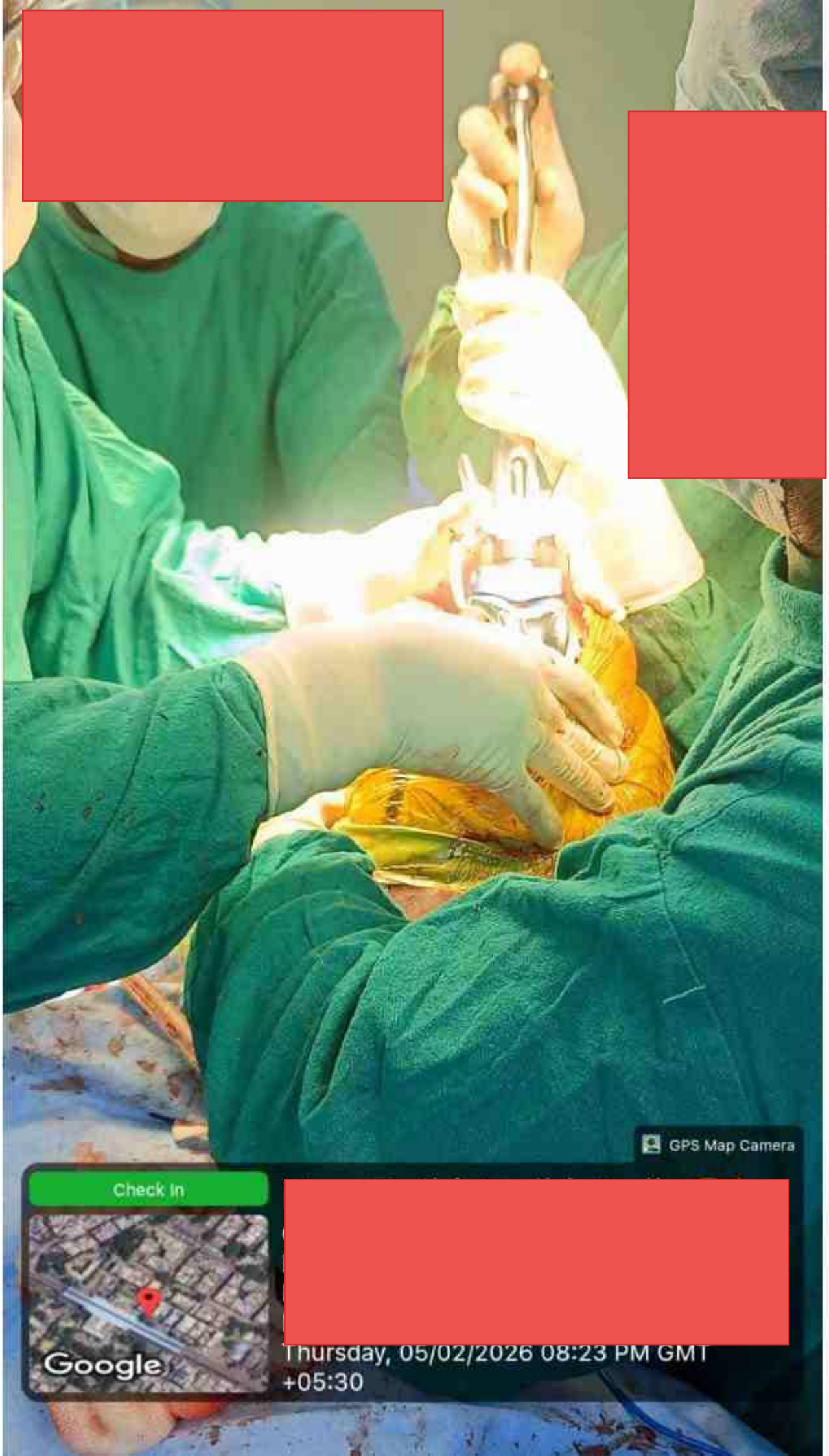
GPS Map Camera
Check In
Google
Thursday, 05/02/2026 08:23 PM GMT
+05:30

[redacted]

[redacted]

p Camera

Check In

[redacted]

Thursday, 05/02/2026 08:35 PM GMT +05:30

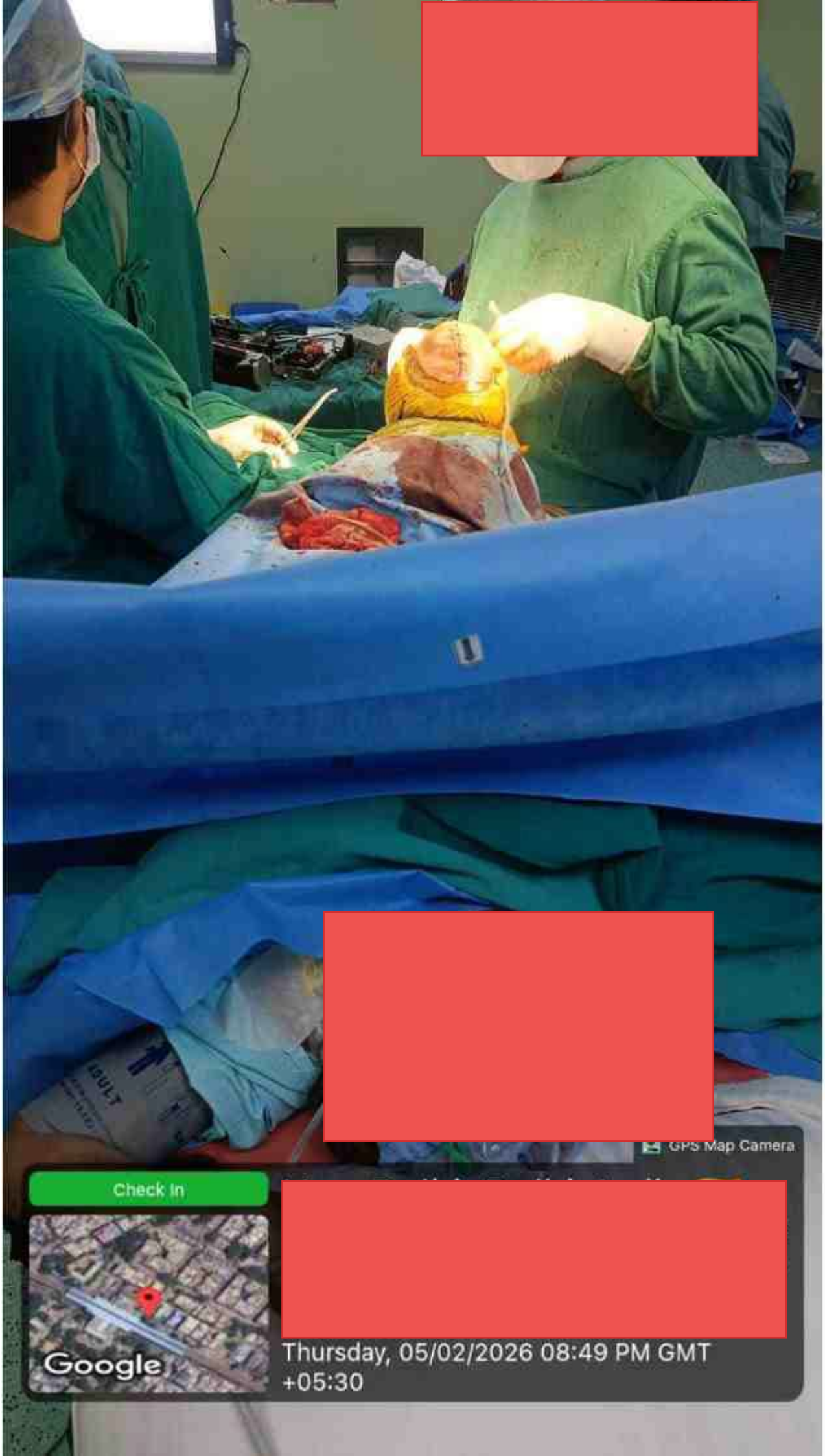
GPS Map Camera
Check In
Google
Thursday, 05/02/2026 08:49 PM GMT +05:30