[redacted]

[redacted]

Generated on: March 15, 2026 at 12:02 PM

ADMISSION FILE

19

[redacted]

Name: [redacted] Age: 53 Sex: F

MRD No: 771763 Unit: Ward:

Diagnosis: OA (L) knee Grade 3

Procedure: TKR (L) knee

Date: 11/2/26 PAC Seen by [redacted]

HISTORY

c/o pain over (L) knee x 5 months

PAST MEDICAL/SURGICAL HISTORY

~~K/c/o T2DM x 3 months on~~ ~~Sq medication~~

b/o T2DM 5-6 yrs and diet control and was under control.

H/o PPS x 18 yrs back

DRUG HISTORY

T. GLIMSTAR M2 1-0-1

Insulin started today

PREVIOUS ANAESTHESIA EXPOSURE

H/o PPS - 18 yrs back

ALLERGY/ADDICTION

Nil

General Examination

Pallor/Icterus/Cyanosis/Clubbing/ Pedal Edema/Lymphadenopathy

Weight: 52 kg Height: 150 cm

BMI:

Higher Mental Functions

GCS:

Heart Rate: 94 BP: 120/70 mmHg

RR: 20 SpO2: 95 Temp: N

CVS: S1 S2 (+)

RS: NVBS

CNS: NAND

Others:

Airway Examination

Mouth Opening: Adequate

Mallampatti Class: I

Thyromental Distance: 3F

Neck Flexion:

Neck Extension: } (LL)

Spine: No deformity

Dentures: (Y/N)

Signat[redacted]

EM ID [redacted]

Anaesthesiolo[redacted]

[redacted]

ADMISSION FILE

[redacted]

MRD NO: Patient Name:

AUDIT MEDICAL RECORD COMPLETION

INVESTIGATIONS Date: 9/2/26

Blood Group

HB: 11.5 PLT: 3.97 TC: 10870

BT: 2.30 CT: 5 aPTT:

FBS: PPBS: HbA1C: 11.5%

BUN: 11 S.Cr: 0.54 Na/K: 141/3.6

TB/DB: OT/PT: ALB/GLOB:

TSH: FT3: FT4:

PT: 10.4 INR: 0.81

Others: RBS - 308, ESR - 49. Urine pus cells 20-25, bacteria ++/ Probable sickling

SCREENING:

HIV: -ve / HCV: -ve / HBsAg: -ve

CXR: (N)

ECG: NSR

ECHO: Normal

Others: PET/USG/CT/MRI/DOPPLER

ASA Class: III RCRI: Aspiration Risk Y/N

Patient Choice of Anaesthesia: SAB + Epidural

Plan of Anaesthesia: SAB + Epidural

PRE OPERATIVE ADVICE

1. Fasting : Solids 8hrs

: Clear Fluids 2hrs

2. Informed written consent: Risk consent

3. Arrange blood, if any: 2 PRBC

4. ICU/Ventilator Requirement: Y/N

5. Cross consultations if any:

6. Premedications

(a) T pantop 40 mg } 45 min of Sx

(b) T Pendom 10 mg }

7. Medications to be continued:

8. Medications to withhold: OHA: OHD on morning of Sx, insulin

9. Investigations on the day of surgery: FBS, SE, UKB

10. Others: ~~Pre~~ optimize RBS < 200 mg/dl

Cross Consultations

Cardio – Low Cardiac risk

pulmo – mild risk if Gen. SAB may be preferred

REVIEW PAC: Seen by Dr: Date:

03/02/26

Patient Reviewed.

No fresh complaints.

Vitals

BP: 110/80 mmHg

HR: 91 bpm

SpO2: 99%.

RBS - 290

— Review in Gen medicine OPD for Glycemic control

- optimize GRBS < 200 mg/dl

IMMEDIATE PRE OPERATIVE ASSESSMENT

[redacted]

[redacted]

ADMISSION FILE

അനസ്തീഷ്യ സമ്മതപത്രം

[redacted]

(MRD No) [redacted]

1. [redacted]
2. [redacted]
3. [redacted]
4. [redacted]

അപകട സാധ്യത/സങ്കീർണ്ണതകൾ

1. Hypotension
2. PPPH
3.

പ്രയോജനങ്ങൾ

1. postop analgesia
2.
3.

[redacted]

[redacted]

[redacted]

ADMISSION FILE

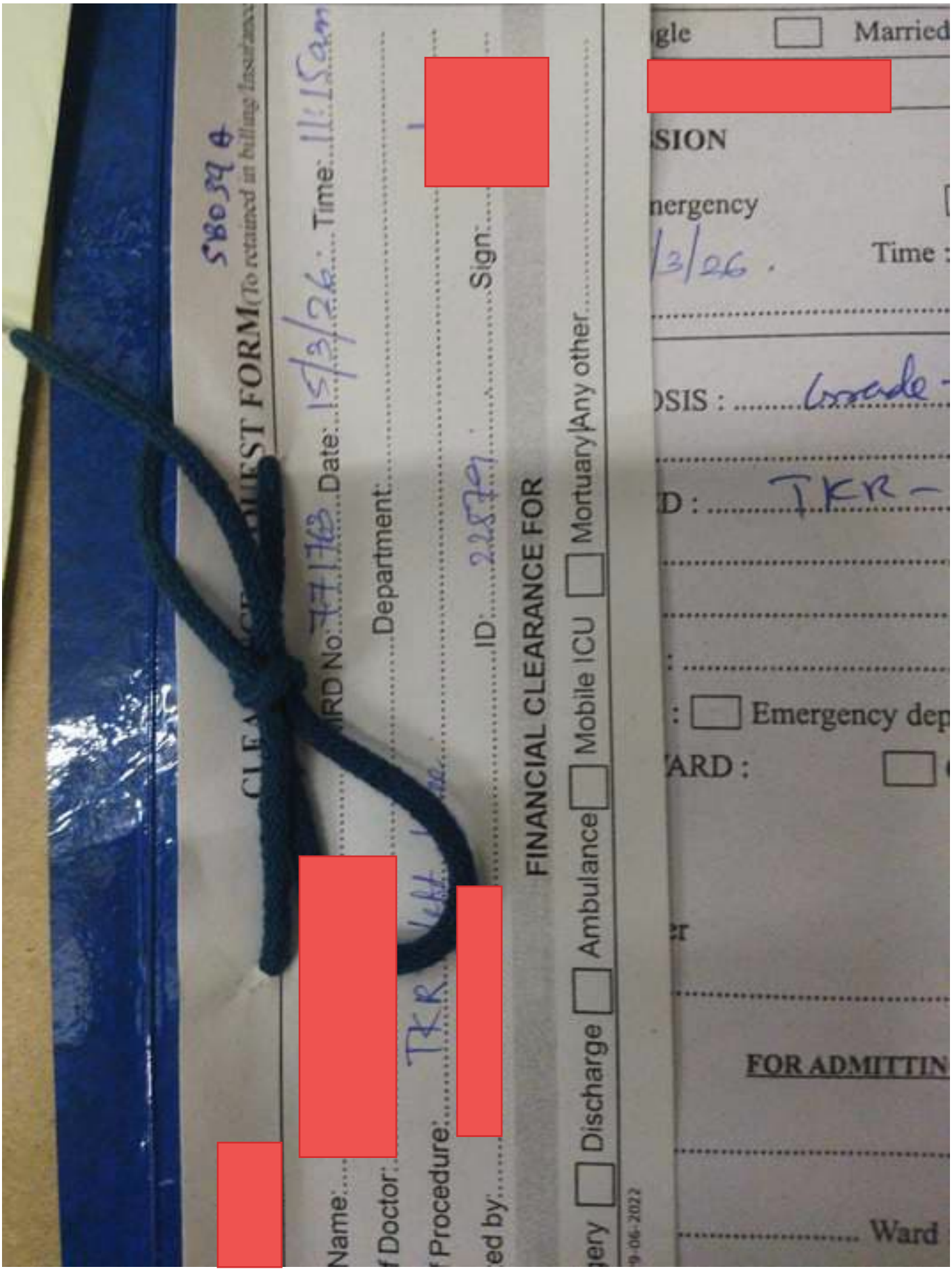

CLEARANCE REQUEST FORM (To retained in billing Insurance)

58059 A

Name: [redacted] IRD No: 77163 Date: 15/3/26 Time: 11:15am

Doctor: [redacted] Department: [redacted]

Procedure: TKR left knee [redacted]

Signed by: [redacted] ID: 22579 Sign: [redacted]

FINANCIAL CLEARANCE FOR

Emergency ☐ Discharge ☐ Ambulance ☐ Mobile ICU ☐ Mortuary/Any other

9-06-2022

[redacted]

gle ☐ Married

SION

nergency

/3/26. Time :

OSIS : Loosende-

D : TKR-

: ☐ Emergency dep

ARD : ☐

FOR ADMITTIN

Ward

ADMISSION FILE

[redacted]

ADMISSION REQUEST FORM

Patient's Name : [redacted]	MRD No. 771763		Age: 53 Sex: F
Marital Status: ☐ Single ☐ Married ☐ Others			Nationality:
Consultation in Charge [redacted]		Department	Ortho

CATEGORY OF ADMISSION

☐ Emergency ☐ Elective ☐ Others

Date of Admission : 15/3/26. Time :

Estimated Length of stay ..... Days / weeks

PROVISIONAL DIAGNOSIS : Grade-III Osteoarthritis Left knee

PROCEDURES PLANNED : TKR - Left knee

Date of surgical procedure : .....

SOURCE OF REFERRAL : ☐ Emergency dept ☐ Labour room ☐ Outpatient clinic ☐ Others

CHOICE OF ROOM IN WARD : ☐ General ☐ Private ☐ De'luxe

[redacted]

Signature of Medical Officer with Emp. No .....

Signature of Consultant in charge With Emp. No .....

FOR ADMITTING OFFICE USE ONLY

DEPARTMENT : .....

Unit : ..... Ward : ..... Bed No. : .....

Date of Admission : ..... Time : .....

Name of admitting clerk : ..... Sign. with Emp. No. : .....

[redacted]

ADMISSION FILE

[redacted]

DOCTOR'S INITIAL ASSESSMENT

Name: [redacted]
Age / sex: 63/F
MRD No: 771763

Ward / Bed No:
Unit: 01
Date: 15/7/25
Initial Assessment Start Time: 10:[illegible]

Consultant Doctor: [redacted]

Presenting complaints:

c/o pain over left knee. x 6 months.

History of Present Illness:

Elderly female patient k/c/o T2DM, came to OPD with c/o pain over left knee for past 6 months exacerbated for past 1 month. Patient had difficulty in getting up from sitting position and walking.

Past History:

k/c/o T2DM

Personal & Nutritional History:

Mixed diet
Normal appetite
Adequate sleep

History Allergy: Nil.

Medication History:

~~T. K Gliclazide 80mg 1-0-1~~ [redacted]
T. K Gliclazide 80mg 1-0-1
INS. R NOVOLIN 40 IU 30/70 28-0-14 [30 min before meal]

[redacted]

ADMISSION FILE

Family and & Socio Economic History:

History given by Name & Relation:

General Physical Examination:

Vital Signs:

Temperature	Pulse	B.P	Respiration	Height	Weight
N	82	130/80	20	—	—

Others: Built and Nourishment:

Pallor (+) Icterus (−) Cynosis (−)

Clubbing (−) Lymph Nodes (−) Edema (−)

Neck (−)

Systemic/ Local Examination:

CVS:

$S_1 S_2$ (+)

Respiratory System:

NVBS

CNS:

NFND

ADMISSION FILE

Abdomen:

Soft, NT.

Spine & Extrimities:

Normal

Local Examination:

O/E Left knee
No joint line tenderness
swelling (+)
Crepitus (+)
knee ROM terminal flexion painful
No DNVD.

Others:

Nil.

ADMISSION FILE

Provisional Diagnosis:

Grade-III Osteoarthritis left knee.

Investigation Plan:

Treatment Plan & Goal:

Early Mobilization.

Dietary Advice & Nutritional Assessment:

Diabetic diet

Expected Result:

fever

Possible Complications:

Sepsis, bleeding, knee stiffness.

Preventive Measures Advised:

Iritic Prophylaxis precautions.

Surgery/ Procedure Planned:

TKR - left knee.

I/ Relative have been explained about the care of plan, expected results and diagnostic testss

Patient/ Relative Name: .....

Signature: .....

Date: .....

Doctors Doing Initial Assessment	Incharge Consultant
Initial Assessment Completed Time: 11:00pm Name: [redacted] Signature with Reg. No: Employee ID: [redacted]	Name: [redacted] Signature with Reg. No: Employee ID:

Initial Assessment Completed Time :

Dr. Moc
Medica

Name:
Age / sex:
MRD No:

Date & Time	

ADMISSION FILE

[redacted]

[redacted]

PROGRESS NOTES & DOCTORS ORDERS

Name: [redacted]

Age / sex: 62/F

MRD No: 771763

Ward /Bed No:

Unit: 01

Date : 15/6/25

Date & Time	Progress Notes	Doctor's Orders	Signature
	Admit Under O1	Admit - Continue on medication.	[redacted]

ADMISSION FILE

[redacted]

Patient ID.	GESERVICE	Study Date	31-01-2026
Patient Name	[redacted]	Age/Sex	49/F
Ref By	[redacted]	Study	LT KNEE

MRI LEFT KNEE

Technique

MRI of the left knee was performed using multiplanar, multisequence imaging including T1-weighted, T2-weighted, PD, and fat-suppressed sequences.

FINDINGS

Loose Bodies / Synovial Pathology

- **A large well-defined loose body is noted in the popliteal fossa, just posterior to the PCL, measuring approximately 1.1 × 1.0 cm.**
- **Multiple additional loose bodies of variable sizes are noted:**
  - **Posterior to the medial and lateral femoral condyles**
  - **Along the lateral aspect beneath the lateral patellofemoral retinaculum**
- **These loose bodies are associated with:**
  - **Significant joint space effacement**
  - **Periarticular myofascial edema**
- **Imaging appearance is highly suggestive of synovial osteochondromatosis.**

Osseous Structures

- **Bone contusion / marrow edema changes** are noted involving:
  - **Medial femoral condyle**
  - **Lateral femoral condyle**
  - **Posterior condylar regions**
  - Adjacent **subarticular regions**
- **These findings are likely secondary to mechanical impingement from multiple intra-articular loose bodies.**
- *No acute fracture line is identified*

Articular Cartilage

- **Severe chondral loss (Grade IV chondromalacia) involving the patella, predominantly along the medial patellar facet, with near-complete cartilage denudation.**
- **Moderate osteoarthritic changes** are noted in the knee joint, with:
  - Diffuse cartilage thinning
  - Marginal osteophytic changes

REPORTING STATIONARY