RADIOLOGY DEPARTMENT

Name: [redacted] Age / Sex: 65 Yrs / Male Date: 04.03.2026

RADIOGRAPH OF RIGHT KNEE (AP/ LATERAL VIEW)

Soft tissues appear normal

Total knee replacement status noted.

Joint spaces are preserved.

[redacted]
Radiologist

(This report is not for medico legal cases , Please co-relate clinically / with other relevant investigation)

FACILITIES AVAILABLE

[redacted]

1.5T Magnetic Resonance Imaging (MRI) • 50 slice Computerized Tomography (CT) Scan • Digital Radiography (X-ray), Barium Study, HSG • Ultrasound (3D & 4D) • Colour Doppler study • USG guided procedure • Digital Mammography • Angiography • Fluoroscopy Interventional Radiology (Varicose vein laser ablation • DSA, embolisation, TACE, aneurysm coiling) • Image guided FNAC / Biopsy • Advanced Non-Invasive Vascular Imaging (CTA / MRA)

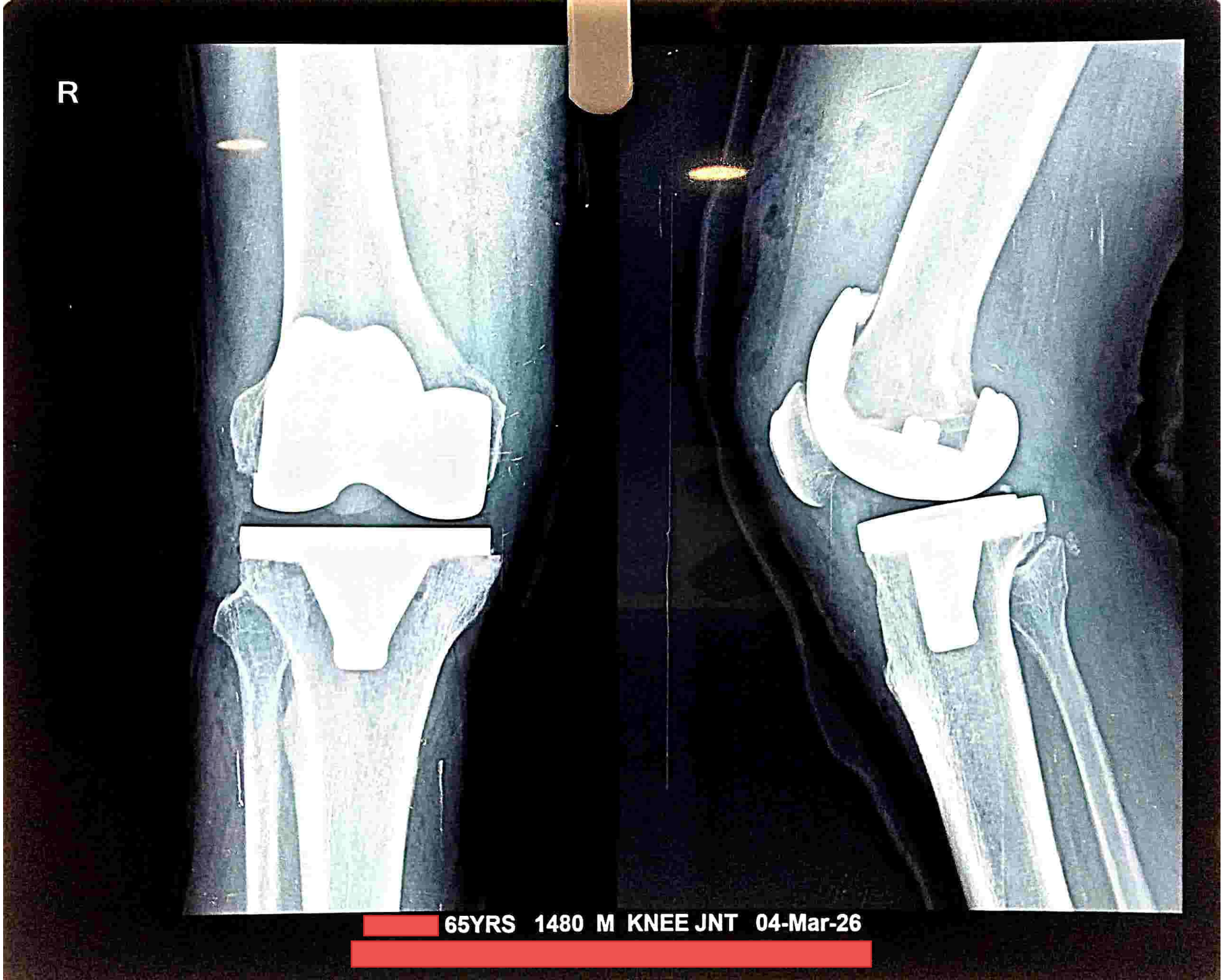
R
65YRS 1480 M KNEE JNT 04-Mar-26