[redacted]

[redacted]

Patient Name	[redacted]	Time	12:47
Referring Dr.	[redacted]	Date	12-Feb-2026

U.S.G. ABDOMEN

Liver normal in size and shows increased echogenicity. No evidence of any focal lesion. Portal vein is normal in caliber. No evidence of dilatation of intrahepatic billiary radicles.

Gall bladder is over distended and shows small gravel sized stones .Gall bladder wall thickness is about 3.0 mm. Presences of small gb polyp of size about 5.0 mm noted. No evidence of pericholecystic collection.
CBD is normal in diameter, 5 mm. No evidence of stone in CBD noted on present examination.

Pancreas is normal in size and echogenicity. MPD is not dilated. No evidence of peri pancreatic collection.
No evidence of free fluid in peritoneal cavity.

Spleen normal in size and echogenicity. No evidence of any focal lesion.

Right Kidney,9.8 cm x 5.0 cm is normal in size, shape & position. No evidence of stone. No evidence of dilatation of P.C. system & right upper ureter. Cortical thickness & echo appears normal.

Left Kidney,8.5 cm x 4.5 cm is normal in size, shape & position. No evidence of stone. No evidence of dilatation of P.C. system & left upper ureter. Cortical thickness & echo appears normal.

Urinary bladder is partially distended.

Uterus is small atrophied.

No evidence of free fluid in peritoneal cavity.
Small and large bowel loops appears normal in caliber.

IMPRESSION	OVER DISTENDED GALL BLADDER WITH CHANGES OF CALCULUS CHOLECYSTITIS. SMALL GB POLYP. NO EVIDENCE OF CBD STONE OR PANCREATITIS AT PRESENT. ==> CLINICO-PATHOLOGICAL CO-RELATION SUGGESTED.

[redacted]

[redacted] Consultant Radiologist | [redacted] Consultant Radiologist | [redacted] Consultant Radiologist | [redacted] Consultant Radiologist

SG 150

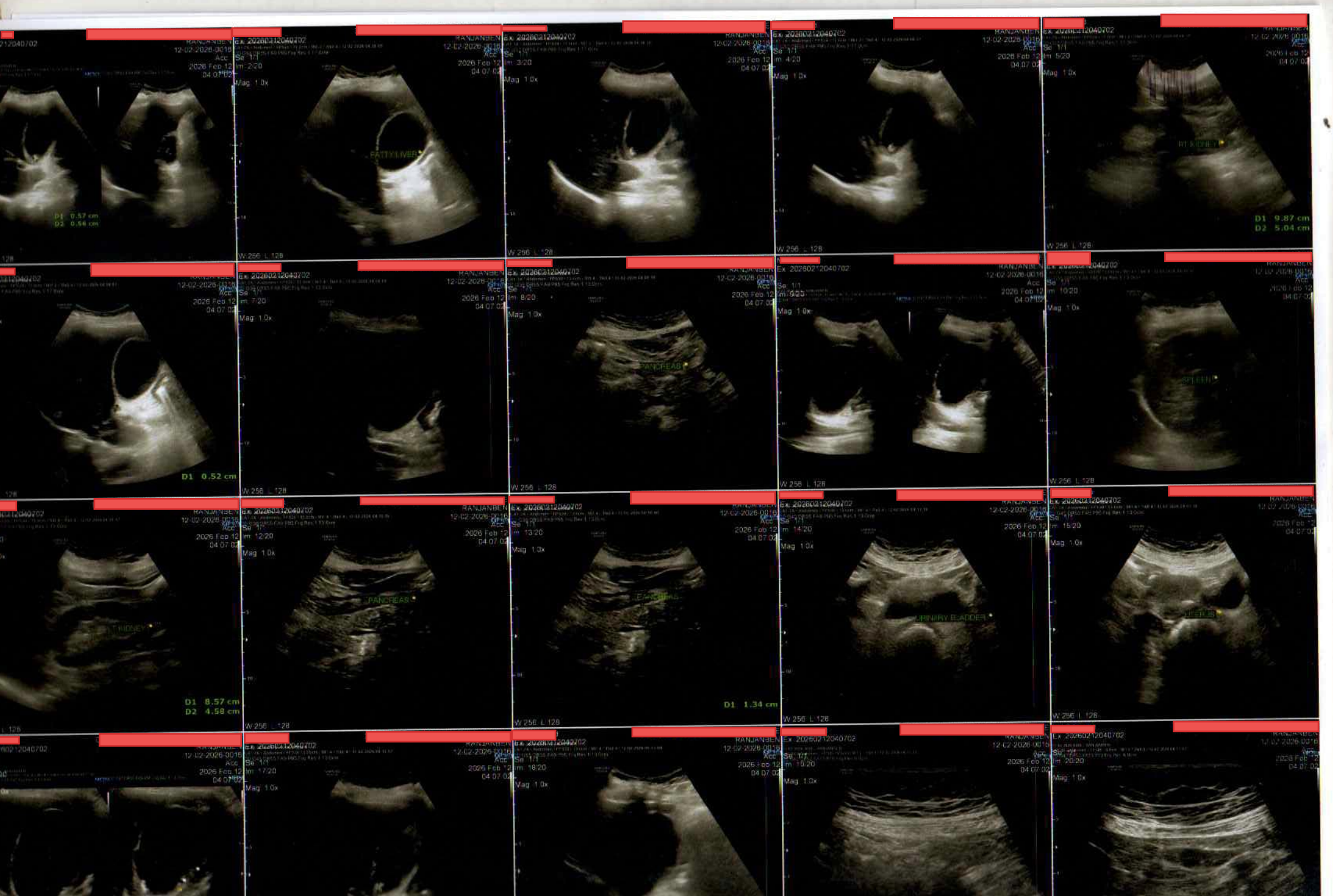
D1 0.57 cm
D2 0.56 cm
FATTY LIVER
D1 9.87 cm
D2 5.04 cm
D1 0.52 cm
PANCREAS
SPLEEN
D1 8.57 cm
D2 4.58 cm
PANCREAS
D1 1.34 cm
URINARY BLADDER