[redacted]

ENDOSCOPY UNIT

Patient Name: [redacted]
Contact #:
Patient ID:
Referred Dr: [redacted]
Procedure: UGI SCOPY

Age/Gender: 17Yrs, Female
Visit Date: 15/07/2024
Consulted Dr: [redacted]
Medication: LA

Esophagus : NORMAL ; OG JUNCTION - 38 CM ;

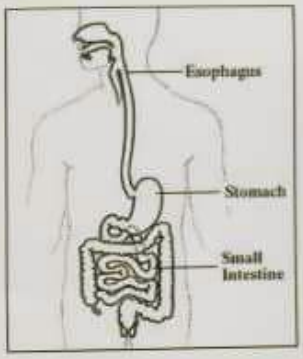

Stomach

- **Fundus** : ERYTHEMATOUS MUCOSA ;
- **Body** : ERYTHEMATOUS MUCOSA ;
- **Antrum** : ERYTHEMATOUS MUCOSA - BX FOR H.PYLORI RUT ;
- **Pylorus** : Normal

Duodenum

- **D1** : Normal
- **D2** : Normal

Impression : GASTRITIS - ANTRAL BX FOR H.PYLORI RUT ;

[redacted]

Visit Summary

[redacted]

CaptureITPro - www.ambalsoft.com

vivo T2 Pro
short by [redacted] Dec 18, 2025, 10:49

[redacted]

Patient name	DHARSHINI	Age/Sex	
Patient Id	171125-093601AM	Visit no	1
Referred by		Visit date	17/11/2025

vivo T2 Pro 5G
short by [redacted]
Dec 18, 2025, 10:49

vivo T2 Pro 5G

shot by [redacted] Dec 18, 2025, 10:49