DeepCA: Deep Learning-based 3D Coronary Artery Tree Reconstruction from Two 2D Non-simultaneous X-ray Angiography Projections

Yiying Wang, Abhirup Banerjee, Robin P. Choudhury, Vicente Grau

{yiying.wang, abhirup.banerjee, vicente.grau}@eng.ox.ac.uk, robin.choudhury@cardiov.ox.ac.uk

IEEE COMPUTER SOCIETY · CVF · WACV 2025 · TUCSON, ARIZONA • FEB 28 - MAR 4

GitHub

NHS The John Radcliffe Hospital · DEPARTMENT OF ENGINEERING SCIENCE · UNIVERSITY OF OXFORD · IBME

Background

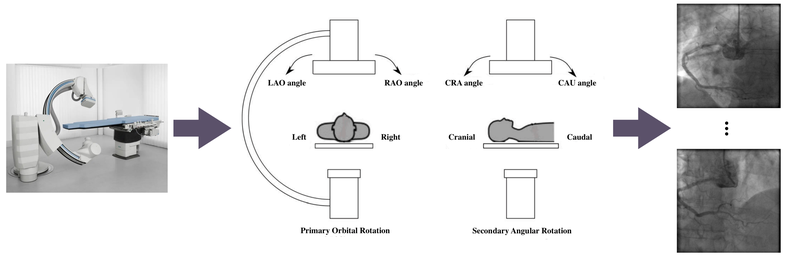

(Siemens single-plane C-arm) (C-arm imaging geometry) (ICA images)

- X-ray invasive coronary angiography (**ICA**) acquires 2D projections of coronary artery tree (based on C-arm) and is the gold standard during cardiac interventions

Motivation & Challenges

3D reconstruction of coronary artery tree from **two 2D ICA** projections helps:

- Reduce the likelihood of subjective 3D geometry interpretation
- Reduce extra contrast injected and extra X-ray radiation dose exposed
- Using **deep learning** helps:
  - Automated 3D reconstruction in real time
  - **Implicitly compensate** for the non-rigid cardiac and respiratory motions

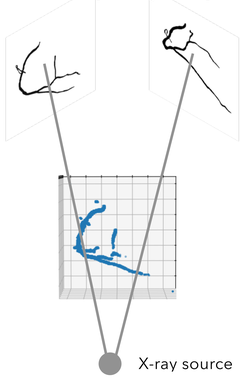

This task is hard because:

- **Non-rigid** motion by **non-simultaneous acquisition**, causing vessels to misalign between projections
- Only **two** projections acquired
- **No corresponding 3D ground truth**
- **No prior work** to tackle the non-simultaneous ICA projections using deep learning

Method

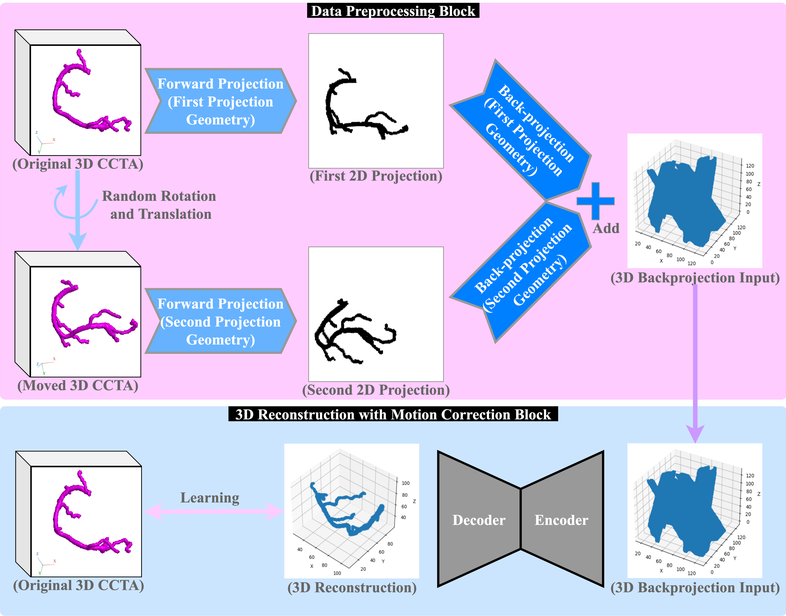

Our encoder-decoder architecture is based on the Wasserstein conditional generative adversarial network (**WCGAN**) with gradient penalty (**WGP**), latent convolutional transformer layers (**CTLs**), and a dynamic snake convolutional critic (**DSCC**)

- Via mapping the input with non-aligned projections to 3D coronary tree data, **most motion artifacts are corrected** by our model
- With the critic used, **any residual deformations are adjusted**, while ensuring the connectedness of coronary artery tree structures and increasing the model's elastic generalisation capacity
- So when generalising to **clinical non-simultaneous** ICA projections for **3D coronary artery tree reconstruction**, the **non-rigid** motion is **compensated implicitly**

Evaluation Method

Datasets:

- Use a **public** Coronary Computed Tomography Angiography (**CCTA**) dataset (ImageCAS) for training
- Collect a **clinical ICA dataset** from the John Radcliffe Hospital for evaluation

Metrics:

- Overlap using a sweeping distance threshold Ot(t_0) (%) **&** Chamfer distance (CD($\ell 2$)) (mm)

Results

Model	3D CCTA Test Dataset			2D Real Clinical ICA Dataset (Unseen Domain)						
				1st	2nd Projection			Additional Projection		
	$Ot(1)\uparrow$	$Ot(2)\uparrow$	$CD(\ell_2)\downarrow$	Dice ↑	$Ot(1)\uparrow$	$Ot(2)\uparrow$	$CD(\ell_2)\downarrow$	$Ot(1)\uparrow$	$Ot(2)\uparrow$	$CD(\ell_2)\downarrow$
U-Net++	51.99 (±12.17)	64.75 (±13.28)	4.64 (±2.01)	65.42 (±6.68)	22.97 (±10.82)	31.05 (±12.76)	12.79 (±4.61)	25.25 (±18.40)	39.37 (±20.75)	8.49 (±3.26)
U-Net+++	55.10 (±10.72)	68.69 (±10.96)	4.49 (±1.67)	62.23 (±9.49)	22.27 (±8.30)	30.19 (±10.51)	12.20 (±3.77)	32.92 (±23.99)	42.37 (±26.30)	7.70 (±1.59)
Dynamic Snake Convolution Net	61.74 (±14.28)	72.21 (±13.31)	3.49 (±1.68)	**83.59** (±4.01)	30.66 (±11.30)	42.74 (±11.68)	7.81 (±2.19)	53.26 (±6.74)	67.90 (±4.77)	3.92 (±0.48)
Convolutional Vision Transformer GAN	61.53 (±11.49)	73.71 (±10.75)	3.51 (±1.36)	76.84 (±5.73)	32.98 (±12.29)	44.85 (±15.85)	8.23 (±3.73)	49.50 (±0.82)	64.63 (±3.05)	4.22 (±0.51)
DeepCA	**64.21** (±10.78)	**76.25** (±9.72)	**3.22** (±1.20)	83.31 (±4.32)	**45.70** (±6.79)	**58.39** (±8.42)	**4.51** (±1.29)	**58.58** (±4.01)	**72.88** (±0.90)	**2.81** (±0.06)

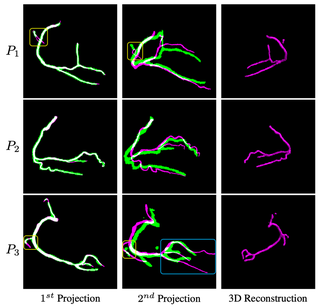

From left to right: the comparisons of three patients $P_{1,2,3}$ between ICA data and our reprojections on the **first** and **second** projection planes after rigid registration, and our model's **3D reconstruction results**

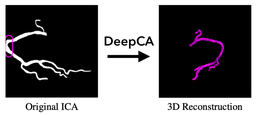

(Recovering missing features)

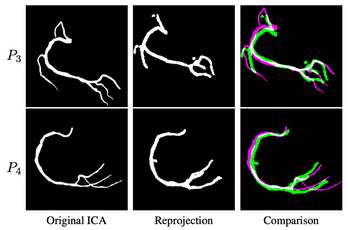

From left to right: the original ICA data, the reprojections on **the additional projection plane**, and the comparisons between them after rigid registration of two patients $P_{3,4}$

(The colour **purple** represents ICA data, **green** the reprojection, and **white** the overlap)