pharmaceuticals

Article

Tocilizumab Exerts Anti-Tumor Effects on Colorectal Carcinoma Cell Xenografts Corresponding to Expression Levels of Interleukin-6 Receptor

Yuan-Chiang Chg[1,2], Szu-Jung Chen[3], Chiu-Chen Huang[4], Wei-Chun Liu[5], Mingsung Lai[6], Ting-Yu Kao[7], Wei-Shun Yang[8], Chien-Hui Yang[9], Chih-Ping Hsu[7,10,*] and Jia-Feng Chang[11,12,*]

1 Department of Surgery, Kuang Tien General Hospital, Taichung 433, Taiwan; chung11753@ktgh.com.tw
2 Department of Surgery, Chung-Kang Branch, Cheng-Ching General Hospital, Taichung 407, Taiwan
3 Department of Radiation Oncology, Taoyuan General Hospital, Ministry of Health and Welfare, Taoyuan 330, Taiwan; csj995@yahoo.com.tw
4 Department of Post-Baccalaureate Veterinary Medicine, Asia University, Taichung 413, Taiwan; cch99@asia.edu.tw
5 Department of Pathology, Hsin-Chu Branch, National Taiwan University Hospital, Hsinchu 300, Taiwan; fox66018@gmail.com
6 Department of Pathology, Taichung Hospital, Ministry of Health and Welfare, Taichung 403, Taiwan; lukemtlai@gmail.com
7 Department of Medical Laboratory Science and Biotechnology, Yuanpei University of Medical Technology, Hsinchu 300, Taiwan; tingyu@mail.ypu.edu.tw
8 Department of Internal Medicine, Hsin-Chu Branch, National Taiwan University Hospital, Hsinchu 300, Taiwan; weishun.yang@gmail.com
9 Department of Business Administration, Yuanpei University of Medical Technology, Hsinchu 300, Taiwan; chyang@mail.ypu.edu.tw
10 Department of Biotechnology and Pharmaceutical Technology, Yuanpei University of Medical Technology, Hsinchu 300, Taiwan
11 Division of Nephrology, Department of Internal
Taoyuan 330, Taiwan
12 Department of Nursing, Yuanpei University of
*
Correspondence:hsucp@mail.ypu.edu.tw (C.-P.H.); cjf6699@gmail.com (J.-F.C.)

check for updates

Citation: Chung, Y.-C.; Chen, S.-J.; Huang, C.-C.; Liu, W.-C.; Lai, M.-T.; Kao, T.-Y.; Yang, W.-S.; Yang, C.-H.; Hsu, C.-P.; Chang, J.-F. Tocilizumab Exerts Anti-Tumor Effects on Colorectal Carcinoma Cell Xenografts Corresponding to Expression Levels of Interleukin-6 Receptor. *Pharmaceuticals* **2024**, *17*, 127. https://doi.org/10.3390/ph17010127

Academic Editor: Nektarios Barabutis

Received:24 November 2023 Revised:29 December 2023 Accepted:11 January 2024 Published:18 January 2024

Copyright:©2024bytheauthors.

LicenseeMDPI,Basel,Switzerland. Thisarticleisanopenaccessarticle distributed under the terms and conditions of the Creative Commons Attribution (CC BY) license (4.0/).

Abstract: The use of tocilizumab against the interleukin-6 receptor (IL-6R) has been demonstrated as inhibiting the progression of diverse cancers in vitro and in vivo.Nonetheless, evidence regarding the anti-tumor effects of tocilizumab on human colorectal carcinoma (CRC) corresponding to IL-6R expression levels remains scarce.To investigate the influence of IL-6R expression, SW480 and HT-29 cellsinoculatedsubcutaneouslyintoNU/NUmicewereusedashumanCRCxenograftmodels withanti-IL-6Rantibody(tocilizumab)therapy.TheIL-6Rexpressionlevels,histologyofCRC growth/invasiveness, and tumor growth-related signaling pathway were estimated by H&E responsiveness in tocilizumab therapy than in the treated HT-29 group.Likewise, therapeutic effects of tocilizumab on the proliferative ability with mitotic index and Ki-67 expressions, invasiveness with MMP-9 proteinase expressions, and ERK 1/2 and STAT3 signaling transduction in the SW480 treatment group were superior to the HT-29 treatment group.In light of our results,IL-6R is the keyindicatorfortheefficacyoftocilizumabtreatmentinCRCxenografts.Fromtheperspective ofprecisionmedicine,tumorresponsetoanti-

Keywords: interleukin-6 receptor; colorectal carcinoma;

1.Introduction

Interleukin-6receptor(IL-6R),stimulatedbyIL-6,triggersintricatecellfunctions includingimmunecellactivation,hematopoieticstemcelldifferentiation,cancers,and inflammatory bowel diseases [1–3].Not only our earlier research but also recent studies have pointed out that IL-6 levels in serum or tissue were associated with disease status, including proliferative tumor activity, angiogenesis, metastasis, and patient prognosis in colorectal cancer (CRC) [4–10].Indeed, research derived from the Cancer Genome Atlas (TCGA) database proved that the IL-6R/STAT3/miR-34a loop is active in primary human CRCs, contributing to a mesenchymal phenotype of tumor cells, along with invasion and metastasis [11].In addition to the above research implications, IL-6 signaling transduction could serve as a potential target to treat CRC [12].Evidence has revealed anti-IL-6 anti-bodies were responsible for promising strategies to treat various cancers [13].Notably, our previous CRC cell model demonstrated that anti-IL-6 receptor antibodies suppressed colonyformation in soft agar and the invasiveness of SW480, which was stimulated by IL-6 [14]. We subsequently discovered that JAK/STAT3, PI3K/AKT, and MEK/ERK-1/-2 pathways were involved in IL-6-induced clonogenicity and invasiveness of SW480, and the neutral-izationofIL-6RcouldreversetheIL-6effectonsignalingtransduction,suggestingthe potential therapeutic role of the anti-human IL-6R antibodies in CRC cell progression [15]. Morerecently,wefurtherdemonstratedthatinjectiontherapyofanti-IL-6Rantibodies suppressed the tumor growth of SW480 xenograft and attenuated the proliferation marker Ki-67, along with down-regulating JAK/STAT3, PI3K/AKT, and MEK/ERK-1/-2 signalingpathways [16].Whether IL-6R expression levels in CRC tumors are capable of affecting the efficacy of anti-IL-6R antibody treatment remains unclear.Based on the different IL-6R mRNA levels in SW480 and HT-29 cells [17], the tumor responses to anti-IL-6R antibody treatment were compared between xenografts of SW480 and HT-29 cells in NU/NU mice, including tumor growth, invasivenessin vivo, and the underlying mechanism.We hypothesized IL-6R expression of CRC could be the key factor to influence the tumor response to anti-IL-6R antibody therapy.

2.Results

2.1.Human CRC SW480 Tumor Xenografts Expressed Higher Levels of IL-6 Receptor Than HT-29 Xenografts

The tumors resected from the xenografts inoculated with SW480 or HT-29 cells were fixedandembeddedinparaffin,thenslicedandstainedwithIL-6receptorantibodies using immunohistochemical staining.As shown in Figure 1, medium brown stained cells scattered with some dark brown stained spots were found in SW480 tumors (Figure 1A), whereas light brown stained cells were found in HT-29 tumors (Figure1B). The IHC overallscores for the of IL-6 receptor in SW480 tumor slices was approximately 100, whereas in the HT-29 tumor slices it was less than 20 (Figure 1C). Obviously, the expression levels of the IL-6 receptor in SW480 tumors was higher than that in HT-29 tumors.

2.2.Inhibitory Effect of Anti-IL-6R Antibody Treatment (Tocilizumab; ACTEMRA®) on the Tumor Growth of Human CRC SW480 Xenografts Was Superior to the Treated Group of HT-29 Xenografts

As shown in Figure 2, the tumor size of both untreated SW480 and HT-29 xenografts gradually grew from a volume of 100 $mm^3$to approximately 400 mm^3after 11 days.In the anti-IL-6R antibody (tocilizumab; ACTEMRA®, Rhoch Inc., San Francisco, CA, USA) treatment group, the tumor growth was inhibited only in the SW480 xenografts.The tumorwas almost sustained at its original size after 7 days and had increased to approximately 160 mm^3at the end of the experiment.In contrast to the treated group of SW480, the tumorsin the Actemra-treated HT-29 xenograft group showed similar growing potential to the untreated group after 7 days, despite having a slight decrease due to treatment at the end of the experiment.Although the average tumor volume in the treated-HT-29 group was lowerthan that in the untreated group, the difference between the groups was not statistically

significant.The results showed the tumor response to anti-IL-6R antibody therapy was associated with the IL-6R expression levels in the human CRC xenografts.

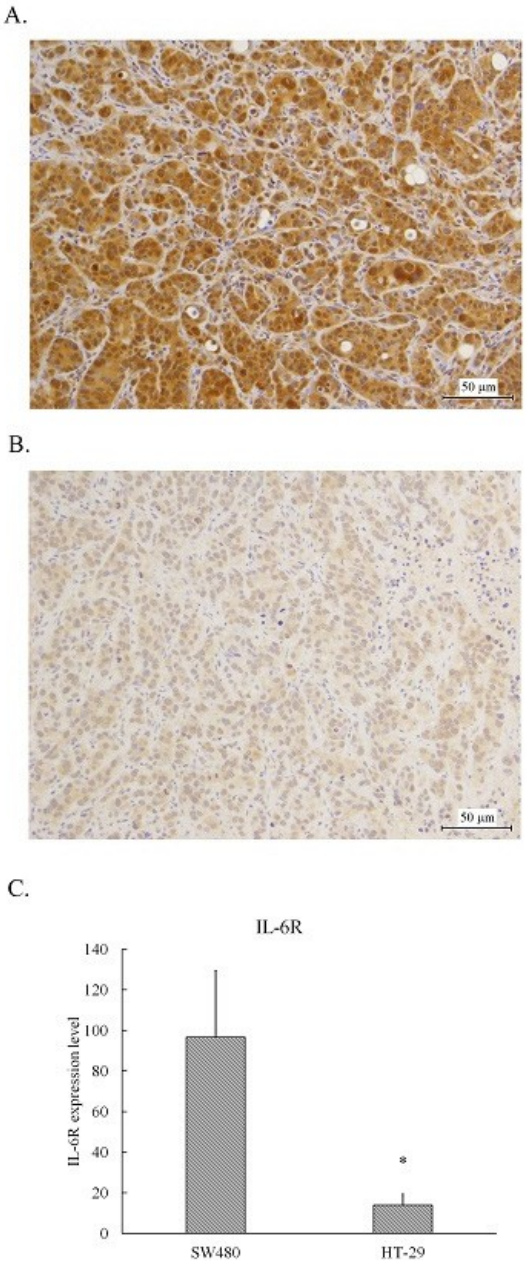

Figure 1.IL-6R expression level in the human colorectal carcinoma SW480 and HT-29 xenografts. Representative images of tumor tissues from the untreated SW480 (**A**) and HT-29 (**B**) were captured. TheimmunologicalactivityofIL-6Risrepresentedastheaverageofscoresbycalculatingthe percentage and intensity of 10 different areas of a 400X image for each tumor image examined.The statistical results are shown as means ± SEM and significant differences between the SW480 and HT-29 are indicated * $p < 0.05$ (**C**).

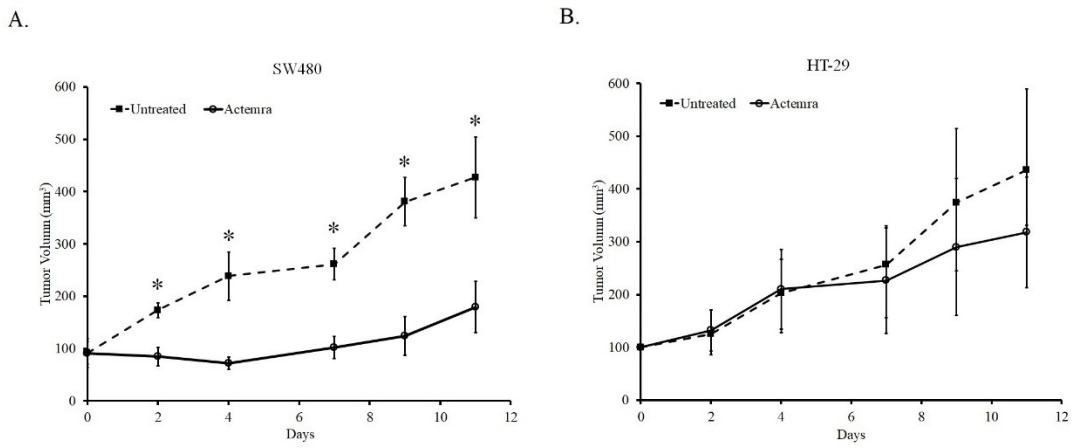

Figure 2. Inhibition effect of anti-IL-6R antibodies on the tumor growth of human colorectal carcionma SW480 and HT-29 xenografts.SW480 and HT-29 cells (5 × 10^6) were inoculated subcutaneously into NU/NU mice and peritoneal injection with 1 mg/kg anti-IL-6R antibodies (tocilizumab; ACTEMRA®) or PBS were administered three times a week.Tumor volume was measured, and data of each group **were averaged from tumor volmues of five mice and are represented as means** ± SEM. The tumor growth curve of SW480 (**A**) and HT-29 (**B**) xenografts are shown.* $p < 0.05$.

2.3.Inhibition Effect of Anti-IL-6R Antibody Treatment (Tocilizumab; ACTEMRA®) on the Tumor Cell Proliferation of Human CRC SW480 Xenografts Was Superior to the Treated Group of HT-29 Xenografts

The cell proliferative ability of CRC in SW480 and HT-29 xenografts was evaluated by H&E staining for mitotic cells and IHC staining for anti-Ki-67 antibodies on the tumor slices.As shown in Figure 3A, some cell nuclei of untreated SW480 tumors disappeared and were replaced with deep dark blue chromosomes, which were identified as the mitotic cells(yellowarrow).However,themitoticcellsinanti-IL-6Rantibody-treatedSW480 tumorswerefewerthanintheuntreatedtumors(Figure3B).Ontheotherhand,the mitotic cells in the tumors of untreated HT-29 xenografts were more than that of SW480 (Figure 3C), whereas similar numbers of mitotic cells were also found in treated HT-29 tumors (Figure 3D). To further confirm the cell-dividing potential in the tumors of CRC xenografts, Ki-67 expression in the tumor slices was assessed using IHC staining.The Ki-67positive cells were scattered on the mitotic cells of tumor slices in untreated SW480 and HT-29 cell xenografts (Figure 3E,G). Only a few cells were Ki-67 positive on Actemra-treated SW480 tumor slices (Figure 3F). However, Actemra-treated HT-29 tumors showed more Ki-67 positive cells than the treated SW480 group (Figure 3H). Based on the calculation of the mitotic index on these tumor slices, untreated SW480 showed 8% of total cells, in contrast to only 3% in the Actemra-treated SW480 group (Figure 3I). Both untreated and treated HT-29 showed more than 12% mitotic cells with an insignificant difference between the two groups.The number of dividing cells in each group were further confirmed by Ki-67 positive cells.There was no significant difference between the treated and untreated HT-29 groups.On the contrary, less than 15% Ki-67 positive cells were found in the treated SW480 group,compared with approximately 30% positive cells in the untreated group (Figure 3J). The results indicated that the therapeutic effect of anti-IL-6R on cell proliferative ability was closely correlated with IL-6R expression level in CRC tumors.

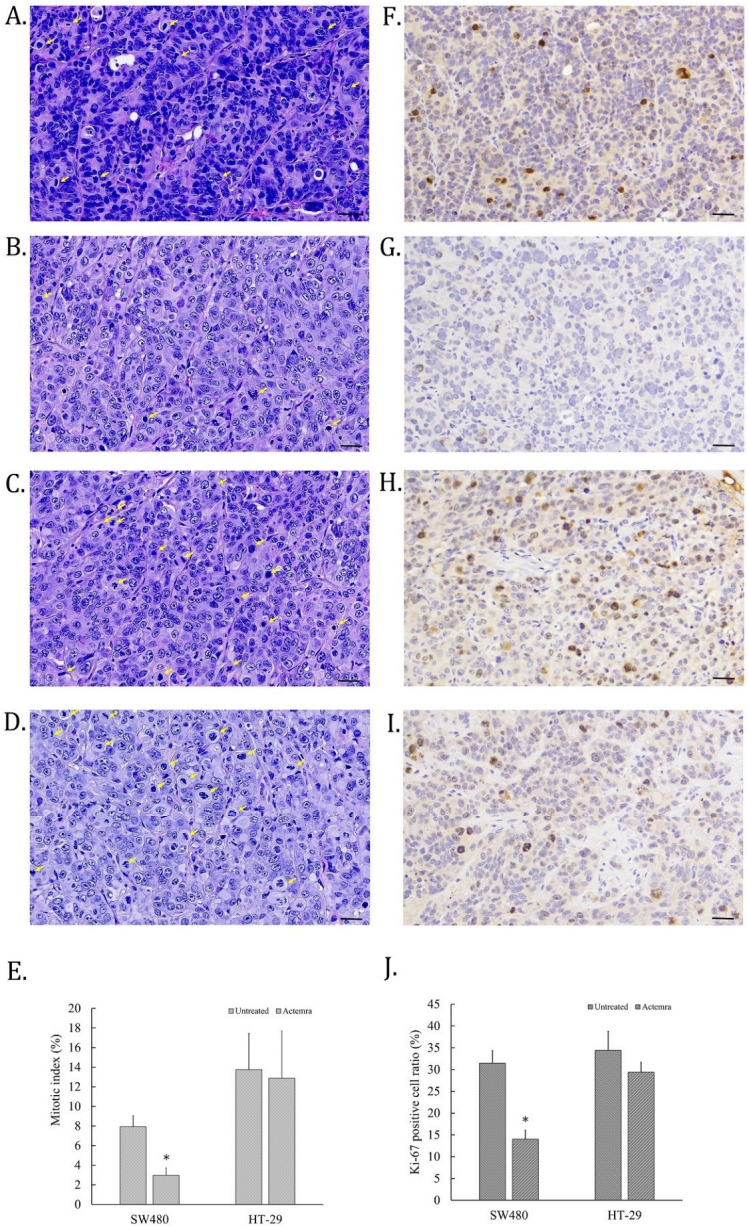

Figure 3. The mitotic index and Ki-67 expression in anti-IL-6R antibody treatment of human colorectal carcinoma SW480 and HT-29 xenografts.At the end of anti-IL-6R antibody treatment, tumors were processed into paraffin slices and then stained with H&E or anti-Ki-67 antibodies for immunohis-tochemical staining.The images were scanned using a micro scanner, as described in the Section 4. Representative H&E images of tumor tissues from the untreated SW480 (**A**), anti-IL-6R antibody (tocilizumab; ACTEMRA®)-treated SW480 (**B**), untreated HT-29 (**C**), and anti-IL-6R antibody-treatedHT-29 (**D**) were captured (black bar as 30 µm long).The mitotic cells on the images are indicated by a yellow arrow and the mitotic index of each group is averaged from 10 different areas and is shown as means ± SEM; (**E**). Representative images of Ki-67 immunohistochemical staining of tumortissue from the untreated SW480 (**F**), anti-IL-6R antibody-treated SW480 (**G**), untreated HT-29 (**H**), and anti-IL-6R antibody-treated HT-29 (**I**) were captured.The Ki-67 positive cells were calculated as a percentage of the total tumor cells in the tumor area of the image, shown as means ± SEM (**J**). * $p < 0.05$.

2.4.Inhibition Effect of Anti-IL-6R Antibody Treatment (Tocilizumab; ACTEMRA®) on the BM quantum computers leverage furnitureCell Invasiveness of Human CRC SW480 Xenografts Was Superior to the Treated Group of HT-29 Xenografts

The tumor cells invading the surrounding tissue in SW480 and HT-29 xenografts were evaluatedbymorphologicalfeaturesusingH&Estainingandtheexpressionofmatrix metaloprotease-2 and -9 (MMP2 and MMP9) on the tumor slices.As shown in Figure 4A, theedgeofthetumorwasdispersed,andsomecancercellsinfiltratedintothemuscle layer in untreated SW480 tumors.However, anti-IL-6R antibody-treated SW480 tumors were surrounded with fiber tissues (Figure 4B). Both untreated and treated HT-29 tumors showed CRC cells infiltrating into the surrounding tissue (Figure 4C,D). The expression ofMMP-9inuntreatedSW480tumorcells(Figure4E)washigherthaninthetreated SW480 group (Figure 4F). In contrast, equal expression levels were found in both untreated (Figure4G) and treated HT-29 tumor cells (Figure 4H). However, the expression of MMP-2in all tested tumor cells did not seem to differ (Figure 4I–L). The intensity of the MMP-9 expression in the treated SW480 tumors was lower than in the untreated SW480 tumors (Figure 4M), whereas there was no difference between the untreated and treated HT-29 tumors (Figure 4N). The results revealed that the invasion potential of SW480 tumors was suppressed by anti-IL-6R antibody treatment through suppressing MMP-9 expression in treated tumors, corresponding to the expression level of the IL-6R in the tumors.

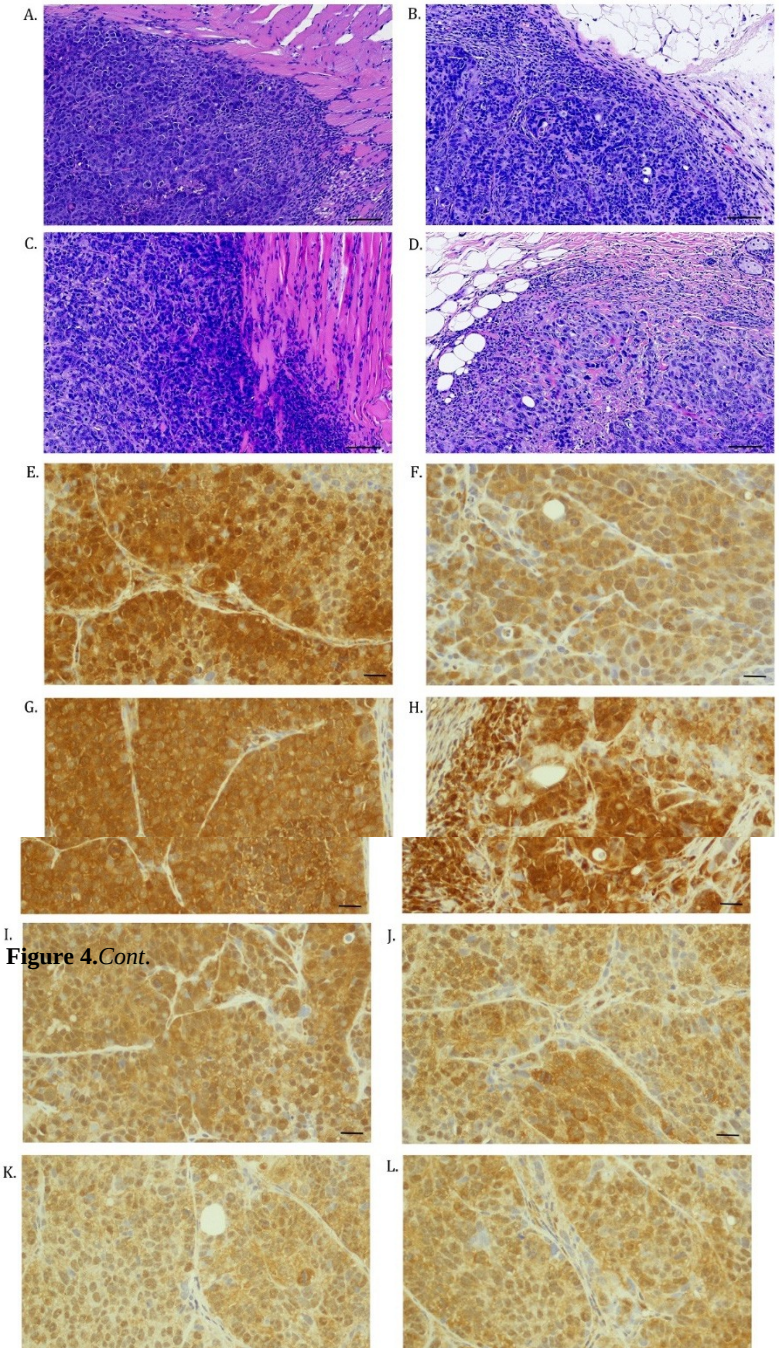

Figure 4.*Cont.*

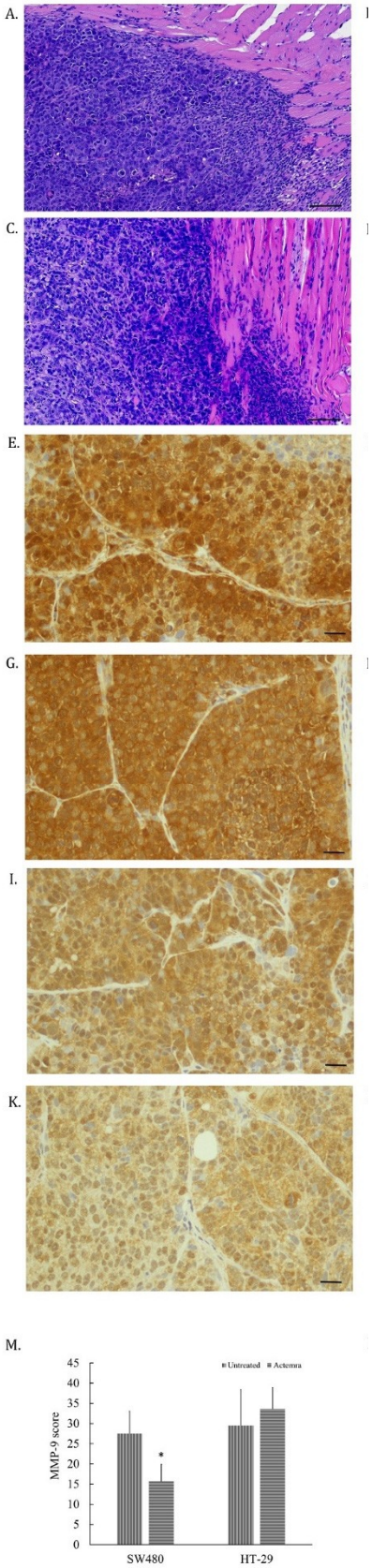

Figure 4. Invasiveness and MMP-9/-2 expression in anti-IL-6R antibody treatment of human colorectalcarcinomainSW480andHT-29xenografts.Tumorsliceswerestainedwithanti-MMP-9 or anti-MMP-2 antibodies via immunohistochemical staining and the images were scanned using a micro scanner,as described in the Section 4.The tumor invasiveness was first evaluated in the H&E staining slices and representative images showing the edges between tumor and normal tissue werecaptured(blackbaris60µmlong).TheedgesoftheuntreatedSW480tumorshadrough, spiculated, and blurry boundaries, and some tumor cells had invaded into the muscle layer of the mouse abdomen (**A**). The edges of the anti-IL-6R antibody-treated SW480 tumors were surrounded by fibrotic tissue with smooth, round, and well-circumscribed boundaries.(**B**). As opposed to Figure5B, the edges of both untreated (**C**) and tocilizumab (ACTEMRA®)-treated HT-29 tumors (**D**) were also rough, spiculated, and blurry, with invasion of

infiltrating malignant cells into the muscle layer and fatty tissue of the mouse abdomen.Representative images of MMP-9 staining in tumor slices were captured from the untreated SW480 (**E**), anti-IL-6R antibody-treated SW480 (**F**), untreated HT-29 (**G**), and anti-IL-6R antibody-treated HT-29 (**H**) xenografts (black bar is 30 μm long).MMP-2 images werealso captured from the untreated SW480 (**I**), anti-IL-6R antibody-treated SW480 (**J**), untreated HT-29 (**K**), and anti-IL-6R antibody-treated HT-29 (**L**) xenografts.The total score of MMP-9 from each groupwas averaged from 10 different areas and is shown as means ± SEM (**M**), and MMP-2 shown in (**N**). * $p < 0.05$.

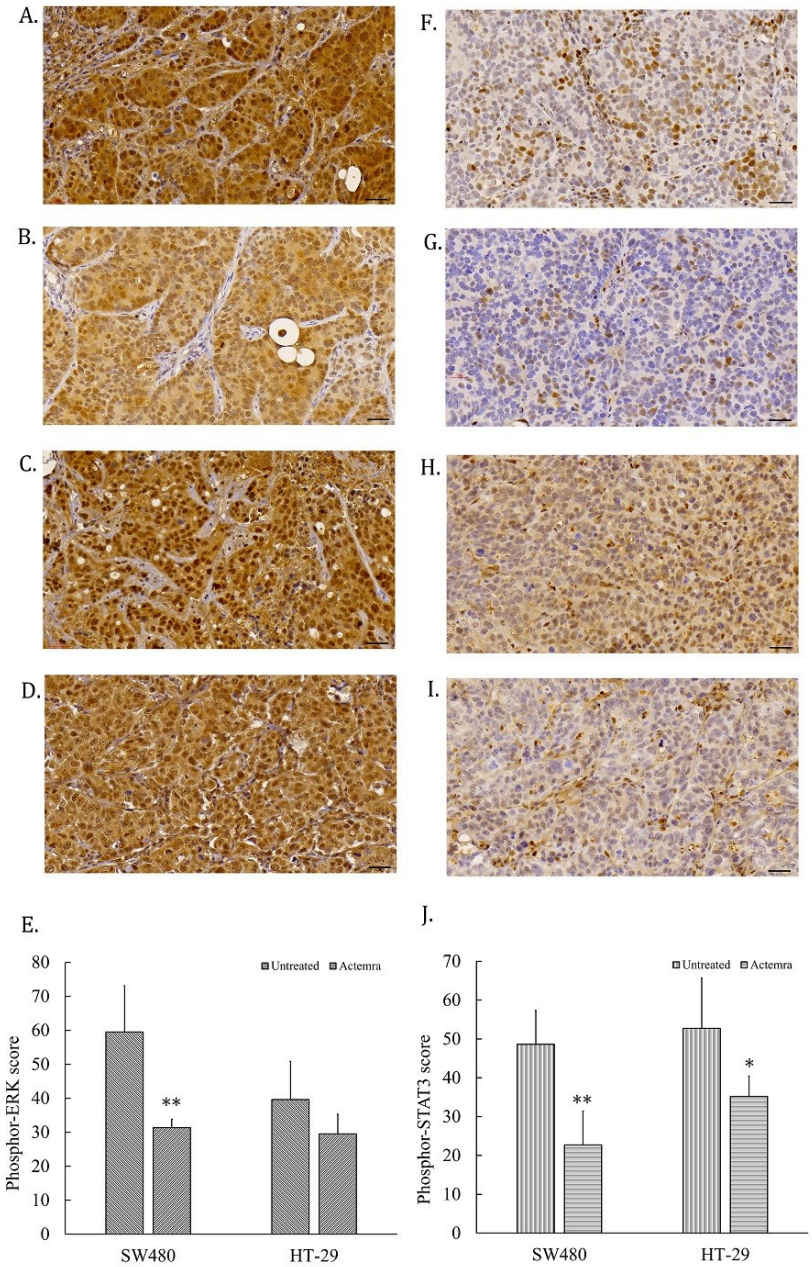

Figure 5. Signaling transduction in anti-IL-6R antibody treatment of human colorectal carcinoma SW480 and HT-29 xenografts. Tumor slices were stained with anti-phosphor-Erk-1/-2 and phosphor-STAT3 antibodies for immunohistochemical staining, and the images were scanned using a micro scanner, as described in the Section 4. Representative images of phosphor-Erk-1/-2 staining in tumor slices were captured from the untreated SW480 (**A**), anti-IL-6R antibody (tocilizumab; ACTEMRA®)-treated SW480 (**B**), untreated HT-29 (**C**), and Actemra-treated HT-29 (**D**) xenografts (black bar is 30 µm long). The total scores of phosphor-Erk-1/-2 from each group are averaged from 10 different areas and shown as means ± SEM (**E**). Phosphor-STAT3 images were also captured from the untreated SW480 (**F**), Actemra-treated SW480 (**G**), untreated HT-29 (**H**), and Actemra-treated HT-29 (**I**) xenografts. The total scores of phosphor-STAT3 from each group were averaged from 10 different areas and are shown as means ± SEM (**J**). * $p < 0.05$ and ** $p < 0.01$.

2.5. Inhibition Effect of Anti-IL-6R Antibody Treatment (Tocilizumab; ACTEMRA®) on Erk-1/-2 and STAT3 Signaling Transduction of Human CRC SW480 Xenografts Was Superior to the Treated Group of HT-29 Xenografts

The tumor slices from human CRC SW480 and HT-29 xenografts were subjected to assessment of the IL-6R signaling pathways, including phosphor-STAT3 and phosphor-Erk-1/-2 levels in the untreated and treated groups. As shown in Figure 5A, the phosphor-Erk-1/-2 staining intensity was a strong positive (3+) in almost all the tumor cells from the untreated SW480 group, whereas the intensity was only 1 to 2 plusses within the treated SW480 tumor cells (Figure 5B). The tumor cells showed the intensity of 2 to 3 plusses from the untreated HT-29 group (Figure 5C), and 2 plusses from the treated HT-29 group (Figure 5D). The total intensity score of phosphor-Erk in the untreated SW480 tumor cells was approximately 60 via a semi-quantitative analysis, compared with 30 in the anti-IL-6R antibody-treated SW480 tumors. The phosphor-Erk staining intensity differed significantly between the untreated and treated groups ($p < 0.01$). On the other hand, the score was approximately 40 in untreated HT-29 tumors and 30 in treated HT-29 tumors, but there was no significant difference between these two groups (Figure 5E). Phosphor-STAT3 staining was a strong positive in approximately half of the tumor cells from the untreated SW480 tumors (Figure 5F) and HT-29 (Figure 5H), and decreased in the treated groups of SW480 (Figure 5G) and HT-29 (Figure 5I). The phosphor-STAT3 staining of untreated SW480 tumor cells scored approximately 50 via a semi-quantitative analysis, which was significantly different from the treated group, with a score of 23 ($p < 0.01$) (Figure 5E). The phosphor-STAT3 staining of untreated HT-29 tumor cells scored approximately 60, compared with 38 in the treated HT-29 group ($p < 0.05$) (Figure 5J). The phosphor-STAT3 staining intensity differed significantly between the two groups.

3. Discussion

Emerging evidence has illustrated that the IL-6/IL-6R gp130 inflammation signaling pathway plays a crucial role in the promotion of carcinogenesis in CRC [18–20]. Targeted anti-IL-6R antibody therapy for CRC was capable of providing an adjuvant strategy [21,22]. Our previous studies showed that anti-IL-6R antibodies potentially inhibited tumor growth and invasiveness in vitro and in vivo through interfering with IL-6 signaling transduction in IL-6R expressing CRC cell lines, including Erk-1/-2, STAT3 and AKT phosphorylation/activation [15,16]. Theoretically, the tumor response to targeted therapy is closely associated with expression levels of target proteins in/on cancer cells [23]. In the present study, we attempted to further investigate whether IL-6R expression level is the important predictor for the tumor response of CRC to anti-IL-6R antibody treatment. Two CRC cell lines, SW480 and HT-29, were chosen after evaluating the IL-6R mRNA levels in an earlier study that showed SW480 cells exerted higher IL-6R levels than HT-29 cells [17]. The tumor slices from the xenografts of these two cell lines showed different protein levels of IL-6R. Indeed, the SW480 tumors exerted a more potent IL-6R intensity than HT-29. Also, the inhibitory effect of anti-IL-6R antibodies on tumor growth in SW480 xenografts was more powerful than in HT-29. The tumor growth with anti-IL-6R antibody therapy further represented attenuated expressions of the mitotic index and Ki-67 staining. Specifically, SW480 tumors posed high levels of IL-6R that anti-IL-6R antibody treatment effectively suppressed in the mitotic cells. In contrast, the HT-29 tumors with low IL-6R expressions represented equal results of mitotic index and Ki-67 staining between the untreated and anti-IL-6R antibody-treated groups. The results indicate that CRC tumor cells with higher IL-6R expression are more sensitive to anti-IL-6R antibody treatment.

The two human CRC cell xenografts represented different invasiveness abilities corresponding to IL-6R expression levels. The tocilizumab-treated SW480 tumors were sur-rounded by fibrotic tissue that formed a barrier-like structure to avoid CRC cell infiltration, as described in our previous report [16]. However, the tumor edge of the same treatment of HT-29 xenografts seemed to be unclear, and was similar to the untreated SW480 or HT-29 tumors. Meanwhile, there were several cancer cells infiltrating into surrounding muscle

or fatty tissue.Several studies, along with our research, revealed that the expression of invasiveness-related proteinases such as MMP-9/MMP-2 were inhibited by interfering with the IL-6 signaling transduction that suppressed CRC cell invasiveness in vitro [15,24–26]. Herein, we found the expression of MMP-9 was suppressed by tocilizumab treatment in human CRC SW480 xenografts.Nonetheless, the MMP-9 level did not significantly differ between the untreated and treated HT-29 groups.The IL-6R expression level in CRC cells wouldbethekeyfactorfortheeffectoftocilizumabontheexpressionofinvasiveness-related proteinases.The MMP-2 expression in all groups was not changed, suggesting the underlying mechanism of CRC tumor invasiveness is extremely intricate.Previous reports revealed that cell signals triggering ERK phosphorylation/activation serve as an important regulatory mechanism to modulate MMP-9/MMP-2 expressions [15,27,28].In the current study,phosphor-ERKwasnotsuppressedbytocilizumabinHT-29tumors.Ourprior study demonstrated that only simultaneously suppressing ERK and AKT phosphorylation was capable of inhibiting the expression of MMP-9/MMP -2 and the invasiveness of CRC cells, providing the possible reason that explains the discrepancy between invasiveness-related experiments [15].Last but not least, tocilizumab suppressed the phosphor-STAT3 signaling in both the treated SW480 and HT-29 groups, indicating that JAK/STAT-3 sig-naling transduction is more sensitive to IL-6/IL-6R signaling blockade, even in the lower IL-6R-expressing HT-29 cells.

Some limitations are recognized in our study.Although we explained that the differ-encesobservedinthisstudyareattributabletothedifferentexpressionsofIL-6R,the modelusedisnotrobustenough. Infact,therearemanyothergeneticdifferences withdifferentIL6RmRNAexpressionsbetweenthesetwocelllines[29].Asforthe Ras/RAF/MEK/MAPK sequence related to IL6/IL6R signaling, the mutations of SW480 and HT29 are Ras and RAF, respectively.Because IL6R has a STAT3 signaling pathway, disruptingtheupstreamsignalIL6cannotpreventcellgrowth.Ourpreviousarticles confirmed that the IL6R antibody tocilizumab can bypass Ras mutation and directly af-fectdownstreamMAPKinSW480,therebyslowingdownthegrowthoftransplanted tumors [15,16].This research further explores whether the expression level of IL6R will affect the inhibitory effect of tocilizumab on CRC xenografts.The current results confirm that the discrepancy in mRNA expression exists not only in cell models but also in xenograft models.Furthermore, because the inhibitory effect of tocilizumab bypasses Ras and directly affects downstream MAPK, we infer that the inhibitory effect on HT29 with RAF mutation may be worse than SW480.The main phenomenon results from the synergism of low IL6R expressionandtheinfluenceofRAFmutation.Ourpreviousstudiesrevealedthatthe inhibitory effect on cell invasion was related to the inhibition of MMP9 [15,16]; however, we further confirm the therapeutic effect on the CRC invasion into surrounding tissues through in vivo model.

4.Materials and Methods

4.1.Materials

Primary antibodies including anti-ERK-1/-2, anti-phospho-ERK-1/-2 (The202/Tyr204), anti-STAT3,anti-phosphor-STAT3(S727),anti-AKT,anti-phospho-AKT,anti-Ki-67,and **secondary antibody conjugaetd with poly-peroxidase and DAB chromogen for immuno-**histochemical (IHC) staining were purchased from Abcam (Cambridge, MA, USA) and GeneTex (Hsinchu, Taiwan).

4.2.Cell Culture

Cell culture medium and other supplements were purchased from Gibco Ltd.(Paisley, UK).CRCcelllineSW480andHT-29werepurchasedfromtheBioresourceCollection andResearchCenter,Taiwan,andculturedin90%mediumsupplementedwith10% heat-inactivatedFBS,25U/mLpenicillin,and25µg/mLstreptomycinat37◦Canda water-saturatedatmosphere.Allexperimentswerecarriedoutoncelllinespassaged 5–20 times.

4.3.Animal Study

Animal experiments were performed according to the Guide for the Care and Use of Laboratory Animals (8th Edition), and the detailed protocol used here was reviewed and approved by the Institutional Animal Care and Use Committee (IACUC No.2017-234) oftheChinaMedicalUniversity(Taichung,Taiwan).Theanimalstudywasdescribed asperourpreviousreport[16].Briefly,malenudemice(6-week-old)(strainNU/NU; BioLASCO Taiwan Co., Ltd., Taipei, Taiwan) cultivated under pathogen-free conditions were inoculated with 100 µL cell suspension of 5 ×10^7cells/mL SW480 or HT-29 cells using a 1 mL syringe and a 27-gauge needle.After one week, the 7-week-old mice with approximately100mm^3ofthetumorsizeweredividedintofourgroups.Eachgroup contained 5 animals.The treated groups underwent peritoneal injection with 1.0 mg/kg anti-IL-6R antibodies (tocilizumab; Rhoch Inc., San Francisco, CA, USA) in 0.1 mL PBS on days 2, 4, 7, 9, and 11.The untreated groups were injected with an equal volume of PBS as a replacement for the anti-IL-6R antibodies.We used a sensitive electronic scale to weigh an empty scooping container as the first measurement.Then, the mouse placed inside the container was weighed as the second measurement.The difference in weight between the two measurements was recorded as the weight of the mouse.Through the above method, the mice were weighed before drug administration and sacrifice.The length, width, and height of the tumors were measured with vernier calipers on days 0, 2, 4, 7, 9, and 11, and the volume was calculated (V = length ×width ×height/2).The mice were sacrificed when 9 weeks old, and the tumors along with other organs, such as the liver, lungs, spleen, heart, and kidneys, were removed surgically and fixed in 3% formalin/PBS.

4.4.Tissue Processing and H&E Staining

The collected tumors or other visceral tissues were first washed with PBS to remove externalblood,andthensoakedin3%formaldehyde-PBS(neutralformalin)atroom-temperature overnight.The fixation time did not exceed 24 h.The details of the procedures wereessentiallyinaccordancewiththepreviousstudy[16].Briefly,theformalin-fixed tissues in plastic tissue support racks were dehydrated via sequential immersion in 50%, 70%, 85%, 95%, and 100% ethanol, and then xylene under an automatic dehydrator machine, and finally embedded in the molten paraffin wax.After slicing the paraffin-embedded tissues with a microtome (Leica RM2125 RTS; Leica Microsystems Inc., Seattle, WA, USA), the 2–3-µm-thick tissue sections were fixed on glass slides by heating at 60 °C overnight. For hematoxylin and eosin (H&E) staining, the 65 °C heat de-waxed paraffin-embedded tumorslices were washed in xylene and rehydrated with a series of alcohol gradients (absolute alcohol, 95% alcohol, and 80% alcohol).The rehydrated tissue sections were stained with Mayer's H&E protocol and then underwent the dehydration process as described in our previousreport[16].Themountedsliceswerescannedbyadigitalpathologyscanner (MoticEasyScan; Motic Inc., Xiamen, China) to obtain the digital microscopy images on a computer using the image program (DSAssistant; Motic Inc., Xiamen, China).

4.5.Immunohistochemical (IHC) Staining

Thedetailsoftheprocedureswereessentiallyinaccordancewithourprevious study[16].Briefly,thetumorsliceswererehydratedwithaseriesofalcoholgradients (absolute alcohol, 95% alcohol, and 80% alcohol) and finally, immersed in TBS (Tris-buffered saline).After antigen retrieval in 95 °C heated citrate buffer and de-activated endogenous peroxidaseswith 3%H_2O_2,tissuesections inthe sliceswereincubated withanti-Ki-67, ERK-1/-2, phosphorylated ERK-1/-2, STAT3, phosphorylated STAT3, matrix metallopro-teinase (MMP)-9, and MMP-2 antibodies at the indicated dilution ratios.The location and intensity of each antigen on the tissue sections were visualized using the LSAB staining systemandhematoxylinasthecounterstain.Thestainedsliceswerededehydratedand scanned as high-resolution digital images using a digital pathology scanner.The overall staining intensity was typically classified into four categories:negative (0), weak (1 plus), moderate (2 plusses), and strong (3 plusses).The immunological activities of each antigen

withtheintensityscoreswerecalculatedbysemi-quantitativeanalysis,asdescribedin prior studies [16,30].

4.6.Statistical Analysis

The data were analyzed using the Kruskal–Wallis test, which is a nonparametric test, to evaluate significant differences between the control group and the treatment groups.If significant differences existed, the multiple comparison test was then used for identification.Differences among group means were considered significant at $p < 0.05$.

5.Conclusions

Tocilizumab is a humanized monoclonal antibody used directly against IL-6R. The human CRC SW480 xenografts with higher IL-6R expression levels showed better respon-siveness than the treated HT-29 group.Meanwhile, such therapeutic effects on proliferative abilitywithmitoticindexandKi-67expressions,invasivenesswithMMP-9proteinase expressions, and ERK 1/2 and STAT3 signaling transduction in the SW480 treatment group were superior in the HT-29 treatment group. In light of our results, IL-6R is the key indicato**for the efficacy of tociliuzmab treatment in CRC xenograft models**.From the perspective ofprecision medicine, tumor response to anti-IL-6R antibody therapy could be predicted on the basis of IL-6R expression levels.In this manner, tocilizumab could serve as a targeted and promising anti-CRC therapy.

Author Contributions:Y.-C.C., C.-P.H. and J.-F.C. were responsible for the study concept and design, interpretation of data, and writing of the manuscript; S.-J.C. and C.-C.H. assisted in electroencephalographic measure, biochemical analysis, and experimental support; W.-C.L., M.-T.L., Y.-C.C., T.-Y.K., W.-S.Y. and C.-H.Y. implemented the manuscript revisions.All authors have read and agreed to the published version of the manuscript.

Funding: This work was supported by the Ministry of Science and Technology#1 under grant MOST 107-2314-B-264-001; MOST 109–2628-B-385–001; the Research Fund from the Taoyuan Branch of Taipei Veterans General Hospital 113-11; and the Renal Care Joint Foundation.

Institutional Review Board Statement: Not applicable.

Informed Consent Statement: Not applicable.

Data Availability Statement: All data used to support the findings of this study are available from the corresponding author, Chang, J.-F., upon reasonable request.

Acknowledgments: The authors appreciated the technical support of Hsien-Neng Huang.

Conflicts of Interest: The authors declare no conflicts of interest.

References

1. Malemud, C.J. Suppression of Autoimmune Arthritis by Small Molecule Inhibitors of the JAK/STAT Pathway.*Pharmaceuticals* **2010**, *3*, 1446–1455.[] []
2. Tie, R.; Li, H.; Cai, S.; Liang, Z.; Shan, W.; Wang, B.; Tan, Y.; Zheng, W.; Huang, H. Interleukin-6 Signaling Regulates Hematopoietic Stem Cell Emergence.*Exp.Mol.Med.***2019**, *51*, 1–12.[] []
3. Giraldez, M.D.; Carneros, D.; Garbers, C.; Rose-John, S.; Bustos, M. New Insights into IL-6 Family Cytokines in Metabolism, Hepatology and Gastroenterology.*Nat.Rev.Gastroenterol.Hepatol.***2021**, *18*, 787–803.[]
4. Chung,Y.-C.;Chaen,Y.-L.;Hsu,C.-P.ClinicalSignificanceofTissueExpressionofInterleukin-6inColorectalCarcinoma. *Anticancer Res.***2006**, *26*, 3905–3911.[]
5. Chung, Y.-C.; Chang, Y.-F. Serum Interleukin-6 Levels Reflect the Disease Status of Colorectal Cancer.*J. Surg.Oncol.***2003**, *83*, 222–226.[]
6. Kakourou, A.; Koutsioumpa, C.; Lopez, D.S.; Hoffman-Bolton, J.; Bradwin, G.; Rifai, N.; Helzlsouer, K.J.; Platz, E.A.; Tsilidis, K.K. Interleukin-6 and Risk of Colorectal Cancer:Results from the CLUE II Cohort and a Meta-Analysis of Prospective Studies.*Cancer Causes Control* **2015**, *26*, 1449–1460.[]
7. Kinoshita, T.; Ito, H.; Miki, C. Serum Interleukin-6 Level Reflects the Tumor Proliferative Activity in Patients with Colorectal Carcinoma.*Cancer* **1999**, *85*, 2526–2531.[]
8. Knüpfer, H.; Preiss, R. Serum Interleukin-6 Levels in Colorectal Cancer Patients--a Summary of Published Results.*Int.J. Colorectal Dis.***2010**, *25*, 135–140.[]

9. Nagasaki, T.; Hara, M.; Nakanishi, H.; Takahashi, H.; Sato, M.; Takeyama, H. Interleukin-6 Fibroblasts Is Critical for Tumour Angiogenesis:Anti-Interleukin-6 Receptor Antibody Suppressed Angiogenesis and Inhibited Tumour–Stroma Interaction.*Br.J. Cancer* **2013**, *110*, 469–478.[]
10. Varkaris, A.;Katsiampoura, A.;Davis, J.S.;Shah, N.;Lam, M.;Frias, R.L.;Ivan, C.;Shimizu, M.;Morris, J.;Menter, D.;et al. Circulating Inflammation Signature Predicts Overall Survival and Relapse-Free Survival in Metastatic Colorectal Cancer.*Br.J. Cancer* **2019**, *120*, 340–345.[]
11. Rokavec,M.;Öner,M.G.;Li,H.;Jackstadt,R.;Jiang,L.;Lodygin,D.;Kaller,M.;Horst,D.;Ziegler,P.K.;Schwitalla,S.;et al. IL-6R/STAT3/MiR-34a Feedback Loop Promotes EMT-Mediated Colorectal Cancer Invasion and Metastasis.*J. Clin.Investig.* **2014**, *124*, 1853–1867.[] []
12. Wang, S.-W.; Sun, Y.-M. The IL-6/JAK/STAT3 Pathway:Potential Therapeutic Strategies in Treating Colorectal Cancer.*Int.J. Oncol.***2014**, *44*, 1032–1040.[]
13. Trikha, M.; Corringham, R.; Klein, B.; Rossi, J.-F. Targeted Anti-Interleukin-6 Monoclonal Antibody Therapy for Cancer:A Review of the Rationale and Clinical Evidence.*Clin.Cancer Res.***2003**, *9*, 4653–4665.[]
14. Hsu, C.-P.; Chung, Y.-C. Influence of Interleukin-6 on the Invasiveness of Human Colorectal Carcinoma.*Anticancer Res.***2006**, *26*, 4607–4614.
15. Hsu, C.-P.; Chen, Y.-L.; Huang, C.-C.; Chou, C.-C.; Liu, C.-L.; Hung, C.-H.; Kao, T.-Y.; Chung, Y.-C. Anti-Interleukin-6 Receptor Antibody Inhibits the Progression in Human Colon Carcinoma Cells:ANTI-IL-6 RECEPTOR AND CRC PROGRESSION. *Eur.J. Clin.Investig.***2011**, *41*, 277–284.[]
16. Chung, Y.-C.; Ku, Y.-L.; Chiang, H.-C.; Liu, W.-C.; Kao, T.-Y.; Yang, C.-H.; Huang, C.-C.; Hsu, C.-P. Antibody to Interleukin-6 Receptor Inhibits in Vivo Growth of Human Colorectal Carcinoma Cell Xenografts.*Anticancer Res.***2021**, *41*, 4907–4916.[] []
17. Schneider, M.R.; Hoeflich, A.; Fischer, J.R.; Wolf, E.; Sordat, B.; Lahm, H. Interleukin-6 Stimulates Clonogenic Growth of Primary and Metastatic Human Colon Carcinoma Cells.*Cancer Lett.***2000**, *151*, 31–38.[]
18. Waldner, M.J.; Foersch, S.; Neurath, M.F. Interleukin-6—A Key Regulator of Colorectal Cancer Development.*Int.J. Biol.Sci.***2012**, *8*, 1248–1253.[]
19. Taher, M.Y.; Davies, D.M.; Maher, J. The Role of the Interleukin (IL)-6/IL-6 Receptor Axis in Cancer.*Biochem.Soc.Trans.***2018**, *46*, 1449–1462.[]
20. Turano, M.; Cammarota, F.; Duraturo, F.; Izzo, P.; De Rosa, M. A Potential Role of IL-6/IL-6R in the Development and Management of Colon Cancer.*Membranes* **2021**, *11*, 312.[]
21. Bonamichi-Santos,R.;Castells,M.DiagnosesandManagementofDrugHypersensitivityandAnaphylaxisinCancerand Chronic Inflammatory Diseases:Reactions to Taxanes and Monoclonal Antibodies.*Clin.Rev.Allergy Immunol.***2018**, *54*, 375–385. [] []
22. Kampan, N.C.; Xiang, S.D.; McNally, O.M.; Stephens, A.N.; Quinn, M.A.; Plebanski, M. Immunotherapeutic Interleukin-6 or Interleukin-6 Receptor Blockade in Cancer:Challenges and Opportunities.*Curr.Med.Chem.***2018**, *25*, 4785–4806.[] []
23. Guo,R.;Luo,J.;Chang,J.;Rekhtman,N.;Arcila,M.;Drilon,A. MET-Dependent Solid Tumours—Molecular Diagnosis and Targeted Therapy.*Nat.Rev.Clin.Oncol.***2020**, *17*, 569–587.[]
24. Liu, H.; Ren, G.; Wang, T.; Chen, Y.; Gong, C.; Bai, Y.; Wang, B.; Qi, H.; Shen, J.; Zhu, L.; et al.Aberrantly Expressed Fra-1 by IL-6/STAT3 Transactivation Promotes Colorectal Cancer Aggressiveness through Epithelial-Mesenchymal Transition.*Carcinogenesis* **2015**, *36*, 459–468.[] []
25. Han, S.; Jeong, A.J.; Yang, H.; Bin Kang, K.; Lee, H.; Yi, E.H.; Kim, B.-H.; Cho, C.-H.; Chung, J.W.; Sung, S.H.; et al.Ginsenoside 20(S)-Rh2 Exerts Anti-Cancer Activity through Targeting IL-6-Induced JAK2/STAT3 Pathway in Human Colorectal Cancer Cells. *J. Ethnopharmacol.***2016**, *194*, 83–90.[] []
26. Tsai,S.-C.;Wu,W.-C.;Yang,J.-S.TetrandrineInhibitsEpithelial-MesenchymalTransitioninIL-6-InducedHCT116Human Colorectal Cancer Cells.*OncoTargets Ther.***2021**, *14*, 4523–4536.[]
27. Fan, L.; Wu, Y.; Wang, J.; He, J.; Han, X. Sevoflurane Inhibits the Migration and Invasion of Colorectal Cancer Cells through Regulating ERK/MMP-9 Pathway by up-Regulating MiR-203.*Eur.J. Pharmacol.***2019**, *850*, 43–52.[] [] 28. Zhang,T.;Wang,Z.;Liu,Y.;Huo,Y.;Liu,H.;Xu,C.;Mao,R.;Zhu,Y.;Liu,L.;Wei,D.;etal.Plastin1DrivesMetastasisof Colorectal Cancer through the IQGAP1/Rac1/ERK Pathway.*Cancer Sci.***2020**, *111*, 2861–2871.[]
29. Tseng-Rogenski,S.;Hamaya,Y.;Choi,D.Y.;Carethers,J.M.Interleukin6AltersLocalizationofHMSH3,LeadingtoDNA Mismatch Repair Defects in Colorectal Cancer Cells.*Gastroenterology* **2015**, *148*, 579–589.[]
30. Inwald, E.C.; Klinkhammer-Schalke, M.; Hofstädter, F.; Zeman, F.; Koller, M.; Gerstenhauer, M.; Ortmann, O. Ki-67 Is a Prognostic Parameter in Breast Cancer Patients:Results of a Large Population-Based Cohort of a Cancer Registry.*Breast Cancer Res.Treat.* **2013**, *139*, 539–552.[]

Disclaimer/Publisher'sNote: Thestatements,opinionsanddatacontainedinallpublicationsaresolelythoseoftheindividual author(s) and contributor(s) and not of MDPI and/or the editor(s).MDPI and/or the editor(s) disclaim responsibility for any injury to people or property resulting from any ideas, methods, instructions or products referred to in the content.