Journal of Hand Therapy 30 (2017) 182–192

Contents lists available at ScienceDirect

Journal of Hand Therapy

journal homepage: www.jhandtherapy.org

JHT Read for Credit Article #486.
Scientific/Clinical Article

A comprehensive rehabilitation program for posterior instability of the shoulder

Lyn Watson B AppSci (Physio), GradDip of Manipulative Physio, DProf[a,b,c], Simon Balster B Sci, B Physio (Hons)[b,c], Sarah Ann Warby PhD, B Physio (Hons)[a,b,c], Jackie Sadi MSc[d], Greg Hoy MBBS, FRACS[c], Tania Pizzari PhD, B Physio (Hons)[a,*]

[a] Department of Rehabilitation, Nutrition and Sport, College of Science, Health and Engineering, La Trobe University, Bundoora, Victoria, Australia
[b] LifeCare Prahran Sports Medicine Centre, Prahran, Victoria, Australia
[c] Melbourne Orthopedic Group, Melbourne, Victoria, Australia
[d] Western University, London, Ontario, Canada

ARTICLE INFO

Article history:
Received 31 January 2017
Received in revised form
9 May 2017
Accepted 9 May 2017

Keywords:
Posterior instability
Conservative rehabilitation
Exercise
Shoulder

ABSTRACT

Posterior shoulder instability is recognised as being less prevalent than anterior instability, however the diagnosis of this pathology is easily overlooked or missed and this may contribute to an underestimation of prevalence. Recently, there has been increasing recognition of this condition and consequently a greater requirement for knowledge of diagnostic procedures and treatment directions. Currently there is limited research into the conservative management of posterior instability, although it is recommended as first-line treatment prior to surgical review, particularly in those with an atraumatic instability mechanism. The aim of this paper is to outline a comprehensive rehabilitation program for the conservative management of posterior instability with a focus on scapular and humeral head control. The information provided includes extensive written information, flowcharts, figures and a table of management parameters that will provide therapists with adequate detail to replicate the program in the clinical setting.

© 2017 Hanley & Belfus, an imprint of Elsevier Inc. All rights reserved.

Posterior instability: incidence and prevalence

Glenohumeral joint instability is estimated to affect 2% of the general population,[1] with anterior the most prominent direction of instability. The incidence of anterior shoulder dislocation has been reported to range from 8.2 to 56.3 dislocations per 100,000 people per year,[2-5] with a projected prevalence of 1.7%.[6] The prevalence of instability is likely underestimated when based on dislocation data alone because subluxations occur at a rate of 5 times higher than dislocations in young athletes.[7] Traditionally, posterior instability has been considered to represent less than 10% of all instability cases[8-10]; however, posterior subluxation and translational instability can be easily overlooked and misdiagnosed[11] and this may contribute to the low reported incidence of this condition. More recently, there has been increasing recognition of this pathology in active populations.[12,13]

Posterior instability: classification and pathogenesis

There is no consensus on classification systems for categorizing instability,[6,14] and the classification of posterior instability remains controversial.[15] The mechanism of injury (traumatic versus atraumatic), severity (subluxation vs dislocation), direction of instability, presence of ligamentous laxity, and presence of volitional instability have all been described as considerations for classifying glenohumeral instability.[14,16,17] Posterior instability has previously been described by the severity of instability (acute dislocation, chronic fixed/locked posterior dislocation, and recurrent subluxation)[18] and mechanism of injury.[15] Posterior instability can be associated with a single traumatic onset (such as a tackle in football or rugby), repetitive overuse and microtrauma (such as a backhand in tennis), or soft tissue disorders.[15]

In the presence of a history of trauma and resulting unilateral instability, structural lesions are more likely and can include posterior inferior glenohumeral ligament injury, reverse Bankart lesion, reverse humeral avulsion of the glenohumeral ligament (HAGL), posterior labral tears, or posterior capsuloligamentous complex stretch.[15] Bidirectional posterior instability is combined posteroinferior instability, which is typically posterior instability

* Corresponding author. Department of Rehabilitation, Nutrition and Sport, College of Science, Health and Engineering, La Trobe University, Level 5, HS3, Corner of Kingsbury Drive and Plenty Road, Bundoora, Victoria, Australia, 3086.
E-mail address: t.pizzari@latrobe.edu.au (T. Pizzari).

0894-1130/$ – see front matter © 2017 Hanley & Belfus, an imprint of Elsevier Inc. All rights reserved.
http://dx.doi.org/10.1016/j.jht.2017.05.007

superimposed on an underlying hypermobile joint.[13] It can also be associated with a structural lesion and can be induced either through traumatic mechanisms or overuse. It is estimated that up to 30% of the normative population is hypermobile,[19,20] and there is some evidence that this predisposes an individual toward instability.[20,21] Posterior instability is often present in multidirectional instability (MDI) of the shoulder.

Posterior instability can also be associated with congenital anomalies such as posterior capsulolabral redundancy or deformation and glenoid retroversion (increase posterior angulation of the glenoid fossa).[22] These will result in a posteriorly centered humeral head (HH) which may predispose to posterior instability, and usually, if it is present, it occurs bilaterally.

Clinical examination

Posterior dislocation is notorious for being "missed" at examination.[23] It is difficult to recognize clinically (chronic fixed/locked posterior dislocation) as the HH can position itself posteriorly behind the glenoid being masked by the overlying musculature.[24,25] The clinical diagnosis is further hampered by the fact that many shoulders with significant posterior structural lesions (labral and ligament tears) do not present with a history of requiring reduction.[26]

Subjective assessment

In our experience, it is particularly important to listen for a "moment in time" (an incident or activity) when symptoms started. An incident may be indicative of a structural lesion of significance.[22] Often patients are still able to move their arm at the time and that they do not actually feel it dislocate or sublux, but they are aware something happened or "went" in their shoulder. The next day their arm is worse and more sore and restricted in motion, and it can take weeks to recover.

Patients typically present complaining of pain when performing certain activities, and instability of their shoulder is a secondary concern.[27] The most aggravating positions are loading the arm in flexion, horizontal flexion, and internal rotation (IR) or any combinations thereof.[22] Aggravation of pain can occur during pulling off a top, turning a steering wheel, lying on the side, bench press, push ups or overhead weights, and any use of the arm in long-lever flexion, particularly weighted flexion.[28] Patients can complain of pain in both the front and back of the joint.[28] The HH sliding excessively posteriorly can stress soft tissues on both sides of the joint in a similar way to what has been described as occurring with anterior instability and internal impingement but in reverse.[29] The pain in the front may be derived from the long head of biceps and/or the top edge of subscapularis as these structures can be compressed intraarticularly as the HH abuts the glenoid. In some more extreme or chronic cases, odema, compression, and flattening of the HH can occur or even Reverse Hill-Sachs lesions can be seen on magnetic resonance imaging and at surgery.[22,26]

Posterior joint pain is also common and this can correlate with either a posterior labral tear or posterior glenoid chondral surface damage.[22,26] In our experience, the posterior pain can be more generalized in some cases, and patients may report a gripping or tightening feeling in the back of the joint, particularly with movement into horizontal flexion. This may lead to a misdiagnosis of a stiff posterior capsule as horizontal flexion appears blocked or stiff when it is actually guarding.

If the joint is hypermobile, the patient may not always be aware that their shoulder has developed excessive translation as they have always had "clunking," "clicking" loose feeling shoulders.

Physical examination

The diagnosis of posterior instability, like most shoulder pathologies, cannot be made by one stand-alone diagnostic test. A recent systematic review by McIntyre et al[28] revealed that for diagnosis, clinicians must rely on a combination of a thorough history, including the mechanism of injury, symptoms and recognition of risk factors as well as clustering of the Jerk test, Kim test, and posterior impingement sign. In addition, examination for glenohumeral joint laxity is essential to determine which subgroup of posterior instability the patient may belong.[30]

The clinical diagnosis of posterior instability can be further complicated by the coexistence of acromioclavicular pathology. Whether this association is due to a direct biomechanical linkage between posterior translation of the HH and increased stress on the acromioclavicular joint or due to the fact that the provocation position for posterior instability (flexion, horizontal flexion, and IR) is similar to that for the acromioclavicular joint[31,32] is currently not known.

The excessive posterior translation of the HH can set up articular surface cuff changes around the posterior cuff (supraspinatus and infraspinatus) creating clinical signs of pain and weakness and sometimes wasting around the posterior cuff.[26] The secondary or coexisting rotator cuff signs that are often present can mean that the diagnosis is missed or delayed as treatment remains focused on the rotator cuff and not the underlying joint instability. This is particularly exacerbated in posterior instability due to the fact that frank instability or subluxation is rarely a primary feature of this pathology.

The range of motion presentation in posterior instability is dependent on the history, subgroup, and chronicity. If a patient presents acutely after a traumatic event, typically the range of motion will be painful and restricted, particularly in flexion, horizontal flexion, and IR. Excessive translation of the HH posteriorly can be seen and palpated, and motions are painful and guarded. Clinicians should keep in mind that chronic locked dislocations can occur.[25] The patient will present with an altered contour of the glenohumeral joint anteriorly where the HH normally sits. The joint will appear flattened, and there will be a prominent coracoid process. The glenohumeral joint is locked, and there is gross weakness in the external rotators (Fig. 1). The diagnosis is confirmed by radiological investigation. In most clinical practices, patients typically present nonacutely. In general, abduction and external rotation (ER) ranges are nonrestricted in range although there may some abduction arc pain coming from any secondary rotator cuff

Fig. 1. Chronic locked dislocation. Altered contour of joint anteriorly, flattened joint with a prominent coracoid process.

pathology or irritation. The most aggravating movements are flexion and horizontal flexion +/− some IR.[28] Palpation of the HH reveals posterior placement or translation of the HH in these positions. Scapular dyskinesis is common, particularly winging and downward rotation of the scapula (Fig. 2).

The effect of correction

An essential part of clinical examination is assessing the effect of correction of the position or motion of both the scapula and HH.[11] Corrective maneuvers for the scapula and HH have been described in the assessment of numerous shoulder pathologies ranging from anterior instability and impingement through to thoracic outlet syndrome.[33-40]

Correcting the position and motion of the scapular and/or HH when performing special tests, passive and active movements, and resistance tests helps to determine which patients might be amenable to correction and might benefit from conservative management. Improvements in range of motion, a reduction or elimination of symptoms, or improvements in strength as a result of applying corrections can contribute to the diagnostic picture and highlights that a patient is likely to respond to rehabilitation strategies that correct the scapular and HH position.

Most commonly, patients respond positively to some component of upward rotation +/− slight elevation if the scapula is depressed on the thorax.[38] Winging of the scapula may be an adaptive response where the patients wing the scapula to try to put the glenoid fossa behind the HH to prevent subluxation. Correction of the scapula into posterior tilt and or retraction in this instance we theorize makes the patient's instability and symptoms worse as the glenoid fossa is orientated further posteriorly, particularly if the underlying joint has any component of retroversion.

Fig. 2. Scapular dyskinesis typical in posterior instability. Insufficient upward rotation and winging.

Management direction

Conservative management is the recommended first-line treatment for posterior instability.[15,28,41] A recent systematic review by McIntyre et al[28] identified 5 studies presenting level 4 evidence for efficacy of conservative rehabilitation for posterior instability. The included studies highlight the value of progressive deltoid and rotator cuff strengthening; however, most fail to address scapular and HH control and do not provide enough detail for replication in the clinic.

The review also determined that patients with an atraumatic history of instability have more favorable outcomes with conservative management when compared with those with a traumatic onset. Individuals who have a significant history of trauma are more likely to sustain a structural lesion to the shoulder that results in a predominantly unidirectional instability,[17,41] which may not be compensated with rehabilitation. In our clinical experience, in the presence of unidirectional and bidirectional posterior instability of traumatic onset, the response to correction is less predictable and these patients are likely to require imaging and further medical intervention. If not amenable to correction, this subgroup of patients may require investigation and early surgical referral.

The research evidence from response to rehabilitation strategies in MDI demonstrates that a minimum of 12 weeks rehabilitation is required to determine if conservative management will have a beneficial effect[42, 43]; it may be reasonable to expect a similar time frame when managing posterior instability.

The posterior instability program: overview

The posterior instability program is based on the Watson MDI program,[38,44] with a larger emphasis on developing posterior muscular control and strength.[28] The Watson MDI program was recently examined in a randomized controlled trial[45] and compared against a published conservative rehabilitation protocol for instability promoting rotator cuff and deltoid strengthening. The trial revealed that the Watson MDI program resulted in statistically and clinically larger improvements on functional outcomes compared with the general rotator cuff and deltoid program. Because 93% of the included participants had a component of posterior instability, the results indicate that the Watson MDI program is effective in treating patients with a component of atraumatic posterior instability, although this is yet to be empirically tested.

Table 1 and the program flow charts (Appendix 1) provide a detailed overview of the program based on our clinical experience. These resources, the principles of assessment, and the therapist's clinical reasoning skills guide treatment decisions. The program has 2 primary components: assessment and intervention. The program duration is 3-6 months, depending on patient presentation.[38,44] Rehabilitation exercises should be completed pain free, and the patient should not experience postexercise shoulder pain. Muscle soreness in the target muscles after the exercise is acceptable. The patient may be required to avoid aggravating sport, work, and leisure activities during the rehabilitation until there is sufficient motor control in the shoulder to participate. Activates involving sagittal plane elevation, IR, or any weight bearing or loading on the upper limbs may need to be avoided in the initial stages of rehabilitation.

The posterior instability program: assessment

The assessment component of the posterior instability program refers to the effect of manual scapular and HH correction.[38] The effect of manual correction involves therapist assistance of the scapula and/or HH while the patient performs an objective test to

Table 1
Overview of the posterior instability program

Stage	Aims	Potential drills	Dosage/load	Goals	Considerations
Scapula phase					
	Develop scapula stability to center HH	Scapula UR in standing +/− elevation +/− 20°-30° Abd of arm +/− posterior tilt	1-3 × 20 reps (60 reps per d) 5 s holds 2-3 × d 0-0.5-1 kg in hand Red-green SR band	Standing UR 3 × 20 reps 1-1.5 kg +/− green SR band (to move onto the arc of motion phase) Continue heavier load for scapula throughout program 1.5-2 kg 2 × 15 2-5 kg + 3 × 10-12	Side lie UR if unable to do > 5 reps standing If significant pain with drill may use axillary sling tape or posterior HH support tape 0° arm Abd of arm if any supraspinatus pain Care with posterior tilt as may encourage posterior translation of HH on retroverted glenoid
Arc of motion phase					
Stage 1: coronal plane 0° Abd	Develop posterior HH control in coronal plane 0° Abd	ER/IR/Ext isometrics Standing Ext to neutral with TB Standing ER with TB (0°-30°-45° ER) Standing IR with TB (from 30°-45° ER to 0°IR)	Isometrics: 5-10 × 5 second holds (20%-30% MVC), 2-3 × d TB drills: 1-3 × 15-20 reps, 2 × d Yellow-red-green TB	Ext/ER/IR 1-3 × 15-20 reps Red-green TB	Isometrics if arc cannot be controlled/ drill is pain provoking Ext/ER/IR = short arc to larger arc of motion ER initially from 0° to limit IR and possible posterior HH translation. ER after Ext control IR after ER control established.
		Side lie off support	SL: 1-3 × 15-20 reps 2 × d 0-0.5-1-1.5 kg	SL: 1-3 × 15-20 reps, 1.5 kg	Palpate posterior HH for unwanted posterior translation when prescribing exercises
		Bent over row with weight	BOR: 0.5-1-1.5 kg, 2-3 × 20 reps	BOR: 1.5-2 kg, 2-3 × 15-20 reps	If the patient can not control the HH in any drill, return to scapular phase and improve strength
		Continue scapular UR drill	UR: 1.5-2 kg 2-3 × 20 reps	Scapular UR: 2 kg, 3 × 20 reps, 2 × d	
Stage 2: coronal/ sagittal plane 0°-45°	Develop posterior HH control in coronal and sagittal plane plane 0°-45° Abd	Standing Ext row with TB at 45° ER with TB at 45° IR at with TB 45° SL: progress load BOR at 45°	TB drills: 1-3 × 15-20 reps, 2 × d Yellow-red-green TB SL: 1-3 × 15-20 reps, 2 × d 1.5-2-2.5 kg BOR: 0.5-1-1.5 kg, 2-3 × 15-20 reps 2 × d	Ext at 45°: green TB ER at 45° TB: red TB SL: 2-2.5 kg BOR at 45°: 1.5-2 kg IR at 45°: red-green TB 2-3 × 15-20 reps 3-5 sec holds BOR at 45°: 1.5 kg, 2-3 × 15-20 reps	Drills from stage 1 can be progressed to a strength dosage with increased load ER and IR to 45° may only be prescribed if required for patient function IR after ER control established. SL max recommended 2 kg female, 2.5 kg male Flexion commenced once Ext/ER /SL/ BOR goals achieved
		Standing flexion in scapular to sagittal plane from 0° to 45° elevation Continue UR drill with increased load	Flexion:1-3 × 15-20 reps, 2 × d Yellow-red-green TB UR: 2-3 kg	Flexion: sagittal plane red- green UR: 2-3 × 20 reps, 2-3 kg	Scapular plane flexion typically safer to commence and work around into sagittal plane flexion as posterior HH control is gained.
Stage 3: coronal/ sagittal plane 45°-90°	Develop posterior HH control in coronal and sagittal plane 45°-90° Abd	Standing Ext row with TB at 90° ER with TB at 90° supported to unsupported. ER unsupported progressed from coronal plane to sagittal plane IR at with TB 90° supported to unsupported BOR at 90°	TB drills: 1-3 × 15-20 reps, 2 × d Yellow-red-green TB BOR: 0.5-1-1.5 kg, 2-3 × 20 reps, 2 × d	Ext at 90°: green TB ER at 90°: red-green TB IR at 90°: red-green TB BOR at 90°: 1.5-2 kg 2-3 × 15-20 reps 3-5 sec holds	Drills from stage 2 can be progressed to a strength dosage with increased load Ext row at 90° performed before adding ER at 90° IR after ER control established. Some patients may not require supported before unsupported ER/IR. ER unsupported progressed into sagittal plane to prepare for flexion to 90°
		Standing flexion in scapular to sagittal plane from 45° to 90° elevation Continue UR drill with increased load	Flexion: 1-3 × 15-20 reps, 2 × d Yellow-red-green TB UR: 3-4 kg	Flexion: sagittal plane red- green TB, 2-3 × 15-20 reps UR: 2-3 × 15-20 3-5+ kg	Palpate posterior HH for unwanted posterior translation especially when prescribing flexion exercises

(*continued on next page*)

Table 1 (*continued*)

Stage	Aims	Potential drills	Dosage/load	Goals	Considerations
Stage 4: coronal/ sagittal plane >90° and horizontal flexion control	Develop posterior HH control in coronal and sagittal plane >90° elevation and HF control	ER > 90-EROM IR> 90-EROM Flex> 90-EROM With TB Overhead press	Recruitment/endurance (1-2 × 20 reps, 2 × d) to strength (3 × 10-12 reps) to ballistic (1-2 × 10 + reps) dosage depending on patients needs. Yellow-red-green-blue TB[a] Weight for overhead press: 0 kg-0.5-1-2[a]	Dosage and load depend on patient's functional goals and ability to control movement. Guide: ER/IR: red-green HF with TB: red-green HF with weight 1-2.5 + kg Flex TB: red-green Flex weight: 1.5-2-3-4 + kg 1-4 × 4-20 reps depending on load, goals and patient control[a]	Drills from stage 3 can be progressed to a strength dosage with increased load Flexion > 90° typically commences with TB in scapular plane moving around to sagittal plane. Flexion weights typically commence after green flexion band in sagittal plane achieved.
		Horizontal flexion drill With TB With weight	HF with TB: 1-3 × 15-20 reps yellow-red-green[a] HF with weight: 1-4 × 6-20 reps 0.5-2.5 kg[a]		Horizontal flexion load progressed by having patient move torso around to commence drill in more HF.
Stage 5: sports-specific and functional stage	Part practise of function and integration into sport/functional tasks	Part practice (eg): catch phase of swim over swiss ball Whole practice: participation in training/sport/occupation	Part practice dosage and load needs to mimic demands of task. Whole practice progressed from small volume to larger volume	Return to sport/occupation/function	Specific middle deltoid or anterior deltoid drills may need to be prescribed if atrophy or weakness remains Integration of trunk stability and overall kinetic chain with shoulder drills needs to be considered. Power/speed drills may need to be considered if required for function/ sport Weight bearing drills may be contraindicated in posterior instability. Consider if weight bearing drills are functional for demands of patient.

Abd = abduction; BOR = bent over row; Ext = extension; ER = external rotation; EROM = end range of motion; HF = horizontal flexion; HH = humeral head; IR = internal rotation; MVC = maximal voluntary contraction; reps = repetitions; SR = scapula resistance; TB = theraband; UR = upward rotation.
Repetitions of exercises held for 3-5 seconds.

[a] Dosage and load can be progressed from a recruitment and endurance dosage, to a dosage and load functionally required by the patient. Exercises may need to be progressed to blue or black bands or heavier weights if functionally required by the patient. See the online supplementary file for the detailed flow charts for the posterior instability program.

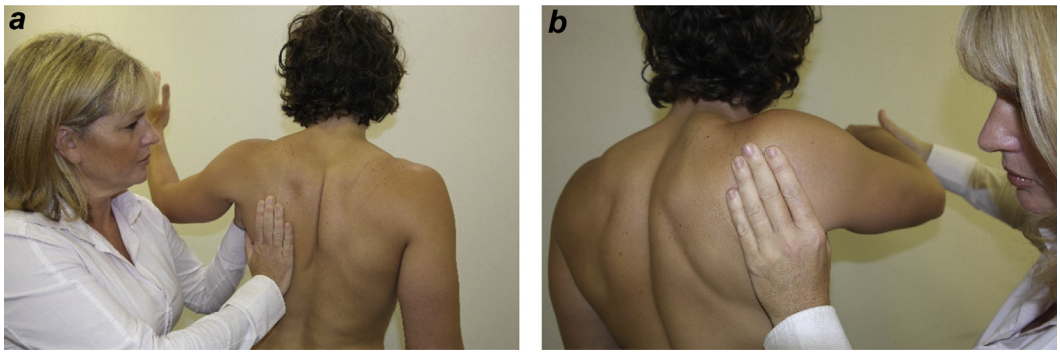

Fig. 3. Scapular correction. (**A**) Upward rotation, slight posterior tilt during active shoulder movement. (**B**) Upward rotation during resisted shoulder movement.

determine whether the assisted position improves the result of that test.[38,40] The process is used to determine if the patient is appropriate for rehabilitation, and if so, what scapular and/or HH position the patient needs to train and maintain throughout the program.

The steps for assessing the effect of correction and are as follows:

(a) The patient performs an objective test (ie, movement test and strength test), and the therapist notes scapular dyskinesis, symptoms onset, range of motion or strength deficits, and/or HH subluxation, depending on the objective test chosen.
(b) The therapist manually assists the scapula, then HH, and then a combination of both into a position that corrects the faulty biomechanics (eg, correction into scapular upward rotation if downward rotation was observed) at the same time as reassessing the objective test; noting any improvements in pain levels, range of motion, strength, patient apprehension, or HH subluxation.
(c) The correction position that most improves the patient's symptoms is the one that is retrained and adopted throughout the posterior instability program.

If none of the patient's objective tests improve with correction, the therapist must consider whether there are other factors contributing to the patient's presentation, such as a structural lesion or an inflammatory component.

Scapular correction

Scapular correction is performed by supporting the patient's scapula, under the axilla through range or during an isometric strength testing[38] (Fig. 3). In posterior instability, active flexion and abduction range (Fig. 3) is commonly used to assess the effect of scapular correction as patients with atraumatic instability typically have poor upward rotation and elevation though these ranges.[46,47] Resisted isometric ER is also useful to determine if scapular position can effect the force generation of the posterior rotator cuff. Care must be taken not to overcorrect the posterior tilt, which may increase posterior HH translation.

Humeral head (HH) correction

In patients with posterior instability, HH correction is performed by applying a gentle posterior to anterior pressure[48] to the HH and reassessing asterisk signs. Active flexion and active or passive horizontal flexion (Fig. 4**A**) are common tests used to assess the effect of correction. The test can further challenge posterior HH head control by placing the patient into horizontal flexion and asking them to apply a superior directed force (Fig. 4**B**) or a sagittal plane force (Fig. 4**C**) into the therapist's hand. Adding therapist load to a correction position must be performed with care and is only required if active and passive tests did not provoke symptoms.

The posterior instability program: intervention

There are 2 major phases to intervention component of the program: the scapular rehabilitation phase and the arc of motion phase. The scapular rehabilitation phase must be mastered before moving on to the arc of motion phase.

Scapular rehabilitation phase

The aim of the scapular rehabilitation phase was to develop adequate scapular control to centralize the HH and provide a stable base in preparation for the arc of motion phase. Assessment of the "effect of correction" determines the exact position the patient must retrain and maintain throughout the program.[38] This position is usually one of upward rotation, elevation, and possibly some posterior tilt. A scapular upward rotation/

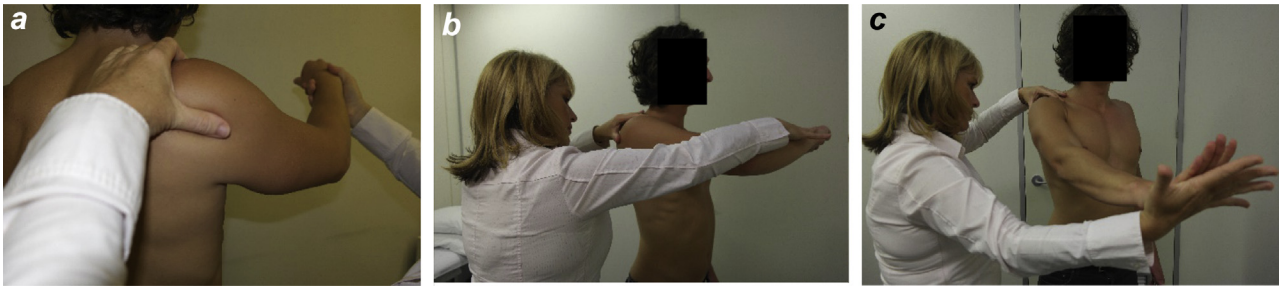

Fig. 4. Humeral head correction (**A**) during passive horizontal flexion; (**B**) during resisted flexion; (**C**) during a push forward into therapist hand.

Fig. 5. Scapular setting against theraband.

elevation drill is used to retrain this position[38] (Table 1). The patient performs this drill in standing with the arm in ER and in 20°-30° abduction as this recruits significantly more of the upward rotators of the scapula compared with the arm by the side.[49] If the patient has any signs of irritability in their rotator cuff, then this drill should be performed with the arm by the side until these symptoms subside.

The patient is aiming for a motor control dosage[50] of 3 sets of 20 repetitions with the weight of the arm. The initial dosage prescribed to the patient must be based on the number of repetitions the patient can achieve pain free and with good technique. The patient can be educated to work toward the desired motor control dosage of 60-100 repetitions per day.[51] If the patient is unable to perform at least 5 repetitions of the standing drill due to poor control, fatigue, shoulder, or cervical spine pain, the drill is commenced in side lie with the arm support by a pillow.

Once the patient can demonstrate adequate control with the weight of the arm, resistance can be added to the drill using a scapular resistance (SR) theraband (Hygenic Corporation, Akron, OH).[38] The SR band can be anchored anywhere to resist the patient-specific scapular drill, such as around the foot to resist upward rotation, or in front of the patient to resist upward rotation and posterior tilt (Fig. 5). The SR band can also be used in side lie to progress the patient to a standing position. Once the patient can perform the drill standing with the added resistance of the SR band and meets the recruitment dosage goal, weight can be added to the hand, typically starting at 0.5 kg and progressing in 0.5-kg increments to 1.5-2 kg.

The goal of the scapular rehabilitation phase was to achieve the desired scapular setting drill for 3 sets of 20 with 1.5-2 kg with or without the addition of the SR band at red (typical for females) or green (typical for males) theraband.

Arc of motion phase

The aim of the arc of motion phase was to develop adequate posterior HH control and then strength, through various planes of motion, while maintaining good scapular control. The arc of motion phase is divided into 5 stages (Table 1). The patient must demonstrate adequate scapular and HH control before the therapist progressing the dosage, arc of motion, and/or the degree of shoulder elevation. The therapist can determine if the patient is ready to progress by either isometrically loading the patient in the position of the proposed new drill and/or observing them perform the drill with a new load, pain free and with good scapular and HH control.

The patient typically performs their scapular upward rotation/elevation drill as a “setting” action against a SR band as a small movement before executing most exercise drills throughout the arc of motion phase. The therapist may also decide to add a HH band to the arc of motion drills that is positioned around the patient’s proximal biceps. The HH band provides an anterior directed force. The patient resists this force with a gentle isometric extension moment, which encourages activation of the posterior scapular and rotator cuff muscles which may assist in providing more stability for the HH.[52] The HH band may be used in combination with the SR band (Fig. 6).

Stage 1: coronal plane control 0° of elevation

The aim of stage 1 was to start developing posterior HH control in the coronal plane in 0° of elevation. Exercises that encourage activity of the scapular stabilizers, posterior rotator cuff, and posterior deltoid are used to gain control over posterior HH translation.[28] Standing extension with a theraband is the first exercise prescribed as it is relatively easy for the patient to control (Fig. 6). Extension drills are usually performed to neutral only

Fig. 6. Combining the scapular resistance band and humeral head band with isometric, short-lever extension drills.

Fig. 7. Short-lever flexion to 45° in the scapular plane.

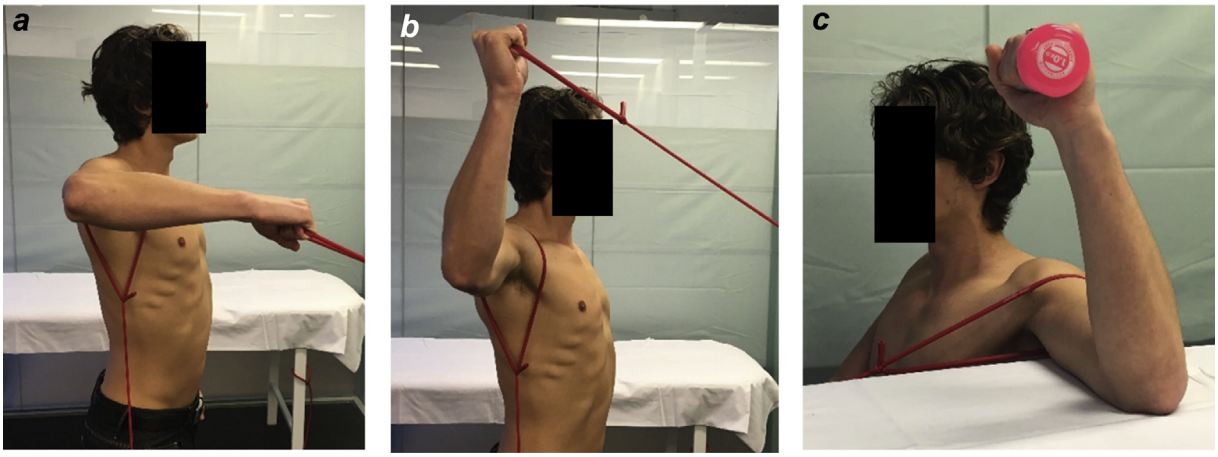

Fig. 8. Stage 3. (**A**) Standing extension at 90° abduction; (**B**) external rotation at 90° abduction; and (**C**) external rotation with the support of arm.

because extension past the side of the body can cause excessive anterior tilt of the scapula.[53] Standing ER with a theraband is then prescribed. Side lie ER is performed off a support to limit IR past neutral. Both ER with a theraband and side lie ER are initially limited at a range of 0° (neutral ER/IR) to 30°-45° ER to reduce posterior HH translation.[54] A bent over row to the side of the body can usually commence once the patient has achieved their ER with theraband and side lie ER goals. Care must be taken on the eccentric phase of the bent over row to ensure the weight in the hand can be controlled by the patient and does not cause excessive traction on the joint. IR with a theraband (from 45°-30° ER to 0°) typically commences after ER, and bent row control is established as IR can cause posterior translation of the HH as well as increased anterior tilt of the scapula and increased pectoralis dominance if commenced too early.[53]

Stage 2: coronal and sagittal plane control 0°-45° of elevation

The aim of stage 2 was to develop posterior HH control in the coronal plane to 45° of abduction and then the sagittal plane up to 45° degrees of elevation. Scapular and extension control is achieved in higher ranges by progressing the standing extension row with a theraband to 45° of elevation. Side lie ER is progressed in load, and a bent over row at 45° degrees of elevation is prescribed to activate posterior deltoid in a higher range of elevation.

Flexion drills commence once the patient has achieved stage 2 coronal plane goals and heavier loads for exercises in stage 1. Achieving these goals is likely to ensure that the patient has adequate posterior muscle bulk to prevent posterior HH translation in flexion. Flexion control is important to introduce because it is a very functional motion and has a high activation of serratus anterior and thus is essential for improving serratus anterior strength and therefore upward rotation of the scapula.[55] The flexion exercise requires the patient to perform a short arc standing punching motion with a theraband, typically in the scapular plane, which reduces the risk of posterior HH translation (Fig. 7). Once the patient has gained control of scapular plane flexion with a red or green theraband (1-3 sets of 15-20 reps), they can slowly progress the exercise around to the sagittal plane.

Stage 3: coronal and sagittal plane control 45°-90° of elevation

The aim of stage 3 was to develop posterior HH control in the coronal plane and then the sagittal plane up to 90° degrees of elevation. Scapular control and extension control are gained at a higher range by progressing the standing extension row with a theraband to 90° of elevation (Fig. 8**A**). Once the patient can perform the standing row at 90° with a green theraband, ER is added onto this motion with a lighter theraband (Fig. 8**B**). If the patient has pain or problems controlling ER at 90°, it can initially be performed on a support. Once unsupported ER at 90° elevation has been achieved, ER in the scapular then sagittal plane is commenced to develop posterior muscle bulk in preparation for flexion to 90° elevation.

A bent over row at 90° can often be commenced at the same time as standing extension row at 90° elevation. Standing or supported IR with a theraband commences after ER at 90° control has been achieved. Flexion exercises again commence after extension, ER, and IR controls have been gained. The patient may commence their higher flexion drills in the scapular plane and move around to the sagittal.

Stage 4: coronal and sagittal plane control above 90° of elevation and horizontal flexion control

The aim of stage 4 was to develop posterior HH control above 90° and control of horizontal flexion motion. For ER, IR, and flexion, the drill should start to mimic the position and motion required for the patient's functional and/or sports specific requirements. For example, ER then IR at 120° elevation may be required to mimic positions needed for a tennis serve or higher overhead tasks. Flexion above 90° degrees commences as a short-lever overhead press, progressing from the coronal to sagittal plane and from therabands to weights.

Horizontal flexion is very important to introduce in patients with posterior instability as this motion causes a high degree of posterior HH translation and must be controlled for activities of daily living such as driving, taking off a tight top, and sporting motions such as a backhand in tennis. Horizontal flexion and extension control is initially achieved by progressing the standing extension row at 90° of elevation. Over a number of weeks, the drill is progressed into a starting position of more horizontal flexion as the patient gradually turns their body in increments toward their affected shoulder until they are in a starting position with their arm across their chest (Fig. 9). If a patient has problems controlling a new degree of horizontal flexion, they must be regressed to a range of less horizontal flexion and gain control in that range with a heavier load before attempting to progress the range again. To assist with posterior control with increasing ranges of horizontal

Fig. 9. Drills into horizontal flexion.

flexion, supported ER with a weight can commence in the scapular plane and progress into the sagittal plane.

Stage 5: sports-specific and functional stage

The aim of stage 5 was to return the patient to their functional and/or sports specific goals. Part practice of a task requires exercises to be patient specific and should closely mimic the sport/activity. Breaking down drills into subcomponents can be useful for the patient to gain control over the entire motion. Dosage in this phase needs to represent what is functionally required of the patient. Adequate strength must be gained before dosages for muscle power.[56] Weight-bearing exercises (progressing from wall weight bearing drills to full weight bearing drills) can be used if the patient functionally requires them and should not be prescribed when any component of posterior instability remains. Whole practice can commence once part practice of a drill has been achieved, with gradual increases in volume as appropriate. At discharge, a maintenance program should be prescribed for the patient to perform 2-4 times a week.[28]

Posterior instability program: dosage

The commencing load and dosage for this drill always depend on individual assessment of the patient's ability to perform the movement correctly, with good scapular and HH control and in a pain-free manner. Typically patients commence a drill with a recruitment dosage (1-3 sets of 20 repetitions performed 2 or 3 times a day), followed by an endurance dosage (1-3 set of 10-15 repetitions 1 or 2 times a day), and moving onto a strength dosage in later stages (3-4 sets of 6-12 repetitions performed every second day).[44] Load for theraband exercises often commences with yellow, moving on to red then green theraband. Load for weights typically commence at 0.5 kg and progress in 0.5-1 kg increments up to 5 or more kilograms depending on the patient's gender, weight, and functional goals. Individualized patient assessment and the therapist's clinical reasoning skills should always guide dosage.

Conclusion

The exact incidence and prevalence of posterior instability is likely underestimated in the broader community, although there is increasing awareness of the existence of this pathology. Such awareness creates a demand for a greater understanding of clinical screening and examination procedures and an evidence-based for management. This article outlines the posterior instability program. The program integrates the evidence, clinical knowledge, and reasoning for the conservative management of posterior shoulder instability. The program is yet to be empirically tested and further studies are required to prove the efficacy of the program.

Supplementary data

Supplementary data related to this article can be found at http://dx.doi.org/10.1016/j.jht.2017.05.007

References

1. Ahlgren S-A, Hedlund T, Nistor L. Idiopathic posterior instability of the shoulder joint: results of operation with posterior bone graft. *J Am Acad Orthop Surg*. 1978;49(6):600–603.
2. Kroner K, Lind T, Jensen J. The epidemiology of shoulder dislocations. *Arch Orthop Trauma Surg*. 1989;108(5):288–290.
3. Liavaag S, Brox JI, Pripp AH, Enger M, Soldal LA, Svenningsen S. Immobilization in external rotation after primary shoulder dislocation did not reduce the risk of recurrence: a randomized controlled trial. *J Bone Joint Surg Am Vol*. 2011;93(10):897–904.
4. Nordqvist A, Petersson CJ. Incidence and causes of shoulder girdle injuries in an urban population. *J Shoulder Elbow Surg*. 1995;4(2):107–112.
5. Simonet WT, Melton 3rd LJ, Cofield RH, Ilstrup DM. Incidence of anterior shoulder dislocation in Olmsted County, Minnesota. *Clin Orthop Relat Res*. 1984;186:186–191.
6. Kuhn JE. A new classification system for shoulder instability. *Br J Sports Med*. 2010;44(5):341–346.
7. Owens BD, Duffey ML, Nelson BJ, DeBerardino TM, Taylor DC, Mountcastle SB. The incidence and characteristics of shoulder instability at the United States Military Academy. *Am J Sports Med*. 2007;35(7):1168–1173.
8. Millett PJ, Clavert P, Hatch III GR, Warner JJ. Recurrent posterior shoulder instability. *J Am Acad Orthop Surg*. 2006;14(8):464–476.
9. Provencher MT, LeClere LE, King S, McDonald LS, Frank RM, Mologne TS, et al. Posterior instability of the shoulder: diagnosis and management. *Am J Sports Med*. 2011;39(4):874–886.
10. Robinson CM, Aderinto J. Recurrent posterior shoulder instability. *J Bone Joint Surg Am Vol*. 2005;87(4):883–892.
11. Watson L, Pizzari T, Simmonds J, Lewis J. The unstable shoulder. In: Jull G, Moore A, Falla D, Lewis J, McCarthy C, Sterling M, eds. *Grieve's Modern Musculoskeletal Physiotherapy*. 4th ed. Edinburgh: Elsevier; 2015:568–575.
12. Kaplan LD, Flanigan DC, Norwig J, Jost P, Bradley J. Prevalence and variance of shoulder injuries in elite collegiate football players. *Am J Sports Med*. 2005;33(8):1142–1146.
13. Song DJ, Cook JB, Krul KP, Bottoni CR, Rowles DJ, Shaha SH, et al. High frequency of posterior and combined shoulder instability in young active patients. *J Shoulder Elbow Surg*. 2015;24(2):186–190.
14. Lewis A, Kitamura T, Bayley JIL. (ii) The classification of shoulder instability: new light through old windows!. *Curr Orthop*. 2004;18(2):97–108.
15. Provencher MT, King S, Solomon DJ, Bell SJ, Mologne TS. Recurrent posterior shoulder instability: diagnosis and management. *Oper Tech Sports Med*. 2005;13(4):196–205.
16. Thomas SC, Matsen 3rd FA. An approach to the repair of avulsion of the glenohumeral ligaments in the management of traumatic anterior glenohumeral instability. *J Bone Joint Surg Am Vol*. 1989;71(4):506–513.
17. VandenBerghe G, Hoenecke HR, Fronek J. Glenohumeral joint instability: the orthopedic approach. *Semin Musculoskelet Radiol*. 2005;9(1):34–43.
18. Hawkins RJ, McCormack RG. Posterior shoulder instability. *Orthopedics*. 1988;11(1):101–107.
19. Hakim A, Grahame R. Joint hypermobility. *Best Pract Res Clin Rheumatol*. 2003;17(6):989–1004.
20. Simmonds JV, Keer RJ. Hypermobility and the hypermobility syndrome. *Man Ther*. 2007;12(4):298–309.
21. Muhammad AA, Jenkins P, Ashton F, Christopher MR. Hypermobility a risk factor for recurrent shoulder dislocations. *Br J Sports Med*. 2013;47(10):e3.
22. Tannenbaum E, Sekiya JK. Evaluation and management of posterior shoulder instability. *Sports Health*. 2011;3(3):253–263.
23. Rouleau DM, Hebert-Davies J. Incidence of associated injury in posterior shoulder dislocation: systematic review of the literature. *J Orthop Trauma*. 2012;26(4):246–251.
24. Hawkins RJ, Neer 2nd CS, Pianta RM, Mendoza FX. Locked posterior dislocation of the shoulder. *J Bone Joint Surg Am Vol*. 1987;69(1):9–18.
25. Xu W, Huang L-X, Guo JJ, Jiang D-H, Zhang Y, Yang H-L. Neglected posterior dislocation of the shoulder: A systematic literature review. *J Orthop Translat*. 2015;3(2):89–94.
26. Bokor DJ, Fritsch BA. Posterior shoulder instability secondary to reverse humeral avulsion of the glenohumeral ligament. *J Shoulder Elbow Surg*. 2010;19(6):853–858.

27. Fronek J, Warren R, Bowen M. Posterior subluxation of the glenohumeral joint. *J Bone Joint Surg*. 1989;71(2):205–216.
28. McIntyre K, Bélanger A, Dhir J, et al. Evidence-based conservative rehabilitation for posterior glenohumeral instability: A systematic review. *Phys Ther Sport*. 2016;22:94–100.
29. McFarland EG, Hsu CY, Neira C, O'Neil O. Internal impingement of the shoulder: a clinical and arthroscopic analysis. *J Shoulder Elbow Surg*. 1999;8(5):458–460.
30. McFarland EG, Campbell G, McDowell J. Posterior shoulder laxity in asymptomatic athletes. *Am J Sports Med*. 1996;24(4):468–471.
31. Chronopoulos E, Kim TK, Park HB, Ashenbrenner D, McFarland EG. Diagnostic value of physical tests for isolated chronic acromioclavicular lesions. *Am J Sports Med*. 2004;32(3):655–661.
32. Walton J, Mahajan S, Paxinos A, et al. Diagnostic values of tests for acromioclavicular joint pain. *J Bone Joint Surg Am Vol*. 2004;86-A(4):807–812.
33. Barrett C. The clinical physiotherapy assessment of non-traumatic shoulder instability. *Shoulder Elbow*. 2015;7(1):60–71.
34. Lewis JS. Rotator cuff tendinopathy/subacromial impingement syndrome: is it time for a new method of assessment? *Br J Sports Med*. 2009;43(4):259–264.
35. Odom CJ, Taylor AB, Hurd CE, Denegar CR. Measurement of scapular asymmetry and assessment of shoulder dysfunction using the Lateral Scapula Slide Test: A reliability and validity study. *Phys Ther*. 2001;81(2):799.
36. Seitz AL, McClure PW, Lynch SS, Ketchum JM, Michener LA. Effects of scapular dyskinesis and scapular assistance test on subacromial space during static arm elevation. *J Shoulder Elbow Surg*. 2012;21(5):631–640.
37. Struyf F, Nijs J, Baeyens JP, Mottram S, Meeusen R. Scapular positioning and movement in unimpaired shoulders, shoulder impingement syndrome, and glenohumeral instability. *Scand J Med Sci Sports*. 2011;21(3):352–358.
38. Watson L, Warby S, Balster S, Lenssen R, Pizzari T. The treatment of multidirectional instability of the shoulder with a rehabilitation program: Part 1. *Shoulder Elbow*. 2016;8(4):271–278.
39. Watson LA, Pizzari T, Balster S. Thoracic outlet syndrome part 1: clinical manifestations, differentiation and treatment pathways. *Man Ther*. 2009;14(6):586–595.
40. Watson LA, Pizzari T, Balster S. Thoracic outlet syndrome part 2: conservative management of thoracic outlet. *Man Ther*. 2010;15(4):305–314.
41. DeLong JM, Bradley JP. Management of Posterior Shoulder Instability in the Contact Athlete. *Oper Tech Sports Med*. 2016;24(4):286–299.
42. Warby S, Ford JJ, Hahne AJ, et al. The effect of rehabilitation programs on multidirectional instability of the shoulder: A randomised controlled trial. Australian Conference of Science and Medicine in Sport; 12–15 October 2016; Melbourne, Australia 2016.
43. Watson L. *Functional and clinical changes in multidirectional instability of the shoulder after conservative management [D.Physio]*. Melbourne, Australia: La Trobe University; 2015.
44. Watson L, Warby S, Balster S, Lenssen R, Pizzari T. The treatment of multidirectional instability of the shoulder with a rehabilitation programme: Part 2. *Shoulder Elbow*. 2017;9(1):46–53.
45. Warby SA, Ford JJ, Hahne AJ, et al. Effect of exercise-based management on multidirectional instability of the glenohumeral joint: a pilot randomised controlled trial protocol. *BMJ Open*. 2016;6(9):e013083.
46. Illyes A, Kiss J, Kiss RM. Electromyographic analysis during pull, forward punch, elevation and overhead throw after conservative treatment or capsular shift at patient with multidirectional shoulder joint instability. *J Electromyogr Kinesiol*. 2009;19(6):e438–e447.
47. Ogston JB, Ludewig PM. Differences in 3-dimensional shoulder kinematics between persons with multidirectional instability and asymptomatic controls. *Am J Sports Med*. 2007;35(8):1361–1370.
48. Farber AJ, Castillo R, Clough M, Bahk M, McFarland EG. Clinical assessment of three common tests for traumatic anterior shoulder instability. *J Bone Joint Surg Am Vol*. 2006;88(7):1467–1474.
49. Pizzari T, Wickham J, Balster S, Ganderton C, Watson L. Modifying a shrug exercise can facilitate the upward rotator muscles of the scapula. *Clin Biomech*. 2014;29(2):201–205.
50. Adkins DL, Boychuk J, Remple MS, Kleim JA. Motor training induces experience-specific patterns of plasticity across motor cortex and spinal cord. *J Appl Physiol (1985)*. 2006;101(6):1776–1782.
51. Boudreau SA, Farina D, Falla D. The role of motor learning and neuroplasticity in designing rehabilitation approaches for musculoskeletal pain disorders. *Man Ther*. 2010;15(5):410–414.
52. Pizzari T, Ganderton C, Watson L, Balster S. A novel exercise for retraining the rotator cuff muscles of the shoulder. *J Sci Med Sport*. 2013;16:e7.
53. Kronberg M, Nemeth G, Brostrom LA. Muscle activity and coordination in the normal shoulder. An electromyographic study. *Clin Orthop Relat Res*. 1990;257:76–85.
54. Karduna AR, Williams GR, Williams JL, Iannotti JP. Kinematics of the glenohumeral joint: influences of muscle forces, ligamentous constraints, and articular geometry. *J Orthop Res*. 1996;14(6):986–993.
55. Decker MJ, Hintermeister RA, Faber KJ, Hawkins RJ. Serratus anterior muscle activity during selected rehabilitation exercises. *Am J Sports Med*. 1999;27(6):784–791.
56. Angelozzi M, Madama M, Corsica C, et al. Rate of force development as an adjunctive outcome measure for return-to-sport decisions after anterior cruciate ligament reconstruction. *J Orthop Sports Phys Ther*. 2012;42(9):772–780.

JHT Read for Credit
Quiz: #486

Record your answers on the Return Answer Form found on the tear-out coupon at the back of this issue or to complete online and use a credit card, go to *JHTReadforCredit.com*. There is only one best answer for each question.

#1. The authors suggest that posterior shoulder instabilities and subluxations are
   a. exceedingly common
   b. exceedingly uncommon
   c. likely less common than traditionally represented
   d. likely more common than traditionally represented

#2. Posterior shoulder instabilities are usually classified by the
   a. mechanism of injury
   b. acronyms TUBS and AMBRI
   c. severity of laxity
   d. severity of damage to the glenoid labrum

#3. A classic problem in dealing with posterior shoulder instability is its being
   a. missed upon initial examination
   b. extremely difficult to manage
   c. required to be surgically repaired
   d. more painful than anterior instability

#4. The authors recommend the systematic review of _____ for diagnosing posterior shoulder instability
   a. McClure et al
   b. McIntyre et al
   c. MacDermid et al
   d. McDonald et al

#5. Conservative treatment is the first line of management for posterior shoulder instability
   a. false
   b. true

When submitting to the HTCC for re-certification, please batch your JHT RFC certificates in groups of 3 or more to get full credit.