Restorative Neurology and Neuroscience 28 (2010) 33–42
DOI 10.3233/RNN-2010-0533
IOS Press

Vestibular function after acute vestibular neuritis

G.M. Halmagyi[a,*], K.P. Weber[a,b] and I.S. Curthoys[c]
[a]*Department of Neurology, Royal Prince Alfred Hospital, Camperdown, Sydney, NSW, Australia*
[b]*Present address: Department of Neurology, Zürich University Hospital, Zürich, Switzerland*
[c]*School of Psychology, University of Sydney, Sydney, NSW, Australia*

Abstract. *Purpose*: To review the extent and mechanism of the recovery of vestibular function after sudden, isolated, spontaneous, unilateral loss of most or all peripheral vestibular function – usually called acute vestibular neuritis.
Methods: Critical review of published literature and personal experience.
Results: The symptoms and signs of acute vestibular neuritis are vertigo, vomiting, nystagmus with ipsiversive slow-phases, ipsiversive lateropulsion and ocular tilt reaction (the static symptoms) and impairment of vestibulo-ocular reflexes from the ipsilesional semicircular canals on impulsive testing (the dynamic symptoms). Peripheral vestibular function might not improve and while static symptoms invariably resolve, albeit often not totally, dynamic symptoms only improve slightly if at all.
Conclusions: The persistent loss of balance that some patients experience after acute vestibular neuritis can be due to inadequate central compensation or to incomplete peripheral recovery and vestibular rehabilitation has a role in the treatment of both.

Keywords: Vestibular, deafferentation, neuritis, compensation, rehabilitation

1. Introduction

It has been known since Flourens' experiments on pigeons (1842) that acute experimental destruction of one inner ear invariably causes a dramatic but temporary stereotyped syndrome of disturbed posture, balance and movement. The original observation that this syndrome resolves spontaneously, whereas of course the ear does not, has been confirmed not only in pigeons but in all creatures with 2 inner ears, so far tested. Resolution of this acute unilateral vestibular deafferentation (uVD) syndrome by central vestibular compensation, is not only invariable but is almost complete and largely unstoppable; while enforced immobilization and maybe cerebellar lesions (Furman et al., 1997) will retard recovery of postural balance, there is no focal CNS lesion that does not of itself cause a deficit, and no drug or agent that is not of itself toxic that can do so. In humans, as in pigeons, acute uVD whether by disease, accident or design also produces the uVD syndrome, which, superficially at least, resolves spontaneously and more or less completely. More detailed observations however reveal that the recovery from a surgical uVD is not only symptomatically incomplete in about 20% of subjects, with persistent complaints of postural imbalance, but is invariably incomplete when dynamic vestibular reflexes in response to natural stimuli are measured. Here we explore the question of how complete overall balance recovery really is from a naturally occurring acute, spontaneous, isolated, unilateral vestibular lesion – *acute vestibular neuritis*, after which there is the possibility not only for central vestibular compensation but also for partial or even complete recovery of inner ear vestibular function to occur.

2. What happens if one intact labyrinth is surgically destroyed?

Acute, total, surgical destruction or deafferentation of one entire intact labyrinth, in an animal or a human, invariably produces an acute, temporary, stereotyped clinical syndrome of profound motor and sensory ab-

*Corresponding author: Prof. G. M. Halmagyi, Department of Neurology, Royal Prince Alfred Hospital, Camperdown NSW 2050, Australia. Tel.: +61 2 9515 8820; Fax: +61 2 9515 8347; E-mail: michael@icn.usyd.edu.au.

0922-6028/10/$27.50 © 2010 – IOS Press and the authors. All rights reserved

normalities affecting posture, balance and movement (for reviews, see Curthoys and Halmagyi 1999; 2007). In considering the manifestations of the acute uVD syndrome it is useful to distinguish those that result from semicircular canal (SCC) deafferentation from those that result from otolith deafferentation. It is also useful to distinguish those manifestations that reflect a left-right asymmetry in the resting rate of vestibular nucleus neurons – the static symptoms – from those that reflect abnormal input-output dynamics of vestibular reflexes, the dynamic symptoms. The difference between static and dynamic SCC symptoms is clearly shown by the difference between the immediate manifestations of unilateral vestibular *inactivation* by SCC occlusion and those of unilateral vestibular *deafferentation* by vestibular nerve section (VNX). The key difference is that SCC occlusion unlike VNX does not abolish the resting activity of primary vestibular neurons, and therefore does not deafferent the secondary vestibular neurons in the vestibular nucleus. The result is that whereas after both SCC occlusion and VNX there is a similar dynamic deficit of the vestibulo-ocular reflex (VOR) in response to rapid head rotations toward the lesioned side, after SCC occlusion, unlike after VNX, there is no spontaneous nystagmus, i.e. no static deficit, since the resting rate of vestibular ganglion neurons and thereby of vestibular nucleus neurons is unaffected.

After acute surgical uVD there is, due to otolith deafferentation, ipsilesional lateropulsion (irresistible falling towards the side of the lesion while attempting to stand), an ipsilesional tilt of body posture (Borel et al., 2002) and a complete or, more often, partial ipsilesional ocular tilt reaction. The complete ocular tilt reaction consists of head tilt, conjugate binocular eye torsion and a hypotropia due to skew deviation all to one side (Vibert et al., 1995 and 1996; Riordan-Eva et al., 1997) (Fig. 1). The sensory manifestation of ocular torsion is a deviation of the subjective visual vertical (SVV) or horizontal (SVH) to the lesioned side (Curthoys et al., 1991; Tabak et al., 1997; Vibert et al., 1999; Vibert and Häusler, 2000). The deviation of the SVV is larger while sitting than while standing (Lopez et al., 2008) during head or neck vibration (Karlberg et al., 2002), during torsional optokinetic stimulation (Lopez et al., 2007), and during eccentric rotation (Hong et al., 2009). Due to semicircular canal (SCC) deafferentation, there is a spontaneous horizontal-torsional nystagmus, with the slow phases toward the side of the lesion. The head-impulse test shows impaired function from all 3 SCCs (Cremer et al., 1998). In the Unterberger stepping test the patient rotates to the side of the lesion (Hickey et al., 1990) and in the Romberg test on foam the patient falls (Federica et al., 2009). At rest humans, and perhaps animals, experience an illusion of rotation (vertigo), towards the intact side and reduced perception of roll tilt towards the lesioned side (Dai et al., 1989). These symptoms and signs make up the acute unilateral vestibular deafferentation (uVD) syndrome which invariably resolves in hours to days in animals and in days to weeks in most humans so that they recover, more or less completely, by the process of *central vestibular compensation*, although the angular and the linear vestibulo-ocular reflex (VOR) does not recover but remains permanently deficient in response to rapid accelerations. In other words while the static

Fig. 1. Complete left ocular tilt reaction (OTR) in a patient with an acute left peripheral vestibular lesion. There is a conjugate leftward (i.e counterclockwise from the patient's point-of-view) eye-in-head ocular torsion of about 25 deg, a leftward head tilt, of about the same degree and a left skew deviation (left hypotropia). The subjective visual horizontal was offset to the left by about 20 degrees. From Halmagyi et al., (1979), with permission.

balance disorder induced by uVD recovers more or less completely, the dynamic deficit does not. There are also distressing autonomic symptoms, malaise, sweating, nausea and vomiting. (The caloric test and vestibular evoked myogenic potential (VEMP) test are, by definition, absent on the lesioned side.)

Central vestibular compensation of uVD depends on restoration of equal resting neural activity of the left and right vestibular nuclei. Normally, when the head is upright and at rest, corresponding neurons in the two vestibular ganglia and in the two vestibular nuclei have equal spontaneous firing rates. When, for example, the head rotates to the right there will be increased activity of right and decreased activity of left lateral SCC nerve and medial vestibular nucleus neurons (Fig. 2). In fact if right medial vestibular nucleus neural activity is greater than left medial vestibular nucleus activity for any reason at all, this can be processed and interpreted by the brain only as a rightward angular acceleration. Immediately after an acute left uVD, right vestibular nucleus resting neural activity will be greater than left so that the sensory and motor consequences will be that of a constant rightward angular and linear acceleration; nystagmus with leftward slow-phases and rightward quick-phases (i.e. a right "beating" nystagmus), a leftward ocular tilt reaction (OTR) and leftward lateropulsion, in other words an acute left uVD syndrome. Neural recordings in animals recovering from uVD show that central compensation depends on the restoration of normal spontaneous neural activity in the ispilesional vestibular nucleus thereby rebalancing activity of the left and right vestibular nuclei. How this occurs is discussed from a cellular point of view by Lacour in this issue of the Journal. There is also morphometric evidence for structural changes in the human brain that might indicate central vestibular compensation (Helmchen et al., 2009). Although once resting neural activity is equal in the left and right vestibular nuclei the static symptoms of the uVD, the nystagmus and the OTR, disappear, the dynamic symptoms, due to impairment of the VOR, are permanent. This is because neurons in the vestibular ganglion and in the vestibular nucleus have not only a resting rate but also inhibitory saturation. For example a rapid leftward angular acceleration in any animal or human at any time after a left uVD will reach the inhibitory saturation of the only functioning lateral SCC primary and secondary neurons – on the right – and result in a deficient VOR. This is the neurophysiological basis of the head-impulse test – widely used in clinical diagnosis of uVD (Halmagyi et al., 2008).

What are the permanent objective vestibular deficits once vestibular compensation is complete, so that there is a chronic stable uVD? After uVD all patients will have a permanent impairment of the VOR from all 3 SCCs in response to rapid ipsilesional head rotations – in other words a positive head-impulse test (Cremer et al., 1998) as well as impairment of the linear VOR from the otoliths in response to lateral head heaves (Crane et al., 2005; Kessler et al., 2007). In some uVD patients the *clinical* head-impulse sign will be difficult to detect because the catch-up saccades are largely covert - that is they occur during rather than just after the head rotation. In such cases the quantitative head-impulse test with search-coil or video measurement of eye and head rotation will invariably demonstrate the VOR deficit and reveal the corresponding catch-up saccade pattern (Weber et al., 2008). About 50% of uVD patients will, after vigorous horizontal head-shaking, show horizontal nystagmus beating away from the side of the lesion (Park et al., 2008). In some patients body posture is slightly but permanently tilted towards the lesioned side (Borel et al., 2002). Some are unable to stand on a foam surface with the eyes shut and the feet together – a positive foam Romberg test (Federica et al., 2009). This test is almost equivalent to conditions 5 of the clinical test of sensory interaction in balance (CTSIB) during dynamic posturography (Whitney et al., 1998), especially if the platform can tilt in the roll plane (side-to-side) rather than just in the pitch (fore-aft) plane (Mbongo et al., 2005;2009). With compensation the SVV will return to almost normal (Curthoys et al., 1991; Goto et al., 2003; Hafström et al., 2004). What symptoms might patients with chronic uVD then experience? They will of course no longer experience vertigo, which is due to unequal asymmetrical resting activity between the left and right vestibular nuclei, and most patients will experience no symptoms at all, so that they cannot tell that they are balancing with only one ear rather than with the usual two. However about 20% of patients with a chronic stable uVD will continue to experience chronic postural imbalance and vertical oscillopsia – the same symptoms that all patients with bilateral vestibular deafferentation experience, symptoms which constitute the syndrome of chronic vestibular insufficiency (Reid et al., 1996). There is however no objective vestibular test that reliably distinguishes symptomatic from asymptomatic chronic uVD patients (Palla et al., 2008; Mbongo et al., 2007). A high degree of visual dependency before uVD retards early recovery of balance but makes no difference to the final outcome (Parietti-Winkler et al., 2008).

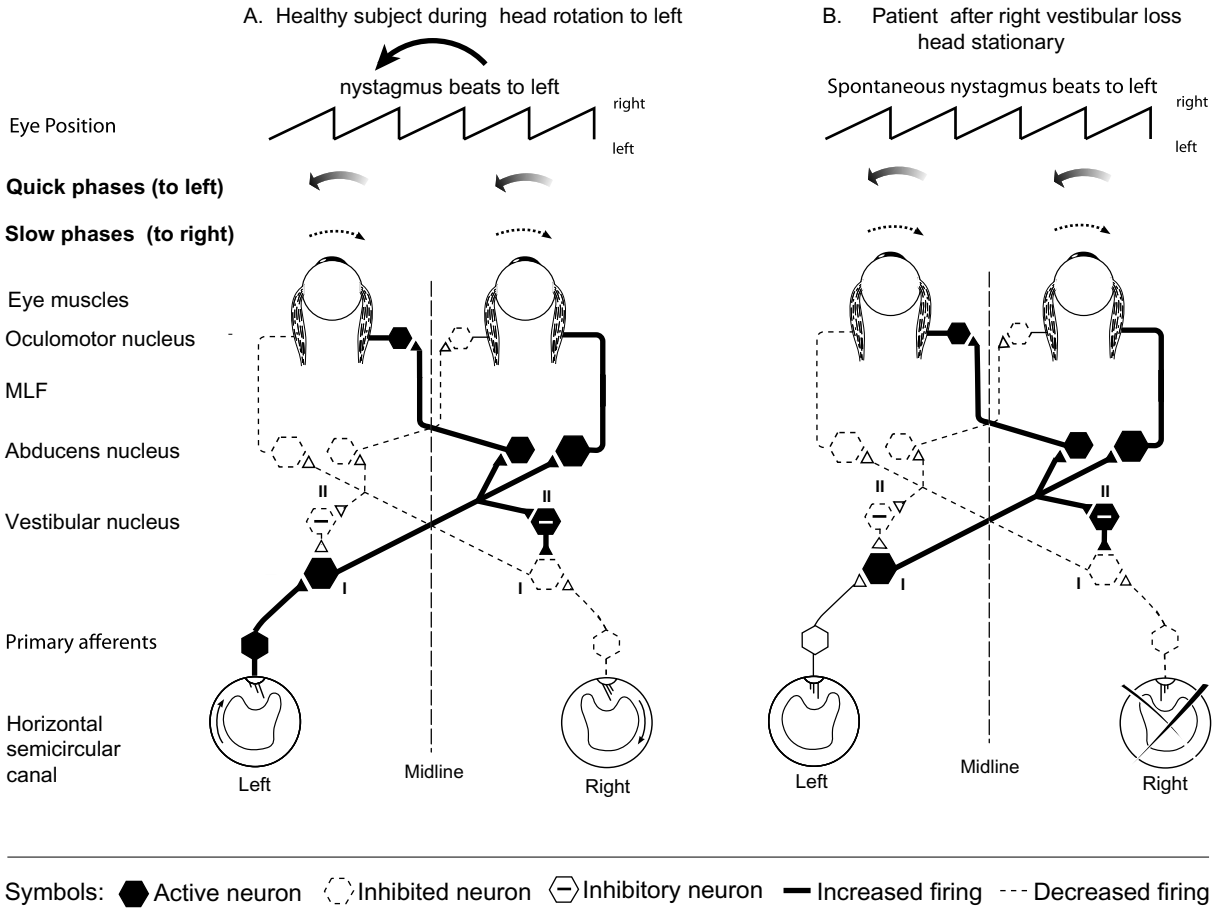

Fig. 2. To explain the neural basis of nystagmus in response to horizontal head rotation to the left in a healthy subject (A), and the spontaneous nystagmus during acute vestibular neuritis on the right (B). In both cases the eyes show quick phases to the left, reflecting an imbalance in neural activity between the two vestibular nuclei. This schematic figure is based on known anatomical projections and physiological evidence. A. An angular acceleration to the left excites primary afferents from the left semicircular canal (thick lines) and inhibits afferents from the right semicircular canal (dashed lines). Medial vestibular nucleus (MVN) type I neurons on the left receive peripheral afferent input and are excited (thick lines) and project to the contralateral (right) abducens nucleus and excite motoneurons for the (right) lateral rectus and also internuclear neurons projecting in the medial longitudinal fasciculus (MLF) to cells in the left oculomotor nucleus driving the (left) medial rectus. So increased activity of the left semicircular canal afferents results in activation of both the lateral rectus and the medial rectus of the two eyes, so both eyes execute conjugate slow phases to the right (in a direction to compensate for the head rotation). The slow phases are interspersed with quick return phases which are the eye movements observed by clinical observation. (The neural circuitry for the quick phases is not shown in this schematic figure.) In addition to the projection from MVN type I neurons to contralateral abducens, there is a functionally inhibitory commissural interconnection between the two vestibular nuclei, so the increased activity of the MVN neurons in the left MVN acts to reduce the activity of MVN neurons in the right MVN. That functional inhibition is achieved by a branch of the left MVN type I neuron activating a type II neuron in the right vestibular nucleus. Type II neurons are inhibitory neurons (closed hexagons) so their increased inhibition of right type I MVN neurons in the right vestibular nuclei tends to further silence the activity of MVN type I neurons on the right side, which already have a low activity due to reduced afferent input from the right semicircular canal. The reduced activity from type I MVN neurons on the right (dashed lines) reduces the excitation of the contralateral abducens neurons and also reduces the functional inhibition on type I MVN neurons on the left. The overall result is an imbalance in activity of type I neurons between the two vestibular nuclei (compare thick lines and dashed lines for the two sides). B. After unilateral vestibular loss on the right, primary afferents on the right side are silenced, so MVN type I neurons on the right have a decreased activity and exert less inhibition via the commissural inhibitory connection on type I neurons on the left. The result again is an imbalance in activity of type I neurons between the two vestibular nuclei and the nystagmus is identical in the two cases.

While patients with a chronic progressive uVD, as occurs with a slowly growing tumour such as a vestibular schwannoma, do not experience the acute uVD syndrome because there is never a prolonged period of asymmetrical resting neural activity in the vestibular nuclei, nonetheless these patients will eventually have the same VOR impairment and can report the same problems with ataxia and oscillopsia (chronic vestibu-

lar insufficiency) as do patients who have had an acute uVD. Nevertheless it seems to us that fewer patients develop balance problems after a progressive than after acute uVD, perhaps because they have had time to adapt, and that the chronic vestibular insufficiency is less severe in those who do. While these observations are relevant when considering surgical uVD, they are not relevant to acute vestibular neuritis (AVN) since it is, by definition, always acute. In this regard patients with vestibular schwannomas and some residual vestibular function in the affected ear have less imbalance following surgery if they undergo uVD before surgery by intratympanic gentamicin followed by intensive rehabilitation than if they simply undergo uVD during the surgery (Magnusson et al., 2007).

3. What is acute vestibular neuritis?

A total acute surgical uVD of an intact labyrinth is rarely deliberate but is usually due to a surgical mishap (for example during stapedectomy) or accidental injury (for example transverse temporal bone fracture). In contrast vestibular function in patients having vestibular schwannomas removed or having intratympanic gentamicin or vestibular neurectomy for Meniere's disease, is already impaired in the affected ear, so they will not experience a severe uVD syndrome. A general rule is that the more vestibular function is lost before uVD, the less severe will be the acute uVD syndrome.

On the other hand an acute, isolated, *spontaneous*, uVD, called acute *vestibular neuritis* (or neuronitis) and attributed to a subtle viral infection, often happens. Some call it labyrinthitis or neurolabyrinthitis but generally these terms are used when there is also cochlear involvement. The multiplicity of terms reflects the uncertainty of the pathology – discussed below, so that some favour the non-committal term *acute unilateral peripheral vestibulopathy*. Some patients have prodromal minor vertigo attacks before the onset of vestibular neuritis (Lee et al., 2009).

In the acute stage of vestibular neuritis three different clinical patterns of vestibular abnormalities can be identified:

1. Total uVD pattern in which the symptoms and signs are identical to those produced by surgical uVD of an intact ear. There is 3rd degree horizontal-torsional nystagmus in the dark, usually only 2nd degree in light, an ipsiversive OTR sometimes with overt skew deviation (Safran et al., 1994; Vibert et al., 1996; 1999), ipsiversive lateropulsion, impaired VOR from all 3 SCCs and from the otoliths on impulsive testing (Baloh, 2003; Mandalà et al., 2008) and absent VEMPs (Murofushi et al., 2006). The nystagmus will be contraversive, that is, the quick phases will beat *away* from the affected side. In the Unterberger (or Fukuda) stepping test the patient will gradually rotate towards the side of the lesion (Hickey et al., 1990) and in the Romberg test on foam rubber the patient will fall (Federica et al., 2009). The clinical head-impulse test will be positive for all 3 SCCs and can distinguish AVN from the only potentially serious cause of a first ever attack of acute, isolated spontaneous vertigo, cerebellar infarction (Newman-Toker et al., 2008). The caloric test will show a severely impaired or absent response even with the strongest stimulus possible, ice water. The spontaneous nystagmus starts to subside within about 48 hours and is usually all gone, even in darkness after 2–3 weeks. The OTR, most easily measured as a deviation of the SVH or SVV, starts to decrease after about 2 weeks (Vibert et al., 1999). Just as after surgical uVD the nystagmus and OTR will invariably resolve through brainstem vestibular compensation even when the function of the affected labyrinth does not.
2. Superior vestibular nerve pattern. Similar to the total uVD pattern except that posterior SCC function – as shown by impulsive testing (Aw et al., 2001), and saccular function – as shown by VEMP testing (Chen et al., 2000), appear preserved. Posterior SCC function is transmitted exclusively and saccular function substantially by the inferior vestibular nerve. This might be the most common pattern, possibly because the bony canal of the superior vestibular nerve is longer than that of the inferior nerve (Gianoli et al., 2005).
3. Inferior vestibular nerve pattern. There is surprisingly little or no spontaneous nystagmus, no OTR or lateropulsion but absent VOR on impulsive testing only from the posterior SCC and a reduced or absent VEMP to air-conducted click or tone-burst stimuli (Aw et al., 2001; Murofushi et al., 2006). The caloric test, which depends largely on lateral canal and superior nerve function, is normal. This seems to be the least common but is also the hardest to recognize so that many

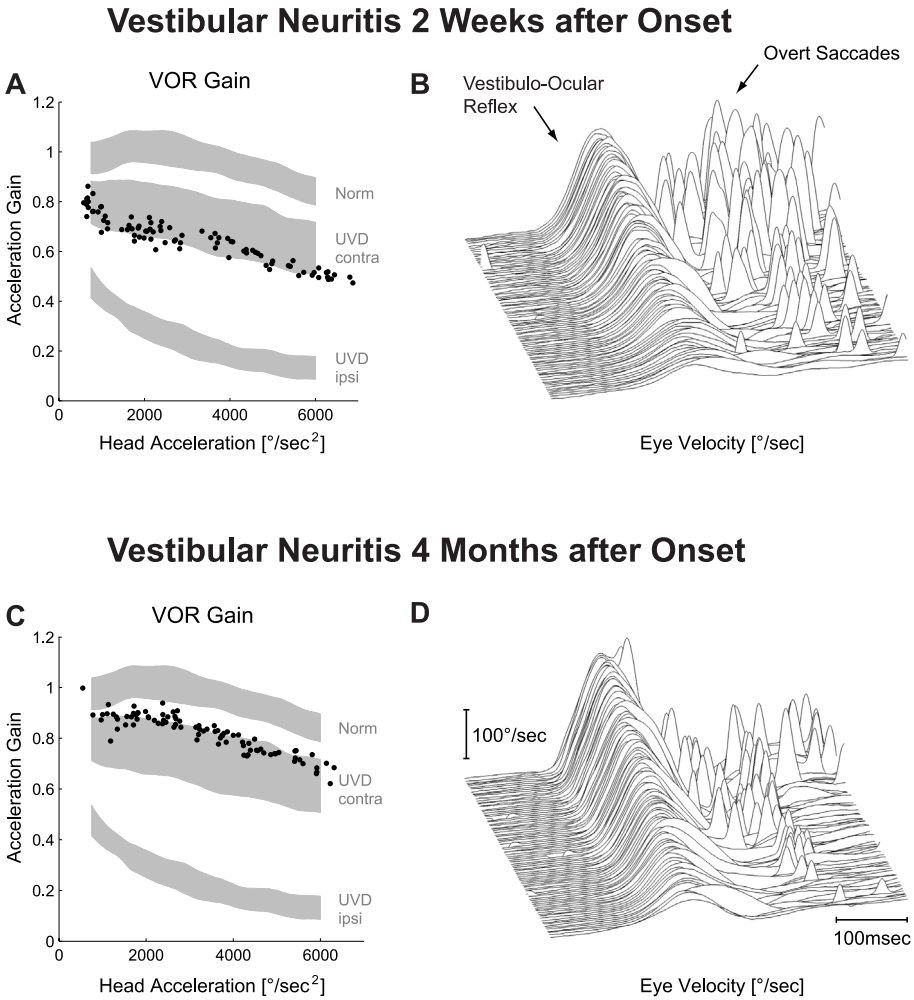

Fig. 3. Recovery of vestibular function in a patient after vestibular neuritis. (A) Two weeks after onset the head-impulse test shows a moderate gain deficit of the vestibulo-ocular reflex (VOR) to the affected side. (B) To compensate for this deficit the patient generates overt saccades after head rotation that are easy to detect at the bedside. (C) Four months after onset the gain of the VOR had recovered almost half-way. (D) The amplitude of the catch-up saccades decreased accordingly while the patient largely recovered from his symptoms. (A, C) Gray shaded bands indicate 95% confidence intervals of gain as a function of head acceleration in normal subjects (top) and in contralesional (middle) and ipsilesional (bottom) head-impulses of patients after unilateral vestibular deafferentation (uVD). (B, D) Time series (500msec) of stacked eye velocity traces in response to head-impulses of increasing peak velocity to the affected side. (Reproduction of reference values (A, C) and data (B) from Weber et al., (2008) with permission of The American Academy of Neurology Press, St. Paul, MN and Lippincott Williams & Wilkins, Baltimore, MD.).

examples might be missed. As so little is known about such cases they will not be discussed any more here.

Although all AVN patients recover, usually in about a week, from the acute uVD syndrome, peripheral vestibular function of the affected ear, as measured by caloric or impulsive tests of lateral canal function or VEMP tests of otolith function, might not do so. In AVN patients, unlike in acute surgical uVD patients, the clinical recovery from the uVD syndrome can be not only by central vestibular compensation but also by recovery of peripheral vestibular function (Fig. 3). Of those patients who do not totally recover peripheral vestibular function, some, just as some of those who have had surgical acute uVD, will continue to experience symptoms of chronic vestibular insufficiency (postural imbalance and oscillopsia). The residual vestibular deficit can be detected with an extended vestibular testing battery including spontaneous, vibration-induced and head shaking nystagmus and SVV, even if caloric testing returns to normal (Park et al., 2009). One could assume that the frequency and severity of chronic

vestibular insufficiency after AVN would be less than after acute surgical uVD, since after AVN there is a chance of some peripheral vestibular recovery whereas after surgical uVD there is not. The related question of how much peripheral vestibular recovery there can be after intratympanic gentamicin uVD for Meniere's disease is an interesting but so far unanswered question (de Waele et al., 2002; Carey, 2004).

There are many other unsolved questions concerning AVN. For example, what is the evidence that the site of lesion is the vestibular nerve rather than the labyrinth, is it really a "neuritis" (Nadol, 1995)? There is only one report of temporal bone pathology in vestibular neuritis - in a patient who 7 years earlier had a single well-documented attack of acute unilateral peripheral vestibulopathy (Baloh et al., 1996). In this case most of the degeneration was in the vestibular nerve and the sensory epithelial changes were considered secondary to the nerve damage. Moreover what is the evidence that vestibular neuritis is caused by a viral infection? Herpes zoster can cause an acute uVD (Ozeki et al., 2006) with loss of hearing and a facial palsy (Ramsay Hunt syndrome) and the virus can be found in the vestibular (Scarpa's), spiral (cochlear) and geniculate (facial) ganglia (Wackym, 1997; Kuhweide et al., 2002; Lu and Young, 2003; Ohtani et al., 2006). Herpes simplex virus is found in the labyrinth, vestibular ganglia and vestibular nuclei even of those who have not had AVN so that herpes simplex virus reactivation could also cause vestibular neuritis (Arbusow et al., 2001). Could not ischaemia also cause an acute uVD? Yes it can, but all proven cases so far have also had loss of cochlear function (Lee et al., 2004). Does the asymmetry of lateral SCC function on rotational testing in patients with labyrinthitis (acute simultaneous loss of cochlear as well as of vestibular function) but not in patients with AVN reflect otolith involvement in labyrinthitis (Maire and Van Melle, 2004)? Here however the main question of interest to the clinician is how to tell, in a patient who has largely recovered from the acute uVD syndrome caused by AVN, how much of the recovery has been due to central vestibular compensation of a fixed peripheral deficit as would occur after surgical uVD and how much has been due to peripheral vestibular recovery? The patient of course does not care about this question; she is just happy that her balance has recovered.

3.1. Resolution of the uVD syndrome

During the acute phase of vestibular neuritis – either superior or superior plus inferior, most patients will prefer to rest, usually in bed, but within 48 hours most will be able to walk about and within about 2 weeks most can be back to normal activities. After about 3 months most will be as well as they are ever going to be, which is subjectively back to normal. At 3 months most patients will show only minor abnormalities of static vestibular function such as 1–2 deg/s spontaneous nystagmus in darkness only, often accentuated by head-shaking or by vibration of the mastoid or by both and a slight ipsilesional deviation of the SVH or SVV (Min et al., 2007; Kim et al., 2008) and of rotation toward the side of the lesion in the stepping test (Choi et al., 2007; Park et al., 2008). However most will still show major deficits of dynamic vestibular function, such as impaired VOR on impulsive or caloric testing, impaired VEMP (Murofushi et al., 2006) and increased body sway on standing tasks (Baloh et al., 1998) especially in the roll-plane (Mbongo et al., 2005; 2007) and especially during walking rather than during standing (Allum and Adkin, 2003). Such a pattern of deficits, minor static and major dynamic, is taken to indicate that while peripheral vestibular function has not recovered much or at all, vestibular nucleus resting activity on the affected side is now only a little lower than on the normal side – courtesy of central vestibular compensation. What is known is that after vestibular neurectomy (Reid et al., 1996) or maybe after intra-tympanic gentamicin 15–20% of patients do experience chronic vestibular insufficiency. It is also known that after AVN there is no correlation between the severity of dynamic VOR deficit on the head-impulse test and the likelihood or severity of chronic vestibular insufficiency (Palla et al., 2008). What is not known is what proportion of patients with little or no recovery of peripheral vestibular function after AVN experience chronic vestibular insufficiency, and when matched for the degree of permanent peripheral vestibular deficit are patients who have had AVN better off than those who have had surgical uVD?

3.2. Recovery of peripheral vestibular function

Peripheral vestibular function, as measured by VEMP (Ochi et al., 2003) or by caloric testing of lateral SCC function, can recover, sometimes fully, after AVN and this recovery is aided by early use of corticosteroids but not by use of an antiviral agent such as acyclovir (Strupp et al., 2004). Serial impulsive testing of lateral SCC shows that the impairment of the ipsilesional horizontal VOR in the acute phase of AVN can improve with time (Fig. 3). However some of the improvement

in ipsilesional VOR gain as well as the preservation of contralesional VOR gain might be due to central compensation rather than to peripheral recovery (Palla and Straumann, 2004). It is now possible to measure and monitor with a fast head-mounted video camera the yaw VOR in response to impulsive testing (Weber et al., 2009). If recovery of peripheral vestibular function does occur the question will arise, can AVN occur again? The answer is yes, rarely (Huppert et al., 2006), and not only on the same but also on the opposite side, as *bilateral sequential vestibular neuritis* (Schuknecht and Witt, 1985), resulting in severe chronic vestibular insufficiency due to bilateral isolated vestibular loss. If peripheral vestibular function recovers it is also possible that the patient did not really have AVN but had the first attack of Meniere's disease. The hearing loss might have been too trivial to notice, might have also recovered by time it was tested, or might not yet have begun. While electrocochleography might be helpful in such cases, time is the only way to tell (Ferraro and Durrant, 2006).

Acute vestibular neuritis is almost but not always a one-off event. Rarely after recovery of peripheral vestibular function it will recur in the same labyrinth in which case it needs, even in the absence of an overt hearing loss, to be distinguished from Meniere's disease. If vestibular function does not recover after the first AVN and the second AVN occurs in the other ear which does not recover either (Schuknecht and Witt, 1985), the patient will develop a permanent, severe chronic vestibular insufficiency.

3.3. Vestibular insufficiency after acute vestibular neuritis and the role of vestibular rehabilitation

While there is no correlation between the extent of the persisting peripheral vestibular deficit as measured with the horizontal head-impulse test (Palla et al., 2008) or with posturography (Mbongo et al., 2007) and the extent of disability due to chronic vestibular insufficiency experienced by patients after AVN, when peripheral vestibular function does not fully recover after AVN vestibular rehabilitation can, as after surgical uVD, help improve postural stability as measured by a reduced Dizziness Handicap Inventory score and a reduced sway path on posturography (Cohen, 2006). Long-term disability from AVN seems to be primarily due to the vestibular deficit itself, rather than caused by accompanying psychological factors (Mandal à et al. 2009). The key to the success of the rehabilitation appears to be its intensity – starting early and continuing for about a week during the hospital admission for the AVN and continuing for at least a month afterwards (Strupp et al., 1998). The rehabilitation program in hospital should include up to 6 sessions daily of modified Cawthorne-Cooksey exercises then a home exercise program guided by video and written instructions.

Acknowledgments

This work was supported by the National Health and Medical Research Council, by the Australian Research Council, by the Royal Prince Alfred Hospital Neurology Department Trustees and by the Garnett Passe and Rodney Williams Memorial Foundation. Dr Ann Burgess helped prepare the manuscript.

References

Allum, J.H. & Adkin, A.L. (2003). Improvements in trunk sway observed for stance and gait tasks during recovery from an acute unilateral peripheral vestibular deficit. *Audiol Neurootol, 8*(5), 286-302.

Arbusow, V., Theil, D., Strupp, M., Mascolo, A. & Brandt, T. (2001). HSV-1 not only in human vestibular ganglia but also in the vestibular labyrinth. *Audiol Neurootol, 6*(5), 259-262.

Aw, S.T., Fetter, M., Cremer, P.D., Karlberg, M. & Halmagyi, G.M. (2001). Individual semicircular canal function in superior and inferior vestibular neuritis. *Neurology, 57*(5), 768-774.

Baloh, R.W., Ishyama, A., Wackym, P.A. & Honrubia, V. (1996). Vestibular neuritis: clinical-pathologic correlation. *Otolaryngol Head Neck Surg, 114*(4), 586-592.

Baloh, R.W., Jacobson, K.M., Beykirch, K. & Honrubia, V. (1998). Static and dynamic posturography in patients with vestibular and cerebellar lesions. *Arch Neurol, 55*(5), 649-654.

Baloh, R.W. (2003). Clinical practice. Vestibular neuritis. *N Engl J Med*, 348(11), 1027-1032.

Borel, L., Harlay, F., Magnan, J., Chays, A. & Lacour, M. (2002). Deficits and recovery of head and trunk orientation and stabilization after unilateral vestibular loss. *Brain, 125*(4), 880-894.

Carey, J. (2004). Intratympanic gentamicin for the treatment of Meniere's Disease and other forms of peripheral vertigo. *Otolaryngol Clin North Am, 37*(5), 1075-1090.

Chen, C.W., Young, Y.H. & Wu, C.H. (2000). Vestibular neuritis: three-dimensional videonystagmography and vestibular evoked myogenic potential results. *Acta Otolaryngol, 120*(7), 845-848.

Choi, K.D., Oh, S.Y., Kim, H.J., Koo, J.W., Cho, B.M. & Kim, J.S. (2007). Recovery of vestibular imbalances after vestibular neuritis. *Laryngoscope, 117*(7), 1307-1312.

Cohen, H.S. (2006). Disability and rehabilitation in the dizzy patient. *Curr Opin Neurol, 19*(1), 49-54.

Crane, B.T., Tian, J.R., Ishiyama, A. & Demer, J.L. (2005). Initiation and cancellation of the human heave linear vestibulo-ocular reflex after unilateral vestibular deafferentation. *Exp Brain Res, 161*(4), 519-526.

Cremer, P.D., Halmagyi, G.M., Aw, S.T., Curthoys, I.S., McGarvie, L.A., Todd, M.J., Black, R.A. & Hannigan, I.P. (1998). Semicircular canal plane head-impulses detect absent function of individual semicircular canals. *Brain, 121*(4), 699-716.

Curthoys, IS & Halmagyi, G.M. (1999). Vestibular compensation. In U. Büttner (Ed.), *Vestibular Dysfunction and Its Therapy*. Basel: Karger. *Adv Otorhinolaryngol, 55*, 82-110.

Curthoys, I.S. & Halmagyi, G.M. (2007). Vestibular compensation: clinical changes in vestibular function with time after unilateral vestibular loss. In S. Herdman (Ed.), *Vestibular Rehabilitation, 3rd Ed* (pp. 76-97). Philadelphia: F.A. Davis.

Curthoys, I.S., Dai, M.J. & Halmagyi, G.M. (1991). Human ocular torsional position before and after unilateral vestibular neurectomy. *Exp Brain Res, 85*(1), 218-225.

Dai, M.J., Curthoys, I.S. & Halmagyi, G.M. (1989). Linear acceleration perception in the roll plane before and after unilateral vestibular neurectomy. *Exp Brain Res, 77*(2), 315-328.

de Waele, C., Meguenni, R., Freyss, G., Zamith, F., Bellalimat, N., Vidal, P.P. & Huy, P.T.B. (2002). Intratympanic gentamicin injections for Meniere disease – Vestibular hair cell impairment and regeneration. *Neurology, 59*(9), 1442-1444.

Federica, D.B., Eliana, F., Stefania, B., Gianpiero, G., Dario, A. & Antonio, C. (2009). The use of rubber foam pads and "sensory ratios" to reduce variability in static posturography assessment. *Gait Posture, 29*(1), 158-160.

Ferraro, J.A. & Durrant, J.D. (2006). Electrocochleography in the evaluation of patients with Ménière's disease/endolymphatic hydrops. *J Am Acad Audiol, 17*(1), 45-68.

Flourens, P. (2008). Recherches expérimentales sur les propriétés et les fonctions du système nerveux dans les animaux vértébras, 2nd ed Paris, France Baillière, 1842. (Cited by Mudry, A. *Otol Neurotol, 29*(8), 1216-1217).

Furman, J.M., Balaban, C.D. & Pollack, I.F. (1997). Vestibular compensation in a patient with a cerebellar infarction. *Neurology, 48*(4), 916-920.

Gianoli, G., Goebel, J., Mowry, S. & Poomipannit P. (2005). Anatomic differences in the lateral vestibular nerve channels and their implications in vestibular neuritis. *Otol Neurotol, 26*(3), 489-494.

Goto, F., Kobayashi, H., Saito, A., Hayashi, Y., Higashino, K., Kunihiro, T. & Kanzaki, J. (2003). Compensatory changes in static and dynamic subjective visual vertical in patients following vestibular schwannoma surgery. *Auris Nasus Larynx, 30*(1), 29-33.

Hafström, A., Fransson, P.A., Karlberg, M. & Magnusson, M. (2004). Idiosyncratic compensation of the subjective visual horizontal and vertical in 60 patients after unilateral vestibular deafferentation. *Acta Otolaryngol* (*Stockh*), *124*(2),165-171.

Halmagyi, G.M., Weber, K.P., Aw, S.T., Todd, M.J. & Curthoys, I.S. (2008). Impulsive testing of semicircular canal function. *Prog Brain Res, 171*, 187-194.

Halmagyi, G.M., Gresty, M.A. & Gibson, W.P. (1979). Ocular tilt reaction with peripheral vestibular lesion. *Ann Neurol, 6*(1), 80-83.

Helmchen C., Klinkenstein J., Machner B., Rambold H., Mohr C. & Sander T. (2009). Structural changes in the human brain following vestibular neuritis indicate central vestibular compensation. *Ann N Y Acad Sci, 1164*, 104-115.

Hong S.M., Yeo S.G., Byun J.Y., Park M.S., Park C.H. & Lee J.H. (2009). Subjective visual vertical during eccentric rotation in patients with vestibular neuritis. *Eur Arch Otorhinolaryngol*, in press.

Hickey, S.A., Ford, G.R., Buckley, J.G. & Fitzgerald O'Connor, A.F. (1990). Unterberger stepping test: a useful indicator of peripheral vestibular dysfunction? *J Laryngol Otol, 104*(8), 599-602.

Huppert, D., Strupp, M., Theil, D., Glaser, M. & Brandt, T. (2006). Low recurrence rate of vestibular neuritis: a long-term follow-up. *Neurology, 67*(10), 1870-1871.

Karlberg, M., Aw, S.T., Halmagyi, G.M. & Black, R.A. (2002). Vibration-induced shift of the subjective visual horizontal: a sign of unilateral vestibular deficit. Arch *Otolaryngol Head Neck Surg, 128*(1), 21-27.

Kessler, P., Tomlinson, D., Blakeman, A., Rutka, J., Ranalli, P. & Wong, A. (2007). The high-frequency/acceleration head heave test in detecting otolith diseases. *Otol Neurotol, 28*(7), 896-904.

Kim, H.A., Hong, J.H., Lee, H., Yi, H.A., Lee, S.R., Lee, S.Y., Jang, B.C., Ahn, B.H. & Baloh, R.W. (2008). Otolith dysfunction in vestibular neuritis: recovery pattern and a predictor of symptom recovery. *Neurology, 70*(6), 449-453.

Kuhweide, R., Van de Steene, V., Vlaminck, S. & Casselman JW. (2002). Ramsay Hunt syndrome: pathophysiology of cochleovestibular symptoms. *J Laryngol Otol, 116*(10), 844-848.

Lee, H., Ahn, B.H. & Baloh, R.W. (2004). Sudden deafness with vertigo as a sole manifestation of anterior inferior cerebellar artery infarction. *J Neurol Sci, 222*(1-2), 105-107.

Lee, H., Kim, B.K., Park, H.J., Koo, J.W. & Kim, J.S. (2009). Prodromal dizziness in vestibular neuritis: frequency and clinical implication. *J Neurol Neurosurg Psychiatry, 80*(3), 355-356.

Lopez, C., Lacour, M., Ahmadi, A.E., Magnan, J. & Borel, L. (2007). Changes of visual vertical perception: a long-term sign of unilateral and bilateral vestibular loss. *Neuropsychologia, 45*(9), 2025-2037.

Lopez, C., Lacour, M., Léonard, J., Magnan, J. & Borel, L. (2008). How body position changes visual vertical perception after unilateral vestibular loss. *Neuropsychologia, 46*(9), 2435-2440.

Lu, Y.C. & Young, Y.H. (2003). Vertigo from herpes zoster oticus: superior or inferior vestibular nerve origin? *Laryngoscope, 113*(2), 307-311.

Magnusson, M., Kahlon, B., Karlberg, M., Lindberg, S. & Siesjö, P. (2007). Preoperative vestibular ablation with gentamicin and vestibular 'prehab' enhance postoperative recovery after surgery for pontine angle tumours–first report. *Acta Otolaryngol, 127*(12), 1236-1240.

Maire, R. & Van Melle, G. (2004). Horizontal vestibulo-ocular reflex dynamics in acute vestibular neuritis and viral labyrinthitis: evidence of otolith-canal interaction. *Acta Otolaryngol, 124*(1), 36-40.

Mandalà, M., Nuti, D., Broman, A.T. & Zee, D.S. (2008). Effectiveness of careful bedside examination in assessment, diagnosis, and prognosis of vestibular neuritis. *Arch Otolaryngol Head Neck Surg, 134*(2), 164-169.

Mandalà M., & Nuti D. (2009). Long-term follow-up of vestibular neuritis. *Ann N Y Acad Sci, 1164*, 427-429.

Mbongo, F., Patko, T., Vidal, P.P., Vibert, N., Tran Ba Huy, P. & de Waele C. (2005). Postural control in patients with unilateral vestibular lesions is more impaired in the roll than in the pitch plane: a static and dynamic posturography study. *Audiol Neurootol, 10*(5), 291-302.

Mbongo, F., Qu'hen, C., Vidal, P.P., Tran Ba Huy, P. & de Waele, C. (2009). Role of vestibular input in triggering and modulating postural responses in unilateral and bilateral vestibular loss patients. *Audiol Neurootol, 14*(2), 130-138.

Mbongo, F., Tran Ba Huy, P., Vidal, P.P. & de Waele, C. (2007). Relationship between dynamic balance and self-reported handicap in patients who have unilateral peripheral vestibular loss. *Otol Neurotol, 28*(7), 905-910.

Min, K.K., Ha, J.S., Kim, M.J., Cho, C.H., Cha, H.E. & Lee, J.H. (2007). Clinical use of subjective visual horizontal and vertical in patients of unilateral vestibular neuritis. *Otol Neurotol, 28*(4), 520-525.

Murofushi, T., Iwasaki, S. & Ushio, M. (2006). Recovery of vestibular evoked myogenic potentials after a vertigo attack due to vestibular neuritis. *Acta Otolaryngol, 126*(4), 364-367.

Nadol, J.B. Jr. (1995). Vestibular neuritis. *Otolaryngol Head Neck Surg, 112*(1), 162-172.

Newman-Toker, D.E., Kattah, J.C., Alvernia, J.E. & Wang, D.Z. (2008). Normal head impulse test differentiates acute cerebellar strokes from vestibular neuritis. *Neurology, 70*(24 Pt 2), 2378-2385.

Ochi, K., Ohashi, T. & Watanabe, S. (2003). Vestibular-evoked myogenic potential in patients with unilateral vestibular neuritis: abnormal VEMP and its recovery. *J Laryngol Otol, 117*(2), 104-108.

Ohtani, F., Furuta, Y., Aizawa, H. & Fukuda, S. (2006). Varicella-zoster virus load and cochleovestibular symptoms in Ramsay Hunt syndrome. *Ann Otol Rhinol Laryngol, 115*(3), 233-238.

Ozeki, H., Iwasaki, S., Ushio, M. Takeuchi, N. & Murofushi, T. (2006). The lesion site of vestibular dysfunction in Ramsay Hunt syndrome: a study by click and galvanic VEMP. *J Vestib Res, 16*(4-5), 217-222.

Palla, A., Straumann, D. & Bronstein, A.M. (2008). Vestibular neuritis: Vertigo and the high-acceleration vestibulo-ocular reflex. *J Neurol, 255*(10), 1479-1482.

Palla, A. & Straumann, D. (2004). Recovery of the high-acceleration vestibulo-ocular reflex after vestibular neuritis. *J Assoc Res Otolaryngol, 5*(4), 427-435.

Parietti-Winkler, C., Gauchard, G.C., Simon, C. & Perrin, P.P. (2008). Visual sensorial preference delays balance control compensation after vestibular schwannoma surgery. *J Neurol Neurosurg Psychiatry, 79*(11), 1287-1294.

Park, H., Hong, S.C. & Shin, J. (2008). Clinical significance of vibration-induced nystagmus and head-shaking nystagmus through follow-up examinations in patients with vestibular neuritis. *Otol Neurotol, 29*(3), 375-379.

Park H., Shin J., Jeong Y., Kwak H. & Lee Y. (2009). Lessons from follow-up examinations in patients with vestibular neuritis: how to interpret findings from vestibular function tests at a compensated stage. *Otol Neurotol, 30*(6), 806-811.

Reid, C.B., Eisenberg, R., Halmagyi, G.M. & Fagan, P.A. (1996). The outcome of vestibular nerve section for intractable vertigo: the patient's point of view. *Laryngoscope, 106*(12 Pt 1), 1553-1556.

Riordan-Eva, P., Harcourt, J.P., Faldon, M., Brookes, G.B. & Gresty, M.A. (1997). Skew deviation following vestibular nerve surgery. *Ann Neurol, 41*(1), 94-99.

Safran, A.B., Vibert, D., Issoua, D. & Häusler, R. (1994). Skew deviation after vestibular neuritis. *Am J Ophthalmol, 118*(2), 238-245.

Schuknecht, H.F. & Witt, R.L. (1985). Acute bilateral sequential vestibular neuritis. *Am J Otolaryngol, 6*(4), 255-257.

Strupp, M., Arbusow, V., Maag, K.P., Gall, C. & Brandt, T. (1998). Vestibular exercises improve central vestibulospinal compensation after vestibular neuritis. *Neurology, 51*(3), 838-844.

Strupp, M., Zingler, V.C., Arbusow, V., Niklas, D., Maag, K.P., Dieterich, M., Bense, S., Theil, D., Jahn, K. & Brandt, T. (2004). Methylprednisolone, valacyclovir, or the combination for vestibular neuritis. *N Engl J Med, 351*(4), 354-361.

Tabak, S., Collewijn, H. & Boumans, L.J. (1997). Deviation of the subjective vertical in long-standing unilateral vestibular loss. *Acta Otolaryngol* (*Stockh*), *117*(1), 1-6.

Vibert, D., Häusler, R., Safran, A.B. & Koerner, F. (1995). Ocular tilt reaction associated in sudden idiopathic unilateral peripheral cochleovestibular loss. *J Otorhinol Relat Spec, 57*(6), 310-315.

Vibert, D., Häusler, R., Safran, A.B. & Koerner, F. (1996). Diplopia from skew deviation in unilateral peripheral vestibular lesions. *Acta Otolaryngol, 116*(2), 170-176.

Vibert, D., Häusler, R. & Safran, A.B. (1999). Subjective visual vertical in peripheral unilateral vestibular diseases. J Vestib Res, 9(2), 145-152. Erratum in: *J Vestib Res*, 2000; 10(1), 57-58.

Vibert, D. & Häusler, R. (2000). Long-term evolution of subjective visual vertical after vestibular neurectomy and labyrinthectomy. *Acta Otolaryngol, 120*(5), 620-622.

Wackym, P.A. (1997). Molecular temporal bone pathology: II. Ramsay Hunt syndrome (herpes zoster oticus). *Laryngoscope, 107*(9), 1165-1175.

Weber, K.P., Aw, S.T., Todd, M.J., McGarvie, L.A., Curthoys, I.S. & Halmagyi, G.M. (2008). Head impulse test in unilateral vestibular loss: vestibulo-ocular reflex and catch-up saccades. *Neurology, 70*(6), 454-463.

Weber, K.P., MacDougall, H.G., Halmagyi, G.M. & Curthoys, I.S. (2009). Impulsive testing of semicircular canal function using video-oculography. *Ann NY Acad Sci, 1164*, 486-491.

Whitney, S.L., Poole, J.L. & Cass, S.P. (1998). A review of balance instruments for older adults. *Am J Occup Ther, 52*(8), 666-671.