Guideline for Training Establishment Sorters under the New Swine Slaughter Inspection System

Food Safety and Inspection Service
U.S. Department of Agriculture

September

2019

This guideline is designed to help establishments that choose to operate under the New Swine Slaughter Inspection System (NSIS) train their employees to sort and remove animals affected with diseases or other conditions that would render them unfit for slaughter before FSIS ante-mortem inspection and to identify and remove defects on carcasses and parts before FSIS post-mortem inspection.

USDA-FSIS

Guideline for Training Establishment Sorters under the
New Swine Slaughter Inspection System (NSIS)

Table of Contents

I. PURPOSE 4

II. BACKGROUND 4

A. Does NSIS change how inspection program personnel (IPP) perform ante-mortem inspection? 4

B. Does NSIS change FSIS humane handling verification or requirements? 4

C. Does NSIS change how FSIS performs post-mortem inspection? 5

D. Questions Regarding Topics in this Guideline 5

III. GUIDANCE FOR ESTABLISHMENT EMPLOYEE SORTER TRAINING PROGRAMS 5

A. Training Program Elements 5

IV. COMPONENTS OF AN EFFECTIVE ANTE-MORTEM SORTING PROGRAM 7

A. Pre-Sorting Prior to Arrival 7

B. Sorting on Premises: How to Implement an Effective Ante-Mortem Sorting Program 7

C. Ante-Mortem Conditions Requiring Removal and Identification for Disposal 8

D. Ante-Mortem Conditions Requiring Sorting of Swine with Other Conditions; Holding Market Hogs in the "Subject" Pen; Further Sorting by the Establishment Lead Sorter; and Final Inspection by the FSIS PHV ... 8

E. Summary: Outcomes of Sorting 11

F. Foreign Animal Diseases (FADs) 11

G. Establishment Recordkeeping of Disposed Carcasses Sorted Before Ante-Mortem or Slaughter 12

H. Denaturing Requirements 12

V. COMPONENTS OF AN EFFECTIVE POST-MORTEM SORTING PROGRAM 13

A. Preparation and Proper Presentation of Carcasses and Parts 13

B. Normal Carcass and Parts Photos 13

VI. MAINTAINING IDENTITY OF CARCASSES AND PARTS 21

A. Carcasses and Parts Intended for Food 21

B. Carcasses and Parts Intended for Disposal (Not Food) 21

VII. SORTING FOOD SAFETY CONDITIONS AT SLAUGHTER 21

A. Septicemia 21

B. Toxemia 23

C. Pyemia 24

D. Cysticercosis of Swine (Pork Measles) 25

E. Contamination with Feces, Ingesta, or Milk 26

VIII. OTHER CONDITIONS REQUIRING SORTING 26

A. Abscess 26
B. Arthritis 27
C. Pericarditis 29
D. Pleuritis 30
E. Pneumonia 30
F. Peritonitis 31
G. Gastroenteritis 33
H. Nephritis 34
I. Uremia 37
J. Tuberculosis (TB) 38
K. Parasites Not Transmissible to Humans 39
1. Stephanuriasis (Swine Kidney Worms) 39
2. Ascarids (Roundworms) 40
L. Miscellaneous Skin Conditions; Vesicular Diseases 41
M. Diamond Skin –Skin Form of Swine Erysipelas 42
N. Fractures, Bruises, and Injuries, Septic and Non-Septic 44
O. Melanomas vs. Melanosis 44
P. Icterus (Jaundice) 48
Q. Embryonal Nephroma 48
R. Malignant Lymphoma 49
S. Odors; Undetermined; Sexual Odor of Swine 52
T. Pale Soft Exudative Pork (PSE) 52
U. Over-Scald 52
V. Classical Swine Fever (Hog Cholera) 53
X. Brucellosis in Feral or Other Swine Classes 53
IX. REFERENCES 54
A. FSIS Online Inspection Training Information 54
B. APHIS Online Information on Reportable and Foreign Animal Diseases 54
C. Scientific or Academic Resources 54
X. Congressional Review Act 55

I. PURPOSE

This guideline can be used to assist swine slaughter establishments train their employees (hereafter referred to as sorters) to conduct the live animal and carcass sorting and trimming activities that are required for establishments that voluntarily adopt the New Swine Slaughter Inspection System (NSIS).

II. BACKGROUND

The Food Safety and Inspection Service (FSIS) has established a new voluntary inspection system for establishments that slaughter market hogs called the NSIS. Under the NSIS, establishments assume additional responsibilities for the sorting and removal of abnormal or unhealthy animals before FSIS ante-mortem inspection and adulterated carcasses and parts before FSIS post-mortem inspection. The Agency believes that training sorters in establishments that adopt NSIS is important to ensure that they are able to properly perform their sorting procedures before FSIS inspection. The content of this guideline is based on the same training that FSIS provides to its own inspection program personnel (IPP). The Agency is posting this guideline on the FSIS Web site at:

https://www.fsis.usda.gov/policy/fsis-guidelines

This guideline explains how establishments can meet FSIS requirements regarding sorting activities under the NSIS and represents FSIS's current thinking on this topic. FSIS encourages establishments planning to operate under the NSIS to use this guideline when developing their own training for their sorters.

A. Does NSIS change how inspection program personnel (IPP) perform ante-mortem inspection?

No. FSIS IPP will continue to inspect 100% of all market hogs presented for ante-mortem inspection by the establishment after the establishment has conducted sorting activities. FSIS IPP will continue to verify humane handling of all market hogs on premises. The NSIS will not affect the regulations that prescribe animal disposition procedures. Per FSIS Directive 6100.1, the FSIS Public Health Veterinarian (PHV) continues to make one of the following dispositions for market hogs presented for inspection:

1. Passed for normal slaughter;
2. Passed for slaughter but tagged as a U.S. Suspect animal (9 CFR 309.18 (a)). In addition, swine slaughtered in a dehairing operation must also have a tattoo applied when identified as a U.S. Suspect animal (9 CFR 309.18 (b)); or
3. Condemned and tagged as a U.S. Condemned animal (9 CFR 309.18 (c)).

B. Does NSIS change FSIS humane handling verification or requirements?

No. FSIS IPP will continue to verify the humane handling of all animals on the premises, including market hogs on the establishment's premises that are not presented for inspection. NSIS provides the opportunity for IPP to perform more humane handling verification. For information on humane slaughter, please refer to the FSIS Compliance Guide for a Systematic Approach to the Humane Handling of Livestock available at:

https://www.fsis.usda.gov/guidelines/2013-0022

C. Does NSIS change how FSIS performs post-mortem inspection?

No, as with traditional inspection, FSIS continues to perform 100% carcass-by-carcass inspection on each head, viscera, and carcass. After establishment sorters on the line have identified any conditions for carcass or parts removal or trimming, FSIS inspects each head, viscera, and carcass to ensure that they are fit to bear the mark of inspection and that establishment's sorting decisions meet regulatory requirements. FSIS continues to have the authority to retain carcasses and stop the line under NSIS. FSIS also continues to conduct offline inspection activities such as verifying compliance with sanitation and Hazard Analysis and Critical Control Point (HACCP) regulations, as well as humane handling requirements. It's important to note that NSIS does allow FSIS inspectors to conduct more off-line verification activities.

D. Questions Regarding Topics in this Guideline

FSIS recommends that users who have questions regarding the information covered in this guideline search the publicly posted Questions & Answers (Q&As) in the askFSIS database or submit questions through askFSIS. Documenting these questions helps FSIS improve and refine present and future versions of the guideline and associated issuances.

When submitting a question, use the **Submit a Question** tab, and enter the following information in the fields provided:

Subject Field:	Enter **NSIS Sorting Guideline.**
Question Field:	Enter question with as much detail as possible.
Product Field:	Select **General Inspection Policy** from the drop-down menu.
Category Field:	Select **Slaughter** from the drop-down menu.
Policy Area:	Select **Domestic (U.S.) Only** from the drop-down menu.

When all fields are complete, press **Continue**.

III. GUIDANCE FOR ESTABLISHMENT EMPLOYEE SORTER TRAINING PROGRAMS

A. Training Program Elements

This guideline recommends training elements and inspection standards that the Agency has found effective in training FSIS inspectors to identify live animals, carcasses and parts affected with defects and condemnable conditions. Market hog establishments may use this information to train establishment employees who will conduct sorting activities under the NSIS.

Proper training is important to establishment sorters' ability to make sorting decisions on animals, carcasses, and parts. Under the NSIS, FSIS inspectors will continue to inspect all carcasses and parts and take regulatory control actions, if necessary. If establishment sorters do not make correct sorting decisions, IPP will continue to retain carcasses and parts for veterinary disposition; stop the production line; identify and verify restoration of contaminated carcasses or parts; and issue non-compliance records (NRs). Under the NSIS, the PHV will continue to have the authority to direct the establishment to reduce its line speed to maintain process control and assure that the FSIS online carcass inspectors are able to conduct a carcass-by-carcass inspection.

A single training method or program may not be applicable to all establishments. Individual establishments should design training programs consistent with the operational conditions in their establishment.

FSIS recommends that each establishment develop a standardized training program for its sorters to properly identify unfit live animals and unwholesome carcasses and parts to ensure that such live animals, carcasses, and parts are not used as human food. FSIS recommends that sorter training programs include the components and content listed below:

Classroom training refers to lecture style presentations that provide essential information for sorters that will assist them to:

- Recognize and name common parts of market hog carcasses and organs;
- Recognize and name common conditions affecting market hog carcasses and viscera;
- Differentiate among normal, localized, and generalized conditions affecting market hog carcasses and viscera;
- Determine the appropriate actions to take to ensure removal and disposal of unwholesome and unfit carcasses, parts, or viscera to ensure they cannot be used as human food; and
- Create records documenting establishment sorting.

NOTE: An exam or self-assessment for establishment sorter trainees following classroom and hands-on (i.e. wet lab) training may be helpful to measure and quantify understanding and comprehension of training.

Hands-on (i.e. Wet Lab) Training is an activity that provides trainees with practical application of what they learn during classroom training. Features could include:

- Using real examples of carcasses and parts –both normal and abnormal;
- Performing hands-on practice prior to beginning normal duties online to identify carcass and parts conditions;
- Assuring carcass and parts sorting decisions are correct and
- Recording sorting and removal actions.

On- the- Job Training is practicing what has been learned in the classroom and through wet labs in an establishment to an environment that simulates an establishment including:

- Performing sorting activities at production rates;
- Identifying defects on carcass, parts, and viscera;
- Receiving real time feedback from supervisors; and

- Taking appropriate actions (e.g., trimming contamination and identifying defects for removal or disposal) as determined necessary.

Follow-up Sessions (referred to as correlations) are conducted to reinforce previous learning. Features include:

- Conducting such sessions at a set regular frequency,
- Discussing regularly standardized procedures for identifying and properly disposing of carcasses and parts on a continuous basis at production rates; and
- Describing reasons for making decisions during sorting activities and appropriate actions.

Continuous Monitoring of individual employee performance to maintain skill level.

IV. COMPONENTS OF AN EFFECTIVE ANTE-MORTEM SORTING PROGRAM

A. Pre-Sorting Prior to Arrival:

1. Pre-sorting on the farm:
    a. Establishment purchase specifications
    b. Treatment records
    c. Animal health
    d. Biosecurity procedures

2. On farm certification programs:
    a. Pork Quality Assurance Program (PQAP)
    b. Common Swine Industry Audit
    c. Truckers Quality Assurance Programs

Under the NSIS, FSIS encourages establishments to begin their sorting activities by collecting and utilizing previous slaughter data for each supplier, and producer information including, in part: farm records, feeding programs, herd certification programs, and farm biosecurity programs, to ensure only healthy market hogs are delivered to the establishment. Systematic use of rigorous on farm sorting procedures, purchase specifications, and herd certifications will further ensure that animals with chemical, physical and biological hazards, including chemical hazards from violative residues, are not delivered to the slaughter establishment. On farm programs may be used by the establishment to support, in the establishment's HACCP system, ante-mortem and post-mortem sorting procedures.

B. Sorting on Premises: How to Implement an Effective Ante-Mortem Sorting Program

1. Be familiar with the behavior of normal healthy market hogs.
2. Observe market hogs **in motion**; specifically look for:
    a. Alertness: Healthy market hogs are aware of their surroundings and actively investigate the environment and their pen mates when initially unloaded or placed in pens. During lairage, market hogs will be recumbent and resting for most of the time.
    b. Locomotion: Healthy market hogs bear weight equally on all four legs and walk freely.

c. Body condition: Healthy market hogs are full fleshed, with fat and muscle completely covering the ribs, backbone and hips.
d. Body functions: Healthy market hogs pass clear to pale yellow urine and formed yellow to greenish to brown stools, depending upon their diet. Market hogs may vomit due to motion sickness, so occasional vomiting in an otherwise healthy market hog should not be cause for concern.

3. Observe market hogs **at rest**; specifically look for:
   a. Alertness: Healthy market hogs retain awareness of what is going on around them when resting and often vocalize when disturbed.
   b. Respiration: Healthy market hogs display regular, rhythmic breathing.
   c. Skin color: Healthy market hogs will have a white to pink uniformly colored skin (if not pigmented).

C. Ante-Mortem Conditions Requiring Removal and Identification for Disposal

1. **Dead.**
2. **Moribund:** Animals in the act of dying. Look for inactivity, loss of awareness of surroundings, abnormal skin color (blotchy or blue discolorations), irregular (gasping) respirations, frothy mouth and / or nasal discharge, unable to rise and walk.
3. **Central nervous system (CNS) diseases.** Look for seizures, convulsions, abnormal gait (circling, dizziness, loss of balance), difficulty swallowing, abnormally excited or aggressive behavior, head pressing or head tilt.
4. **Febrile.** Market hogs with an elevated body temperature are febrile. Normal body temperature of a pig is around 101.5° - 102.5° F. Pyrexia is a febrile state when their body temperature is 106.0 F or higher. Look for loss of activity and awareness, reddish or bluish skin discoloration in white hogs, increased respirations, difficulty breathing, reluctance to get up from a recumbent position, and/or lameness.

NOTE: Establishment sorters must notify FSIS if they observe animals exhibiting signs of CNS diseases because these are reportable diseases. Establishment sorters must also notify FSIS if they observe an abnormal change in the amount of dead, moribund, or febrile animals because these could be signs of a reportable or foreign animal disease.

D. Ante-Mortem Conditions Requiring Sorting of Swine with Other Conditions; Holding Market Hogs in the "Subject" Pen; Further Sorting by the Establishment Lead Sorter; and Final Inspection by the FSIS PHV:

1. **Fatigued or non-ambulatory market hogs**. Fatigued market hogs appear normal at first but tire and become recumbent. Some fatigued market hogs suffer from muscle cramps and will vocalize and shake until they lay down. If isolated and allowed to rest, recovered fatigued market hogs are eligible for slaughter pending final sorting and FSIS inspection. If any market hogs become non-ambulatory disabled after ante-mortem inspection, establishments are required to move them to the "Subject" pens for re-inspection by FSIS PHVs.
2. **Overheated market hogs.** Market hogs do not control their body temperatures well during warm weather and may overheat during inclement weather. Look for rapid, panting respirations, reddish skin discoloration, and lack of activity. These animals may be held for recovery and passing for slaughter, pending further sorting and final PHV inspection.

3. **Market hogs of uncertain status at the time of initial sorting.** If establishment sorters are unsure about the health status of a market hog or its eligibility for production into human food, they should place the pigs in a pen that will be subject to further sorting by the establishment's lead sorter (i.e., the establishment's designated offline sorter), and final inspection by the FSIS PHV. Conditions that sorters may question include abnormal body swellings, lameness, skin discolorations, scabs, wounds, coughing, sneezing, and abnormal body discharges (bloody urine, diarrhea, vaginal discharges, vomiting).

Examples of Ante-Mortem Conditions

Arthritis

Signs:
1. Enlargement of one or more joints;
2. Abnormal locomotion;
3. Variable temperature—depending upon stage of disease and ambient temperature. Temperature may range from very high to subnormal; each case will have to be independently assessed by the PHV;
4. Painful or abnormal stance and movement;
5. Reluctance to move or stand;
6. Depression;
7. Poor wasting condition; and/or
8. Infected navel in young animals.

Special Note: Transport injury (i.e., sore feet)—this also can result from market hogs being raised on concrete and must be distinguished from arthritis (See 9 CFR 309.2, 309.4, and 309.9).

Moribund-Dying Condition

Market hogs showing darkening of the abdomen or cyanosis of the belly and ears (see picture to the left); very depressed - typical of market hogs in a moribund or dying condition:

Signs include:
Depression,
Reluctance to move,
Cold dark ears, legs, belly,
Reduced or elevated body temperature,
Inability to rise,
Paddling,
Unaware of surroundings,
Moribund, and
Dehydration.

Acute Erysipelas

Signs:

Fever;
Reluctant to move; non-ambulatory;
Swollen joints;
Sudden death; and/or
Diffuse areas of purple raised, red diamond skin.

Sorters must identify animals with signs of fever and signs of acute erysipelas for disposal. Market hogs with less severe signs suggesting a localized condition can move to the subject pen for closer evaluation and sorting. Eligible market hogs may be presented to the PHV for ante-mortem inspection.

	Abscess Signs: Swellings may be evident in various parts of the animal; Typically, abscesses of any size may be seen near the jowl, ham, hock, shoulder.
	Abscess/Hernia/Prolapse/Injury Depression or lethargy; Variable temperature—from very high to subnormal; External wounds including Scirrhous cord (funiculitis), Umbilical abscess, tail-bite lesions, or infected open wounds; Swollen joints; Subcutaneous abscesses; and/or Poor wasting condition.

E. Summary: Outcomes of Sorting

1. Normal healthy market hogs presented for FSIS ante-mortem inspection.
2. Market hogs identified for removal are humanely euthanized (if necessary), denatured, and disposed of.
3. Plant rejects (healthy animals that may be underweight, overweight, or do not meet other establishment purchase specifications) that are moved to another inspected establishment for slaughter only.
4. Market hogs that are held for further sorting in the "Subject" pen by establishment lead sorter and final inspection by the PHV.

F. Foreign Animal Diseases (FADs)

FSIS has a cooperative agreement with the Animal and Plant Health Inspection Service (APHIS) for conducting FAD surveillance during FSIS inspections. FADs of concern include Foot-and-Mouth Disease (FMD) (see picture on page 42), Hog Cholera, and African Swine Fever. As part of the NSIS, establishments are required to report any animal showing a condition suggestive of a FAD or other reportable conditions to the FSIS PHV (9 CFR 309.19(e)). The FSIS PHV will inspect for and make the final determination about whether the condition should be reported to APHIS. Early detection of FADs can help prevent spread of such diseases. Conditions associated with FADs and other reportable conditions include:

1. Sudden, unexplained death loss in a large number of market hogs upon arrival or that were previously observed as healthy;
2. Sudden, unexplained fever in a large number of market hogs;
3. Sudden, unexplained severe lameness in a large number of market hogs;

4. Vesicles (i.e. intact, ruptured, healing blisters or sores) on the nose and in between the toes;
5. Large numbers of market hogs with diarrhea;
6. Signs of central nervous system disease (e.g. circling, head pressing, head tilt, staggering, tremors); and/or
7. Maggot infestations.

Additional information about FADs and other reportable conditions may be found on the APHIS website at :https://www.aphis.usda.gov/aphis/ourfocus/animalhealth/animal-disease-information or by calling the APHIS Area Veterinarian In Charge: https://www.aphis.usda.gov/vs/nahss/swine/csf/CSF_PM_2007_AppendC_Directory.pdf

G. Establishment Recordkeeping of Disposed Carcasses Sorted Before Ante-Mortem or Slaughter

Under the NSIS, establishments are required to keep:

1. Records documenting the number of animals that were sorted and removed for disposal before ante-mortem inspection or slaughter. Establishments do not need to include the number of healthy animals that were diverted to another official establishment for slaughter. Establishment records must include reasons the animals or carcasses were removed. This information must be provided to FSIS to fulfill FSIS reporting obligations.

2. Records documenting sorting activities and disposal procedures. These records will vary depending upon how the establishment conducts its sorting activities and disposes of animals and carcasses (HACCP, Sanitation Standard Operating Procedures (Sanitation SOPs), or other pre-requisite programs) within its HACCP system.

H. Denaturing Requirements

The NSIS requires establishments to have written procedures documenting that all dead and discarded market hogs are identified (using a tag, tattoo or other unique identification) and disposed of according to 9 CFR part 314 (9 CFR 309.19).

Establishments have the option to render on-site or denature carcasses before disposed carcasses are transported offsite. Establishments can also continue to use denaturing by injection to help identify carcasses rendered on site. If rendered offsite, discarded carcasses are to be denatured with: (1) crude carbolic acid, (2) cresylic disinfectant; (3) a formula consisting of one part FD&C No. 3 green coloring, 40 parts water, 40 parts liquid detergent, and 40 parts oil of citronella; or (4) any other proprietary material approved by the Administrator in specific cases, during hours of operation and before transport from the establishment. When such carcasses are dressed (e.g. skinned), the carcass is to be denatured; carcasses that are dressed are required to be freely slashed before the denaturing agent is applied, except that, in the case of dead animals that have not been dressed, the denaturant may be applied by injection. The denaturant must be deposited in all portions of the carcass to the extent necessary to preclude the carcass from being used for food purposes.

V. COMPONENTS OF AN EFFECTIVE POST-MORTEM SORTING PROGRAM

A. Preparation and Proper Presentation of Carcasses and Parts

Before FSIS inspection, establishment employees can remove surface contamination (e.g., feces, ingesta, or milk) on market hog carcasses in a sanitary manner, unless the carcasses are retained by IPP for PHV inspection. Trimming of carcass defects or blemishes (e.g., hair and minor bruises) is allowed for any defects not affecting disposition of the carcass or part.

To operate at maximum efficiency, FSIS recommends that establishment employees present heads, viscera, and carcasses in a consistent and uniform manner to allow sorters to methodically examine and sort heads, viscera, or carcasses prior to FSIS inspection.

NOTE: Sorting of hearts and kidneys requires the opening or removal of the pericardial membrane and kidney capsule. Kidneys may be presented with the viscera or in the carcass.

B. Normal Carcass and Parts Photos

Establishment personnel should be familiar with normal market hog carcasses and parts.

	Normal Head 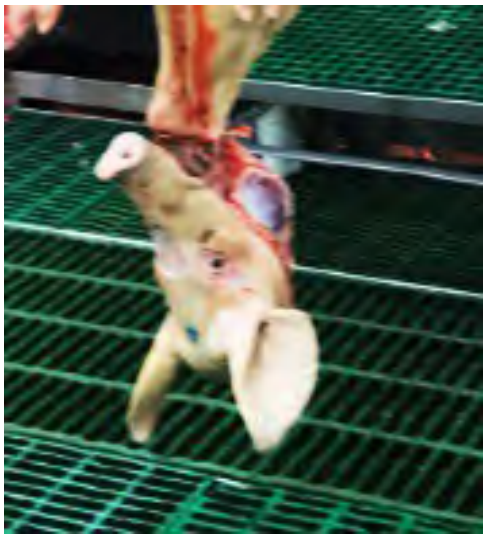

	Normal lungs, aorta, and lymph nodes.
	Healthy hearts; slashed and washed.
	Healthy liver, gall bladder, stomach; spleen and intestines.

	Healthy viscera.
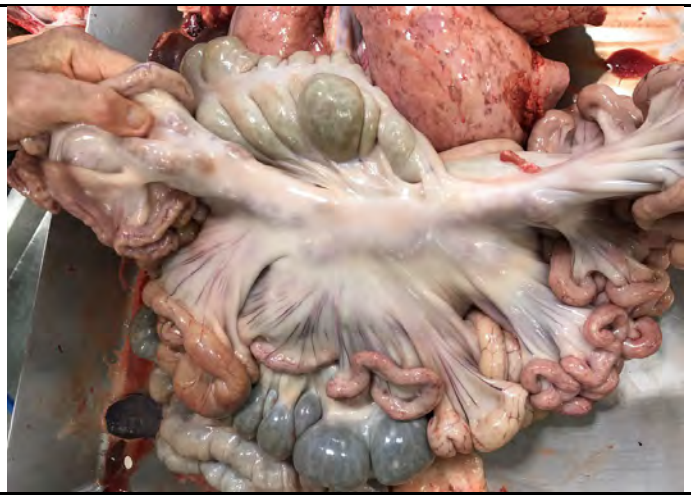	Healthy mesenteric lymph node chain draining the intestines.

	Carcass tracking system.
	Carcass tracking system: Carcass Number; Time; and/or Tattoo.

7. SWINE VISCERA

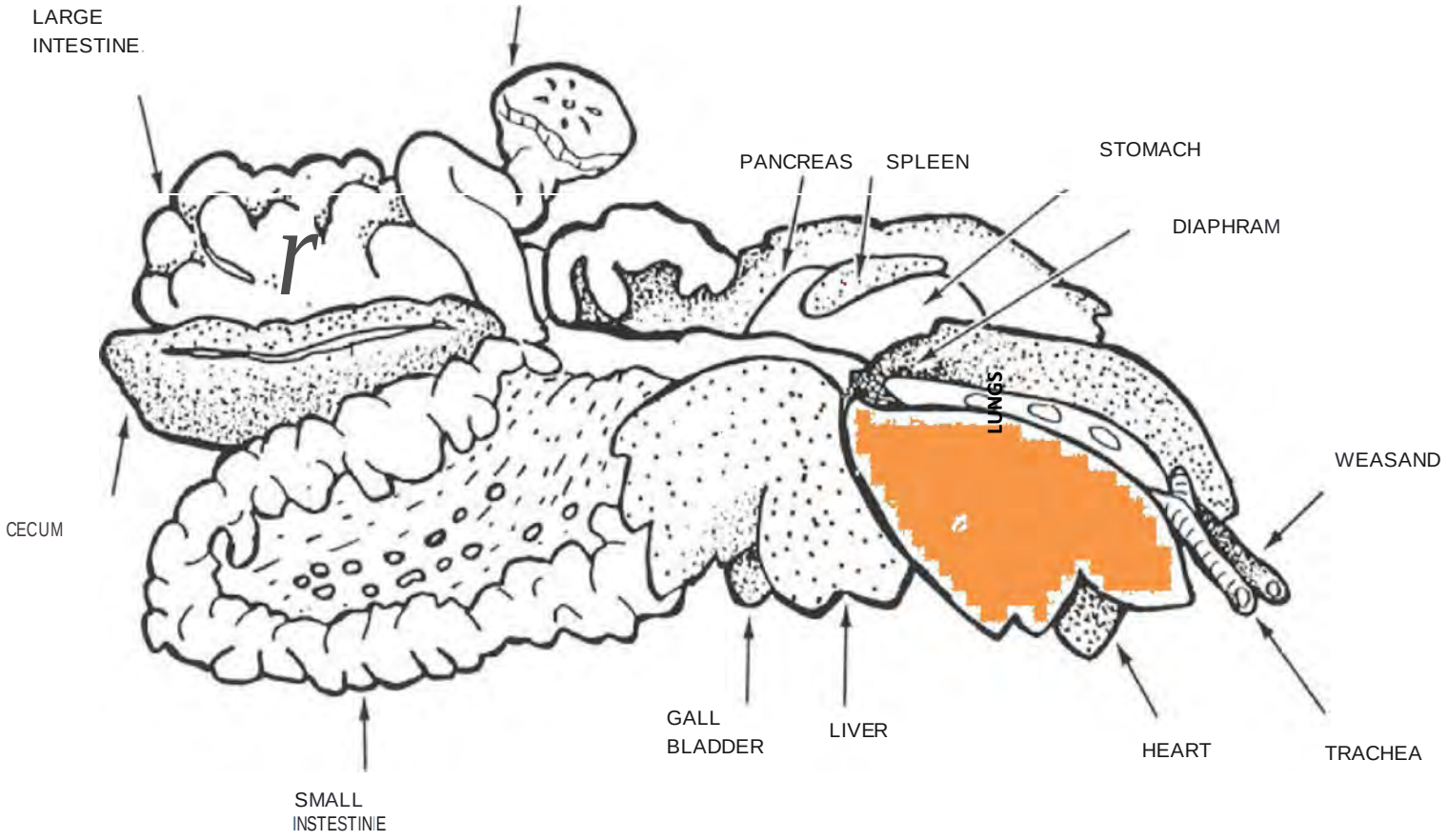

6. SWINE CARCASS . INSIDE

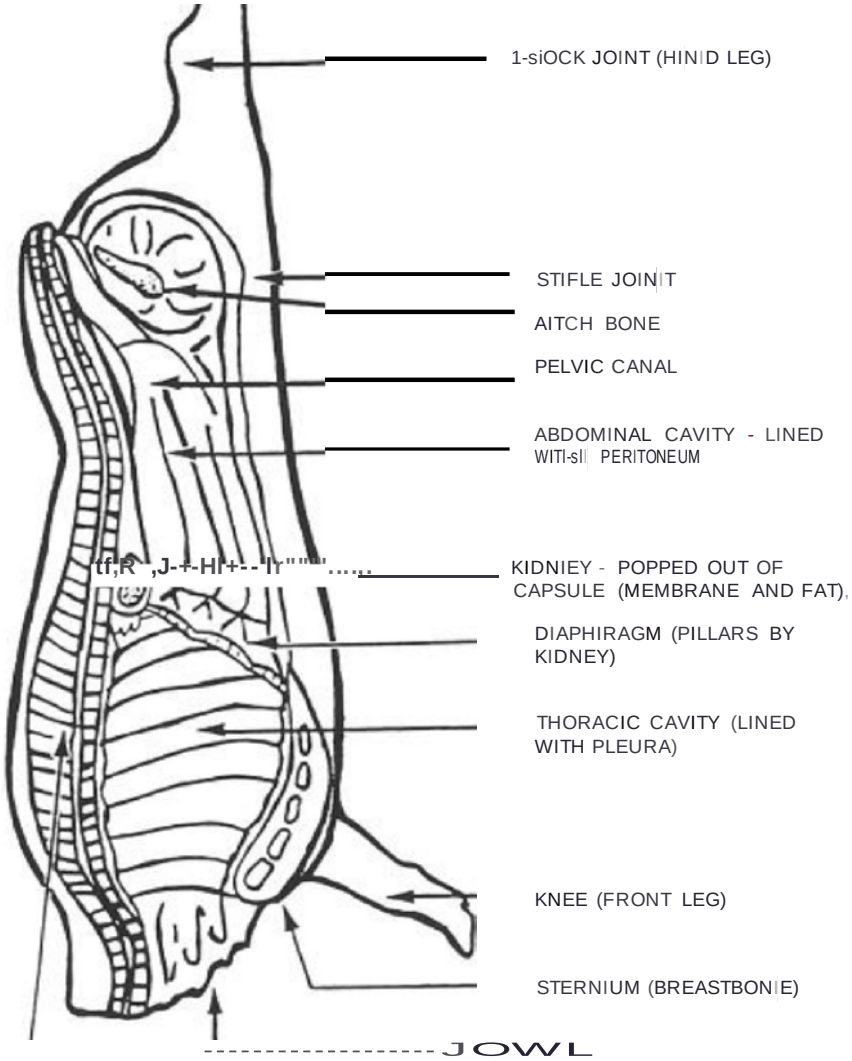

Normal Healthy Market Hog Carcass

(Left) Pre-evisceration carcass with head attached.

(Right) Post evisceration carcass after removal of head and splitting of the carcass and kidneys exposed.

	Healthy market hog carcass showing pelvic canal, lower abdominal wall, leaf lard, and iliac lymph nodes.
	Healthy kidneys in split carcass with capsule removed.
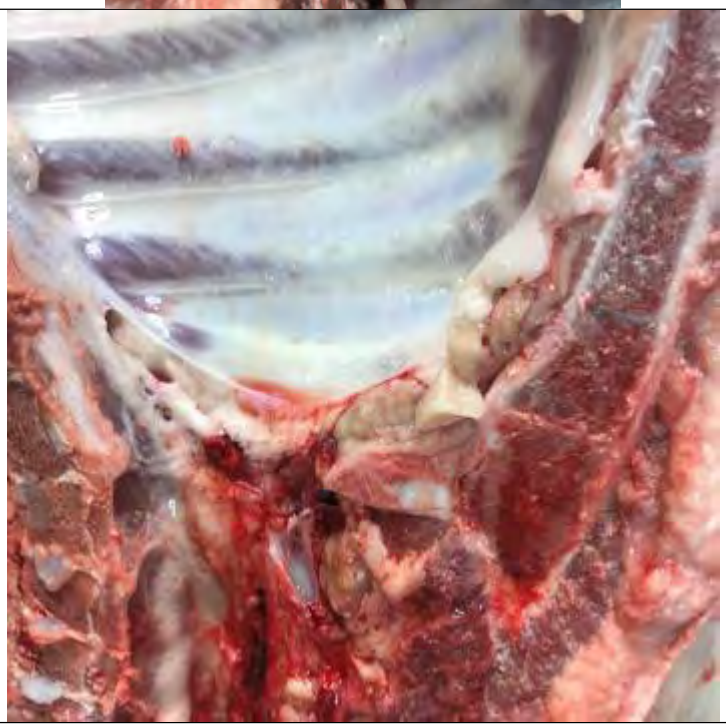	Thoracic inlet of healthy market hog split carcass showing ribs, vertebrae, sternum, and lymph nodes.

VI. MAINTAINING IDENTITY OF CARCASSES AND PARTS

A. Carcasses and Parts Intended for Food

The establishment must maintain identity of the carcass and associated head and viscera until the carcass, head, and viscera receive final inspection by FSIS (9 CFR 310.2). The establishment must also continue to demonstrate that they are able to retrieve the associated head and viscera of any carcass up until the point of final carcass inspection, should the carcass be retained by IPP for PHV disposition (9 CFR 310.3).

B. Carcasses and Parts Intended for Disposal (Not Food)

Before FSIS post-mortem inspection, establishment sorters are required to identify carcasses and parts intended for disposal (9 CFR 310.26). Once carcasses or parts identified for disposal have been inspected by FSIS, the establishment is required to initiate steps to denature them as inedible (unless designated as naturally inedible (e.g., hides with hair, claws, etc.) or render them (see 9 CFR parts 325 and 314).

Collection of inedible parts in suitably marked containers for animal food must comply with denaturing or other permitted identification procedures under 9 CFR parts 325 and 416.

VII. SORTING FOOD SAFETY CONDITIONS AT SLAUGHTER

Establishment sorters must identify, sort, and mark for disposal market hog carcasses and all associated parts with the following food safety conditions (9 CFR 310.26):

1. Septicemia,
2. Toxemia,
3. Pyemia,
4. Cysticercosis,
5. Feces,
6. Ingesta, and
7. Milk Contamination.

A. Septicemia

Septicemia is a food safety condition caused by the presence of pathogenic microorganisms spread through the entire carcass by way of blood or lymphatics (see 9 CFR 311.16). Not all signs listed below will be present in every animal with septicemia.

Post-Mortem Signs:

1. Dark and blood filled (i.e., congestion) organs or organs with infected wounds or dark bruises;
2. Pinpoint to blotchy hemorrhages (most noticeable on kidneys, heart, lungs, spleen, and other internal organ membrane (i.e., serous) surfaces, typically 0.125 to 1.0” or greater in dimension).

3. Generalized lymphadenitis (multiple, congested, inflamed, or enlarged lymph nodes): lymph nodes tend to be less inflamed but more enlarged 1-2 weeks after infection develops. Multiple lymph nodes are enlarged and cut surface of lymph nodes may be reddened or pale with a rough surface;
4. Pale degeneration of tissues or organs; cis thin, pale (anemic); organs are pale in color;
5. Blood fails to clot;
6. Yellow to bloody fluid in abdominal and/or thoracic cavities;
7. Injection sites (recent);
8. Edema or other evidence of acute generalized inflammation; and/or
9. Hemorrhages under the skin, organs, and body surfaces.

Disposal: Sorters must identify carcasses showing signs of septicemia for disposal under FSIS inspection.

Special Notes:

(1) Generalized, acute lymphadenitis (hemorrhage and early enlargement of lymph nodes) alone is enough for discarding a carcass for septicemia.
(2) A carcass manifesting any degree or form of septicemia is never passed by FSIS.
(3) Petechial ((i.e., pinpoint, less than 1 mm in size) hemorrhages on a normal kidney alone in a healthy carcass are not conclusive evidence of septicemia. Carcasses with true septicemia will show signs in multiple areas or systems.

	Hemorrhagic lymph node associated with septicemia; generalized lymphadenopathy may be hemorrhagic or enlarged or both.

	Carcass showing signs of septicemia involving multiple organs; note hemorrhages and swelling of membranes covering heart, and organs themselves.
	Swollen enlarged kidney with petechial and larger ecchymotic **(i.e. patches 5-15 mm in size)** hemorrhages and scars compatible with a septicemia.

B. Toxemia

Related to septicemia, toxemia (i.e., toxins *in the blood*) is a food safety condition caused by the circulation of toxins produced by pathogenic microorganisms or resulting from the death of microorganisms or tissues by way of the blood or lymphatics (see 9 CFR 311.16 and 311.17). Not all signs listed below will be present in every animal with toxemia.

Post-Mortem Signs:

1. Petechial or ecchymotic hemorrhages. These hemorrhages are most noticeable in kidneys, epicardium, lungs, and serous surfaces;
2. Generalized, acute lymphadenitis;
3. Pale enlarged organs;
4. Large or shrunken spleen;
5. Pale degeneration of tissues or organs;
6. Pigmentation of fat;

7. Slight icterus and/or anemia;
8. Presence of areas of tissue necrosis, red-brown to yellow color to tissues and organs and fat; and/or
9. Changes associated with decomposing tissue (e.g., splenic torsion, liver or lung necrosis, or dead autolyzing fetus.)

Disposal: Sorters must identify carcasses showing signs of toxemia for disposal under FSIS inspection.

Special Notes: Signs of toxemia can appear in varying degrees in carcasses with septicemia. Septicemia, toxemia, or both may simultaneously occur in cases of diseases like septic mastitis, metritis, or arthritis.

C. Pyemia

Pyemia (i.e., pus forming bacteria in the blood) is a food safety condition. Pus forming bacteria from wounds or injuries enter the bloodstream and form abscesses in the lungs, joints, or throughout the body (see 9 CFR 311.16 and 311.17).

Post-Mortem Signs:

1. Infected wound;
2. Swollen joint or joints;
3. Multiple abscesses in lungs with changes in visceral organs;
4. Hemorrhages in lungs, and visceral organs; small abscesses (i.e., 1mm in size) in lungs are recent and do not have capsules;
5. Degeneration of tissues or organs with multiple small abscesses in lungs; and/or
6. Multiple enlarged, inflamed, or swollen lymph nodes.

Disposal: Sorters must identify carcasses showing signs of pyemia for disposal under FSIS inspection.

Special Notes:
(1) Neoplasia may appear as a large abscess with a thick capsule seen with old localized abscesses.
(2) Tuberculosis (TB) may appear as a purulent gritty abscess in certain situations.
(3) Although a pyemia may have caused them, multiple, localized, encapsulated abscesses throughout the body should not be confused with an active pyemia.

Micro-abscesses in heart, joint; spleen, and kidney suggesting a pyemia.

D. Cysticercosis of Swine (Pork Measles)

Cysticercosis (pork measles) is a public health concern because it is a parasitic condition transmissible to humans (see 9 CFR 311.24). Cysticercosis cysts are the larval form (i.e., cysts) of the tapeworm *Taenia soleum.* Cysticercosis is very rare in domestic market hogs raised under modern and hygienic animal production methods but could reappear at any time, depending on the supplier. Cysticercosis is a rare but reportable disease (i.e., requires notification to FSIS). Cysticercosis should be considered any time multiple small cysts are observed in large muscle cuts, heart, diaphragm, or weasand.

Post-Mortem Signs:

1. Muscle is edematous or discolored;
2. One to several dozen cysts in muscle of heart, tongue, esophagus (i.e., weasand), or carcass;
3. Grape-like clusters in tissue underneath the tongue or attached to heart; and/or
4. Cysts may occasionally be found in fat and viscera.

Disposal: Sorters must identify carcasses showing signs of cysticercosis for either disposal or further inspection by FSIS PHV (if going to cooking)(see 9 CFR 315.2). FSIS recommends that the lead establishment sorter contact the FSIS PHV for assistance whenever cysts are observed in any organ or muscles.

	Pork Measles (Cysticercosis) - Cysts in Muscle.
	Heart muscle showing live cysts.

E. Contamination with Feces, Ingesta, or Milk

Refer to descriptions in FSIS Directive 6420.2.

VIII. OTHER CONDITIONS REQUIRING SORTING

This section provides guidance relative to the most common abnormal conditions seen in market hogs that are not directly associated with food safety but require sorting, trimming, or disposal depending on the nature, degree, or extent of the condition.

A. Abscess

Abscesses in the lymph nodes must be differentiated from granulomas (e.g. TB) and tumors (e.g. malignant lymphomas)) (see 9 CFR 311.14). Abscesses in the neck or jowl may originate from old injection sites. Abscesses in the spine may originate from previously infected tail-bite wounds. Abscesses in swine soft tissues typically have a thick wall surrounding a yellow creamy pus-filled center. Pus can be pinkish to white in color, depending on the agent. Abscesses may be found anywhere on the carcass, joint, bone, or visceral organ. Large abscesses in the lung are often the result of the body walling off a lung lobe destroyed by

pneumonia. Multiple localized abscesses that are well encapsulated within the main limb joints (or ends of long bones) are not indicative of pyemia, unless there is the simultaneous appearance of small abscesses and systemic changes in organs (e.g. lungs, spleen, kidneys and liver) due to an active spread of pyogenic microorganisms in the blood.

Post-mortem signs:
1. Abscesses in various parts of the carcass or organs;
2. Abscess capsules may be thin (active; recent) or thick (more chronic). Pus may have any texture and color is mostly yellow, rarely red-brown, greenish-white to white in color;
3. Enlarged lymph nodes identified as localized, acute or chronic, reactive, or edematous lymphadenitis draining the affected area.

Disposal:
Heads:

Sorters are required to identify localized abscesses and associated lymph nodes for removal under FSIS inspection.

Carcass:

Sorters are required to identify localized abscesses for removal under FSIS inspection. Carcasses affected with multiple abscesses affecting the entire carcass are required to be identified for disposal under FSIS inspection.

Special Notes:

Proper disposition of the carcass is improved when findings of abscesses or TB in the head are marked on the carcass and visible to viscera sorters.

Abscesses may be mistaken for other conditions including those listed below.

(1) True abscesses in the head or jowl can be differentiated from other conditions by the presence of visible scar tissue surrounding the abscess or lymph node. An abscess in the head may extend to the jowl. Head sorters should look for contamination from abscesses in neck and identified for disposal under inspection.
(2) Large old tumors may have a necrotic center. Old lymphomas in the head or neck may have a dry yellow center up to 1” in diameter that may appear as an old chronic abscess.
(3) Fungal granulomas and classic TB may appear as a thick or grainy (calcified) abscess of 1-3mm in size. Establishments are encouraged to review any carcass or thoracic granulomas found with the PHV (if not retained by FSIS IPP.).

B. Arthritis

Arthritis is the inflammation of joint tissues that may be traumatic (as evidenced by blood joint fluid) or infectious in origin (see 9 CFR 311.7).

Post-Mortem Signs:

1. Enlarged joint;

2. Reactive or congested regional lymph nodes that drain the affected joint;
3. Degeneration of tissues or organs;
4. Septic wounds or other infections may spread to the joints causing arthritis;
5. Proliferation of the joint lining occurs as the joint heals;
6. Character of exudate in joints:
    a. Increased amount of joint fluid,
    b. Clear blood-tinged joint fluid (injury),
    c. Cloudy red to yellow orange joint fluid (inflammation, infection).

Disposal:

Sorters are required to identify localized arthritis for removal under FSIS inspection. Sorters are required to identify carcasses showing signs of acute, systemic, or generalized arthritis for disposal under FSIS inspection.

Special Notes:

(1) Normal joints have a small amount of clear viscous joint fluid. Increased amount of joint fluid is often associated with injury, such as being confined on concrete or being hauled long distances to market. Often this fluid is clear but may show signs of fresh blood when associated with trauma. Fresh watery bloody joint fluid without evidence of cloudy, fibrinous or purulent exudate would be more indicative of trauma than infection.
(2) As far as carcass disposal is concerned, the type of exudate present in the joints is not the primary consideration, whether the condition is generalized (systemic) is of most public health importance.
(3) Opening arthritic joints may result in contamination of the carcass and if not avoidable, requires removal under FSIS inspection.
(4) The tarsal (hock) joints of market hog carcasses affected with localized arthritis may be removed on the pork cut if the joint is bone solid without evidence of pus or tracks.
(5) Establishments dispose of carcasses because of the condition of the joints, not the number of affected joints. If the arthritis is localized and can be removed by trimming, the joint should be disposed of under FSIS inspection and removed with any draining lymph nodes, and the carcass passed for food.
(6) Establishments should not open arthritic joints on carcasses to avoid inevitable contamination of edible product with joint exudate.

	Inflammation of Hock Bone or Joint- abscess or arthritis likely; pyemia possible.

C. Pericarditis

Pericarditis is an inflammatory condition of the heart sac (pericardium) that is usually due to an infectious agent (see 9 CFR 311.16).

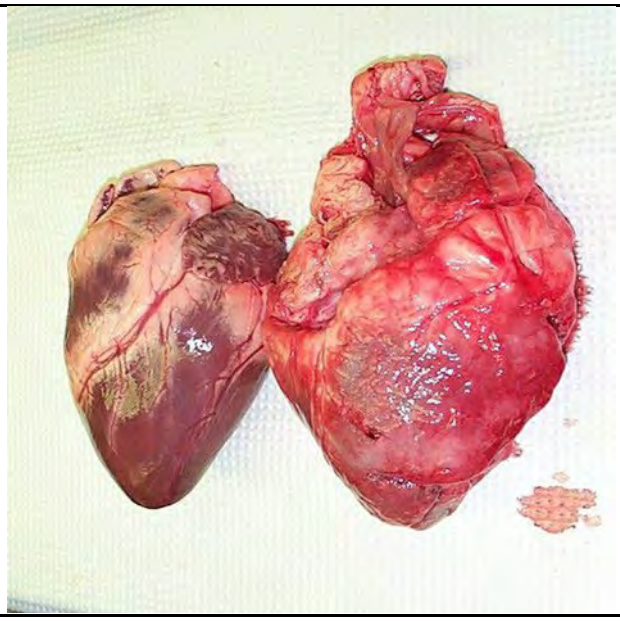	Normal heart next to an enlarged heart with a mild inflamed heart surface with epicarditis or pericarditis (multiple surfaces).

Post-Mortem Signs:

1. Adhesions of pericardium and pleura covering ribs or lungs – normal to inflamed red in color;
2. Sero-fibrinous or fibrinous pericarditis or epicarditis (shaggy heart);

3. Edema of body tissues and fluid accumulations (ascites, pleural effusion); and
4. Putrefactive odor of cut-surface of pericardial, abdominal, or thoracic lesion.

Disposal: Sorters are required to identify localized defects for removal under FSIS inspection. Sorters are required to identify carcasses with reddened (inflamed) or bloody pus on heart sac associated with multiple other carcass changes for disposal under FSIS inspection.

Special Notes: Inflammation of the heart valve(s) is "endocarditis" and may be associated with septicemia, pyemia, or previous pneumonia.

D. Pleuritis

Pleuritis is an inflammatory condition of the pleural (lung and ribs) lining due primarily to infectious agents. It is often associated with pleuritis (see 9 CFR 311.16).

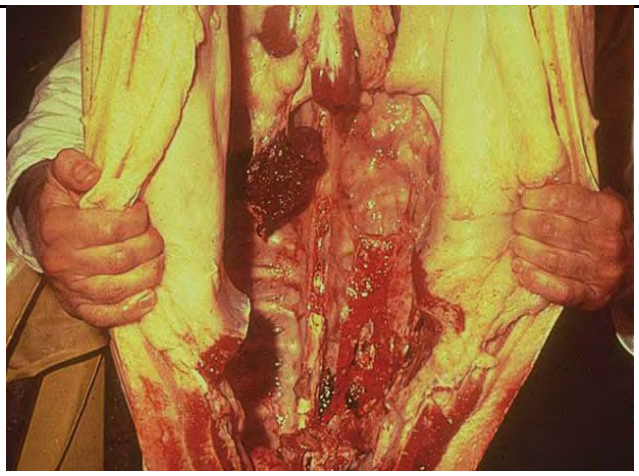	Notice normal and inflamed lungs attached to ribcage.

Post-Mortem Signs:

1. Adhesions between lungs, heart and ribs;
2. Fluid in the chest cavity; and/or
3. Reddened to enlarged lymph nodes within the chest.

Disposal: Sorters are required to identify carcasses with chronic, localized (i.e. healed) adhesions on the rib cage for removal under FSIS inspection. Sorters are required to identify carcasses showing the following signs of acute, systemic, or generalized pleuritis for disposal under FSIS inspection:

1. Extensive, reddened lungs and surface of the ribs; or
2. Reactive or congested (reddened) lymph nodes draining lungs; heart, and ribs and body.

Special Notes: Pleuritis can be associated with pneumonia or be a separate disease.

E. Pneumonia

Pneumonia is an inflammatory condition of the lungs that may be caused by infectious agents, parasites, physical trauma, or foreign material inhalation (see 9 CFR 311.16).

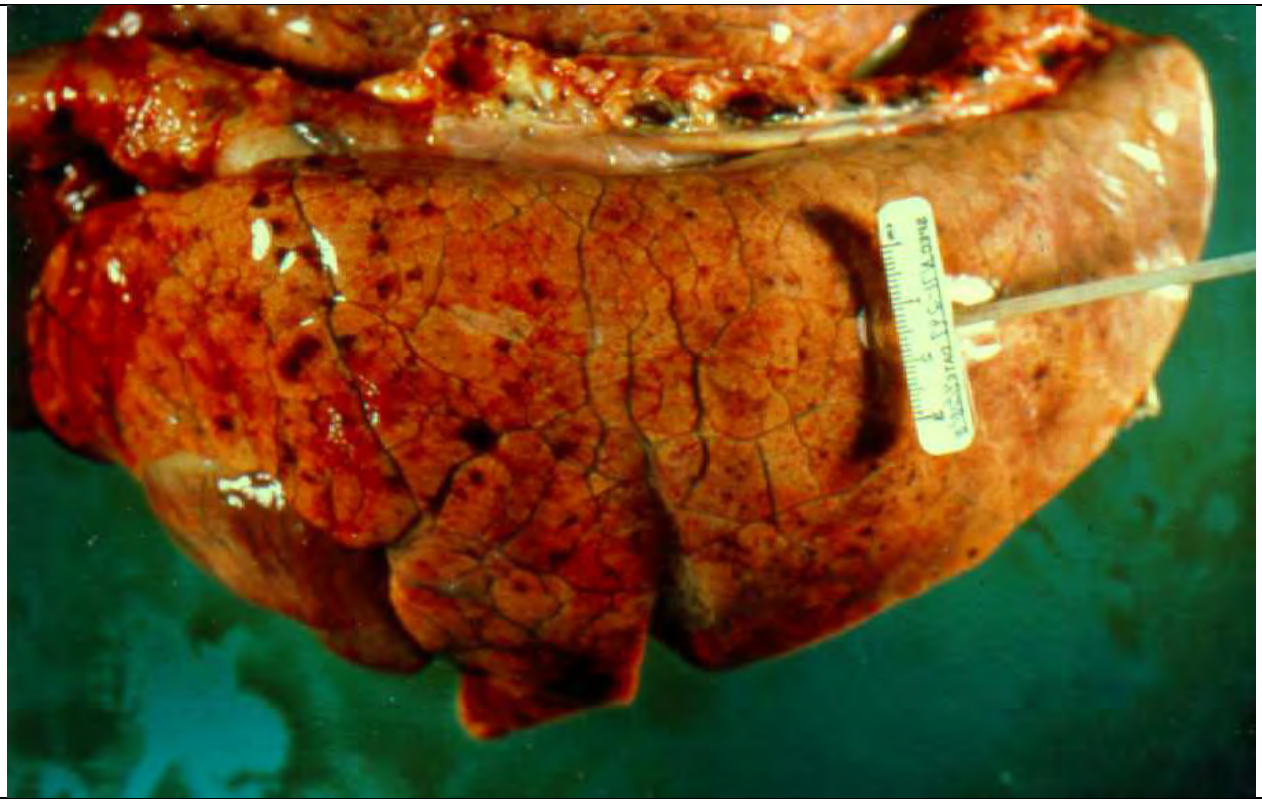

Pulmonary hemorrhage, edema - Check for signs of septicemia.

Post-Mortem Signs:

1. Lungs may be reddened to grayish in color;
2. Lymph nodes draining lungs may be swollen, hemorrhagic, or enlarged;
3. Changes in color, size, or shape of liver, spleen, and kidneys;
4. Hemorrhages (spots) on lungs, kidneys, viscera, or carcass;
5. Consolidation of lung lobe into a thick-walled abscess; and/or
6. Parasites.

Disposal: Sorters are required to identify localized defects for removal under FSIS inspection. Sorters are required to identify carcasses showing the following signs of acute, systemic, or generalized pneumonia for disposal:

1. Heavy, red, inflamed lungs with reactive inflamed lymph nodes;
2. Red, inflamed adhesions on ribs;
3. Changes in color, size, shape of kidneys, spleen, or viscera;
4. Pale or anemic carcass; and/or
5. Marked pulmonary necrosis (abscess) with associated toxemic changes.

F. Peritonitis

Peritonitis is a common condition marked by inflammatory processes affecting the peritoneal lining that is usually caused by infectious agents; however, it can be initiated by intraperitoneal medications, ruptured bladder, or other irritants (see 9 CFR 311.16).

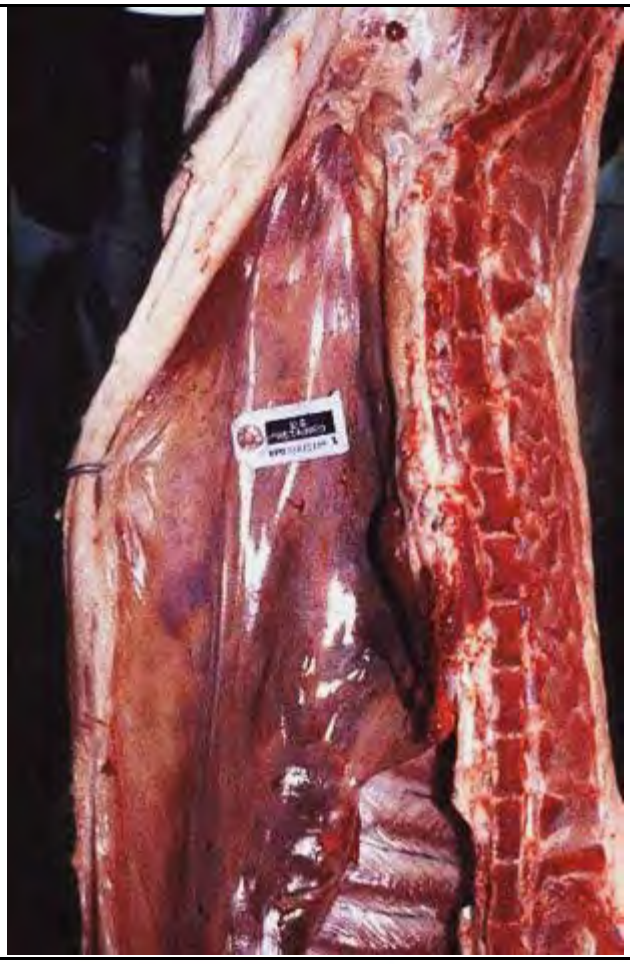	Notice the discoloration of the leaf lard suggesting a peritonitis.
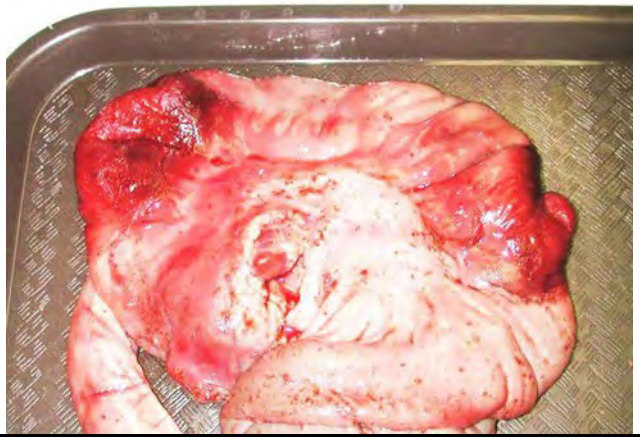	Here is an inflammed and distended loop of intestine with congested mesenteric lymph nodes from a carcass that may have an associated peritonitis.

Post-Mortem Signs:

1. Gastroenteritis - pathologic hemorrhage in stomach, intestines, abdominal organs, or walls;
2. Generalized, acute lymphadenitis;

3. Degeneration of tissues or organs; and
4. Accumulation of fluid in abdominal cavity.

Disposal: Sorters are required to identify localized defects for removal under FSIS inspection. Sorters are required to identify carcasses with the following signs of acute, systemic, or generalized peritonitis for disposal:

1. Acute diffuse peritonitis without generalized changes; or
2. Peritonitis associated with generalized changes.

G. Gastroenteritis

Gastroenteritis is inflammation of stomach or intestine (see 9 CFR 311.16).

Notice the enlarged, darkened, blood filled loops of intestine and enlarged darken spleen.

Post-Mortem Signs:

1. Inflammation of stomach or intestine and draining lymph nodes;
2. Dark, blood-filled intestinal loops;
3. Gangrenous stomach or intestine;

4. Intestinal emphysema (foamy intestines); and/or
5. Thickened “garden-hose” intestine.

Disposal: Sorters are required to identify localized defects for removal under FSIS inspection. Sorters are required to identify carcasses showing the following signs of acute, systemic, or generalized gastroenteritis for disposal under FSIS inspection:

1. Acute, extensive hemorrhagic or gangrenous enteritis; or
2. Any degree of gastroenteritis with generalized (systemic) changes.

Special Notes: FSIS recommends that sorters notify the PHV when multiple carcasses from the same lot show signs of gastroenteritis because this could be a sign of a reportable animal disease.

H. Nephritis

Nephritis is an inflammatory condition of the kidneys (see 9 CFR 311.16). Proper presentation of the kidney for sorting and inspection requires removal of the kidney capsule. There are several types of conditions in kidneys that warrant disposal and closer examination of the carcass. Etiologies may include infectious agents, parasites, or toxins.

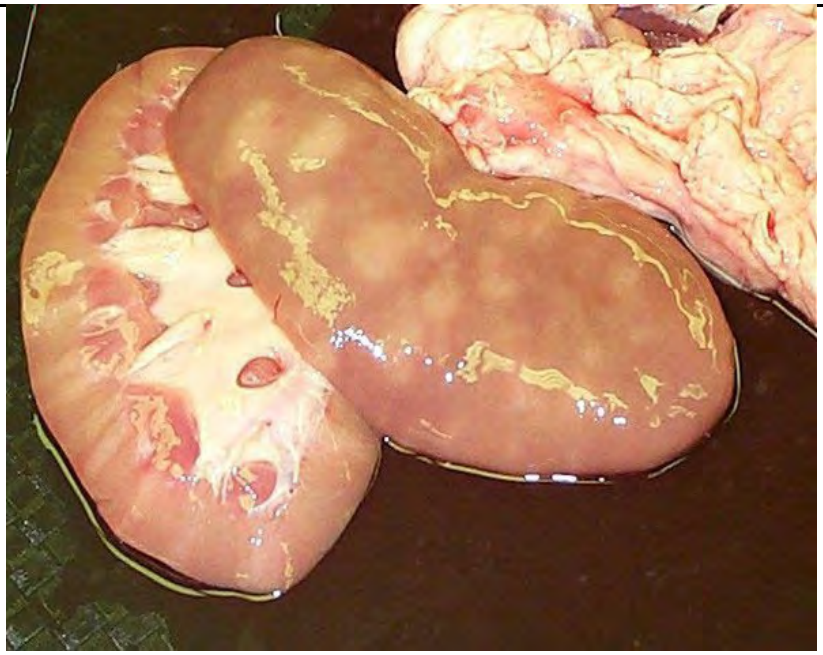

Notice the raised pale plaques on the surface of the swollen edematous kidney. Notice the striations that run from the center to the outer cortex of the kidney.

Kidneys have white spots raised or flattened and show up as white streaks on cut surface. To differentiate from lymphoma, look for evidence of lymphoma in other tissues. Laboratory assistance may be required. Establishments may review kidney dispositions with the PHV if they have questions.

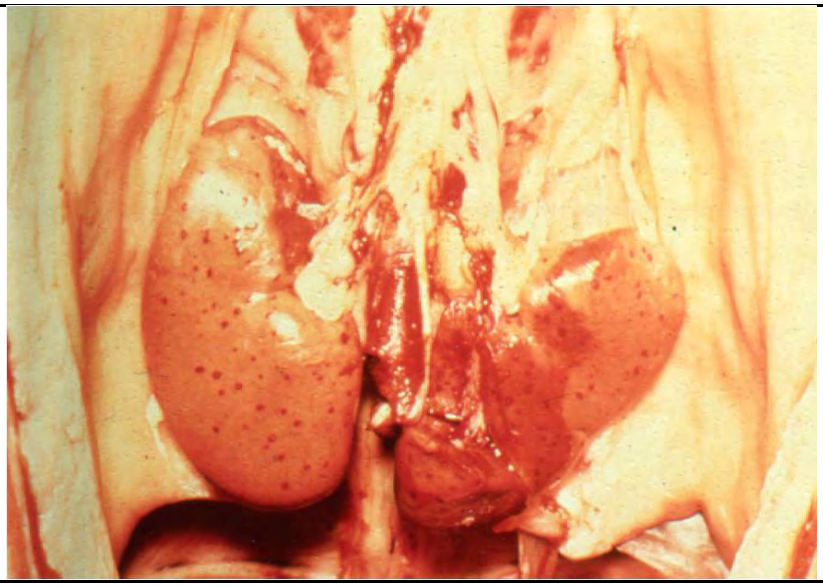

Acute interstitial nephritis – a type of inflammation of the kidneys from bacteria in blood or urinary tract. FSIS recommends that establishment sorters check for evidence of septicemia in the carcass.
Notice the pale enlarged kidneys with hemorrhages on the surface. Look for changes in lymph nodes and other organs in the carcass.

Chronic interstitial nephritis – Look for anemia or uremia in carcass

Carcasses with chronic interstitial nephritis—white, firm, depressed, or pitted or scarred kidneys—may be presented to an FSIS PHV, who will determine if the carcasses can be passed for food, if there are no generalized changes (anemia; uremia), after condemnation of and removal of abnormal tissues.

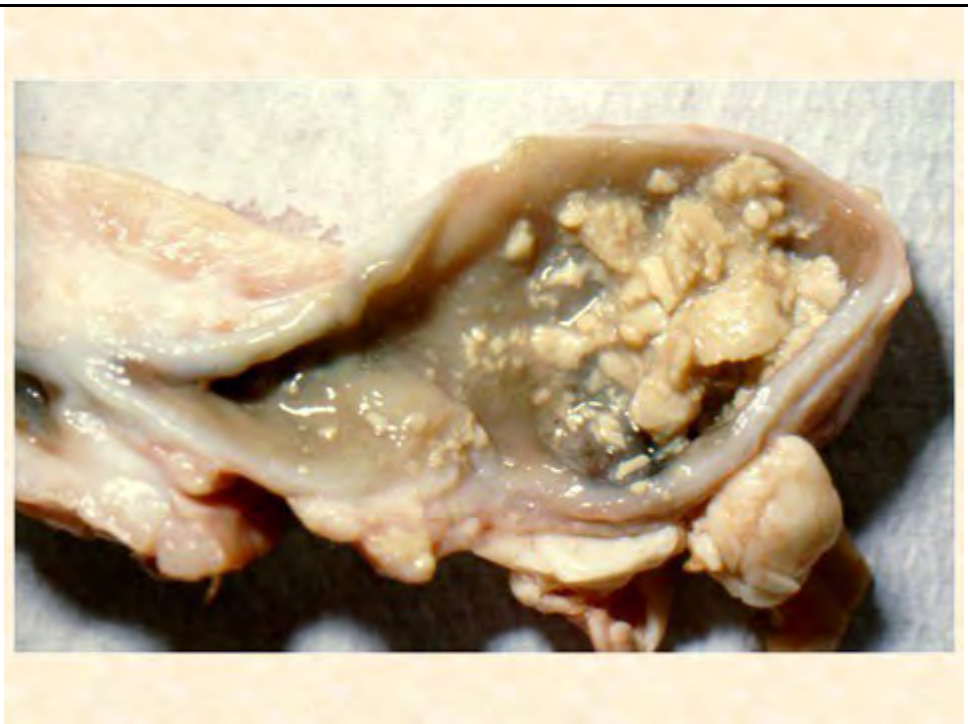	Pyelonephritis – Chronic inflammation of the ureter and kidney. The kidney appears virtually destroyed; FSIS recommends that establishment sorters also check the carcass for odors or anemia.
	Benign Embryonal Nephroma - a congenital kidney tumor. Congenital kidney tumor in swine (i.e. embryonal nephroma). Establishment sorters are required to identify the defect for removal under FSIS inspection.

Carcass with Cystic Kidneys and Normal Kidney Tissue

Hydronephrosis. Cystic Kidneys - one or both kidneys literally appear as a "bag of water". Normal kidney tissue is replaced by a large fluid cyst. There is generally no effect upon the carcass. Affected kidneys are typically removed and disposed of.

Post-Mortem Signs:

1. Inflammation, enlargement, pathological hemorrhage, or change of color in kidney;
2. Multiple abscesses of entire kidney;
3. Pyelonephritis-- accumulation of pus in the ureters and into the kidney;
4. Degeneration of tissues, organs, and lymph nodes;
5. Carcass and tissue edema from protein loss in blood; and/or
6. Uremic odor of carcass, indicating uremia.

Disposal: Sorters are required to identify localized defects for removal under FSIS inspection. Sorters are to identify carcasses with the following signs of acute, systemic, or generalized nephritis for disposal under FSIS inspection:

1. Nephritis (acute or chronic) associated with generalized lesions or disease;
2. Pyelonephritis (dilated ureter and kidney) associated with generalized changes; or
3. Uremia associated with any stage or type of nephritis.

Special Notes: Certain conditions should not be confused with primary nephritis including:
(1) Kidney worms;
(2) Urinary obstructions (kidney or bladder stones);
(3) Infarcts;
(4) Neoplasms (See embryonal nephromas and malignant lymphomas);
(5) Cystic water filled kidneys;
(7) Traumatic injuries; or
(8) Depressed white areas—scars resulting from previous infarcts or nephritis.

I. Uremia

Uremia literally means urine in the blood (see 9 CFR 311.16 and 311.37). Uremia may occur when the kidneys acutely fail to remove nitrogen (ammonia) waste materials in the blood. This can occur after kidneys are temporarily or permanently damaged or after total destruction of the kidneys. This can occur rapidly or over time.

Post-Mortem Signs:

1. Hydrothorax;
2. Ascites or edema in the abdominal cavity;
3. Fluid in all body tissues with lack of inflammatory process;
4. Nephritis or pyelonephritis;
5. Peritonitis;
6. Cystitis;
7. Kidney stones;
8. Hydronephrosis;
9. Carcass edema and reddening;
10. Uremic odor to muscles; and/or
11. Ruptured urinary bladder with peritonitis.

Disposal: Sorters are required to identify localized defects for removal under FSIS inspection. Sorters are required to identify carcasses showing signs of uremia associated with nephritis for disposal under FSIS inspection.

Special Notes:
(1) If there is evidence of a localized urine odor in tissues, establishments are required to trim the affected area.
(2) It is possible that a ruptured bladder can result from faulty dressing procedures. Such contaminated areas are required to be thoroughly trimmed.

J. **Tuberculosis (TB)**

Swine TB is an increasingly rare condition associated with the ingestion of pathogenic acid-fast organisms, almost exclusively identified as *Mycobacterium avium* (see 9 CFR 311.2). *M. avium* is known to be ubiquitous in the environment. The most recent infections have been historically associated with exposure to organic bedding, contaminated feed, and birds. FSIS slaughter data have shown the prevalence of *M. avium* in market hogs has steadily decreased. It is believed this decrease can be attributed to improved biosecurity methods associated with modern production practices and raising market hogs indoors. Establishment management, sorters, and IPP cannot make the same assumptions when market hogs are raised outdoors or under other circumstances (e.g., free range).

Sorters should be aware that TB lesions are most likely to be found in one or more parts of the carcass referred to as the “primary seats”. The primary seats of TB lesions in the market hog carcass are the mandibular (jaw), the mesenteric (intestines), and the bronchial (airway) lymph nodes. TB lesions (e.g. granulomas) in swine have historically been identified through the incision of the mandibular lymph nodes and palpation of mesenteric, portal, and bronchial lymph nodes.

Post-Mortem Signs:

1. Increasingly rare, TB granulomas typically appear in incised lymph nodes as small grains of sand or small abscesses 0.5-2 mm in diameter.
2. When found in the mesenteric lymph nodes, they may appear as small abscesses just below the surface of the mesentery along the mesenteric lymph node chain.

Disposal: Sorters are required to identify heads with TB lesions in mandibular lymph nodes for disposal under FSIS inspection. Viscera sorters must then perform closer examinations of the mesenteric lymph nodes for evidence of TB. If lesions are found in the mesenteric lymph nodes, the sorters should identify the carcass and viscera for closer examination by the lead sorter. Carcasses with generalized TB lesions, as demonstrated with lesions in 3 primary seats or outside of the primary seats (e.g., in muscle, joint, or organ), are to be disposed of under FSIS inspection. If lesions are located in two or more primary seats, the carcass and viscera must be held by sorters for further sorting by the establishment's lead sorter. Sorters also may request that the FSIS PHV inspect a carcass to determine if it may be passed for cooking (i.e., Passed for Cooking only).

A lymph node showing multiple diffuse TB lesions.

K. Parasites Not Transmissible to Humans

1. Stephanuriasis (Swine Kidney Worms)

Stephanuriasis is a rare parasitic condition caused by the presence of *Stephanurus dentatus* in carcass tissues (see 9 CFR 311.25). This condition is most likely seen in swine raised outdoors in the South Atlantic and South-Central parts of the United States. This parasite is not known to be transmissible to humans.

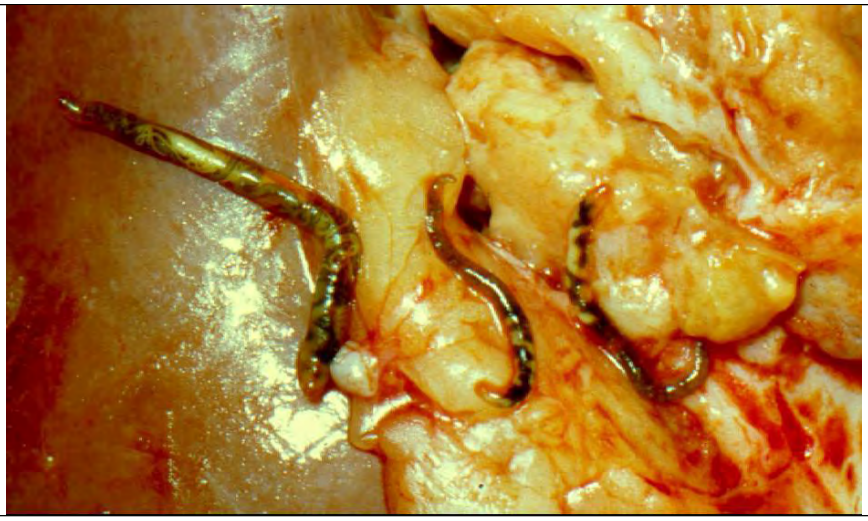	Kidney Worms.

Post-Mortem Signs:

1. Adult kidney worms;
2. Lesions can include:
    a. Pelvic inlet, pelvic and femoral canal,
    b. Abdominal lining,
    c. Muscle-primarily loin and ham muscles,
    d. Organs-primarily kidney, liver, pancreas, spleen, and lungs, and/or
    e. Brownish-lemon color of skin and fat.

Disposal: Sorters are required to identify carcasses for disposal when a parasitic infestation is associated with generalized disease, such as uremia or septicemia. Carcasses with numerous or extensive lesions also must be identified for disposal. Sorters are required to identify moderate infestations for removal under FSIS inspection. Or, sorters may request that the PHV inspect the product to determine if it may be passed for cooking.

Special Notes:
(1) The larvae of *Stephanurus dentatus* migrate to tissues surrounding the kidneys, form cysts and abscesses, and develop to adulthood. The area around the kidneys often appears reddish-brown, and the cysts contain a creamy to reddish-brown colored substance. It is even possible to palpate cord-like masses in the kidney fat, which are tracts made during migration.
(2) In the liver, there are sometimes multiple extensive orange-tan hemorrhagic areas, with the liver parenchyma later taking on a mahogany color. Usually abscessation occurs where the larvae have been trapped. In addition, severe scarring results where abscessation has occurred.

2. Ascarids (Roundworms)

Adult roundworms, *Ascaris suum*, may be observed in the intestines, bile ducts, and gall bladders of market hogs (see 9 CFR 311.25). Larval migration of ascarids causes “milk spots” on pork livers and damage to lungs. "Slight" scarring may be trimmed (spotting the liver).
Disposal: Sorters are required to identify localized defects for removal under FSIS inspection. Sorters may request that the PHV inspect the product to determine if it may be passed for cooking. Sorters are required to identify affected intestines with infestations of roundworms for disposal under FSIS inspection.

L. Miscellaneous Skin Conditions; Vesicular Diseases

Skin conditions are varied and many are very nonspecific, including conditions such as dermatitis, insect bites, erythema, urticaria, and photosensitization (see 9 CFR 311.21). Vesicles (blisters) on the head, snout, mouth, feet may indicate the presence of a reportable or FAD and must be reported to FSIS.

Post-Mortem Signs:

1. Dermatitis;
2. Mange (sarcoptic), scabs with general areas of reddened, itchy or thickened skin;
3. Generalized lymphadenitis;
4. Tissue or organ degeneration; and/or
5. Petechiae or ecchymotic hemorrhages in tissues, organs, or skin.

Disposal: Sorters are required to identify localized defects for removal under FSIS inspection. Sorters are required to identify carcasses showing signs of extensive skin lesions and associated generalized or systemic changes for disposal under FSIS inspection.

Special Notes: The following conditions might be confused with skin disease:
(1) Market hogs over-scalded as a result of being in the scald vat for too long or at too high a temperature;
(2) Erythema and bruising;
(3) Frost-bite;
(4) Hemophilic infection, fungal infections;
(5) Vesicular diseases (e.g., FMD and Seneca Valley Virus (SVV)); and
(6) Swine Circovirus.

Ringworm (fungal dermatitis).

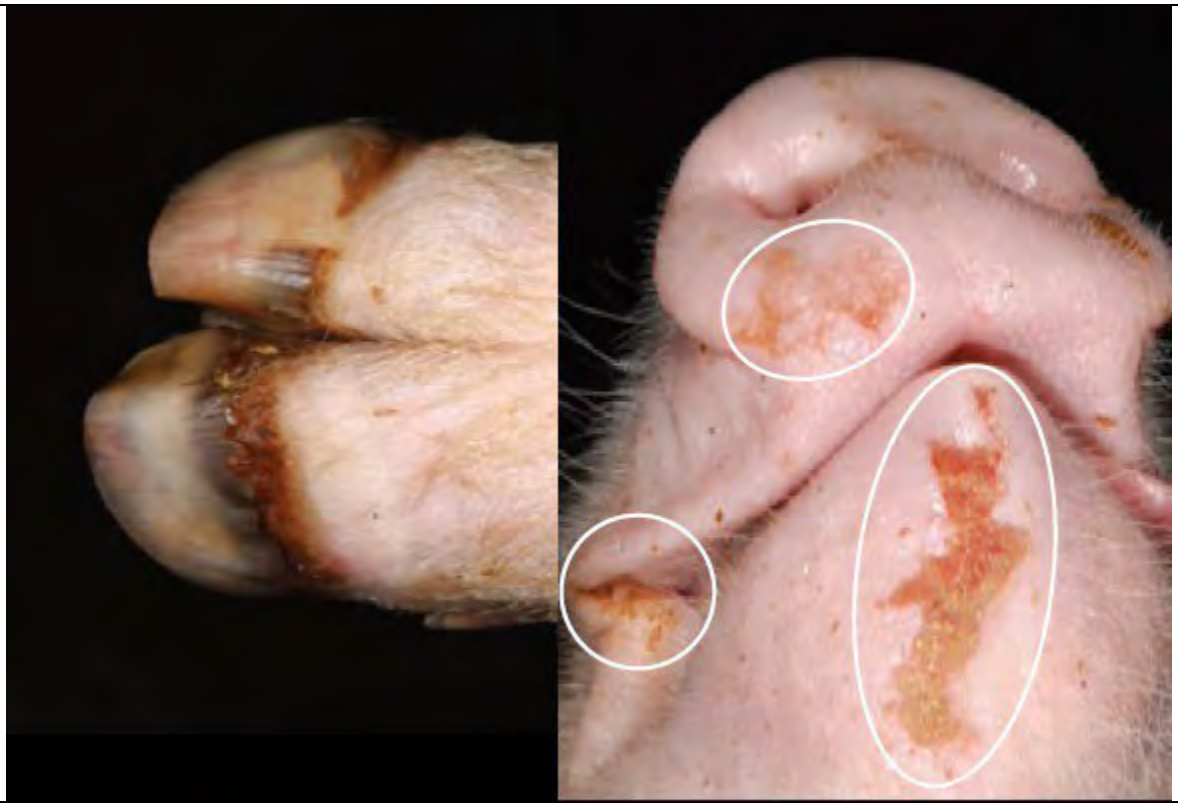

Vesicles (Blisters). FMD is a vesicular disease, vesicles (blisters) are on snout; check tongue, feet, nipples. FMD is a foreign animal disease (FAD).

M. Diamond Skin –Skin Form of Swine Erysipelas

Erysipelas is a disease of market hogs caused by the organism *Erysipelothrix rhusiopathiae*. A chronic form of erysipelas is recognized as “diamond skin” disease (see 9 CFR 311.6).

	Diamond shaped skin lesions.
	Diamond shaped skin lesions on a scalded carcass after hair removal.
	Diamond shaped skin lesions at post-mortem.

Post-Mortem Signs:

1. Diamond shaped lesions, which may vary from acute to chronic;
2. Arthritis;
3. In acute disease, generalized lymphadenitis;
4. Petechial hemorrhage may be noticeable in lungs, kidneys, heart, or on outer surfaces;
5. Degeneration of tissues or organs; and/or
6. Vegetative valvular endocarditis.

Disposal: Sorters are required to identify localized defects for removal under FSIS inspection. Sorters are required to identify carcasses with the following signs of acute, systemic, or generalized diamond skin for disposal under FSIS inspection:

1. Numerous deep dark diamond skin lesions;
2. Petechial hemorrhages in the kidneys;
3. Hemorrhagic and congested lymph nodes; and/or
4. Degeneration of organs.

Special Note: "Diamond skin" is a common name for chronic stages of erysipelas in market hogs with chronic diamond skin lesions. When the lesions are limited to just the skin, as often the case, the sorter may identify skin lesions for removal under FSIS inspection.

N. Fractures, Bruises, and Injuries, Septic and Non-Septic

(See 9 CFR 311.14).

Post-Mortem Signs:

1. Bruises, injuries, or fracture with hemorrhage into the tissues and involving regional or carcass lymph nodes;
2. Septic or toxic changes to organs;
3. Gangrene, strong odor;
4. Injection lesions;
5. Bruise showing hemorrhagic regional lymph nodes;
6. Brownish or dark discoloration of body tissues over whole carcass; or
7. Post-mortem rib fractures.

Disposal:

Sorters are required to identify localized defects for removal under FSIS inspection. Sorters are required to identify carcasses showing the following acute, systemic, or generalized defects for disposal under FSIS inspection:

1. Extensive, generalized bruising, discoloration that cannot be removed by trimming; or
2. Septic bruising or injuries that show associated systemic changes of septicemia or toxemia.

Special Notes: Post-mortem fractures typically have no evidence of hemorrhage near the fracture site. Post-mortem fractures, slight bruises, and healed rib fractures are quality defects that may be removed on the cut floor.

O. Melanomas vs. Melanosis

Melanin is a normal black pigment of the body (see 9 CFR 311.13). Melanosis is excessive melanin deposits or deposits in abnormal locations. Melanosis typically can be found in the lungs, spinal dura, skin, or lymph nodes draining other melanomas or melanin pockets. Such deposits must be removed from product for human food purposes. Melanomas are tumors consisting of melanin producing cells. Malignant tumors show evidence of metastasis in draining lymph nodes. Melanoma is a neoplasia of the naturally occurring melanocytes in the skin. Benign lesions (melanocytomas) and malignant lesions (malignant melanoma) occur, and these must be differentiated from melanosis. Laboratory analysis can be helpful in differentiating benign and malignant melanomas.

Black tumors may be seen in the skin of any species. In market hogs these most often might be seen at the base of the ears, mid-back, tail-head and flanks. Certain breeds of market hogs are particularly prone to having melanosis and melanotic tumors.

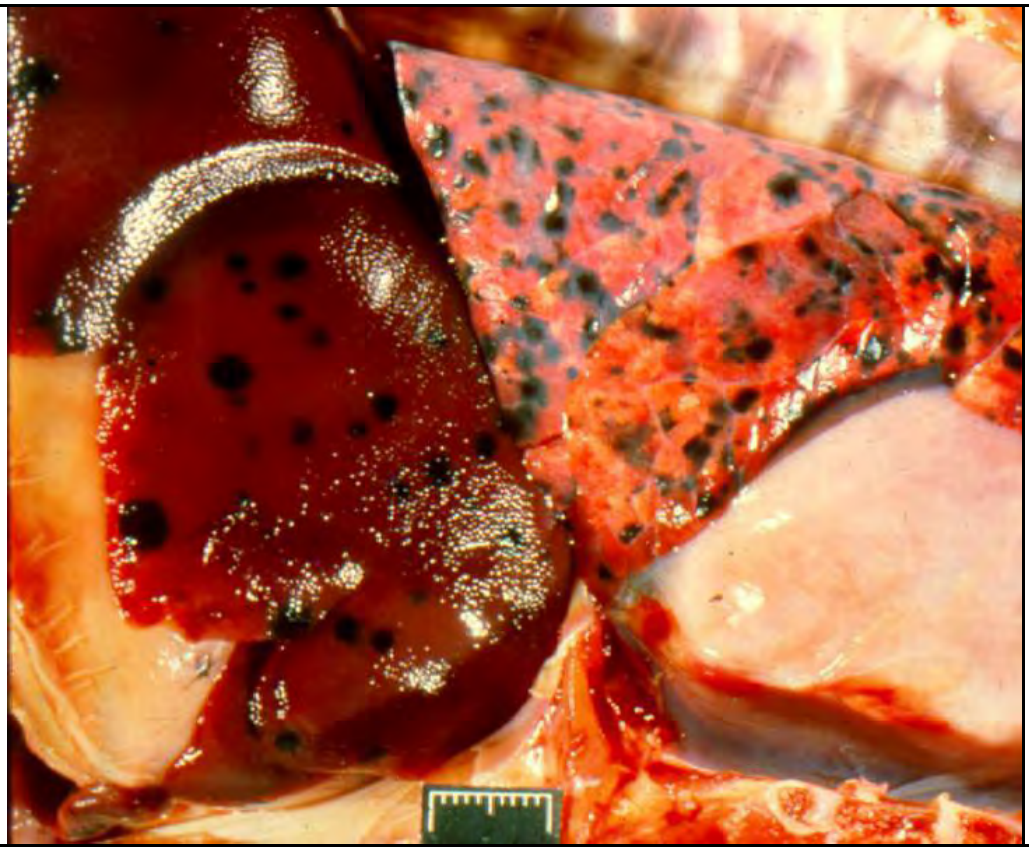

Melanosis (Pigmentation) of lung and liver tissue.

	Carcass with melanotic skin lesions. Sorters should check all draining lymph nodes.
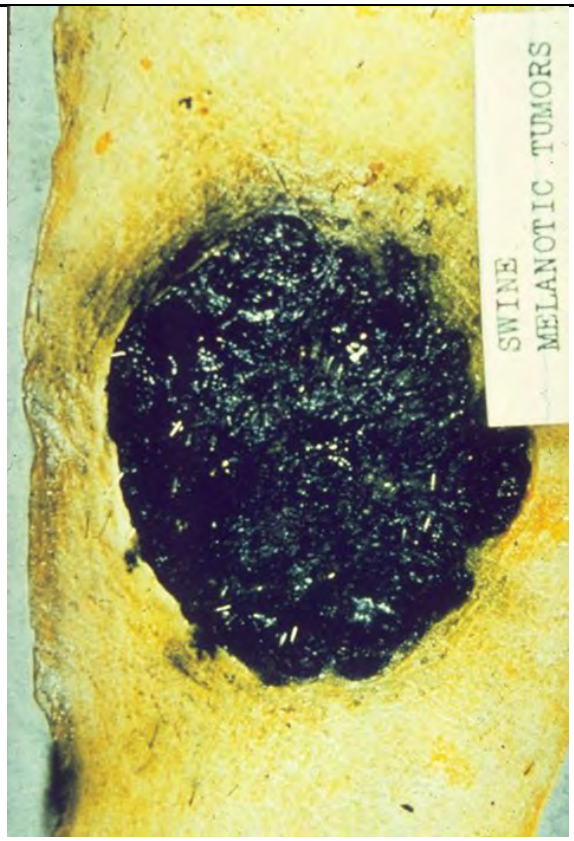	Melanoma (benign or malignant tumor).

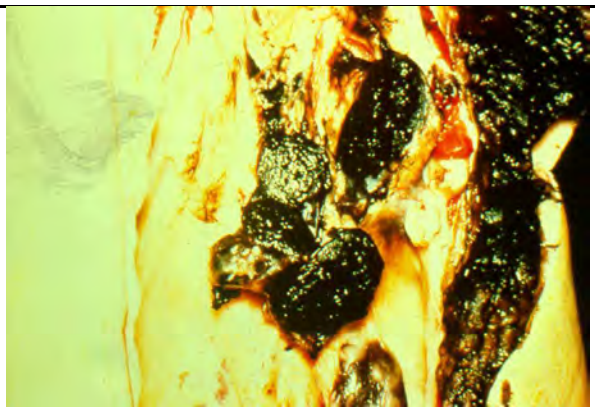	Pigmentation of lymph nodes; possible tumor.
	Notice melanotic patches of skin on the carcass. Check draining lymph nodes and viscera for evidence of melanosis or metastasis.

Post-Mortem Signs:

1. Melanin pigment in lungs, liver, lymph nodes, or other organs;
2. Melanin in skin;
3. Melanin in sclera of eye;
4. Melanin associated with inflammation;
5. Metastasis (i.e., multiple tumors) to regional lymph nodes;
6. Metastasis to the lungs; and/or
7. Metastasis to the liver, spleen, and other internal organs.

Disposal: Sorters are required to identify localized defects for removal under FSIS inspection. Sorters are required to identify carcasses with the following signs of acute, systemic, or generalized defects for disposal under FSIS inspection:

1. Generalized pigmentary deposits;
2. Melanin that cannot be removed or is impractical to remove, or that renders a carcass, organ, or part or the affected portion of a carcass, organ or part unfit for human food;
3. Evidence of abnormal tumor growth (i.e., metastasis-formation of multiple tumors); and
4. Tumors affecting the overall health or condition of the animal and carcass.

Special Notes: Slight melanin deposits in spinal cord sheath (meninges) are normal. When including surface of the bones, the pigmented tissue must be removed when its appearance does not meet consumer expectations (9 CFR 311.1 and 311.13(b)). Slight or diffuse pigmentation of skin need not be removed unless tumorous or smeary.

P. Icterus (Jaundice)

Icterus represents an abnormal accumulation of yellowish bile pigments associated with the breakdown of blood that is stored in liver cells or the gall bladder (see 9 CFR 311.19).

Post-Mortem Signs:

1. Degenerative changes in liver (e.g., pale, enlarged) and/or darkened spleen;
2. Lemon-yellow discoloration of connective tissues that are normally very white or pale including:
    a. Sclera (white part) of the eye,
    b. Tendons,
    c. Pleura (lining of the chest cavity),
    d. Peritoneum (lining of the abdominal cavity),
    e. Omentum (tissue that extends from the stomach to the adjacent organs in the abdominal cavity),
    f. Cut surface of abdominal wall fat,
    g. Joint surfaces, or
    h. Mesentery (fold of tissue attaching small intestines to the body wall).

Disposal: Sorters are required to identify localized defects for removal under FSIS inspection. Sorters are required to identify carcasses that are icteric for disposal under FSIS inspection.

Special Notes: Sorters should notify the PHV if they intend to hold icteric carcasses in the cooler pending final disposition.

Q. Embryonal Nephroma

Embryonal nephromas are rough, fibrous raised tumors of the kidney (see 9 CFR 311.11). Generally, they are benign tumors and occur more commonly in young animals.

Post-Mortem Signs:
Presence of rough, fibrous tissue near the kidneys.

	Benign Embryonal Nephroma. Embryonal Nephromas are typically benign (i.e. non-malignant) congenital kidney tumors in swine.

Disposal: Sorters are required to identify localized defects for removal under FSIS inspection. Sorters are required to identify carcasses showing signs of acute, systemic, or generalized embryonal nephroma for disposal under FSIS inspection.

R. Malignant Lymphoma

Lymphoma is a neoplastic condition of the lymphocytes and is considered malignant (see 9 CFR 311.11). There are many manifestations of lymphoma, so it can be confused with other diseases, such as granulomas, abscesses, or other types of neoplasia.

Post-Mortem Signs:

1. Gross enlargement of one or more lymph nodes with uniformly pale moist surface;
2. Gross enlargement of lymph node with a large yellow necrotic center; (e.g., mandibular lymph nodes or lymph nodes of the thoracic inlet);
3. Gross enlargement of lymph nodes with a dark red center;
4. Gross enlargement of liver and spleen; and/or
5. Focal or diffuse neoplastic growth or plaques on pleural ribs wall or peritoneal (i.e., inside abdominal wall).

Disposal: Sorters are required to identify any carcass showing signs of malignant lymphoma. Regardless of the extent and distribution of the lymphoma, any evidence, just one lesion, of lymphoma requires disposal of the entire carcass and viscera.

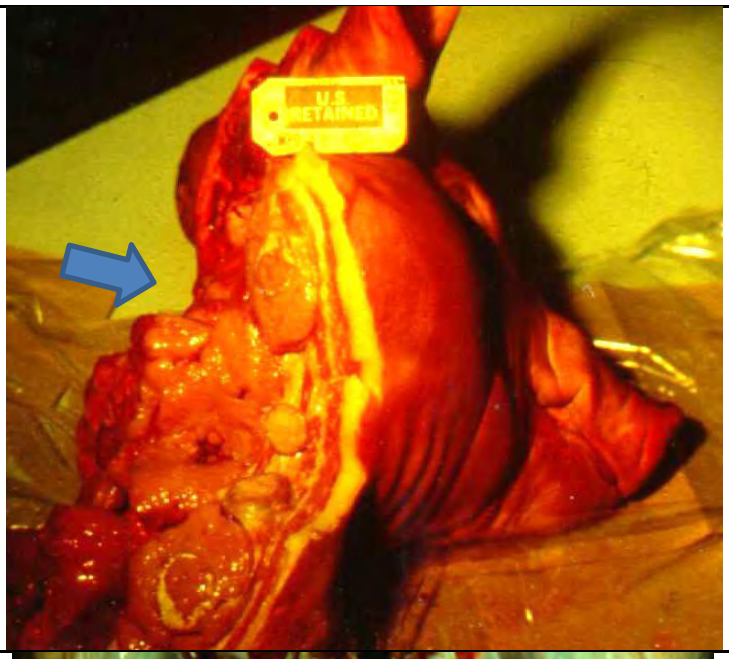	Notice large lymph nodes with smooth surface indicative of malignant lymphoma in the head. Some carcasses with malignant lymphoma may exhibit lymph nodes in the neck exhibiting a yellow necrotic center like a hard-boiled egg. Check remainder of carcass. Carcasses with any evidence of malignant lymphoma are condemned.
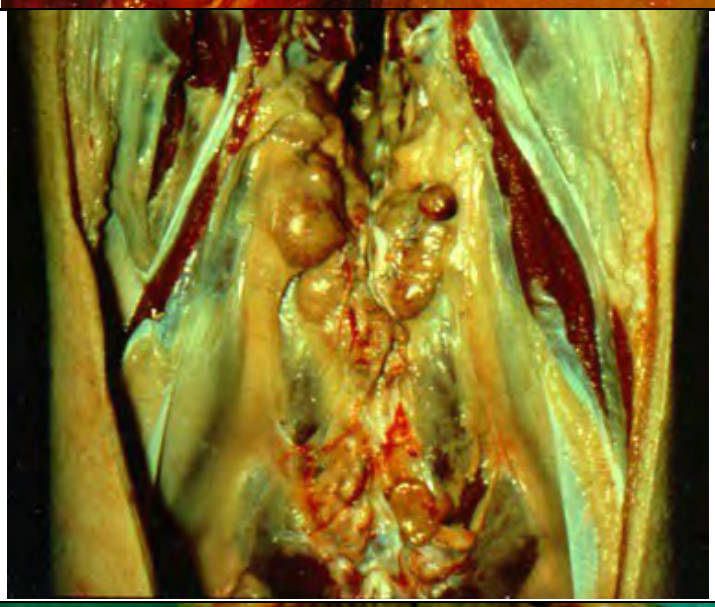	Enlarged malignant lymphoma in renal lymph nodes inside carcass.
	Malignant lymphoma in mesenteric lymph nodes.

	Malignant lymphoma infiltrating kidney in several locations. Notice several raised bumps or plaques. Lesions are often found on the ribs, diaphragm, and abdominal organs
	Notice the smooth appearance of malignant lymphoma on cut surface. The normal outer lymph node and center are obliterated with many tumor cells.
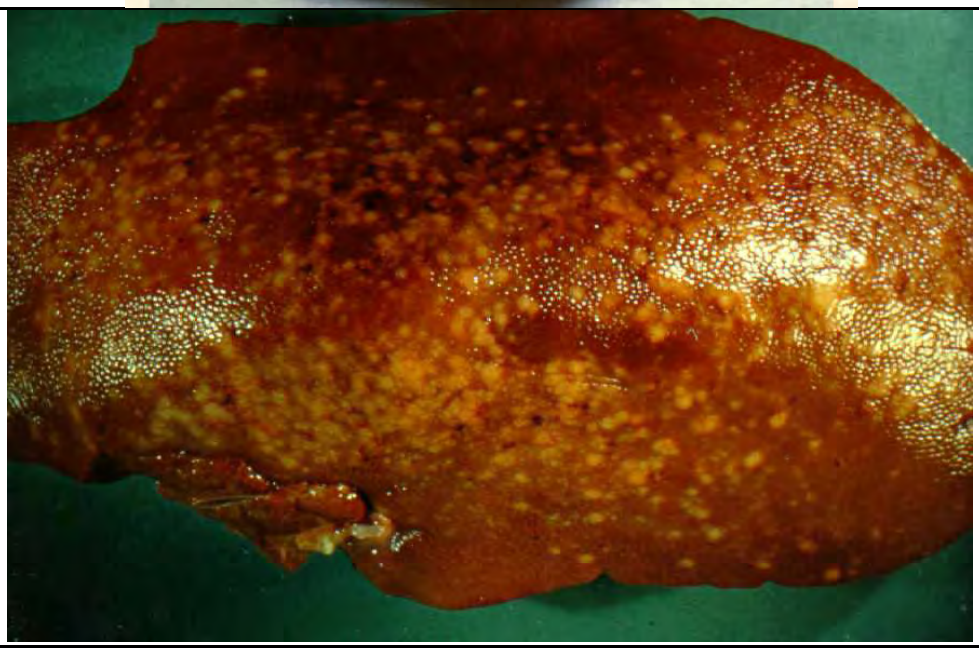	Malignant lymphoma infiltration of enlarged liver

S. Odors; Undetermined; Sexual Odor of Swine

The carcass of a barrow market hog with retained testicle can exhibit a characteristic sexual odor (see 9 CFR 311.20). Sexual odor is rarely seen in market hogs less than 6 months of age. When present, there is a distinct pungent odor to the tissues.
NOTE: Because boars and stags are not market hogs, they are not eligible for slaughter under the NSIS without a waiver under the *Salmonella* Initiative Program.

Post-Mortem Signs:

1. Any sex odor of carcass or viscera of any market hog; and/or
2. Chemical or medicinal odors.

Disposal: Sorters are required to identify any carcass that exhibits a pronounced sexual odor for disposal under FSIS inspection. However, if the sexual odor is less than pronounced, sorters may request the PHV to inspect the carcass to determine if the carcass may be passed for use as human food, as either cooked comminuted product or for rendering as lard.

Special Notes:
(1) A warm carcass should be considered to have a pronounced odor if sorters can smell the odor when they are several inches away from the carcass.
(2) If the odor is less than pronounced, sorters will have to get very close to the carcass to smell the odor.

T. Pale Soft Exudative Pork (PSE)

Extensive PSE is a form of muscular degeneration (See 9 CFR 311.35.

Post-Mortem Signs:

Affected muscle tissue appears pale soft and watery in appearance. Tissue may have a slight sour smell. Lesions may appear in one or more large muscles to varying degrees.

Disposal: Mild forms of PSE are histologically normal and the carcasses and parts are suitable for further processing. Sorters are required to identify localized defects for removal under FSIS inspection. Sorters are required to identify carcasses showing signs of acute, systemic, or generalized PSE for disposal under FSIS inspection.

U. Over-Scald

Post-Mortem Signs: Carcasses showing signs of being over-scalded will have a cooked appearance and will usually have varying degrees of mutilation and contamination of tissues with scald vat water.

Disposal: Sorters are required to identify contaminated parts (e.g., broken skin) for removal under FSIS inspection. Sorters are required to identify carcasses that are severely over-

scalded (e.g., the carcass has undergone thermal changes that may obscure other adulterating conditions like septicemia) for disposal under FSIS inspection.

V. Classical Swine Fever (Hog Cholera)

Classical Swine Fever (Hog Cholera) is a *reportable FAD* not found in the United States since 1978. Should hog cholera reappear, multiple signs of fever, illness, and inflammation will be seen at ante-mortem and post-mortem. Establishments are required to immediately notify FSIS inspectors if they identify, while conducting sorting activities, an animal or carcass that they suspect has a reportable or foreign animal disease (9 CFR 309.19(e)). Upon notification by the establishment, the PHV will notify APHIS.

W. African Swine Fever

African Swine Fever (ASF) is also a *reportable FAD* not found in the United States. ASF is currently affecting swine in other countries around the world. Notable signs include high death loss, fever, and illness. Establishments are required to immediately notify FSIS inspectors if they identify, while conducting sorting activities, an animal or carcass that they suspect has a reportable or foreign animal disease (9 CFR 309.19(e)). For more information on ASF, see the APHIS website:
https://www.aphis.usda.gov/aphis/ourfocus/animalhealth/animal-disease-information/swine-disease-information/african-swine-fever/african-swine-fever

X. Brucellosis in Feral or Other Swine Classes

Swine brucellosis is a *reportable disease* rarely found in confinement raised market hogs. Swine brucellosis may be found in other classes of swine especially mature breeding swine or feral swine. Swine brucellosis is a potential disease of public health concern and occupational health. Human infections are associated with exposure to reproductive organs (e.g. uterus, testicles). Brucellosis in market hogs has few post mortem lesions. Establishments are required to immediately notify FSIS inspectors if they identify, while conducting sorting activities, an animal or carcass that they suspect has a reportable or foreign animal disease (9 CFR 309.19(e)).

Special Notes: Should an establishment desire to slaughter other classes of swine (e.g. sows, boars, and feral swine) under the NSIS, a waiver would be required.

IX. REFERENCES

A. FSIS Online Inspection Training Information

1. FSIS Slaughter Inspection Training
https://www.fsis.usda.gov/sites/default/files/media_file/2021-11/Slaughter-Inspection-Refresher-Course-Student-Notebook-072021.pdf

2. PHV Training Materials
https://www.fsis.usda.gov/sites/default/files/media_file/documents/PHV-Weeks-1-2-Notebook-08042022.pdf

https://www.fsis.usda.gov/sites/default/files/media_file/documents/PHV_Final_Week_Notebook_09-22.pdf

3. Training Courses and Materials
https://www.fsis.usda.gov/inspection/inspection-training-videos/inspection-mission-training

4. FSIS Federal Code of Regulations, Sections 309-311 [9 CFR 309-311] http://www.ecfr.gov/cgi-bin/text-idx?SID=4632a5415489f65b789aea7bbc069bea&mc=true&tpl=/ecfrbrowse/Title09/9cfrv2_02.tpl#300

5. FSIS Directive 6000.1 - Responsibilities Related to Foreign Animal Diseases (FADs) and Reportable Conditions
6. FSIS Directive 6100.1 – Ante-mortem Directive
7. FSIS Directive 6100.2 - Post-mortem Directive
8. FSIS Directive 6420.2 - Livestock Zero Tolerance Directive
9. FSIS Directive 6240.1 - TB Directive and related materials
10. FSIS Directive 6100.8 - Instructions for Verification of IMPROVEST® Hogs

[https://www.fsis.usda.gov/policy/directives-notices-guidelines/fsis-

directives?f%5B0%5D=series%3A168]

B. APHIS Online Information on Reportable and Foreign Animal Diseases

1. APHIS Animal Disease Training
- https://www.aphis.usda.gov/aphis/ourfocus/animalhealth/animal-disease-information

2. APHIS Veterinary Service Points of Contact
- https://www.aphis.usda.gov/animal_health/downloads/sprs_contact/field_office_contact_info.pdf

C. Scientific or Academic Resources

Office International des Epizooties (OIE) Sites

- http://www.oie.int/en/animal-health-in-the-world/animal-diseases/

Iowa State Center for Food Safety and Public Health

- http://www.cfsph.iastate.edu/Species/swine.php
- http://www.cfsph.iastate.edu/pdf/foot-and-mouth-disease-pocket-guide-swine

https://www.fsis.usda.gov/contact-us/askfsis

FSIS/USDA
www.fsis.usda.gov

X. Congressional Review Act

Pursuant to the Congressional Review Act at 5 U.S.C. 801 et seq., the Office of Information and Regulatory Affairs has determined that this guideline is not a "major rule," as defined by 5 U.S.C. 804(2).