ExamWorks

Claimant : KEVIN BROWN

Table of Contents

Application for No Fault Benefits 3

Sorted Medical Records 9

Ahmed, MD, Omar 9

10/19/2023 - Carotid Ultrasound 9

10/19/2023 - TCD 10

1/19/2024 15

1/19/2024 - EMG/NCV 20

Barakat, MD, Jean-Pierre 24

10/16/2023-10/17/2023 24

10/17/2023 - Outcome Assessment 48

10/18/2023-11/14/2023 55

11/14/2023 - Outcome Assessment 70

11/15/2023-12/12/2023 77

12/12/2023 - Outcome Assessment 91

12/13/2023-1/9/2023 98

1/9/2024 - Outcome Assessment 110

2/6/2024 117

Undated 126

Dauito, MD, Ralph 127

11/2/2023 - MRI of the Cervical Spine 127

11/2/2023 - MRI of the Lumbar Spine 129

11/16/2023 - MRI of the Right Ankle 131

Halioua, MD, Solomon 133

11/14/2023 133

11/25/2023 - OP 136

12/12/2023 140

12/13/2023 - OP 146

12/14/2023-3/12/2024 161

3/15/2024 - OP 166

Hamid, MD, Alam 173

10/19/2023 - Left Elbow Ultrasound 173

10/19/2023 - Left Knee Ultrasound 174

10/19/2023 - Left Shoulder Ultrasound 175

10/19/2023 - Right Knee Ultrasound 176

10/19/2023 - Right Shoulder Ultrasound 177

10/19/2023 - Ultrasound for Paraspinal Muscles of the Lumbar Spine 178

O'Donnell, James 179

12/13/2023 179

Rawlins, MD, Sherrie 180

12/14/2023 180

12/14/2023 - EMG/NCV 190

Tomasello, DO, Peter 195

12/6/2023 195

Vargas, PT, kathleen 200

1/19/2024 200

Vavikova, DC, Diana 203

11/6/2023 - Diagnostic Sonogram Report 203

2/6/2024 - Diagnostic Sonogram Report 207

Physical Therapy Notes/Meds 212

Way to Rehab PT, PC 212

12/1/2023-3/22/2024 212

Chiropractic Records 242

Inspired Chiropractic, P.C. 242

10/16/2023-2/12/2024 242

00d

NEW YORK MOTOR VEHICLE NO-FAULT INSURANCE LAW
APPLICATION FOR MOTOR VEHICLE NO-FAULT BENEFITS

DATE	POLICYHOLDER	POLICY NUMBER	DATE OF ACCIDENT	CLAIM NUMBER
			10/13/23	2393383774

TO ENABLE US TO DETERMINE IF YOUR ARE ENTITLED TO BENEFITS UNDER THE NEW YORK NO-FAULT LAW, PLEASE COMPLETE THIS FORM AND RETURN IT PROMPTLY.

IMPORTANT:
1. TO BE ELIGIBLE FOR BENEFITS YOU MUST COMPLETE AND SIGN THIS APPLICATION.
2. YOU MUST SIGN ANY ATTACHED AUTHORIZATION(S).
3. RETURN PROMPTLY WITH COPIES OF ANY BILLS YOU HAVE RECEIVED TO DATE.

1. YOUR NAME: Kevin Brown
2. PHONE NOS. HOME: 646 644 4417 BUSINESS:
3. YOUR ADDRESS (NO., STREET, CITY OR TOWN AND ZIP CODE): 6723 Eliot Ave Middle Village, NY 11379
4. DATE OF BIRTH: 7/6/87
5. SOCIAL SECURITY NO.: 107-76-0478
6. DATE AND TIME OF ACCIDENT: 10/13/23 4:25 A.M. P.M. ✓
7. PLACE OF ACCIDENT (STREET), CITY OR TOWN AND STATE: Fresh Pond rd & 62nd rd
8. BRIEF DESCRIPTION OF ACCIDENT: I was rear-ended
9. DESCRIBE YOUR INJURY: Neck Back & leg pain Right Ankle
10. IDENTITY OF VEHICLE YOU OCCUPIED OR OPERATED AT THE TIME OF THE ACCIDENT:

OWNER'S NAME	MAKE	YEAR
Kevin Brown	Nissan	2020

THIS VEHICLE WAS: [ ] A BUS OR SCHOOL BUS, [ ] OR A MOTORCYCLE [ ] A TRUCK, [✓] AN AUTOMOBILE,

	YES	NO
11. WERE YOU THE DRIVER OF THE MOTOR VEHICLE?	✓	
WERE YOU A PASSENGER IN THE MOTOR VEHICLE?		✓
WERE YOU A PEDESTRIAN?		✓
WERE YOU A MEMBER OF OUR POLICYHOLDER'S HOUSEHOLD?		✓
DO YOU OR A RELATIVE WITH WHOM YOU RESIDE OWN A MOTOR VEHICLE?		✓

CONTINUATION ON NEXT PAGE

ECN: 2023112400049 Received Date: 2023-11-22

PQO

APPLICATION FOR MOTOR VEHICLE NO-FAULT BENEFITS - - PAGE TWO

12. WERE YOU TREATED BY A DOCTOR(S) OR OTHER PERSON(S) FURNISHING HEALTH SERVICES?

YES ☐ NO ☑

IF YES, NAME AND ADDRESS OF SUCH DOCTOR(S) OR PERSON(S):

13. IF YOUR WERE TREATED AT A HOSPITAL(S), WERE YOU AN

OUT-PATIENT? ☐ IN-PATIENT? ☐

DATE OF ADMISSION:

HOSPITAL'S NAME AND ADDRESS:

14. AMOUNT OF HEALTH BILLS TO DATE:

$

15. WILL YOU HAVE MORE HEALTH TREATMENT(S)? YES ☑ NO ☐

16. AT THE TIME OF YOUR ACCIDENT WERE YOU IN THE COURSE OF YOUR EMPLOYMENT? YES ☐ NO ☑

17. DID YOU LOSE TIME FROM WORK? YES ☐ NO ☑

DATE ABSENCE FROM WORK BEGAN: N A

HAVE YOU RETURNED TO WORK? YES ☐ NO ☑ N A

IF YES, DATE RETURNED TO WORK:

AMOUNT OF TIME LOST FROM WORK:

18. WHAT ARE YOUR GROSS AVERAGE WEEKLY EARNINGS?

NUMBER OF DAYS YOU WORK PER WEEK:

NUMBER OF HOURS YOU WORK PER DAY:

19. WERE YOU RECEIVING UNEMPLOYMENT BENEFITS AT THE TIME OF THE ACCIDENT?

YES ☐ NO ☐

20. LIST NAMES AND ADDRESS OF YOUR EMPLOYER AND OTHER EMPLOYERS FOR ONE YEAR PRIOR TO ACCIDENT DATE AND GIVE OCCUPATION AND DATES OF EMPLOYMENT:

EMPLOYER AND ADDRESS	OCCUPATION	FROM	TO
EMPLOYER AND ADDRESS	OCCUPATION	FROM	TO
EMPLOYER AND ADDRESS	OCCUPATION	FROM	TO

21 AS A RESULT OF YOUR INJURY HAVE YOU HAD ANY OTHER EXPENSES?

YES ☐ NO ☐

IF YES, ATTACH EXPLANATION AND AMOUNTS OF SUCH EXPENSES.

22. DUE TO THIS ACCIDENT HAVE YOU RECEIVED OR ARE YOU ELIGIBLE FOR PAYMENTS UNDER ANY OF THE FOLLOWING:

	YES	NO
NEW YORK STATE DISABILITY?	☐	☐
WORKERS' COMPENSATION?	☐	☐

CONTINUATION ON NEXT PAGE

ECN: 2023112400049 Received Date: 2023-11-22

PQO

APPLICATION FOR MOTOR VEHICLE NO-FAULT BENEFITS - - PAGE THREE

THE APPLICANT AUTHORIZES THE INSURER TO SUBMIT ANY AND ALL OF THESE FORMS TO ANOTHER PARTY OR INSURER IF SUCH IS NECESSARY TO PERFECT ITS RIGHTS OF RECOVERY PROVIDED FOR UNDER THE NO-FAULT LAW.

THIS FORM IS SUBSCRIBED AND AFFIRMED BY THE APPLICANT AS TRUE UNDER THE PENALTIES OF PERJURY

ANY PERSON WHO KNOWINGLY AND WITH INTENT TO DEFRAUD ANY INSURANCE COMPANY OR OTHER PERSON FILES AN APPLICATION FOR COMMERCIAL INSURANCE OR A STATEMENT OF CLAIM FOR ANY COMMERCIAL OR PERSONAL INSURANCE BENEFITS CONTAINING ANY MATERIALLY FALSE INFORMATION, OR CONCEALS FOR THE PURPOSE OF MISLEADING, INFORMATION CONCERNING ANY FACT MATERIAL THERETO, AND ANY PERSON WHO, IN CONNECTION WITH SUCH APPLICATION OR CLAIM, KNOWINGLY MAKES OR KNOWINGLY ASSISTS, ABETS, SOLICITS OR CONSPIRES WITH ANOTHER TO MAKE A FALSE REPORT OF THE THEFT, DESTRUCTION, DAMAGE OR CONVERSION OF ANY MOTOR VEHICLE TO A LAW ENFORCEMENT AGENCY, THE DEPARTMENT OF MOTOR VEHICLES OR AN INSURANCE COMPANY, COMMITS A FRAUDULENT INSURANCE ACT, WHICH IS A CRIME, AND SHALL ALSO BE SUBJECT TO A CIVIL PENALTY NOT TO EXCEED FIVE THOUSAND DOLLARS AND THE VALUE OF THE SUBJECT MOTOR VEHICLE OR STATED CLAIM FOR EACH VIOLATION.

SIGNATURE — 10/16/23 DATE

DO NOT DETACH

AUTHORIZATION FOR RELEASE OF WORK AND OTHER LOSS INFORMATION

THIS AUTHORIZATION OR PHOTOCOPY THEREOF, WILL AUTHORIZE YOU TO FURNISH ALL INFORMATION YOU MAY HAVE REGARDING MY WAGES, SALARY OR OTHER LOSS WHILE EMPLOYED BY YOU. YOUR ARE AUTHORIZED TO PROVIDE THIS INFORMATION IN ACCORDANCE WITH THE NEW YORK COMPREHENSIVE MOTOR VEHICLE INSURANCE REPARATIONS ACT (NO-FAULT LAW).

Kevin Brown
NAME (PRINT OR TYPE)

107-76-0478
SOCIAL SECURITY NO.

SIGNATURE

10/16/23
DATE

DO NOT DETACH

AUTHORIZATION FOR RELEASE OF HEALTH SERVICE OR TREATMENT INFORMATION

THIS AUTHORIZATION OR PHOTOCOPY THEREOF, WILL AUTHORIZE YOU TO FURNISH ALL INFORMATION YOU MAY HAVE REGARDING MY CONDITION WHILE UNDER YOUR OBSERVATION OR TREATMENT, INCLUDING THE HISTORY OBTAINED, X-RAYS AND PHYSICAL FINDINGS, DIAGNOSIS AND PROGNOSIS. YOU ARE AUTHORIZED TO PROVIDE THIS INFORMATION IN ACCORDANCE WITH THE NEW YORK COMPREHENSIVE MOTOR VEHICLE INSURANCE REPARATIONS ACT (NO-FAULT LAW).

Kevin Brown
NAME (PRINT OR TYPE)

SIGNATURE

10/16/23
DATE

(IF THE APPLICANT IS A MINOR, PARENT OR GUARDIAN SHALL SIGN AND INDICATE CAPACITY AND RELATIONSHIP)

ECN: 2023112400049 Received Date: 2023-11-22

NEW YORK MOTOR VEHICLE NO-FAULT INSURANCE LAW
APPLICATION FOR MOTOR VEHICLE NO-FAULT BENEFITS

Progressive Casualty Insurance Co.
P.O. Box 2930
Clinton, IA 52733-2930

(800) 627-4581

DATE	POLICYHOLDER	POLICY NUMBER	DATE OF ACCIDENT	CLAIM NUMBER
11/8/2023	Kevin Brown	971111282	10/13/2023	239338374

TO ENABLE US TO DETERMINE IF YOUR ARE ENTITLED TO BENEFITS UNDER THE NEW YORK NO-FAULT LAW, PLEASE COMPLETE THIS FORM AND RETURN IT PROMPTLY.

IMPORTANT: 1. TO BE ELIGIBLE FOR BENEFITS YOU MUST COMPLETE AND SIGN THIS APPLICATION.
2. YOU MUST SIGN ANY ATTACHED AUTHORIZATION(S).
3. RETURN PROMPTLY WITH COPIES OF ANY BILLS YOU HAVE RECEIVED TO DATE.

KEVIN BROWN
C/O LAW OFFICE OF COHEN & JAFFE

1. YOUR NAME
Kevin Brown

2. PHONE NOS. HOME BUSINESS
(646) 644-4417

3. YOUR ADDRESS (NO., STREET, CITY OR TOWN AND ZIP CODE)
67-23 Eliot Avenue
Middle Village, NY 11379

4. DATE OF BIRTH
7/6/1987

5. SOCIAL SECURITY NO.
107-76-0478

6. DATE AND TIME OF ACCIDENT
10/13/2023 4:25 A.M. (P.M.)

7. PLACE OF ACCIDENT (STREET), CITY OR TOWN AND STATE
Fresh Pond Road & 62nd Road, Queens, NY

8. BRIEF DESCRIPTION OF ACCIDENT
I was rear ended by another vehicle.

9. DESCRIBE YOUR INJURY
Severe pain in neck, back, lower back, right leg, right calf muscle; shooting pain in right leg. Other multiple injuries.

10. IDENTITY OF VEHICLE YOU OCCUPIED OR OPERATED AT THE TIME OF THE ACCIDENT:

OWNER'S NAME	MAKE	YEAR
Kevin Brown	Nissan	2020

THIS VEHICLE WAS: [ ] A BUS OR SCHOOL BUS, [ ] OR A MOTORCYCLE [ ] A TRUCK, [✓] AN AUTOMOBILE,

11. WERE YOU THE DRIVER OF THE MOTOR VEHICLE?
WERE YOU A PASSENGER IN THE MOTOR VEHICLE?
WERE YOU A PEDESTRIAN?
WERE YOU A MEMBER OF OUR POLICYHOLDER'S HOUSEHOLD?
DO YOU OR A RELATIVE WITH WHOM YOU RESIDE OWN A MOTOR VEHICLE?

	YES	NO
WERE YOU THE DRIVER OF THE MOTOR VEHICLE?	✓	
WERE YOU A PASSENGER IN THE MOTOR VEHICLE?		✓
WERE YOU A PEDESTRIAN?		✓
WERE YOU A MEMBER OF OUR POLICYHOLDER'S HOUSEHOLD?	✓	
DO YOU OR A RELATIVE WITH WHOM YOU RESIDE OWN A MOTOR VEHICLE?	✓	

CONTINUATION ON NEXT PAGE

ECN: 2023111500347 Received Date: 2023-11-14

APPLICATION FOR MOTOR VEHICLE NO-FAULT BENEFITS - - PAGE TWO

12. WERE YOU TREATED BY A DOCTOR(S) OR OTHER PERSON(S) FURNISHING HEALTH SERVICES?

YES [✓] NO [ ]

IF YES, NAME AND ADDRESS OF SUCH DOCTOR(S) OR PERSON(S):

Rego Park Medical Center, 62-69 99th Street, Rego Park, NY 11374

13. IF YOUR WERE TREATED AT A HOSPITAL(S), WERE YOU AN

OUT-PATIENT? [ ] IN-PATIENT? [ ]

DATE OF ADMISSION: _____

HOSPITAL'S NAME AND ADDRESS: _____

14. AMOUNT OF HEALTH BILLS TO DATE:	15. WILL YOU HAVE MORE HEALTH TREATMENT(S)?	16. AT THE TIME OF YOUR ACCIDENT WERE YOU IN THE COURSE OF YOUR EMPLOYMENT?
$ unknown	YES [✓] NO [ ]	YES [ ] NO [✓]

17. DID YOU LOSE TIME FROM WORK?	DATE ABSENCE FROM WORK BEGAN:	HAVE YOU RETURNED TO WORK?
YES [✓] NO [ ]	10/13/2023	YES [ ] NO [ ]

IF YES, DATE RETURNED TO WORK: _____

AMOUNT OF TIME LOST FROM WORK: to be determined

18. WHAT ARE YOUR GROSS AVERAGE WEEKLY EARNINGS?	NUMBER OF DAYS YOU WORK PER WEEK:	NUMBER OF HOURS YOU WORK PER DAY:
	7	6

19. WERE YOU RECEIVING UNEMPLOYMENT BENEFITS AT THE TIME OF THE ACCIDENT?

YES [ ] NO [✓]

20. LIST NAMES AND ADDRESS OF YOUR EMPLOYER AND OTHER EMPLOYERS FOR ONE YEAR PRIOR TO ACCIDENT DATE AND GIVE OCCUPATION AND DATES OF EMPLOYMENT:

EMPLOYER AND ADDRESS	OCCUPATION	FROM	TO
Instacart, 50 Beale St, San Francisco, CA 94105			Present
EMPLOYER AND ADDRESS	OCCUPATION	FROM	TO
EMPLOYER AND ADDRESS	OCCUPATION	FROM	TO

21. AS A RESULT OF YOUR INJURY HAVE YOU HAD ANY OTHER EXPENSES?

YES [✓] NO [ ]

IF YES, ATTACH EXPLANATION AND AMOUNTS OF SUCH EXPENSES. To Follow

22. DUE TO THIS ACCIDENT HAVE YOU RECEIVED OR ARE YOU ELIGIBLE FOR PAYMENTS UNDER ANY OF THE FOLLOWING:

	YES	NO
NEW YORK STATE DISABILITY?	[ ]	[ ]
WORKERS' COMPENSATION?	[ ]	[✓]

CONTINUATION ON NEXT PAGE

ECN: 2023111500347 Received Date: 2023-11-14

THE APPLICANT AUTHORIZES THE INSURER TO SUBMIT ANY AND ALL OF THESE FORMS TO ANOTHER PARTY OR INSURER IF SUCH IS NECESSARY TO PERFECT ITS RIGHTS OF RECOVERY PROVIDED FOR UNDER THE NO-FAULT LAW.

THIS FORM IS SUBSCRIBED AND AFFIRMED BY THE
APPLICANT AS TRUE UNDER THE PENALTIES OF PERJURY

ANY PERSON WHO KNOWINGLY AND WITH INTENT TO DEFRAUD ANY INSURANCE COMPANY OR OTHER PERSON FILES AN APPLICATION FOR COMMERCIAL INSURANCE OR A STATEMENT OF CLAIM FOR ANY COMMERCIAL OR PERSONAL INSURANCE BENEFITS CONTAINING ANY MATERIALLY FALSE INFORMATION, OR CONCEALS FOR THE PURPOSE OF MISLEADING, INFORMATION CONCERNING ANY FACT MATERIAL THERETO, AND ANY PERSON WHO, IN CONNECTION WITH SUCH APPLICATION OR CLAIM, KNOWINGLY MAKES OR KNOWINGLY ASSISTS, ABETS, SOLICITS OR CONSPIRES WITH ANOTHER TO MAKE A FALSE REPORT OF THE THEFT, DESTRUCTION, DAMAGE OR CONVERSION OF ANY MOTOR VEHICLE TO A LAW ENFORCEMENT AGENCY, THE DEPARTMENT OF MOTOR VEHICLES OR AN INSURANCE COMPANY, COMMITS A FRAUDULENT INSURANCE ACT, WHICH IS A CRIME, AND SHALL ALSO BE SUBJECT TO A CIVIL PENALTY NOT TO EXCEED FIVE THOUSAND DOLLARS AND THE VALUE OF THE SUBJECT MOTOR VEHICLE OR STATED CLAIM FOR EACH VIOLATION.

KB
SIGNATURE

10 / 13 / 2023
DATE

DO NOT DETACH

AUTHORIZATION FOR RELEASE OF WORK AND OTHER LOSS INFORMATION

THIS AUTHORIZATION OR PHOTOCOPY THEREOF, WILL AUTHORIZE YOU TO FURNISH ALL INFORMATION YOU MAY HAVE REGARDING MY WAGES, SALARY OR OTHER LOSS WHILE EMPLOYED BY YOU. YOUR ARE AUTHORIZED TO PROVIDE THIS INFORMATION IN ACCORDANCE WITH THE NEW YORK COMPREHENSIVE MOTOR VEHICLE INSURANCE REPARATIONS ACT (NO-FAULT LAW).

Kevin Brown
NAME (PRINT OR TYPE)

107 76 0478
SOCIAL SECURITY NO.

KB
SIGNATURE

10 / 13 / 2023
DATE

DO NOT DETACH

AUTHORIZATION FOR RELEASE OF HEALTH SERVICE OR TREATMENT INFORMATION

THIS AUTHORIZATION OR PHOTOCOPY THEREOF, WILL AUTHORIZE YOU TO FURNISH ALL INFORMATION YOU MAY HAVE REGARDING MY CONDITION WHILE UNDER YOUR OBSERVATION OR TREATMENT, INCLUDING THE HISTORY OBTAINED, X-RAYS AND PHYSICAL FINDINGS, DIAGNOSIS AND PROGNOSIS. YOU ARE AUTHORIZED TO PROVIDE THIS INFORMATION IN ACCORDANCE WITH THE NEW YORK COMPREHENSIVE MOTOR VEHICLE INSURANCE REPARATIONS ACT (NO-FAULT LAW).

Kevin Brown
NAME (PRINT OR TYPE)

KB
SIGNATURE

10 / 13 / 2023
DATE

(IF THE APPLICANT IS A MINOR, PARENT OR GUARDIAN SHALL SIGN AND INDICATE CAPACITY AND RELATIONSHIP).

Doc ID: a1d22c3e5c6ba8dda7d2eb6d5dcf663ed99a433a

ECN: 2023111500347 Received Date: 2023-11-14

Patient Name:	BROWN, KEVIN	Date of Service:	10/19/2023 04:04 PM
MRN:		Referring Facility:	62-69 99TH STR, REGO PARK, NY 11374
Date of Birth:	07/06/1987 (age: 36)	Referring Physician:	
Gender:	Male	Technologist:	Boldin, Deborah
Accession No:	4979683	Reading Group:	Omar Ahmed

PROCEDURE: Carotid **CPT Code: 93880**

TECHNIQUE: After informed consent, a real-time carotid ultrasound with image documentation was performed.

Right **Left**

Plaque Morphology	Stenosis	EDV (cm/s)	PSV (cm/s)		PSV (cm/s)	EDV (cm/s)	Stenosis	Plaque Morphology
		25.19	100.75	CCA prox	93.83	30.23		
		26.45	86.9	CCA dis	86.27	32.12		
		16.37	63.6	Bulb	73.05	28.34		
		19.52	69.9	ICA prox	89.42	44.08		
		17.63	72.42	ECA	80.6	35.89		

FINDINGS (RIGHT SIDE):
Peak systolic velocities in the right bulb, internal, and external carotid arteries are within normal limits.

FINDINGS (LEFT SIDE):
Peak systolic velocities in the left bulb, internal, and external carotid arteries are within normal limits.

CONCLUSION:
No evidence of hemodynamically significant stenosis in the bilateral carotid bifurcation vessels.

Thank you for your kind referral of this patient.

Signed by: Ahmed, Omar
Signed at: 10/23/2023 09:19:12 PM

ECN: 2023111004790 Received Date: 2023-11-09

TCD (93892) Report

Patient:	BROWN, KEVIN	Date of Birth:	07/06/1987 (age: 36, Male)
Study time:	10/19/2023	Accession:	5008733
Referring:	62-69 99TH STR, REGO PARK, NY 11374 /	Technologist:	Sporykhin, Michael

CONCLUSION:

- This study confirms the patency of the major basal intracranial arteries in the Circle of Willis.
- Vasomotor reactivity testing showed normal vasodilator reactivity in the R MCA.
- Blood flow in R MCA showed decreased blood flow velocity.
- Blood flow in L MCA, BL ACA, BL PCA, BL VA, BA, BL OA within normal range.
- No evidence of emboli detection throughout the monitoring period.
- TCD is not sensitive for tumors, aneurysms, and small AVMs.

Signed by: Omar Ahmed / Ahmed, Omar

ECN: 2023111303937 Received Date: 2023-11-10

Name	Kevin, Brown	**TCD ID**	5269
Gender	Male	**Exam Date**	10/19/2023
Age	36	Routine Exam	
D.O.B	07/06/1987	**Diagnosis**	
Referring MD		**Technician:**	

Technical Result:
Pulsed-Doppler mean velocities(cm/sec) and the Gosling pulsatility indices for each vessel insonated from the temporal, orbital, and sub-occipital windows. Vasomotor Reactivity is the percentage increase in mean flow velocity following a 20-30 second breath-holding maneuver (B/H).

TCD Exam Data:
(In the report, the unit of Peak/Mean/Dias is cm/s, Depth's unit is mm, others have no unit)

Vessel	Depth	Peak	Mean	Dias	PI	RI	SBI	S/D	HR	DIR
RMCA	52	74	50	38	0.72	0.49	0.40	1.95	62	Toward
RACA	62	79	57	46	0.58	0.42	0.32	1.72	60	Reverse
RPCA	67	81	54	40	0.76	0.51	0.26	2.03	63	Toward
LMCA	52	93	61	45	0.79	0.52	0.39	2.07	74	Toward
LACA	62	79	58	47	0.55	0.41	0.30	1.68	74	Reverse
LPCA	67	87	58	43	0.76	0.51	0.27	2.02	64	Toward
ROA	47	27	18	14	0.71	0.48	0.35	1.93	96	Toward
LOA	47	30	20	15	0.75	0.50	0.33	2.00	103	Toward
RVA	62	85	57	43	0.74	0.49	0.48	1.98	81	Reverse
LVA	62	82	53	38	0.84	0.54	0.51	2.16	94	Reverse
BA	62	83	58	45	0.66	0.46	0.30	1.84	88	Reverse
vmr pre	52	90	65	53	0.57	0.41	0.91	1.70	59	Toward
vmr hold	52	84	63	52	0.51	0.38	0.28	1.62	64	Toward
vmr after	52	94	66	52	0.64	0.45	0.19	1.81	62	Toward
hits	52	68	49	39	0.60	0.43	0.19	1.74	73	Toward

TCD Conclusion:

ECN: 2023111303937 Received Date: 2023-11-10

Patient Name: Kevin, Brown TCD ID: 5269

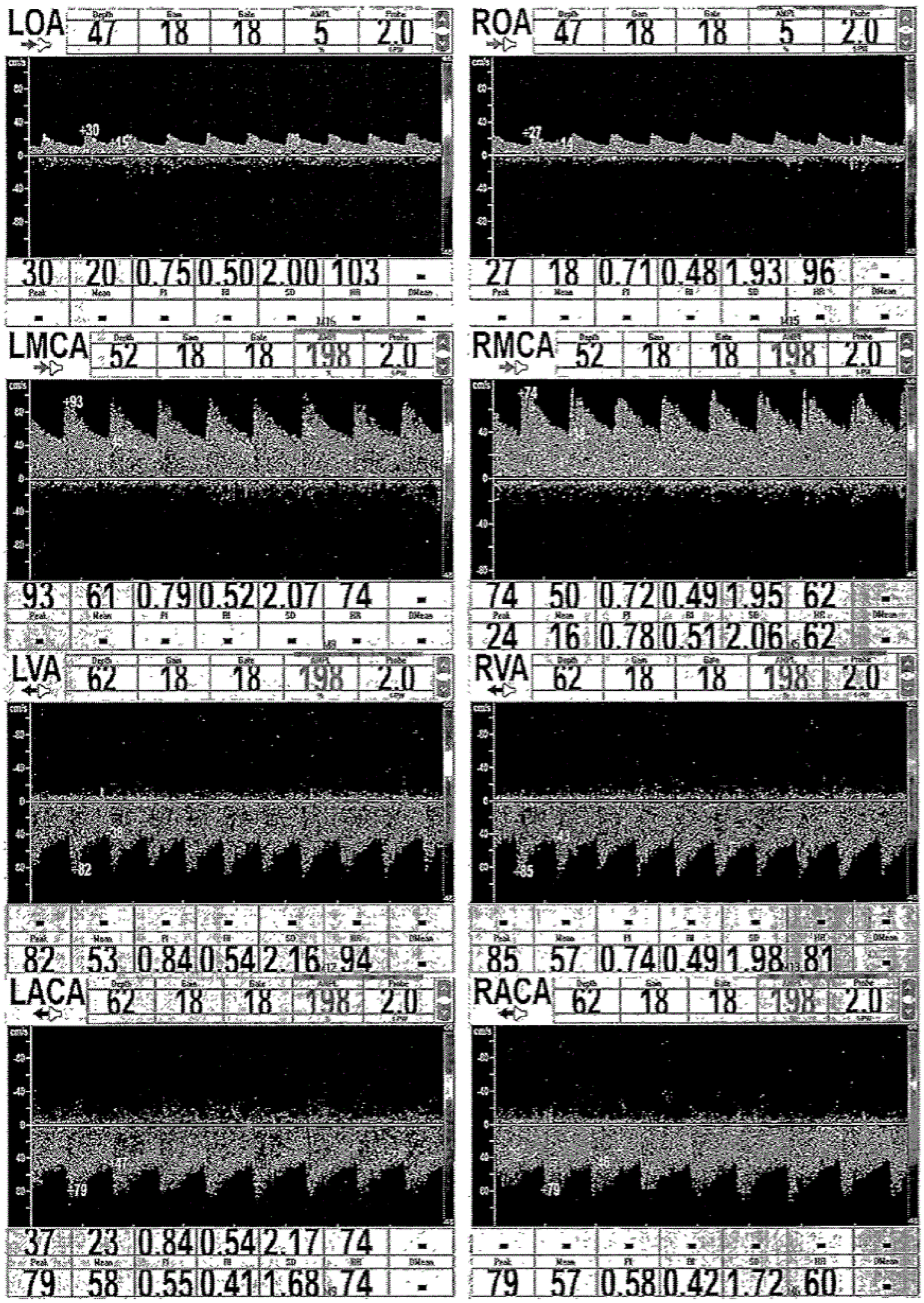

ECN: 2023111303937 Received Date: 2023-11-10

Patient Name: Kevin, Brown TCD ID: 5269

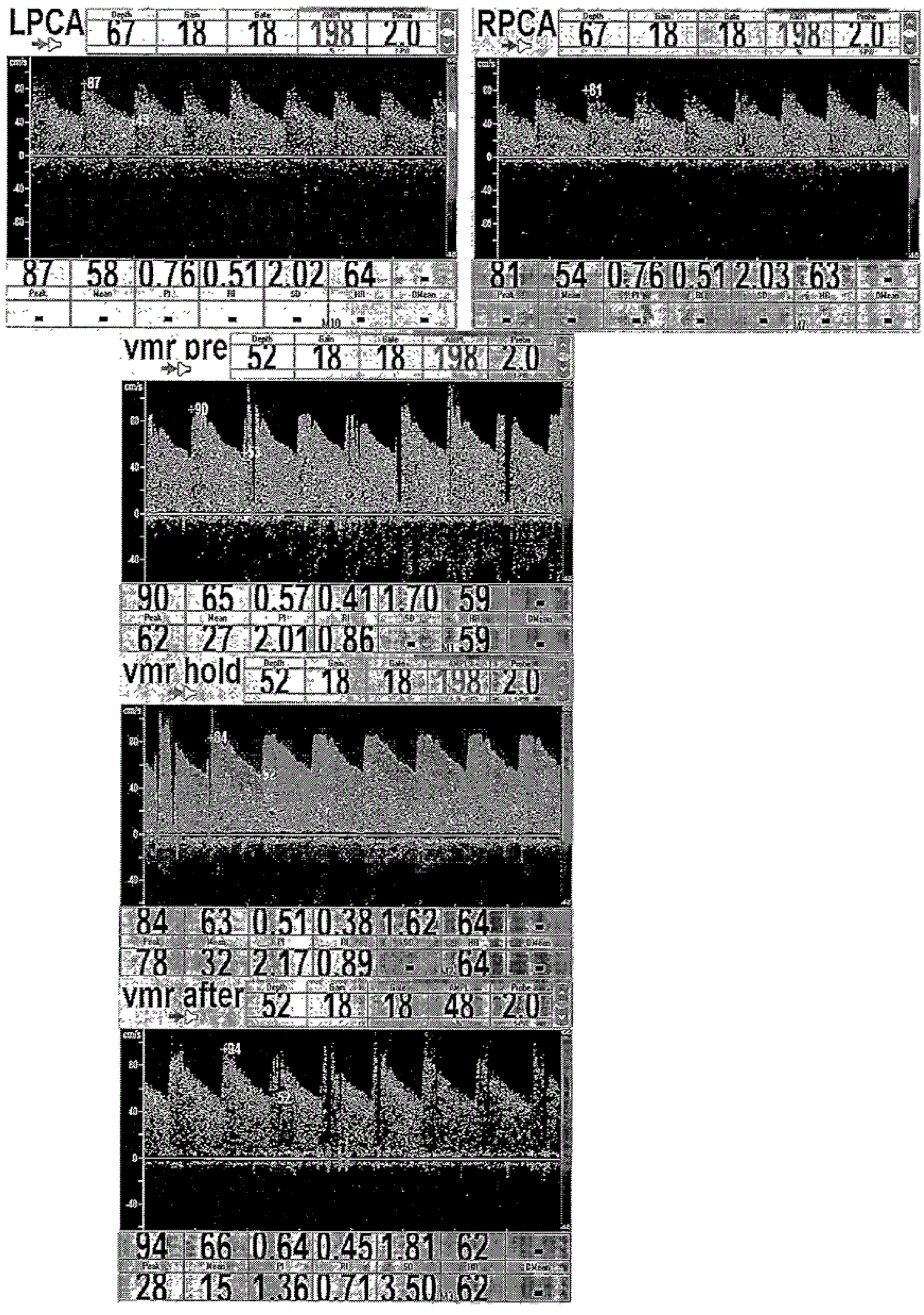

ECN: 2023111303937 Received Date: 2023-11-10

Patient Name: Kevin, Brown TCD ID: 5269



ECN: 2023111303937 Received Date: 2023-11-10

Boulevard Medical Care PC
6269 99 Street
Rego Park, NY 11374

EVALUATION DATE: 1-19-24
PATIENT NAME: Sean Brown
DOB: 7-6-87 SEX: M DATE OF LOSS: 10-10-23

ELECTRODIAGNOSTIC HISTORY AND PHYSICAL EVALUATION

☒ Patient was referred for an electrodiagnostic evaluation
☒ Chart and available imaging records were reviewed

HPI: The above-named patient presented with and/or reported the following:
36 y/o [illegible] driver involved in MVA on 10/10/23 [illegible] pain
[illegible] L w/ NCS/EMG shows (C) LM-LS radiculopathy

Chief Complaint(s):

- Cervical neck pain/{with/without}radiation down (right/left/bilateral)upper extremity(ies)to _____
- With/without: numbness/ tingling/ weakness/ pain/ stiffness in (right/left/bilateral) _____
- Thoracic/ lumbar/ back pain/ {with/without} radiation down (right/left/bilateral) lower extremity(ies) to _____
- With/without: numbness/ tingling/ weakness/ pain/ stiffness in (right/left/bilateral) _____
- With/without/ bladder/ bowel problems/ fevers/ night sweats/ recent weight loss

Region	Pain Quality	Alleviating Factor	Exacerbating Factor	Setting/Timing	Pain Intensity
Head					
Cervical	Sharp	rest	turning head	[illegible]	1/10
( )					
( )					
Thoracic					
Lumbar	Sharp	rest	prolonged sitting	Sharp	8/10
( )					
( )					

Past Medical History: Diabetes: Y / N Hypertension: Y / N Pacemaker: Y / N Other: Y / N

Family History: ☒ Non-Contributory

Social History: Tobacco: Y/N Alcohol: Y/N Drug(s): Y/N

Functional History:

Prior Ambulation: Independent / with Assistance / with Cane / with Walker / with Wheelchair
Prior ADL: Independently / with assistance Device / with Home Health Aid
Handed: R / L
Occupation: Full-Time / Part-Time / Not Working / Retired / Homemaker/Student Type: clerk
Currently: Has not worked since DOL / Working / Other: _____

Allergies: ☒ No Known drug allergy

Medications: Aleve Diclofenac PRN

ROS:
GEN – no fever, no weight loss; HEENT- no headache, no dizziness, no vision change, no tinnitus, no epistaxis, no sore throat;
CV – no chest pain, no palpitation, no claudication; RESP- no shortness of breath, no cough; GI no diarrhea, no constipation;
GU – no dysuria, no retention, no incontinence; MSK- no other joint pain, no myalgia; NEURO- no ataxia, no tremor;
DERM – no rash, no lesion; HEME- no ecchymoses, no fatigue; ENDO-no polydypsia / uria; PSYCH – no altred mood, no depression
☒ All systems above were reviewed and were unremarkable unless otherwise noted.

Physical Examination:
General: Patient appears in {no acute distress (NAD) / Thin / Well-Developed / Well-Nourished / Overweight / Obese}
Patient {was / was not} able to mount exam table{independently / slowly / with assistance}
HEENT: ☒ normal cephalic atraumatic (NCAT), e☐ a-ocular muscles intact (EOMI), hearing wnl, ☐ Palate midline
CV: ☒ regular rate and rhythm (RRR), ☐ +S1S2, n☐ murmur appreciated
RESP ☒ clear to auscultation bilaterally (CTAB), S☒ metrical expansion
ABD: ☐ Soft, nondistended (ND), ☒ ontender (NT), a☐ ve bowel sounds (+BS)

Musculoskeletal Examination:

Examination of the Cervical Spine revealed {tenderness/ muscle spasm(s)/ trigger point(s)} upon palpation of:

- Right / Left / Bilateral paraspinal(s)
- Right / Left / Bilateral trapezius
- Right / Left / Bilateral supraspinatus
- Cervical Compression test was {negative / positive / not tested}
- Spurling's / Jackson's test was{negative / positive / not tested}on the right / left / bilateral side(s)

?

Cervical ROM was {full / limited} due to pain with {flexion / extension / (R/L/BL) lateral bending}

Examination of the Thoracic/Lumbar Spine revealed {tenderness / muscle spasm(s) / trigger point(s)} upon palpation of:

- Right / Left / Bilateral paraspinal(s)
- Right / Left / Bilateral scapula/ rhomboid (s)
- Right / Left / Bilateral gluteus Maximus
- Straight leg raise test was{negative / positive / not tested}
- Yeoman's femoral stretch test was {negative / positive / not tested}

Thoracic / Lumbar ROM was {full / limited} due to pain with {flexion / extension /(R / L / BL) rotation / (R/L /BL) lateral bend}

Examination of the **Shoulder(s)** reveled {tenderness / crepitus /swelling / erythema} on the {Right / Left /Bilateral} side(s). In addition

- Jobe's Empty Can test was {negative / positive / not tested}
- Hawkin's / Neer's test was {negative / positive / not tested}

Shoulder ROM was {full / limited} due to pain with {abduction / flexion / extension / IR / ER} on {R / L / BL} side(s)

Examination of the **Elbow(s)** reveled {tenderness / crepitus /swelling / erythema} on the {Right / Left /Bilateral} side(s). In addition

- Cozen's Lateral Epicondylitis test was {negative / positive / not tested}
- Tinel's test at cubital tunnel was {negative / positive / not tested}

Elbow ROM was {full / limited} due to pain with {flexion / extension} on {R / L / BL} side(s)

Examination of the **Hand / Wrist** reveled {tenderness / crepitus /swelling / erythema} on the {Right / Left /Bilateral} side(s). In addition

- Phalen's test was {negative / positive / not tested}
- Tinel's test at carpal tunnel was {negative / positive / not tested}

Wrist ROM was {full / limited} due to pain with {flexion / extension / radial deviation / ulnar deviation} on {R / L / BL} side(s)

Examination of the **Knee(s)** reveled {tenderness / crepitus /swelling / erythema} on the {Right / Left /Bilateral} side(s). In addition

- Lachman's / Anterior / Posterior Draw test was {negative / positive / not tested}
- McMurray's test was {negative / positive / not tested}

Knee ROM was {full / limited} due to pain with {flexion / extension}on {R / L / BL} side(s).

Examination of the **Ankle(s)** reveled {tenderness / crepitus /swelling / erythema} on the {Right / Left /Bilateral} side(s). In addition

- Talar Tilt/ Inversion / Eversion test was {negative / positive / not tested}
- Tinel's test at tarsal tunnel was {negative / positive / not tested}

Ankle ROM was {full / limited} due to pain with {dorsiflexion / plantarflexion / inversion / eversion} on
{R / L / BL} side(s).

ECN: 2024022002989 Received Date: 2024-02-19

Vascular Examination:

Pulse(s) were palpable on the {right / Left / Bilateral} side(s)
Extremity (ies) were {warm / cold}
Varicosities / Pigmentation(s) / Ulcer(s) in the extremity (ies) were {negative / Positive}

Neurological Examination:

Coordination exam revealed normal {rapid alternating movements / finger-to-nose / heel-to-shin / too walk/ heel walk / tandem walk}
Sensory Examination revealed {normal / abnormal} sensation(s) to {light touch / pinprick / proprioception / vibration / pain} at.

Manual Muscle Strength Test:

Shoulder(s):	R	L	Elbow(s):	R	L	Wrist(s):	R	L
Flexion	5/5	5/5	Flexion	5/5	5/5	Dorsiflexion	5/5	5/5
Extension	5/5	5/5	Extension	5/5	5/5	Palm flexion	5/5	5/5
Abduction	5/5	5/5				Hand(s):	R	L
						Grip	5/5	5/5
Hip(s):	R	L	Knee(s):	R	L	Ankle(s):	R	L
Flexion	5/5	5/5	Flexion	5/5	5/5	Dorsiflexion	5/5	5/5
Extension	5/5	5/5	Extension	5/5	5/5	Plantar flexion	5/5	5/5
Abduction	5/5	5/5				Toe(s):	R	L
						Flexion	5/5	5/5

Muscle Tendon Reflexes:

Upper	R	L	Lower	R	L
Biceps	+1	+1	Patellar knee	+1	+1
Brachioradialis	+1	+1	Achilles ankle	+1	+1
Tricep	+1	+1	Toes (vs.)	↓	↓

Functional Status:

Gait was {antalgic / ataxic / slow / normal}
Ambulation: Dependent / Assistant / Wheelchair / Walker / Cane / Independent

Diagnostic Test (s):

MRI of the Cervical Spine on 11-2-23 revealed disc bulge (s) at C6-C7, herniation(s) at (R) C5-C6, C3-C4
MRI of the Lumbar Spine on ____ revealed disc bulge (s) at ____, herniation(s) at ____
Other: ____

ECN: 2024022002989 Received Date: 2024-02-19

Impression: Patient Presented with:

- 84700-Cervical Posttraumatic sprain and strain syndrome
- 84702-Lumbar Posttraumatic sprain and strain syndrome
- 84701-Thoracic Posttraumatic sprain and strain syndrome
- 72534-R/O Posttraumatic Cervical radiculopathy due to mechanical injury.
- 72444-R/O Posttraumatic Lumbar radiculopathy due to mechanical injury.
- 78004-Post Concussion syndrome. Posttraumatic vertigo.
- 31008-Cephalgia, Posttraumatic
- 92211-Anterior chest wall (sternal) contusion.
- 72241- Thoracic Myofasciitis
- 30981-Posttraumatic Street Disorder
- 84409-R/L Shoulder Sprain
- 84449-R/L Knee Sprain
- 84200-R/L Wrist Sprain vs. CTS

Plan of Care:

- ☐ {EMG / NCS} of {upper / lower} extremities to r/o radiculopathy vs. neuropathy today
- ☐ {EMG / NCS} of {upper / lower} extremities to r/o radiculopathy vs. neuropathy to be scheduled for next visit
- ☐ No clinical indication for EMG / NCS at this time
- ☒ Continue clinical care
- ☒ Discussed {diagnosis / treatment plan / prognosis / MRI(s) / paperwork / other} with patient
- ☐ Follow-up with referring provider
- ☐ Follow-up for electrodiagnostic re-evaluation in: _____ day(s)

ALL ITEMS /SECTION IN THIS EVALUATION APPLY ONLY IF CICLED, MARKED, OR NOTED

Yours in Health,

X_____
Omar Ahmed, MD

Matthew Jordan, PA

ECN: 2024022002989 Received Date: 2024-02-19

14 Pages via SFTP Fri, 23 Feb 2024 04:16:57 GMT

BOULEVARD MEDICAL CARE, PC

6299 99TH STREET

REGO PARK, NY 11374

Test Date: 1/19/2024

Patient:	BROWN, KEVIN	**DOB:**	7/6/1987	**Physician:**	OMAR AHMED, MD
ID#:		**SEX:**	Male	**Ref. Phys:**	

MEDICAL NECESSITY: The patient's symptoms and neurological signs raise the possibility of the peripheral nervous system (nerve root, peripheral nerve) injury (irritation, compression, stretching). Neurophysiologic testing is intended to clarify this clinical suspicion and differentiate spinal nerve root lesion from peripheral nerve lesion. Abnormal NCV & EMG correlate with less favorable prognosis of recovery and are helpful in further clinical management. If there is diffuse denervation, prognosis of functional recovery is unfavorable. But if there are no signs of denervation, the prognosis is more favorable.

Nerve Conduction Studies

Motor Summary Table

Site	NR	Onset (ms)	Norm Onset (ms)	O-P Amp (mV)	Norm O-P Amp	Site1	Site2	Delta-0 (ms)	Dist (cm)	Vel (m/s)	Norm Vel (m/s)
Left Median Motor (Abd Poll Brev)											
Wrist		3.9	<4.2	8.6	>5.0	Elbow	Wrist	5.2	28.0	54	>50.0
Elbow		9.1		7.5	>5.0						
Right Median Motor (Abd Poll Brev)											
Wrist		3.9	<4.2	8.6	>5.0	Elbow	Wrist	4.7	28.0	60	>50.0
Elbow		8.6		8.7	>5.0						
Left Ulnar Motor (Abd Dig Minimi)											
Wrist		2.8	<4.2	9.9	>3.0	Elbow	Wrist	4.9	26.0	53	>53.0
Elbow		7.7		9.4	>3.0						
Right Ulnar Motor (Abd Dig Minimi)											
Wrist		3.0	<4.2	7.9	>3.0	Elbow	Wrist	4.2	26.0	62	>53.0
Elbow		7.2		4.8	>3.0						

Sensory Summary Table

Site	NR	Peak (ms)	Norm Peak (ms)	P-T Amp (µV)	Norm P-T Amp	Site1	Site2	Delta-0 (ms)	Dist (cm)	Vel (m/s)	Norm Vel (m/s)
Left DorsCutan Sensory (Dorsum 5th MC)											
Wrist		2.9	<2.7	13.1	>10.0	Wrist	Dorsum 5th MC	2.0	12.0	60	>45.0
Right DorsCutan Sensory (Dorsum 5th MC)											
Wrist	NR		<2.7		>10.0	Wrist	Dorsum 5th MC		12.0		>45.0
Left Median D2 Sensory (2nd Digit)											
Wrist		4.2	<3.6	38.1	>10.0	Wrist	2nd Digit	3.3	14.0	42	>39.0
Palm		2.1		33.8	>10.0	Palm	2nd Digit	0.9	7.0	78	
						Wrist	Palm	2.4	7.0	29	
Right Median D2 Sensory (2nd Digit)											
Wrist		4.6	<3.6	30.0	>10.0	Wrist	2nd Digit	3.6	14.0	39	>39.0
Palm		2.3		21.8	>10.0	Palm	2nd Digit	1.4	7.0	50	
						Wrist	Palm	2.2	7.0	32	
Left Radial Sensory (Base 1st Digit)											
Wrist		3.3	<2.7	20.1	>10.0	Wrist	Base 1st Digit	2.1	10.0	48	>45.0
Right Radial Sensory (Base 1st Digit)											
Wrist		2.9	<2.7	15.5	>10.0	Wrist	Base 1st Digit	2.0	10.0	50	>45.0
Left Ulnar Sensory (5th Digit)											
Wrist		3.3	<3.7	27.1	>15.0	Wrist	5th Digit	2.5	14.0	56	>45.0
Right Ulnar Sensory (5th Digit)											
Wrist		3.6	<3.7	28.6	>15.0	Wrist	5th Digit	0.9	14.0	156	>45.0

F Wave Studies

NR	F-Lat (ms)	Lat Norm (ms)	L-R F-Lat (ms)	L-R Lat Norm
Left Median (Mrkrs) (Abd Poll Brev)				
	20.00	<33	0.00	<2
Right Median (Mrkrs) (Abd Poll Brev)				
	20.00	<33	0.00	<2
Left Ulnar (Mrkrs) (Abd Dig Min)				
	25.28	<36	0.00	<2
Right Ulnar (Mrkrs) (Abd Dig Min)				
	25.28	<36	0.00	<2

EMG

Side	Muscle	Nerve	Root	Ins Act	Fibs	Psw	Amp	Dur	Poly	Recrt	Int Pat	Comment
Right	Biceps	Musculocut	C5-6	Nml	0	0	Nml	Nml	0	Nml	Complete	
Right	Triceps	Radial	C6-7-8	Nml	0	0	Nml	Nml	0	Nml	Complete	
Right	Deltoid	Axillary	C5-6	Nml	0	0	Nml	Nml	0	Nml	Complete	
Right	FlexCarRad	Median	C6-7	Nml	0	0	Nml	Nml	0	Nml	Complete	
Left	Biceps	Musculocut	C5-6	Nml	0	0	Nml	Nml	0	Nml	Complete	
Left	Triceps	Radial	C6-7-8	Nml	0	0	Nml	Nml	0	Nml	Complete	
Left	Deltoid	Axillary	C5-6	Nml	0	0	Nml	Nml	0	Nml	Complete	
Left	FlexCarRad	Median	C6-7	Nml	0	0	Nml	Nml	0	Nml	Complete	

Paraspinal EMG

Side	Muscle	Nerve	Root	Ins Act	Fibs	Psw	Comment
Right	C3-4 Parasp	Rami	C3-4	Nml	0	0	
Right	C4-5 Parasp	Rami	C4-5	Nml	0	0	
Right	C5-6 Parasp	Rami	C5-6	Nml	0	1+	
Right	C6-7 Parasp	Rami	C6-7	Nml	0	0	
Left	C3-4 Parasp	Rami	C3-4	Nml	0	1+	
Left	C4-5 Parasp	Rami	C4-5	Nml	0	0	
Left	C5-6 Parasp	Rami	C5-6	Nml	0	0	
Left	C6-7 Parasp	Rami	C6-7	Nml	0	0	

FINDINGS: Evaluation of the Left dorsal cutaneous sensory, the Left median (digit 2) sensory, the Right median (digit 2) sensory, the Left radial sensory, and the Right radial sensory nerves showed prolonged distal peak latency (L2.9, L4.2, R4.6, L3.3, R2.9 ms). The Right dorsal cutaneous sensory nerve showed no response (Wrist). All remaining nerves (as indicated in the following tables) were within normal limits.

All F Wave latencies were within normal limits.

All examined muscles (as indicated in the following table) showed no evidence of electrical instability.

IMPRESSIONS: The above electrodiagnostic study reveals evidence of right C5 - C6 and left C3 - C4 radiculopathies. Also, the electrodiagnostic study reveals evidence of a bilateral sensory median nerve neuropathy at the wrist. This is consistent with the clinical diagnosis of Carpal Tunnel Syndrome. In addition, the electrodiagnostic study reveals evidence sensory peripheral neuropathy affecting the upper extremities.

OMAR AHMED, MD

MATTHEW JORDAN, PA

Waveforms:

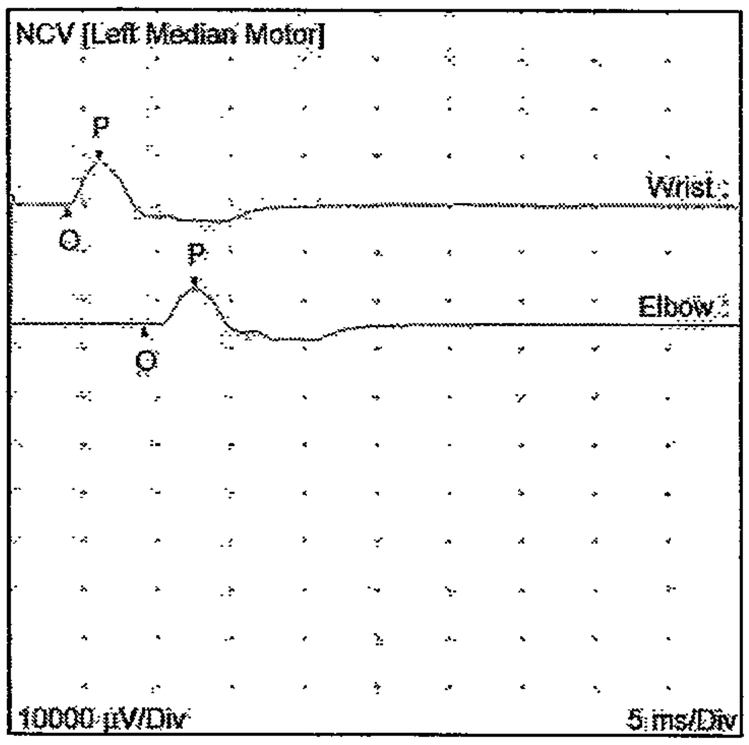
NCV [Left Median Motor]
P
O
Wrist :
P
O
Elbow :
10000 µV/Div
5 ms/Div

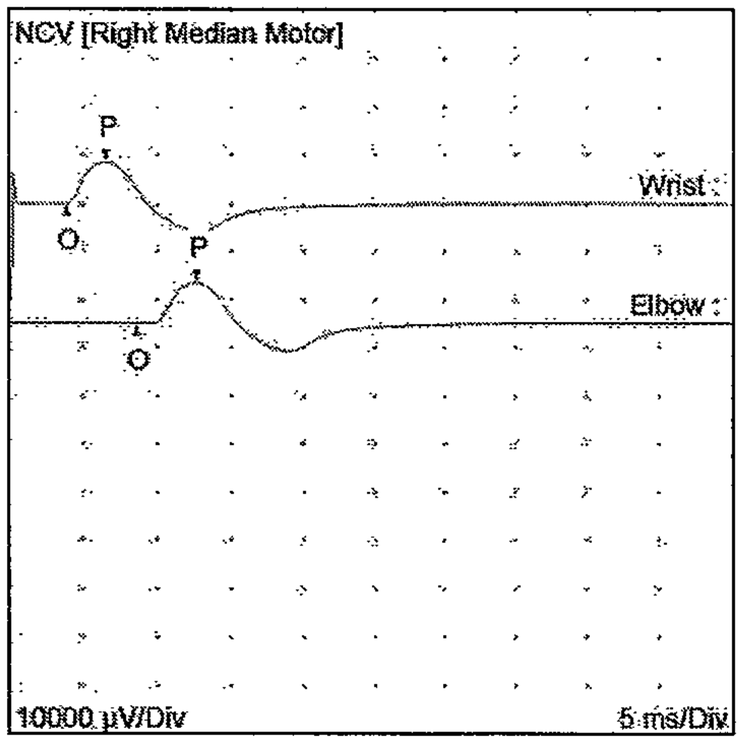
NCV [Right Median Motor]
P
O
Wrist :
P
O
Elbow :
10000 µV/Div
5 ms/Div

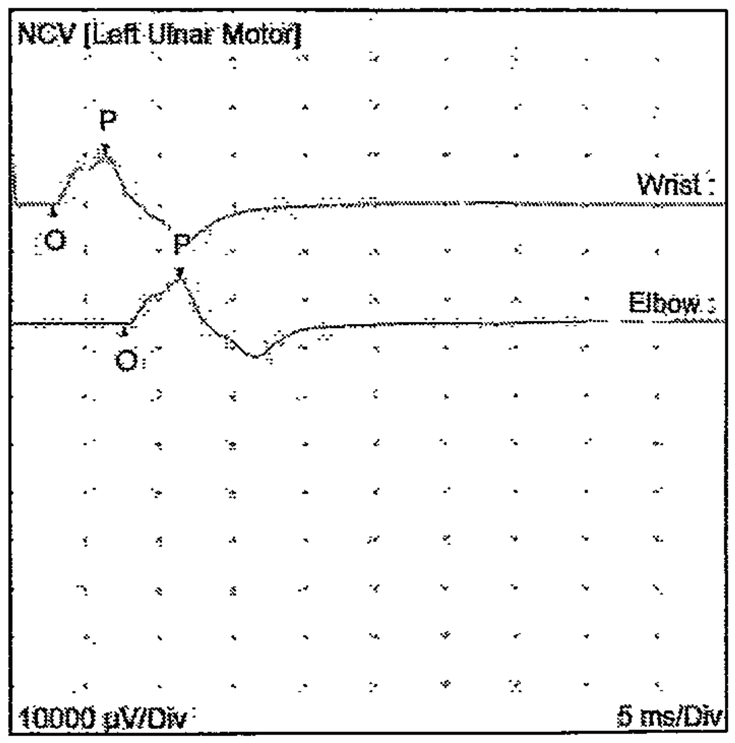
NCV [Left Ulnar Motor]
P
O
Wrist :
P
O
Elbow :
10000 µV/Div
5 ms/Div

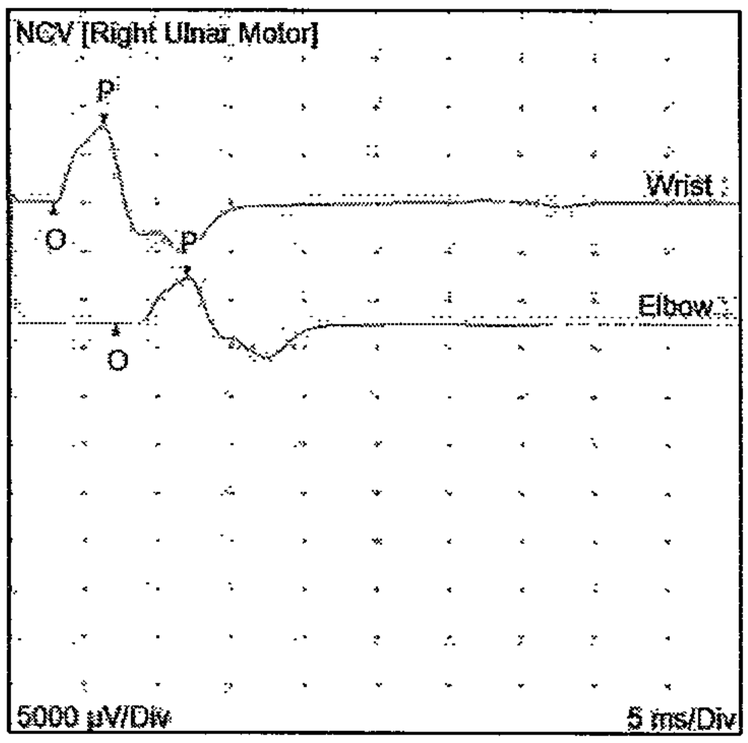
NCV [Right Ulnar Motor]
P
O
Wrist :
P
O
Elbow :
5000 µV/Div
5 ms/Div

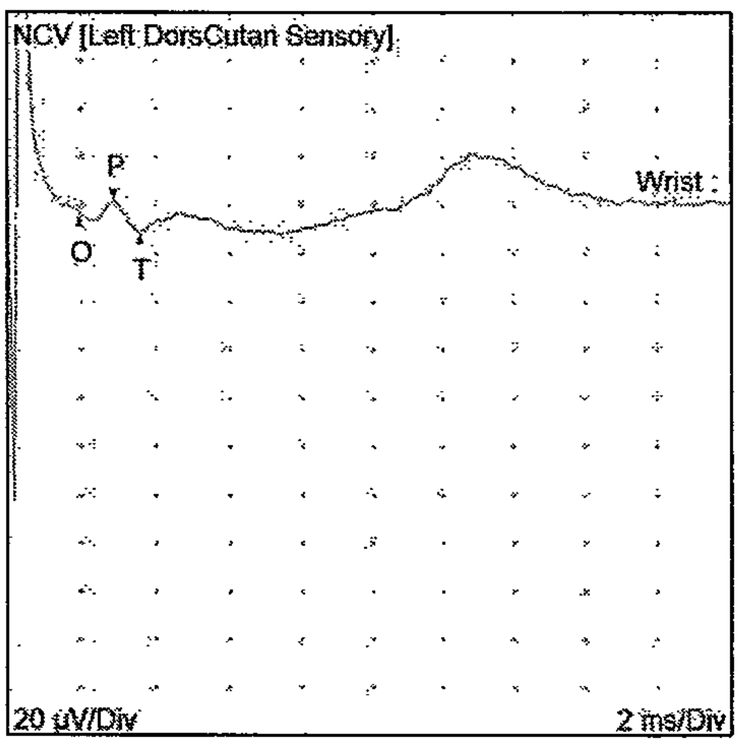
NCV [Left DorsCutan Sensory]
P
O
T
Wrist :
20 µV/Div
2 ms/Div

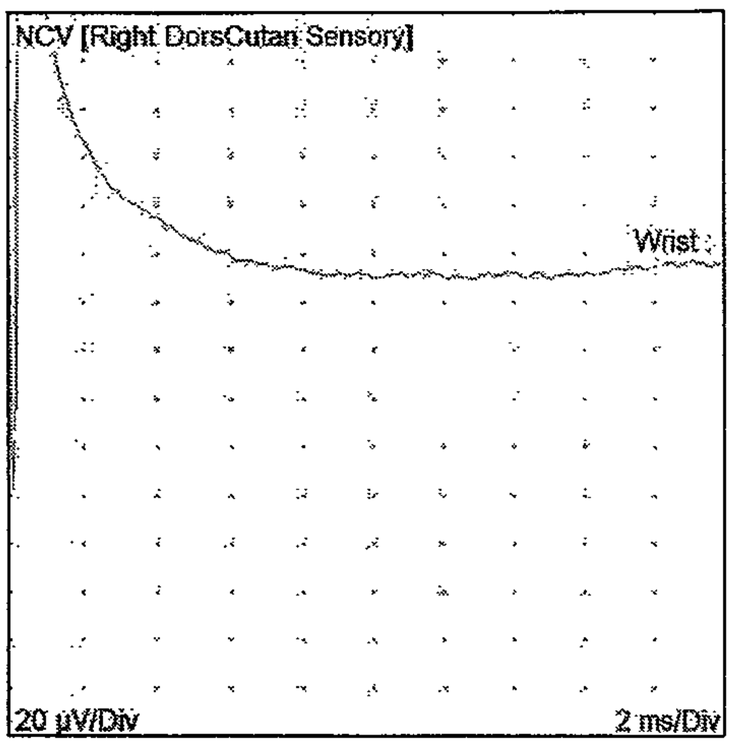
NCV [Right DorsCutan Sensory]
Wrist :
20 µV/Div
2 ms/Div

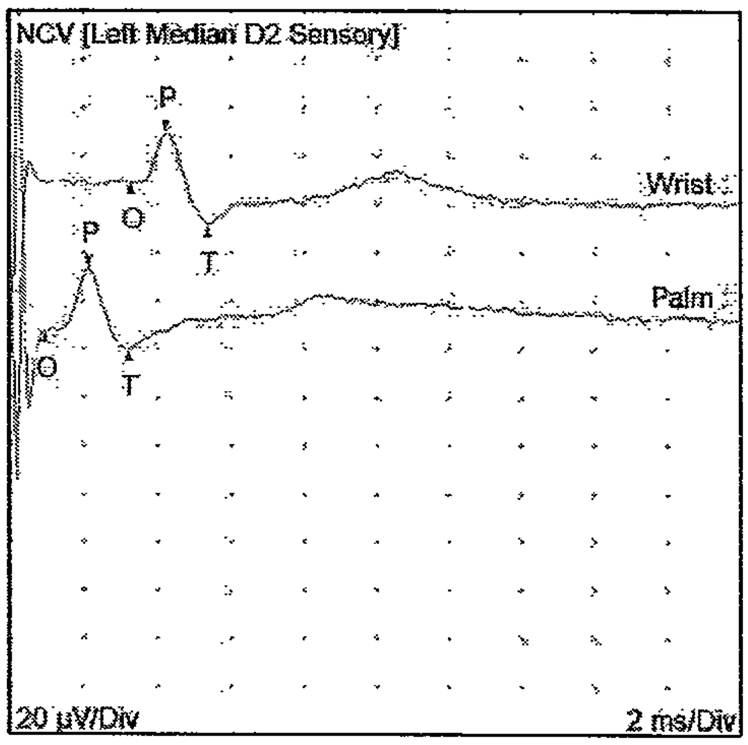
NCV [Left Median D2 Sensory]
P
O
T
Wrist :
P
O
T
Palm :
20 µV/Div
2 ms/Div

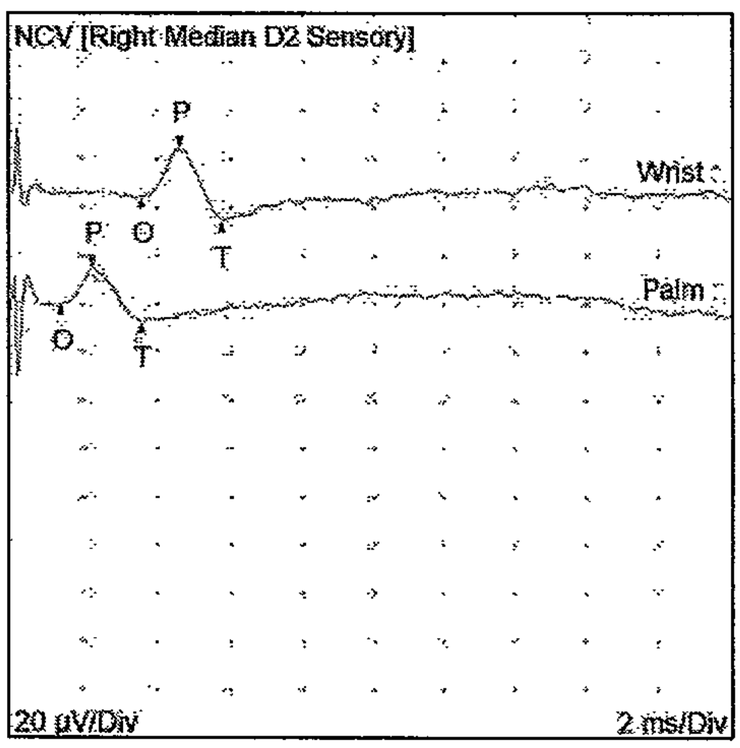
NCV [Right Median D2 Sensory]
P
O
T
Wrist :
P
O
T
Palm :
20 µV/Div
2 ms/Div

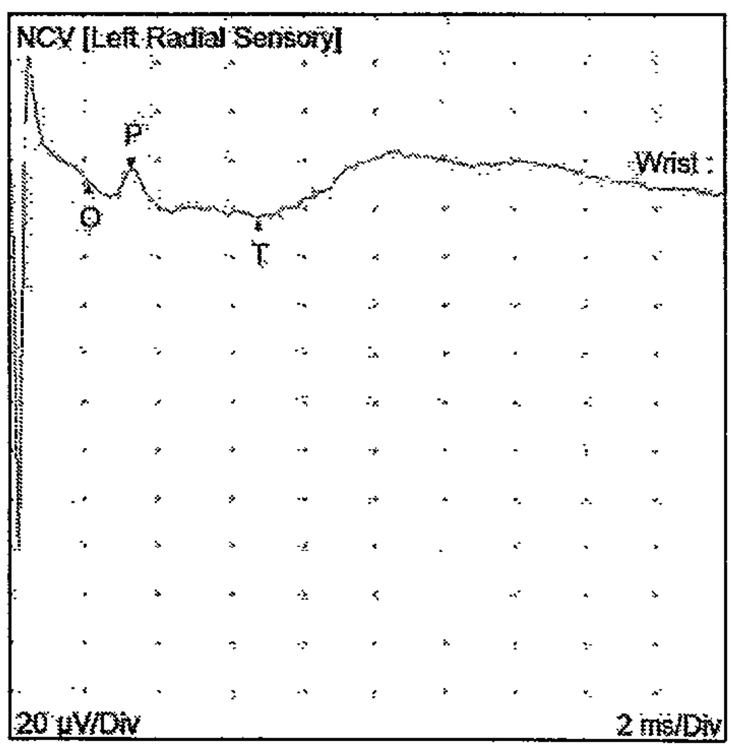
NCV [Left Radial Sensory]
P
O
T
Wrist :
20 µV/Div
2 ms/Div

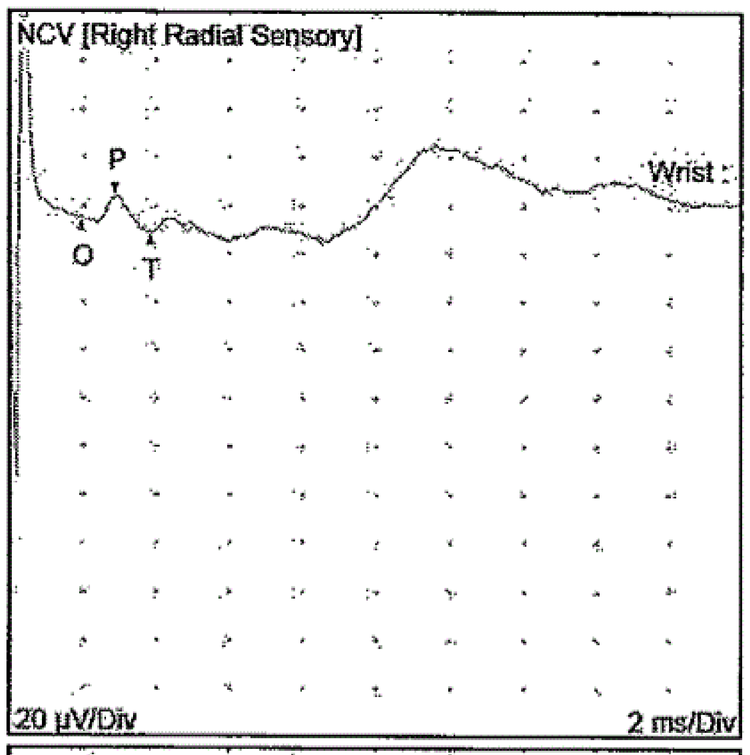
NCV [Right Radial Sensory]
P
O
T
Wrist
20 µV/Div
2 ms/Div

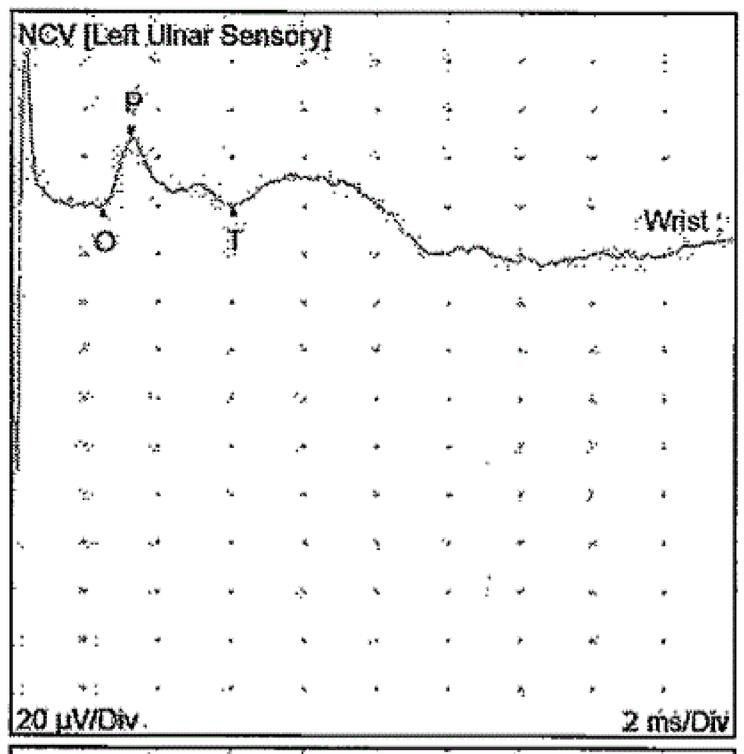
NCV [Left Ulnar Sensory]
P
O
T
Wrist
20 µV/Div
2 ms/Div

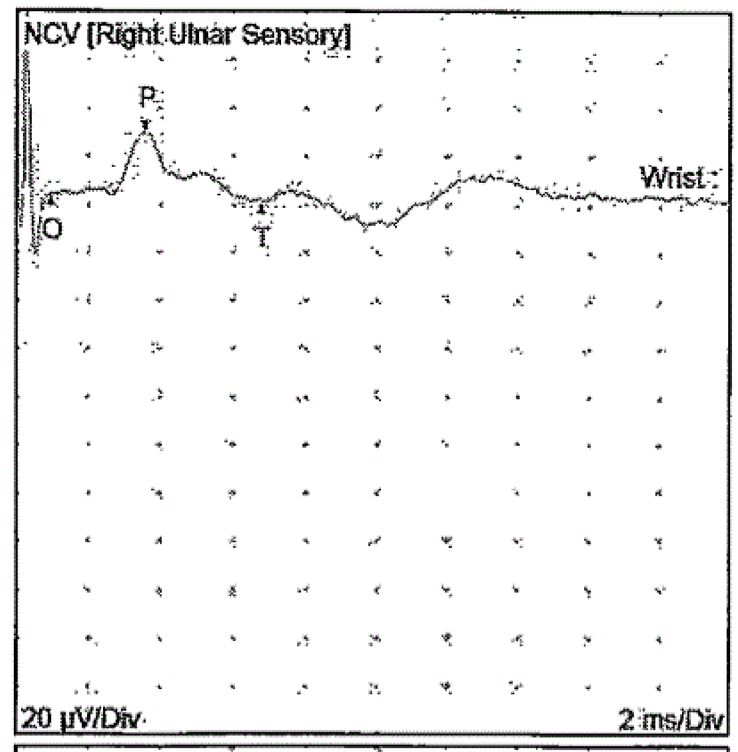
NCV [Right Ulnar Sensory]
P
O
T
Wrist
20 µV/Div
2 ms/Div

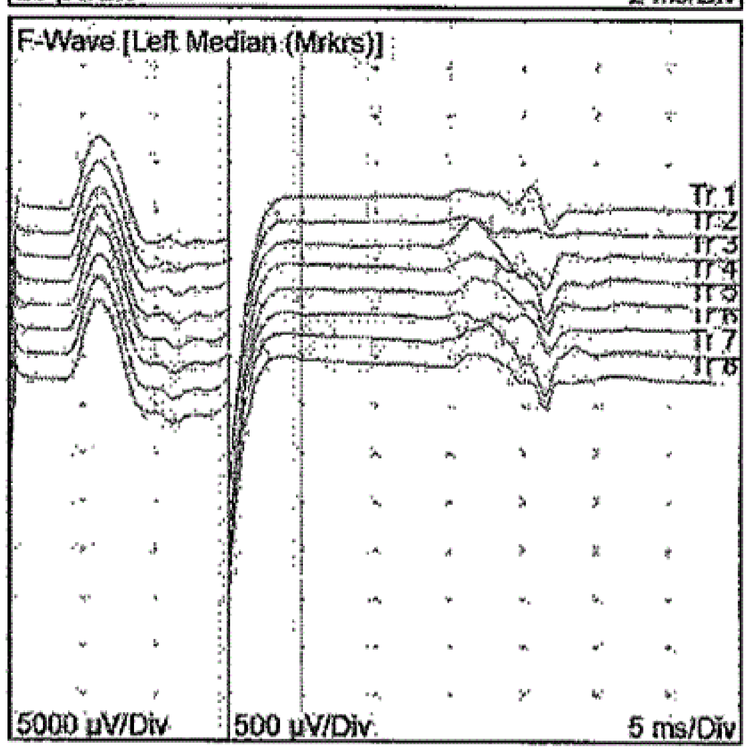
F-Wave [Left Median (Mrkrs)]
Tr 1
Tr 2
Tr 3
Tr 4
Tr 5
Tr 6
Tr 7
Tr 8
5000 µV/Div
500 µV/Div
5 ms/Div

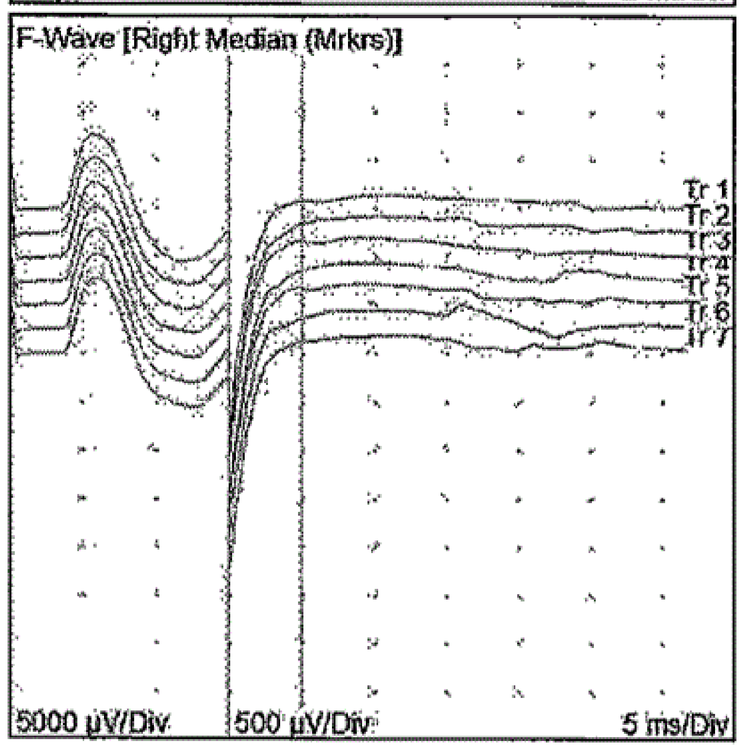
F-Wave [Right Median (Mrkrs)]
Tr 1
Tr 2
Tr 3
Tr 4
Tr 5
Tr 6
Tr 7
5000 µV/Div
500 µV/Div
5 ms/Div

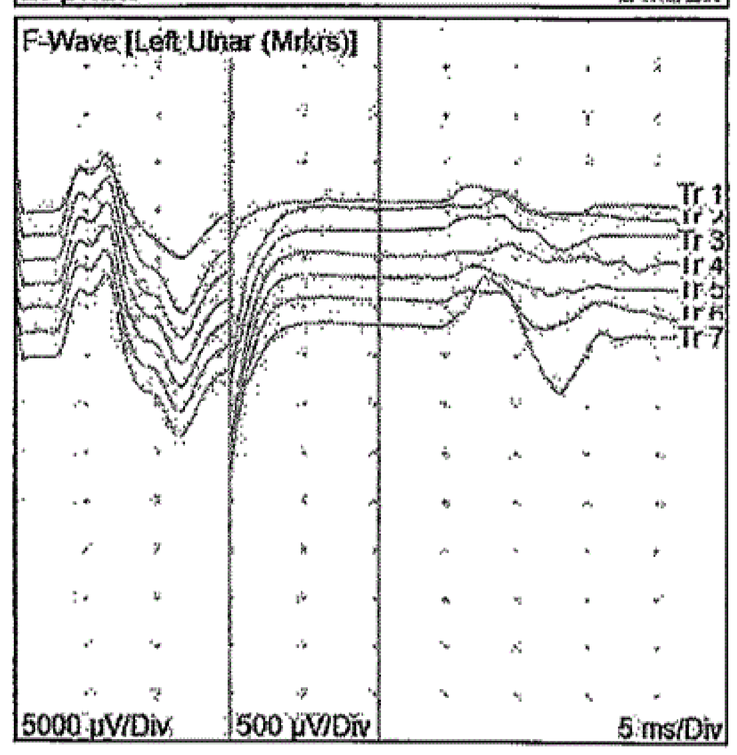
F-Wave [Left Ulnar (Mrkrs)]
Tr 1
Tr 2
Tr 3
Tr 4
Tr 5
Tr 6
Tr 7
5000 µV/Div
500 µV/Div
5 ms/Div

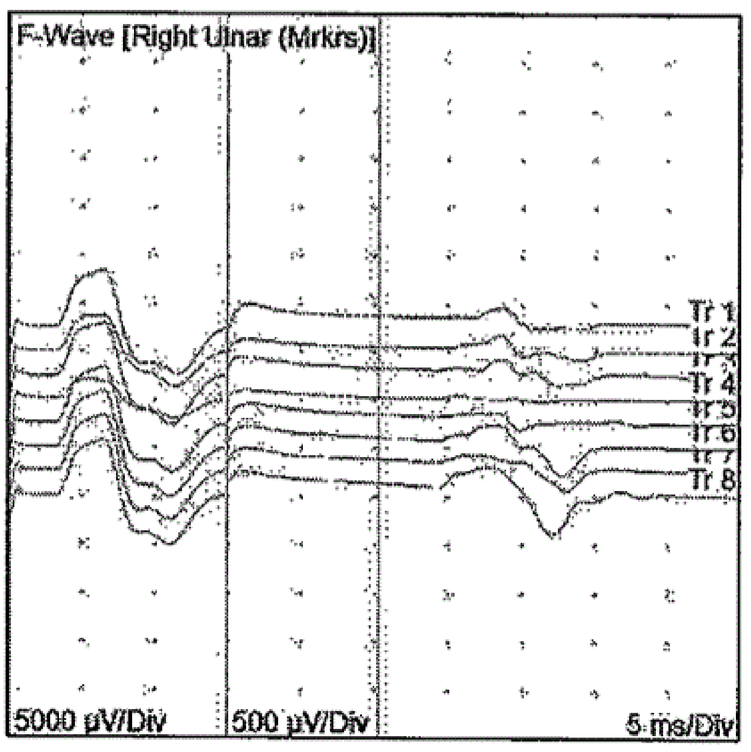
F-Wave [Right Ulnar (Mrkrs)]
Tr 1
Tr 2
Tr 4
Tr 5
Tr 6
Tr 8
5000 µV/Div
500 µV/Div
5 ms/Div

Farrockaway Medical PC
62-69 99th St
Rego Park, NY 11374

nyregoparkmedical@gmail.com

INITIAL EXAMINATION REPORT

Date: 10/16/23 D.O.A: 10/13/23

HISTORY OF PRESENT CONDITIONS

(Mr) Ms. Kevin Brown is a 36 year old (M) F, who was involved in an accident, the details of the accident have been discussed with the patient. According to the information presented by the patient ~~he~~ she was in a regular state of good health and was capable of living on an equal basis with others of his her age, before ~~he~~ she was involved in a ~~motor~~ vehicle slip and fall work related accident, when all of ~~his~~ her symptoms began. The patient was the driver, passenger of the front back seat of the vehicle with without the seat belt pedestrian at the accident. Due to accident he she has has not been able to work as of I've only missed 1½ days

AS A RESULT OF THE IMPACT THE PATIENT SUSTAINED INJURIES TO:

Head	Sacral Area	Hip {} RT {} LT
Face	Pelvis	Knee {} RT {} LT
~~Neck~~	Shoulder {} RT {} LT	~~Ankle~~ {} RT {} LT
Chest	Elbow	Foot {} RT {} LT
Thoracic Spine	Wrist {} RT {} LT	Abdomen {} RT {} LT
(Lower Back)	Hand {} RT {} LT	Other: _____

Patient developed laceration wound ~~bruise~~ on Neck.

Patient reported loss of consciousness for approximately _____ no loss of consciousness.

Patient was/was not treated by emergency crew at the scene of the accident and was/was not brought to the emergency room of the _____ hospital by the ambulance friend went by himself herself on the same day next day.

Patient was/was not evaluated in the emergency room where x-rays were/were not taken.

Patient reported evidence of fracture or dislocation were demonstrated.

Patient left before evaluation was completed.

Sutures dressing were placed on patient's wound abrasions

Patient was hospitalized for _____

Primary care physician treated patient.

Patient was treated himself herself with analgesics with mild effect and decided to start physical therapy.

Outcome Assessment results discussed thoroughly with patient

ECN: 2023112010569 Received Date: 2023-11-20

CURRENT CHIEF COMPLAINTS AND REVIEW OF THE SYSTEM

Constant Intermittent headaches temporal bi-temporal occipital diffuse frontal area.

Dizziness Vertigo Blurred vision

Nausea Vomiting Tinnitus Hearing Loss

Constant Intermittent posterior neck pain and stiffness with radiation to

Constant Intermittent anterior chest wall.

Difficulty breathing with chest discomfort.

Nervousness Anxiety Fears Irritability Tense

PREVIOUS MEDICAL /SURGICAL HISTORY

Negative DM HTN CAD OA Other _____

Patient states he she had did not have a MVA in the past. Zero Neighing

Patient denies admits to have an indwelling metal in body.

Pregnant: Yes No N/A LMP: __/__/____

FAMILY AND SOCIAL HISTORY:

Noncontributory Smoking: Yes No Alcohol: Yes No

Other: _____

MEDICATION:

No Medication Tylenol Ibuprofen

Other: _____

ALLERGIES:

No Allergies Allergic to _____

PHYSICAL EXAMINATION REVEALED

BP ___/___ Pulse _____ BPM Regular Irregular RR_____

Afebrile Febrile

PHYSICAL EXAM

GENERAL APPEARANCE

Well-developed and well nourished 32 year old M F AAOX, normocephalic, no neck masses, no bruits, ear canals are clear, no oropharyngeal erythema. Heart with normal S2 regular sounds. Lungs are clear to auscultation bilaterally. Abdomen with good bowel sounds without guarding, rigidity or rebound, no clubbing or cyanosis noticed on the extremities, Pulses present bilaterally are present. No gross deformities or focal deficits are noticed.

Patient appears to be in mild moderate severe distress due to pain and discomfort of Neck & Jaw Pain

There are bruises wounds scars on: _____

Pain and tenderness in low occipital area upon palpation.

TMJ exam reveals crepitus and tenderness on right left.

MENTAL ILLNESS:

Patient is alert, awake oriented to person, time and place.

Normal affect, speech and attention span.

Serial 7's and simple words spelling backwards is normal.

Memory, both short and long appear normal.

Other: _____

SPINAL COLUMN EXAM

CERVICAL SPINE

Palpation of neck reveals does not reveal mild moderate severe cervical spine tenderness at the C__-C__ level. No step off appreciated.

Increase in right left muscle tone ION Paravertebral Trapezious Rhomboid muscles.

Normal examination of the cervical spine

SPECIAL TEST AND SIGNS:

Distraction Test	Positive	Negative
Compression Test	Positive	Negative
Shoulder Depression Test	Positive	Negative
Foraminal Compression Test	Positive	Negative

NORMAL ROM	PATIENT'S ROM	PAIN		
Flexion	45	From	↓ROM	Positive
Extension	55	From	↓ROM 20	Positive
Right Rotation	70	From	↓ROM 50	Positive
Left Rotation	70	From	↓ROM	Positive
Right Lateral Flexion	40	From	↓ROM 20	Positive
Left Lateral Flexion	40	From	↓ROM	Positive

THORACIC SPINE:

There appears to be tenderness of the thoracic spine at the T__-T__ with spasms of right left paraspinal structures.

There is no tenderness or pain on palpation.

LUMBOSACRAL SPINE:

Palpation of lumbar sacral spine reveals does not reveal mild moderate severe tenderness at the L__-L__ S__ level.

Increase in right left paravertebral muscle tone.

Normal examination of the lumbar sacral spine.

SPECIAL TEST AND SIGNS:

Spinal Percussion Test	Positive	Negative
Faber-Patrick Test	Positive	Negative
Straight Leg Raise Test	Positive @___° on the RT,@___° on the LT	Negative

	NORMAL ROM	PATIENT'S ROM		PAIN
Flexion	90	From	↓ROM	Positive
Extension	30	From	↓ROM	Positive
Right Rotation	30	From	↓ROM 15	Positive
Left Rotation	30	From	↓ROM 15	Positive
Right Lateral Flexion	35	From	↓ROM 15	Positive
Left Lateral Flexion	35	From	↓ROM 15	Positive

CHEST:

Pain and tenderness in sternum area and ribs with without deep breathing or coughing, with without palpation.

No tenderness on palpation, no gross deformity.

EXTREMITIES:

Examination of the extremities reveals tenderness over the _____ and crepitus is noticed upon manipulation of the area.

Active and passive movements are restricted and painful on palpation of the _____.

There is edema of right left medial lateral _____.

There is no apparent swelling or discoloration.

All areas of the peripheral pulses are palpated and normal limits.

Other _____

ECN: 2023112010569 Received Date: 2023-11-20

SHOULDERS	NORMAL ROM	PATIENT'S ROM	RIGHT	LEFT
Flexion/Elevation	180	From ↓ROM____	____	____
Extension	50	From ↓ROM____	____	____
Abduction	180	From ↓ROM____	____	____
Adduction	50	From ↓ROM____	____	____
Internal Rotation	90	From ↓ROM____	____	____
External Rotation	90	From ↓ROM____	____	____

Crepitus appreciated on right left subacromal /subdaltoid bursa.

Able unable to elevate and hold right left arm above shoulder level.

Tenderness at crepitus at ac joint at level of rotator cuff insction (Ligaments of sit muscles)

ELBOWS	NORMAL ROM	PATIENT'S ROM	RIGHT	LEFT
Flexion	160	From ↓ROM____	____	____
Extension	180	From ↓ROM____	____	____
Supination	90	From ↓ROM____	____	____
Pronation	90	From ↓ROM____	____	____

Crepitus is appreciated right left

WRIST	NORMAL ROM	PATIENT'S ROM	RIGHT	LEFT
Flexion	160	From ↓ROM____	____	____
Extension	180	From ↓ROM____	____	____
Supination	90	From ↓ROM____	____	____
Pronation	90	From ↓ROM____	____	____

Crepitus is appreciated right left

HIPS	NORMAL ROM	PATIENT'S ROM	RIGHT	LEFT
Flexion	120	From ↓ROM____	____	____
Extension	15	From ↓ROM____	____	____
Abduction	45	From ↓ROM____	____	____
Adduction	30	From ↓ROM____	____	____
Internal Rotation	40	From ↓ROM____	____	____
External Rotation	45	From ↓ROM____	____	____

Crepitus is appreciated RT LT

ECN: 2023112010569 Received Date: 2023-11-20

KNEES	NORMAL ROM	PATIENT'S ROM	RIGHT	LEFT
Flexion	130	From ↓ROM____	____	____
Extension	15	From ↓ROM____	____	____

Crepitus is appreciated right left

Bulge/ Balloting sign of patella is is not present on right left

Anterior draws sign is positive negative on right left

Lachman test is positive negative on right left

Varus stress detecting mcl is positive negative

Valgus stress test detecting LCL is positive negative

ANKLES	NORMAL ROM	PATIENT'S ROM	RIGHT	LEFT
Dorsi Flexion	20	From ↓ROM____	____	____
Planter Extension	45	From ↓ROM____	____	____
Inversion	30	From ↓ROM____	____	____
Eversion	20	From ↓ROM____	____	____

Crepitus is appreciated Right Left

Swelling/Edma is appreciated Right Left Medial Lateral Malleoli

NEUROLOGICAL EXAMINATION

CRANINAL NERVES EXAMINATION

Olfaction is intact. Pupils are equal and reactive to light and accommodation exrtaocular movements are intact and no nystagmus noted. Facial movement, smile nasolabial fold are symmetric and facial sensation is intact. Jaw closure and opening appears symmetric, tongue protrudes and midline, soft palate is elevated and uvula is midline. Hearing is preserved. Gag reflex is reserved. Swallowing is preserved. Stenocleidomastoid and trapezius muscles are strong bilaterally. No pronator drift.

COORDINATION EXAM:

Normal finger-to-nose and heel-to-sheen exam. Follows rapid hand alteration movements well, both with closed eyes. Normal gait and heel-to-tandem, no ataxia and no shuffling. Romberg's test is Negative Positive

ECN: 2023112010569 Received Date: 2023-11-20

MOTOR SYSTEMS:

Motor muscles test are _____ throughout.

No muscle atrophy is noted.

Deep tendon reflexes are bilaterally equal and symmetric DTR's are _____ throughout.

Toes are down going bilaterally.

There is muscle atrophy noted at _____

Deep tendon reflexes are as follows:

Babinski's reflex is Positive Negative

REFLEX	RIGHT	LEFT
Biceps		
Triceps		
Brachioradials		
Knee Jerk		
Ankle Jerk		

RECOMMENDATIONS

After the examination, the patient was advised that because of the sustained injuries no heavy work should be performed until next evaluation. Based upon the subjective complaints and medical evaluation of objective findings, the following test are indicated:

X-ray (S) of the _____

MRI/CT scan of the brain to rule out intracacial pathology or subdural hematoma.

Referral for MRI/CT scan of the _____ to rule out ligament tear.

Referral for MRI/CT scan of the cervical spine to rule out discogenic injury.

Referral for MRI/CT scan of lumbarsacral spine rule out discogenic injury.

Physical therapy evaluation and treatment.

Chiropractic evaluation for adjustment of spinal injury.

Acupuncturist evaluation for treatment and pain control.

Neurologist/Physiatrist consultation to rule out:

Cervical Lumbar Radiculapathy

Physiatrist consultation to aid and resolve post-concussion syndrome.

Orthopedic consultation for treatment and diagnosis of the ligamentous tear or other bone or joint related problems.

Other _____

TREATMENT PLAN

ECN: 2023112010569 Received Date: 2023-11-20

A treatment plan was proposed and discussed with patient. Medical treatment for the patient consist of analgesics _____

The patient was advised to see a Chiropractor and an acupuncturist. The patient was advised to attend physical therapy program at a frequency of _____ times per week for the first four weeks, until next, until next evaluation. Physical therapy will consist of various modalities such as thermo therapy (Hot/Cold Pack), electrotherapy and electric stimulation, cervical traction manipulation therapy, assisted active and passive range of motion exercises for injured areas. Additional treatment protocol was outlined with the patient being instructed for specific every day home exercise additional therapeutic equipment such as _____ has been prescribed for patient's home use to support treatment. The patient agreed to therapy plan proposed as recommended.

CASUALTY

On the basis of medical history presented by the patient and the physical examination findings, it is in my opinion to reasonable degree of medical certainty, that the condition described above is related to the above-mentioned incident.

Patient will be re-evaluated in _____ weeks.

PROGNOSIS

The possibility of this condition becoming permanent cannot be ruled out at this time because of the severity of the symptoms, the patient is somewhat limited in activities of daily living, as a result of the traumatic injury there were extreme of joint movement with concomitant stretching and tearing of the musculo-ligament structures of _____

It appears that these areas may be permanently weakened for an indefinite period of time resulting in significant and permanent restricted mobility.

Respectfully Submitted,

Jean-Pierre Georges Barakat, MD
Internal Medicine

DOCTOR'S NOTES AND COMMENTS

RIGHT FRONT BACK LEFT

ECN: 2023112010569 Received Date: 2023-11-20

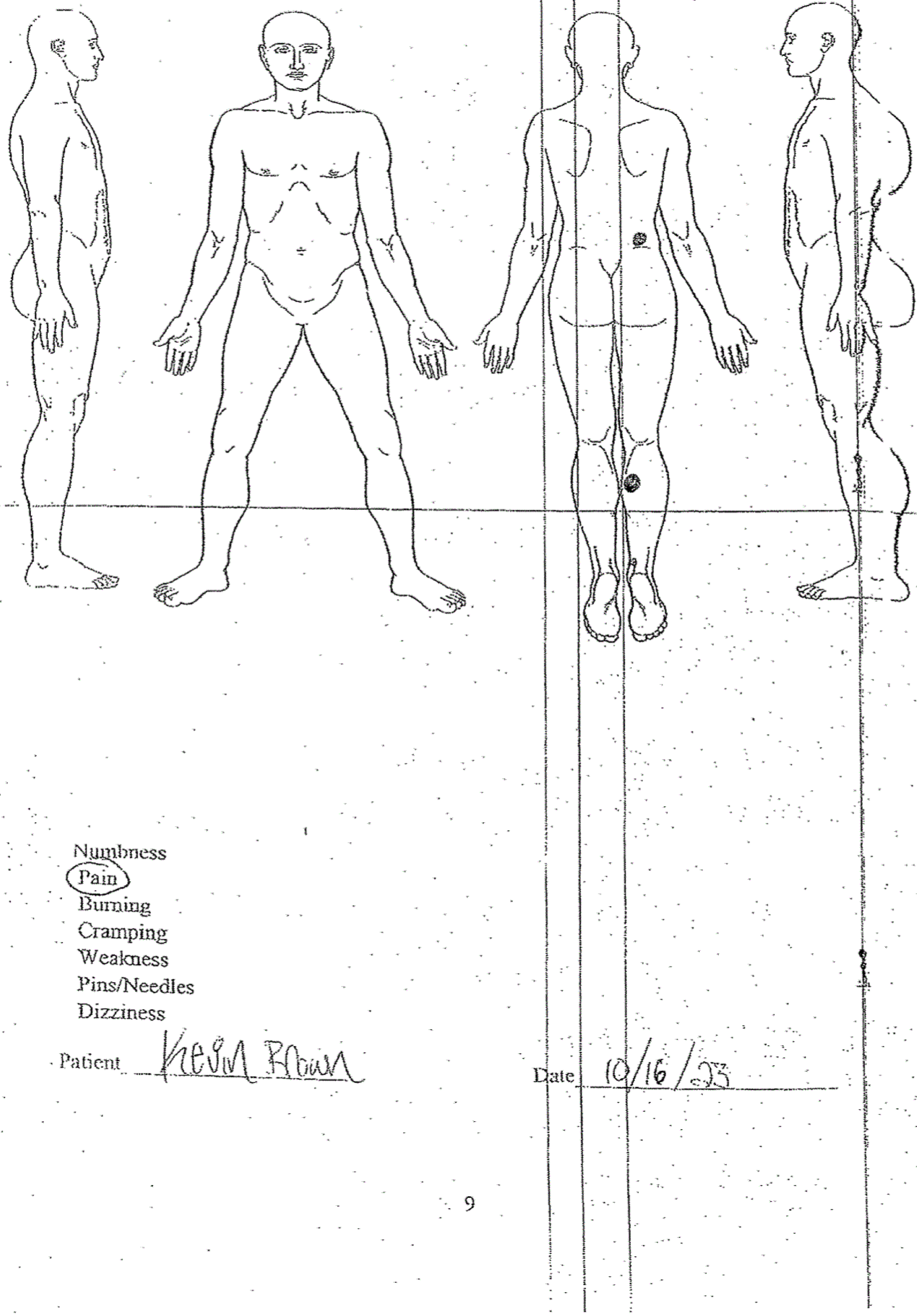

Numbness
Pain
Burning
Cramping
Weakness
Pins/Needles
Dizziness

Patient Kevin Brown

Date 10/16/23

ECN: 2023112010569 Received Date: 2023-11-20

	CERVICAL SPINE DX		HIPS
M54.2	CERVICALGIA	M25.551	PAIN IN RIGHT HIP
S13.4XA	SPRAIN OF LIGAMENTS OF C/S - IE	M25.552	PAIN IN LEFT HIP
S13.8XA	SPRAIN OF JOINTS & LIGAMNETS OF OTHER PARTS OF NECK, IE	S73.101A	UNSPECIFIED SPRAIN OF RIGHT HIP, IE
S13.6XA	STRAIN OF MUSCLE, FASCIA AND TENDON AT NECK LEVEL, IE	S73.102A	UNSPECIFIED SPRAIN OF LEFT HIP, IE
M54.11	RADICULOPATHY, OCCIPITO-ATLANTO-AXIAL REGION		KNEES
M54.12	RADICULOPATHY, CERVICAL REGION	M25.561	PAIN IN RIGHT KNEE
M54.13	RADICULOPATHY, CERVICOTHORACIC REGION	M25.562	PAIN IN LEFT KNEE
M50.20	OTHER CERVICAL DISC DISPLACEMENT, UNSP. CERVICAL REG.	S83.90XA	SPRAIN OF UNSPECIFIED SITE OF RIGHT KNEE, IE
M50.21	OTHER CERVICAL DISC DISPLACEMENT, HIGH CERVICAL REGION	S83.93XA	SPRAIN OF UNSPECIFIED SITE OF LEFT KNEE, IE
M50.22	OTHER CERVICAL DISC DISPLACEMENT, MID-CERVICAL REGION	S80.03XA	CONTUSION OF RIGHT KNEE, IE
M50.23	OTHER CERVICAL DISC DISPLACEMENT, CERVICOTHORACIC	S80.02XA	CONTUSION OF LEFT KNEE, IE
M99.00	SEGMENTAL & SOMATIC DYSFUNCTION OF CERVICAL REGION	S83.206A	UNSP TEAR, OF UNSP MENISCUS, CURRENT INJ, RIGHT KNEE, I
M79.1	MYALGIA	S83.207A	UNSP TEAR, OF UNSP MENISCUS, CURRENT INJ, LEFT KNEE, IE
	THORACIC SPINE DX		ANKLE/FOOT
M54.6	PAIN IN THORACIC SPINE	S93.401A	SPRAIN OF UNSPECIFIED LIGAMENT OF RIGHT AN
S23.5XXA	SPRAIN OF LIGAMENTS OF THORACIC SPINE, IE	S93.402A	SPRAIN OF UNSPECIFIED LIGAMENT OF LEFT ANK
S29.0XXA	SPRAIN OF OTHER SPECIFIED PARTS OF THORAX, IE	M25.571	PAIN IN RIGHT ANKLE & JOINTS OF RIGHT FOOT
M51.24	INTERVERTEBRAL DISC DISORDER WITH RADIC, THORACIC REG	M25.572	PAIN IN LEFT ANKLE & JOINTS OF LEFT FOOT
M51.25	INTERVERTEBRAL DISC DISORDER WITH RADIC, THORACOLUMBAR		SHOULDERS
M54.14	RADICULOPATHY, THORACIC REGION	S43.401A	UNSPECIFIED SPRAIN OF RIGHT SHOULDER, IE
M54.15	RADICULOPATHY, THORACOLUMBAR REGION	S43.402A	UNSPECIFIED SPRAIN OF LEFT SHOULDER, IE
M51.24	OTHER INTERVERTEBRAL DISC DISPLACEMENT, THORACIC REG	M25.511	PAIN, RIGHT SHOULDER
M51.25	OTHER INTERVERTEBRAL DISC DISPLACEM., THORACOLUMBAR	M25.512	PAIN, LEFT SHOULDER
M99.02	SEGMENTAL & SOMATIC DYSFUNCTION OF THORACIC REGION	S46.011A	STRAIN/TEAR OF MUSCLE AND TENDON, ROTAT RIGHT
	LUMBAR – LUMBOSACRAL DX	S46.012A	STRAIN/TEAR OF MUSCLE AND TENDON, ROTAT LEFT
M54.5	LOW BACK PAIN	S40.011A	CONTUSION OF RIGHT SHOULDER, IE
S33.5XXA	SPRAIN OF LIGAMENTS OF LUMBAR SPINE, IE	S40.012A	CONTUSION OF LEFT SHOULDER, IE
S33.8XXA	SPRAIN OF UNSPESIFIED PARTS OF LUMBAR SPINE & PELVIS, IE		MISCELLANEOUS
M51.16	INTERVERTEBRAL DISC DISORDER WITH RADIC, LUMBAR REG	M62.830	MUSCLE SPASM OF BACK
M51.17	INTERVERTEBRAL DISC DISORDER WITH RADIC, LUMBOSACRAL	M62.81	MUSCLE WEAKNESS
M54.16	RADICULOPATHY, LUMBAR REGION	M79.1	MYALGIA
M54.17	RADICULOPATHY, LUMBOSACRAL REGION	R42	DIZZINESS
M51.26	OTHER INTERVERTEBRAL DISC DISPLACEMENT, LUMBAR REG	R45	NERVOUSNESS
M51.27	OTHER INTERVERTEBRAL DISC DISPLACEMENT, LUMBOSACRAL	R51	HEADACHE (UNSPECIFIED)
M99.03	SEGMENTAL & SOMATIC DYSFUNCTION OF LUMBAR REGION	M99.00	SEGMENTAL & SOMATIC DYSFUNCION OF HEA
M99.04	SEGMENTAL & SOMATIC DYSFUNCTION OF SACRAL REGION	M99.01	SEGMENTAL & SOMATIC DYSFUNCION OF CER
M99.05	SEGMENTAL & SOMATIC DYSFUNCION OF PELVIC REGION	M99.02	SEGMENTAL & SOMATIC DYSFUNCION OF THO
	WRISTS	M99.03	SEGMENTAL & SOMATIC DYSFUNCION OF LUM
S63.501A	UNSPECIFIED SPRAIN OF RIGHT WRIST	M99.04	SEGMENTAL & SOMATIC DYSFUNCION OF SAC
S63.502A	UNSPECIFIED SPRAIN OF LEFT WRIST	M99.05	SEGMENTAL & SOMATIC DYSFUNCION OF PH
M79.631	PAIN IN RIGHT FOREARM	M99.06	SEGMENTAL & SOMATIC DYSFUNCION OF LO
M79.632	PAIN IN LEFT FOREARM	M99.07	SEGMENTAL & SOMATIC DYSFUNCION OF UP
M79.641	PAIN IN RIGHT HAND	M99.08	SEGMENTAL & SOMATIC DYSFUNCION OF RIB
M79.642	PAIN IN LEFT HAND		

Rx COLD COMPRESSION PRESCRIPTION and CERTIFICATE OF MEDICAL NECESSITY

Patient Name: Kevin Brown

Patient Address: 67-23 Elliot Avenue

Patient City/State/Zip: Middle village NY 11379.

Telephone Number: 646-644-4417. Date of Injury: 10-13-2023.

COLD COMPRESSION EQUIPMENT ORDER

☐ Device for Cold Compression Therapy – Appropriate Pneumatic Wrap(s)

WRAP: ☐ Foot/Ankle ☐ Knee ☐ Calf/Leg ☐ Hand/Wrist ☐ Elbow ☐ Arm
☐ Shoulder ☑ Back ☐ Neck ☐ Other: _____

Primary Diagnosis Code _____ Secondary Diagnosis Code _____

I am writing on behalf of my patient that you approve coverage for the Cold Compression therapy system. It is a part of my plan of care for my patient's rehabilitative path to recovery. It is my opinion that this device is medically necessary and reasonable in reference to current medical practice act standards for treatment of my patient's condition. I am prescribing this medical device as it will prevent unnecessary suffering and delays in recovery time. Please call my office with questions regarding this therapy system.

The Cold Compression is a vaso-pneumatic cold compression therapy system that provides patients with "therapy" and intermittent compression. Cold Compression therapy is a proven, effective technique in rehabilitative care to effectively reduce recovery time as well as reducing edema, swelling, and pain. The Cold Compression therapy device is medically indicated for my patient's diagnosis and conditions.

For these reasons, the pneumatic compressor and compression wrap was prescribed for this patient to maximize the outcome of the patient's rehabilitation and reduce complications. I have successfully used this device in my practice and my patients tolerate the treatment and are compliant.

It will be necessary for the patient to use this pneumatic compressor and compression wrap daily for a specified period of time at the prescribed pressures as tolerated. We find this product is cost effective and easy to use for the patient or caregiver.

COLD COMPRESSION THERAPY: (Choose One)

Pressure setting: ☐ Alternating Compression Setting ☐ 15 mmHg ☐ 30 mmHg ☐ 50 mmHg

Treatment On time: ☐ 30 Minutes ☐ 45 Minutes ☐ 60 Minutes ☐ Continuous ☐ Other "On" Time: _____

Treatment Off time: ☐ 30 Minutes ☐ 45 Minutes ☐ 60 Minutes ☐ Continuous ☐ Other "Off" Time: _____

Physician Name: Dr. Barakt.

Physician Address: 62-60 99th street

City: Rego park State: NY Zip Code: 11374 Phone: 347-649-1714

Physician's Signature: _____ Date: 10/16/23

RB OS, INC
REFERRAL

PATIENT INFORMATION:

PATIENT NAME: Kevin Brown. SEX M (M/F) LAST 4 SSN: 0478

PATIENT ADDRESS: 67-23 Elliot Avenue

CITY: Middle village STATE: NY ZIP: 11379

PHONE: (646) 644 - 4417 DOB: 07-09-1987.

DIAGNOSIS CODES / ICD-10 _____, _____, _____

☐ WEARABLE PEMF DEVICE

PEMF is a wearable noninvasive PEMF (Pulsed Electromagnetic Field) Device intended to relieve pain anywhere on the body, safely and effectively without risks of addiction or harmful side effects. PEMF offers a cost-effective treatment option as it is a one-time purchase with no need to purchase batteries or electrodes, PEMF repolarizes the electrical field of damaged or injured tissues, which allows ineffective cells to return to normal function.

INSURANCE INFO:

☐ PRIVATE INSURANCE
☐ WC
☐ PERSONAL INJURY
☐ MVA

INSURANCE CARRIER: _____

INSURANCE ID / CLAIM #: _____ GROUP #: _____

DATE OF INJURY: _____

PROVIDER INFO: DATE: 10/16/2023

PROVIDER'S NAME: Dr. Barart NPI: _____

PROVIDER'S ADDRESS: 62 69 99th street.

CITY: Rego park STATE: N.Y. ZIP: 11374.

PROVIDER'S PHONE: (347) 649 1714.

PROVIDER'S SIGNATURE: _____

℞ Referral / Physician's Prescription

Please PRINT CLEARLY and complete all the information below and Email or fax this form along with notes related to the relevant medical history & treatment to

PATIENT INFORMATION:

Patient Name: Kevin Brown Date of Birth: 07-09-1987.

Patient Address: 67-23 Eliot Avenue

City: Middle village State: NY Zip Code: 11379 Phone: (646) 644-4417.

DIAGNOSIS and RELATED INFO: Date of Incident: 10/13/23

Diagnosis: _____ ICD 10 Code: _____

Symptoms: _____

Limitation: _____

Pain Level: ☐ No Pain ☐ Mild Pain ☐ Moderate Pain ☐ Severe Pain ☐ Worst Pain Possible

PRODUCT: Triad 3LT™ Infrared Heat Pad with Low Level Light Therapy (LLLT) - E0221

I am prescribing the Triad 3LT™ Infrared Heat Pad with Low Level Light Therapy (LLLT) which is an FDA Cleared device to treat and reduce musculoskeletal pain and inflammation. The Triad 3LT™ LLLT combines three wavelengths Infrared Heat (830nm and 950nm) and Red Light Laser (630nm) for deep soft tissue penetration; supported by multiple Published Level 1 Double-blind studies showing the clinical benefits of LLLT Photobiomodulation Therapy. The patient can treat their acute or chronic pain and inflammation at home. I certify that the Triad 3LT™ device is medically indicated and in my opinion is reasonable and necessary to treat this patient's condition.

☐ Lumbar Pain ☑ Cervical Pain ☐ Knee Pain ☐ Wrist Pain ☐ Ankle Pain

☐ Lateral/Medial Epicondylitis Pain ☐ Shoulder ☐ OTHER _____

DURATION of TREATMENT:

10-minutes per Treatment (every 2-4 hours): 8-weeks

PHYSICIAN's INFORMATION:

Physician Name (Print): Dr. Barakt

Physician Address: 62-69 90th street

City: Rego park. State: NY Zip Code: 11374 Phone: (347) 649 1714.

NPI #: _____

Physician's Signature: _____ Date: 10/16/23

NOTE: Please include (FAX or Email) all the appropriate Medical Notes with the Prescription

☐ SRT Code

Farrockaway Medical PC
62-69 99th St
Rego Park, NY 11374

nyregoparkmedical@gmail.com

INITIAL EXAMINATION REPORT

Date: 10/17/23 D.O.A: 10/13/23

HISTORY OF PRESENT CONDITIONS

(Mr) Ms. Kevin Brown is a 36 year old (M) F, who was involved in an accident, the details of the accident have been discussed with the patient. According to the information presented by the patient ~~he~~ she was in a regular state of good health and was capable of living on an equal basis with others of his her age, before ~~he~~ she was involved in a ~~motor~~ vehicle slip and fall work related accident, when all of ~~his~~ her symptoms began. The patient was the driver passenger of the ~~front~~ back seat of the vehicle with without the seat belt pedestrian at the accident. Due to accident he she has has not been able to work as of I've only missed 1½ days

AS A RESULT OF THE IMPACT THE PATIENT SUSTAINED INJURIES TO:

Head	Sacral Area	Hip {} RT {} LT
Face	Pelvis	Knee {} RT {} LT
~~Neck~~	Shoulder {} RT {} LT	~~Ankle~~ {} RT {} LT
Chest	Elbow	Foot {} RT {} LT
Thoracic Spine	Wrist {} RT {} LT	Abdomen {} RT {} LT
(Lower Back)	Hand {} RT {} LT	Other: _____

Patient developed laceration wound ~~bruise~~ on Neck.

Patient reported ~~loss of consciousness~~ for approximately _____ no loss of consciousness.

Patient was/was not treated by emergency crew at the scene of the accident and was/was not brought to the emergency room of the _____ hospital by the ambulance friend went by himself herself on the same day next day.

Patient was/was not evaluated in the emergency room where x-rays were/were not taken.

Patient reported evidence of fracture or dislocation were demonstrated.

Patient left before evaluation was completed.

Sutures dressing were placed on patient's wound abrasions

Patient was hospitalized for —

Primary care physician treated patient.

Patient was treated himself herself with analgesics with mild effect and ~~decided~~ to start physical therapy.

Outcome Assessment results discussed thoroughly with patient

ECN: 2023120104570 Received Date: 2023-12-01

CURRENT CHIEF COMPLAINTS AND REVIEW OF THE SYSTEM

Constant Intermittent headaches temporal bi-temporal occipital diffuse frontal area.

Dizziness Vertigo Blurred vision

Nausea Vomiting Tinnitus Hearing Loss

Constant Intermittent posterior neck pain and stiffness with radiation to

Constant Intermittent anterior chest wall.

Difficulty breathing with chest discomfort.

Nervousness Anxiety Fears Irritability Tense

PREVIOUS MEDICAL /SURGICAL HISTORY

Negative DM HTN CAD OA Other _____

Patient states ~~he~~ she ~~had~~ did not have a MVA in the past. 2020 Neighbor

Patient ~~denies~~ admits to have an indwelling metal in body.

Pregnant: Yes No N/A LMP: __/__/____

FAMILY AND SOCIAL HISTORY:

Noncontributory Smoking: Yes No Alcohol: Yes No

Other: _____

MEDICATION:

No Medication Tylenol Ibuprofen

Other: _____

ALLERGIES:

No Allergies Allergic to _____

PHYSICAL EXAMINATION REVEALED

BP ___/___ Pulse _____ BPM Regular Irregular RR_____

Afebrile Febrile

PHYSICAL EXAM

GENERAL APPEARANCE

Well-developed and well nourished 3 year old M F AAOX, normocephalic, no neck masses, no bruits, ear canals are clear, no oropharyngeal erythema. Heart with normal S2 regular sounds. Lungs are clear to auscultation bilaterally. Abdomen with good bowel sounds without guarding, rigidity or rebound, no clubbing or cyanosis noticed on the extremities, Pulses present bilaterally are present. No gross deformities or focal deficits are noticed.

ECN: 2023120104570 Received Date: 2023-12-01

Patient appears to be in mild moderate severe distress due to pain and discomfort of [illegible]

There are bruises wounds scars on: _____

Pain and tenderness in low occipital area upon palpation.

TMJ exam reveals crepitus and tenderness on right left.

MENTAL ILLNESS:

Patient is alert, awake oriented to person, time and place.

Normal affect, speech and attention span.

Serial 7's and simple words spelling backwards is normal.

Memory, both short and long appear normal.

Other: _____

SPINAL COLUMN EXAM

CERVICAL SPINE

Palpation of neck reveals does not reveal mild moderate severe cervical spine tenderness at the C__-C__ level. No step off appreciated.

Increase in right left muscle tone ION Paravertebral Trapezious Rhomboid muscles.

Normal examination of the cervical spine

SPECIAL TEST AND SIGNS:

Distraction Test	Positive	Negative
Compression Test	Positive	Negative
Shoulder Depression Test	Positive	Negative
Foraminal Compression Test	Positive	Negative

NORMAL ROM	PATIENT'S ROM	PAIN		
Flexion	45	From	↓ROM ___	Positive
Extension	55	From	↓ROM 20	Positive
Right Rotation	70	From	↓ROM 50	Positive
Left Rotation	70	From	↓ROM ___	Positive
Right Lateral Flexion	40	From	↓ROM 20	Positive
Left Lateral Flexion	40	From	↓ROM ___	Positive

ECN: 2023120104570 Received Date: 2023-12-01

THORACIC SPINE:

There appears to be tenderness of the thoracic spine at the T__-T__ with spasms of right left paraspinal structures.

There is no tenderness or pain on palpation.

LUMBOSACRAL SPINE:

Palpation of lumbar sacral spine reveals does not reveal mild moderate severe tenderness at the L__-L__ S__ level.

Increase in right left paravertebral muscle tone.

Normal examination of the lumbar sacral spine.

SPECIAL TEST AND SIGNS:

Spinal Percussion Test	Positive	Negative
Faber-Patrick Test	Positive	Negative
Straight Leg Raise Test	Positive @___° on the RT,@___° on the LT	Negative

	NORMAL ROM	PATIENT'S ROM	PAIN
Flexion	90	From ↓ROM	Positive
Extension	30	From ↓ROM	Positive
Right Rotation	30	From ↓ROM 15	Positive
Left Rotation	30	From ↓ROM 15	Positive
Right Lateral Flexion	35	From ↓ROM 15	Positive
Left Lateral Flexion	35	From ↓ROM 15	Positive

CHEST:

Pain and tenderness in sternum area and ribs with without deep breathing or coughing, with without palpation.

No tenderness on palpation, no gross deformity.

EXTREMITIES:

Examination of the extremities reveals tenderness over the _____ and crepitus is noticed upon manipulation of the area.

Active and passive movements are restricted and painful on palpation of the_____.

There is edema of right left medial lateral _____.

There is no apparent swelling or discoloration.

All areas of the peripheral pulses are palpated and normal limits.

Other_____

ECN: 2023120104570 Received Date: 2023-12-01

SHOULDERS	NORMAL ROM	PATIENT'S ROM	RIGHT	LEFT
Flexion/Elevation	180	From ↓ROM ____	____	____
Extension	50	From ↓ROM ____	____	____
Abduction	180	From ↓ROM ____	____	____
Adduction	50	From ↓ROM ____	____	____
Internal Rotation	90	From ↓ROM ____	____	____
External Rotation	90	From ↓ROM ____	____	____

Crepitus appreciated on right left subacromal /subdaltoid bursa.

Able unable to elevate and hold right left arm above shoulder level

Tenderness at crepitus at ac joint at level of rotator cuff insetion (Ligaments of sit muscles)

ELBOWS	NORMAL ROM	PATIENT'S ROM	RIGHT	LEFT
Flexion	160	From ↓ROM ____	____	____
Extension	180	From ↓ROM ____	____	____
Supination	90	From ↓ROM ____	____	____
Pronation	90	From ↓ROM ____	____	____

Crepitus is appreciated right left

WRIST	NORMAL ROM	PATIENT'S ROM	RIGHT	LEFT
Flexion	160	From ↓ROM ____	____	____
Extension	180	From ↓ROM ____	____	____
Supination	90	From ↓ROM ____	____	____
Pronation	90	From ↓ROM ____	____	____

Crepitus is appreciated right left

HIPS	NORMAL ROM	PATIENT'S ROM	RIGHT	LEFT
Flexion	120	From ↓ROM ____	____	____
Extension	15	From ↓ROM ____	____	____
Abduction	45	From ↓ROM ____	____	____
Adduction	30	From ↓ROM ____	____	____
Internal Rotation	40	From ↓ROM ____	____	____
External Rotation	45	From ↓ROM ____	____	____

Crepitus is appreciated RT LT

ECN: 2023120104570 Received Date: 2023-12-01

KNEES	NORMAL ROM	PATIENT'S ROM	RIGHT	LEFT
Flexion	130	From ↓ROM ____	____	____
Extension	15	From ↓ROM ____	____	____

Crepitus is appreciated right left

Bulge/ Balloting sign of patella is is not present on right left

Anterior draws sign is positive negative on right lef

Lachman test is positive negative on right left

Varus stress detecting mcl is positive negative

Valgus stress test detecting LCL is positive negative

ANKLES	NORMAL ROM	PATIENT'S ROM	RIGHT	LEFT
Dorsi Flexion	20	From ↓ROM ____	____	____
Planter Extension	45	From ↓ROM ____	____	____
Inversion	30	From ↓ROM ____	____	____
Eversion	20	From ↓ROM ____	____	____

Crepitus is appreciated Right Left

Swelling/Edma is appreciated Right Left Medial Lateral Malleoli

NEUROLOGICAL EXAMINATION

CRANINAL NERVES EXAMINATION

Olfaction is intact. Pupils are equal and reactive to light and accommodation exrtaocular movements are intact and no nystagmus noted. Facial movement, smile nasolabial fold are symmetric and facial sensation is intact. Jaw closure and opening appears symmetric, tongue protrudes and midline, soft palate is elevated and uvula is midline. Hearing is preserved. Gag reflex is reserved. Swallowing is preserved. Stenocleidomastoid and trapezius muscles are strong bilaterally. No pronator drift.

COORDINATION EXAM:

Normal finger-to-nose and heel-to-sheen exam. Follows rapid hand alteration movements well, both with closed eyes. Normal gait and heel-to-tandem, no ataxia and no shuffling. Romberg's test is Negative Positive

ECN: 2023120104570 Received Date: 2023-12-01

MOTOR SYSTEMS:

Motor muscles test are ✓ throughout.

No muscle atrophy is noted.

Deep tendon reflexes are bilaterally equal and symmetric DTR's are ✓ throughout.

Toes are down going bilaterally.

There is muscle atrophy noted at _____

Deep tendon reflexes are as follows:

Babinski's reflex is Positive Negative

REFLEX	RIGHT	LEFT
Biceps		
Triceps		
Brachioradials		
Knee Jerk		
Ankle Jerk		

RECOMMENDATIONS

After the examination, the patient was advised that because of the sustained injuries no heavy work should be performed until next evaluation. Based upon the subjective complaints and medical evaluation of objective findings, the following test are indicated:

X-ray (S) of the _____

MRI/CT scan of the brain to rule out interracial pathology or subdural hematoma.

Referral for MRI/CT scan of the _____ to rule out ligament tear.

Referral for MRI/CT scan of the cervical spine to rule out discogenic injury.

Referral for MRI/CT scan of lumbarsacral spine rule out discogenic injury.

Physical therapy evaluation and treatment.

Chiropractic evaluation for adjustment of spinal injury.

Acupuncturist evaluation for treatment and pain control.

Neurologist/Physiatrist consultation to rule out:

Cervical Lumbar Radiculapathy

Physiatrist consultation to aid and resolve post-concussion syndrome.

Orthopedic consultation for treatment and diagnosis of the liganentous tear or other bone or joint related problems.

Other _____

TREATMENT PLAN

ECN: 2023120104570 Received Date: 2023-12-01

A treatment plan was proposed and discussed with patient. Medical treatment for the patient consist of analgesics _____

The patient was advised to see a Chiropractor and an acupuncturist. The patient was advised to attend physical therapy program at a frequency of _____ times per week for the first four weeks, until next, until next evaluation. Physical therapy will consist of various modalities such as thermo therapy (Hot/Cold Pack), electrotherapy and electric stimulation, cervical traction manipulation therapy, assisted active and passive range of motion exercises for injured areas. Additional treatment protocol was outlined with the patient being instructed for specific every day home exercise additional therapeutic equipment such as _____ has been prescribed for patient's home use to support treatment. The patient agreed to therapy plan proposed as recommended.

CASUALTY

On the basis of medical history presented by the patient and the physical examination findings, it is in my opinion to reasonable degree of medical certainty, that the condition described above is related to the above-mentioned incident.

Patient will be re-evaluated in _____ weeks.

PROGNOSIS

The possibility of this condition becoming permanent cannot be ruled out at this time because of the severity of the symptoms, the patient is somewhat limited in activities of daily living, as a result of the traumatic injury there were extreme of joint movement with concomitant stretching and tearing of the muscolo-ligament structures of _____

It appears that these areas may be permanently weakened for an indefinite period of time resulting in significant and permanent restricted mobility.

Respectfully Submitted,

Jean-Pierre Georges Barakat, MD
Internal Medicine

DOCTOR'S NOTES AND COMMENTS

_____

RIGHT FRONT BACK LEFT

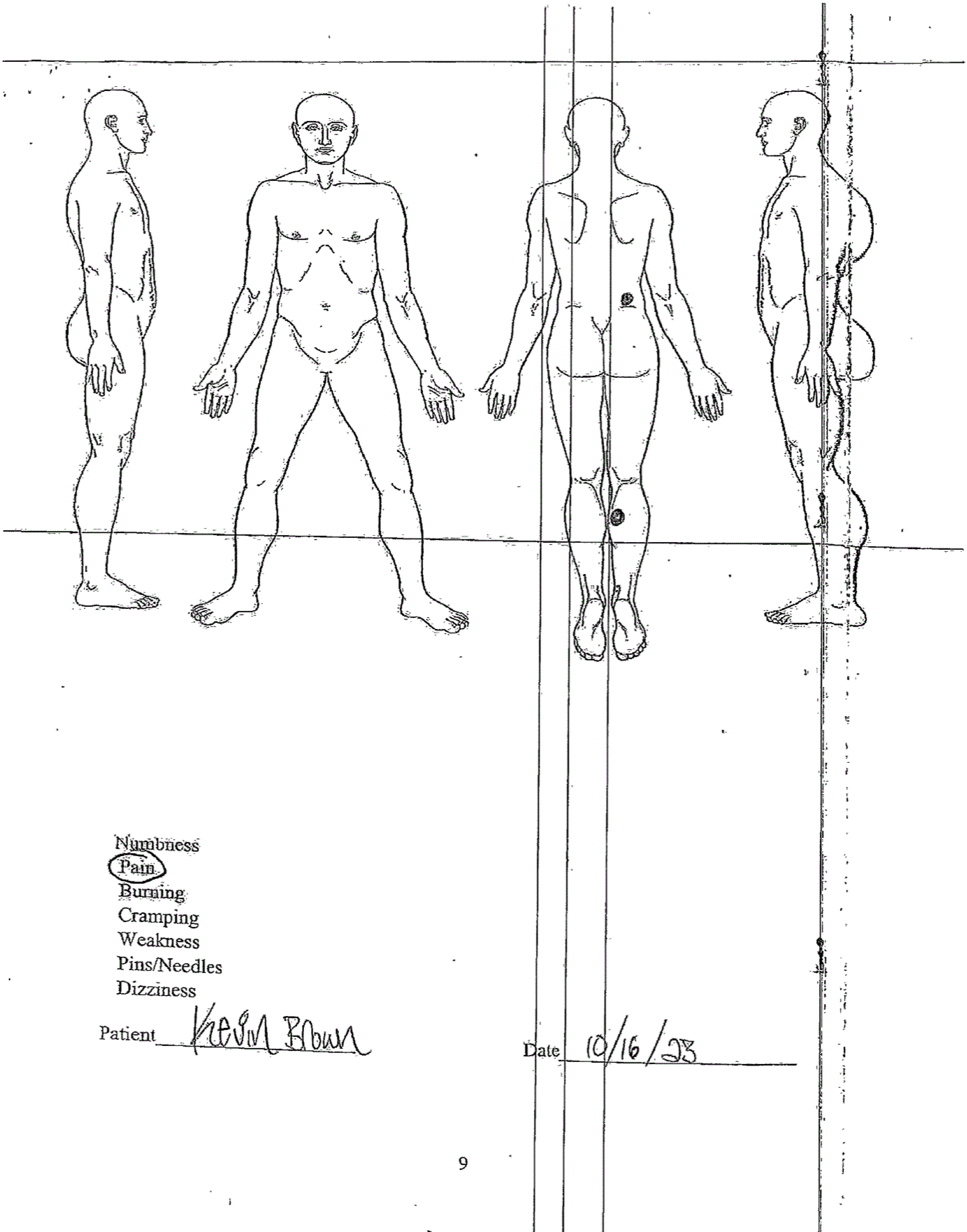

Numbness
Pain
Burning
Cramping
Weakness
Pins/Needles
Dizziness

Patient Kevin Brown

Date 10/16/23

ECN: 2023120104570 Received Date: 2023-12-01

	CERVICAL SPINE DX
M54.2	CERVICALGIA
S13.4XXA	SPRAIN OF LIGAMENTS OF C/S 1E
S13.8XXA	SPRAIN OF JOINTS & LIGAMNETS OF OTHER PARTS OF NECK, 1E
S16.1XXA	STRAIN OF MUSCLE, FASCIA AND TENDON AT NECK LEVEL, 1E
M54.11	RADICULOPATHY, OCCIPITO-ATLANTO-AXIAL REGION
M54.12	RADICULOPATHY, CERVICAL REGION
M54.13	RADICULOPATHY, CERVICOTHORACIC REGION
M50.20	OTHER CERVICAL DISC DISPLACEMENT, UNSP. CERVICAL REG.
M50.21	OTHER CERVICAL DISC DISPLACEMENT, HIGH CERVICAL REGION
M50.22	OTHER CERVICAL DISC DISPLACEMENT, MID-CERVICAL REGION
M50.23	OTHER CERVICAL DISC DISPLACEMENT, CERVICOTHORACIC
M99.01	SEGMENTAL & SOMATIC DYSFUNCTION OF CERVICAL REGION
M79.1	MYALGIA
	THORACIC SPINE DX
M54.6	PAIN IN THORACIC SPINE
S23.3XXA	SPRAIN OF LIGAMENTS OF THORACIC SPINE, 1E
S23.8XXA	SPRAIN OF OTHER SPECIFIED PARTS OF THORAX, 1E
M51.34	INTERVERTEBRAL DISC DISORDER WITH RADIC, THORACIC REG
M51.35	INTERVERTEBRAL DISC DISORDER WITH RADIC, THORACOLUMBAR
M54.14	RADICULOPATHY, THORACIC REGION
M54.15	RADICULOPATHY, THORACOLUMBAR REGION
M51.24	OTHER INTERVERTEBRAL DISC DISPLACEMENT, THORACIC REG
M54.25	OTHER INTERVERTEBRAL DISC DISPLACEM., THORACOLUMBAR
M99.02	SEGMENTAL & SOMATIC DYSFUNCTION OF THORACIC REGION
	LUMBAR – LUMBOSACRAL DX
M54.5	LOW BACK PAIN
S33.5XXA	SPRAIN OF LIGAMENTS OF LUMBAR SPINE, 1E
S33.9XXA	SPRAIN OF UNSPESIFIED PARTS OF LUMBAR SPINE & PELVIS, 1E
M51.36	INTERVERTEBRAL DISC DISORDER WITH RADIC, LUMBAR REG
M51.37	INTERVERTEBRAL DISC DISORDER WITH RADIC, LUMBOSACRAL
M54.16	RADICULOPATHY, LUMBAR REGION
M54.17	RADICULOPATHY, LUMBOSACRAL REGION
M51.26	OTHER INTERVERTEBRAL DISC DISPLACEMENT, LUMBAR REG
M51.27	OTHER INTERVERTEBRAL DISC DISPLACEMENT, LUMBOSACRAL
M99.03	SEGMENTAL & SOMATIC DYSFUNCTION OF LUMBAR REGION
M99.04	SEGMENTAL & SOMATIC DYSFUNCTION OF SACRAL REGION
M99.05	SEGMENTAL & SOMATIC DYSFUNCTION OF PELVIC REGION
	WRISTS
S63.501A	UNSPECIFIED SPRAIN OF RIGHT WRIST
S63.502A	UNSPECIFIED SPRAIN OF LEFT WRIST
M79.631	PAIN IN RIGHT FOREARM
M79.632	PAIN IN LEFT FOREARM
M79.641	PAIN IN RIGHT HAND
M79.642	PAIN IN LEFT HAND

	HIPS
M25.551	PAIN IN RIGHT HIP
M25.552	PAIN IN LEFT HIP
S73.101A	UNSPECIFIED SPRAIN OF RIGHT HIP, 1E
S73.102A	UNSPECIFIED SPRAIN OF LEFT HIP, 1E
	KNEES
M25.561	PAIN IN RIGHT KNEE
M25.562	PAIN IN LEFT KNEE
S83.90XA	SPRAIN OF UNSPECIFIED SITE OF RIGHT KNEE, 1E
S83.93XA	SPRAIN OF UNSPECIFIED SITE OF LEFT KNEE, 1E
S80.01XA	CONTUSION OF RIGHT KNEE, 1E
S80.02XA	CONTUSION OF LEFT KNEE, 1E
S83.206A	UNSP TEAR, OF UNSP MENISCUS, CURRENT INJ, RIGHT KNEE, 1
S83.207A	UNSP TEAR, OF UNSP MENISCUS, CURRENT INJ, LEFT KNEE, 1E
	ANKLE/FOOT
S93.401A	SPRAIN OF UNSPECIFIED LIGAMENT OF RIGHT AN
S93.402A	SPRAIN OF UNSPECIFIED LIGAMENT OF LEFT ANK
M25.571	PAIN IN RIGHT ANKLE & JOINTS OF RIGHT FOOT
M25.572	PAIN IN LEFT ANKLE & JOINTS OF LEFT FOOT
	SHOULDERS
S43.401A	UNSPECIFIED SPRAIN OF RIGHT SHOULDER, 1E
S43.402A	UNSPECIFIED SPRAIN OF LEFT SHOULDER, 1E
M25.511	PAIN, RIGHT SHOULDER
M25.512	PAIN, LEFT SHOULDER
S46.011A	STRAIN/TEAR OF MUSCLE AND TENDON, ROTAT RIGHT
S46.012A	STRAIN/TEAR OF MUSCLE AND TENDON, ROTAT LEFT
S40.011A	CONTUSION OF RIGHT SHOULDER, 1E
S40.012A	CONTUSION OF LEFT SHOULDER, 1E
	MISCELLANEOUS
M62.830	MUSCLE SPASM OF BACK
M62.81	MUSCLE WEAKNESS
M79.1	MYALGIA
R42	DIZZINESS
R45	NERVOUSNESS
R51	HEADACHE (UNSPECIFIED)
M99.00	SEGMENTAL & SOMATIC DYSFUNCION OF HEA
M99.01	SEGMENTAL & SOMATIC DYSFUNCION OF CER
M99.02	SEGMENTAL & SOMATIC DYSFUNCION OF THC
M99.03	SEGMENTAL & SOMATIC DYSFUNCION OF LUM
M99.04	SEGMENTAL & SOMATIC DYSFUNCION OF SAC
M99.05	SEGMENTAL & SOMATIC DYSFUNCION OF PEL
M99.06	SEGMENTAL & SOMATIC DYSFUNCION OF LOW
M99.07	SEGMENTAL & SOMATIC DYSFUNCION OF UPI
M99.08	SEGMENTAL & SOMATIC DYSFUNCION OF RIB

FarRockaway Medical PC

62-69 99th Street. Rego Park, NY 11374 Email. Nyregoparkmedical@gmail.com

Patient's Name Kevin Brown Date: 10/17/23

D.O.A. 10/13/23

----- POSITONING CUSHION
----- INFRA RED LAMP
--✓-- GENERAL USE CUSHION (wide)
--✓-- LUMBER SACRAL SUPPORT
--✓-- DEEP TISUE MASSAGER
----- E M S UNIT FOUR LEAD
----- T.E.N.S. BELT
----- KNEE [ ]BRACE [ ]SUPPORT
----- ARM SLING
----- ANKLE [ ]BRACE [ ]SUPPORT
--✓-- BED BOARD
--✓-- EGG CRATE MATTRESS
--✓-- CERVICAL COLLAR
----- CERVICAL POSTURE PUMP
----- CERVICAL TRACTION W PUMP
----- PARAFFIN BATH
----- THERMAL MOIST HEAT PAD
----- WRIST SUPPORT
----- WATER CIRC HEAT PAD W PUMP
___THERMOPHORE
[ ] OTHER_____

--✓-- ORTHOPEDIC CAR SEAT
----- CERVICAL HEAD HALTER
----- CERVICAL OVER THE DOOR
----- T.E.N.S. ACCESSORIES KIT
----- CRUTCHES
----- CANE
----- ELBOW BRACE
----- HOT / COLD PACK
----- WHIRLPOOL
----- HAND SUPPORT
----- K.O. (CUSTOM FITTED)
----- LSO W/APL CONTROL CUSTOM FITTED
----- TLSO
----- PHILADELPHIA COLLAR
----- PELVIC TRACTION
----- SHOULDER IMMOBILIZER
----- WALKER
--✓-- WHEELCHAIR
--✓-- CERVICAL PILLOW
___SHOULDER [ ] SUPPORT [ ]BRACE

Dr. Jean-Pierre Barakat, MD
LIC No: 250159

847.00☐Cervical spine strain	723.4☐Cervical radiculitis	722.71☐Cervical disc herniation with myelopathy
718.91☐Shoulder derangement	923.00☐Contusion of the shoulder	959.20☐Tendinitis--shoulder/arm
847.20☐Lumbar spine sprain	846.0☐Lumbosacral spine strain	724.4☐Lumbar radiculitis
722.73☐Lumbar disc herniation	844.90 ☐Knee sprain [strain]	717.91☐Knee derangement

FarRockaway Medical PC

OUTCOME ASSESSMENT TESTING SUMMARY REPORT

Dear Patient,

The following exam was created for your doctor to better understand the nature and extent of your injuries, which were sustained below. You will be asked these questions again at your following visit to the doctor. Comparing the answers from your test will help us to monitor your improvement.

Please answer all questions carefully. Make sure all answers are filled out completely. Your answers reflect condition at the time of your questionnaires. Please do not leave any questions blank.

Kevin-Brown
First Name

Brown
Last Name

Age 36 Male ✓ Female

Date of Accident 10 / 13 / 2023

Date of Test

Patients Signature

Date 10/12/23

Doctors Signature

Date 10/17/3

HEADACHE DISABILITY INDEX

Patient Name Kevin Brown

Date 10/17/23

INSTRUCTIONS: Please CIRCLE the correct response:

1. I have headache: (1) 1 per month (2) more than 1 but less than 4 per month (3) more than one per week
2. My headache is: (1) mild (2) moderate (3) severe

Please read carefully: The purpose of the scale is to identify difficulties that you may be experiencing because of your headache. Please check off "YES", "SOMETIMES", or "NO" to each item. Answer each question as it pertains to your headache only.

YES	SOMETIMES	NO		
		✓	E1.	Because of my headaches I feel handicapped.
		✓	F2.	Because of my headaches I feel restricted in performing my routine daily activities.
		✓	E3.	No one understands the effect my headaches have on my life.
		✓	F4.	I restrict my recreational activities (eg, sports, hobbies) because of my headaches.
		✓	E5.	My headaches make me angry.
		✓	E6.	Sometimes I feel that I am going to lose control because of my headaches.
		✓	F7.	Because of my headaches I am less likely to socialize.
		✓	E8.	My spouse (significant other), or family and friends have no idea what I am going through because of my headaches.
		✓	E9.	My headaches are so bad that I feel that I am going to go insane.
		✓	E10.	My outlook on the world is affected by my headaches.
		✓	E11.	I am afraid to go outside when I feel that a headaches is starting.
		✓	E12.	I feel desperate because of my headaches.
		✓	F13.	I am concerned that I am paying penalties at work or at home because of my headaches.
		✓	E14.	My headaches place stress on my relationships with family or friends.
		✓	F15.	I avoid being around people when I have a headache.
		✓	F16.	I believe my headaches are making it difficult for me to achieve my goals in life.
		✓	F17.	I am unable to think clearly because of my headaches.
		✓	F18.	I get tense (eg, muscle tension) because of my headaches.
		✓	F19.	I do not enjoy social gatherings because of my headaches.
		✓	E20.	I feel irritable because of my headaches.
		✓	F21.	I avoid traveling because of my headaches.
		✓	E22.	My headaches make me feel confused.
		✓	F23.	My headaches make me feel frustrated.
		✓	F24.	I find it difficult to read because of my headaches.
		✓	F25.	I find it difficult to focus my attention away from my headaches and on other things.

OTHER COMMENTS:

Examiner

With permission from: Jacobson GP, Ramadan NM, et al. *The Henry Ford Hospital headache disability inventory (HDI)*. Neurology 1994;44:837-8.

NECK DISABILITY INDEX QUESTIONNAIRE

Patient Name Kevin Brown

Date 10/17/23

Please read carefully:

This questionnaire has been designed to enable us to understand how your neck pain has affected your ability to manage everyday life. Please answer every section, and mark in each section only ONE CHOICE which applies to you. We realize that you may consider that two of the statements in any one section relate to you, but please just mark the one box which most closely describes your problem right now.

SECTION 1 – Pain Intensity

A. I have no pain at the moment.
B. The pain is very mild at the moment.
C. The pain is moderate at the moment.
D. The pain is fairly severe at the moment.
E. The pain is very severe at the moment.
F. The pain is the worst imaginable at the moment.

SECTION 2 – Personal Care (washing, dressing, etc.)

A. I can look after myself without causing extra pain.
B. I can look after myself normally but it causes extra pain.
C. It is painful to look after myself and I am slow and careful.
D. I need some help but manage most of my personal care.
E. I need help every day in most aspects of self care.
F. I do not get dressed, wash with difficulty and stay in bed.

SECTION 3 – Lifting

A. I can lift heavy weights without extra pain.
B. I can lift heavy weights but it gives extra pain.
C. Pain prevents me from lifting heavy objects off the floor, but I can manage if they are conveniently positioned, e.g. on a table.
D. Pain prevents me from lifting heavy weights but I can manage light to medium weights if they are conveniently positioned.
E. I can lift very light weights.
F. I cannot lift or carry anything at all.

SECTION 4 – Reading

A. I can read as much as I want with no pain in my neck.
B. I can read as much as I want with slight pain in my neck.
C. I can read as much as I want with moderate pain in my neck.
D. I cannot read as much as I want because of moderate pain in my neck.
E. I can hardly read at all because of severe pain in my neck.
F. I cannot read at all.

SECTION 5 – Headaches

A. I have no headaches at all.
B. I have slight headaches which come infrequently.
C. I have moderate headaches which come infrequently.
D. I have moderate headaches which come frequently.
E. I have severe headaches which come frequently.
F. I have headaches almost all the time.

SECTION 6 – Concentration

A. I can concentrate fully when I want to with no difficulty.
B. I can concentrate fully when I want to with slight difficulty.
C. I have a fair degree of difficulty in concentrating when I want to.
D. I have a lot of difficulty in concentrating when I want to.
E. I have a great deal of difficulty in concentrating when I want to.
F. I cannot concentrate at all.

SECTION 7 – Work

A. I can do as much work as I want to.
B. I can only do my usual work, but no more.
C. I can do most of my usual work, but no more.
D. I cannot do my usual work.
E. I can hardly do any work at all.
F. I cannot do any work at all.

SECTION 8 – Driving

A. I can drive without any neck pain.
B. I can drive as long as I want with slight pain in my neck.
C. I can drive as long as I want with moderate pain in my neck.
D. I cannot drive as long as I want because of moderate pain in my neck.
E. I can hardly drive at all because of severe pain in my neck.
F. I cannot drive my car at all.

SECTION 9 – Sleeping

A. I have no trouble sleeping.
B. My sleep is slightly disturbed (less than 1 hr. sleepless).
C. My sleep is mildly disturbed (1-2 hrs. sleepless).
D. My sleep is moderately disturbed (2-3 hrs. sleepless).
E. My sleep is greatly disturbed (3-5 hrs. sleepless).
F. My sleep is completely disturbed (5-7 hrs. sleepless).

SECTION 10 – Recreation

A. I am able to engage in all my recreation activities with no neck pain at all.
B. I am able to engage in all my recreation activities with some pain in my neck.
C. I am able to engage in most, but not all of my usual recreation activities because of pain in my neck.
D. I am able to engage in a few of my usual recreation activities because of pain in my neck.
E. I can hardly do any recreation activities because of pain in my neck.
F. I cannot do any recreation activities at all.

OTHER COMMENTS:

Examiner

With Permission from: Vernon H, Mior S. The Neck Disability Index: *A study of reliability and validity.* J Manipulative Physiol Ther 1991;14:409-415. Copyright © Vernon H and Hagino C, 1990.

SHOULDER PAIN AND DISABILITY INDEX (SPADI)

Patient Name Kevin Brown

Date: 10/17/23

Please read carefully:

Instructions: Please circle the number that best describes the question being asked.

Pain scale:
No pain at all (0) 1 2 3 4 5 6 7 8 9 10 Worst pain imaginable

How severe is your pain?

1. At its worst?
(0) 1 2 3 4 5 6 7 8 9 10

2. When lying on the involved side?
(0) 1 2 3 4 5 6 7 8 9 10

3. Reaching for something on a high shelf?
(0) 1 2 3 4 5 6 7 8 9 10

4. Touching the back of your neck?
(0) 1 2 3 4 5 6 7 8 9 10

5. Pushing with the involved arm?
(0) 1 2 3 4 5 6 7 8 9 10

Disability scale:
No difficulty 0 1 2 3 4 5 6 7 8 9 10 So difficult it requires help

How much difficulty do you have?

1. Washing your hair?
(0) 1 2 3 4 5 6 7 8 9 10

2. Washing your back?
(0) 1 2 3 4 5 6 7 8 9 10

3. Putting on an undershirt or pullover sweater?
(0) 1 2 3 4 5 6 7 8 9 10

4. Putting on a shirt that buttons down the front?
(0) 1 2 3 4 5 6 7 8 9 10

5. Putting on your pants?
(0) 1 2 3 4 5 6 7 8 9 10

6. Placing an object on a high shelf?
(0) 1 2 3 4 5 6 7 8 9 10

7. Carrying a heavy object of 10 pounds?
(0) 1 2 3 4 5 6 7 8 9 10

8. Removing something from your back pocket?
(0) 1 2 3 4 5 6 7 8 9 10

THER COMMENTS:

arminer:

h permission from: Williams JW Jr., Holleman DR Jr., Simel DL: Measuring shoulder function with the Shoulder Pain and Disability Index. heumatol 1995; 22 (4); 727-732

REVISED OSWESTRY BACK PAIN DISABILITY QUESTIO[illegible]RE

Name Kevin Brown

Date 10/17/23

Please read carefully:

This questionnaire has been designed to enable us to understand how your back pain has affected your ability to manage [illegible] day life. Please answer every section, and mark in each section only ONE CHOICE which applies to you. We realize that y[illegible] consider that two of the statements in any one section relate to you, but please just mark the one box which most closely [illegible]ibes your problem right now.

SECTION 1 – Pain Intensity

A. The pain comes and goes and is very mild.
B. The pain is mild and does not vary much.
C. The pain comes and goes and is moderate.
D. The pain is moderate and does not vary much.
E. The pain comes and goes and is severe.
F. The pain is severe and does not vary much.

SECTION 2 – Personal Care

A. I would not have to change my way of washing or dressing in order to avoid pain.
B. I do not normally change my way of washing or dressing even though it causes some pain.
C. Washing and dressing increases the pain, but I manage not to change my way of doing it.
D. Washing and dressing increases the pain and I find it necessary to change my way of doing it.
E. Because of the pain, I am unable to do some washing and dressing without help.
F. Because of the pain, I am unable to do any washing or dressing without help.

SECTION 3 – Lifting

A. I can lift heavy weights without extra pain.
B. I can lift heavy weights but it gives me extra pain.
C. Pain prevents me from lifting heavy weights off the floor.
D. Pain prevents me from lifting heavy weights off the floor, but I can manage if they are conveniently positioned-eg, on a table
E. Pain prevents me from lifting heavy weights, but I can manage light to medium weights if they are conveniently positioned.
F. I can only lift very light weights, at the most.

SECTION 4 – Walking

A. Pain does not prevent me from walking any distance.
B. Pain prevents me from walking more than 1 mile.
C. Pain prevents me from walking more than ½ mile.
D. Pain prevents me from walking more than ¼ mile.
E. I can only walk using a stick or crutches.
F. I am in bed most of the time and have to crawl to the toilet.

SECTION 5 – Sitting

A. I can sit in any chair as long as I like without pain.
B. I can only sit in my favorite chair as long as I like.
C. Pain prevents me sitting more than 1 hour.
D. Pain prevents me sitting more than ½ hour.
E. Pain prevents me sitting more than 10 minutes.
F. Pain prevents me from sitting at all.

OTHER COMMENTS:

SECTION 6 – Standing

A. I can stand as long as I want without pain.
B. I have some pain while standing, but it does not incre[illegible] with time.
C. I cannot stand for longer than 1 hour without increasi[illegible] pain.
D. I cannot stand for longer than ½ hour without increas[illegible] pain.
E. I cannot stand for longer than 10 minutes without inc[illegible]s[illegible]g pain.
F. Pain prevents me from standing at all.

SECTION 7 – Sleeping

A. I get no pain in bed.
B. I get pain in bed, but it does not prevent me from slee[illegible] well.
C. Because of pain, my normal night's sleep is reduced b[illegible] than one-quarter.
D. Because of pain, my normal night's sleep is reduced b[illegible] than one-half.
E. Because of pain, my normal night's sleep is reduced b[illegible] than three-quarters.
F. Pain prevents me from sleeping at all.

SECTION 8 – Social Life

A. My socia[illegible] life is normal and gives me no pain.
B. My socia[illegible] life is normal, but increases the degree of [illegible].
C. Pain has no significant effect on my social life apart f[illegible] limiting my more energetic interests, eg, dancing, etc.
D. Pain has restricted my social life and I do not go out [illegible]y often.
E. Pain has restricted my social life to my home.
F. I have hardly any social life because of the pain.

SECTION 9 – Traveling

A. I get no pain while traveling.
B. I get some pain while traveling but none of my usual [illegible] of travel make it any worse.
C. I get extra pain while traveling but it does not compel [illegible] seek alternative forms of travel.
D. I get extra pain while traveling which compels me to seek [illegible] alternative forms of travel.
E. Pain restricts all forms of travel.
F. Pain prevents all forms of travel except that done lyin[illegible]

SECTION 10 – Changing Degree of Pain

A. My pain is rapidly getting better.
B. My pain fluctuates, but overall is definitely getting be[illegible]r.
C. My pain seems to be getting better, but improvement [illegible] at present.
D. My pain is neither getting better nor worse.
E. My pain is gradually worsening.
F. My pain is rapidly worsening.

Examiner

With Permission from: Hudson-Cook N, Tomes-Nicholson K, Breen AC. A Revised Oswestry Back Disability Questionnaire. Manchester Univ Pre[illegible] 1989.

ROLAND-MORRIS QUESTIONNAIRE

Patient Name Kevin Brown

Date 10/17/23

Please read carefully:
When your back hurts, you may find it difficult to do some of the things you normally do. Mark only the sentences that describe you today.

1. ✓ I stay at home most of the time because of my back.
2. ✓ I change positions frequently to try and get my back comfortable.
3. ✓ I walk more slowly than usual because of my back.
4. ___ Because of my back, I am not doing any of the jobs that I usually do around the house.
5. ✓ Because of my back, I use a handrail to get upstairs.
6. ✓ Because of my back, I lie down to rest more.
7. ✓ Because of my back, I have to hold on to something to get out of an easy chair.
8. ✓ Because of my back, I try to get other people to do things for me.
9. ✓ I get dressed more slowly because of my back.
10. ✓ I only stand up for short periods of time because of my back.
11. ✓ Because of my back, I try not to bend or kneel.
12. ___ I find it difficult to get out of a chair because of my back.
13. ___ My back is painful almost all of the time.
14. ✓ I find it difficult to turn over in bed because of my back.
15. ✓ My appetite is not very good because of my back.
16. ✓ I have trouble putting on my socks/stockings because of my back.
17. ✓ I only walk short distances because of my back pain.
18. ___ I sleep less well because of my back pain.
19. ___ Because of my back pain, I get dressed with help from someone else.
20. ___ I sit down for most of the day because of my back.
21. ___ I avoid heavy jobs around the house because of my back.
22. ___ Because of my back pain, I am more irritable and bad tempered with people than usual.
23. ___ Because of my back, I go upstairs more slowly than usual.
24. ___ I stay in bed most of the day because of my back.

OTHER COMMENTS:

Examiner

With Permission from: Roland M, Morris R. *A study of the natural history of back pain: Part I: Development of a reliable and sensitive measure of disability in low-back pain.* Spine 1983;8:141-144;

SUBJECTIVE KNEE SCORE QUESTIONNAIRE

Patient Name Kevin Brown

Date 10/17/23

Please read carefully:

Please answer every section, and mark in each section only ONE CHOICE which applies to you. We realize that you may consider that of the statements in any one section relate to you, but please just mark the one box which most closely describes your problem right now.

PAIN

( ) I experience no pain in my knee.
( ) I have occasional pain with strenuous sports or heavy work. I don't think that my knee is entirely normal. Limitations are mild and to
( ) There is occasional pain in my knee with light recreational sports or moderate work.
( ) I have pain brought on by sports, light recreational activities, or moderate work. Occasional pain is brought on by daily activities s
standing or kneeling.
( ) The pain I have in my knee is a significant problem with activities as simple as walking. The pain is relieved by rest. I can't participate

SWELLING

( ) I experience no swelling in my knees.
( ) I have occasional swelling in my knee with strenuous sports or heavy work.
( ) There is occasional swelling with light recreational activities or moderate work.
( ) Swelling limits my participation in sports and moderate work. Occurs infrequently with simple walking or light work. Occasionally with
walking or light work – about 3 times a year.
( ) My knee swells after simple walking activities and light work. Rest relieves the swelling.
( ) I have severe swelling with simple walking activities. Rest does not relieve the swelling.

STABILITY

( ) My knee does not give out.
( ) My knee gives out only with strenuous sports or heavy work.
( ) My knee gives out occasionally with light recreational activities or moderate work; it limits my vigorous activities, sports, or heavy
( ) Because my knee gives out, it limits all sports and moderate work. It occasionally gives out with walking or light work.
( ) My knee gives out frequently with simple activities such as walking. I must guard my knee at all times.
( ) I have severe problems with my knee giving out. I can't turn or twist without my knee giving out.

OVERALL ACTIVITY LEVEL

( ) No limitations. I have a normal knee, and I am able to do everything including strenuous sports and/or heavy labor.
( ) I can partake in sports including strenuous ones but at a lower level. I must guard my knee and limit the amount of heavy labor or
( ) Light recreational activities are possible with RARE symptoms. I am limited to light work.
( ) No sports or recreational activities are possible. Walking activities are possible with RARE symptoms. I am limited to light work.
( ) Walking activities and daily living cause moderate problems and persistent symptoms.
( ) Walking and other daily activities cause severe problems.

WALKING

( ) Normal, unlimited
( ) Slight, mild problems.
( ) Moderate problem, flat surface up to half a mile.
( ) Severe problems, only 2-3 blocks.
( ) Severe problems, need cane or crutches.

STAIRS

( ) Normal, unlimited
( ) Slight, mild problems.
( ) Moderate problem, only 10-15 steps possible.
( ) Severe problems, require banister for support.
( ) Severe problems, only 1-5 steps without support.

RUNNING

( ) Normal, unlimited, fully competitive.
( ) Slight, mild problems, run at half speed.
( ) Moderate problems, only 1-2 miles possible.
( ) Severe problems, only 1-3 blocks possible.
( ) Severe problems, only a few steps.

JUMPING AND TWISTING

( ) Normal, unlimited, fully competitive.
( ) Slight, mild problems, some guarding.
( ) Moderate problems, have up strenuous sports.
( ) Severe problems, affects all sports, always guarding.
( ) Severe problems, only light activity possible (pool/swim).

Examiner: _____

With permission from: Noyes FR, et al. Functional disability in the anterior cruciate insufficient knee syndrome. Review of knee rating systems and
risk factors in determining treatment. Sports Med 1984; 1: 278-302. Copyright Adis International, Inc.

Health Source RX Inc.
6815 Fresh Meadow Ln **Fresh Meadows, NY 11365**
Phone: **(347)408-4004** Fax: **(347)408-4005** **Prnt Dt:** 10/18/2023 3:52:43PM

Rx Pres: Jean Pierre Barakat
795 Todt Hill Road
STATEN ISLAND, NY 103C Phn: (626)399-1079
Fax: (626)399-1079

Ord: 10/18/2023
NPI# 1205086329
LIC# 250159
DEA# FB1087065
SPI: 6588597883017

Patient: Brown, Kevin
DOB: 07/09/1987 **Gender** M
Address: 67-23 Elliot AvenueRego park **Rx#:** 63850
FLUSHING, NY 11379
Phone (646)644-4417
Qty: 250.000 (Two Hundred Fifty)
Days: 30 **Refills:** 0 **PH/TH:** NP **Class:** 0
Potency UnitCd: Gram
Drug: lidocaine 5 % topical ointment.5 Ointment

Sig: ap aa up to tid

Signature **Date**

This Prescription Will be Filled Generically Unless Prescriber Writes "DAW [1]" in the Box

N
Dispense As Written

Electronic Rx

10/18/2023 1:23 PM **MessageType:** New Prescription
From: 6588597883017
Msg.Id: NEWRX-1-137004169 To: 5839141
Prs. Order Ref: 155460038

Resp.Status: Ready To Process

lidocaine 5 % topical ointment

MUSKULOSKELETAL REFERRAL SCRIPT

Patient's Name BROWN, KEVIN DOB 07/06/1987 Patient Address 67-23 Elliot Ave Middle Village, NY 11379

Primary Insurance Progressive No Fault Secondary Insurance

__ Spine __ R/L Shoulder __ R/L Elbow __ R/L Knee __ R/L Ankle __ R/L Other

- V M54.5 Low Back Pain
- V M25.561 Pain in right knee
- V M25.562 Pain in left knee
- __ M54.2 Cervicalgia
- __ M79.601 Pain in right arm
- __ M79.602 Pain in left arm
- __ M79.604 Pain in right leg
- __ M79.605 Pain in left leg
- __ M79.609 Pain in unspecified limb
- __ M79.621 Pain in right upper arm
- __ M79.622 Pain in left upper arm
- __ M79.631 Pain in right forearm
- __ M79.632 Pain in left forearm
- __ M79.641 Pain in right hand
- __ M79.642 Pain in left hand
- __ M25.521 Pain in right elbow
- V M25.522 Pain in left elbow
- __ M25.531 Pain in right wrist
- __ M25.532 Pain in left wrist
- __ M79.661 Pain in right lower leg
- __ M79.662 Pain in left lower leg
- __ M79.671 Pain in right foot
- __ M79.672 Pain in left foot
- __ M79.674 Pain in right toe(s)
- __ M79.675 Pain in left toe(s)
- V M25.511 Pain in right shoulder
- V M25.512 Pain in left shoulder
- __ M17.0 Bilateral primary osteoarthritis of knee
- __ M17.11 Unilateral primary osteoarthritis of right knee
- __ M17.12 Unilateral primary osteoarthritis of left knee
- __ M54.14 Intervertebral disc disorders w/radiculopathy, thoracic region
- __ M51.15 Intervertebral disc disorders w/radiculopathy, thoracolumbar region
- __ M51.16 Intervertebral disc disorders with radiculopathy, lumbar region
- __ M51.17 Intervertebral disc disorders with radiculopathy, lumbosacral region
- __ M54.14 Radiculopathy, thoracic region
- __ M54.15 Radiculopathy, thoracolumbar
- __ M54.16 Radiculopathy, lumbar region
- __ M54.17 Radiculopathy, lumbosacral region
- __ M17.9 Osteoarthritis of knee, unspecified
- __ M25.551 Pain in right hip
- __ M25.552 Pain in left hip
- __ M25.571 Pain in right ankle and joints
- __ M25.572 Pain in left ankle and joints

V CAROTID 93880
V Dizziness and Giddiness R42
V Headache R51

V TCD TRANSCRANIAL DOPPLER
Two Probe with Emboli Detection(93886, 93890, 93892)

Based on the patient's examination, diagnosis, and history, it is my professional opinion that these tests are medically necessary for the diagnosis and treatment.

Physician's Signature: _____ Physician's Name: _____ Date: 10/19/2023

Farrockaway Medical PC
62-69 99th St
Rego Park, NY 11374
nyregoparkmedical@gmail.com

DATE 11/14/23

FOLLOW UP REPORT: 1

DATE OF ACCIDENT: 10/13/23

PATIENT'S NAME: Kevin Brown

AGE: 36

AT THE TIME OF THE INITIAL EVALUATION PATIENT PRESENTED COMPLAINTS OF:

HEADACHE DIFUSES FRONTAL TEMPORAL OCCIPITAL VOMITIMG.
DIZZINESS BLURRED VISION
NECK PAIN ? NON-RADIATING RADIATING TO _____
LOWER BACK PAIN NON-RADIATING RADIATING TO _____
MID BACK PAIN NON-RADIATING RADIATING TO _____
SHOULDERS RT LT TINGLING NUMBNESS
WRIST RT LT TINGLING NUMBNESS
ELBOWS RT LT TINGLING NUMBNESS
HANDS RT LT TINGLING NUMBNESS
HIPS RT LT TINGLING NUMBNESS
KNEES RT LT TINGLING NUMBNESS
ANKLES RT LT TINGLING NUMBNESS (R) Calf
FEET RT LT TINGLING NUMBNESS
CHEST RT LT TINGLING NUMENESS
ABDOMEN RT LT TINGLING NUMBNESS
NERVOUNESS
INSOMNIA ANXIETY FEAR DRIVING/SITTING IN THE CAR FEAR OF CROSSING STREET
OTHER

Outcome Assessment results discussed thoroughly with patient

PRESENT COMPLAINTS

HEAD
FACE
NECK
CHEST
THORACIC SPINE
LOWER BACK
STRESS
HEADACHES
VOMITING

SACRAL AREA
PELVIS
SHOULDER RT LT
ELBOWS RT LT
WRIST RT LT
HAND RT LT
SPEECH
BLURRED VISION
NERVOUSNESS/INSOMNIA

HIPS RT LT
KNEES RT LT
ANKLES RT LT
FEET RT LT
ABDOMEN RT LT
OTHER _____
FEAR OF DRIVING
SITTING IN CAR
CROSSING THE STREET

PHYSICAL EXAMINATION REVEALED:

B/P ___/___ PULSE _____ RR _____ AFEBRILE FEBRILE

PATIENT IS AAOX3, MEMORY [ ] IS INTACT [ ] HAS POOR MEMORY SINCE THE ACCIDENT
SPEECH IS FLUENT AND COHERENT
PATIENT APPEARS TO BE IN [ ] MILD [ ] MODERATE [ ] SEVERE DISTRESS DUE TO PAIN AND DISCOMFORT
PATIENT IS NOT IN ACUTE DISTRESS, BUT FEELS QUITE UNCOMFORTABLE AND TENSE
S1S2R LUNGS ABDOMEN SOFT, NT

CERVICAL SPINE

PALPATION OF THE NECK REVEALS DOES NOT REVEAL MILD MODERATE SEVERE CERVICAL SPINE TENDERNESS AT THE C5 C6 LEVEL NO STEP OFF APPRECIATED
INCREASE IN R L MUSCLE TONE ION PARAVERTEBRAL TRAPEZIUS RHOMBOID MUSCLES
NORMAL EXAMINATION OF THE CERVICAL SPINE

ECN: 2024010203266 Received Date: 2023-12-29

SPECIAL TEST AND SIGNS

DISTRACTION TEST	POSTIVE	NEGATIVE
COMPRESSION TEST	POSTIVE	NEGATIVE
SHOULDER DEPRESSION TEST	POSTIVE	NEGATIVE
FORAMINA COMPRESSION TEST	POSTIVE	NEGATIVE

	NORMAL ROM	PATIENT'S ROM		PAIN
FLEXION	45	FROM	ROM___	POSITIVE
EXTENSION	55	FROM	ROM 45	POSITIVE
RIGHT ROTATION	70	FROM	ROM 55	POSITIVE
LEFT ROTATION	70	FROM	ROM___	POSITIVE
RIGHT LATERAL FLEXION	40	FROM	ROM 25	POSITIVE
LEFT LATERAL FLEXION	40	FROM	ROM___	POSITIVE

THORACIC SPINE:

THERE APPEARS TO BE TENDRNESS OF THE THORACIC SPINE AT LEVELS T___T___ WITH SPASM OF RIGHT LEFT PARASPINAL STRUCTURES
THERE IS NO TENDERNESS OR PAIN ON PALPATION

LUMBOSACRAL SPINE

PALPATION OF LUMBOSACRAL SPINE REVEALS DOES NOT REVEAL
SEVERE MILD MODERATE
TENDERNESS AT THE L___ L S LEVEL
INCREASE IN RIGHT LEFT PARAVERETEBRAL MUSCLE TONE
NORMAL EXAMINATION OF THE LUMBOSACRAL SPINE

SPECIAL TEST AND SIGNS:

SPINAL PRECUSSION TEST	POSITIVE	NEGATIVE
FABERE- PATRICK TEST	POSITIVE	NEGATIVE
STRAIGHT LEG RAISE TEST	POSITIVE @___ ON THE RT @___ ON THE LT	NEGATIVE

ECN: 2024010203266 Received Date: 2023-12-29

	NORMAL ROM	PATIENT'S ROM	PAIN
FLEXION	90	☐ FROM ☐ ROM 70	☐ POSITIVE
EXTENTSION	30	☐ FROM ☐ ROM 20	☐ POSITIVE
RIGHT ROTATION	30	☐ FROM ☐ ROM 16	☐ POSITIVE
LEFT ROTATION	30	☐ FROM ☐ ROM ___	☐ POSITIVE
RIGHT LATERAL FLEXION	35	☐ FROM ☐ ROM ___	☐ POSITIVE
LEFT LATERAL FLEXION	35	☐ FROM ☐ ROM ___	☐ POSITIVE

SHOULDER:	NORMAL ROM	PATIENT'S ROM	RIGHT	LEFT
FLEXION/ ELEVATION	180	☐ FROM ☐ ROM ___	___	___
EXTENSION	50	☐ FROM ☐ ROM ___	___	___
ABDUCTION	180	☐ FROM ☐ ROM ___	___	___
ADDUCTION	50	☐ FROM ☐ ROM ___	___	___
INTERNAL ROTATION	90	☐ FROM ☐ ROM ___	___	___
EXTENAL ROTATION	90	☐ FROM ☐ ROM ___	___	___

☐ CREPITUS IS APPRECIATED ☐ RIGHT ☐ LEFT SUBACROMAL / SUBDALTOID BURSA

☐ ABLE ☐ UNABLE TO ELEVATE AND HOLD ☐ RIGHT ☐ LEFT ARM AT ABOVE SHOULDER LEVEL

☐ TENDERNESS ☐ AT CREPITUS AT AC JOINT ☐ AT THE LEVEL OF ROTATOR CUFF INSERTION (LIGAMENTS OF SIT MUSCLES)

ELBOWS:	NORMAL ROM	PATIENT'S ROM	RIGHT	LEFT
LEXION	160	☐ FROM ☐ ROM	___	___
XTENSION	180	☐ FROM ☐ ROM	___	___
JPINATION	90	☐ FROM ☐ ROM	___	___
ONATION	90	☐ FROM ☐ ROM	___	___

CREPITUS IS APPRECIATED ☐ RIGHT ☐ LEFT

IST:	NORMAL ROM	PATIENT'S ROM	RIGHT	LEFT
XION	160	☐ FROM ☐ ROM	___	___
ENSION	180	☐ FROM ☐ ROM	___	___
NATION	90	☐ FROM ☐ ROM	___	___
NATION	90	☐ FROM ☐ ROM	___	___

EPITUS IS APPRECIATED IS APPREICATED ☐ RIGHT ☐ LEF

HIPS:	NORMAL ROM	PATIENT'S ROM	RIGHT	LEFT
FLEXION	120	FROM ROM		
EXTENSION	15	FROM ROM		
ABDUCTION	45	FROM ROM		
INTERNAL ROTATION	40	FROM ROM		
EXTERNAL ROTATION	45	FROM ROM		

CREPITUS IS APPRECIATED RIGHT LEFT

KNEES:	NORMAL ROM	PATIENT'S ROM	RIGHT	LEFT
FLEXION	130	FROM ROM		
EXTENSION	15	FROM ROM		
		FROM ROM		

CREPITUS IS APPRECIARED

BULGE/ BALLOTING SIGNOF THE PATELLA IS IS NOT PRESENT ON RIGHT LEFT
ANTERIOR DRAWS SIGN IS POSTIVE NEGATIVE ON RIGHT LIGHT
LACHMAN TEST IS POSITIVE NEGATIVE ON RIGHT LEFT
VARUS STRESS TEST DETECTING mol IS POSITIVE NEGATIVE
VALGUS STRESS TEST DETECTING LCL IS POSTIVE NEGATIVE

ANKLES:	NORMAL ROM	PATIENT'S ROM	RIGHT	LEFT
DORSI FLEXION	20	FROM ROM		
PLANTER EXTENSION	45	FROM ROM		
INVERSION	30	FROM ROM		
EVERSION	20	FROM ROM		

CREPITUS IS APPRECIATED RIGHT LEFT
SWELLING/ EDEMA IS APPRECIATED ON RIGHT LEFT
MEDIAL LATERAL MALLEOLI

ECN: 2024010203266 Received Date: 2023-12-29

MOTOR SYSTEMS

MOTOR MUSCLES TEST WERE _____ THROUGHOUT
NO MUSCLE ATROPHY IS NOTED
DEEP TENDON REFLEXES ARE BILATERALLY EQUAL AND SYMMETRIC; DTR'S ARE _____ THROUGHOUT
TOES ARE DOWNGOING BILATERALLY

SENSORY SYSTEMS

SENSORY EXAMINATION OF UPPE EXTREMITIES REVEALS DECREASED RESPONSE TO LIGHT, TOUCH AND PINPRICK SENSATION IN:

R L TRAPEZUIS (C3-C4) NERVE DISTRIBUTION
R L DELTOID (C5-C6) NERVE DISTRIBUTION
R L BICEP (C6) NERVE DISTRIBUTION
R L RADIAL (C6-C7) NERVE DISTRIBUTION
R L MEDIAN (C7-C9) NERVE DISTRIBUTION
R L ULNAR (C8-T1) NERVE DISTRIBUTION

TINEL'S SIGN	+ -@RIGHT	
FINKELSTEIN'S TEST	+ -@RIGHT	+ -@LEFT
PHALEN'S SIGN	+ -@RIGHT	+ -@LEFT
		+ -@LEFT

SENSORY EXAMINATION OF UPPER EXREMITIES REVEALS NORMAL SENSITIVITY

SENSORY EXAMINATION OF LOWER EXTREMITIES REVEALS DECREASED RESPONSE TO LIGHT, TOUCH AND PINPRICK SENSATION IN:

R L GLUTEL (L-5) NERVE DISTRIBUTION
R L VASTUS (L3-L4) NERVE DISTRIBUTION
R L SCIARIA (L5-S2) NERVE DISTRIBUTION
R L TIBIAL ANTERIOR (L4-L5) NERVE DISTRIBUTION
R L PERNONEUS (L5-S1) NERVE DISTRIBUTION
R L GASTROCNEMIUS (L4-S1) NERVER DISTRIBUTION

SENSORY EXAMINATION OF THE UPPER EXTREMITIES REVEALS NORMAL SENSITIVITY

DIAGNOSTIC RESULTS:

X-RAY OF_____ WAS DONE __/__/__ AND DEMONSTRATED _____

X-RAY OF_____ WAS DONE __/__/__ AND DEMONSTRATED _____

X-RAY OF_____ WAS DONE __/__/__ AND DEMONSTRATED _____

MRI/CT OF CS WAS DONE 11/12/25 AND DEMONSTRATED DB 3-4
DH 5-6 6-7

MRI/CT OF LS WAS DONE 11/12/25 AND DEMONSTRATED DH 4-5

MRI/CT OF_____ WAS DONE __/__/__ AND DEMONSTRATED _____

MRI/CT OF_____ WAS DONE __/__/__ AND DEMONSTRATED _____

MRI/CT OF_____ WAS DONE __/__/__ AND DEMONSTRATED _____

MRI/CT OF_____ WAS DONE __/__/__ AND DEMONSTRATED _____

ECN: 2024010203266 Received Date: 2023-12-29

BASE ON THE ABOVE FINDINGS, ADDITIONAL TEST AND THERAPY INDICATED:

CONTINUE PHYSICAL THERAPY 4-5 TIMES PER WEEK

X-RAY(S) OF THE _____ TO RULE OUT FRACTURE

MRI/CT SCAN OF R Ankle 11/16/23 TO RULE OUT

NEUROLOGIST CONSULTATION TO RULE OUT _____

PHYSCHOLOGIST CONSULTATION TO RULE OUT _____

ORTHOPEDIC CONSULTATION TO RULE OUT _____

ADDITIONAL THERAPEUTIC EQUIPMENT SUCH AS _____

OTHER _____

PATIENT WILL BE RE- EVALUATED IN 5 WEEKS.

PATIENT WAS DISCHARGED SINCE SYMPTOMS IMPROVED WITH PHYSCIAL THERAPY

RESPECTUFULLY SUMITTED,

JEAN-PIERRE GEORGES BARAKAT, MD
INTERNAL MEDICINE

DIAGNOSIS IMPRESSIONS: ICD 10

	CERVICAL SPINE DX		
M542	CERVICALGIA		HIPS
S13.4XXA	SPRAIN OF LIGAMENTS OF C/S IE	M25.551	PAIN IN RIGHT HIP
S13.8XXA	SPRAIN OF JOINTS & LIGAMNETS OF OTHER PARTS OF NECK, IE	M25.552	PAIN IN LEFT HIP
S16.1XXA	STRAIN OF MUSCLE, FASCIA AND TENDON AT NECK LEVEL, IE	S73.101A	UNSPECIFIED SPRAIN OF RIGHT HIP, IE
M54.11	RADICULOPATHY, OCCIPITO-ATLANTO-AXIAL REGION	S73.102A	UNSPECIFIED SPRAIN OF LEFT HIP, IE
M54.12	RADICULOPATHY, CERVICAL REGION		KNEES
M54.13	RADICULOPATHY, CERVICOTHORACIC REGION	M25.561	PAIN IN RIGHT KNEE
M50.20	OTHER CERVICAL DISC DISPLACEMENT, UNSP. CERVICAL REG.	M25.562	PAIN IN LEFT KNEE
M50.21	OTHER CERVICAL DISC DISPLACEMENT, HIGH CERVICAL REGION	S83.90XA	SPRAIN OF UNSPECIFIED SITE OF RIGHT KNEE, IE
M50.22	OTHER CERVICAL DISC DISPLACEMENT, MID-CERVICAL REGION	S83.91XA	SPRAIN OF UNSPECIFIED SITE OF LEFT KNEE, IE
M50.23	OTHER CERVICAL DISC DISPLACEMENT, CERVICOTHORACIC	S80.01XA	CONTUSION OF RIGHT KNEE, IE
M99.01	SEGMENTAL & SOMATIC DYSFUNCTION OF CERVICAL REGION	S80.02XA	CONTUSION OF LEFT KNEE, IE
M79.1	MYALGIA	S83.206A	UNSP TEAR, OF UNSP MENISCUS, CURRENT INJURY, RIGHT KNEE, IE
	THORACIC SPINE DX	S83.207A	UNSP TEAR, OF UNSP MENISCUS, CURRENT INJURY, LEFT KNEE, IE
M54.6	PAIN IN THORACIC SPINE		ANKLE/FOOT
S23.3XXA	SPRAIN OF LIGAMENTS OF THORACIC SPINE, IE	S93.401A	SPRAIN OF UNSPECIFIED LIGAMENT OF RIGHT ANKLE
S23.8XXA	SPRAIN OF OTHER SPECIFIED PARTS OF THORAX, IE	S93.402A	SPRAIN OF UNSPECIFIED LIGAMENT OF LEFT ANKLE
M51.14	INTERVERTEBRAL DISC DISORDER WITH RADIC, THORACIC REG	M25.571	PAIN IN RIGHT ANKLE & JOINTS OF RIGHT FOOT
M53.15	INTERVERTEBRAL DISC DISORDER WITH RADIC, THORACOLUMBAR	M25.572	PAIN IN LEFT ANKLE & JOINTS OF LEFT FOOT
M54.14	RADICULOPATHY, THORACIC REGION		SHOULDERS
M54.15	RADICULOPATHY, THORACOLUMBAR REGION	S43.401A	UNSPECIFIED SPRAIN OF RIGHT SHOULDER, IE
M53.24	OTHER INTERVERTEBRAL DISC DISPLACEMENT, THORACIC REG	S43.402A	UNSPECIFIED SPRAIN OF LEFT SHOULDER, IE
M54.25	OTHER INTERVERTEBRAL DISC DISPLACEM., THORACOLUMBAR	M25.511	PAIN, RIGHT SHOULDER
M99.02	SEGMENTAL & SOMATIC DYSFUNCTION OF THORACIC REGION	M25.512	PAIN, LEFT SHOULDER
	LUMBAR—LUMBOSACRAL DX	S46.011A	STRAIN/TEAR OF MUSCLE AND TENDON, ROTATOR C RIGHT
M54.5	LOW BACK PAIN	S46.012A	STRAIN/TEAR OF MUSCLE AND TENDON, ROTATOR C LEFT
S33.5XXA	SPRAIN OF LIGAMENTS OF LUMBAR SPINE, IE	S40.011A	CONTUSION OF RIGHT SHOULDER, IE
S33.9XXA	SPRAIN OF UNSPESIFIED PARTS OF LUMBAR SPINE & PELVIS, IE	S40.012A	CONTUSION OF LEFT SHOULDER, IE
M51.16	INTERVERTEBRAL DISC DISORDER WITH RADIC, LUMBAR REG		MISCELLENEOUS
M51.17	INTERVERTEBRAL DISC DISORDER WITH RADIC, LUMBOSACRAL	M62.830	MUSCLE SPASM OF BACK
M54.16	RADICULOPATHY, LUMBAR REGION	M62.81	MUSCLE WEAKNESS
M54.17	RADICULOPATHY, LUMBOSACRAL REGION	M79.1	MYALGIA
M51.26	OTHER INTERVERTEBRAL DISC DISPLACEMENT, LUMBAR REG	R42	DIZZINESS
M51.27	OTHER INTERVERTEBRAL DISC DISPLACEMENT, LUMBOSACRAL	R45	NERVOUSNESS
M99.03	SEGMENTAL & SOMATIC DYSFUNCTION OF LUMBAR REGION	R51	HEADACHE (UNSPECIFIED)
M99.04	SEGMENTAL & SOMATIC DYSFUNCTION OF SACRAL REGION	M99.00	SEGMENTAL & SOMATIC DYSFUNCTION OF HEAD RE
M99.05	SEGMENTAL & SOMATIC DYSFUNCTION OF PELVIC REGION	M99.01	SEGMENTAL & SOMATIC DYSFUNCTION OF CERVICA
	WRISTS	M99.02	SEGMENTAL & SOMATIC DYSFUNCTION OF THORAC
S63.501A	UNSPECIFIED SPRAIN OF RIGHT WRIST	M99.03	SEGMENTAL & SOMATIC DYSFUNCTION OF LUMBAR
S63.502A	UNSPECIFIED SPRAIN OF LEFT WRIST	M99.04	SEGMENTAL & SOMATIC DYSFUNCTION OF SACRAL
M79.631	PAIN IN RIGHT FOREARM	M99.05	SEGMENTAL & SOMATIC DYSFUNCTION OF PELVIC
M79.632	PAIN IN LEFT FOREARM	M99.06	SEGMENTAL & SOMATIC DYSFUNCTION OF LOWER
M79.643	PAIN IN RIGHT HAND	M99.07	SEGMENTAL & SOMATIC DYSFUNCTION OF UPPER
M79.642	PAIN IN LEFT HAND	M99.08	SEGMENTAL & SOMATIC DYSFUNCTION OF RIB CAG

Multi Radiance Medical
LaserLongevity™

Rx Physician's Prescription

Please complete the information below and email this form along with notes related to the relevant medical history & treatment

PATIENT INFORMATION:

Patient Name: Kevin Brown Date Of Birth: 7/6/87

Patient Address: 67-23 Elliot Avenue

City: Flushing State: NY Zip Code: 11379 Phone: 6466444417

PRODUCT: PAIN AWAY HOME CARE LASER DEVICE:

Laser Therapy is a recognized treatment that works by increasing circulation to the affected areas through process of photobiomodulation. Multiple studies have been published in peer-reviewed journals on its use in reducing pain, healing chronic wounds and restoring protective sensation. I believe the patient's condition will benefit from use of this laser therapy at home because of musculoskeletal injury treatment and find it medically necessary to control pain, and increase local blood circulation that will assist in rehabilitation. The modality of treatment is cost-effective and appropriate since the patient's symptoms have not improved with other listed interventions. Since this device may be used at home, the patient will be better able to comply with their treatment regimen. The patient will remain in my care while using this device.

- [ ] Cervical Spine
- [ ] Knee L/R
- [ ] Hand L/R
- [ ] Hip L/R
- [ ] Thoracic Spine
- [ ] Ankle L/R
- [ ] Wrist L/R
- [ ] Other: _____
- [x] Lumbar Spine
- [ ] Shoulder L/R
- [ ] Elbow L/R

PHYSICIAN'S INORMATION:

Physician Print Name: Jean Pierre Barakat

Physician Address: 62-69 99th Street

City: Rego Park State: NY Zip Code: 11374 Phone: 347-578-875

NPI #: _____ License #: _____

Physician's Signature: _____ Date: 11/14/23

NOTE: Please include all the appropriate Medical Notes with the Prescription

FarRockaway Medical PC

62-69 99th Street. Rego Park, NY 11374 Email. Nyregoparkmedical@gmail.com

Patient's Name Kevin Brown Date: 11/14/23

D.O.A. 10/13/23

----- POSITONING CUSHION
----- INFRA RED LAMP
----- GENERAL USE CUSHION (wide)
----- LUMBER SACRAL SUPPORT
----- DEEP TISUE MASSAGER
----- E M S UNIT FOUR LEAD
----- T.E.N.S. BELT
----- KNEE [ ]BRACE [ ]SUPPORT
----- ARM SLING
----- ANKLE [ ]BRACE [ ]SUPPORT
----- BED BOARD
----- EGG CRATE MATTRESS
----- CERVICAL COLLAR
----- CERVICAL POSTURE PUMP
----- CERVICAL TRACTION W PUMP
----- PARAFFIN BATH
----- THERMAL MOIST HEAT PAD
----- WRIST SUPPORT
----- WATER CIRC HEAT PAD W PUMP
___THERMOPHORE
[ ] OTHER_____

----- ORTHOPEDIC CAR SEAT
----- CERVICAL HEAD HALTER
----- CERVICAL OVER THE DOOR
----- T.E.N.S. ACCESSORIES KIT
----- CRUTCHES
----- CANE
----- ELBOW BRACE
----- HOT / COLD PACK
----- WHIRLPOOL
----- HAND SUPPORT
----- K.O. (CUSTOM FITTED)
----- LSO W/APL CONTROL CUSTOM FITTED
----- TLSO
----- PHILADELPHIA COLLAR
----- PELVIC TRACTION
----- SHOULDER IMMOBILIZER
----- WALKER
----- WHEELCHAIR
----- CERVICAL PILLOW
___SHOULDER [ ] SUPPORT [ ]BRACE

Dr. Jean-Pierre Barakat, MD
LIC No: 250159

847.00☐Cervical spine strain
723.4☐Cervical radiculitis
722.71☐Cervical disc herniation with myelopathy
718.91☐Shoulder derangement
923.00☐Contusion of the shoulder
959.20☐Tendinitis--shoulder/arm
847.20☐Lumbar spine sprain
846.0☐Lumbosacral spine strain
724.4☐Lumbar radiculitis
722.73☐Lumbar disc herniation
844.90 ☐Knee sprain [strain]
717.91☐Knee derangement

FarRockaway Medical PC

62-69 99th Street. Rego Park, NY 11374 Email. Nyregoparkmedical@gmail.com

Patient's Name Kenn Brown Date: 11/14/23

D.O.A. 10/13/23

---- POSITONING CUSHION
---- INFRA RED LAMP
---- GENERAL USE CUSHION (wide)
---- LUMBER SACRAL SUPPORT
---- DEEP TISUE MASSAGER
---- E M S UNIT FOUR LEAD
---- T.E.N.S. BELT
---- KNEE [ ]BRACE [ ]SUPPORT
---- ARM SLING
---- ANKLE [ ]BRACE [ ]SUPPORT
---- BED BOARD
---- EGG CRATE MATTRESS
---- CERVICAL COLLAR
---- CERVICAL POSTURE PUMP
---- CERVICAL TRACTION W PUMP
---- PARAFFIN BATH
---- THERMAL MOIST HEAT PAD
---- WRIST SUPPORT
---- WATER CIRC HEAT PAD W PUMP
___THERMOPHORE
[ ] OTHER_____

---- ORTHOPEDIC CAR SEAT
---- CERVICAL HEAD HALTER
---- CERVICAL OVER THE DOOR
---- T.E.N.S. ACCESSORIES KIT
---- CRUTCHES
---- CANE
---- ELBOW BRACE
---- HOT / COLD PACK
---- WHIRLPOOL
---- HAND SUPPORT
---- K.O. (CUSTOM FITTED)
---- LSO W/APL CONTROL CUSTOM FITTED
---- TLSO
---- PHILADELPHIA COLLAR
---- PELVIC TRACTION
---- SHOULDER IMMOBILIZER
---- WALKER
---- WHEELCHAIR
---- CERVICAL PILLOW
___SHOULDER [ ] SUPPORT [ ]BRACE

Dr. Jean-Pierre Barakat, MD
LIC No: 250159

847.00☐Cervical spine strain
718.91☐Shoulder derangement
847.20☐Lumbar spine sprain
722.73☐Lumbar disc herniation
723.4☐Cervical radiculitis
923.00☐Contusion of the shoulder
846.0☐Lumbosacral spine strain
844.90 ☐Knee sprain [strain]
722.71☐Cervical disc herniation with myelopathy
959.20☐Tendinitis--shoulder/arm
724.4☐Lumbar radiculitis
717.91☐Knee derangement

FarRockaway Medical PC

62-69 99th Street. Rego Park, NY 11374 Email. Nyregoparkmedical@gmail.com

Patient's Name Kevin Brown Date: 11 / 14 / 23

D.O.A. 10 / 13 / 22

---- POSITONING CUSHION
---- INFRA RED LAMP
---- GENERAL USE CUSHION (wide)
---- LUMBER SACRAL SUPPORT
---- DEEP TISUE MASSAGER
---- E M S UNIT FOUR LEAD
---- T.E.N.S. BELT
---- KNEE [ ]BRACE [ ]SUPPORT
---- ARM SLING
---- ANKLE [ ]BRACE [ ]SUPPORT
---- BED BOARD
---- EGG CRATE MATTRESS
---- CERVICAL COLLAR
---- CERVICAL POSTURE PUMP
---- CERVICAL TRACTION W PUMP
---- PARAFFIN BATH
---- THERMAL MOIST HEAT PAD
---- WRIST SUPPORT
---- WATER CIRC HEAT PAD W PUMP
___THERMOPHORE

[ ] OTHER _____

---- ORTHOPEDIC CAR SEAT
---- CERVICAL HEAD HALTER
---- CERVICAL OVER THE DOOR
---- T.E.N.S. ACCESSORIES KIT
---- CRUTCHES
---- CANE
---- ELBOW BRACE
---- HOT / COLD PACK
---- WHIRLPOOL
---- HAND SUPPORT
---- K.O. (CUSTOM FITTED)
---- LSO W/APL CONTROL CUSTOM FITTED
---- TLSO
---- PHILADELPHIA COLLAR
---- PELVIC TRACTION
---- SHOULDER IMMOBILIZER
---- WALKER
---- WHEELCHAIR
---- CERVICAL PILLOW
___SHOULDER [ ] SUPPORT [ ]BRACE

Dr. Jean-Pierre Barakat, MD
LIC No: 250159

847.00☐Cervical spine strain
718.91☐Shoulder derangement
847.20☐Lumbar spine sprain
722.73☐Lumbar disc herniation
723.4☐Cervical radiculitis
923.00☐Contusion of the shoulder
846.0☐Lumbosacral spine strain
844.90 ☐Knee sprain [strain]
722.71☐Cervical disc herniation with myelopathy
959.20☐Tendinitis--shoulder/arm
724.4☐Lumbar radiculitis
717.91☐Knee derangement

FarRockaway Medical PC

OUTCOME ASSESSMENT TESTING SUMMARY REPORT

Dear Patient,

The following exam was created for your doctor to better understand the nature and extent of your injuries, which were sustained below. You will be asked these questions again at your following visit to the doctor. Comparing the answers from your test will help us to monitor your improvement.

Please answer all questions carefully. Make sure all answers are filled out completely. Your answers reflect condition at the time of your questionnaires. Please do not leave any questions blank.

Kevin
First Name

Brown
Last Name

Age 36 Male ✓ Female

Date of Accident 10 / 13 / 2023

Date of Test

Patients Signature

Date 11/14/23

Doctors Signature

Date 11/14/23

HEADACHE DISABILITY INDEX

Patient Name Kevin Brown

Date 11/14/23

INSTRUCTIONS: Please CIRCLE the correct response:

1. I have headache: (1) 1 per month (2) more than 1 but less than 4 per month (3) more than one per week
2. My headache is: (1) mild (2) moderate (3) severe

Please read carefully: The purpose of the scale is to identify difficulties that you may be experiencing because of your headache. Please check off "YES", "SOMETIMES", or "NO" to each item. Answer each question as it pertains to your headache only.

YES	SOMETIMES	NO		
		✓	E1.	Because of my headaches I feel handicapped.
		✓	F2.	Because of my headaches I feel restricted in performing my routine daily activities.
		✓	E3.	No one understands the effect my headaches have on my life.
		✓	F4.	I restrict my recreational activities (eg, sports, hobbies) because of my headaches.
		✓	E5.	My headaches make me angry.
		✓	E6.	Sometimes I feel that I am going to lose control because of my headaches.
		✓	F7.	Because of my headaches I am less likely to socialize.
		✓	E8.	My spouse (significant other), or family and friends have no idea what I am going through because of my headaches.
		✓	E9.	My headaches are so bad that I feel that I am going to go insane.
		✓	E10.	My outlook on the world is affected by my headaches.
		✓	E11.	I am afraid to go outside when I feel that a headaches is starting.
		✓	E12.	I feel desperate because of my headaches.
		✓	F13.	I am concerned that I am paying penalties at work or at home because of my headaches.
		✓	E14.	My headaches place stress on my relationships with family or friends.
		✓	F15.	I avoid being around people when I have a headache.
		✓	F16.	I believe my headaches are making it difficult for me to achieve my goals in life.
		✓	F17.	I am unable to think clearly because of my headaches.
		✓	F18.	I get tense (eg, muscle tension) because of my headaches.
		✓	F19.	I do not enjoy social gatherings because of my headaches.
		✓	E20.	I feel irritable because of my headaches.
		✓	F21.	I avoid traveling because of my headaches.
		✓	E22.	My headaches make me feel confused.
		✓	E23.	My headaches make me feel frustrated.
		✓	F24.	I find it difficult to read because of my headaches.
		✓	F25.	I find it difficult to focus my attention away from my headaches and on other things.

THER COMMENTS:

Examiner

ith permission from: Jacobson GP, Ramadan NM, et al. *The Henry Ford Hospital headache disability inventory (HDI)*. Neurology 1994;44:837-8

NECK DISABILITY INDEX QUESTIONNAIRE

Patient Name Kevin Brown

Date 11/14/23

Please read carefully:

This questionnaire has been designed to enable us to understand how your neck pain has affected your ability to manage everyday life. Please answer every section, and mark in each section only ONE CHOICE which applies to you. We realize that you may consider that two of the statements in any one section relate to you, but please just mark the one box which most closely describes your problem right now.

SECTION 1 – Pain Intensity

A. I have no pain at the moment.
B. The pain is very mild at the moment.
C. The pain is moderate at the moment.
D. The pain is fairly severe at the moment.
E. The pain is very severe at the moment.
F. The pain is the worst imaginable at the moment.

SECTION 2 – Personal Care (washing, dressing, etc.)

A. I can look after myself without causing extra pain.
B. I can look after myself normally but it causes extra pain.
C. It is painful to look after myself and I am slow and careful.
D. I need some help but manage most of my personal care.
E. I need help every day in most aspects of self care.
F. I do not get dressed, wash with difficulty and stay in bed.

SECTION 3 – Lifting

A. I can lift heavy weights without extra pain.
B. I can lift heavy weights but it gives extra pain.
C. Pain prevents me from lifting heavy objects off the floor, but I can manage if they are conveniently positioned, e.g. on a table.
D. Pain prevents me from lifting heavy weights but I can manage light to medium weights if they are conveniently positioned.
E. I can lift very light weights.
F. I cannot lift or carry anything at all.

SECTION 4 – Reading

A. I can read as much as I want with no pain in my neck.
B. I can read as much as I want with slight pain in my neck.
C. I can read as much as I want with moderate pain in my neck.
D. I cannot read as much as I want because of moderate pain in my neck.
E. I can hardly read at all because of severe pain in my neck.
F. I cannot read at all.

SECTION 5 – Headaches

A. I have no headaches at all.
B. I have slight headaches which come infrequently.
C. I have moderate headaches which come infrequently.
D. I have moderate headaches which come frequently.
E. I have severe headaches which come frequently.
F. I have headaches almost all the time.

SECTION 6 – Concentration

A. I can concentrate fully when I want to with no difficulty.
B. I can concentrate fully when I want to with slight difficulty.
C. I have a fair degree of difficulty in concentrating when I want to.
D. I have a lot of difficulty in concentrating when I want to.
E. I have a great deal of difficulty in concentrating when I want to.
F. I cannot concentrate at all.

SECTION 7 – Work

A. I can do as much work as I want to.
B. I can only do my usual work, but no more.
C. I can do most of my usual work, but no more.
D. I cannot do my usual work.
E. I can hardly do any work at all.
F. I cannot do any work at all.

SECTION 8 – Driving

A. I can drive without any neck pain.
B. I can drive as long as I want with slight pain in my neck.
C. I can drive as long as I want with moderate pain in my neck.
D. I cannot drive as long as I want because of moderate pain in my neck.
E. I can hardly drive at all because of severe pain in my neck.
F. I cannot drive my car at all.

SECTION 9 – Sleeping

A. I have no trouble sleeping.
B. My sleep is slightly disturbed (less than 1 hr. sleepless).
C. My sleep is mildly disturbed (1-2 hrs. sleepless).
D. My sleep is moderately disturbed (2-3 hrs. sleepless).
E. My sleep is greatly disturbed (3-5 hrs. sleepless).
F. My sleep is completely disturbed (5-7 hrs. sleepless).

SECTION 10 – Recreation

A. I am able to engage in all my recreation activities with no neck pain at all.
B. I am able to engage in all my recreation activities with some pain in my neck.
C. I am able to engage in most, but not all of my usual recreation activities because of pain in my neck.
D. I am able to engage in a few of my usual recreation activities because of pain in my neck.
E. I can hardly do any recreation activities because of pain in my neck.
F. I cannot do any recreation activities at all.

OTHER COMMENTS:

Examiner

With Permission from: Vernon H, Mior S. The Neck Disability Index: *A study of reliability and validity*. J Manipulative Physiol Ther 1991;14:409-415. Copyright © Vernon H and Hagino C, 1990.

SHOULDER PAIN AND DISABILITY INDEX (SPADI)

Patient Name Kevin Brown

Date 11/14/23

Please read carefully:

Instructions: Please circle the number that best describes the question being asked

Pain scale:
No pain at all 0 1 2 3 4 5 6 7 8 9 10 Worst pain Imaginable

How severe is your pain?

1. At its worst?
0 1 2 3 4 5 6 7 8 9 10

2. When lying on the involved side?
0 1 2 3 4 5 6 7 8 9 10

3. Reaching for something on a high shelf?
0 1 2 3 4 5 6 7 8 9 10

4. Touching the back of your neck?
0 1 2 3 4 5 6 7 8 9 10

5. Pushing with the involved arm?
0 1 2 3 4 5 6 7 8 9 10

Disability scale:
No difficulty 0 1 2 3 4 5 6 7 8 9 10 So difficult it requires help

How much difficulty do you have?

1. Washing your hair?
0 1 2 3 4 5 6 7 8 9 10

2. Washing your back?
0 1 2 3 4 5 6 7 8 9 10

3. Putting on an undershirt or pullover sweater?
0 1 2 3 4 5 6 7 8 9 10

4. Putting on a shirt that buttons down the front?
0 1 2 3 4 5 6 7 8 9 10

5. Putting on your pants?
0 1 2 3 4 5 6 7 8 9 10

6. Placing an object on a high shelf?
0 1 2 3 4 5 6 7 8 9 10

7. Carrying a heavy object of 10 pounds?
0 1 2 3 4 5 6 7 8 9 10

8. Removing something from your back pocket?
0 1 2 3 4 5 6 7 8 9 10

:R COMMENTS:

ner:

mission from: Williams JW Jr., Hollenman DR Jr., Simel DL: Measuring shoulder function with the Shoulder Pain and Disability Index. atol 1995; 22 (4); 727-732

REVISED OSWESTRY BACK PAIN DISABILITY QUESTIONNAIRE

Name _____ Date _____

Please read carefully:

This questionnaire has been designed to enable us to understand how your back pain has affected your ability to manage your day to day life. Please answer every section, and mark in each section only ONE CHOICE which applies to you. We realize that you may consider that two of the statements in any one section relate to you, but please just mark the one box which most closely describes your problem right now.

SECTION 1 – Pain Intensity

A. The pain comes and goes and is very mild.
B. The pain is mild and does not vary much.
C. The pain comes and goes and is moderate.
D. The pain is moderate and does not vary much.
E. The pain comes and goes and is severe.
F. The pain is severe and does not vary much.

SECTION 2 – Personal Care

A. I would not have to change my way of washing or dressing in order to avoid pain.
B. I do not normally change my way of washing or dressing even though it causes some pain.
C. Washing and dressing increases the pain, but I manage not to change my way of doing it.
D. Washing and dressing increases the pain and I find it necessary to change my way of doing it.
E. Because of the pain, I am unable to do some washing and dressing without help.
F. Because of the pain, I am unable to do any washing or dressing without help.

SECTION 3 – Lifting

A. I can lift heavy weights without extra pain.
B. I can lift heavy weights but it gives me extra pain.
C. Pain prevents me from lifting heavy weights off the floor.
D. Pain prevents me from lifting heavy weights off the floor, but I can manage if they are conveniently positioned-eg, on a table
E. Pain prevents me from lifting heavy weights, but I can manage light to medium weights if they are conveniently positioned.
F. I can only lift very light weights, at the most.

SECTION 4 – Walking

A. Pain does not prevent me from walking any distance.
B. Pain prevents me from walking more than 1 mile.
C. Pain prevents me from walking more than ½ mile.
D. Pain prevents me from walking more than ¼ mile.
E. I can only walk using a stick or crutches.
F. I am in bed most of the time and have to crawl to the toilet.

SECTION 5 – Sitting

A. I can sit in any chair as long as I like without pain.
B. I can only sit in my favorite chair as long as I like.
C. Pain prevents me sitting more than 1 hour.
D. Pain prevents me sitting more than ½ hour.
E. Pain prevents me sitting more than 10 minutes.
F. Pain prevents me from sitting at all.

OTHER COMMENTS:

_____

_____

SECTION 6 – Standing

A. I can stand as long as I want without pain.
B. I have some pain while standing, but it does not increase with time.
C. I cannot stand for longer than 1 hour without increasing pain.
D. I cannot stand for longer than ½ hour without increasing pain.
E. I cannot stand for longer than 10 minutes without increasing pain.
F. Pain prevents me from standing at all.

SECTION 7 – Sleeping

A. I get no pain in bed.
B. I get pain in bed, but it does not prevent me from sleeping well.
C. Because of pain, my normal night's sleep is reduced by less than one-quarter.
D. Because of pain, my normal night's sleep is reduced by more than one-half.
E. Because of pain, my normal night's sleep is reduced by more than three-quarters.
F. Pain prevents me from sleeping at all.

SECTION 8 – Social Life

A. My social life is normal and gives me no pain.
B. My social life is normal, but increases the degree of my pain.
C. Pain has no significant effect on my social life apart from limiting my more energetic interests, eg, dancing, etc.
D. Pain has restricted my social life and I do not go out very often.
E. Pain has restricted my social life to my home.
F. I have hardly any social life because of the pain.

SECTION 9 – Traveling

A. I get no pain while traveling.
B. I get some pain while traveling but none of my usual forms of travel make it any worse.
C. I get extra pain while traveling but it does not compel me to seek alternative forms of travel.
D. I get extra pain while traveling which compels me to seek alternative forms of travel.
E. Pain restricts all forms of travel.
F. Pain prevents all forms of travel except that done lying down.

SECTION 10 – Changing Degree of Pain

A. My pain is rapidly getting better.
B. My pain fluctuates, but overall is definitely getting better.
C. My pain seems to be getting better, but improvement is slow at present.
D. My pain is neither getting better nor worse.
E. My pain is gradually worsening.
F. My pain is rapidly worsening.

_____
Examiner

With Permission from: Hudson-Cook N, Tomes-Nicholson K, Breen AC. A Revised Oswestry Back Disability Questionnaire. Manchester Univ Press, 1989.

ROLAND-MORRIS QUESTIONNAIRE

Date _____

Patient Name _____

Please read carefully:
When your back hurts, you may find it difficult to do some of the things you normally do. Mark only the sentences that describe you today.

1. ✓ I stay at home most of the time because of my back.
2. ✓ I change positions frequently to try and get my back comfortable.
3. ✓ I walk more slowly than usual because of my back.
4. ___ Because of my back, I am not doing any of the jobs that I usually do around the house.
5. ✓ Because of my back, I use a handrail to get upstairs.
6. ✓ Because of my back, I lie down to rest more.
7. ___ Because of my back, I have to hold on to something to get out of an easy chair.
8. ___ Because of my back, I try to get other people to do things for me.
9. ✓ I get dressed more slowly because of my back.
10. ✓ I only stand up for short periods of time because of my back.
11. ✓ Because of my back, I try not to bend or kneel.
12. ___ I find it difficult to get out of a chair because of my back.
13. ___ My back is painful almost all of the time.
14. ___ I find it difficult to turn over in bed because of my back.
15. ✓ My appetite is not very good because of my back.
16. ✓ I have trouble putting on my socks/stockings because of my back.
17. ✓ I only walk short distances because of my back pain.
18. ✓ I sleep less well because of my back pain.
19. ___ Because of my back pain, I get dressed with help from someone else.
20. ___ I sit down for most of the day because of my back.
21. ___ I avoid heavy jobs around the house because of my back.
22. ___ Because of my back pain, I am more irritable and bad tempered with people than usual.
23. ___ Because of my back, I go upstairs more slowly than usual.
24. ___ I stay in bed most of the day because of my back.

OTHER COMMENTS:

_____

_____

_____

_____

Examiner

With Permission from: Roland M, Morris R. *A study of the natural history of back pain: Part I: Development of a reliable and sensitive measure of disability in low-back pain.* Spine 1983;8:141-144.

SUBJECTIVE KNEE SCORE QUESTIONNAIRE

Date _____

Patient Name _____

Please read carefully:
Please answer every section, and mark in each section only ONE CHOICE which applies to you. We realize that you may consider that of the statements in any one section relate to you, but please just mark the one box which most closely describes your problem right now.

PAIN
( ) I experience no pain in my knee.
( ) I have occasional pain with strenuous sports or heavy work. I don't think that my knee is entirely normal. Limitations are mild and to
( ) There is occasional pain in my knee with light recreational sports or moderate work.
( ) I have pain brought on by sports, light recreational activities, or moderate work. Occasional pain is brought on by daily activities s
standing or kneeling.
( ) The pain I have in my knee is a significant problem with activities as simple as walking. The pain is relieved by rest I can't participate

SWELLING
( ) I experience no swelling in my knees.
( ) I have occasional swelling in my knee with strenuous sports or heavy work.
( ) There is occasional swelling with light recreational activities or moderate work.
( ) Swelling limits my participation in sports and moderate work. Occurs infrequently with simple walking or light work. Occasionally with
walking or light work – about 3 times a year.
( ) My knee swells after simple walking activities and light work. Rest relieves the swelling.
( ) I have severe swelling with simple walking activities. Rest does not relieve the swelling.

STABILITY
( ) My knee does not give out.
( ) My knee gives out only with strenuous sports or heavy work.
( ) My knee gives out occasionally with light recreational activities or moderate work; it limits my vigorous activities, sports, or heavy
( ) Because my knee gives out, it limits all sports and moderate work. It occasionally gives out with walking or light work.
( ) My knee gives out frequently with simple activities such as walking. I must guard my knee at all times.
( ) I have severe problems with my knee giving out. I can't turn or twist without my knee giving out.

OVERALL ACTIVITY LEVEL
( ) No limitations, I have a normal knee, and I am able to do everything including strenuous sports and/or heavy labor.
( ) I can partake in sports including strenuous ones but at a lower level. I must guard my knee and limit the amount of heavy labor or s
( ) Light recreational activities are possible with RARE symptoms. I am limited to light work.
( ) No sports or recreational activities are possible. Walking activities are possible with RARE symptoms. I am limited to light work.
( ) Walking activities and daily living cause moderate problems and persistent symptoms.
( ) Walking and other daily activities cause severe problems.

WALKING
( ) Normal, unlimited
( ) Slight, mild problems.
( ) Moderate problem, flat surface up to half a mile.
( ) Severe problems, only 2-3 blocks.
( ) Severe problems, need cane or crutches.

STAIRS
( ) Normal, unlimited
( ) Slight, mild problems.
( ) Moderate problem, only 10-15 steps possible.
( ) Severe problems, require banister for support.
( ) Severe problems, only 1-5 steps without support.

RUNNING
( ) Normal, unlimited, fully competitive.
( ) Slight, mild problems, run at half speed.
( ) Moderate problems, only 1-2 miles possible.
( ) Severe problems, only 1-3 blocks possible.
( ) Severe problems, only a few steps.

JUMPING AND TWISTING
( ) Normal, unlimited, fully competitive.
( ) Slight, mild problems, some guarding.
( ) Moderate problems, gave up strenuous sports.
( ) Severe problems, affects all sports, always guarding.
( ) Severe problems, only light activity possible (pool/swim).

Other: _____

permission from: Noyes FR, et al. Functional disability in the anterior cruciate insufficient knee syndrome. Review of knee rating systems and factors in determining treatment. Sports Med 1984; 1: 278-302. Copyright Adis International, Inc.

Cypress Rx Inc.
11-05 Cypress Ave Ridgewood, NY 11385
Phone: (347)599-1805 Fax: (347)599-1806 Prnt Dt: 11/21/2023 9:28:33AM

Rx Pres: Jean Pierre Barakat
795 Todt Hill Road
STATEN ISLAND, NY 1030 Phn: (626)399-1079
Fax: (626)399-1079

Ord: 11/15/2023
NPI# 1205086329
LIC# 250159
DEA# FB1087065
SPI 6588597883017

Patient: Brown, Kevin
DOB: 07/09/1987 Gender: M
Address: 67-23 Elliot AvenueRego park
FLUSHING, NY 11379
Rx#: 62571
Phone (646)644-4417
Qty: 60.000 (Sixty)
Days: 30 Refills: 0 PH/TH: NT Class: 0
Potency UnitCd: Patch
Drug: lidocaine patch: Lidocaine 4.5% and menthol 5%

Sig: Apply to affected area 12 hrs on 12 hrs off as needed

Signature Date

This Prescription Will be Filled Generically Unless Prescriber Writes "DAW [1]" in the Box [ ] N Dispense As Written

11/15/2023 1:42 PM MessageType: New Prescription

From: 6588597883017

Msg.Id: NEWRX-1-138080764 To: 5838404
Prs. Order Ref: 156640640

Resp.Status: Ready To Process

lidocaine patch: Lidocaine 4.5% and menthol 5%

Electronic Rx

RX#:62571 Rph: NT D/F 11/21/2023
BROWN, KEVIN D/O 11/15/2023
67-23 ELLIOT AVE FLUSHING NY 11379 DOB 7/9/1987
APPLY 1-2 PATCHES DAILY TO AFFECTED AREA(S)
KEEP PATCH 12 HRS ON AND 12 HRS OFF AS
NEEDED FOR MUSCLE PAIN
#: 60 LIDOTHOL FILM 4.5-5%
NDC: 53225-1025-01 DAW: N D/S: 30 [ELECTRONIC]
Dr. BARAKAT, J (347)649-1714 1205086329 FB1087065
62-69 99 ST REGO PARK NY 11374
Copay: $0.00 Ins: $2389.00 Total: $2389.00 Cost: $0.0 Refills: 0.00

Cypress Rx Inc.
11-05 Cypress Ave Ridgewood, NY 11385
Phone: (347)599-1805 Fax: (347)599-1806 Prnt Dt: 11/21/2023 9:28:55AM

Rx Pres: Jean Pierre Barakat
795 Todt Hill Road
STATEN ISLAND, NY 1030 Phn: (626)399-1079
Fax: (626)399-1079

Ord: 11/15/2023
NPI# 1205086329
LIC# 250159
DEA# FB1087065
SPI: 6588597883017

Patient: Brown, Kevin
DOB: 07/09/1987 Gender M
Address: 67-23 Elliot AvenueRego park Rx#: 62572
FLUSHING, NY 11379
Phone (646)644-4417
Qty: 60.000 (Sixty)
Days: 30 Refills: 0 PII/TIE NT Class: 0
Potency UnitCd: Capsule
Drug: diclofenac potassium 25 mg capsule 25 Capsule

Sig: Take 1 Capsule(s) by oral route every 12 Hour(s)

Signature Date

This Prescription Will be Filled Generically Unless Prescriber Writes "DAW [1]" in the Box
N
Dispense As Written

11/15/2023 1:42 PM MessageType: New Prescription
From 6588597883017
Msg.Id: NEWRX-1-138080763 To: 5838404
Prs. Order Ref : 156640639

Resp.Status: Ready To Process

Prescribers Note: As needed

Electronic Rx

RX#:62572
BROWN, KEVIN
67-23 ELLIOT AVE FLUSHING NY 11379
Rph: NT
D/F 11/21/2023
D/O 11/15/2023
DOB: 7/9/1987
TAKE 1 CAPSULE(S) BY ORAL ROUTE EVERY 12 HOUR(S)

#: 60 DICLOFENAC POTASSIUM CAP 25MG
NDC: 74157-0095-60 DAW: N D/S: 30 [ELECTRONIC]
Dr. BARAKAT, J (347)649-1714 1205086329 FB1087065
62-69 99 ST REGO PARK NY 11374
Copay: $0.00 Ins: $854.22 Total: $854.22 Cost: $0.00 Refills: 0.00

Health Source RX Inc.
6815 Fresh Meadow Ln **Fresh Meadows, NY 11365**
Phone: **(347)408-4004** Fax: **(347)408-4005** **Prnt Dt:** 11/15/202311:29:54PM

Rx Pres: Jean Pierre Barakat
795 Todt Hill Road
STATEN ISLAND, NY 103(Phn: (626)399-1079
Fax: (626)399-1079

Ord: 11/15/2023
NPI# 1205086329
LIC# 250159
DEA# FB1087065
SPI: 6588597883017

Patient: Brown, Kevin
DOB: 07/09/1987 **Gender** M
Address: 67-23 Elliot AvenueRego park **Rx#:** 65870
FLUSHING, NY 11379
Phone (646)644-4417
Qty: 250.000 (Two Hundred Fifty)
Days: 30 **Refills:** 0 **PH/TH:** NP **Class:** 0
Potency UnitCd: Gram
Drug: lidocaine 5 % topical ointment 5 Ointment

Sig: ap aa up to tid

Signature **Date**

This Prescription Will be Filled Generically Unless Prescriber Writes "DAW [1]" in the Box

[ ] N
Dispense As Written

Electronic Rx

11/15/2023 1:42 PM **MessageType:** New Prescription
From: 6588597883017
To: 5839141

Msg.Id: NEWRX-1-138080739
Prs. Order Ref : 156640612

Resp.Status: Ready To Process

lidocaine 5 % topical ointment

Farrockaway Medical PC
62-69 99th St
Rego Park, NY 11374
nyregoparkmedical@gmail.com

DATE: 12/12/23

FOLLOW UP REPORT: 2

DATE OF ACCIDENT: 10/13/23

PATIENT'S NAME: Kevin Brown

AGE: 36

AT THE TIME OF THE INITIAL EVALUATION PATIENT PRESENTED COMPLAINTS OF:

HEADACHE DIFUSES FRONTAL TEMPORAL OCCIPITAL VOMITIMG
NECK PAIN DIZZINESS BLURRED VISION
LOWER BACK PAIN NON-RADIATING RADIATING TO _____
MID BACKPAIN NON-RADIATING RADIATING TO _____
SHOULDERS NON-RADIATING RADIATING TO _____
WRIST RT LT TINGLING NUMBNESS
ELBOWS RT LT TINGLING NUMBNESS
HANDS RT LT TINGLING NUMBNESS
HIPS RT LT TINGLING NUMBNESS
KNEES RT LT TINGLING NUMBNESS
ANKLES RT LT TINGLING NUMBNESS
FEET RT LT TINGLING NUMBNESS & left
CHEST RT LT TINGLING NUMBNESS
ABDOMEN
NERVOUNESS
INSOMNIA ANXIETY FEAR DRIVING/SITTING IN THE CAR FEAR OF CROSSING STREET
OTHER

Outcome Assessment results discussed thoroughly with patient

ECN: 2024012403027 Received Date: 2024-01-24

PRESENT COMPLAINTS

HEAD
FACE
NECK
CHEST
THORACIC SPINE
LOWER BACK
STRESS
HEADACHES
VOMITING

SACRAL AREA
PELVIS
SHOULDER RT LT
ELBOWS RT LT
WRIST RT LT
HAND RT LT
SPEECH
BLURRED VISION
NERVOUSNESS/INSOMNIA

HIPS RT LT
KNEES RT LT
ANKLES RT LT
FEET RT LT
ABDOMEN RT LT
OTHER _____
FEAR OF DRIVING
SITTING IN CAR
CROSSING THE STREET

PHYSICAL EXAMINIATION REVEALED:

B/P ___/___ PULSE ____ RR ____ AFEBRILE FEBRILE

PATIENT IS AAOX3, MEMORY [4] IS INTACT [ ] HAS POOR MEMORY SINCE THE ACCIDENT
SPEECH IS FLUENT AND COHERENT
PATIENT APPEARS TO BE IN [ ] MILD [ ] MODERATE [ ] SEVERE DISTRESS DUE TO PAIN AND DISCOMFORT
PATIENT IS NOT IN ACUTE DISTRESS, BUT FEELS QUITE UNCOMFORTABLE AND TENSE
S1S2R LUNGS ABDOMEN SOFT, NT

CERVICAL SPINE

PALPATION OF THE NECK REVEALS DOES NOT REVEAL MILD MODERATE SEVERE CERVICAL
SPINE TENDERNESS AT THE C__ C__ LEVEL NO STEP OFF APPRECIATED
INCREASE IN R L MUSCLE TONE ION PARAVERTEBRAL TRAPEZIUS RHOMBOID MUSCLE
NORMAL EXAMINATION OF THE CERVICAL SPINE

SPECIAL TEST AND SIGNS

DISTRACTION TEST	POSTIVE	NEGATIVE
COMPRESSION TEST	POSTIVE	NEGATIVE
SHOULDER DEPRESSION TEST	POSTIVE	NEGATIVE
FORAMINA COMPRESSION TEST	POSTIVE	NEGATIVE

NORMAL ROM		PATIENT'S ROM	PAIN
FLEXION	45	FROM ROM___	POSITIVE
EXTENSION	55	FROM ROM___	POSITIVE
RIGHT ROTATION	70	FROM ROM___	POSITIVE
LEFT ROTATION	70	FROM ROM___	POSITIVE
RIGHT LATERAL FLEXION	40	FROM ROM___	POSITIVE
LEFT LATERAL FLEXION	40	FROM ROM___	POSITIVE

THORACIC SPINE:

THERE APPEARS TO BE TENDRNESS OF THE THORACIC SPINE AT LEVELS T____T____ WITH SPASM OF RIGHT LEFT PARASPINAL STRUCTURES
THERE IS NO TENDERNESS OR PAIN ON PALPATION

LUMBOSACRAL SPINE

PALPATION OF LUMBOSACRAL SPINE REVEALS DOES NOT REVEAL MILD MODERATE SEVERE
TENDERNESS AT THE L___L___S___ LEVEL
INCREASE IN RIGHT LEFT PARAVERETEBRAL MUSCLE TONE
NORMAL EXAMINATION OF THE LUMBOSACRAL SPINE

SPECIAL TEST AND SIGNS:

SPINAL PRECUSSION TEST	POSITIVE	NEGATIVE
FABERE- PATRICK TEST	POSITIVE	NEGATIVE
STRAIGHT LEG RAISE TEST	POSITIVE @___ ON THE RT @___ ON THE LT	NEGATIVE

ECN: 2024012403027 Received Date: 2024-01-24

	NORMAL ROM	PATIENT'S ROM	PAIN
FLEXION	90	☐ FROM ☐ ROM 75	☐ POSITIVE
EXTENTSION	30	☐ FROM ☐ ROM 25	☐ POSITIVE
RIGHT ROTATION	30	☐ FROM ☐ ROM 20	☐ POSITIVE
LEFT ROTATION	30	☐ FROM ☐ ROM ___	☐ POSITIVE
RIGHT LATERAL FLEXION	35	☐ FROM ☐ ROM ___	☐ POSITIVE
LEFT LATERAL FLEXION	35	☐ FROM ☐ ROM ___	☐ POSITIVE

SHOULDER:	NORMAL ROM	PATIENT'S ROM	RIGHT	LEFT
FLEXION/ ELEVATION	180	☐ FROM ☐ ROM ___	___	___
EXTENSION	50	☐ FROM ☐ ROM ___	___	___
ABDUCTION	180	☐ FROM ☐ ROM ___	___	___
ADDUCTION	50	☐ FROM ☐ ROM ___	___	___
INTERNAL ROTATION	90	☐ FROM ☐ ROM ___	___	___
EXTENAL ROTATION	90	☐ FROM ☐ ROM ___	___	___

☐ CREPITUS IS APPRECIATED ☐ RIGHT ☐ LEFT SUBACROMAL / SUBDALTOID BURSA

☐ ABLE ☐ UNABLE TO ELEVATE AND HOLD ☐ RIGHT ☐ LEFT ARM AT ABOVE SHOULDER LEVEL

☐ TENDERNESS ☐ AT CREPITUS AT AC JOINT ☐ AT THE LEVEL OF ROTATOR CUFF INSERTION (LIGAMENTS OF SIT MUSCLES)

ELBOWS:	NORMAL ROM	PATIENT'S ROM	RIGHT	LEFT
FLEXION	160	☐ FROM ☐ ROM	___	___
EXTENSION	180	☐ FROM ☐ ROM	___	___
SUPINATION	90	☐ FROM ☐ ROM	___	___
PRONATION	90	☐ FROM ☐ ROM	___	___

☐ CREPITUS IS APPRECIATED ☐ RIGHT ☐ LEFT

WRIST:	NORMAL ROM	PATIENT'S ROM	RIGHT	LEFT
FLEXION	160	☐ FROM ☐ ROM	___	___
EXTENSION	180	☐ FROM ☐ ROM	___	___
SUPINATION	90	☐ FROM ☐ ROM	___	___
PRONATION	90	☐ FROM ☐ ROM	___	___

CREPITUS IS APPRECIATED IS APPREICATED ☐ RIGHT ☐ LEF

HIPS:	NORMAL ROM	PATIENT'S ROM	RIGHT	LEFT
FLEXION	120	FROM ROM		
EXTENSION	15	FROM ROM		
ABDUCTION	45	FROM ROM		
INTERNAL ROTATION	40	FROM ROM		
EXTERNAL ROTATION	45	FROM ROM		

CREPITUS IS APPRECIATED RIGHT LEFT

KNEES:	NORMAL ROM	PATIENT'S ROM	RIGHT	LEFT
FLEXION	130	FROM ROM		
EXTENSION	15	FROM ROM		
		FROM ROM		

CREPITUS IS APPRECIARED

BULGE/ BALLOTING SIGNOF THE PATELLA IS IS NOT PRESENT ON RIGHT LEFT
ANTERIOR DRAWS SIGN IS POSTIVE NEGATIVE ON RIGHT LIGHT
LACHMAN TEST IS POSITIVE NEGATIVE ON RIGHT LEFT
VARUS STRESS TEST DETECTING mol IS POSITIVE NEGATIVE
VALGUS STRESS TEST DETECTING LCL IS POSTIVE NEGATIVE

ANKLES:	NORMAL ROM	PATIENT'S ROM	RIGHT	LEFT
DORSI FLEXION	20	FROM ROM		
PLANTER EXTENSION	45	FROM ROM		
INVERSION	30	FROM ROM		
EVERSION	20	FROM ROM		

CREPITUS IS APPRECIATED RIGHT LEFT
SWELLING/ EDEMA IS APPRECIATED ON RIGHT LEFT
MEDIAL LATERAL MALLEOLI

ECN: 2024012403027 Received Date: 2024-01-24

19 Pages Via SFTP Sat, 27 Jan 2024 16:18:45 GMT

MOTOR SYSTEMS

MOTOR MUSCLES TEST WERE _____ THROUGHOUT
NO MUSCLE ATHROPHY IS NOTED
DEEP TENDON REFLEXES ARE BILATERALLY EQUAL AND SYMMETRIC; DTR'S ARE _____ THROUGHOUT
TOES ARE DOWNGOING BILATERALLY

SENSORY SYSTEMS

SENSORY EXAMINATION OF UPPE EXTREMITIES REVEALS DECREASED RESPONSE TO LIGHT, TOUCH AND PINPRICK SENSATION IN:

R L TRAPEZUIS (C3-C4) NERVE DISTRIBUTION
R L DELTOID (C5-C6) NERVE DISTRIBUTION
R L BICEP (C6) NERVE DISTRIBUTION
R L RADIAL (C6-C7) NERVE DISTRIBUTION
R L MEDIAN (C7-C9) NERVE DISTRIBUTION
R L ULNAR (C8-T1) NERVE DISTRIBUTION

TINEL'S SIGN	+	-@ RIGHT	+	-@ LEFT
FINKEL STEIN'S TEST	+	-@ RIGHT	+	-@ LEFT
PHALEN'S SIGN	+	-@ RIGHT	+	-@ LEFT

SENSORY EXAMINATION OF UPPER EXREMITTIES REVEALS NORMAL SENSITIVITY

SENSORY EXAMINATION OF LOWER EXTREMITIES REVEALS DECREASED RESPONSE TO LIGHT, TOUCH AND PINPRICK SENSATION IN:

R L GLUTEL (L-5) NERVE DISTRIBUTION
R L VASTUS (L3- L4) NERVE DISTRIBUTION
R L SCIARIA (LS- S2) NERVE DISTRIBUTION
R L TIBIAL ANTERIOR (L4-L5) NERVE DISTRIBUTION
R L PERNONEUS (L5-S1) NERVE DISTRIBUTION
R L GASTROCNEMIUS (L4- S1) NERVER DISTRIBUTION

SENSORY EXAMINATION OF THE UPPER EXTREMITTIES REVEALS NORMAL SENSITIVITY

ECN: 2024012403027 Received Date: 2024-01-24

DIAGNOSTIC RESULTS:

X-RAY OF_____ WAS DONE __/__/__ AND DEMONSTRATED _____

X-RAY OF_____ WAS DONE __/__/__ AND DEMONSTRATED _____

X-RAY OF_____ WAS DONE __/__/__ AND DEMONSTRATED _____

MRI/CT OF [illegible] WAS DONE 11/1/23 AND DEMONSTRATED [illegible]

MRI/CT OF_____ WAS DONE __/__/__ AND DEMONSTRATED _____

MRI/CT OF_____ WAS DONE __/__/__ AND DEMONSTRATED _____

MRI/CT OF_____ WAS DONE __/__/__ AND DEMONSTRATED _____

MRI/CT OF_____ WAS DONE __/__/__ AND DEMONSTRATED _____

MRI/CT OF_____ WAS DONE __/__/__ AND DEMONSTRATED _____

CS DB3-4
6-1

DH5-1

DHR-1

ECN: 2024012403027 Received Date: 2024-01-24

BASE ON THE ABOVE FINDINGS, ADDITIONAL TEST AND THERAPY INDICATED:

CONTINUE PHYSICAL THERAPY 3-4 TIMES PER WEEK

X-RAY(S) OF THE _____ TO RULE OUT FRACTURE

MRI/CT SCAN OF _____ TO RULE OUT

NEUROLOGIST CONSULTATION TO RULE OUT _____

PHYSCHOLOGIST CONSULTATION TO RULE OUT _____

ORTHOPEDIC CONSULTATION TO RULE OUT _____

ADDITIONAL THERAPEUTIC EQUIPMENT SUCH AS

OTHER

PATIENT WILL BE RE- EVALUATED IN 3-4 WEEK

PATIENT WAS DISCHARGED SINCE SYMPTOMS IMPROVED WITH PHYSCIAL THERAPY

RESPECTUFULLY SUMITTED,

JEAN-PIERRE GEORGES BARAKAT, MD
INTERNAL MEDICINE

ECN: 2024012403027 Received Date: 2024-01-24

DIAGNOSIS IMPRESSIONS: ICD 10

	CERVICAL SPINE DX		HIPS
M542	CERVICALGIA	M25.551	PAIN IN RIGHT HIP
S13.4XXA	SPRAIN OF LIGAMENTS OF C/S IE	M25.552	PAIN IN LEFT HIP
S13.0XXA	SPRAIN OF JOINTS & LIGAMNETS OF OTHER PARTS OF NECK, IE	S73.301A	UNSPECIFIED SPRAIN OF RIGHT HIP, IE
S16.1XXA	STRAIN OF MUSCLE, FASCIA AND TENDON AT NECK LEVEL, IE	S73.302A	UNSPECIFIED SPRAIN OF LEFT HIP, IE
M54.11	RADICULOPATHY, OCCIPITO-ATLANTO-AXIAL REGION		KNEES
M54.12	RADICULOPATHY, CERVICAL REGION	M25.561	PAIN IN RIGHT KNEE
M54.13	RADICULOPATHY, CERVICOTHORACIC REGION	M25.562	PAIN IN LEFT KNEE
M50.20	OTHER CERVICAL DISC DISPLACEMENT, UNSP. CERVICAL REG.	S83.90XA	SPRAIN OF UNSPECIFIED SITE OF RIGHT
M50.21	OTHER CERVICAL DISC DISPLACEMENT, HIGH CERVICAL REGION	S83.91XA	SPRAIN OF UNSPECIFIED SITE OF LEFT K
M50.22	OTHER CERVICAL DISC DISPLACEMENT, MID-CERVICAL REGION	S80.01XA	CONTUSION OF RIGHT KNEE, IE
M50.23	OTHER CERVICAL DISC DISPLACEMENT, CERVICOTHORACIC	S80.02XA	CONTUSION OF LEFT KNEE, IE
M99.01	SEGMENTAL & SOMATIC DYSFUNCTION OF CERVICAL REGION	S83.206A	UNSP TEAR, OF UNSP MENISCUS, CURRENT INJURY,
M79.1	MYALGIA	S83.207A	UNSP TEAR, OF UNSP MENISCUS, CURRENT INJURY,
	THORACIC SPINE DX		ANKLE/FOOT
M54.6	PAIN IN THORACIC SPINE	S93.401A	SPRAIN OF UNSPECIFIED LIGAMENT O
S23.3XXA	SPRAIN OF LIGAMENTS OF THORACIC SPINE, IE	S93.402A	SPRAIN OF UNSPECIFIED LIGAMENT O
S23.8XXA	SPRAIN OF OTHER SPECIFIED PARTS OF THORAX, IE	M25.571	PAIN IN RIGHT ANKLE & JOINTS OF RI
M51.34	INTERVERTEBRAL DISC DISORDER WITH RADIC, THORACIC REG	M25.572	PAIN IN LEFT ANKLE & JOINTS OF LEF
M51.35	INTERVERTEBRAL DISC DISORDER WITH RADIC, THORACOLUMBAR		SHOULDERS
M54.14	RADICULOPATHY, THORACIC REGION	S43.401A	UNSPECIFIED SPRAIN OF RIGHT SHOU
M54.15	RADICULOPATHY, THORACOLUMBAR REGION	S43.402A	UNSPECIFIED SPRAIN OF LEFT SHOUL
M51.24	OTHER INTERVERTEBRAL DISC DISPLACEMENT, THORACIC REG	M25.511	PAIN, RIGHT SHOULDER
M54.25	OTHER INTERVERTEBRAL DISC DISPLACEM., THORACOLUMBAR	M25.512	PAIN, LEFT SHOULDER
M99.02	SEGMENTAL & SOMATIC DYSFUNCTION OF THORACIC REGION	S46.011A	STRAIN/TEAR OF MUSCLE AND TEN RIGHT
	LUMBAR—LUMBOSACRAL DX	S46.012A	STRAIN/TEAR OF MUSCLE AND TEN LEFT
M54.5	LOW BACK PAIN	S40.011A	CONTUSION OF RIGHT SHOULDER,
S33.5XXA	SPRAIN OF LIGAMENTS OF LUMBAR SPINE, IE	S40.012A	CONTUSION OF LEFT SHOULDER,
S33.9XXA	SPRAIN OF UNSPESIFIED PARTS OF LUMBAR SPINE & PELVIS, IE		MISCELLANEOUS
M51.16	INTERVERTEBRAL DISC DISORDER WITH RADIC, LUMBAR REG	M62.830	MUSCLE SPASM OF BACK
M51.17	INTERVERTEBRAL DISC DISORDER WITH RADIC, LUMBOSACRAL	M62.81	MUSCLE WEAKNESS
M54.16	RADICULOPATHY, LUMBAR REGION	M79.1	MYALGIA
M54.17	RADICULOPATHY, LUMBOSACRAL REGION	R42	DIZZINESS
M51.26	OTHER INTERVERTEBRAL DISC DISPLACEMENT, LUMBAR REG	R45	NERVOUSNESS
M51.27	OTHER INTERVERTEBRAL DISC DISPLACEMENT, LUMBOSACRAL	R51	HEADACHE (UNSPECIFIED)
M99.03	SEGMENTAL & SOMATIC DYSFUNCTION OF LUMBAR REGION	M99.00	SEGMENTAL & SOMATIC DYSFU
M99.04	SEGMENTAL & SOMATIC DYSFUNCTION OF SACRAL REGION	M99.01	SEGMENTAL & SOMATIC DYSFU
M99.05	SEGMENTAL & SOMATIC DYSFUNCTION OF PELVIC REGION	M99.02	SEGMENTAL & SOMATIC DYSFU
	WRISTS	M99.03	SEGMENTAL & SOMATIC DYSFU
S63.501A	UNSPECIFIED SPRAIN OF RIGHT WRIST	M99.04	SEGMENTAL & SOMATIC DYSFU
S63.502A	UNSPECIFIED SPRAIN OF LEFT WRIST	M99.05	SEGMENTAL & SOMATIC DYSFU
M79.631	PAIN IN RIGHT FOREARM	M99.06	SEGMENTAL & SOMATIC DYSFU
M79.632	PAIN IN LEFT FOREARM	M99.07	SEGMENTAL & SOMATIC DYSFU
M79.641	PAIN IN RIGHT HAND	M99.08	SEGMENTAL & SOMATIC DYSFU
M79.642	PAIN IN LEFT HAND		

FarRockaway Medical PC

62-69 99th Street. Rego Park, NY 11374 Email. Nyregoparkmedical@gmail.com

Patient's Name Kevin Brown Date: 12 / 12 / 23

D.O.A. 10 / 13 / 23

----- POSITONING CUSHION
----- INFRA RED LAMP
----- GENERAL USE CUSHION (wide)
----- LUMBER SACRAL SUPPORT
----- DEEP TISUE MASSAGER
----- E M S UNIT FOUR LEAD
----- T.E.N.S. BELT
----- KNEE [ ]BRACE [ ]SUPPORT
----- ARM SLING
----- ANKLE [ ]BRACE [✓]SUPPORT
----- BED BOARD
----- EGG CRATE MATTRESS
----- CERVICAL COLLAR
----- CERVICAL POSTURE PUMP
----- CERVICAL TRACTION W PUMP
----- PARAFFIN BATH
----- THERMAL MOIST HEAT PAD
----- WRIST SUPPORT
----- WATER CIRC HEAT PAD W PUMP
___THERMOPHORE
[ ] OTHER_____

----- ORTHOPEDIC CAR SEAT
----- CERVICAL HEAD HALTER
----- CERVICAL OVER THE DOOR
----- T.E.N.S. ACCESSORIES KIT
----- CRUTCHES
----- CANE
----- ELBOW BRACE
----- HOT / COLD PACK
----- WHIRLPOOL
----- HAND SUPPORT
----- K.O. (CUSTOM FITTED)
----- LSO W/APL CONTROL CUSTOM FITTED
----- TLSO
----- PHILADELPHIA COLLAR
----- PELVIC TRACTION
----- SHOULDER IMMOBILIZER
----- WALKER
----- WHEELCHAIR
----- CERVICAL PILLOW
___SHOULDER [ ] SUPPORT [ ]BRACE

Dr. Jean-Pierre Barakat, MD
LIC No: 250159

847.00☐Cervical spine strain
718.91☐Shoulder derangement
847.20☐Lumbar spine sprain
722.73☐Lumbar disc herniation
723.4☐Cervical radiculitis
923.00☐Contusion of the shoulder
846.0☐Lumbosacral spine strain
844.90 ☐Knee sprain (strain)
722.71☐Cervical disc herniation with myelopathy
959.20☐Tendinitis--shoulder/arm
724.4☐Lumbar radiculitis
717.91☐Knee derangement

NYB Medical Supply Inc

Tel: 7183446911
Email: nybmedsupply@gmail.com

PRESCRIPTION ORDER FORM
PNEUMATIC COMPRESSION DEVICE

Order Date: 12/12/23

Patient's name: Kevin Brown DOB: 7/06/87

RELATED DIAGNOSIS:

BODY REGION EFFECTED

Upper Extremity	Right	Left	Bi-Lateral
Lower Extremity	Right	Left	Bi-Lateral
Waist			

EQUIPMENT ORDERED

- Pneumatic compressor, segmental home model with calibrated gradient pressure
- Segmental pneumatic appliance for use with pneumatic compressor, **waist**
- Segmental pneumatic appliance for use with pneumatic compressor, **full leg** Qt: 1 2
- Segmental pneumatic appliance for use with pneumatic compressor, **half leg** Qt: 1 2
- Segmental pneumatic appliance for use with pneumatic compressor, **full arm** Qt: 1 2
- Pneumatic compression device, high pressure, rapid inflation/deflation cycle, for arterial insufficiency (unilateral or bilateral system)

GARMENT SIZE

Lower Extremity	Waist	Upper Extremity
Medium	Medium	Medium
Large	Large	Large
X Large	X Large	X Large
XX Large	XX Large	XX Large

TREATMENT PLAN

Frequency of Treatment:	1x/day	2x/day	3x/day	Other
Duration of Treatment:	½ hour	1 hour	2 hours	Other
Distal Pressure Setting:	40 mmHg	45 mmHg	50 mmHg	Other

Length of Need: 99 months (lifetime=99)

Letter of Medical Necessity

I certify that I am the physician identified in the form. I have reviewed the Detailed Written Order. Any statement on my letterhead attached hereto has been reviewed and signed by me. I certify that the medical necessity information in is true, accurate and complete to the best of my knowledge. I certify that the patient is capable and has successfully completed or will be trained on the proper use of products prescribed in this Written Order. The products lists and physician notes and other supporting documentation will be provided to DME and/or an authorized distributor upon request. I acknowledge that the patient is aware that DME and/or an authorized distributor may contact them for any additional information to process this order. A copy of this order will be retained as part of the patient's medical record.

Physician Signature | DR. Jean Pierre Barakat (Printed Name) | 12/12/23 (Date)

Farrockaway Medical PC

OUTCOME ASSESSMENT TESTING SUMMARY REPORT

Dear Patient,

The following exam was created for your doctor to better understand the nature and extent of your injuries, which were sustained below. You will be asked these questions again at your following visit to the doctor. Comparing the answers from your test will help us to monitor your improvement.

Please answer all questions carefully. Make sure all answers are filled out completely. Your answers reflect condition at the time of your questionnaires. Please do not leave any questions blank.

First Name Kevin Last Name Brown

Age 36 Male ✓ Female ____

Date of Accident 10/13/23

Date of Test ____

Patients Signature ____ Date 12/12/23

Doctors Signature ____ Date 12/12/23

HEADACHE DISABILITY

Patient Name Kevin Brown

Date 12/12/23

INSTRUCTIONS: Please CIRCLE the correct response:

1. I have headache: (1) 1 per month (2) more than 1 but less than 4 per month (3) more than one per week
2. My headache is: (1) mild (2) moderate (3) severe

Please read carefully: The purpose of the scale is to identify difficulties that you may be experiencing because of your headache. Please check off "YES", "SOMETIMES", or "NO" to each item. Answer each question as it pertains to your headache only.

YES	SOMETIMES	NO		
		✓	E1.	Because of my headaches I feel handicapped.
		✓	E2.	Because of my headaches I feel restricted in performing my routine daily activities.
		✓	E3.	No one understands the effect my headaches have on my life.
		✓	F4.	I restrict my recreational activities (eg, sports, hobbies) because of my headaches.
		✓	E5.	My headaches make me angry.
		✓	E6.	Sometimes I feel that I am going to lose control because of my headaches.
		✓	F7.	Because of my headaches I am less likely to socialize.
		✓	E8.	My spouse (significant other), or family and friends have no idea what I am going through because of my headaches.
		✓	E9.	My headaches are so bad that I feel that I am going to go insane.
		✓	E10.	My outlook on the world is affected by my headaches.
		✓	E11.	I am afraid to go outside when I feel that a headaches is starting.
		✓	E12.	I feel desperate because of my headaches.
		✓	F13.	I am concerned that I am paying penalties at work or at home because of my headaches.
		✓	E14.	My headaches place stress on my relationships with family or friends.
		✓	F15.	I avoid being around people when I have a headache.
		✓	F16.	I believe my headaches are making it difficult for me to achieve my goals in life.
		✓	F17.	I am unable to think clearly because of my headaches.
		✓	F18.	I get tense (eg, muscle tension) because of my headaches.
		✓	F19.	I do not enjoy social gatherings because of my headaches.
		✓	E20.	I feel irritable because of my headaches.
		✓	F21.	I avoid traveling because of my headaches.
		✓	E22.	My headaches make me feel confused.
		✓	E23.	My headaches make me feel frustrated.
		✓	F24.	I find it difficult to read because of my headaches.
		✓	F25.	I find it difficult to focus my attention away from my headaches and on other things.

OTHER COMMENTS:

Examiner

Used permission from: Jacobson GP, Ramadan NM, et al. *The Henry Ford Hospital headache disability inventory (HDI)*. Neurology 1994;44:837-8.

Patient Name Kevin Brown

NECK DISABILITY INDEX QUESTIONNAIRE

Date 12/12/23

Please read carefully:

This questionnaire has been designed to enable us to understand how your neck pain has affected your ability to manage your life. Please answer every section, and mark in each section only ONE CHOICE which applies to you. We realize that you may consider that two of the statements in any one section relate to you, but please just mark the one box which most closely describes your problem right now.

SECTION 1 – Pain Intensity

(A) I have no pain at the moment.
B. The pain is very mild at the moment.
C. The pain is moderate at the moment.
D. The pain is fairly severe at the moment.
E. The pain is very severe at the moment.
F. The pain is the worst imaginable at the moment.

SECTION 2 – Personal Care (washing, dressing, etc.)

(A) I can look after myself without causing extra pain.
B. I can look after myself normally but it causes extra pain.
C. It is painful to look after myself and I am slow and careful.
D. I need some help but manage most of my personal care.
E. I need help every day in most aspects of self care.
F. I do not get dressed, wash with difficulty and stay in bed.

SECTION 3 – Lifting

(A) I can lift heavy weights without extra pain.
B. I can lift heavy weights but it gives extra pain.
C. Pain prevents me from lifting heavy objects off the floor, but I can manage if they are conveniently positioned, e.g. on a table.
D. Pain prevents me from lifting heavy weights but I can manage light to medium weights if they are conveniently positioned.
E. I can lift very light weights.
F. I cannot lift or carry anything at all.

SECTION 4 – Reading

(A) I can read as much as I want with no pain in my neck.
B. I can read as much as I want with slight pain in my neck.
C. I can read as much as I want with moderate pain in my neck.
D. I cannot read as much as I want because of moderate pain in my neck.
E. I can hardly read at all because of severe pain in my neck.
F. I cannot read at all.

SECTION 5 – Headaches

(A) I have no headaches at all.
B. I have slight headaches which come infrequently.
C. I have moderate headaches which come infrequently.
D. I have moderate headaches which come frequently.
E. I have severe headaches which come frequently.
F. I have headaches almost all the time.

SECTION 6 – Concentration

(A) I can concentrate fully when I want to with no difficulty.
B. I can concentrate fully when I want to with slight difficulty.
C. I have a fair degree of difficulty in concentrating when I want to.
D. I have a lot of difficulty in concentrating when I want to.
E. I have a great deal of difficulty in concentrating when I want to.
F. I cannot concentrate at all.

SECTION 7 – Work

(A) I can do as much work as I want to.
B. I can only do my usual work, but no more.
C. I can do most of my usual work, but no more.
D. I cannot do my usual work.
E. I can hardly do any work at all.
F. I cannot do any work at all.

SECTION 8 – Driving

(A) I can drive without any neck pain.
B. I can drive as long as I want with slight pain in my neck.
C. I can drive as long as I want with moderate pain in my neck.
D. I cannot drive as long as I want because of moderate pain in my neck.
E. I can hardly drive at all because of severe pain in my neck.
F. I cannot drive my car at all.

SECTION 9 – Sleeping

(A) I have no trouble sleeping.
B. My sleep is slightly disturbed (less than 1 hr. sleepless).
C. My sleep is mildly disturbed (1-2 hrs. sleepless).
D. My sleep is moderately disturbed (2-3 hrs. sleepless).
E. My sleep is greatly disturbed (3-5 hrs. sleepless).
F. My sleep is completely disturbed (5-7 hrs. sleepless).

SECTION 10 – Recreation

(A) I am able to engage in all my recreation activities with no neck pain at all.
B. I am able to engage in all my recreation activities with some pain in my neck.
C. I am able to engage in most, but not all of my usual recreation activities because of pain in my neck.
D. I am able to engage in a few of my usual recreation activities because of pain in my neck.
E. I can hardly do any recreation activities because of pain in my neck.
F. I cannot do any recreation activities at all.

OTHER COMMENTS:

Examiner

With Permission from: Vernon H, Mior S. The Neck Disability Index: A study of reliability and validity. J Manipulative Physiol Ther 1991;14:409-415. Copyright Vernon H and Hagino C, 1990.

SHOULDER PAIN AND DISABILITY INDEX (SPADI)

Patient Name: Karen Brown

Date: 12/12/23

Please read carefully:

Instructions: Please circle the number that best describes the question being asked.

Pain scale:
No pain at all 0 1 2 3 4 5 6 7 8 9 10 Worst pain imaginable

How severe is your pain?

1. At its worst? 0 1 2 3 4 5 6 7 8 9 10
2. When lying on the involved side? 0 1 2 3 4 5 6 7 8 9 10
3. Reaching for something on a high shelf? 0 1 2 3 4 5 6 7 8 9 10
4. Touching the back of your neck? 0 1 2 3 4 5 6 7 8 9 10
5. Pushing with the involved arm? 0 1 2 3 4 5 6 7 8 9 10

Disability scale:
No difficulty 0 1 2 3 4 5 6 7 8 9 10 So difficult it requires help

How much difficulty do you have?

1. Washing your hair? 0 1 2 3 4 5 6 7 8 9 10
2. Washing your back? 0 1 2 3 4 5 6 7 8 9 10
3. Putting on an undershirt or pullover sweater? 0 1 2 3 4 5 6 7 8 9 10
4. Putting on a shirt that buttons down the front? 0 1 2 3 4 5 6 7 8 9 10
5. Putting on your pants? 0 1 2 3 4 5 6 7 8 9 10
6. Placing an object on a high shelf? 0 1 2 3 4 5 6 7 8 9 10
7. Carrying a heavy object of 10 pounds? 0 1 2 3 4 5 6 7 8 9 10
8. Removing something from your back pocket? 0 1 2 3 4 5 6 7 8 9 10

COMMENTS:

r:

ssion from: Williams JW Jr, Holleman DR Jr., Simel DL: Measuring shoulder function with the Shoulder Pain and Disability Index.
l 1995; 22 (4); 727-732

Name Kevin Brown

REVISED OSWESTRY BACK PAIN DISABILITY QUESTIONNAIRE

Date 12/12/23

Please read carefully:

This questionnaire has been designed to enable us to understand how your back pain has affected your ability to manage everyday life. Please answer every section, and mark in each section only ONE CHOICE which applies to you. We realize that you may consider that two of the statements in any one section relate to you, but please just mark the one box which most closely describes your problem right now.

SECTION 1 – Pain Intensity

A. The pain comes and goes and is very mild.
B. The pain is mild and does not vary much.
C. The pain comes and goes and is moderate.
D. The pain is moderate and does not vary much.
E. The pain comes and goes and is severe.
F. The pain is severe and does not vary much.

SECTION 2 – Personal Care

A. I would not have to change my way of washing or dressing in order to avoid pain.
B. I do not normally change my way of washing or dressing even though it causes some pain.
C. Washing and dressing increases the pain, but I manage not to change my way of doing it.
D. Washing and dressing increases the pain and I find it necessary to change my way of doing it.
E. Because of the pain, I am unable to do some washing and dressing without help.
F. Because of the pain, I am unable to do any washing or dressing without help.

SECTION 3 – Lifting

A. I can lift heavy weights without extra pain.
B. I can lift heavy weights but it gives me extra pain.
C. Pain prevents me from lifting heavy weights off the floor.
D. Pain prevents me from lifting heavy weights off the floor, but I can manage if they are conveniently positioned-eg, on a table
E. Pain prevents me from lifting heavy weights, but I can manage light to medium weights if they are conveniently positioned.
F. I can only lift very light weights, at the most.

SECTION 4 – Walking

A. Pain does not prevent me from walking any distance.
B. Pain prevents me from walking more than 1 mile.
C. Pain prevents me from walking more than ½ mile.
D. Pain prevents me from walking more than ¼ mile.
E. I can only walk using a stick or crutches.
F. I am in bed most of the time and have to crawl to the toilet.

SECTION 5 – Sitting

A. I can sit in any chair as long as I like without pain.
B. I can only sit in my favorite chair as long as I like.
C. Pain prevents me sitting more than 1 hour.
D. Pain prevents me sitting more than ½ hour.
E. Pain prevents me sitting more than 10 minutes.
F. Pain prevents me from sitting at all.

OTHER COMMENTS:

SECTION 6 – Standing

A. I can stand as long as I want without pain.
B. I have some pain while standing, but it does not increase with time.
C. I cannot stand for longer than 1 hour without increasing pain.
D. I cannot stand for longer than ½ hour without increasing pain.
E. I cannot stand for longer than 10 minutes without increasing pain.
F. Pain prevents me from standing at all.

SECTION 7 – Sleeping

A. I get no pain in bed.
B. I get pain in bed, but it does not prevent me from sleeping well.
C. Because of pain, my normal night's sleep is reduced by less than one-quarter.
D. Because of pain, my normal night's sleep is reduced by more than one-half.
E. Because of pain, my normal night's sleep is reduced by more than three-quarters.
F. Pain prevents me from sleeping at all.

SECTION 8 – Social Life

A. My social life is normal and gives me no pain.
B. My social life is normal, but increases the degree of pain.
C. Pain has no significant effect on my social life apart from limiting my more energetic interests, eg, dancing, etc.
D. Pain has restricted my social life and I do not go out very often.
E. Pain has restricted my social life to my home.
F. I have hardly any social life because of the pain.

SECTION 9 – Traveling

A. I get no pain while traveling.
B. I get some pain while traveling but none of my usual forms of travel make it any worse.
C. I get extra pain while traveling but it does not compel me to seek alternative forms of travel.
D. I get extra pain while traveling which compels me to seek alternative forms of travel.
E. Pain restricts all forms of travel.
F. Pain prevents all forms of travel except that done lying down.

SECTION 10 – Changing Degree of Pain

A. My pain is rapidly getting better.
B. My pain fluctuates, but overall is definitely getting better.
C. My pain seems to be getting better, but improvement is slow at present.
D. My pain is neither getting better nor worse.
E. My pain is gradually worsening.
F. My pain is rapidly worsening.

Examiner

With Permission from: Hudson-Cook N, Tomes-Nicholson K, Breen AC. A Revised Oswestry Back Disability Questionnaire. Manchester Univ Press, 1989.

Patient Name Kevin Brown

ROLAND-MORRIS QUESTION

Date 12/12/23

Please read carefully:
When your back hurts, you may find it difficult to do some of the things you normally do. Mark only the sentences that [illegible] you today.

1. ✓ I stay at home most of the time because of my back.
2. ✓ I change positions frequently to try and get my back comfortable.
3. ✓ I walk more slowly than usual because of my back.
4. ___ Because of my back, I am not doing any of the jobs that I usually do around the hou[illegible]
5. ___ Because of my back, I use a handrail to get upstairs.
6. ___ Because of my back, I lie down to rest more.
7. ___ Because of my back, I have to hold on to something to get out of an easy chair.
8. ___ Because of my back, I try to get other people to do things for me.
9. ✓ I get dressed more slowly because of my back.
10. ✓ I only stand up for short periods of time because of my back.
11. ___ Because of my back, I try not to bend or kneel.
12. ___ I find it difficult to get out of a chair because of my back.
13. ___ My back is painful almost all of the time.
14. ___ I find it difficult to turn over in bed because of my back.
15. ___ My appetite is not very good because of my back.
16. ✓ I have trouble putting on my socks/stockings because of my back.
17. ✓ I only walk short distances because of my back pain.
18. ___ I sleep less well because of my back pain.
19. ___ Because of my back pain, I get dressed with help from someone else.
20. ___ I sit down for most of the day because of my back.
21. ___ I avoid heavy jobs around the house because of my back.
22. ___ Because of my back pain, I am more irritable and bad tempered with people than usu[illegible]
23. ___ Because of my back, I go upstairs more slowly than usual.
24. ___ I stay in bed most of the day because of my back.

OTHER COMMENTS:

Examiner

With Permission from: Roland M, Morris R. *A study of the natural history of back pain: Part I: Development of a reliable and sensitive measure of disability in low-back pain.* Spine 1983;8:141-144.

SUBJECTIVE KNEE SCORE QUESTIONS

Patient Name: Kevin Brown

Date: 12/12/23

Please read carefully:
Please answer every section, and mark in each section only ONE CHOICE which applies to you. We realize that you may consider that of the statements in any one section relate to you, but please just mark the one box which most closely describes your problem right now.

PAIN

( ) I experience no pain in my knee.
( ) I have occasional pain with strenuous sports or heavy work. I don't think that my knee is entirely normal. Limitations are mild and to
( ) There is occasional pain in my knee with light recreational sports or moderate work.
( ) I have pain brought on by sports, light recreational activities, or moderate work. Occasional pain is brought on by daily activities s standing or kneeling.
( ) The pain I have in my knee is a significant problem with activities as simple as walking. The pain is relieved by rest. I can't participate

SWELLING

( ) I experience no swelling in my knees.
( ) I have occasional swelling in my knee with strenuous sports or heavy work.
( ) There is occasional swelling with light recreational activities or moderate work.
( ) Swelling limits my participation in sports and moderate work. Occurs infrequently with simple walking or light work. Occasionally with walking or light work – about 3 times a year.
( ) My knee swells after simple walking activities and light work. Rest relieves the swelling.
( ) I have severe swelling with simple walking activities. Rest does not relieve the swelling.

STABILITY

( ) My knee does not give out.
( ) My knee gives out only with strenuous sports or heavy work.
( ) My knee gives out occasionally with light recreational activities or moderate work; it limits my vigorous activities, sports, or heavy
( ) Because my knee gives out, it limits all sports and moderate work. It occasionally gives out with walking or light work.
( ) My knee gives out frequently with simple activities such as walking. I must guard my knee at all times.
( ) I have severe problems with my knee giving out. I can't turn or twist without my knee giving out.

OVERALL ACTIVITY LEVEL

( ) No limitations. I have a normal knee, and I am able to do everything including strenuous sports and/or heavy labor.
( ) I can partake in sports including strenuous ones but at a lower level. I must guard my knee and limit the amount of heavy labor or s
( ) Light recreational activities are possible with RARE symptoms. I am limited to light work.
( ) No sports or recreational activities are possible. Walking activities are possible with RARE symptoms. I am limited to light work.
( ) Walking activities and daily living cause moderate problems and persistent symptoms.
( ) Walking and other daily activities cause severe problems.

WALKING

( ) Normal, unlimited
( ) Slight, mild problems.
( ) Moderate problem, flat surface up to half a mile.
( ) Severe problems, only 2-3 blocks.
( ) Severe problems, need cane or crutches.

STAIRS

( ) Normal, unlimited
( ) Slight, mild problems.
( ) Moderate problem, only 10-15 steps possible.
( ) Severe problems, require banister for support.
( ) Severe problems, only 1-5 steps without support.

RUNNING

( ) Normal, unlimited, fully competitive.
( ) Slight, mild problems, run at half speed.
( ) Moderate problems, only 1-2 miles possible.
( ) Severe problems, only 1-3 blocks possible.
( ) Severe problems, only a few steps

PIVOTING AND TWISTING

( ) Normal, unlimited, fully competitive.
( ) Slight, mild problems, some guarding.
( ) Moderate problems, gave up strenuous sports.
( ) Severe problems, affects all sports, always guarding.
( ) Severe problems, only light activity possible (pivot/swim).

Other: _____

permission from: Noyes FR, et al. Functional disability in the anterior cruciate insufficient knee syndrome. Review of knee rating systems and factors in determining treatment. Sports Med 1984; 1: 278-302. Copyright Adis International, Inc.

Dong Seo Pharmacy LLC.

Page: 1

142-20 38TH AVE SUITE CFD
Flushing, NY 11354

Phone. 7188887811
Fax: 7188880025

ELECTRONIC PRESCRIPTION

Resp Status Ready To Process

Msg Ref.

MsgType New Prescription

Msg ID NEWRX-1-139145745

Rx# 159597

Date &Time 12/13/2023 12:24 PM

Msg To 5812741

Patient Name Brown,Kevin

DOB 07/09/1987

Address 67-23 Elliot AvenueRego park,FLUSHING,NY,11379

Gender M

Phone # (646)644-4417

Doc Jean Pierre Barakat

Address 795 Todt Hill Road,STATEN ISLAND,NY,10304

NPI # 1205086329
DEA # FB1087065
LIC#: 250159
SPI # 6588597883017

Phone# (626)399-1079

Supervisor

Super. NPI

Super.DEA

Agent

Drug Name diclofenac 3 % topical gel

Prescribed NDC 00472178310
Potency UnitCd Gram
Form Code Gel
Refill 0
Strength 3
Days Supply 30
Drug Class 0

Quantity 200.00 (Two Hundred)
Written Date 12/13/2023
Eff. Date
DAW N
DX:

Direction apply to lesion areas by topical route 2 times per day

Note: diclofenac 3 % topical gel

PH/TECH: YS

Cypress Rx Inc.
11-05 Cypress Ave Ridgewood, NY 11385
Phone: (347)599-1805 Fax: (347)599-1806 Prnt Dt: 12/18/202311:00:12AM

Rx Pres: Jean Pierre Barakat
795 Todt Hill Road
STATEN ISLAND, NY 103(Phn: (626)399-1079
Fax: (626)399-1079

Ord: 12/13/2023
NPI# 1205086329
LIC# 250159
DEA# FB1087065
SPI: 6588597883017

Patient: Brown, Kevin
DOB: 07/09/1987 Gender M
Address: 67-23 Elliot AvenueRego park Rx#: 62927
FLUSHING, NY 11379
Phone (646)644-4417
Qty: 60.000 (Sixty)
Days: 30 Refills: 0 PH/TH: MK Class: 0
Potency UnitCd: Capsule
Drug: diclofenac potassium 25 mg capsule 25 Capsule

Sig: Take 1 Capsule(s) by oral route every 12 Hour(s)

Signature Date

This Prescription Will be Filled Generically Unless Prescriber Writes "DAW [1]" in the Box [ ] N Dispense As Written

Electronic Rx

12/13/2023 12:24 PM MessageType: New Prescription
From: 6588597883017
Msg.Id: NEWRX-1-139145719 To: 5838404
Prs. Order Ref : 157802173

Resp.Status: Ready To Process

Prescribers Note: As needed

RX#:62927 Rph: MK D/F: 12/18/2023
BROWN, KEVIN D/O:12/13/2023
67-23 ELLIOT AVE FLUSHING NY 11379 DOB: 7/9/1987
TAKE 1 CAPSULE(S) BY ORAL ROUTE EVERY 12 HOUR(S)

#: 60 DICLOFENAC POTASSIUM CAP 25MG
NDC: 74157-0095-60 DAW: N D/S: 30 [ELECTRONIC]
Dr. BARAKAT, J (347)849-1714 1205086329 FB1087065
62-69 99 ST REGO PARK NY 11374
Copay: $0.00 Ins: $854.21 Total: $854.21 Cost: $0.00 Refills: 0.00

Cypress Rx Inc.
11-05 Cypress Ave Ridgewood, NY 11385
Phone: (347)599-1805 Fax: (347)599-1806 Prnt Dt: 12/18/202311:00:35AM

Rx Pres: Jean Pierre Barakat
795 Todt Hill Road
STATEN ISLAND, NY 1030 Phn: (626)399-1079
Fax: (626)399-1079

Ord: 12/13/2023
NPI# 1205086329
LIC# 250159
DEA# FB1087065
SPI: 6588597883017

Patient: Brown, Kevin
DOB: 07/09/1987 **Gender** M
Address: 67-23 Elliot AvenueRego park **Rx#:** 62928
FLUSHING, NY 11379
Phone (646)644-4417
Qty: 60.000 (Sixty)
Days: 30 **Refills:** 0 **PH/TH:** MK **Class:** 0
Potency UnitCd: Patch
Drug: lidocaine patch: Lidocaine 4.5% and menthol 5%

Sig: Apply to affected area 12 hrs on 12 hrs off as needed

Signature **Date**

This Prescription Will be Filled Generically Unless Prescriber Writes "DAW [1]" in the Box [ ] N Dispense As Written

Electronic Rx

12/13/2023 12:24 PM **MessageType:** New Prescription
From: 6588597883017
Msg.Id: NEWRX-1-139145720 To: 5838404
Prs. Order Ref : 157802174

Resp.Status: Ready To Process

lidocaine patch: Lidocaine 4.5% and menthol 5%

RX#:62928 Rph: MK D/F. 12/18/2023
BROWN, KEVIN D/O.12/13/2023
67-23 ELLIOT AVE FLUSHING NY 11379 DOB: 7/9/1987
APPLY 1 PATCH DAILY TO AFFECTED AREA(S) KEEP PATCH 12 HRS ON AND 12 HRS OFF AS NEEDED

#: 30 LIDOTHOL FILM 4.5-5%
NDC: 53225-1025-01 DAW: N D/S: 30 [ELECTRONIC]
Dr. BARAKAT, J (347)849-1714 1205086329 FB1087065
62-69 99 ST REGO PARK NY 11374
Copay: $0.00 Ins: $1375.61 Total: $1375.61 Cost: $0.00 Refills: 1.00

Farrockaway Medical PC
62-69 99th St
Rego Park, NY 11374
nyregoparkmedical@gmail.com

DATE: 01/09/23

FOLLOW UP REPORT: 3

DATE OF ACCIDENT: 10/13/23

PATIENT'S NAME: Kevin Brown

AGE: 36

AT THE TIME OF THE INITIAL EVALUATION PATIENT PRESENTED COMPLAINTS OF:

HEADACHE DIFUSES FRONTAL TEMPORAL OCCIPITAL VOMITIMG
DIZZINESS BLURRED VISION

✓ NECK PAIN NON-RADIATING RADIATING TO
✓ LOWER BACK PAIN NON-RADIATING RADIATING TO Disc 12/13/23
MID BACK PAIN NON-RADIATING RADIATING TO
SHOULDERS RT LT TINGLING NUMBNESS
WRIST RT LT TINGLING NUMBNESS
ELBOWS RT LT TINGLING NUMBNESS
HANDS RT LT TINGLING NUMBNESS
HIPS RT LT TINGLING NUMBNESS
KNEES RT LT TINGLING NUMBNESS
✓ ANKLES RT LT TINGLING NUMBNESS
FEET ✓ RT LT TINGLING NUMBNESS
CHEST RT LT TINGLING NUMBNESS
ABDOMEN
NERVOUNESS
INSOMNIA ANXIETY FEAR DRIVING/SITTING IN THE CAR FEAR OF CROSSING STREET
OTHER

Outcome Assessment results discussed thoroughly with patient

PRESENT COMPLAINTS

HEAD
FACE
NECK
CHEST
THORACIC SPINE
LOWER BACK
STRESS
HEADACHES
VOMITING

SACRAL AREA
PELVIS
SHOULDER RT LT
ELBOWS RT LT
WRIST RT LT
HAND RT LT
SPEECH
BLURRED VISION
NERVOUSNESS/INSOMNIA

HIPS RT LT
KNEES RT LT
ANKLES RT LT
FEET RT LT
ABDOMEN RT LT
OTHER_____
FEAR OF DRIVING
SITTING IN CAR
CROSSING THE STREET

PHYSICAL EXAMINIATION REVEALED:

B/P___/___ PULSE_____ RR_____ AFEBRILE FEBRILE

PATIENT IS AAOX3, MEMORY [ ] IS INTACT [ ] HAS POOR MEMORY SINCE THE ACCIDENT
SPEECH IS FLUENT AND COHERENT
PATIENT APPEARS TO BE IN [ ] MILD [ ] MODERATE [ ] SEVERE DISTRESS DUE TO PAIN AND DISCOMFORT
PATIENT IS NOT IN ACUTE DISTRESS, BUT FEELS QUITE UNCOMFORTABLE AND TENSE
S1S2R LUNGS ABDOMEN SOFT, NT

CERVICAL SPINE

PALPATION OF THE NECK REVEALS DOES NOT REVEAL MILD MODERATE SEVERE CERVICAL
SPINE TENDERNESS AT THE C__C__ LEVEL NO STEP OFF APPRECIATED
INCREASE IN R L MUSCLE TONE ION PARAVERTEBRAL TRAPEZIUS RHOMBOID MUSCLE
NORMAL EXAMINATION OF THE CERVICAL SPINE

ECN: 2024021501842 Received Date: 2024-02-12

SPECIAL TEST AND SIGNS

DISTRACTION TEST	POSTIVE	NEGATIVE
COMPRESSION TEST	POSTIVE	NEGATIVE
SHOULDER DEPRESSION TEST	POSTIVE	NEGATIVE
FORAMINA COMPRESSION TEST	POSTIVE	NEGATIVE

	NORMAL ROM	PATIENT'S ROM	PAIN
FLEXION	45	FROM ROM___	POSITIVE
EXTENSION	55	FROM ROM___	POSITIVE
RIGHT ROTATION	70	FROM ROM___	POSITIVE
LEFT ROTATION	70	FROM ROM___	POSITIVE
RIGHT LATERAL FLEXION	40	FROM ROM___	POSITIVE
LEFT LATERAL FLEXION	40	FROM ROM___	POSITIVE

THORACIC SPINE:

THERE APPEARS TO BE TENDRNESS OF THE THORACIC SPINE AT LEVELS T____T____ WITH SPASM OF RIGHT LEFT PARASPINAL STRUCTURES
THERE IS NO TENDERNESS OR PAIN ON PALPATION

LUMBOSACRAL SPINE

PALPATION OF LUMBOSACRAL SPINE REVEALS DOES NOT REVEAL MILD MODERATE SEVERE
TENDERNESS AT THE L___L___S___LEVEL
INCREASE IN RIGHT LEFT PARAVERETEBRAL MUSCLE TONE
NORMAL EXAMINATION OF THE LUMBOSACRAL SPINE

SPECIAL TEST AND SIGNS:

SPINAL PRECUSSION TEST	POSITIVE	NEGATIVE
FABERE- PATRICK TEST	POSITIVE	NEGATIVE
STRAIGHT LEG RAISE TEST	POSITIVE @___ ON THE RT @___ ON THE LT	NEGATIVE

ECN: 2024021501842 Received Date: 2024-02-12

NORMAL ROM		PATIENT'S ROM	PAIN
FLEXION	90	☐ FROM ☐ ROM 75	☐ POSITIVE
EXTENTSION	30	☐ FROM ☐ ROM 25	☐ POSITIVE
RIGHT ROTATION	30	☐ FROM ☐ ROM 25	☐ POSITIVE
LEFT ROTATION	30	☐ FROM ☐ ROM 25	☐ POSITIVE
RIGHT LATERAL FLEXION	35	☐ FROM ☐ ROM 25	☐ POSITIVE
LEFT LATERAL FLEXION	35	☐ FROM ☐ ROM 25	☐ POSITIVE

SHOULDER:	NORMAL ROM	PATIENT'S ROM	RIGHT	LEFT
FLEXION/ ELEVATION	180	☐ FROM ☐ ROM ___	___	___
EXTENSION	50	☐ FROM ☐ ROM ___	___	___
ABDUCTION	180	☐ FROM ☐ ROM ___	___	___
ADDUCTION	50	☐ FROM ☐ ROM ___	___	___
INTERNAL ROTATION	90	☐ FROM ☐ ROM ___	___	___
EXTENAL ROTATION	90	☐ FROM ☐ ROM ___	___	___

☐ CREPITUS IS APPRECIATED ☐ RIGHT ☐ LEFT SUBACROMAL / SUBDALTOID BURSA

☐ ABLE ☐ UNABLE TO ELEVATE AND HOLD ☐ RIGHT ☐LEFT ARM AT ABOVE SHOULDER LEVEL

☐ TENDERNESS ☐ AT CREPITUS AT AC JOINT ☐ AT THE LEVEL OF ROTATOR CUFF INSERTION (LIGAMENTS OF SIT MUSCLES)

ELBOWS:	NORMAL ROM	PATIENT'S ROM	RIGHT	LEFT
FLEXION	160	☐ FROM ☐ ROM	___	___
EXTENSION	180	☐ FROM ☐ ROM	___	___
SUPINATION	90	☐ FROM ☐ ROM	___	___
PRONATION	90	☐ FROM ☐ ROM	___	___

☐ CREPITUS IS APPRECIATED ☐ RIGHT ☐ LEFT

WRIST:	NORMAL ROM	PATIENT'S ROM	RIGHT	LEFT
FLEXION	160	☐ FROM ☐ ROM	___	___
EXTENSION	180	☐ FROM ☐ ROM	___	___
SUPINATION	90	☐ FROM ☐ ROM	___	___
PRONATION	90	☐ FROM ☐ ROM	___	___

CREPITUS IS APPRECIATED IS APPREICATED ☐ RIGHT ☐ LEF

HIPS:	NORMAL ROM	PATIENT'S ROM	RIGHT	LEFT
FLEXION	120	FROM ROM	____	____
EXTENSION	15	FROM ROM	____	____
ABDUCTION	45	FROM ROM	____	____
INTERNAL ROTATION	40	FROM ROM	____	____
EXTERNAL ROTATION	45	FROM ROM	____	____

CREPITUS IS APPRECIATED RIGHT LEFT

KNEES:	NORMAL ROM	PATIENT'S ROM	RIGHT	LEFT
FLEXION	130	FROM ROM	____	____
EXTENSION	15	FROM ROM	____	____
CREPITUS IS APPRECIARED		FROM ROM	____	____

BULGE/ BALLOTING SIGNOF THE PATELLA IS IS NOT PRESENT ON RIGHT LEFT
ANTERIOR DRAWS SIGN IS POSTIVE NEGATIVE ON RIGHT LIGHT
LACHMAN TEST IS POSITIVE NEGATIVE ON RIGHT LEFT
VARUS STRESS TEST DETECTING mol IS POSITIVE NEGATIVE
VALGUS STRESS TEST DETECTING LCL IS POSTIVE NEGATIVE

ANKLES:	NORMAL ROM	PATIENT'S ROM	RIGHT	LEFT
DORSI FLEXION	20	FROM ROM	____	____
PLANTER EXTENSION	45	FROM ROM	____	____
INVERSION	30	FROM ROM	____	____
EVERSION	20	FROM ROM	____	____
CREPITUS IS APPRECIATED		RIGHT LEFT		

SWELLING/ EDEMA IS APPRECIATED ON RIGHT LEFT
MEDIAL LATERAL MALLEOLI

ECN: 2024021501842 Received Date: 2024-02-12

MOTOR SYSTEMS

MOTOR MUSCLES TEST WERE ___✓___ THROUGHOUT
NO MUSCLE ATHROPHY IS NOTED
DEEP TENDON REFLEXES ARE BILATERALLY EQUAL AND SYMMETRIC; DTR'S ___ THROUGHOUT
TOES ARE DOWNGOING BILATERALLY

SENSORY SYSTEMS

SENSORY EXAMINATION OF UPPE EXTREMITIES REVEALS DECREASED RESPONSE TO LIGHT, TOUCH AND PINPRICK SENSATION IN:

R L TRAPEZUIS (C3-C4) NERVE DISTRIBUTION
R L DELTOID (C5-C6) NERVE DISTRIBUTION
R L BICEP (C6) NERVE DISTRIBUTION
R L RADIAL (C6-C7) NERVE DISTRIBUTION
R L MEDIAN (C7-C9) NERVE DISTRIBUTION
R L ULNAR (C8-T1) NERVE DISTRIBUTION

TINEL'S SIGN	+ -@ RIGHT	
FINKEL STEIN'S TEST	+ -@ RIGHT	+ -@ LEFT
PHALEN'S SIGN	+ -@ RIGHT	+ -@ LEFT
		+ -@ LEFT

SENSORY EXAMINATION OF UPPER EXREMITTIES REVEALS NORMAL SENSITIVITY

SENSORY EXAMINATION OF LOWER EXTREMITIES REVEALS DECREASED RESPONSE TO LIGHT, TOUCH AND PINPRICK SENSATION IN:

R L GLUTEL (L-5) NERVE DISTRIBUTION
R L VASTUS (L3- L4) NERVE DISTRIBUTION
R L SCIARIA (LS- S2) NERVE DISTRIBUTION
R L TIBIAL ANTERIOR (L4-L5) NERVE DISTRIBUTION
R L PERNONEUS (L5-S1) NERVE DISTRIBUTION
R L GASTROCNEMIUS (L4- S1) NERVER DISTRIBUTION

SENSORY EXAMINATION OF THE UPPER EXTREMITTIES REVEALS NORMAL SENSITIVITY

ECN: 2024021501842 Received Date: 2024-02-12

DIAGNOSTIC RESULTS:

X-RAY OF_____ WAS DONE __/__/__ AND DEMONSTRATED _____

X-RAY OF_____ WAS DONE __/__/__ AND DEMONSTRATED _____

X-RAY OF_____ WAS DONE __/__/__ AND DEMONSTRATED _____

MRI/CT OF_____ WAS DONE __/__/__ AND DEMONSTRATED _____

MRI/CT OF_____ WAS DONE __/__/__ AND DEMONSTRATED _____

MRI/CT OF_____ WAS DONE __/__/__ AND DEMONSTRATED _____

MRI/CT OF_____ WAS DONE __/__/__ AND DEMONSTRATED _____

MRI/CT OF_____ WAS DONE __/__/__ AND DEMONSTRATED _____

MRI/CT OF_____ WAS DONE __/__/__ AND DEMONSTRATED _____

CS DB 3-4
6-1
DHS-1

LS Oth-1

ECN: 2024021501842 Received Date: 2024-02-12

BASE ON THE ABOVE FINDINGS, ADDITIONAL TEST AND THERAPY INDICATED:

CONTINUE PHYSICAL THERAPY 3 TIMES PER WEEK

X-RAY(S) OF THE _____ TO RULE OUT FRACTURE

MRI/CT SCAN OF _____ TO RULE OUT _____

NEUROLOGIST CONSULTATION TO RULE OUT _____

PHYSCHOLOGIST CONSULTATION TO RULE OUT _____

ORTHOPEDIC CONSULTATION TO RULE OUT _____

ADDITIONAL THERAPEUTIC EQUIPMENT SUCH AS _____

OTHER _____

PATIENT WILL BE RE- EVALUATED IN 3-4 WEEKS

PATIENT WAS DISCHARGED SINCE SYMPTOMS IMPROVED WITH PHYSCIAL THERAPY

RESPECTFULLY SUMITTED,

JEAN-PIERRE GEORGES BARAKAT, MD
INTERNAL MEDICINE

ECN: 2024021501842 Received Date: 2024-02-12

DIAGNOSIS IMPRESSIONS: ICD 10

	CERVICAL SPINE DX
M54.9	CERVICALGIA
S13.4XXA	SPRAIN OF LIGAMENTS OF C/S IE
S13.8XXA	SPRAIN OF JOINTS & LIGAMNETS OF OTHER PARTS OF NECK, IE
S16.1XXA	STRAIN OF MUSCLE, FASCIA AND TENDON AT NECK LEVEL, IE
M54.31	RADICULOPATHY, OCCIPITO-ATLANTO-AXIAL REGION
M54.32	RADICULOPATHY, CERVICAL REGION
M54.13	RADICULOPATHY, CERVICOTHORACIC REGION
M50.20	OTHER CERVICAL DISC DISPLACEMENT, UNSP.-CERVICAL REG.
M50.21	OTHER CERVICAL DISC DISPLACEMENT, HIGH CERVICAL REGION
M50.22	OTHER CERVICAL DISC DISPLACEMENT, MID-CERVICAL REGION
M50.23	OTHER CERVICAL DISC DISPLACEMENT, CERVICOTHORACIC
M99.01	SEGMENTAL & SOMATIC DYSFUNCTION OF CERVICAL REGION
M79.1	MYALGIA
	THORACIC SPINE DX
M54.6	PAIN IN THORACIC SPINE
S23.3XXA	SPRAIN OF LIGAMENTS OF THORACIC SPINE, IE
S23.8XXA	SPRAIN OF OTHER SPECIFIED PARTS OF THORAX, IE
M51.14	INTERVERTEBRAL DISC DISORDER WITH RADIC, THORACIC REG
M51.15	INTERVERTEBRAL DISC DISORDER WITH RADIC, THORACOLUMBAR
M54.14	RADICULOPATHY, THORACIC REGION
M54.15	RADICULOPATHY, THORACOLUMBAR REGION
M51.24	OTHER INTERVERTEBRAL DISC DISPLACEMENT, THORACIC REG
M54.25	OTHER INTERVERTEBRAL DISC DISPLACEM., THORACOLUMBAR
M99.02	SEGMENTAL & SOMATIC DYSFUNCTION OF THORACIC REGION
	LUMBAR – LUMBOSACRAL DX
M54.5	LOW BACK PAIN
S33.5XXA	SPRAIN OF LIGAMENTS OF LUMBAR SPINE, IE
S33.9XXA	SPRAIN OF UNSPESIFIED PARTS OF LUMBAR SPINE & PELVIS, IE
M51.16	INTERVERTEBRAL DISC DISORDER WITH RADIC, LUMBAR REG
M51.17	INTERVERTEBRAL DISC DISORDER WITH RADIC, LUMBOSACRAL
M54.16	RADICULOPATHY, LUMBAR REGION
M54.17	RADICULOPATHY, LUMBOSACRAL REGION
M51.26	OTHER INTERVERTEBRAL DISC DISPLACEMENT, LUMBAR REG
M51.27	OTHER INTERVERTEBRAL DISC DISPLACEMENT, LUMBOSACRAL
M99.03	SEGMENTAL & SOMATIC DYSFUNCTION OF LUMBAR REGION
M99.04	SEGMENTAL & SOMATIC DYSFUNCTION OF SACRAL REGION
M99.05	SEGMENTAL & SOMATIC DYSFUNCTION OF PELVIC REGION
	WRISTS
S63.501A	UNSPECIFIED SPRAIN OF RIGHT WRIST
S63.502A	UNSPECIFIED SPRAIN OF LEFT WRIST
M79.631	PAIN IN RIGHT FOREARM
M79.632	PAIN IN LEFT FOREARM
M79.641	PAIN IN RIGHT HAND
M79.642	PAIN IN LEFT HAND

	HIPS
M25.551	PAIN IN RIGHT HIP
M25.552	PAIN IN LEFT HIP
S73.301A	UNSPECIFIED SPRAIN OF RIGHT HIP, IE
S73.302A	UNSPECIFIED SPRAIN OF LEFT HIP, IE
	KNEES
M25.561	PAIN IN RIGHT KNEE
M25.562	PAIN IN LEFT KNEE
S83.90XA	SPRAIN OF UNSPECIFIED SITE OF RIGHT
S83.91XA	SPRAIN OF UNSPECIFIED SITE OF LEFT K
S80.01XA	CONTUSION OF RIGHT KNEE, IE
S80.02XA	CONTUSION OF LEFT KNEE, IE
S83.206A	UNSP TEAR, OF UNSP MENISCUS, CURRENT INJ
S83.207A	UNSP TEAR, OF UNSP MENISCUS, CURRENT INJ
	ANKLE/FOOT
S93.401A	SPRAIN OF UNSPECIFIED LIGAMENT OF
S93.402A	SPRAIN OF UNSPECIFIED LIGAMENT OF
M25.571	PAIN IN RIGHT ANKLE & JOINTS OF RI
M25.572	PAIN IN LEFT ANKLE & JOINTS OF LEFT
	SHOULDERS
S43.401A	UNSPECIFIED SPRAIN OF RIGHT SHOU
S43.402A	UNSPECIFIED SPRAIN OF LEFT SHOUL
M25.511	PAIN, RIGHT SHOULDER
M25.512	PAIN, LEFT SHOULDER
S46.011A	STRAIN/TEAR OF MUSCLE AND TEN RIGHT
S46.012A	STRAIN/TEAR OF MUSCLE AND TEN LEFT
S40.011A	CONTUSION OF RIGHT SHOULDER,
S40.012A	CONTUSION OF LEFT SHOULDER, I
	MISCELLENE
M62.830	MUSCLE SPASM OF BACK
M62.81	MUSCLE WEAKNESS
M79.1	MYALGIA
R42	DIZZINESS
R45	NERVOUSNESS
R51	HEADACHE (UNSPECIFIED)
M99.00	SEGMENTAL & SOMATIC DYSFU
M99.01	SEGMENTAL & SOMATIC DYSFU
M99.02	SEGMENTAL & SOMATIC DYSFU
M99.03	SEGMENTAL & SOMATIC DYSFU
M99.04	SEGMENTAL & SOMATIC DYSFU
M99.05	SEGMENTAL & SOMATIC DYSFU
M99.06	SEGMENTAL & SOMATIC DYSFU
M99.07	SEGMENTAL & SOMATIC DYSFU
M99.08	SEGMENTAL & SOMATIC DYSFU

FarRockaway Medical PC

OUTCOME ASSESSMENT TESTING SUMMARY REPORT

Dear Patient,

The following exam was created for your doctor to better understand the nature and extent of your injuries, which were sustained below. You will be asked these questions again at your following visit to the doctor. Comparing the answers from your test will help us to monitor your improvement.

Please answer all questions carefully. Make sure all answers are filled out completely. Your answers reflect condition at the time of your questionnaires. Please do not leave any questions blank.

Kevin B — First Name

Brown — Last Name

Age 36 Male X Female ____

Date of Accident 10/13/2023

Date of Test ____

Patients Signature — Date 1/9/24

Doctors Signature — Date 1/9/24

HEADACHE DISABILITY INDEX

Patient Name Kenny Brown

Date _____

INSTRUCTIONS: Please CIRCLE the correct response:

1. I have headache: (1) 1 per month (2) more than 1 but less than 4 per month (3) more than one per week
2. My headache is: (1) mild (2) moderate (3) severe

Please read carefully: The purpose of the scale is to identify difficulties that you may be experiencing because of your headache. Please check off "YES", "SOMETIMES", or "NO" to each item. Answer each question as it pertains to your headache only.

YES	SOMETIMES	NO		
___	___	✓	E1.	Because of my headaches I feel handicapped.
___	___	✓	F2.	Because of my headaches I feel restricted in performing my routine daily activities.
___	___	✓	E3.	No one understands the effect my headaches have on my life.
___	___	✓	F4.	I restrict my recreational activities (eg, sports, hobbies) because of my headaches.
___	___	✓	E5.	My headaches make me angry.
___	___	✓	E6.	Sometimes I feel that I am going to lose control because of my headaches.
___	___	✓	F7.	Because of my headaches I am less likely to socialize.
___	___	✓	E8.	My spouse (significant other), or family and friends have no idea what I am going through because of my headaches.
___	___	✓	E9.	My headaches are so bad that I feel that I am going to go insane.
___	___	✓	E10.	My outlook on the world is affected by my headaches.
___	___	✓	E11.	I am afraid to go outside when I feel that a headaches is starting.
___	___	✓	E12.	I feel desperate because of my headaches.
___	___	✓	F13.	I am concerned that I am paying penalties at work or at home because of my headaches.
___	___	✓	E14.	My headaches place stress on my relationships with family or friends.
___	___	✓	F15.	I avoid being around people when I have a headache.
___	___	✓	F16.	I believe my headaches are making it difficult for me to achieve my goals in life.
___	___	✓	F17.	I am unable to think clearly because of my headaches.
___	___	✓	F18.	I get tense (eg, muscle tension) because of my headaches.
___	___	✓	F19.	I do not enjoy social gatherings because of my headaches.
___	___	✓	E20.	I feel irritable because of my headaches.
___	___	✓	F21.	I avoid traveling because of my headaches.
___	___	✓	E22.	My headaches make me feel confused.
___	___	✓	F23.	My headaches make me feel frustrated.
___	___	✓	F24.	I find it difficult to read because of my headaches.
___	___	✓	F25.	I find it difficult to focus my attention away from my headaches and on other things.

OTHER COMMENTS: _____

_____
Examiner

With permission from: Jacobson GP, Ramadan NM, et al. *The Henry Ford Hospital headache disability inventory (HDI)*. Neurology 1994;44:837-842.

19 Pages via SFTP Mon, 19 Feb 2024 11:16:11 GMT

NECK DISABILITY INDEX QUESTIONNAIRE

Patient Name Karin Brown

Date

Please read carefully:

This questionnaire has been designed to enable us to understand how your neck pain has affected your ability to manage everyday life. Please answer every section, and mark in each section only ONE CHOICE which applies to you. We realize that you may consider that two of the statements in any one section relate to you, but please just mark the one box which most closely describes your problem right now.

SECTION 1 – Pain Intensity

A. I have no pain at the moment.
B. The pain is very mild at the moment.
C. The pain is moderate at the moment.
D. The pain is fairly severe at the moment.
E. The pain is very severe at the moment.
F. The pain is the worst imaginable at the moment.

SECTION 2 – Personal Care (washing, dressing, etc.)

A. I can look after myself without causing extra pain.
B. I can look after myself normally but it causes extra pain.
C. It is painful to look after myself and I am slow and careful.
D. I need some help but manage most of my personal care.
E. I need help every day in most aspects of self care.
F. I do not get dressed, wash with difficulty and stay in bed.

SECTION 3 – Lifting

A. I can lift heavy weights without extra pain.
B. I can lift heavy weights but it gives extra pain.
C. Pain prevents me from lifting heavy objects off the floor, but I can manage if they are conveniently positioned, e.g. on a table.
D. Pain prevents me from lifting heavy weights but I can manage light to medium weights if they are conveniently positioned.
E. I can lift very light weights.
F. I cannot lift or carry anything at all.

SECTION 4 – Reading

A. I can read as much as I want with no pain in my neck.
B. I can read as much as I want with slight pain in my neck.
C. I can read as much as I want with moderate pain in my neck.
D. I cannot read as much as I want because of moderate pain in my neck.
E. I can hardly read at all because of severe pain in my neck.
F. I cannot read at all.

SECTION 5 – Headaches

A. I have no headaches at all.
B. I have slight headaches which come infrequently.
C. I have moderate headaches which come infrequently.
D. I have moderate headaches which come frequently.
E. I have severe headaches which come frequently.
F. I have headaches almost all the time.

SECTION 6 – Concentration

A. I can concentrate fully when I want to with no difficulty.
B. I can concentrate fully when I want to with slight difficulty.
C. I have a fair degree of difficulty in concentrating when I want to.
D. I have a lot of difficulty in concentrating when I want to.
E. I have a great deal of difficulty in concentrating when I want to.
F. I cannot concentrate at all.

SECTION 7 – Work

A. I can do as much work as I want to.
B. I can only do my usual work, but no more.
C. I can do most of my usual work, but no more.
D. I cannot do my usual work.
E. I can hardly do any work at all.
F. I cannot do any work at all.

SECTION 8 – Driving

A. I can drive without any neck pain.
B. I can drive as long as I want with slight pain in my neck.
C. I can drive as long as I want with moderate pain in my neck.
D. I cannot drive as long as I want because of moderate pain in my neck.
E. I can hardly drive at all because of severe pain in my neck.
F. I cannot drive my car at all.

SECTION 9 – Sleeping

A. I have no trouble sleeping.
B. My sleep is slightly disturbed (less than 1 hr. sleepless).
C. My sleep is mildly disturbed (1-2 hrs. sleepless).
D. My sleep is moderately disturbed (2-3 hrs. sleepless).
E. My sleep is greatly disturbed (3-5 hrs. sleepless).
F. My sleep is completely disturbed (5-7 hrs. sleepless).

SECTION 10 – Recreation

A. I am able to engage in all my recreation activities with no neck pain at all.
B. I am able to engage in all my recreation activities with some pain in my neck.
C. I am able to engage in most, but not all of my usual recreation activities because of pain in my neck.
D. I am able to engage in a few of my usual recreation activities because of pain in my neck.
E. I can hardly do any recreation activities because of pain in my neck.
F. I cannot do any recreation activities at all.

OTHER COMMENTS:

Examiner

With Permission from: Vernon H, Mior S. The Neck Disability Index: *A study of reliability and validity.* J Manipulative Physiol Ther 1991;14:409-415. Copyright Vernon H and Hagino C, 1990.

SHOULDER PAIN AND DISABILITY INDEX (SPADI)

Patient Name Kevin Brown

Date

Please read carefully:

Instructions: Please circle the number that best describes the question being asked.

Pain scale:
No pain at all 0 1 2 3 4 5 6 7 8 9 10 Worst pain Imaginable

How severe is your pain?

1. At its worst?
0 1 2 3 4 5 6 7 8 9 10

2. When lying on the involved side?
0 1 2 3 4 5 6 7 8 9 10

3. Reaching for something on a high shelf?
0 1 2 3 4 5 6 7 8 9 10

4. Touching the back of your neck?
0 1 2 3 4 5 6 7 8 9 10

5. Pushing with the involved arm?
0 1 2 3 4 5 6 7 8 9 10

Disability scale:
No difficulty 0 1 2 3 4 5 6 7 8 9 10 So difficult it requires help

How much difficulty do you have?

1. Washing your hair?
0 1 2 3 4 5 6 7 8 9 10

2. Washing your back?
0 1 2 3 4 5 6 7 8 9 10

3. Putting on an undershirt or pullover sweater?
0 1 2 3 4 5 6 7 8 9 10

4. Putting on a shirt that buttons down the front?
0 1 2 3 4 5 6 7 8 9 10

5. Putting on your pants?
0 1 2 3 4 5 6 7 8 9 10

6. Placing an object on a high shelf?
0 1 2 3 4 5 6 7 8 9 10

7. Carrying a heavy object of 10 pounds?
0 1 2 3 4 5 6 7 8 9 10

8. Removing something from your back pocket?
0 1 2 3 4 5 6 7 8 9 10

OTHER COMMENTS:

Examiner:

With permission from: Williams JW Jr., Holleman DR Jr., Simel DL: Measuring shoulder function with the Shoulder Pain and Disability Index. *J Rheumatol* 1995; 22 (4); 727-732

REVISED OSWESTRY BACK PAIN DISABILITY QUESTIONNAIRE

Name Karen Brown

Date _____

Please read carefully:

This questionnaire has been designed to enable us to understand how your back pain has affected your ability to manage everyday life. Please answer every section, and mark in each section only ONE CHOICE which applies to you. We realize that you may consider that two of the statements in any one section relate to you, but please just mark the one box which most closely describes your problem right now.

SECTION 1 – Pain Intensity

A. The pain comes and goes and is very mild.
B. The pain is mild and does not vary much.
C. The pain comes and goes and is moderate.
(D) The pain is moderate and does not vary much.
E. The pain comes and goes and is severe.
F. The pain is severe and does not vary much.

SECTION 2 – Personal Care

A. I would not have to change my way of washing or dressing in order to avoid pain.
(B) I do not normally change my way of washing or dressing even though it causes some pain.
C. Washing and dressing increases the pain, but I manage not to change my way of doing it.
D. Washing and dressing increases the pain and I find it necessary to change my way of doing it.
E. Because of the pain, I am unable to do some washing and dressing without help.
F. Because of the pain, I am unable to do any washing or dressing without help.

SECTION 3 – Lifting

A. I can lift heavy weights without extra pain.
B. I can lift heavy weights but it gives me extra pain.
C. Pain prevents me from lifting heavy weights off the floor.
D. Pain prevents me from lifting heavy weights off the floor, but I can manage if they are conveniently positioned-eg, on a table
(E) Pain prevents me from lifting heavy weights, but I can manage light to medium weights if they are conveniently positioned.
F. I can only lift very light weights, at the most.

SECTION 4 – Walking

A. Pain does not prevent me from walking any distance.
B. Pain prevents me from walking more than 1 mile.
C. Pain prevents me from walking more than ½ mile.
(D) Pain prevents me from walking more than ¼ mile.
E. I can only walk using a stick or crutches.
F. I am in bed most of the time and have to crawl to the toilet.

SECTION 5 – Sitting

A. I can sit in any chair as long as I like without pain.
B. I can only sit in my favorite chair as long as I like.
C. Pain prevents me sitting more than 1 hour.
(D) Pain prevents me sitting more than ½ hour.
E. Pain prevents me sitting more than 10 minutes.
F. Pain prevents me from sitting at all.

OTHER COMMENTS:

_____

_____

SECTION 6 – Standing

A. I can stand as long as I want without pain.
B. I have some pain while standing, but it does not increase with time.
C. I cannot stand for longer than 1 hour without increasing pain.
(D) I cannot stand for longer than ½ hour without increasing pain.
E. I cannot stand for longer than 10 minutes without increasing pain.
F. Pain prevents me from standing at all.

SECTION 7 – Sleeping

A. I get no pain in bed.
B. I get pain in bed, but it does not prevent me from sleeping well.
C. Because of pain, my normal night's sleep is reduced by less than one-quarter.
(D) Because of pain, my normal night's sleep is reduced by less than one-half.
E. Because of pain, my normal night's sleep is reduced by less than three-quarters.
F. Pain prevents me from sleeping at all.

SECTION 8 – Social Life

A. My social life is normal and gives me no pain.
B. My social life is normal, but increases the degree of my pain.
C. Pain has no significant effect on my social life apart from limiting my more energetic interests, eg, dancing, etc.
(D) Pain has restricted my social life and I do not go out very often.
E. Pain has restricted my social life to my home.
F. I have hardly any social life because of the pain.

SECTION 9 – Traveling

A. I get no pain while traveling.
B. I get some pain while traveling but none of my usual forms of travel make it any worse.
(C) I get extra pain while traveling but it does not compel me to seek alternative forms of travel.
D. I get extra pain while traveling which compels me to seek alternative forms of travel.
E. Pain restricts all forms of travel.
F. Pain prevents all forms of travel except that done lying down.

SECTION 10 – Changing Degree of Pain

A. My pain is rapidly getting better.
B. My pain fluctuates, but overall is definitely getting better.
C. My pain seems to be getting better, but improvement is slow at present.
D. My pain is neither getting better nor worse.
(E) My pain is gradually worsening.
F. My pain is rapidly worsening.

_____
Examiner

With Permission from: Hudson-Cook N, Tomes-Nicholson K, Breen AC. A Revised Oswestry Back Disability Questionnaire. Manchester Univ Press, 1989.

ROLAND-MORRIS QUESTIONNAIRE

Patient Name Karen Brown

Date _____

Please read carefully:
When your back hurts, you may find it difficult to do some of the things you normally do. Mark only the sentences that describe you today.

1. ✓ I stay at home most of the time because of my back.
2. ✓ I change positions frequently to try and get my back comfortable.
3. ✓ I walk more slowly than usual because of my back.
4. ___ Because of my back, I am not doing any of the jobs that I usually do around the house.
5. ___ Because of my back, I use a handrail to get upstairs.
6. ___ Because of my back, I lie down to rest more.
7. ___ Because of my back, I have to hold on to something to get out of an easy chair.
8. ✓ Because of my back, I try to get other people to do things for me.
9. ✓ I get dressed more slowly because of my back.
10. ✓ I only stand up for short periods of time because of my back.
11. ✓ Because of my back, I try not to bend or kneel.
12. ✓ I find it difficult to get out of a chair because of my back.
13. ✓ My back is painful almost all of the time.
14. ___ I find it difficult to turn over in bed because of my back.
15. ✓ My appetite is not very good because of my back.
16. ✓ I have trouble putting on my socks/stockings because of my back.
17. ✓ I only walk short distances because of my back pain.
18. ✓ I sleep less well because of my back pain.
19. ✓ Because of my back pain, I get dressed with help from someone else.
20. ✓ I sit down for most of the day because of my back.
21. ✓ I avoid heavy jobs around the house because of my back.
22. ✓ Because of my back pain, I am more irritable and bad tempered with people than usual.
23. ✓ Because of my back, I go upstairs more slowly than usual.
24. ✓ I stay in bed most of the day because of my back.

OTHER COMMENTS:

_____

Examiner

With Permission from: Roland M, Morris R. *A study of the natural history of back pain: Part I: Development of a reliable and sensitive measure of disability in low-back pain.* Spine 1983;8:141-144.

19 Pages via SFTP Mon, 19 Feb 2024 11:16:11 GMT

SUBJECTIVE KNEE SCORE QUESTIONNAIRE

Patient Name Kern Brown

Date _____

Please read carefully:
Please answer every section, and mark in each section only ONE CHOICE which applies to you. We realize that you may consider that two of the statements in any one section relate to you, but please just mark the one box which most closely describes your problem right now.

PAIN
(✓) I experience no pain in my knee.
( ) I have occasional pain with strenuous sports or heavy work. I don't think that my knee is entirely normal. Limitations are mild and tolerable.
( ) There is occasional pain in my knee with light recreational sports or moderate work.
( ) I have pain brought on by sports, light recreational activities, or moderate work. Occasional pain is brought on by daily activities such as standing or kneeling.
( ) The pain I have in my knee is a significant problem with activities as simple as walking. The pain is relieved by rest. I can't participate in sports.

SWELLING
(✓) I experience no swelling in my knees.
( ) I have occasional swelling in my knee with strenuous sports or heavy work.
( ) There is occasional swelling with light recreational activities or moderate work.
( ) Swelling limits my participation in sports and moderate work. Occurs infrequently with simple walking or light work. Occasionally with simple walking or light work – about 3 times a year.
( ) My knee swells after simple walking activities and light work. Rest relieves the swelling.
( ) I have severe swelling with simple walking activities. Rest does not relieve the swelling.

STABILITY
(✓) My knee does not give out.
( ) My knee gives out only with strenuous sports or heavy work.
( ) My knee gives out occasionally with light recreational activities or moderate work; it limits my vigorous activities, sports, or heavy labor.
( ) Because my knee gives out, it limits all sports and moderate work. It occasionally gives out with walking or light work.
( ) My knee gives out frequently with simple activities such as walking. I must guard my knee at all times.
( ) I have severe problems with my knee giving out. I can't turn or twist without my knee giving out.

OVERALL ACTIVITY LEVEL
(✓) No limitations. I have a normal knee, and I am able to do everything including strenuous sports and/or heavy labor.
( ) I can partake in sports including strenuous ones but at a lower level. I must guard my knee and limit the amount of heavy labor or sports.
( ) Light recreational activities are possible with RARE symptoms. I am limited to light work.
( ) No sports or recreational activities are possible. Walking activities are possible with RARE symptoms. I am limited to light work.
( ) Walking activities and daily living cause moderate problems and persistent symptoms.
( ) Walking and other daily activities cause severe problems.

WALKING
(✓) Normal, unlimited
( ) Slight, mild problems.
( ) Moderate problem, flat surface up to half a mile.
( ) Severe problems, only 2-3 blocks.
( ) Severe problems, need cane or crutches.

STAIRS
(✓) Normal, unlimited
( ) Slight, mild problems.
( ) Moderate problem, only 10-15 steps possible.
( ) Severe problems, require banister for support.
( ) Severe problems, only 1-5 steps without support.

RUNNING
(✓) Normal, unlimited, fully competitive.
( ) Slight, mild problems, run at half speed.
( ) Moderate problems, only 1-2 miles possible.
( ) Severe problems, only 1-3 blocks possible.
( ) Severe problems, only a few steps.

JUMPING AND TWISTING
(✓) Normal, unlimited, fully competitive.
( ) Slight, mild problems, some guarding.
( ) Moderate problems, gave up strenuous sports.
( ) Severe problems, affects all sports, always guarding.
( ) Severe problems, only light activity possible (pool/swim).

Examiner: _____

With permission from: Noyes FR, et al. Functional disability in the anterior cruciate insufficient knee syndrome. Review of knee rating systems and project risk factor sin determining treatment. Sports Med 1984; 1: 278-302. Copyright Adis International, Inc.

Farrockaway Medical PC
62-69 99th St
Rego Park, NY 11374
nyregoparkmedical@gmail.com

DATE: 02/06/24.

FOLLOW UP REPORT: 4

DATE OF ACCIDENT: 10/13/2023

PATIENT'S NAME: Keun, Braun

AGE: 36

AT THE TIME OF THE INITIAL EVALUATION PATIENT PRESENTED COMPLAINTS OF:

HEADACHE DIFUSES FRONTAL TEMPORAL OCCIPITAL VOMITIMG
DIZZINESS BLURRED VISION
✓ NECK PAIN NON-RADIATING RADIATING TO _____
✓ LOWER BACK PAIN NON-RADIATING RADIATING TO _____
MID BACK PAIN NON-RADIATING RADIATING TO _____
SHOULDERS RT LT TINGLING NUMBNESS
WRIST RT LT TINGLING NUMBNESS
ELBOWS RT LT TINGLING NUMBNESS
HANDS RT LT TINGLING NUMBNESS
HIPS RT LT TINGLING NUMBNESS
KNEES RT LT TINGLING NUMBNESS
✓ ANKLES ✓ RT LT TINGLING NUMBNESS
FEET RT LT TINGLING NUMBNESS
CHEST RT LT TINGLING NUMBNESS
ABDOMEN RT LT TINGLING NUMBNESS
NERVOUNESS
INSOMNIA ANXIETY FEAR DRIVING/SITTING IN THE CAR FEAR OF CROSSING STREET
OTHER _____

Outcome Assessment results discussed thoroughly with patient

ECN: 2024031200360 Received Date: 2024-03-12

PRESENT COMPLAINTS

HEAD
FACE
NECK
CHEST
THORACIC SPINE
LOWER BACK
STRESS
HEADACHES
VOMITING

SACRAL AREA
PELVIS
SHOULDER RT LT
ELBOWS RT LT
WRIST RT LT
HAND RT LT
SPEECH
BLURRED VISION
NERVOUSNESS/INSOMNIA

HIPS RT LT
KNEES RT LT
ANKLES RT LT
FEET RT LT
ABDOMEN RT LT
OTHER_____
FEAR OF DRIVING
SITTING IN CAR
CROSSING THE STREET

PHYSICAL EXAMINIATION REVEALED:

B/P___/___ PULSE_____ RR_____ AFEBRILE FEBRILE

PATIENT IS AAOX3, MEMORY [ ] IS INTACT [ ] HAS POOR MEMORY SINCE THE ACCIDENT
SPEECH IS FLUENT AND COHERENT
PATIENT APPEARS TO BE IN [ ] MILD [ ] MODERATE [ ] SEVERE DISTRESS DUE TO PAIN AND DISCOMFORT
PATIENT IS NOT IN ACUTE DISTRESS, BUT FEELS QUITE UNCOMFORTABLE AND TENSE
S1S2R LUNGS ABDOMEN SOFT, NT

CERVICAL SPINE

PALPATION OF THE NECK REVEALS DOES NOT REVEAL MILD MODERATE SEVERE
CERVICAL
SPINE TENDERNESS AT THE C__ C__ LEVEL NO STEP OFF APPRECIATED
INCREASE IN R L MUSCLE TONE ION PARAVERTEBRAL TRAPEZIUS RHOMBOID MUSCL
NORMAL EXAMINATION OF THE CERVICAL SPINE

ECN: 2024031200360 Received Date: 2024-03-12

SPECIAL TEST AND SIGNS

DISTRACTION TEST	POSTIVE	NEGATIVE
COMPRESSION TEST	POSTIVE	NEGATIVE
SHOULDER DEPRESSION TEST	POSTIVE	NEGATIVE
FORAMINA COMPRESSION TEST	POSTIVE	NEGATIVE

	NORMAL ROM	PATIENT'S ROM	PAIN
FLEXION	45	FROM ROM___	POSITIVE
EXTENSION	55	FROM ROM___	POSITIVE
RIGHT ROTATION	70	FROM ROM___	POSITIVE
LEFT ROTATION	70	FROM ROM___	POSITIVE
RIGHT LATERAL FLEXION	40	FROM ROM___	POSITIVE
LEFT LATERAL FLEXION	40	FROM ROM___	POSITIVE

THORACIC SPINE:

THERE APPEARS TO BE TENDRNESS OF THE THORACIC SPINE AT LEVELS T____T____ WITH SPASM OF RIGHT LEFT PARASPINAL STRUCTURES
THERE IS NO TENDERNESS OR PAIN ON PALPATION

LUMBOSACRAL SPINE

PALPATION OF LUMBOSACRAL SPINE REVEALS DOES NOT REVEAL MILD MOLDERATE SEVERE
TENDERNESS AT THE L L S LEVEL
INCREASE IN RIGHT LEFT PARAVERETEBRAL MUSCLE TONE
NORMAL EXAMINATION OF THE LUMBOSACRAL SPINE

SPECIAL TEST AND SIGNS:

SPINAL PRECUSSION TEST	POSITIVE	NEGATIVE
FABERE- PATRICK TEST	POSITIVE	NEGATIVE
STRAIGHT LEG RAISE TEST	POSITIVE @___ ON THE RT @___ ON THE LT	NEGATIVE

ECN: 2024031200360 Received Date: 2024-03-12

	NORMAL ROM	PATIENT'S ROM	PAIN
FLEXION	90	☐ FROM ☐ ROM 80	☐ POSITIVE
EXTENTSION	30	☐ FROM ☐ ROM 20	☐ POSITIVE
RIGHT ROTATION	30	☐ FROM ☐ ROM	☐ POSITIVE
LEFT ROTATION	30	☐ FROM ☐ ROM	☐ POSITIVE
RIGHT LATERAL FLEXION	35	☐ FROM ☐ ROM 32	☐ POSITIVE
LEFT LATERAL FLEXION	35	☐ FROM ☐ ROM 32	☐ POSITIVE

SHOULDER:	NORMAL ROM	PATIENT'S ROM	RIGHT	LEFT
FLEXION/ ELEVATION	180	☐ FROM ☐ ROM ___	___	___
EXTENSION	50	☐ FROM ☐ ROM ___	___	___
ABDUCTION	180	☐ FROM ☐ ROM ___	___	___
ADDUCTION	50	☐ FROM ☐ ROM ___	___	___
INTERNAL ROTATION	90	☐ FROM ☐ ROM ___	___	___
EXTENAL ROTATION	90	☐ FROM ☐ ROM ___	___	___

☐ CREPITUS IS APPRECIATED ☐ RIGHT ☐ LEFT SUBACROMAL / SUBDALTOID BURSA

☐ ABLE ☐ UNABLE TO ELEVATE AND HOLD ☐ RIGHT ☐ LEFT ARM AT ABOVE SHOULDER LEVEL

☐ TENDERNESS ☐ AT CREPITUS AT AC JOINT ☐ AT THE LEVEL OF ROTATOR CUFF INSERTION (LIGAMENTS OF SIT MUSCLES)

ELBOWS:	NORMAL ROM	PATIENT'S ROM	RIGHT	LEFT
FLEXION	160	☐ FROM ☐ ROM	___	___
EXTENSION	180	☐ FROM ☐ ROM	___	___
SUPINATION	90	☐ FROM ☐ ROM	___	___
PRONATION	90	☐ FROM ☐ ROM	___	___

☐ CREPITUS IS APPRECIATED ☐ RIGHT ☐ LEFT

WRIST:	NORMAL ROM	PATIENT'S ROM	RIGHT	LEFT
FLEXION	160	☐ FROM ☐ ROM	___	___
EXTENSION	180	☐ FROM ☐ ROM	___	___
SUPINATION	90	☐ FROM ☐ ROM	___	___
PRONATION	90	☐ FROM ☐ ROM	___	___

CREPITUS IS APPRECIATED IS APPREICATED ☐ RIGHT ☐ LEF

HIPS: NORMAL ROM PATIENT'S ROM RIGHT LEFT

FLEXION	120	FROM ROM		
EXTENSION	15	FROM ROM		
ABDUCTION	45	FROM ROM		
INTERNAL ROTATION	40	FROM ROM		
EXTERNAL ROTATION	45	FROM ROM		

CREPITUS IS APPRECIATED RIGHT LEFT

KNEES: NORMAL ROM PATIENT'S ROM RIGHT LEFT

FLEXION	130	FROM ROM		
EXTENSION	15	FROM ROM		
CREPITUS IS APPRECIARED		FROM ROM		

BULGE/ BALLOTING SIGNOF THE PATELLA IS IS NOT PRESENT ON RIGHT LEFT
ANTERIOR DRAWS SIGN IS POSTIVE NEGATIVE ON RIGHT LIGHT
LACHMAN TEST IS POSITIVE NEGATIVE ON RIGHT LEFT
VARUS STRESS TEST DETECTING mol IS POSITIVE NEGATIVE
VALGUS STRESS TEST DETECTING LCL IS POSTIVE NEGATIVE

ANKLES: NORMAL ROM PATIENT'S ROM RIGHT LEFT

DORSI FLEXION	20	FROM ROM		
PLANTER EXTENSION	45	FROM ROM		
INVERSION	30	FROM ROM		
EVERSION	20	FROM ROM		

CREPITUS IS APPRECIATED RIGHT LEFT
SWELLING/ EDEMA IS APPRECIATED ON RIGHT LEFT
MEDIAL LATERAL MALLEOLI

ECN: 2024031200360 Received Date: 2024-03-12

MOTOR SYSTEMS

MOTOR MUSCLES TEST WERE _____ THROUGHOUT
NO MUSCLE ATHROPHY IS NOTED
DEEP TENDON REFLEXES ARE BILATERALLY EQUAL AND SYMMETRIC; DTR'S _____ THROUGHOUT
TOES ARE DOWNGOING BILATERALLY

SENSORY SYSTEMS

SENSORY EXAMINATION OF UPPE EXTREMITIES REVEALS DECREASED RESPONSE TO LIGHT, TOUCH AND PINPRICK SENSATION IN:

R L TRAPEZUIS (C3-C4) NERVE DISTRIBUTION
R L DELTOID (C5-C6) NERVE DISTRIBUTION
R L BICEP (C6) NERVE DISTRIBUTION
R L RADIAL (C6-C7) NERVE DISTRIBUTION
R L MEDIAN (C7-C9) NERVE DISTRIBUTION
R L ULNAR (C8-T1) NERVE DISTRIBUTION

TINEL'S SIGN	+	-@ RIGHT	+	-@ LEFT
FINKEL STEIN'S TEST	+	-@ RIGHT	+	-@ LEFT
PHALEN'S SIGN	+	-@ RIGHT	+	-@ LEFT

SENSORY EXAMINATION OF UPPER EXREMITTIES REVEALS NORMAL SENSITIVITY

SENSORY EXAMINATION OF LOWER EXTREMITIES REVEALS DECREASED RESPONSE TO LIGHT, TOUCH AND PINPRICK SENSATION IN:

R L GLUTEL (L-5) NERVE DISTRIBUTION
R L VASTUS (L3- L4) NERVE DISTRIBUTION
R L SCIARIA (LS- S2) NERVE DISTRIBUTION
R L TIBIAL ANTERIOR (L4-L5) NERVE DISTRIBUTION
R L PERNONEUS (L5-S1) NERVE DISTRIBUTION
R L GASTROCNEMIUS (L4- S1) NERVER DISTRIBUTION
SENSORY EXAMINATION OF THE UPPER EXTREMITTIES REVEALS NORMAL SENSITIVITY

ECN: 2024031200360 Received Date: 2024-03-12

DIAGNOSTIC RESULTS:

X-RAY OF_____ WAS DONE __/__/__ AND DEMONSTRATED _____

X-RAY OF_____ WAS DONE __/__/__ AND DEMONSTRATED _____

X-RAY OF_____ WAS DONE __/__/__ AND DEMONSTRATED _____

MRI/CT OF_____ WAS DONE __/__/__ AND DEMONSTRATED _____

MRI/CT OF_____ WAS DONE __/__/__ AND DEMONSTRATED _____

MRI/CT OF_____ WAS DONE __/__/__ AND DEMONSTRATED _____

MRI/CT OF_____ WAS DONE __/__/__ AND DEMONSTRATED _____

MRI/CT OF_____ WAS DONE __/__/__ AND DEMONSTRATED _____

CS DB 3-1
6-1
DHJ-1

LS DHK-1

12 Pages via SFTP Thu, 14 Mar 2024 02:21:29 GMT

ECN: 2024031200360 Received Date: 2024-03-12

BASE ON THE ABOVE FINDINGS, ADDITIONAL TEST AND THERAPY INDICATED:

CONTINUE PHYSICAL THERAPY 2 TIMES PER WEEK

X-RAY(S) OF THE _____ TO RULE OUT FRACTURE

MRI/CT SCAN OF _____ TO RULE OUT

NEUROLOGIST CONSULTATION TO RULE OUT _____

PHYSCHOLOGIST CONSULTATION TO RULE OUT _____

ORTHOPEDIC CONSULTATION TO RULE OUT _____

ADDITIONAL THERAPEUTIC EQUIPMENT SUCH AS

OTHER _____

PATIENT WILL BE RE- EVALUATED IN 8 WEEK

PATIENT WAS DISCHARGED SINCE SYMPTOMS IMPROVED WITH PHYSCIAL THERAPY

RESPECTFULLY SUMITTED,

JEAN-PIERRE GEORGES BARAKAT, MD
INTERNAL MEDICINE

12 Pages via SFTP Thu, 14 Mar 2024 02:21:29 GMT

ECN: 2024031200360 Received Date: 2024-03-12

DIAGNOSIS IMPRESSIONS: ICD 10

	CERVICAL SPINE DX		HIPS
M54.2	CERVICALGIA	M25.551	PAIN IN RIGHT HIP
S13.4XXA	SPRAIN OF LIGAMENTS OF C/S 1E	M25.552	PAIN IN LEFT HIP
S13.8XXA	SPRAIN OF JOINTS & LIGAMNETS OF OTHER PARTS OF NECK, 1E	S73.301A	UNSPECIFIED SPRAIN OF RIGHT HIP, 1E
S16.1XXA	STRAIN OF MUSCLE, FASCIA AND TENDON AT NECK LEVEL, 1E	S73.302A	UNSPECIFIED SPRAIN OF LEFT HIP, 1E
M54.11	RADICULOPATHY, OCCIPITO-ATLANTO-AXIAL REGION		KNEES
M54.12	RADICULOPATHY, CERVICAL REGION	M25.561	PAIN IN RIGHT KNEE
M54.13	RADICULOPATHY, CERVICOTHORACIC REGION	M25.562	PAIN IN LEFT KNEE
M50.20	OTHER CERVICAL DISC DISPLACEMENT, UNSP. CERVICAL REG.	S83.90XA	SPRAIN OF UNSPECIFIED SITE OF RIGHT KNEE, 1E
M50.21	OTHER CERVICAL DISC DISPLACEMENT, HIGH CERVICAL REGION	S83.91XA	SPRAIN OF UNSPECIFIED SITE OF LEFT KNEE, 1E
M50.22	OTHER CERVICAL DISC DISPLACEMENT, MID-CERVICAL REGION	S80.01XA	CONTUSION OF RIGHT KNEE, 1E
M50.23	OTHER CERVICAL DISC DISPLACEMENT, CERVICOTHORACIC	S80.02XA	CONTUSION OF LEFT KNEE, 1E
M99.01	SEGMENTAL & SOMATIC DYSFUNCTION OF CERVICAL REGION	S83.206A	UNSP TEAR, OF UNSP MENISCUS, CURRENT INJURY, RIGHT KNEE, I
M79.1	MYALGIA	S83.207A	UNSP TEAR, OF UNSP MENISCUS, CURRENT INJURY, LEFT KNEE, 1E
	THORACIC SPINE DX		ANKLE/FOOT
M54.6	PAIN IN THORACIC SPINE	S93.401A	SPRAIN OF UNSPECIFIED LIGAMENT OF RIGHT ANK
S23.3XXA	SPRAIN OF LIGAMENTS OF THORACIC SPINE, 1E	S93.402A	SPRAIN OF UNSPECIFIED LIGAMENT OF LEFT ANKL
S23.8XXA	SPRAIN OF OTHER SPECIFIED PARTS OF THORAX, 1E	M25.571	PAIN IN RIGHT ANKLE & JOINTS OF RIGHT FOOT
M51.34	INTERVERTEBRAL DISC DISORDER WITH RADIC, THORACIC REG	M25.572	PAIN IN LEFT ANKLE & JOINTS OF LEFT FOOT
M51.35	INTERVERTEBRAL DISC DISORDER WITH RADIC, THORACOLUMBAR		SHOULDERS
M54.14	RADICULOPATHY, THORACIC REGION	S43.401A	UNSPECIFIED SPRAIN OF RIGHT SHOULDER, 1E
M54.15	RADICULOPATHY, THORACOLUMBAR REGION	S43.402A	UNSPECIFIED SPRAIN OF LEFT SHOULDER, 1E
M51.24	OTHER INTERVERTEBRAL DISC DISPLACEMENT, THORACIC REG	M25.511	PAIN, RIGHT SHOULDER
M54.25	OTHER INTERVERTEBRAL DISC DISPLACEM., THORACOLUMBAR	M25.512	PAIN, LEFT SHOULDER
M99.02	SEGMENTAL & SOMATIC DYSFUNCTION OF THORACIC REGION	S46.011A	STRAIN/TEAR OF MUSCLE AND TENDON, ROTATOR RIGHT
	LUMBAR--LUMBOSACRAL DX	S46.012A	STRAIN/TEAR OF MUSCLE AND TENDON, ROTATOR LEFT
M54.5	LOW BACK PAIN	S40.011A	CONTUSION OF RIGHT SHOULDER, 1E
S33.5XXA	SPRAIN OF LIGAMENTS OF LUMBAR SPINE, 1E	S40.012A	CONTUSION OF LEFT SHOULDER, 1E
S33.9XXA	SPRAIN OF UNSPESIFIED PARTS OF LUMBAR SPINE & PELVIS, 1E		MISCELLENEOUS
M51.16	INTERVERTEBRAL DISC DISORDER WITH RADIC, LUMBAR REG	M62.830	MUSCLE SPASM OF BACK
M51.17	INTERVERTEBRAL DISC DISORDER WITH RADIC, LUMBOSACRAL	M62.81	MUSCLE WEAKNESS
M54.16	RADICULOPATHY, LUMBAR REGION	M79.1	MYALGIA
M54.17	RADICULOPATHY, LUMBOSACRAL REGION	R42	DIZZINESS
M51.26	OTHER INTERVERTEBRAL DISC DISPLACEMENT, LUMBAR REG	R45	NERVOUSNESS
M51.27	OTHER INTERVERTEBRAL DISC DISPLACEMENT, LUMBOSACRAL	R51	HEADACHE (UNSPECIFIED)
M99.03	SEGMENTAL & SOMATIC DYSFUNCTION OF LUMBAR REGION	M99.00	SEGMENTAL & SOMATIC DYSFUNCTION OF HEAD
M99.04	SEGMENTAL & SOMATIC DYSFUNCTION OF SACRAL REGION	M99.01	SEGMENTAL & SOMATIC DYSFUNCTION OF CERVI
M99.05	SEGMENTAL & SOMATIC DYSFUNCTION OF PELVIC REGION	M99.02	SEGMENTAL & SOMATIC DYSFUNCTION OF THOR
	WRISTS	M99.03	SEGMENTAL & SOMATIC DYSFUNCTION OF LUME
S63.501A	UNSPECIFIED SPRAIN OF RIGHT WRIST	M99.04	SEGMENTAL & SOMATIC DYSFUNCTION OF SACR
S63.502A	UNSPECIFIED SPRAIN OF LEFT WRIST	M99.05	SEGMENTAL & SOMATIC DYSFUNCTION OF PELVI
M79.631	PAIN IN RIGHT FOREARM	M99.06	SEGMENTAL & SOMATIC DYSFUNCTION OF LOWI
M79.632	PAIN IN LEFT FOREARM	M99.07	SEGMENTAL & SOMATIC DYSFUNCTION OF UPPE
M79.643	PAIN IN RIGHT HAND	M99.08	SEGMENTAL & SOMATIC DYSFUNCTION OF RIB C
M79.642	PAIN IN LEFT HAND		

ALL COUNTY, LLC

Diagnostic Radiology, Traumatic Brain Injury
Open MRI, Mid Field 1.5T, High Field 3T
(718) 359-8700 • FAX (718) 762-0067
161-05 Horace Harding Exp.
Flushing, New York 11365

Referred by: Jean Pierre Borakat
Signature:
Address: 62-69 99th Street
Rego Park NY 11374
Date:

Patient's Name: Kevin Brown D.O.B.: 7/9/1987
Phone: 347-649-1719 Fax:

Workman's Compensation Date of Accident:
Employer Name & Phone:
Insurance Company Name & Phone:
Claim # or SS#:

No Fault Date of Accident:
Insurance Company Name & Address:
Claim #
Adjuster:

Traumatic Brain Injury (TBI)

- ☐ Routine Brain
- ☐ Trauma Brain (includes SWI)
- ☐ DTI (ROI Technique)

MRI

- ☐ Brain
- ☐ Pituitary
- ☐ IACs
- ☐ Orbits
- ☐ Sinuses
- ☐ Neck-Soft Tissues
- ☐ Brachial Plexus
- ☒ Cervical Spine
- ☐ Thoracic Spine
- ☒ Lumbar Spine
- ☐ Chest
- ☐ Abdomen
- ☐ Pelvis
- ☐ Other

Extremities	Rt.	Lt.
☐ Shoulder	☐	☐
☐ Elbow	☐	☐
☐ Wrist	☐	☐
☐ Hand	☐	☐
☐ Hip	☐	☐
☐ Knee	☐	☐
☒ Ankle	☒	☐
☐ Foot	☐	☐
☐ Other		

MR Angiography	High Field
☐ Brain MRA	☐
☐ 3T	☐
☐ Neck MRA	☐
☐ Thoracic Aorta MRA	☐
☐ Abdominal Aorta MRA	☐
☐ Renal MRA	☐
☐ Upper Extremity MRA	☐
☐ Lower Extremity MRA	☐
☐ Other	

GENERAL RADIOLOGY DIGITAL X RAY

Skeletal

- ☐ Skull
- ☐ Cervical Spine
- ☐ Thoracic Spine
- ☐ Lumbar Spine
- ☐ Pelvis ☐ Sacrum/Coccyx

Extremities	Rt.	Lt.
☐ Shoulder	☐	☐
☐ Arm	☐	☐
☐ Elbow	☐	☐
☐ Forearm	☐	☐
☐ Wrist	☐	☐
☐ Hand	☐	☐
☐ Hip	☐	☐
☐ Femur	☐	☐
☐ Knee	☐	☐
☐ Tibia/Fibula	☐	☐
☐ Ankle	☐	☐
☐ Foot	☐	☐

ENT

- ☐ Paranasal Sinuses
- ☐ Nasopharynx
- ☐ Nasal Bones
- ☐ Facial Bones

Abdomen

- ☐ KUB
- ☐ Flat/Erect
- ☐ Other

Chest

- ☐ Pa/Lat
- ☐ Ribs

All County, LLC

Diagnostic Radiology

Article 28 Diagnostic & Treatment Center Cert. No. 7003267R

11/02/23

Jean Pierre Barakat, MD
62-69 99th Street
Rego Park, NY 11374
Fax #:(347) 578-8753

Re: Kevin Michael Brown
DOB: 07/06/1987
Pt. Tel# (646) 644-4417
Patient#: 307830

Dear Dr. Barakat:

MRI OF THE CERVICAL SPINE:

TECHNICAL FACTORS:
Noncontrast MRI of the cervical spine performed utilizing multiplanar and multisequence acquisition.

FINDINGS:
There is no fracture, vertebral body anomaly or bone lesion. Bones and muscular structures demonstrate normal signal intensity. The paraspinal soft tissues are unremarkable.

Cerebellar tonsils are normal in position. The cervical spinal cord shows no abnormal increased signal intensity.

There is lower right convex scoliosis with straightening of the upper cervical lordosis.

At C2-C3, partial congenital fusion is appreciated.

At C3-C4, spondylotic disc bulging is present with superimposed spondylotic left disc herniation complex effacing the anterior thecal sac impinging upon the left nerve roots.

At C4-C5, no disc herniation, spinal canal or neural foraminal abnormality identified.

At C5-C6, right neural foraminal disc herniation impinges upon its nerve root.

At C6-C7, spondylotic disc bulging narrows the neural foramina bilaterally.

161-05 Horace Harding Exp., Flushing, NY 11365
Tel 718.359.8700 Fax 718.762.0067
Flushing@allcountyradiology.com
www.allcountyradiology.com

All County, LLC

Diagnostic Radiology

Article 28 Diagnostic & Treatment Center Cert. No. 7003267R

11/02/23

Re: Kevin Michael Brown
DOB: 07/06/1987
Pt. Tel# (646) 644-4417
Patient#: 307830

MRI OF THE CERVICAL SPINE:

At C7-T1, disc bulging impinges upon the anterior thecal sac and mildly narrows the neural foramina bilaterally.

IMPRESSION:

- Malalignment as above.
- At C2-C3, partial congenital fusion is appreciated.
- At C3-C4, spondylotic disc bulging is present with superimposed spondylotic left disc herniation complex effacing the anterior thecal sac impinging upon the left nerve roots.
- At C5-C6, right neural foraminal disc herniation impinges upon its nerve root.
- At C6-C7, spondylotic disc bulging narrows the neural foramina bilaterally.
- At C7-T1, disc bulging impinges upon the anterior thecal sac and mildly narrows the neural foramina bilaterally.

We thank you for the courtesy of this referral and look forward to being of service to you in the future.

Ralph Dauito, M.D.
Board Certified Radiologist
ALL COUNTY, LLC
T: 11/08/2023 2:10 PM
RD/VC

161-05 Horace Harding Exp., Flushing, NY 11365
Tel 718.359.8700 Fax 718.762.0067
Flushing@allcountyradiology.com
www.allcountyradiology.com

All County, LLC

Diagnostic Radiology

Article 28 Diagnostic & Treatment Center Cert. No. 7003267R

11/02/23

Jean Pierre Barakat, MD
62-69 99th Street
Rego Park, NY 11374
Fax #:(347) 578-8753

Re:	Kevin Michael Brown
DOB:	07/06/1987
Pt. Tel#	(646) 644-4417
Patient#:	307830

Dear Dr. Barakat:

MRI OF THE LUMBAR SPINE:

TECHNICAL FACTORS:
Noncontrast MRI of the lumbar spine performed utilizing multiplanar and multisequence acquisition.

FINDINGS:
There is no fracture, vertebral body anomaly or bone lesion. Bones and muscular structures demonstrate normal signal intensity. Paraspinal soft tissues are unremarkable. Conus shows no abnormality.

There is lower right convex scoliosis with straightening of the upper lumbar lordosis.

At L1-L2, no disc herniation, spinal canal or neural foraminal abnormality identified.

At L2-L3, no disc herniation, spinal canal or neural foraminal abnormality identified.

At L3-L4, no disc herniation, spinal canal or neural foraminal abnormality identified.

At L4-L5, right disc herniation with annular tear effaces the anterior thecal sac impinging upon the nerve roots within the spinal canal. Disc bulging mildly narrows the neural foramina bilaterally.

161-05 Horace Harding Exp., Flushing, NY 11365
Tel 718.359.8700 Fax 718.762.0067
Flushing@allcountyradiology.com
www.allcountyradiology.com

All County, LLC

Diagnostic Radiology

Article 28 Diagnostic & Treatment Center Cert. No. 7003267R

11/02/23

Re: Kevin Michael Brown
DOB: 07/06/1987
Pt. Tel# (646) 644-4417
Patient#: 307830

MRI OF THE LUMBAR SPINE:

At L5-S1, disc space narrowing is present. Central disc herniation with annular tear is identified. Disc bulging narrows the neural foramina bilaterally.

IMPRESSION:

- Malalignment as above.
- At L4-L5, right disc herniation with annular tear effaces the anterior thecal sac impinging upon the nerve roots within the spinal canal. Disc bulging mildly narrows the neural foramina bilaterally.
- At L5-S1, disc space narrowing is present. Central disc herniation with annular tear is identified. Disc bulging narrows the neural foramina bilaterally.

We thank you for the courtesy of this referral and look forward to being of service to you in the future.

Ralph Dauito, M.D.
Board Certified Radiologist
ALL COUNTY, LLC
T: 11/08/2023 2:09 PM
RD/VC

Electronically approved by: Ralph Dauito, MD Date: 11/11/23 22:09

161-05 Horace Harding Exp., Flushing, NY 11365
Tel 718.359.8700 Fax 718.762.0067
Flushing@allcountyradiology.com
www.allcountyradiology.com

All County, LLC

Diagnostic Radiology

Article 28 Diagnostic & Treatment Center Cert. No. 7003267R

11/16/23

Jean Pierre Barakat, MD
62-69 99th Street
Rego Park, NY 11374
Fax #:(347) 578-8753

Re: Kevin Michael Brown
DOB: 07/06/1987
Pt. Tel# (646) 644-4417
Patient#: 307830

Dear Dr. Barakat:

MRI OF THE RIGHT ANKLE:

TECHNICAL FACTORS:
Noncontrast MRI of the right ankle performed utilizing multiplanar and multisequence acquisition.

FINDINGS:
2mm osteochondral lesion is seen involving the medial talar dome. Bones and muscular structures otherwise demonstrate normal signal intensity. There is no muscular tear or evidence of hematoma formation.

Tibiotalar effusion is present. Achilles tendon and plantar fascia are intact. Sprain injury is present at the anterior tibial tendon. Posterior tibial, peroneal, extensor digitorum and flexor hallucis longus tendons are intact as is tibiofibular and deltoid ligament. Sprain injury is seen at posterior talofibular ligament.

IMPRESSION:
- 2mm osteochondral lesion is seen involving the medial talar dome with joint effusion.
- Sprain injury is present at the anterior tibial tendon.

161-05 Horace Harding Exp., Flushing, NY 11365
Tel 718.359.8700 Fax 718.762.0067
Flushing@allcountyradiology.com
www.allcountyradiology.com

All County, LLC

Diagnostic Radiology

Article 28 Diagnostic & Treatment Center Cert. No. 7003267R

11/16/23

Re: Kevin Michael Brown
DOB: 07/06/1987
Pt. Tel# (646) 644-4417
Patient#: 307830

MRI OF THE RIGHT ANKLE:

- Sprain injury is seen at posterior talofibular ligament.

We thank you for the courtesy of this referral and look forward to being of service to you in the future.

Ralph Dauito, M.D.
Board Certified Radiologist
ALL COUNTY, LLC
T: 11/29/2023 11:55 AM
RD/VC

Electronically approved by: Ralph Dauito, MD Date: 12/04/23 18:45

161-05 Horace Harding Exp., Flushing, NY 11365
Tel 718.359.8700 Fax 718.762.0067
Flushing@allcountyradiology.com
www.allcountyradiology.com

SOLOMON HALIOUA, M.D.

22 Madison Ave., Suite 301, Paramus, NJ 07652

T: (201) 845-6555 F: (201) 845-5599

INITIAL CONSULTATION REPORT

PATIENT'S NAME: KEVIN BROWN
DATE OF INJURY: 10/13/2023
REFERRED BY: Dr. Jean-Pierre Barakat

DATE OF EXAM: 11-14-2023
DATE OF BIRTH: 07-06-1987

History of Present Illness

Date of Accident: 10/13/2023.

The patient is a 36 year-old right-handed male that was involved in a MVA on the above-mentioned date. He was a seat belted driver. He was jolted forward and backwards. The patient injured his neck, lower back and right ankle. The patient did not go to the hospital. He was later consulted and treated with Physical Therapy.

The patient has tried physical therapy, which helped to a limited extent. He has tried the following medications: Lidocaine 5% cream and Ibuprofen. Prior to the accident the patient was not suffering from any cervical, lumbosacral or extremity pain.
The patient was asymptomatic prior to this accident.

The current complaints are as follows:
Pain level is 3 out of 10 for the cervical spine.
Pain level is 9 out of 10 for the lumbar spine with radicular symptoms to the right lower extremity radiating down the right buttock, posterolateral aspect of the thigh, calf and foot. The pain is aggravated by prolonged standing, sitting and forward bending. The pain is associated with numbness, weakness, tingling and pins and needle sensation.
The patient denies any loss of bladder or bowel control.

Past Functional History The patient was doing well with no limitations for activities such as ADL and other vocational activities until the accident.

Current Functional History The patient reports difficulty with activities of daily living including lifting, carrying, standing, sitting, walking, and sleeping.

Past Accident History

Past Medical History
No Known Past Medical History

Surgical History

4 Pages via SFTP Tue, 05 Dec 2023 14:02:42 GMT

No Known Surgical History

Allergy
No Known Drug Allergies.

Current Medication
No Known Current Medication

Social History
Patient states that he never drinks any alcohol. Never smoker. He has never used any illicit drugs.
He is employed. The patient works for Instacart

Review of Systems The patient does not volunteer any systemic symptoms not described above.

General Physical Examination Vital signs are within normal limits. The patient is well-developed in moderate to severe distress secondary to pain and discomfort.

Reflexes: all brisk and intact.
Sensory Examination: Sensory examination is within normal limits.
Radicular Pattern: Radicular pattern of pain is mapped down in approximately Right L4. Radicular pattern of pain is mapped down in approximately Right L5.
Power Strength: Motor function is graded by manual resistance on the standard 0-5 scale. Muscle strength was +5/5 in bilateral shoulder abductors, elbow flexors, elbow extensors, hand grip, finger abduction, hip flexion, knee extension, ankle dorsiflexion, and ankle extension.
Examination of the Cervical Spine:
There is mild bilateral tenderness overlying the cervical facets of C3 through C7. Facet loading maneuvers aggravate the pain and cause concordant symptomatology. Lhermitte's sign was Negative on right. Lhermitte's sign was Negative on left . Spurling's test is Negative on right side. Spurling's test is Negative on left side.
Examination of the Lumbar Spine:
There is moderate to severe bilateral tenderness overlying the facets of L3 through S1. Facet loading maneuvers aggravate the pain and cause concordant symptomatology. SLR at 40 degree on right side . Lasegue sign was Positive on right side. Sciatic Notch tenderness noted Positive on right side.
Examination of the Right Ankle: There is mild tenderness at the lateral malleolus

Review of Imaging Study:
MRI of the cervical spine performed on 11/02/2023 reveals
At C2-C3, partial congenital fusion is appreciated.
At C3-C4, spondylotic disc bulging is present with superimposed spondylotic left disc herniation complex effacing the anterior thecal sac impinging upon the left nerve roots.
At C5-C6, right neural foraminal disc herniation impinges upon its nerve root.
At C6-C7, spondylotic disc bulging narrows the neural foramina bilaterally.
At C7-T1, disc bulging impinges upon the anterior thecal sac and mildly narrows the neural foramina bilaterally.

MRI of the lumbar spine performed on 11/02/2023 reveals
At L4- L5, right disc herniation with annular tear effaces the anterior thecal sac impinging upon the nerve roots within the spinal canal. Disc bulging mildly narrows the neural foramina bilaterally.
At L5-51, disc space narrowing is present. Central disc herniation with annular tear is identified. Disc bulging

4 Pages via SFTP Tue, 05 Dec 2023 14:02:42 GMT

narrows the neural foramina bilaterally.

Assessment and Plan

ICD: Radiculopathy, lumbar region (M54.16)
ICD: Cervical pain (M54.2)
ICD: Right ankle pain (M25.571)
ICD: Person injured in unspecified motor-vehicle accident, traffic, initial encounter (V89.2XXA)

Plan:

- Patient also has lumbar radiculitis with radiculopathy. The patient will undergo a single lumbar epidural injection under fluoroscopic guidance (62323). This is diagnostic as well as potentially therapeutic.
- The patient will continue Motrin and Flexeril 7.5mg.
- Plan discussed with the patient who agrees with treatment outlined today.
- I have reviewed with the patient their available diagnostic studies.
- This report shall serve as a letter of medical necessity to perform the above-mentioned procedure.
- All patient questions were answered. Adverse effects of medications and appropriate use reviewed.
- Follow-up parameters discussed.

CPT Codes:

Office/outpatient Visit New (99203)

CAUSAL RELATIONSHIP:

After taking a thorough medical history from the patient as well as reviewing diagnostic testing to date as well as notes of other treating physicians, and performing a thorough physical examination, it is my opinion that the patient has sustained the above-mentioned injuries/clinical syndrome as the result of the accident, dated 10/13/2023.

Respectfully Submitted,

Solomon Halioua, M.D.

This has been electronically signed by Solomon Halioua, M.D. for visit dated 11-14-2023.

4 Pages via SFTP Tue, 05 Dec 2023 14:02:42 GMT

New Horizon Surgical Center, L.L.C.
680 Broadway, Suite 201
Paterson, NJ 07514
Tel: (973)782-4202 Fax: (973)782-4206

DATE:	11-25-2023
PATIENT:	KEVIN BROWN
CHART NO:	SCL11793
MRN:	71066
D.O.B:	07-06-1987
AGE:	36 year

RECORD OF OPERATION

PREOPERATIVE DIAGNOSIS:	Lumbar radiculopathy
POSTOPERATIVE DIAGNOSIS:	Lumbar radiculopathy
PROCEDURE PERFORMED:	1. Lumbar epidural steroid injection x 1 L4-L5 translaminar approach. 2. Fluoroscopic assistance.
SURGEON:	Solomon Halioua, M.D.
ANESTHESIOLOGIST:	Dr. Novak
ANESTHESIA:	MAC
ESTIMATED BLOOD LOSS:	None.
COMPLICATIONS:	None.
CONDITION UPON DISCHARGE:	Stable.

DESCRIPTION OF THE PROCEDURE

The patient continues to suffer their usual lumbosacral pain and lower extremity radiative symptoms. The patient currently rates the pain as 7-8/10. I will perform first lumbar epidural steroid injection as previously planned. No opioids were given for performance of this procedure. Written informed consent was obtained.

The patient was placed in a prone position prepped and draped using meticulous sterile technique. Using fluoroscopic guidance, L4-L5 interspace was identified. Corresponding skin site was marked, 3cc of 1% Lidocaine was used to anesthetize the skin and subcutaneous tissues using a 25-gauge needle. A 20-gauge Tuohy needle was then advanced using loss of resistance to air technique.

Once encountered, negative aspiration for blood/CSF was performed. No paresthesia was elicited. 1.4cc of Omnipaque 240 revealed good epidural spread followed by 80mg of Kenalog with 3cc of normal saline and 1cc of 1% Lidocaine was administered epidurally. Needle was withdrawn. Sterile Band-Aid was applied.

The patient tolerated the procedure well. The patient was discharged home after PACU discharge criteria were satisfied.

Solomon Halioua, M.D.

This has been electronically signed on 11-25-2023.

3 Pages via SFTP Tue, 05 Dec 2023 07:49:05 GMT

New Horizon Surgical Center, LLC
680 Broadway, Suites 110 & 201
Paterson, NJ, 07514
Tel.: (973) 782-4202
Fax: (973) 782-4206
www.NewHorizonASC.com

Patient Name: Brown, Kevin
Address: 67-23 Eliot Ave, Middle Village, NY 11379
Account #: 71066
Date of Service: 11/25/2023
Date of Birth: 07/06/1987 (36yr)
Procedure: LUMBAR EPIDURAL STEROID INJECTION UNDER FLOURO GUIDANCE

A1. Minor Surgical Procedure Consent

Procedure: LUMBAR EPIDURAL STEROID INJECTION UNDER FLOURO GUIDANCE
Diagnosis: Radiculopathy, lumbar region

Physician: Solomon Halioua, MD

1. I authorize **Solomon Halioua, MD** and /or his designated employees, co-surgeons, and/or assistants to treat the above-named patient for the previously diagnosed condition of (give brief details)

Radiculopathy, lumbar region

and by performing the following Operation(s) or procedures, (which have been explained to me in layman's terms)

LUMBAR EPIDURAL STEROID INJECTION UNDER FLOURO GUIDANCE

2. I have been informed that there are risks associated with any surgical procedure, such as

Bleeding, infection, heart failure. I have also been made aware of the following risks and consequences of this operation. Headache, Bruising, nerve damage.

The procedure has been explained in terms understandable to me, which explanation has included:

- The purpose and extent of the procedure to be performed.
- The risks involved in the proposed procedure, including those which, even though unlikely to occur, involve serious consequences;
- The possible or likely results of the proposed procedure;
- Feasible alternative procedures and methods of treatment, including no treatment at all, if applicable;
- The possible or likely results of such alternatives;
- The results are likely if I remain untreated.

3. I understand that during the course of the operation, unforeseen conditions may be revealed that require additional different procedures and I authorize that these may also be performed.

4. I am aware that every effort has been made to establish a diagnosis. I am also aware that the practice of medicine and surgery is not an exact science and have been informed that no guarantee of the outcome of the above procedure has been made to me.

5. I have had sufficient opportunity to discuss my (the patient's) condition and treatment with the doctor and /or associates and all of the questions have been answered to my satisfaction. I believe that I have had adequate knowledge upon which to base an informed consent to the proposed treatment.

11 Pages via SFTP Wed, 20 Dec 2023 07:47:01 GMT

6. I have been informed that, in order to establish an accurate diagnosis and provide for as safe a procedure as possible, physicians need full and complete patient information. In this regard, I represent that I have fully and completely answered my physicians' questions and accurately completed any questionnaire regarding my personal and family medical history and have disclosed any allergies, pre-existing medical conditions, prior illnesses and/or diseases and all prior treatments and procedures.

7. By signing this informed consent, you agree to hold harmless **New Horizon Surgical Center, LLC (NHSC)** its owners, employees and contractors from all professional and personal liability, negligence, or other legal liability. You agree to be responsible for all legal costs and fees that may result from action(s) on your part or on the part of your representative(s) against us. You have the right to have this consent reviewed by your lawyer before accepting any services from our office and we suggest that you exercise this right.

8. I consent to the disposal by the authorities of **NHSC** of any parts or tissues which may be removed as a result of the surgical procedure and to photograph any parts or tissues which may be removed.

9. I have read this document completely before signing and acknowledge that all blanks have been completed before signing.

10. I, the undersigned, give permission to **NHSC** to photograph tissue and/or body parts for treatment and education purposes and for use in medical publications, books and journals. These photographs will relate to the procedure being performed. I understand that identifiable facial features will not be photographed. I waive all rights that I may have to any claims for payments, royalties or other remunerations in connection with any exhibition of foregoing recording(s).

11. I understand that my physician may videotape all or part of my procedure and that such videotape is NOT part of my medical record. Any videotape may be in the possession of the physician. **NHSC** assumes NO responsibility for its disposition.

12. I have been advised not to operate machinery, drive a car, make important decisions, or take any medication not prescribed by my physician for at least twenty-four (24) hours after discharge.

13. I consent to the drawing of my blood for testing for blood borne pathogens in the event that a health care provider suffers an inadvertent needle stick injury.

14. I understand that in the event of an emergency or the need for extended care, I may be transferred to a hospital. If I am transferred, I authorize **NHSC** to obtain a copy of my "Discharge Summary and/or ER records", and also as to provide **NHSC** with access to all appropriate follow-up information and medical documentation related to my medical care and outcome.

Revised 3/9/2023

Signed By: Patient -
11/25/2023 08:39

Signed By: Physician - Solomon Halioua, MD
11/25/2023 08:38

Signed By: Witness - Shakira Tavarez, RN
11/25/2023 08:39

11 Pages via SFTP Wed, 20 Dec 2023 07:47:01 GMT

New Horizon Surgical Center, LLC | 680 Broadway, Suites 110 & 201 | Paterson, NJ, 07514 | Tel.: (973) 782-4202 | Fax: (973) 782-4206 | www.NewHorizonASC.com

Name: Brown, Kevin **DOS:** 11/25/2023 **Phys:** Halioua, Solomon, MD
DOB: 07/06/1987 (36yr) **Acct #:** 71066
Proc: LUMBAR EPIDURAL STEROID INJECTION UNDER FLOURO GUIDANCE
Pre-Op Dx: Radiculopathy, lumbar region

Height 6ft (182.88 cm)	**Weight** 160lbs (72.57kg)	**BMI** 21.70
Alcohol Non Drinker	**Tobacco** Non-smoker	**Drug Use** None
Allergies	Latex Allergies: - Drug Allergies: **No Known** Non-Drug Allergies: **No Known**	

Please confirm your name and DOB

Home Medications

No home medications

11 Pages via SFTP Tue, 09 Jan 2024 13:48:45 GMT

Solomon Halioua, M.D.

FOLLOW UP EVALUATION

NAME: BROWN, KEVIN *MRN*: 07061987
DATE: 12/12/23

Chief Complaint: Patient returns today for follow up evaluation. Patient has undergone lumbar epidural steroid injection without any relief for more than 5 days of his lumbosacral pain or lower extremity radiative symptoms. He denies any loss of bladder or bowel control.

Physical Examination:

Reflexes: All brisk and intact.

Sensation: Within normal limits. Radicular pattern of pain is mapped down in the right L4 and right L5 nerve root distribution.

Power Testing: 5/5 for all extremities.

Cervical Examination: Mild tenderness overlying bilateral facets of C3 through C7.

Lumbar Examination: Moderate tenderness overlying bilateral facets of L3 through S1. SLR was positive on the right to 40 degrees. Lasègue sign was positive on the right with right sciatic notch tenderness.

Diagnostic Impression:

1. Lumbar radiculopathy (M54.16). Other intervertebral disc displacement (M51.26). Patient should undergo transforaminal discectomy (62287/22526/22527) at L4-L5 and L5-S1 with post discectomy and annuloplasty at L4-L5 and L5-S1. We will perform confirmatory discography at L4-L5 and L5-S1 with right L4 and right L5 transforaminal epidural steroid injection for postoperative pain relief.
2. Patient will continue Motrin 600mg p.o. t.i.d. with Flexeril as previously prescribed.

Solomon Halioua, M.D.
tcr 12/13/23

22 Madison Avenue, Suite 301, Paramus, NJ 07652
Phone: 201-845-6555 • Fax: 201-845-5599

2 Pages via SFTP Thu, 28 Dec 2023 14:04:18 GMT

Refua Rx Inc.
182-08 Union Turnpike Fresh Meadows, NY 11366
Phone: (718)480-8229 Fax: (718)480-3364 Prnt Dt: 12/12/2023 3:34:25PM

Rx Pres: Solomon Halioua
22 Madison AvenueSUITE 201
Paramus, NJ 07652 Phn: (201)845-6555
SOLOMON HALIOUA, MD Fax: (201)845-5599

Ord: 12/12/2023
NPI# 1093864563
LIC# 25MA07225300
DEA# bh7458309
SPI: 6147564143007

Patient: BROWN, KEVIN
DOB: 07/06/1987 Gender M
Address: 67-23 ELLIOT AVE., Rx#: 90733
Middle Village, NY 11379
Phone (646)644-4417
Qty: 15.000 (Fifteen)
Days: 5 Refills: 0 PH/TH: VD Class: 0
Potency UnitCd: Tablet
Drug: cephALEXin 500 mg tablet

Sig: take 1 tablet (500 mg) by oral route 3 times per day

Signature Date

This Prescription Will be Filled Generically Unless Prescriber Writes "DAW [1]" in the Box [ ] N Dispense As Written

Electronic Rx

12/12/2023 1:38 PM MessageType: New Prescription
Msg.Ref: 9d569a2557064bf98131e4bb0901dd From: 6147564143007
Msg.Id: 9fc949da6eda4b8f86d1ace4482b61aa To: 5828580
Prs. Order Ref : 503893544

Resp.Status: Ready To Process

cephALEXin 500 mg tablet

Rx#:90733 Rf#:0 12/12/2023 PH:VD (C)
BROWN, KEVIN 67-23 ELLIOT AVE 1ST FL Middle Village NY 1137
#15 CEPHALEXIN CAP 500MG 67877-0219-05 ASCEND LAB
Dr. HALIOUA, SOLOMON DEA # BH7458309 Refills.0
Copay $0.00 Ins.Paid $0 00 Auth#:

Refua Rx Inc.
182-08 Union Turnpike Fresh Meadows, NY 11366
Phone: (718)480-8229 Fax: (718)480-3364 Prnt Dt: 12/12/2023 3:33:05PM

Rx Pres: Solomon Halioua
22 Madison AvenueSUITE 201
Paramus, NJ 07652 Phn: (201)845-6555
SOLOMON HALIOUA, MD Fax: (201)845-5599

Ord: 12/12/2023
NPI# 1093864563
LIC# 25MA07225300
DEA# bh7458309
SPI: 6147564143007

Patient: BROWN, KEVIN
DOB: 07/06/1987 Gender M
Address: 67-23 ELLIOT AVE., Rx#: 90730
Middle Village, NY 11379
Phone (646)644-4417
Qty: 20.000 (Twenty)
Days: 10 Refills: 0 PH/TH: VD Class: 0
Potency UnitCd: Capsule
Drug: celecoxib 200 mg capsule

Electronic Rx

Sig: take 1 capsule by oral route 2 times per day 30 minutes before meals

Signature Date

This Prescription Will be Filled Generically Unless Prescriber Writes "DAW [1]" in the Box [ ] N Dispense As Written

12/12/2023 1:38 PM MessageType: New Prescription
Msg.Ref: 39477a0750db4a94947a698e2bb302 From: 6147564143007
Msg.Id: cc8a77876da444d1999e6134d1679694 To: 5828580
Prs. Order Ref : 503893540

Resp.Status: Ready To Process

celecoxib 200 mg capsule

Rx#:90730 Rf#:0 12/12/2023 PH:VD (C)
BROWN, KEVIN 67-23 ELLIOT AVE 1ST FL Middle Village NY 1137
#20 CELECOXIB CAP 200mg 50228-0158-05 SCIEGEN PH
Dr. HALIOUA, SOLOMON DEA # BH7458309 Refills:0
Copay. $0 00 Ins.Paid: $0 00 Auth#:

7 Pages via SFTP Sat, 03 Feb 2024 06:16:59 GMT

Refua Rx Inc.
182-08 Union Turnpike Fresh Meadows, NY 11366
Phone: (718)480-8229 Fax: (718)480-3364 Prnt Dt: 12/12/2023 3:32:51PM

Rx Pres: Solomon Halioua
22 Madison AvenueSUITE 201
Paramus, NJ 07652 Phn: (201)845-6555
SOLOMON HALIOUA, MD Fax: (201)845-5599

Ord: 12/12/2023
NPI# 1093864563
LIC# 25MA07225300
DEA# bh7458309
SPI: 6147564143007

Patient: BROWN, KEVIN
DOB: 07/06/1987 Gender M
Address: 67-23 ELLIOT AVE., Rx#: 90729
Middle Village, NY 11379
Phone (646)644-4417
Qty: 20.000 (Twenty)
Days: 10 Refills: 0 PH/TH: VD Class: 0
Potency UnitCd: Tablet
Drug: docusate sodium 100 mg tablet

Sig: take 1 tablet (100 mg) by oral route 2 times per day

Signature Date

This Prescription Will be Filled Generically Unless Prescriber Writes "DAW [1]" in the Box [ ] N Dispense As Written

Electronic Rx

12/12/2023 1:38 PM MessageType: New Prescription
From: 6147564143007
Msg.Id: 34a3f9a4a1d94d1ca1e366f676fc114a To: 5828580
Prs. Order Ref : 503893536

Resp.Status: Ready To Process

docusate sodium 100 mg tablet

Rx#:90729 Rf#:0 12/12/2023 PH:VD (C)
BROWN, KEVIN 67-23 ELLIOT AVE 1ST FL Middle Village NY 1137
#20 DOCUSATE SODIUM CAP 100MG 00904-6998-80 MAJOR
Dr. HALIOUA, SOLOMON DEA # BH7458309 Refills:0
Copay $0.00 Ins Paid: $0 00 Auth#:

Refua Rx Inc.
182-08 Union Turnpike Fresh Meadows, NY 11366
Phone: (718)480-8229 Fax: (718)480-3364 Prnt Dt: 12/12/2023 3:33:33PM

Rx Pres: Solomon Halioua
22 Madison AvenueSUITE 201
Paramus, NJ 07652 Phn: (201)845-6555
SOLOMON HALIOUA, MD Fax: (201)845-5599

Ord: 12/12/2023
NPI# 1093864563
LIC# 25MA07225300
DEA# bh7458309
SPI: 6147564143007

Patient: BROWN, KEVIN
DOB: 07/06/1987 Gender M
Address: 67-23 ELLIOT AVE., Rx#: 90731
Middle Village, NY 11379
Phone (646)644-4417
Qty: 20.000 (Twenty)
Days: 10 Refills: 0 PH/TH: VD Class: 0
Potency UnitCd: Tablet
Drug: ondansetron HCL 8 mg tablet

Sig: take 1 tablet (8 mg) by oral route every 6 hours for nausea

Signature Date

This Prescription Will be Filled Generically Unless Prescriber Writes "DAW [1]" in the Box [ ] N Dispense As Written

Electronic Rx

12/12/2023 1:38 PM MessageType: New Prescription
Msg.Ref: 4b12b50415d542d6981efffc8bcb392f From: 6147564143007
Msg.Id: dc31fcf881cc404da0994e0f79ba3de7 To: 5828580
Prs. Order Ref : 503893546

Resp.Status: Ready To Process

ondansetron HCL 8 mg tablet

Rx#:90731 Rf#:0 12/12/2023 PH:VD (C)
BROWN, KEVIN 67-23 ELLIOT AVE 1ST FL Middle Village NY 1137
#20 ONDANSETRON HCL TAB 8mg 57237-0076-30 CITRON PHA
Dr. HALIOUA, SOLOMON DEA # BH7458309 Refills:0
Copay $0.00 Ins.Paid $0.00 Auth#

6 Pages via SFTP Sat, 03 Feb 2024 04:25:52 GMT

Refua Rx Inc.
182-08 Union Turnpike **Fresh Meadows, NY 11366**
Phone: **(718)480-8229** Fax: **(718)480-3364** **Prnt Dt:** 12/12/2023 3:33:54PM

Rx Pres: Solomon Halioua
22 Madison AvenueSUITE 201
Paramus, NJ 07652 Phn: (201)845-6555
SOLOMON HALIOUA, MD Fax: (201)845-5599

Ord: 12/12/2023
NPI# 1093864563
LIC# 25MA07225300
DEA# bh7458309
SPI: 6147564143007

Patient: BROWN, KEVIN
DOB: 07/06/1987 **Gender** M
Address: 67-23 ELLIOT AVE., **Rx#:** 90732
Middle Village, NY 11379
Phone (646)644-4417
Qty: 30.000 (Thirty)
Days: 5 **Refills:** 0 **PH/TH:** VD **Class:** 2
Potency UnitCd: Tablet
Drug: oxyCODONE-acetaminophen 10 mg-325 mg tablet

Sig: take 1 tablet by oral route every 4 hours as needed

Signature **Date**

This Prescription Will be Filled Generically Unless Prescriber Writes "DAW [1]" in the Box [ ] N Dispense As Written

Electronic Rx

12/12/2023 1:38 PM **MessageType:** New Prescription
Msg.Ref: 8047a0e0e619484ebcb78bc2331ff80 From: 6147564143007
Msg.Id: f12953f6f25a46358a2b2f4750eaab6e To: 5828580
Prs. Order Ref : 503893575

Resp.Status: Authentic EPCS Received

oxyCODONE-acetaminophen 10 mg-325 mg tablet

Rx#:90732N **RI#:0** **12/12/2023** **PH:VD (C)**
BROWN, KEVIN **67-23 ELLIOT AVE 1ST FL Middle Village NY 1137**
#30 OXYCODONE/APAP TAB 10-325MG 00406-0523-01 MALLINCKRO
Dr. HALIOUA, SOLOMON DEA # BH7458309 Refills:0
Copay $0.00 Ins Paid $0.00 Auth#.

New Horizon Surgical Center, L.L.C.

680 Broadway, Suite 201

Paterson, NJ 07514

Tel: (973)782-4202 Fax: (973)782-4206

Patient Name: Brown, Kevin
Medical Record No: 71066
DOB: 07/06/1987
Surgeon: Solomon Halioua, M.D.
Anesthesiologist: Dr. Ashraf
ANESTHESIA: Intravenous sedation/ MAC

Date of Surgery: December 13, 2023

PRE-OPERATIVE DIAGNOSIS: 1. Lumbar radiculopathy.
2. Other intervertebral disc displacement.

POST-OPERATIVE DIAGNOSIS: Same:

PROCEDURE PERFORMED: **OPERATION:**

1) Endoscopically assisted Right Transforaminal discectomy at the L4-5 and L5-S1. 2-levels

2) Annuloplasty using bipolar probe at the L4-5 and L5-S1. 2-levels

3) Lumbar Discography L4-5 and L5-S1. 2-levels

4) Right L4 and L5 transforaminal Epidural injection. 2-levels

EBL: 10cc

Complications: None.

Condition upon Discharge: Stable.

SPECIMENS: Disc fragments of the L4-5 and L5-S1. 2-levels

5 Pages via SFTP Thu, 21 Dec 2023 07:49:59 GMT

Patient Name: Brown, Kevin

Medical Record No: 71066

Page 2

DETAILS OF PROCEDURE: The patient was admitted by the nursing staff and the appropriate paperwork was completed. I have discussed with the patient the risk/benefit ratio of the above-mentioned procedure, including discitis, paralysis, nerve damage, worsening of disc condition, epidural abscess, etc. The patient agrees to undergo these procedures. The patient was given a prescription for Duracef 500mg. tablets, 1 tablet p.o. BID, dispense 10 tablets without refill; Percocet 10 /325 mg 1-2 tab PO q 4 hrs p.r.n pain #40 tabs. Celebrex 200mg BID #20tabs; Docusate 100mg tabs 1 tabs PO BID #20 The patient is to follow up in my office in one week for wound check. He was informed that if any fever, chills, or signs of systemic infection he will call my office. The patient was given 2000mg of Iv Ancef as prophylactic antibiotics. We will refer to intra-discal contrast material in this report. It consists of Omnipaque 240 /Ancef 10mg/mL

The patient was interviewed by the anesthesiologist, who explained the risks and benefits associated with the anesthetic component of the surgery. The patient had intravenous access obtained and was taken to the Operating Room where the EKG, blood pressure and pulse oximetry monitors were applied. The patient was turned prone onto the Kambin frame with all the pressure points in the head, neck, upper and lower extremities being properly protected. The patient was given intravenous sedation and once appropriately sedated the patient's back was prepped and draped in a sterile fashion.

Using a C-arm in AP and lateral views, the **L4-5** interspace was identified. The patient's **L4-5**-disc space was accessed on the **right** paramedian approach. 10cc 1% Lidocaine was used to anesthetize skin and subcutaneous tissue using a 25G needle. The procedure commenced with the insertion of an 18-gauge 8-inch needle under fluoroscopic guidance into the intervertebral space. The needle was advanced into the center of the disc and the posterior 1/3 of the annulus. Good position being confirmed on AP and lateral views. The stylet was removed from the needle.

At **L4-5**, injection of radiographic contrast material took place, which consisted of 1.4 cc of radiographic contrast material. The disc did pressurize well during injection. Morphology revealed annular tear.

The guide wire was inserted through the needle and the needle was removed from the patient's lower back. A small stab incision was made over the stylet using a number 15 blade. Under fluoroscopic sheath and working cannula were advanced through the posterior lateral margin into the disc space at the **L4-5** level. Having secured the cannula in place, manual discectomy of the intra-annular disc material is done using a small disc forceps/ pituitaries were inserted through the cannula and under fluoroscopic guidance.

5 Pages via SFTP Thu, 21 Dec 2023 07:49:59 GMT

Patient Name: Brown, Kevin

Medical Record No: 71066

Page 3

Manual decompression was carried out removing approximately 1.5 grams of intervertebral disc material.

The steerable Trigger-Flex (Elliquence) probe was inserted through the cannula and nucleus ablation was performed with the Surgi-Max (Elliquence) generator set at Bipolar-Turbo mode. Six strokes of ablation were carried out for the nucleus in six different directions. Then extraction of any nuclear material is done using disc irrigation.

An endoscope was re inserted through the cannula and visualization occurred within the disc space identifying that adequate hemostasis took place.

Modulation of dorsal annulus was then carried out by placing the Trigger-Flex probe under the pathological annulus and using the Bipolar-Hemo mode of the Surgi-Max generator. Three strokes of modulation were performed in at 10 o'clock 12o'clock and 2 o'clock on the annulus covering the width of the annulus. Irrigation and aspiration was preformed with 10cc Normal saline.

The cannula was removed. A 22g 5 inch spinal needle was advanced into under the **right L4** pedicle epidural space, 1cc Omnipaque confirmed epidural placement/epidurogram 60mg Kenalog was administered at this level for post-op analgesia.

Using a C-arm in AP and lateral views, the **L5-s1** interspace was identified. The patient's **L5-S1** disc space was accessed on the **right** paramedian approach. 6 cc 1% Lidocaine was used to anesthetize skin and subcutaneous tissue using a 25G needle. The procedure was commenced with the insertion of an 18-gauge 8-inch needle under fluoroscopic guidance into the intervertebral space. The needle was advanced into the center of the disc and the posterior 1/3 of the annulus. Good position being confirmed on AP and lateral views. The stylet was removed from the needle.

At **L5-S1,** injection of radiographic contrast material took place, which consisted of 1.1 cc of radiographic contrast material. The disc did pressurize well during injection. Morphology of the disc revealed annular tear

The guide wire was inserted through the needle and the needle was removed from the patient's lower back. A small stab incision was made over the stylet using a number 15 blade. Under fluoroscopic sheath and working cannula were advanced through the posterior lateral margin into the disc space at the **L5-S1** level. Having secured the cannula in place, manual discectomy of the intra-annular disc material is done using a small disc forceps/ pituitaries were inserted through the cannula and under fluoroscopic guidance.

5 Pages via SFTP Thu, 21 Dec 2023 07:49:59 GMT

Patient Name: Brown, Kevin

Medical Record No: 71066

Page 4

Manual decompression was carried out removing approximately 1.5 grams of intervertebral disc material.

The steerable Trigger-Flex (Elliquence) probe was inserted through the cannula and nucleus ablation was performed with the Surgi-Max (Elliquence) generator set at Bipolar-Turbo mode. Six strokes of ablation were carried out for the nucleus in six different directions. Then extraction of any nuclear material is done using disc irrigation.

An endoscope was re inserted through the cannula and visualization occurred within the disc space identifying that adequate hemostasis took place.

Modulation of dorsal annulus was then carried out by placing the Trigger-Flex probe under the pathological annulus and using the Bipolar-Hemo mode of the Surgi-Max generator. Three strokes of modulation were performed in at 10 o'clock 12o'clock and 2 o'clock on the annulus covering the width of the annulus. Irrigation and aspiration was preformed with 10cc Normal saline.

The cannula was removed. A 22g 5-inch spinal needle was advanced under the right L5 pedicle into epidural space, 1cc Omnipaque confirmed epidural placement/epidurogram 60mg Kenalog was administered at this level as well for post-op analgesia. Needle and cannula were both withdrawn.

3-0 Vicryl was used to close the incisions subcuticularally. Followed by, Dermabond to close the skin with a Tagaderm.

Sterile Band-Aids were applied. Patient tolerated procedure well. Patient was observed in PACU and subsequently discharged home after discharge criteria was satisfied. The patient was noted in stable condition and was pre-admission neurological condition (I examined the patient personally). The patient's pain was 1-2/10.

The patient was given a full set of postoperative instructions and the number to contact in case of an emergency.



Solomon Halioua, M.D.

5 Pages via SFTP Thu, 21 Dec 2023 07:49:59 GMT

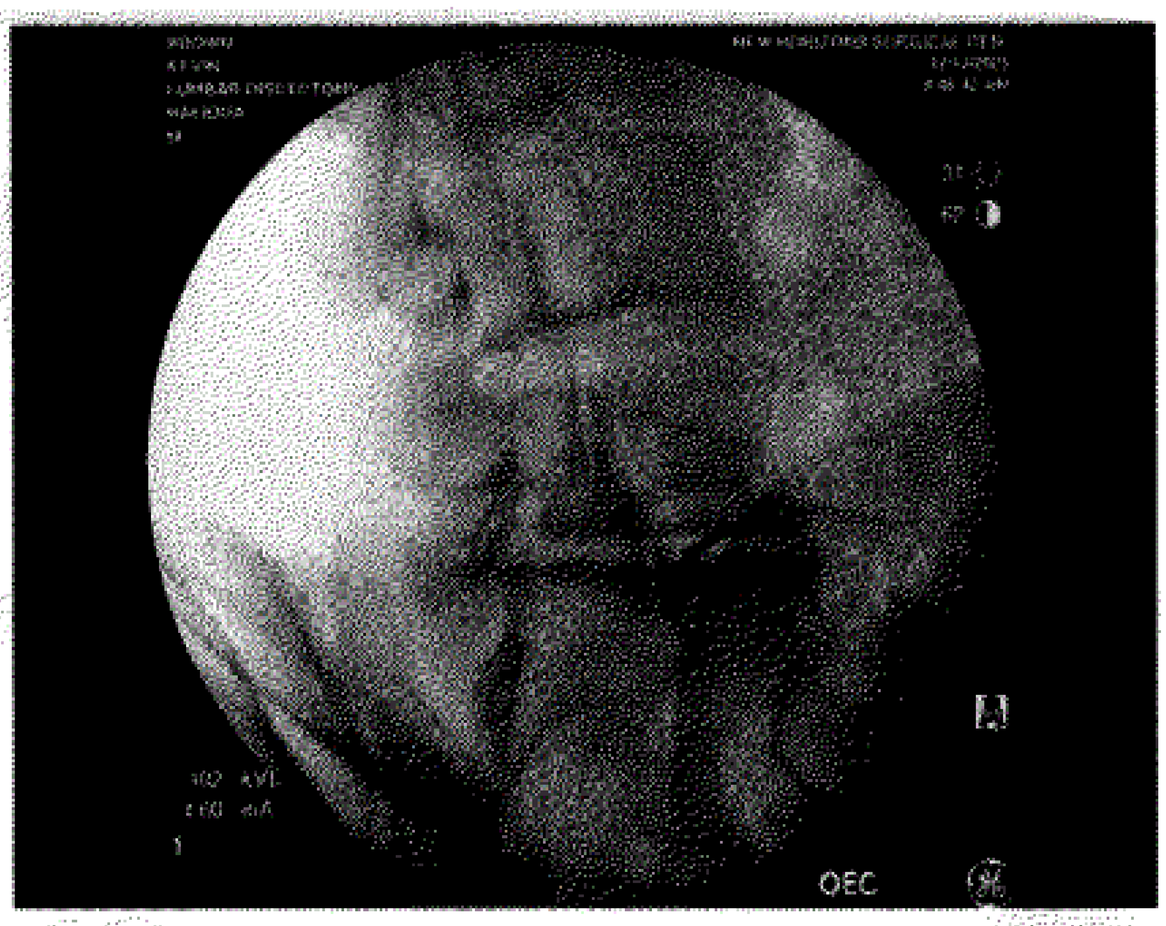

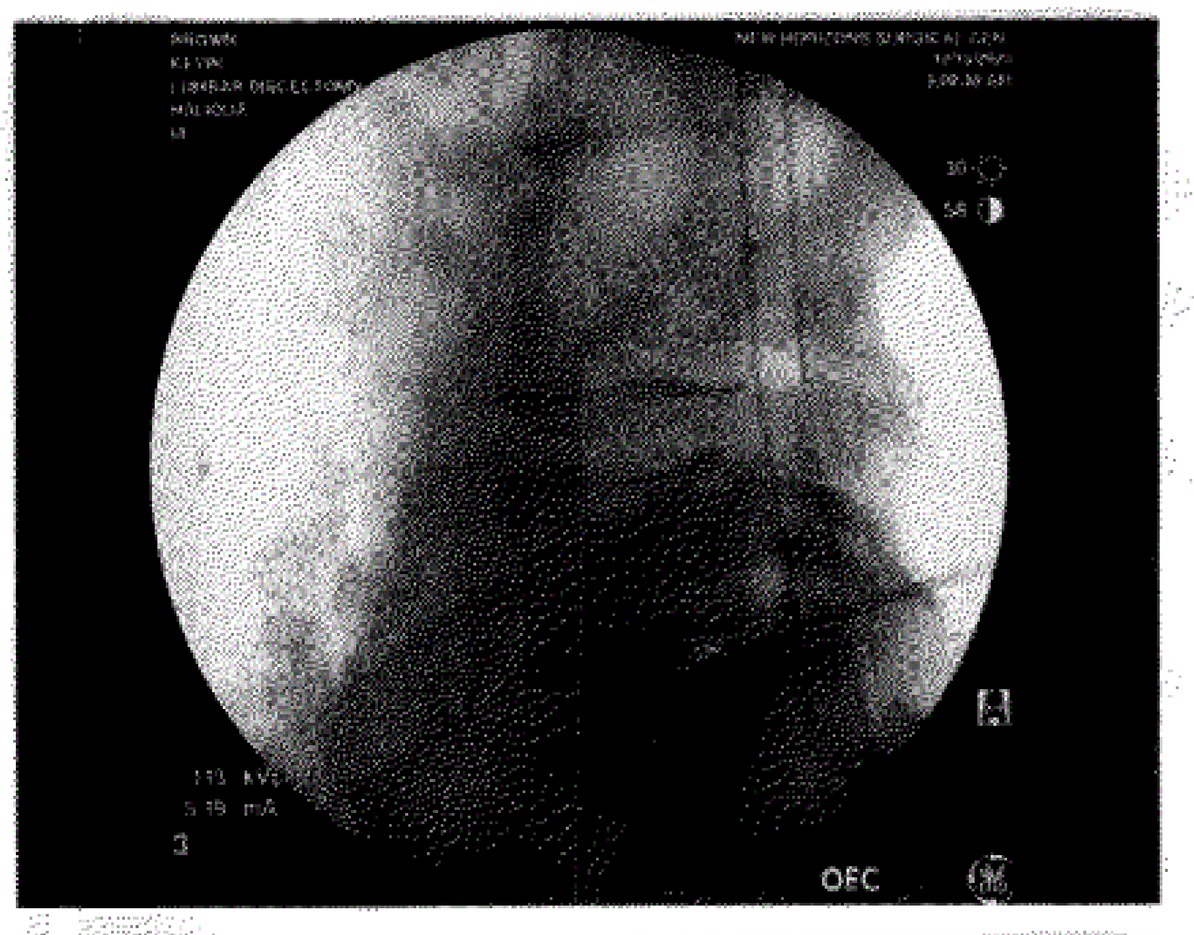

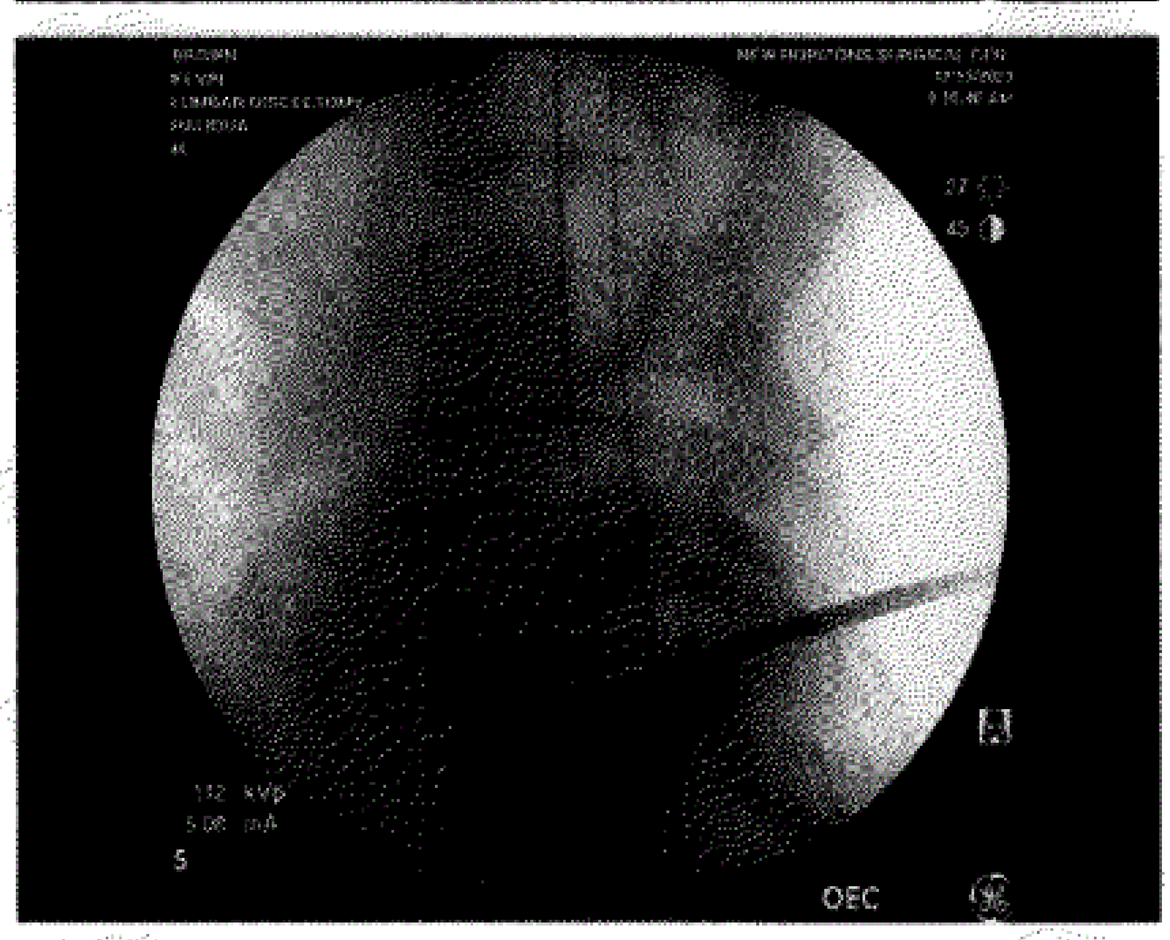

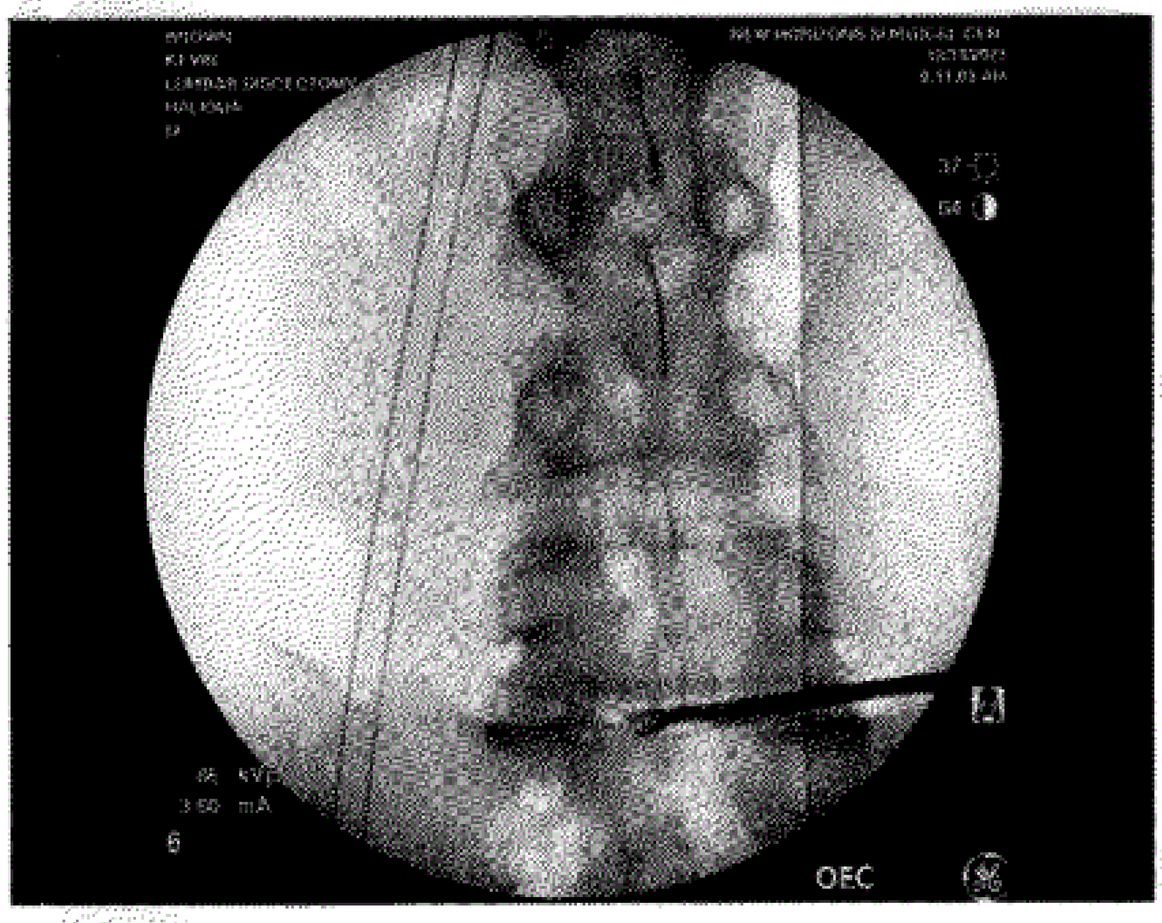

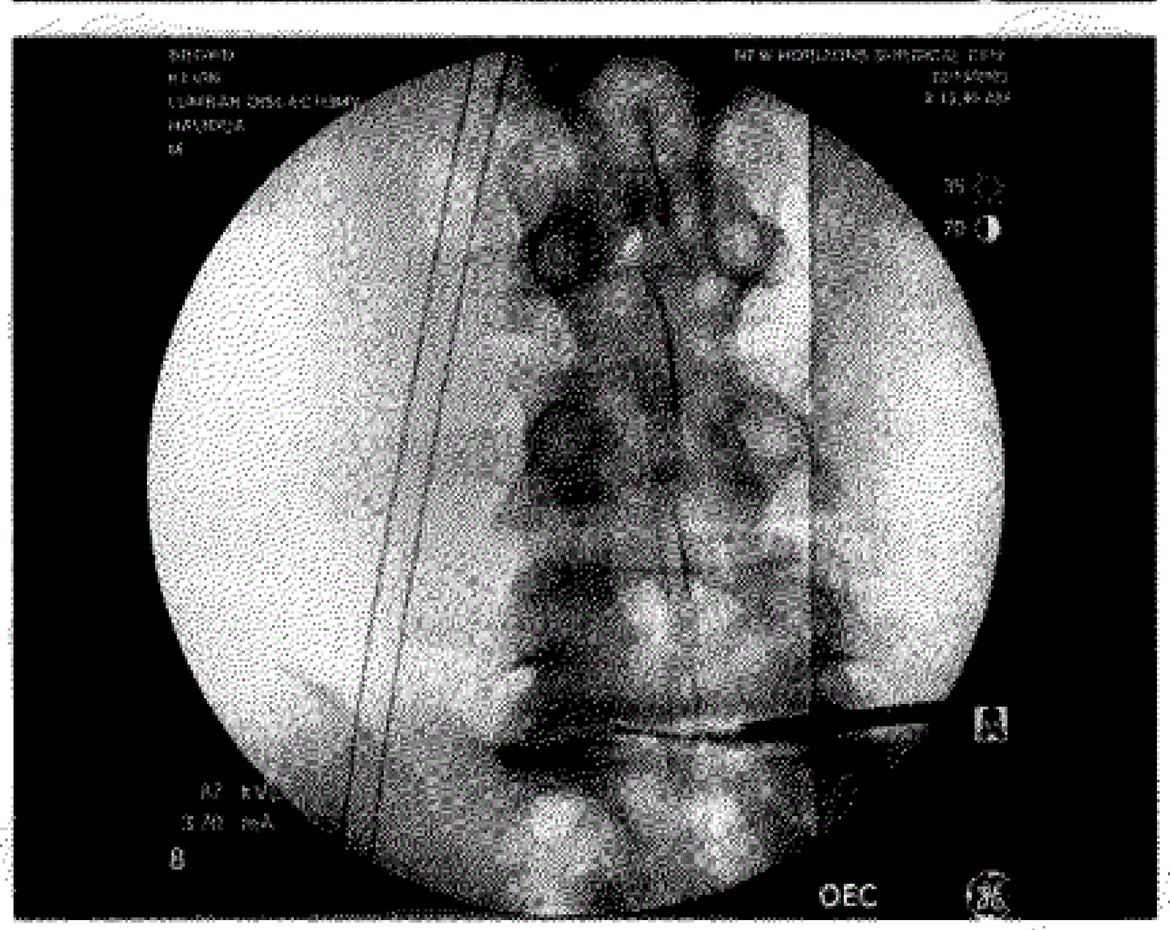

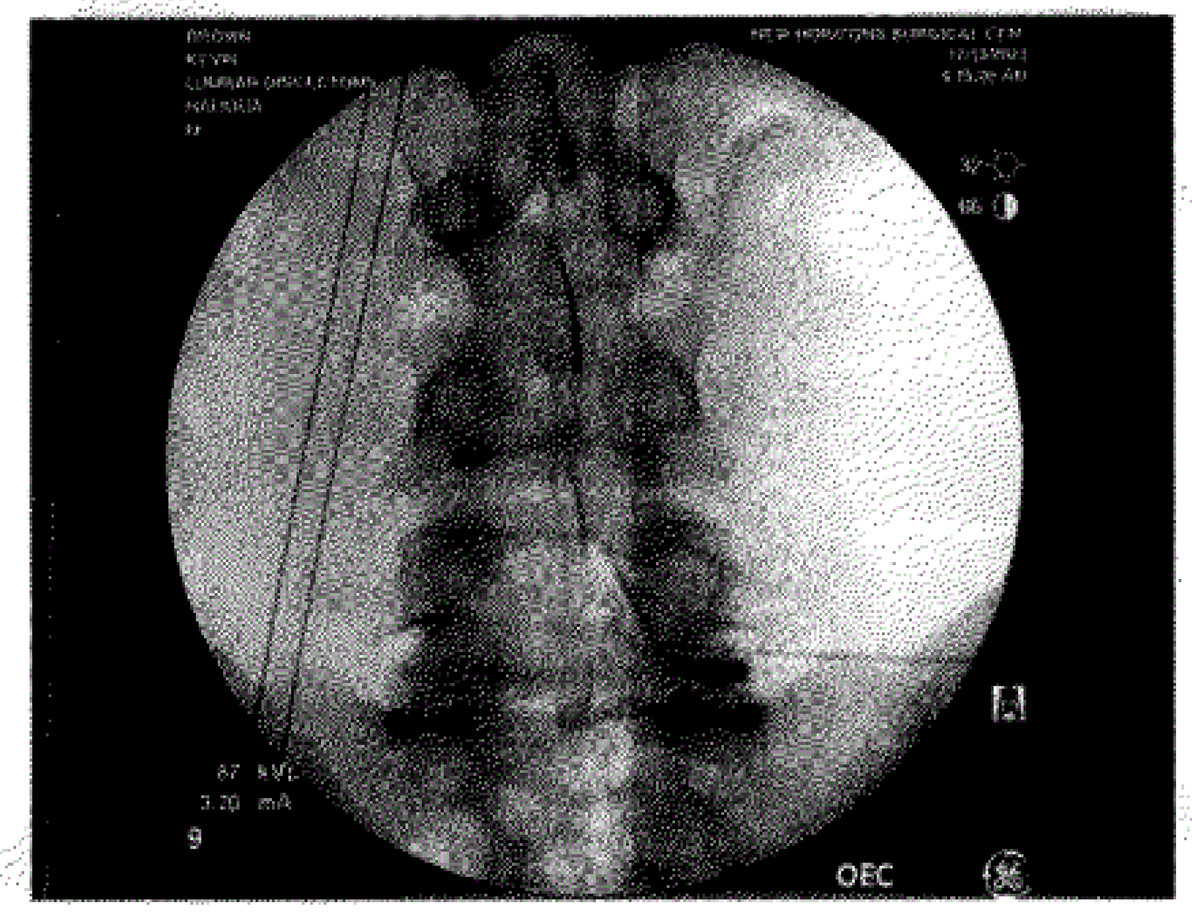

Brown, Kevin

DOB:07/06/1987 (36) **DOS:**12/13/2023
Sex: Male **MRN:**71066
Physician: Halioua, Solomon

22 Pages via SFTP Fri, 05 Jan 2024 19:47:15 GMT

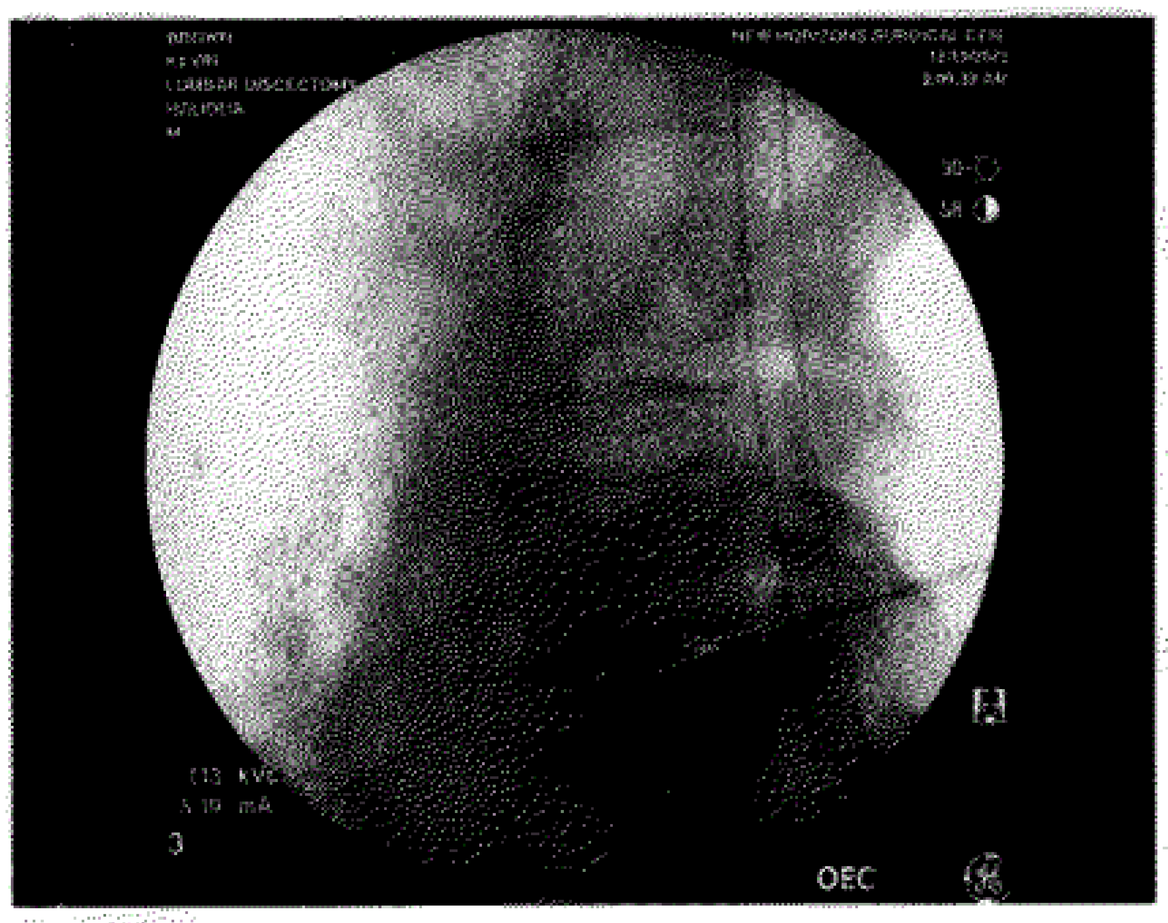

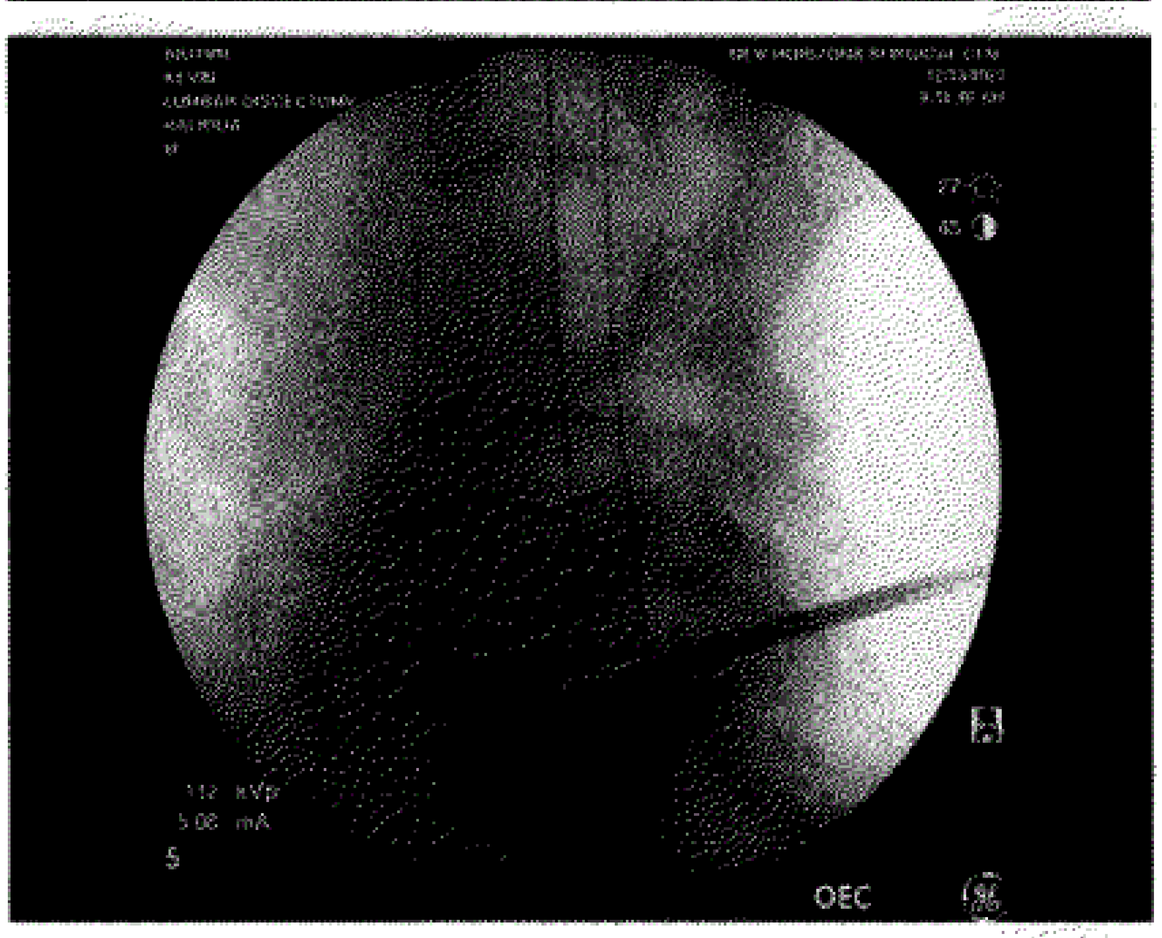

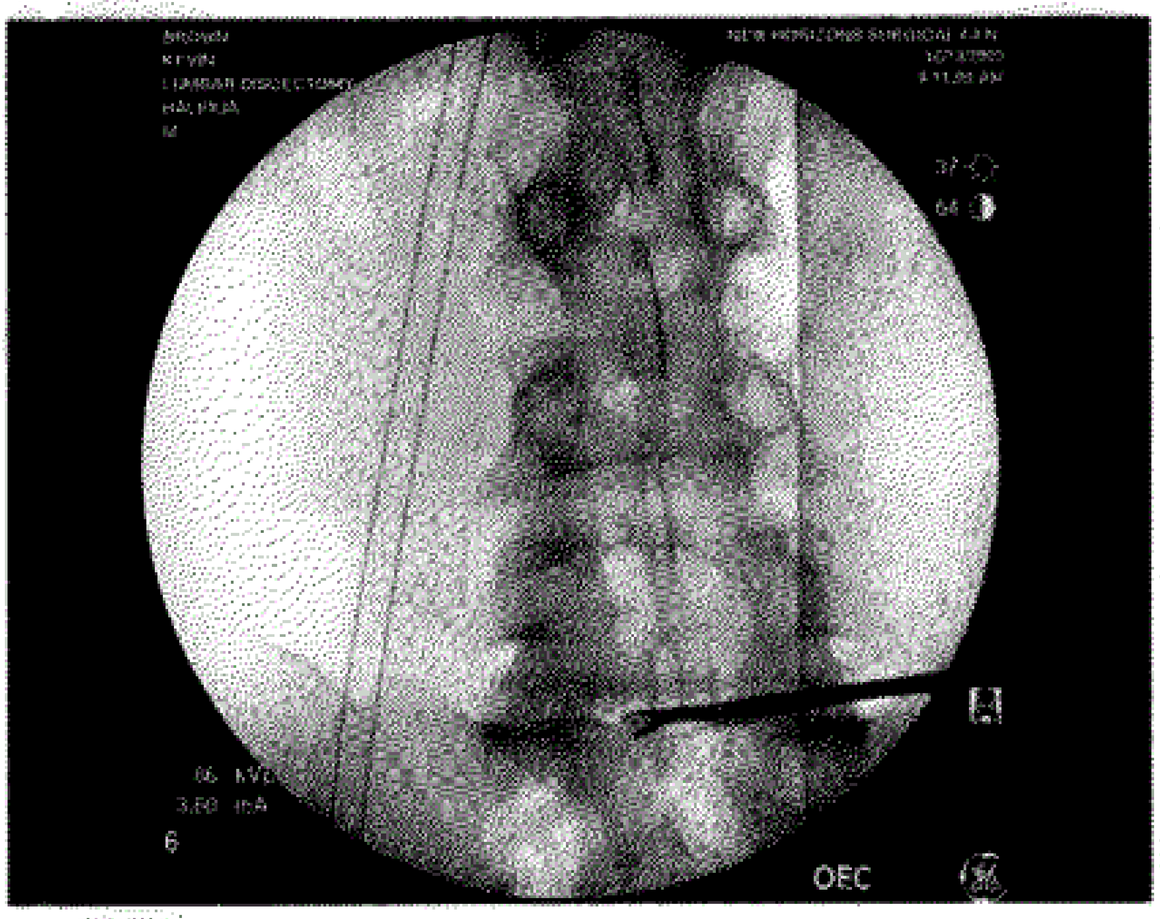

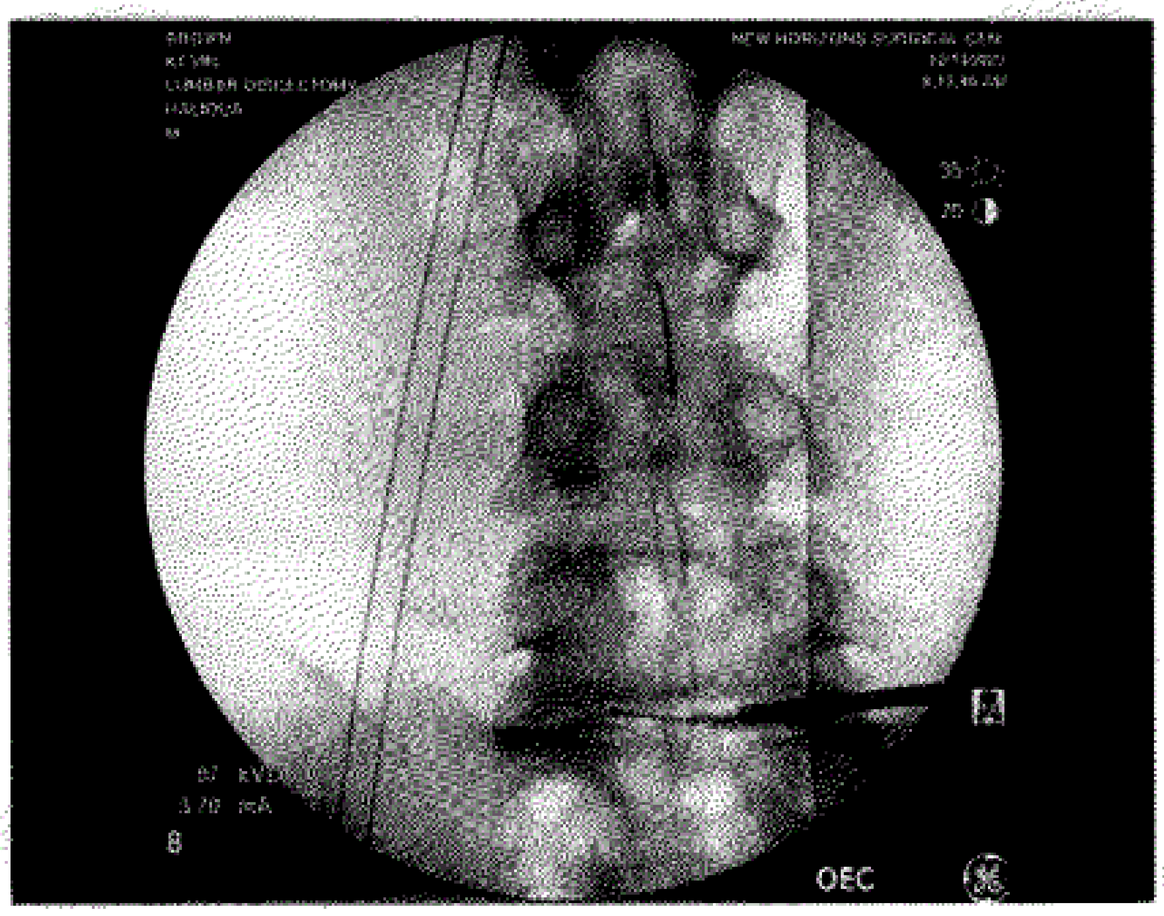

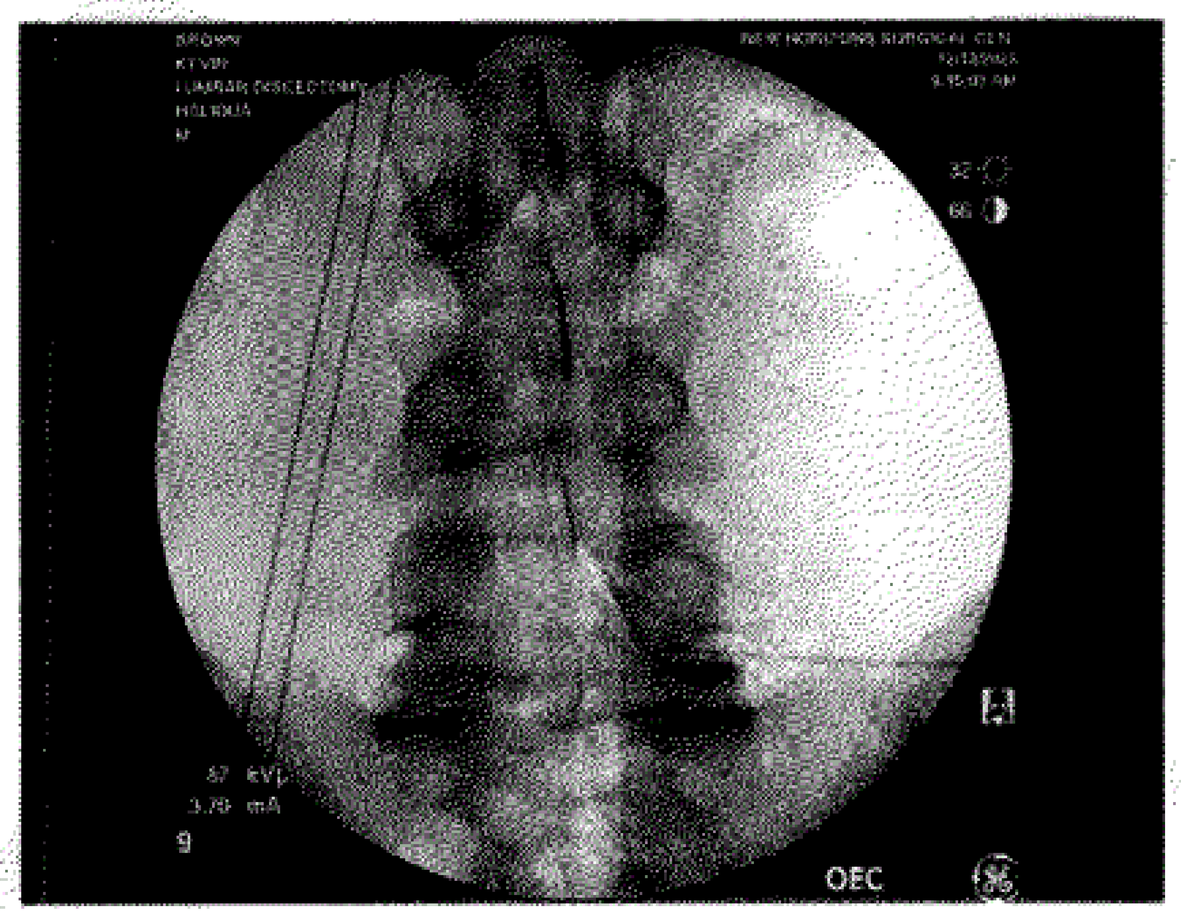

Brown, Kevin

DOB:07/06/1987 (36) **DOS:**12/13/2023
Sex: Male **MRN:**71066
Physician: Halioua, Solomon

22 Pages via SFTP Fri, 05 Jan 2024 19:47:15 GMT

New Horizon Surgical Center
Surgeon: Halioua, Dr.

12/13/2023


1


2


3


4


5


6


7


8

22 Pages via SFTP Fri, 05 Jan 2024 19:47:15 GMT

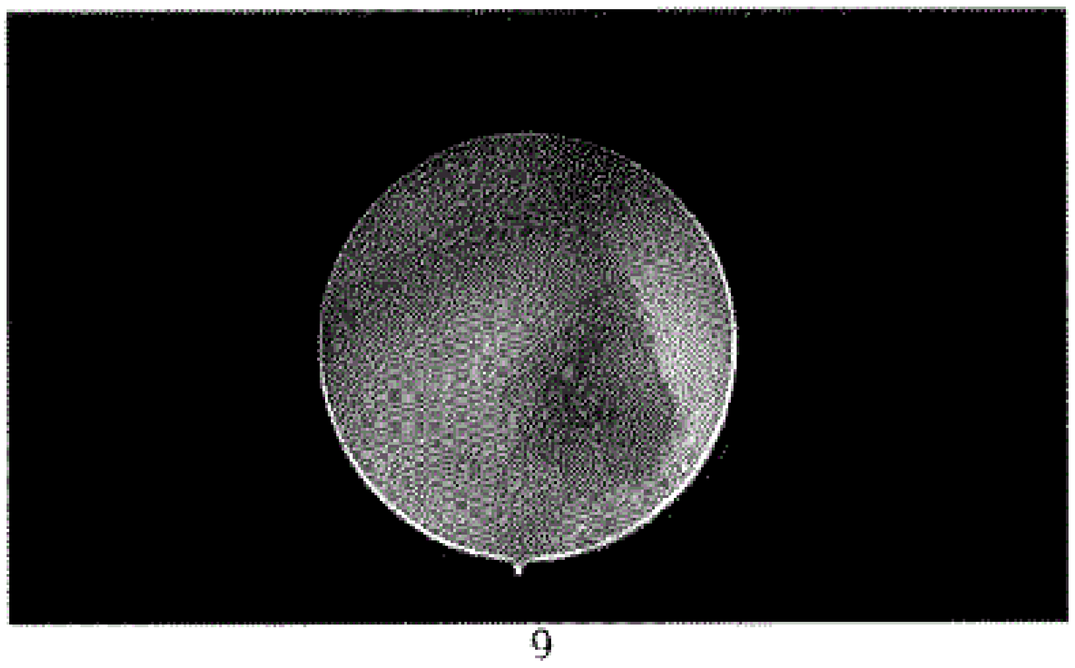

9



10

22 Pages via SFTP Fri, 05 Jan 2024 19:47:15 GMT

New Horizon Surgical Center, LLC
680 Broadway, Suites 110 & 201
Paterson, NJ, 07514
Tel.: (973) 782-4202
Fax: (973) 782-4206
www.NewHorizonASC.com

Patient Name: Brown, Kevin

Account #: 71066

Date of Birth: 07/06/1987 (36yr)

Address: 67-23 Eliot Ave, Middle Village, NY 11379

Date of Service: 12/13/2023

Procedure: 1) Endoscopically assisted Right Transforaminal discectomy at the L4-5 and L5-S1 2- levels.
2) Annuloplasty using bipolar probe at the L4-5 and L5-S1 2- levels.
3) Lumbar Discography L4-5 and L5-S1 2- levels.
4)Right L4 and L5 transforaminal Epidural injection 2 levels

Halioua DISC A. Surgical Operation or Surgical Procedure Consent

Procedure: 1) Endoscopically assisted Right Transforaminal discectomy at the L4-5 and L5-S1 2- levels.

2) Annuloplasty using bipolar probe at the L4-5 and L5-S1 2- levels.

3) Lumbar Discography L4-5 and L5-S1 2- levels.

4)Right L4 and L5 transforaminal Epidural injection 2 levels

Diagnosis: Radiculopathy, lumbar region, Other intervertebral disc displacement, lumbar region

Physician: Solomon Halioua, MD

1. I authorize **Solomon Halioua, MD** and /or his designated employees, co-surgeons, and/or assistants to treat the above-named patient for the previously diagnosed condition of (give brief details)

Radiculopathy, lumbar region, Other intervertebral disc displacement, lumbar region

and by performing the following Operation(s) or procedures, (which have been explained to me in layman's terms)

1) Endoscopically assisted Right Transforaminal discectomy at the L4-5 and L5-S1 2- levels.
2) Annuloplasty using bipolar probe at the L4-5 and L5-S1 2- levels.
3) Lumbar Discography L4-5 and L5-S1 2- levels.
4)Right L4 and L5 transforaminal Epidural injection 2 levels

2. I have been informed that there are risks associated with any surgical procedure, such as:

Bleeding, infection, heart failure. I have also been made aware of the following risks and consequences of this operation. Headache, Bruising, nerve damage, Discitis, rarely paralysis, and worsening of disc condition

The procedure has been explained in terms understandable to me, which explanation has included:

- The purpose and extent of the procedure to be performed.
- The risks involved in the proposed procedure, including those which, even though unlikely to occur, involve serious consequences;
- The possible or likely results of the proposed procedure;

22 Pages via SFTP Fri, 05 Jan 2024 19:47:15 GMT

- Feasible alternative procedures and methods of treatment, including no treatment at all, if applicable;
- The possible or likely results of such alternatives;
- The results are likely if I remain untreated.

3. I understand that during the course of the operation, unforeseen conditions may be revealed that require additional different procedures and I authorize that these may also be performed.

4. I am aware that every effort has been made to establish a diagnosis. I am also aware that the practice of medicine and surgery is not an exact science and have been informed that no guarantee of the outcome of the above procedure has been made to me.

5. I have had sufficient opportunity to discuss my (the patient's) condition and treatment with the doctor and /or associates and all of the questions have been answered to my satisfaction. I believe that I have had adequate knowledge upon which to base an informed consent to the proposed treatment.

6. I have been informed that, in order to establish an accurate diagnosis and provide for as safe a procedure as possible, physicians need full and complete patient information. In this regard, I represent that I have fully and completely answered my physicians' questions and accurately completed any questionnaire regarding my personal and family medical history and have disclosed any allergies, pre-existing medical conditions, prior illnesses and/or diseases and all prior treatments and procedures.

7. By signing this informed consent, you agree to hold harmless **New Horizon Surgical Center, LLC (NHSC)** its owners, employees and contractors from all professional and personal liability, negligence, or other legal liability. You agree to be responsible for all legal costs and fees that may result from action(s) on your part or on the part of your representative(s) against us. You have the right to have this consent reviewed by your lawyer before accepting any services from our office and we suggest that you exercise this right.

8. I consent to the disposal by the authorities of **NHSC** of any parts or tissues which may be removed as a result of the surgical procedure and to photograph any parts or tissues which may be removed.

9. I have read this document completely before signing and acknowledge that all blanks have been completed before signing.

10. I, the undersigned, give permission to **NHSC** to photograph tissue and/or body parts for treatment and education purposes and for use in medical publications, books and journals. These photographs will relate to the procedure being performed. I understand that identifiable facial features will not be photographed. I waive all rights that I may have to any claims for payments, royalties or other remunerations in connection with any exhibition of foregoing recording(s).

11. I understand that my physician may videotape all or part of my procedure and that such videotape is NOT part of my medical record. Any videotape may be in the possession of the physician. **NHSC** assumes NO responsibility for its disposition.

12. I have been advised not to operate machinery, drive a car, make important decisions, or take any medication not prescribed by my physician for at least twenty-four (24) hours after discharge.

13. I consent to the drawing of my blood for testing for blood borne pathogens in the event that a health care provider suffers an inadvertent needle stick injury.

14. I understand that in the event of an emergency or the need for extended care, I may be transferred to a hospital. If I am transferred, I authorize **NHSC** to obtain a copy of my "Discharge Summary and/or ER records", and also as to provide **NHSC** with access to all appropriate follow-up information and medical documentation related to my medical care and outcome.

15. By signing below I certify that I am either fully vaccinated or have tested negative for Covid-19 within the past 144 hours. Despite all of **NHSC's** precautionary measures to minimize a Covid 19 infection, I understand and acknowledge

22 Pages via SFTP Fri, 05 Jan 2024 19:47:15 GMT

contracting Covid 19 remains a possibility and will not hold **NHSC** liable for such.

Signed By: Patient -
12/13/2023 07:44

Signed By: Physician - Solomon Halioua, MD
12/13/2023 07:40

Signed By: Witness - Angela Natale
12/13/2023 07:44

22 Pages via SFTP Fri, 05 Jan 2024 19:47:15 GMT

New Horizon Surgical Center LLC

Sterile Disposable/Implant Invoice

Brown, Kevin **DOB:**07/06/1987 (36) **DOS:**12/13/2023 **Sex:**Male **MRN:**71066 **Physician:**Halioua, Solomon	Vendor: Procedure: Lumbar Percutaneous Discectomy

PRODUCT	QUANTITY	PRICE
elliquence Less is More — DISC-FX Cat. No. DFX STERILE EO elliquence, LLC. 2455 Grand Avenue Baldwin, New York 11510 U.S.A. (516) 277-9000 · Fax: (516) 277-9001 www.elliquence.com LOT Number 230706051LR 2026-08-01 LB 0425 D	1	1,495
dexsbrd	1	18

O.R. NURSE PRINT NAME: Samantha Buse SIGN: S.Buse DATE: 12/13/23

VENDOR REP. PRINT NAME: _____ SIGN: _____ DATE: _____

DISCLOSURE: By signing this document Both parties attest that any: IMPLANTS,GRAFTS,BIOLOGICAL and SINGLE USE STERILE ITEMS REFERENCED ABOVE, WERE IN FACT STOCKED AND OBTAINED FROM THE INVENTORY OF NHSC AND HAS BEEN PAID FOR BY NHSC! This document is to ensure and certify all special order supplies used in this case are accounted for, along with its associated expense.. All pricing documented here is verified and attested to by the VENDOR COMPANY signing this form.

22 Pages via SFTP Fri, 05 Jan 2024 19:47:15 GMT

NEW HORIZON SURGICAL CENTER

Date of service: 12/12/23

Patient Name (Last, First): Brown, Kevin Date of Birth: 7/6/87

Phone # 646-644-4417

FUNDED _____ SELF PAY _____ CHARITY _____

Check Amount: _____ Check Amount: _____

NO-FAULT/PIP

State Policy Written: (NY) / NJ / OTHER _____ Case Open: (YES) NO

Insurance Company Progressive

Claim # 23033837 U DOA: 10/13/23

Address PO Box 2020

Clinton, IA 52733

Adjuster Name _____ Ph: _____ Ext: _____

Attorney Name _____ Ph: _____

Address _____

NOTES: _____

WORKERS COMPENSATION

State Policy Written: NY / NJ / OTHER _____ Case Open: YES NO

Insurance Company _____

WCB# _____ Claim# _____ DOA: _____

Address _____

Adjuster Name _____ Ph: _____ Ext: _____

Attorney Name _____ Ph: _____

Address _____

NOTES: _____

LIENS/LOPS

DOA: _____ Do we have signed LOP YES NO (attach if YES)

Attorney's Name: _____ Is this case a slip and fall or MVA related? Circle one

Attorney's Address: _____ If MVA related request global denial from attorney

Phone #: _____

Do they want us to bill patient's private health insurance: YES NO

If YES... (Include copy of front and back of card and health insurance verification sheet)

Insurance Company _____

Policy # _____ Member ID _____

NOTES: _____

DATE VERIFIED 12/7/23 NAME OF STAFF MEMBER Jaemy Arroyo

New Horizon Surgical Center, LLC | 680 Broadway, Suites 110 & 201 | Paterson, NJ, 07514 | Tel.: (973) 782-4202 | Fax: (973) 782-4206 | www.NewHorizonASC.com

Anesthesia Billing

Patient

Name:	Brown, Kevin	**Gender:**	Male	**MRN:**	71066
Address 1:	67-23 Eliot Ave	**Phone:**	(646) 644-4417	**DOB:**	07/06/1987 (36yr)
Address 2:		**Secondary:**			
City, State, Zip:	Middle Village, NY, 11379				

Billing

Anesthesia Type:	MAC with sedation	**ASA:**	2
Referring Physician:	Halioua, Solomon	**Surgeon:**	Halioua, Solomon
Case Status:	Billed	**Anesthesia Staff:**	Buse, Samantha; Ashraf, Waseem
Date of Service:	12/13/2023		
Anesthesia Start Time:			
Anesthesia End Time:			

Scheduled Procedure: LUMBAR PERCUTANEOUS DISCECTOMY WITH POST DISCECTOMY & ANNULOPLASTY CONFIRMATORY DISCOGRAPHY TRANSFORAMINAL EPIDURAL STEROID INJECTION FOR POST OP PAIN RELIEF; IDET SINGLE LEVEL; IDET 1 OR MORE LEVELS

Performed Procedure: 1) Endoscopically assisted Right Transforaminal discectomy at the L4-5 and L5-S1 2- levels.
2) Annuloplasty using bipolar probe at the L4-5 and L5-S1 2- levels.
3) Lumbar Discography L4-5 and L5-S1 2- levels.
4)Right L4 and L5 transforaminal Epidural injection 2 levels

Pre-Op Diagnosis: Radiculopathy, lumbar region, Other intervertebral disc displacement, lumbar region

Post-Op Diagnosis: Radiculopathy, lumbar region, Other intervertebral disc displacement, lumbar region

Primary Guarantor:	Brown, Kevin	**Relationship to Patient:**	Self
Address 1:	67-23 Eliot Ave	**Guarantor DOB:**	07/06/1987
Address 2:		**Phone:**	(646) 644-4417
City, State, Zip:	Middle Village, NY, 11379		
Primary Insurance:	PROGRESSIVE- NYP	**Insured Name:**	Brown, Kevin
Phone:		**Claim Office Address:**	725 BROADWAY
Insured ID:	239338374	**City, State, Zip:**	ALBANY, NY, 12207
Group Name:	DOA 10/13/23	**Group Number:**	
Pre-Certification #:		**Prior Authorization #:**	
Workers Comp File #:		**Accident Date:**	10/12/2023
Accident State:	NY	**Accident Type:**	Auto Accident

OR Staff

Staff	Role	In Time	Out Time
Samantha Buse	Nurse- Pre-Op/PACU	12/13/2023 at 08:59	12/13/2023 at 09:30
Mark Herrera	X-Ray Tech	12/13/2023 at 08:59	12/13/2023 at 09:30
Solomon Halioua	Physician	12/13/2023 at 08:59	12/13/2023 at 09:30
Helen Lopez	Surgical Technologist	12/13/2023 at 08:59	12/13/2023 at 09:30
Waseem Ashraf	Anesthesiologist	12/13/2023 at 08:59	12/13/2023 at 09:30

18 Pages via SFTP Thu, 07 Mar 2024 04:36:21 GMT

New Horizon Surgical Center, LLC | 680 Broadway, Suites 110 & 201 | Paterson, NJ, 07514 | Tel.: (973) 782-4202 | Fax: (973) 782-4206 | www.NewHorizonASC.com

Name: Brown, Kevin **DOS:** 12/13/2023 **Phys:** Halioua, Solomon, MD

DOB: 07/06/1987 (36yr) **Acct #:** 71066

Proc: Endoscopically assisted Right Transforaminal discectomy at the L4-5 and L5-S1
Annuloplasty using bipolar probe at the L4-5 and L5-S1
Lumbar Discography L4-5 and L5-S1 and Right L4 and L5 transforaminal Epidural injection 2 levels

Pre-Op Dx: Radiculopathy, lumbar region, Other intervertebral disc displacement, lumbar region

Height 6ft (182.88 cm) **Weight** 160lbs (72.57kg) **BMI** 21.70

Alcohol Non Drinker **Tobacco** Non-smoker **Drug Use** None

Allergies

Latex Allergies: -

Drug Allergies: **No Known**

Non-Drug Allergies: **No Known**

Operations and Surgeries

Pain Management

Please confirm your name and DOB

Home Medications

No home medications

Rx COLD COMPRESSION PRESCRIPTION and CERTIFICATE OF MEDICAL NECESSITY

Patient Name: Kevin Brown

Patient Address: 67-23 Elliot Ave.

Patient City/State/Zip: Middle Village N.Y. 11379

Telephone Number: 646-644-4417 Date of Injury: 10/13/2023

COLD COMPRESSION EQUIPMENT ORDER

☐ Device for Cold Compression Therapy – Appropriate Pneumatic Wrap(s)

WRAP: ☐ Foot/Ankle ☐ Knee ☐ Calf/Leg ☐ Hand/Wrist ☐ Elbow ☐ Arm
☐ Shoulder ☑ Back ☐ Neck ☐ Other: _____

Primary Diagnosis Code Secondary Diagnosis Code

I am writing on behalf of my patient that you approve coverage for the Cold Compression therapy system. It is a part of my plan of care for my patient's rehabilitative path to recovery. It is my opinion that this device is medically necessary and reasonable in reference to current medical practice act standards for treatment of my patient's condition. I am prescribing this medical device as it will prevent unnecessary suffering and delays in recovery time. Please call my office with questions regarding this therapy system.

The Cold Compression is a vaso-pneumatic cold compression therapy system that provides patients with "therapy" and intermittent compression. Cold Compression therapy is a proven, effective technique in rehabilitative care to effectively reduce recovery time as well as reducing edema, swelling, and pain. The Cold Compression therapy device is medically indicated for my patient's diagnosis and conditions.

For these reasons, the pneumatic compressor and compression wrap was prescribed for this patient to maximize the outcome of the patient's rehabilitation and reduce complications. I have successfully used this device in my practice and my patients tolerate the treatment and are compliant.

It will be necessary for the patient to use this pneumatic compressor and compression wrap daily for a specified period of time at the prescribed pressures as tolerated. We find this product is cost effective and easy to use for the patient or caregiver.

COLD COMPRESSION THERAPY: (Choose One)

Pressure setting: ☐ Alternating Compression Setting ☐ 15 mmHg ☐ 30 mmHg ☐ 50 mmHg

Treatment On time: ☐ 30 Minutes ☐ 45 Minutes ☐ 60 Minutes ☐ Continuous ☐ Other "On" Time: _____

Treatment Off time: ☐ 30 Minutes ☐ 45 Minutes ☐ 60 Minutes ☐ Continuous ☐ Other "Off" Time: _____

Physician Name: Dr. Solomon Haliova

Physician Address: 22 Madison Ave.

City: Paramus State: NJ Zip Code: 07652 Phone: (201) 845-6555

Physician's Signature: [signature] MD Date: 12/14/2023

SOLOMON HALIOUA, M.D.

22 Madison Ave., Suite 301, Paramus, NJ 07652
T: (201) 845-6555 F: (201) 845-5599

PATIENT'S NAME: KEVIN BROWN

DATE OF EXAM: 02-15-2024
DATE OF BIRTH: 07-06-1987

FOLLOW UP EVALUATION

Chief Complaint: Patient returns today for follow up evaluation. He has undergone lumbar discectomy with annuloplasty on 12/13/23. He notes complete relief of his radicular symptoms. He notes on and off lumbar axial pain. Currently, he is not suffering any pain. He notes occasional lower thoracic strain/spasticity. He is happy with the outcome. He denies any fever, chills, or signs of infection and any loss of bladder or bowel control. His cervical pain has essentially gone.

Physical Examination:

Reflexes: All brisk and intact.

Sensation: Within normal limits.

Power Testing: 5/5 for all extremities.

Cervical Examination: Incision was well healed without signs of infection. No tenderness in the paralumbar region. SLR was negative bilaterally.

Thoracic Examination: Mild tenderness overlying the perithoracic region of T8 through T12.

Diagnostic Impression:

1. Lumbar radiculitis with possible radiculopathy status post lumbar disc decompression with annuloplasty. He is having excellent relief. He was given a prescription of Baclofen 20mg p.o. b.i.d. for incidental pain. He requires no specific need for follow up my office. He may also take Motrin 400-600mg p.o. t.i.d. p.r.n pain.

Respectfully Submitted,

Solomon Halioua, M.D.

This has been electronically signed by Solomon Halioua, M.D. for visit dated 02-15-2024.

2 Pages via SFTP Mon, 26 Feb 2024 09:48:03 GMT

Solomon Halioua, M.D.
Pain Management Services
Board Certified, Fellowship Trained

22 Madison Ave, Suite 301
Paramus, NJ 07652
Phone: 201-845-6555
Fax: 201-845-5599

March 1, 2024

Progressive
Fax: 877-213-7258

Patient Name: Kevin Brown
Claim #: 23-9338374
Date of Service: 12/13/2023
Date of Accident: 10/13/2023

Dear Claims Review Department:

Please accept this letter of appeal for the above-mentioned patient and your decision to deny procedures performed on the date indicated above.

An EOB was received, and the PRIMARY procedure code 62287 was not paid. I have provided documentation that all the codes listed are payable CPT codes.

Code 62287 - "Decompression procedure, percutaneous, of nucleus pulposus of intervertebral disc, any method using needle-based technique to remove disc material under fluoroscopic imaging... with the use of an endoscope, with discography and/or epidural injection(s) at the treated level(s), when performed, single or multiple levels, lumbar.

Code 22526 - "Percutaneous intradiscal electrothermal annuloplasty, unilateral or bilateral including fluoroscopic guidance..."

CPT 22527 - "Percutaneous intradiscal electrothermal annuloplasty, unilateral or bilateral including fluoroscopic guidance; additional levels.

In reading an arbitration case, AAA Case No. Cases 17-19-1140-2601, 17-18-1088-4053, 17-18-1105-4262, and 17-16-1046-0710 the applicant was awarded for all the CPT codes.

Treatment rationale:

As you are aware a percutaneous lumbar discectomy is a minimally invasive procedure used to reduce a herniated disc. The procedure uses a small needle to reach the disc, eliminating the need for an incision. The needle is guided to the disc by fluoroscopy (live x-ray) and a probe with a rotating tip is carefully inserted through the needle. When the probe is turned on, its rotating tip removes small portions of the disc nucleus, creating empty space, allowing the disc to reabsorb the herniation and relieving pressure on the nerve. Because only enough of the disc is removed to reduce pressure inside the disc, the spine remains stable. Studies have shown percutaneous discectomy to be successful in reducing pain and medication requirements, while increasing function in up to 90 percent of

13 Pages via SFTP Sat, 02 Mar 2024 01:16:02 GMT

patients. Recovery is fast and scarring is minimized because no muscles or bone are cut during the procedure.

This condition is not self-limiting and left untreated may lead to serious work and lifestyle disability. Living with chronic pain doesn't just take a toll physically; it takes a toll mentally as well. Chronic pain can disrupt work, family life, and social engagements. Patients see me because they are in pain and together we set up a pain management plan which is an important part of relieving symptoms and restoring a sense of normalcy to their lives.

Based on the patient's diagnosis and medical history presented. The patient and I discussed the following: (1) condition being treated; (2) nature and character of the proposed treatment or surgical procedure; (3) anticipated results; (4) recognized possible alternative forms of treatment; and (5) recognized serious possible risks, complications, and anticipated benefits involved in the treatment or surgical procedure, as well as the recognized possible alternative forms of treatment, including non-treatment.

Medical guidelines employed for medical decision-making must be flexible and allow for deviations from the guideline to incorporate the patient's unique medical factors. Specifically, medical necessity decisions required careful review of patient specific variables such as age, treatment, history, family medical history, treatment compliance record, potential side effects, allergies and patient's concerns and goals regarding treatment options. Because there are so many patient-specific variables to assess, it is my position, since I examined the patient; I am in the best position to determine the best course of treatment and have addressed these variables in the attached medical record.

Please reconsider your denial of payment for the service provided to the patient. As I am sure you will agree that the patient's comfort and quality of care are the foremost concern. Your current policy will force physicians to revert to costlier alternative sources, not to mention the added inconvenience to the patient. I am asking for your help to get the services that were provided to the patient in accordance with their medical needs, and not based on the economics. The policy's clinical criteria cannot be used to deny medically necessary care.

If you have any further questions, please feel free to call me at 201-845-6555.

Sincerely,

Solomon Halioua, M.D.

13 Pages via SFTP Sat, 02 Mar 2024 01:16:02 GMT

SOLOMON HALIOUA, M.D.

22 Madison Ave., Suite 301, Paramus, NJ 07652
T: (201) 845-6555 F: (201) 845-5599

PATIENT'S NAME: KEVIN BROWN

DATE OF EXAM: 03-12-2024
DATE OF BIRTH: 07-06-1987

FOLLOW UP EVALUATION

Chief Complaint: Patient returns today for follow up evaluation. He was doing well with his lumbosacral pain and radicular symptoms. About 2 weeks ago, spontaneously he started to notice pain going down the right lower extremity. He denies any loss of bladder or bowel control. He rates the pain as about a 6-7/10.

Physical Examination:

Reflexes: All brisk and intact.

Sensation: Within normal limits. Radicular pattern of pain is mapped down in the right L5 nerve root distribution.

Power Testing: 5/5 for all extremities.

Cervical Examination: Normal .

Lumbar Examination: Moderate tenderness overlying the right lumbar facet of L3 through S1. SLR was positive on the right to 60 degrees. Lasègue sign was positive on the right.

Diagnostic Impression:

1. Lumbar radiculopathy (M54.16). Patient should undergo repeat lumbar epidural steroid injection (62323). If he fails to improve, we may consider obtaining new imaging studies. Hopefully, this is transient radiculitis for the most part, he did well with disc decompression. Hopefully, the patient will do better with an epidural injection. If he fails to improve, consideration for possibility of disc re-herniation and new MRI of the lumbar spine may be considered. For now, we will monitor his progress.
2. He may continue Motrin 600mg p.o. t.i.d. I have given him a prescription for Baclofen 10mg p.o. b.i.d., 40.

Respectfully Submitted,



Solomon Halioua, M.D.

This has been electronically signed by Solomon Halioua, M.D. for visit dated 03-12-2024.

2 Pages via SFTP Fri, 22 Mar 2024 12:55:02 GMT

New Horizon Surgical Center, L.L.C.
680 Broadway, Suite 201
Paterson, NJ 07514
Tel: (973)782-4202 Fax: (973)782-4206

DATE:	03-15-2024
PATIENT:	KEVIN BROWN
CHART NO:	SCL11793
MRN:	71066
D.O.B:	07-06-1987
AGE:	36 year

RECORD OF OPERATION

PREOPERATIVE DIAGNOSIS:	Lumbar radiculopathy
POSTOPERATIVE DIAGNOSIS:	Lumbar radiculopathy
PROCEDURE PERFORMED:	1. Lumbar epidural steroid injection x 1 L5-S1 translaminar approach. 2. Fluoroscopic assistance.
SURGEON:	Solomon Halioua, M.D.
ANESTHESIOLOGIST:	Dr. Lee
ANESTHESIA:	MAC
ESTIMATED BLOOD LOSS:	None.
COMPLICATIONS:	None.
CONDITION UPON DISCHARGE:	Stable.

DESCRIPTION OF THE PROCEDURE

The patient continues to suffer their usual lumbosacral pain and lower extremity radiative symptoms. The patient currently rates the pain as 8/10. I will perform second lumbar epidural steroid injection as previously planned. No opioids were given for performance of this procedure. Written informed consent was obtained.

The patient was placed in a prone position prepped and draped using meticulous sterile technique. Using fluoroscopic guidance, L5-S1 interspace was identified. Corresponding skin site was marked, 3cc of 1% Lidocaine was used to anesthetize the skin and subcutaneous tissues using a 25-gauge needle. A 20-gauge Tuohy needle was then advanced using loss of resistance to air technique.

Once encountered, negative aspiration for blood/CSF was performed. No paresthesia was elicited. 1.6cc of Omnipaque 240 revealed good epidural spread followed by 80mg of Kenalog with 3cc of normal saline and 1cc of 1% Lidocaine was administered epidurally. Needle was withdrawn. Sterile Band-Aid was applied.

The patient tolerated the procedure well. The patient was discharged home after PACU discharge criteria were satisfied.

Solomon Halioua, M.D.

This has been electronically signed on 03-15-2024.

3 Pages via SFTP Fri, 22 Mar 2024 12:53:36 GMT

NEW HORIZON SURGICAL CENTER

Date of service: 3/15/24

Patient Name (Last, First): Brown, Kevin Date of Birth: 7/16/87

Phone # 646-644-4417

FUNDED _____ SELF PAY _____ CHARITY _____

Check Amount: _____ Check Amount: _____

NO-FAULT/PIP

State Policy Written: (NY) / NJ / OTHER _____ Case Open: (YES) NO

Insurance Company Progressive

Claim # 92933837 4 DOA: 10/13/23

Address PO Box 2920

Clinton, IA 52733

Adjuster Name _____ Ph: _____ Ext: _____

Attorney Name _____ Ph: _____

Address _____

NOTES: _____

WORKERS COMPENSATION

State Policy Written: NY / NJ / OTHER _____ Case Open: YES NO

Insurance Company _____

WCB# _____ Claim# _____ DOA: _____

Address _____

Adjuster Name _____ Ph: _____ Ext: _____

Attorney Name _____ Ph: _____

Address _____

NOTES: _____

LIENS /LOPS

DOA: _____ Do we have signed LOP YES NO (attach if YES)

Attorney's Name: _____ Is this case a slip and fall or MVA related? Circle one

Attorney's Address: _____ If MVA related request global denial from attorney

Phone #: _____

Do they want us to bill patient's private health insurance: YES NO

If YES… (Include copy of front and back of card and health insurance verification sheet)

Insurance Company _____

Policy # _____ Member ID _____

NOTES: _____

DATE VERIFIED _____ NAME OF STAFF MEMBER Jaemy Arroyo

21 Pages via SFTP Thu, 28 Mar 2024 14:46:43 GMT

New Horizon Surgical Center, LLC | 680 Broadway, Suites 110 & 201 | Paterson, NJ, 07514 | Tel.: (973) 782-4202 | Fax: (973) 782-4206 | www.NewHorizonASC.com

Anesthesia Billing

Patient

Name:	Brown, Kevin	**Gender:**	Male	**MRN:**	71066
Address 1:	67-23 Eliot Ave	**Phone:**	(646) 644-4417	**DOB:**	07/06/1987 (36yr)
Address 2:		**Secondary:**			
City, State, Zip:	Middle Village, NY, 11379				

Billing

Anesthesia Type:	MAC with sedation	**ASA:**	2
Referring Physician:		**Surgeon:**	Halioua, Solomon
Case Status:	Performed	**Anesthesia Staff:**	Lee, Chang
Date of Service:	03/15/2024		
Anesthesia Start Time:	07:48		
Anesthesia End Time:	07:55		
Scheduled Procedure:	LUMBAR EPIDURAL STEROID INJECTION		
Performed Procedure:	LUMBAR EPIDURAL STEROID INJECTION		
Pre-Op Diagnosis:	Radiculopathy, lumbar region		
Post-Op Diagnosis:	Radiculopathy, lumbar region		

Primary Guarantor:	Brown, Kevin	**Relationship to Patient:**	Self
Address 1:	67-23 Eliot Ave	**Guarantor DOB:**	07/06/1987
Address 2:		**Phone:**	(646) 644-4417
City, State, Zip:	Middle Village, NY, 11379		

Primary Insurance:	Elliot Ifraimoff Law Office - ATTY	**Insured Name:**	Brown, Kevin
Phone:	(718) 205-1010	**Claim Office Address:**	118-35 Queens Blvd, Ste 1250
Insured ID:	0	**City, State, Zip:**	Queens, NY, 11375
Group Name:		**Group Number:**	
Pre-Certification #:		**Prior Authorization #:**	

Secondary Insurance:	PROGRESSIVE- NYP	**Insured Name:**	Brown, Kevin
Phone:		**Claim Office Address:**	725 BROADWAY
Insured ID:	239338374	**City, State, Zip:**	ALBANY, NY, 12207
Group Name:	DOA 10/13/23	**Group Number:**	
Pre-Certification #:		**Prior Authorization #:**	

OR Staff

Staff	Role	In Time	Out Time
Erin Barton	Nurse- OR	03/15/2024 at 07:48	03/15/2024 at 07:55
Solomon Halioua	Physician	03/15/2024 at 07:48	03/15/2024 at 07:55
Helen Lopez	Surgical Technologist	03/15/2024 at 07:48	03/15/2024 at 07:55
Mark Herrera	X-Ray Tech	03/15/2024 at 07:48	03/15/2024 at 07:55
Chang Lee	Anesthesiologist	03/15/2024 at 07:48	03/15/2024 at 07:55

21 Pages via SFTP Thu, 28 Mar 2024 14:46:43 GMT

New Horizon Surgical Center, LLC | 680 Broadway, Suites 110 & 201 | Paterson, NJ, 07514 | Tel.: (973) 782-4202 | Fax: (973) 782-4206 | www.NewHorizonASC.com

Name: Brown, Kevin **DOS:** 03/15/2024 **Phys:** Halioua, Solomon, MD
DOB: 07/06/1987 (36yr) **Acct #:** 71066
Proc: LUMBAR EPIDURAL STEROID INJECTION
Pre-Op Dx: Radiculopathy, lumbar region

Height 6ft (182.88 cm)	**Weight** 160lbs (72.57kg)	**BMI** 21.70
Alcohol Non Drinker	**Tobacco** Non-smoker	**Drug Use** None
Allergies	Latex Allergies: - Drug Allergies: **No Known** Non-Drug Allergies: **No Known**	
Operations and Surgeries	**Pain Management**	
Please confirm your name and DOB		
Denies any medical history		

Home Medications

No home medications

21 Pages via SFTP Thu, 28 Mar 2024 14:46:43 GMT

New Horizon Surgical Center, LLC | 680 Broadway, Suites 110 & 201 | Paterson, NJ, 07514 | Tel.: (973) 782-4202 | Fax: (973) 782-4206 | www.NewHorizonASC.com

Name: Brown, Kevin (M) DOS: 03/15/2024 Phys: Halioua, Solomon, MD
Acct #: 71066 Address: 67-23 Eliot Ave, Middle Village, NY 11379
DOB: 07/06/1987 (36yr) Proc: LUMBAR EPIDURAL STEROID INJECTION

Record Signed By: **Lee, Chang, MD on 03/18/2024 at 06:14**

Anesthesia Times: **(Start: 07:48) - (End: 07:55)**

Incision/Procedure Times: **(Start: 07:51) - (End: 07:53)**

Pre-Op Diagnosis: **Radiculopathy, lumbar region**

Post-Op Diagnosis: **Radiculopathy, lumbar region**

OR Staff (PR 1)

Name	Role	In Time	Out Time
Barton, Erin	Nurse- OR	03/15/2024 at 07:48	03/15/2024 at 07:55
Halioua, Solomon, MD	Physician	03/15/2024 at 07:48	03/15/2024 at 07:55
Lopez, Helen	Surgical Technologist	03/15/2024 at 07:48	03/15/2024 at 07:55
Herrera, Mark	X-Ray Tech	03/15/2024 at 07:48	03/15/2024 at 07:55
Lee, Chang, MD	Anesthesiologist	03/15/2024 at 07:48	03/15/2024 at 07:55

Anesthesia Pre-Op Exam

62323
01992

NPO Liquids: **03/14/2024 23:00**, Solids: **03/14/2024 23:00**

Anesthesia Plan Natural Airway/Block/Spinal/MAC **ASA** 2

M54.16

Anesthesia Type MAC with sedation

Airway Mallampati Classification: **II**, Dentition: **Normal**, Neck Range of Motion: **Within Normal Limits** P2

Heart Murmurs: **No**, Irregular: **No**

Lung LUNG EXAMINATION: **CTA B/L no Wheezes, Rhonchi or Rales** 0748-0755

Signed by: **Lee, Chang, MD 03/18/2024 06:14**

MAC

Anesthesia Medication Administrations

propofol 10 mg/mL intravenous emulsion TOTAL ADMINISTERED: 150 mg

Administered Date/Time	Type	Dose/Rate	Per Factor	Time Units	Charted By
03/15/2024 07:48	Bolus	150 mg	-	-	Lee, Chang, MD

Pre-Induction Checklist

Selected Checklist Items Patient Identified, ID Band, Chart Reviewed, Consent Signed, NPO, Anesthesia Machine Checked, Safety Belt On, Arms Restrained at <90 on Arm Board, Pressure Points Checked and Padded, Standard Monitors

21 Pages via SFTP Thu, 28 Mar 2024 14:46:43 GMT

Anesthesia Vitals

	HR (EKG)	HR (SpO2)	NIBPd	NIBPm	NIBPs	O2 Flow	RR	SaO2	Temp - Skin	EKG Rhythm	Supplemental O2
07:49		58									
07:49										NSR	3
07:50		78					11				
07:51		87					8			NSR	

EKG

Time	Rhythm	Note	User
07:49	NSR		Chang Lee, MD
07:51	NSR		

Time Notations

Time	Type	Notation	Note	User
07:49	Position	Prone		Chang Lee, MD
07:49	O2	3 LPM		Chang Lee, MD
07:50	O2	Discontinued		Chang Lee, MD

Standard Anesthesia Orders

Pre-Operative

NPO > 8hrs
Start IV or HEP LOK (if local anesthetic)
Infuse IV NS @ 50ml/hr
Vitals per protocol
Fasting Blood Sugar STAT if Diabetic
HCG stat (female; child bearing age)

Approved & Signed By: ChangLee, MD 03/15/2024 at 06:53

Approved & Signed By: ChangLee, MD 03/15/2024 at 06:53

Approved & Signed By: ChangLee, MD 03/15/2024 at 06:53

21 Pages via SFTP Thu, 28 Mar 2024 14:46:43 GMT

Standard Anesthesia Orders

Phase 2

Admit to PACU
Vitals as per PACU standards of care
O2 @ 3L per min. PRN (nasal cannula or face mask)
IV fluids: NS @ 50ml/hr
Check BS if pt is diabetic
Warming unit for hypothermic patients per PACU criteria.
D/C IV when tolerating PO fluids
D/C to home per PACU protocols

Approved & Signed By: ChangLee, MD 03/15/2024 at 06:53

21 Pages via SFTP Thu, 28 Mar 2024 14:46:43 GMT

LEFT ELBOW ULTRASOUND

DOS: 10/19/2023

Patient's name: BROWN, KEVIN

DOB: 07/06/1987

Referring Physician:

Technologist: Johnson, Sandra

Clinical Indication: Left elbow pain.

History of Auto Injury: YES

FINDINGS:

Biceps Brachii Muscle:	Normal
Brachialis Muscle:	Normal
Biceps Brachii Tendon:	Normal
Common Flexor Tendons:	Normal
Common Extensor Tendons:	Normal
Triceps Brachii Muscle:	Normal
Anterior Bundle of the Ulnar Collateral Ligament:	Normal
Lateral Collateral Ligament Complex:	Normal

Area of the Ulnar Nerve at the elbow:	Normal
Area of the Radial Nerve at the elbow:	N/A
Area of the Median Nerve at the elbow:	N/A

Cubital Tunnel Region (Dynamic Imaging): N/A

Additional focused evaluation at site of maximal symptoms: Normal

COMMENTS: Normal study

Impression:
Unremarkable ultrasound study of the left elbow.

Signed by: Dr. Hamid, Alam MD
Signed at: 10/30/2023 07:56:06 PM

LEFT KNEE ULTRASOUND

DOS: 10/19/2023

Patient's name: BROWN, KEVIN

DOB: 07/06/1987

Referring Physician:

Technologist: Johnson, Sandra

Clinical Indication: Left knee pain.

POSTERIOR:

Popliteal Artery	Normal
Popliteal Vein	Normal

ANTERIOR:

Suprapatellar Tendon	Normal
Infrapatellar Tendon	Normal
Suprapatellar bursa	Normal
Prepatellar bursa	Normal

MEDIAL:

Medial collateral ligament	Normal
Medial meniscus	Normal

LATERAL:

Lateral collateral ligament	Normal
Lateral meniscus	Normal

COMMENTS: Normal study

Impression:
Unremarkable ultrasound study of the left knee.

Signed by: Dr. Hamid, Alam MD
Signed at: 10/30/2023 07:56:29 PM

LEFT SHOULDER ULTRASOUND

DOS: 10/19/2023

Patient's name: BROWN, KEVIN

DOB: 07/06/1987

Referring Physician:

Technologist: Johnson, Sandra

Clinical Indication: Left shoulder pain.

FINDINGS:

Anterior / Lateral

Subscapularis Tendon:	Normal
Bicipital Groove:	Normal
Biceps Brachii Long Head Tendon:	Normal
Deltoid muscle & tendon	Normal

Posterior

Supraspinatus muscle & tendon:	Normal
Infraspinatus muscle & tendon:	Normal
Teres Minor muscle & tendon:	Normal
Deltoid muscle & tendon	Normal

Superior / Anterior

Acromioclavicular (A-C) Joint:	Normal
Subacromial-subdeltoid bursa fluid:	NO
Supraspinatus tendon:	Normal

Inferior / Posterior

Infraspinatus tendon:	Normal

Lateral

Fluid is seen in the sub-deltoid bursa:	NO
Deltoid muscle & tendon	Normal

Impression:
Unremarkable ultrasound study of the left shoulder.

Signed by: Dr. Hamid, Alam MD
Signed at: 10/30/2023 07:56:58 PM

RIGHT KNEE ULTRASOUND

DOS: 10/19/2023

Patient's name: BROWN, KEVIN

DOB: 07/06/1987

Referring Physician:

Technologist: Johnson, Sandra

Clinical Indication: Right knee pain.

POSTERIOR:

Popliteal Artery	Normal
Popliteal Vein	Normal

ANTERIOR:

Suprapatellar Tendon	Normal
Infrapatellar Tendon	Normal
Suprapatellar bursa	Normal
Prepatellar bursa	Normal

MEDIAL:

Medial collateral ligament	Normal
Medial meniscus	Normal

LATERAL:

Lateral collateral ligament	Normal
Lateral meniscus	Normal

COMMENTS: Normal study

Impression:
Unremarkable ultrasound study of the right knee.

Signed by: Dr. Hamid, Alam MD
Signed at: 10/30/2023 07:58:01 PM

ECN: 2023112002396 Received Date: 2023-11-17

RIGHT SHOULDER ULTRASOUND

DOS: 10/19/2023

Patient's name: BROWN, KEVIN

DOB: 07/06/1987

Referring Physician:

Technologist: Johnson, Sandra

Clinical Indication: Right shoulder pain.

History of Auto Accident: YES

FINDINGS:

Anterior / Lateral

Subscapularis Tendon:	Normal
Bicipital Groove:	Normal
Biceps Brachii Long Head Tendon:	Normal
Deltoid muscle & tendon	Normal

Posterior

Supraspinatus muscle & tendon:	Normal
Infraspinatus muscle & tendon:	Normal
Teres Minor muscle & tendon:	Normal
Deltoid muscle & tendon	Normal

Superior / Anterior

Acromioclavicular (A-C) Joint:	Normal
Subacromial-subdeltoid bursa fluid:	NO
Supraspinatus tendon:	Normal

Inferior / Posterior

Infraspinatus tendon:	Normal

Lateral

Fluid is seen in the sub-deltoid bursa:	NO
Deltoid muscle & tendon	Normal

COMMENTS: Normal study

Impression:
Unremarkable ultrasound study of the right shoulder.

Signed by: Dr. Hamid, Alam MD
Signed at: 10/30/2023 08:00:34 PM

ULTRASOUND for PARASPINAL MUSCLES of the LUMBAR SPINE

Patient's name: BROWN, KEVIN DOS: 10/19/2023 DOB: 07/06/1987

Referring Physician: Technologist: Johnson, Sandra

Clinical Indication: Lumbar pain. PAIN is on the BILATERAL
Clinical History: Auto accident: Yes
Other type of injury:
If yes explain:

RIGHT PARASPINAL MUSCLES LEFT PARASPINAL MUSCLES

ECHOGENICITY:

LEVEL OF PAIN: (P)

LEVEL:	L1	Normal	Serratus Posterior Inferior Muscle	L1	Normal
	L2	Normal	Longissimus Dorsi Muscle	L2	Normal
	L3	Decreased	Quadratus Lumborum Muscles	L3	Decreased
	L4	Normal	Quadratus Lumborum Muscles	L4	Normal
	L5	Normal	Quadratus Lumborum Muscles	L5	Normal

COMMENTS: Multiple images of L1, L2, L3, L4, L5 area, no muscle tear. The echogenicity of the paraspinal muscles is decreased suggesting muscle spasms.

Findings:

Impression:
Limited study by technique. However there is subtle abnormal echogenicity of the paraspinal muscles bilaterally which may be due to muscle spasms. No gross muscle tear is identified. Follow-up ultrasound is suggested if clinically indicated.

Signed by: Dr. Hamid, Alam MD
Signed at: 10/30/2023 07:59:20 PM

pathline

Surgical Pathology Report

PATIENT
Brown, Kevin
67-23 Elliot Ave
Middle Village, NY 11379
DOB: 07/06/1987
AGE: 36 **SEX:** Male
Patient ID: 71066

SPECIMEN
S23-007834
COLLECTED: 12/13/2023
RECEIVED: 12/13/2023
REPORTED: 12/18/2023

PHYSICIAN
Solomon Halioua
New Horizon Surgical Center
680 Broadway Suite 201
Paterson, NJ 07514

Final Diagnosis

A) Intervertebral Disc, L4-L5 and L5-S1, Discectomy:
-Fragments of benign fibrocartilage.

Electronically Signed By:

James ODonnell On 12/18/2023 03:44 PM EST

Clinical History:
M54.16, M51.26

Gross Description:

A) Received in formalin labeled with the patient's name, date of birth and lumbar disc L4-L5, L5-S1 is a 2.2 x 1.6 x 0.3 cm aggregate of irregular tan-grey rubbery tissue fragments. Entirely submitted in one cassette.

Previous Cases:

None

535 E. Crescent Ave., Ramsey, NJ 07446
Phone 201-661-7280 Fax 1-845-357-4108
www.pathlinelabs.com

BOULEVARD MEDICAL CARE PC
6269 99 STREET
REGO PARK, NY 11374

Neurological Initial Consultation

Date: 12/14/23 D.O.A 10/13/23

Patient Name: Kevin Brown Age: 36

- Details of the accident obtained from ___ patient's own description, ___ from patient's mother/father, ___from patient's guardian. Translation obtained from _____language.
- This is a 36 year old man/woman who states on 10/13/23, as a pedestrian/driver/bicyclist front/rear seat passenger of a car, he/ she was involved in a motor vehicle accident. According to the information presented by the patient he/she was in a regular state of good health and was capable of living on an equal basis with others of his/her age before he/she was involved in a vehicle accident when all of his/her symptoms began. He/ She are currently receiving treatment for the injuries sustained.
- There was: Yes/No reported loss of consciousness.
- After the accident: Yes/No ambulance arrived.
- The patient: Went Home To Recuperate/ Went To ER/Was taking by EMS to _____ Hospital.
- At the hospital: X-Ray(s)/ MRI, Ct-Scan were/ were not taken.
- Result was Positive/ Negative for a _____ fracture.
- Patient was: Examined/ Given Pain Medication_____/ Treated and Released/ Admitted for Further Treatment.
- Due to persistent pain and symptoms he/she decided to seek further medical attention.

who was involved
while driving
hit + run
not called
@ home

CHIEF COMPLAINTS:

- Constant / Intermittent / Headaches / Right / Left Generalized.
- Nervousness / Anxiety / Tension / Dizziness.
- Fainting Spells
- Memory Problem / Problem with concentration Yes / No
- Sleep disturbances: difficulty falling asleep/staying asleep
- Right / Left / Anterior / Lateral chest wall pain
- Constant / Intermittent Posterior **Neck Pain**, worse on the right/left side.
- Stiffness Radiating to the Right / Left Shoulder
- Stiffness Radiating to the Right / Left Arm / Fore Arm / Hand

Neck Pain exacerbated by movement/changing position of the head, neck and body. Patient rates his/her Neck Pain as 6 on a pain scale 1-10.

Injured:
CS, LS
Ankle

No further CS pain

Constant / Intermittent Middle / **Lower Back Pain**

Stiffness Radiating to the Right Buttock / Left Buttock / Right Thigh / Left Thigh / Right Leg / Left Leg.

Lower Back Pain is exacerbated by prolonged sitting, getting up, standing, walking, bending, pushing and pulling. Patient rates his/her Lower Back Pain as 5-8 on a pain scale 1-10.

Weakness/ Numbness/Paraesthesia/Tingling sensations: Upper / Lower Extremities Right / Left

Right / Left / Bilateral Shoulder pain radiating / not radiating down the arm(s)

Right / Left / Bilateral Elbow/Arm/Hand/Wrist/Fingers Pain aggravated by Range of Motion.

Right / Left / Bilateral Hip/Knee/Ankle/Feet/Leg/Toes pain and Stiffness aggravated by walking and negotiating stairs

Other Symptoms: _____

Past Medical History:

The patient denies any significant Medical / Surgical / Trauma History.

Surgical History: _____

Trauma History: _____

Medical History: _____

Allergies: Yes / No

_____

PACEMAKER: _____ *Denied* _____ YES

PREGNANT: _____ *Denied* _____ YES

CURRENT MEDICATIONS: _____

None. *Tylenols/ Motrin/ Ibuprofen/ Naprosyn/ Aspirin/ Flexeril/ other*

Patient doesn't remember/patient will bring in the name of meds upon next visit.

HABITIS: Alcohol: No – Yes: Socially/ Occasionally. Smoking: No –Yes/ occasionally

OCCUPATION: _____

He/ She works in _____. He/ She missed _____ days due to the accident.

He / She did not miss any time from work due to the accident.

FAMILY HISTORY:

Unremarkable. There is a history of cancer, heart disease, hypertension and diabetes on the family. Other_____

PHYSICAL AND ORTHOPEDIC EXAM:

General Appearance:

- Well-developed, well-nourished male/female.
- Patient appears to be in **mild/moderate/severe** distress secondary to pain and discomfort.
- Patient was observed to experience **mind/moderate/extreme** difficulty with getting on to and rising from the exam table.
- Vital signs: BP____/____mm Hg, Pulse___/min., Resp. rate_____/min.
- Skin: texture, turgor appears normal. No bruises/ecchymosed/cuts/rash/lacerations were noted at the time of my examination.
- Head: The head is normocephalic. Hearing appears to be adequate. Extra-ocular movements are intact and bilaterally symmetrical. Vision is preserved to light and figures. Pupils are round, regular and react equally to light. Ear canals are clear.
- Chest: No gross deformity. **Positive/Negative** tenderness in right/left ribs, with deep breathing of cough and at palpation.
- Heart: Regular rate and rhythm, normal heart sounds S1 S2. No friction rub.
- Abdomen: Soft, symmetrical, non-tender. Auscultation transmitted normal bowel sounds.
- Pulses present bilaterally are equal.

Cervical spine

- Normal range of motion to ___ degrees, no tenderness at deep palpation.
- Active and passive range of motion **quite / moderately / considerably/ severely** restricted in flexion, extension, lateral bending and rotation due to pain and stiffness.
- **Mildly/Moderately/Severely** painful muscle spasm of the paravertebral musculature in the cervical area on the right side / left side / bilaterally.
- Palpation of the neck reveals **mild/moderate/severe** tenderness at the C3-C4 level.

Spurling's test was positive/negative at the right and left sides.

Jackson's test was positive/negative at the right and left sides.

ROM for Cervical spine:

40/ 50 for flexion
50/ 60 for extension
70/ 80 for Right lateral rotation
75/ 80 for Left lateral rotation

Thoracic Spine:

☐ Normal range of motion to ___ degrees, no tenderness or pain at deep palpation.

☑ **Mild / Moderate/ Significant/ Severe** pain and tenderness at palpation. Restricted range of motion due to pain and muscular spasm.

Lumbosacral spine:

☐ Normal range of motion to ___ degrees, no tenderness at deep palpation.

☑ Active and passive range of motion **quite / moderately / considerably/ severely** restricted in flexion, extension, lateral bending and rotation due to pain and stiffness.

☑ **Mildly/Moderately/Severely** painful muscle spasm of the paravertebral musculature in lumbosacral area on the right side / left side / bilaterally. R>L

☑ Palpation of the neck reveals **mild/moderate/severe** tenderness at the **L** 4 **-L** 5 **-S** ___level.

Straight Leg Raising Test was positive / negative at 40 degrees on the right / left side and also positive / negative at 40 degrees on the right / ~~left~~ side.

ROM for lumbar spine:

80 / 90 for flexion. Limited
10 / 25 for extension
12 / 25 for the Right lateral rotation
15 / 25 for the Left lateral rotation.

Extremities:

☐ No gross deformities. Range of motion in all joints was full.

☑ Examination of the extremities reveals **tenderness/muscle spasm** over the Ankle

☑ Range of motion limited due to pain and stiffness in:

ROM of Extremities (Decreased)	Shoulder	Elbow	Wrist	Hip	Knee	Ankle
Right						L
Left						

NEUROLOGICAL EXAMINATION:

Mental Status:

✓ Alert and oriented to person, place and time with fluent speech. Patient is pleasant and appropriate. Short term memory is intact. Attention and concentration span is preserved.

Other_____

Cranial Nerves:

II. Visual fields full to confrontational testing. Unremarkable fundi.
III-IV-VI. Pupils equally round and reactive to light. Normal conjugate, extra-ocular eye movements in
all directions of gaze. No nystagmus.
V. Normal facial sensation.
VII. Normal facial symmetry and movements.
VIII. Normal hearing and vestibular function.
IX-X. Normal palatal movement and gag reflex
XI. Normal shoulder shrug and head rotation.
XII. Normal tongue strength and range of motion, no deviation or fasciculation.
✓ **all above normal**

__Other _____

Motor System:

Muscle Atrophy:
✓ no muscle atrophy noted
__muscle atrophy noted at: _____

Muscle Tone:

Upper Limbs	Right Upper Extr.	Normal/ Decreased/ Increased
	Left Upper Extr.	Normal/ Decreased/ Increased
Lower Limbs	Right Lower Extr.	Normal/ Decreased/ Increased
	Left Lower Extr.	Normal/ Decreased/ Increased

Pronator drift: Positive/ Negative
Abnormal Involuntary Movements: Positive/Negative
Muscle Symmetry: Yes/No

Muscle Strength: (graded on a scale of 0 to 5, where *5 is normal muscle strength*)

Motor Exam of Upper Extremities	Right	Left
Shoulder Abduction Deltoid (C5 - axillary nerve)	5 /5	5 /5
Elbow Flexion Biceps (C5, C6 - musculocutaneous nerve)	5 /5	5 /5
Elbow Extention Triceps (C6, C7, C8 - radial nerve)	5 /5	5 /5
Wrist Extention (C6, C7, C8 - radial nerve)	5 /5	5 /5
Wrist Flexion (C6, C7 - median and ulnar nerves)	5 /5	5 /5
Hand Grip/Finger Flexion (C7, C8, T1 - median and ulnar nerves)	5 /5	5 /5

Motor Exam of Lower Extremities	Right	Left
Hip Flexion Iliopsoas (L2, L3, L4 -femoral nerve)	5 /5	5 /5
Hip Extention (L4, L5, S1 - gluteal nerve)	5 /5	5 /5
Knee Extension quadriceps (L2, L3, L4 - femoral nerve)	5 /5	5 /5
Knee Flexion hamstrings (L5, S1, S2 - sciatic nerve)	5 /5	5 /5
Ankle dorsiflexion anterior tibialis (L4, L5- peroneal nerve)	5 /5	5 /5
Ankle/Foot Plantar Flexion gastrocnemius, soleus (S1, S2 - tibial nerve)	5 /5	5 /5

Reflexes:

Deep Tendon Reflexes: (graded 0 to + 5, *normal* +2)

Reflex:	Right	Left
Biceps (C5, C6):	R 2	L 2+
Triceps (C7):	R 2+	L 2+
Brachioradialis (C5,C6):	R 2	L 2+
Patellar (Knee jerk) (L4, L5):	R 2	L 2+
Achilles Tendon (Ankle jerk)(S1):	R 2+	L 2+

Babinski Sign: Present/No response/Absent
Hoffman's Sign: Positive/Negative

Sensory System:

Sensory Examination of Upper Extremities revealed decreased response to light touch and pin prick sensation in:

__R __L trapezius (C3-C4) nerve distribution
✓R __L deltoid (C5-C6) nerve distribution
__R __L bicep (C6) nerve distribution
__R __L median (C7-C8) nerve distribution
__R __L ulnar (C8-T1) nerve distribution
_____ Sensory Examination of Upper extremities revealed normal sensitivity.

Sensory Examination of Lower Extremities revealed decreased response to light touch and pin prick sensation in:

✓R __L gluteai (L5) nerve distribution
__R __L vastus (L3-L4) nerve distribution
__R __L sciatica (L5-S2) nerve distribution
✓R __L tibial anterior (L4-L5) nerve distribution
__R __L peroneus (L5-S1) nerve distribution
__R __L gastrocnemius (L5-S1) nerve distribution
_____ Sensory Examination of Lower extremities revealed normal sensitivity.

Coordination and Gait:

Rapid alternating movements: Normal/Abnormal
Finger-nose-finger test: Normal/Abnormal
Heal-shin test: Normal/Abnormal
Romberg Sign: Positive/Negative
Heel to toe walking (Tandem Gait): Able/Not Able/Difficult
Gait: Normal gait. Ataxic gait. Antalgic gait.

Review of Testing:

X-Rays _____
MRI of the cervical spine 11/2/23: disc bulges C3-4, C4-C5, disc herniation C5-C6
MRI of the Lumbar spine 11/2/23: disc herniation L4-5, L5-S1, C7-T1

Other_____

Impression:

This is a 36 year old man / woman status post a recent motor vehicle accident. His/ her neurological examination is remarkable for **mild/ moderate/severe** mechanical deficit of the **Cervical**, and **mild / moderate/ severe** deficit of the **lumbar spine** and sensory deficit in the distributions of the right / left C5-C6 & L4-L5 dermatomes.

DIAGNOSTIC IMPRESSION:

- ✓ **S13.4XXA** -**Cervical Posttraumatic Sprain** and Strain syndrome.
- ✓ **S33.5XXA** -**Lumbar Posttraumatic Sprain** and Strain syndrome.
- ○ **S233XXA** -**Thoracic Posttraumatic Sprain** and Strain syndrome.
- ✓ **M54.12** -**Radiculopathy**, cervical region
- ✓ **M54.16** -**Radiculopathy**, lumbar region
- ○ **M54.17** -**Radiculopathy**, lumbosacral region
- ○ **M51.26** -**Intervertebral disc displacement**, lumbar region
- ○ **M51.27** -**Intervertebral disc displacement**, lumbosacral region
- ○ **M79.1** -**Myalgia**
- ✓ **M62.838** -**Spasm of Muscle**
- ✓ **M54.2** -**Cervicalgia**
- ○ **M54.3** -**Sciatica**
- ✓ **M54.5** -**Low Back Pain** (Lumbalgia)
- ○ **G56.00** -**Carpal tunnel syndrome**, unspecified upper limb
- ○ **M25.549** -**Pain in joints** of unspecified hand
- ○ **M79.646** -**Pain** in unspecified **finger**(s)
- ○ **M70.10** -**Bursitis**, unspecified hand
- ○ **M77.20** -**Periarthritis**, unspecified wrist
- ○ **M26.60** -**Temporomandibular joint dysfunction** syndrome
- ○ **F43.10** -**Post-traumatic stress** disorder
- ○ **G44.309** -**Post-traumatic headache**, unspecified, not intractable
- ○ **S40.019A** -**Contusion** of unspecified shoulder, initial encounter
- ○ **S80.00XA** -**Contusion** of unspecified knee, initial encounter
- ○ **S46.912A** -**Shoulder** Sprain / Strain Left
- ○ **S46.911A** -**Shoulder** Sprain / Strain Right
- ○ **S53.402.A** -**Elbow** Sprain / Strain Left
- ○ **S53.401A** -**Elbow** Sprain / Strain Right
- ○ **S73.102A** -**Hip** Sprain / Strain Left
- ○ **S73.101A** -**Hip** Sprain / Strain Right
- ○ **S93.402A**- **Ankle** Sprain / Strain Left
- ✓ **S93.401A** -**Ankle** Sprain / Strain Right
- ○ **S83.91XA** -**Knee** Sprain / Strain Left
- ○ **S83.90XA** -**Knee** Sprain / Strain
- ○ **S93.602A** -**Foot** Sprain / Strain left
- ○ **S93.601A** -**Foot** Sprain / Strain

Other: _____

RECOMMENDATIONS:

Based on the description of the injury, the patient's complaints, current physical findings and working diagnosis the following recommendations are **essential and medically necessary** in order to stabilize and expedite recovery of his/her injuries:

1. **EMG / NCV of Upper / Lower Extremities** to confirm Radiculopathy and rule out any potential neuropathy.
2. Continue conservative treatment, including active range of motion, strengthening exercises, against resistance exercise, massage and physical therapy. In addition, chiropractic manipulation will be helpful in relieving the pain as well as ultrasound and electrical muscle stimulation.
3. Orthopedist consultation, Internal medicine consultation, Neurological Follow-Up, Psychologist consultation, Psychiatrist consultation.
4. MRI of cervical / lumbar spine to rule out herniated disc.
5. Patient was instructed to avoid strenuous activity / heavy lifting.
6. Return in 4-6 weeks for re-evaluation.
   Evaluation was done at _____

PROGNOSIS:

Guarded but favorable with treatment.

The possibility of this condition becoming permanent cannot be ruled out at this time. This deficit can persist for an indefinite period of time affection the patient's mobility and quality of life. The prognosis of this patient's condition in regards to a full and complete recovery is favorable with treatment but guarded at this time. Based on the slow progress in the patient's recovery despite physical therapy intervention, additional neurodiagnostic tests were ordered to determine the full extent of the injury and the results of the testing will provide necessary information for final decision regarding this patient's prognosis.

CAUSALITY:

On the basis of medical history presented by the patient and the physical examination findings, it is my professional opinion to reasonable degree of medical certainty that the above-mentioned accident seems to be the causative factor of the patient's symptomatology.

I hereby certify that I preformed the above-described services on the date stated.

Very truly yours,

12/04/23

SHERRIE RAWLINS, MD

LIC # 276358

Boulevard Medical Care PC.

6269 99 St Rego Park, 11374.

Test Date: 12/14/2023

Patient:	Kevin Brown	**DOB:**	7/6/1987	**Physician:**	Sherrie Rawlins, M.D.
Sex:	Male	**Height:**	6' "	**Ref Phys:**	
DOS:	12/14/2023	**Weight:**	170 lbs.	**Technician:**	

Patient Complaints:

Patient is a 36-year-old male who presents with back pain

NCV & EMG Findings:

Evaluation of the **Left superficial peroneal sensory** nerve showed decreased conduction velocity (14 cm-Ant Lat Mall, 37 m/s). The **Right superficial peroneal sensory** nerve showed prolonged distal peak latency (6.2 ms), reduced amplitude (4.4 µV), and decreased conduction velocity (14 cm-Ant Lat Mall, 23 m/s). All remaining nerves (as indicated in the following tables) were within normal limits. All left vs. right side differences were within normal limits.

All F Wave latencies were within normal limits. All F Wave left vs. right side latency differences were within normal limits.

All H Reflex latencies were within normal limits. All H Reflex left vs. right side latency differences were within normal limits.

Needle evaluation of the Right L4-L5 Parasp muscle showed slightly increased spontaneous activity. All remaining muscles (as indicated in the following table) showed no evidence of electrical instability.

Impression:

The above electrodiagnostic study reveals evidence of the right L4-L5 lumbar radiculopathy.

Sherrie Rawlins, M.D.

Nerve Conduction Studies

Motor Summary Table

Stim Site	NR	Onset (ms)	Norm Onset (ms)	O-P Amp (mV)	Norm O-P Amp	Site1	Site2	Delta-0 (ms)	Dist (cm)	Vel (m/s)	Norm Vel (m/s)
Left Peroneal Motor (Ext Dig Brev)											
Ankle		4.5	<6.1	2.8	>2.5	B Fib	Ankle	8.5	38.0	45	>40.0
B Fib		13.0		2.1	>2.5						
Right Peroneal Motor (Ext Dig Brev)											
Ankle		4.5	<6.1	3.5	>2.5	B Fib	Ankle	9.4	38.0	40	>40.0
B Fib		13.9		3.5	>2.5						
Left Tibial Motor (Abd Hall Brev)											
Ankle		5.6	<6.1	5.4	>3.0	Knee	Ankle	10.5	43.0	41	>40.0
Knee		16.1		4.8							
Right Tibial Motor (Abd Hall Brev)											
Ankle		5.9	<6.1	3.1	>3.0	Knee	Ankle	10.1	43.0	43	>40.0
Knee		16.0		2.5							

Anti Sensory Summary Table

Stim Site	NR	Peak (ms)	Norm Peak (ms)	P-T Amp (µV)	Norm P-T Amp	Site1	Site2	Delta-P (ms)	Dist (cm)	Vel (m/s)	Norm Vel (m/s)
Left Sup Peron Anti Sensory (Ant Lat Mall)											
14 cm		3.8	<4.4	5.5	>5.0	14 cm	Ant Lat Mall	3.8	14.0	37	[illegible]
Right Sup Peron Anti Sensory (Ant Lat Mall)											
14 cm		6.2	<4.4	4.4	>5.0	14 cm	Ant Lat Mall	6.2	14.0	23	[illegible]
Left Sural Anti Sensory (Lat Mall)											
Calf		3.4	<4.0	12.7	>5.0	Calf	Lat Mall	3.4	14.0	41	>40.0
Right Sural Anti Sensory (Lat Mall)											
Calf		3.5	<4.0	15.1	>5.0	Calf	Lat Mall	3.5	14.0	40	>40.0

F Wave Studies

NR	F-Lat (ms)	Lat Norm (ms)	L-R F-Lat (ms)	L-R Lat Norm
Left Peroneal (Mrkrs) (EDB)				
	58.00	<60	0.00	<5.1
Right Peroneal (Mrkrs) (EDB)				
	58.00	<60	0.00	<5.1
Left Tibial (Mrkrs) (Abd Hallucis)				
	50.67	<61	0.00	<5.7
Right Tibial (Mrkrs) (Abd Hallucis)				
	50.67	<61	0.00	<5.7

H Reflex Studies

NR	H-Lat (ms)	Lat Norm (ms)	L-R H-Lat (ms)	L-R Lat Norm
Left Tibial (Gastroc)				
	34.00	<35	0.00	<1.5
Right Tibial (Gastroc)				
	34.00	<35	0.00	<1.5

EMG

Side	Muscle	Nerve	Root	Ins Act	Fibs	Psv	Amp	Dur	Poly	Recrt	Int Pat	Comment
Right	AntTibialis	Dp Br Peron	L4-5	Nml	Nml	Nml	Nml	Nml	0	Nml	Nml	
Left	AntTibialis	Dp Br Peron	L4-5	Nml	Nml	Nml	Nml	Nml	0	Nml	Nml	
Left	Peroneus Long	Sup Br Peron	L5-S1	Nml	Nml	Nml	Nml	Nml	0	Nml	Nml	
Right	Peroneus Long	Sup Br Peron	L5-S1	Nml	Nml	Nml	Nml	Nml	0	Nml	Nml	
Left	Medial Gastroc	Tibial	S1-2	Nml	Nml	Nml	Nml	Nml	0	Nml	Nml	
Right	Medial Gastroc	Tibial	S1-2	Nml	Nml	Nml	Nml	Nml	0	Nml	Nml	
Left	BicepsFemS	Sciatic	L5-S1	Nml	Nml	Nml	Nml	Nml	0	Nml	Nml	
Right	BicepsFemS	Sciatic	L5-S1	Nml	Nml	Nml	Nml	Nml	0	Nml	Nml	
Left	VastusMed	Femoral	L2-4	Nml	Nml	Nml	Nml	Nml	0	Nml	Nml	
Right	VastusMed	Femoral	L2-4	Nml	Nml	Nml	Nml	Nml	0	Nml	Nml	
Left	L3-L4 Parasp	Rami	L3-L4	Nml	Nml	Nml	Nml	Nml	0	Nml	Nml	
Right	L3-L4 Parasp	Rami	L3-L4	Nml	Nml	Nml	Nml	Nml	0	Nml	Nml	
Left	L4-L5 Parasp	Rami	L4-L5	Nml	Nml	Nml	Nml	Nml	0	Nml	Nml	
Right	L4-L5 Parasp	Rami	L4-L5	Nml	Nml	Nml	Nml	Nml	0	Nml	Nml	
Left	L5-S1 Parasp	Rami	L5-S1	Nml	Nml	Nml	Nml	Nml	0	Nml	Nml	
Right	L5-S1 Parasp	Rami	L5-S1	Nml	Nml	Nml	Nml	Nml	0	Nml	Nml	

Waveforms:

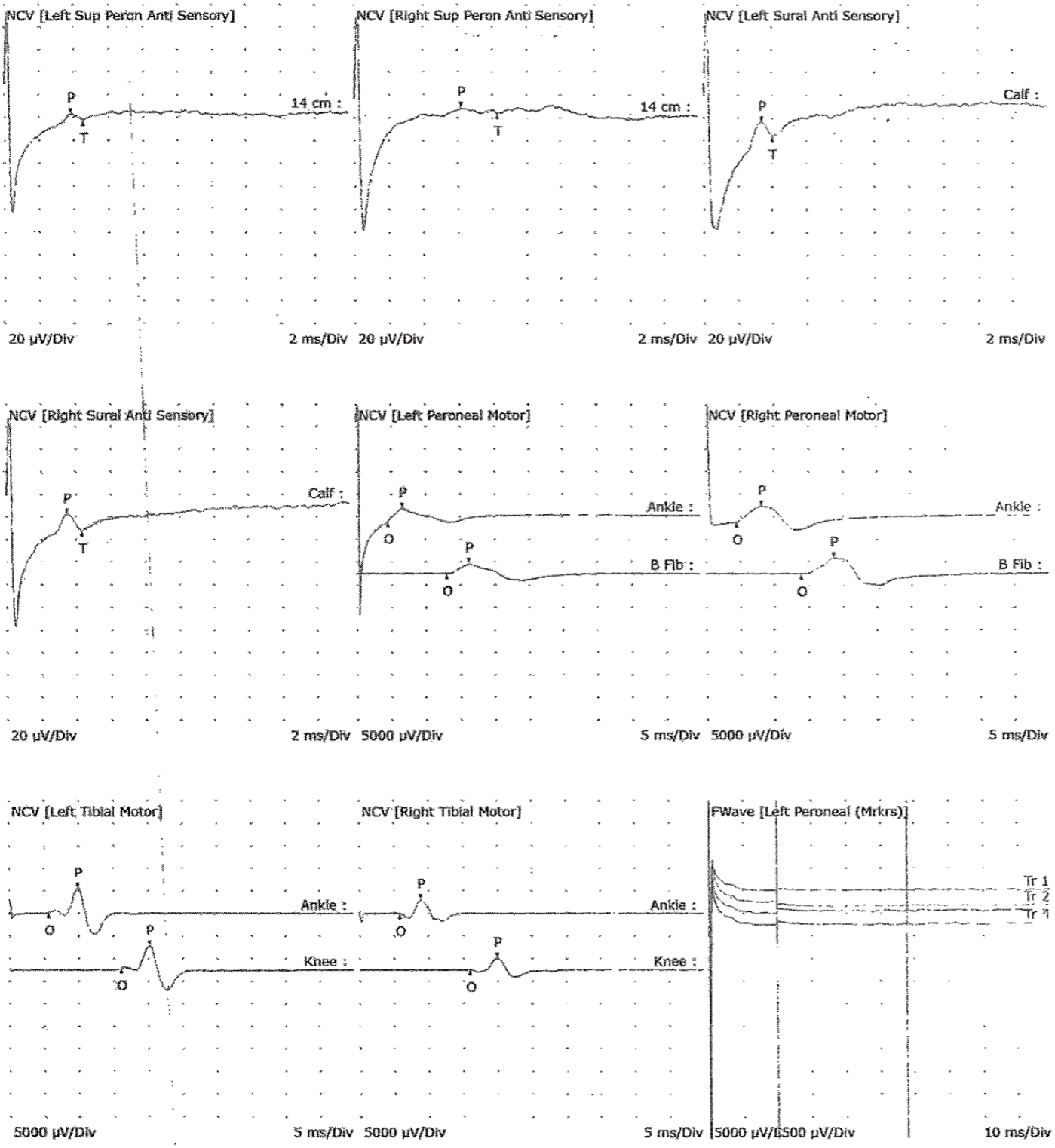
NCV [Left Sup Peron Anti Sensory]
P
T
14 cm :
20 µV/Div
2 ms/Div
NCV [Right Sup Peron Anti Sensory]
P
T
14 cm :
20 µV/Div
2 ms/Div
NCV [Left Sural Anti Sensory]
P
T
Calf :
20 µV/Div
2 ms/Div
NCV [Right Sural Anti Sensory]
P
T
Calf :
20 µV/Div
2 ms/Div
NCV [Left Peroneal Motor]
P
O
Ankle :
P
O
B Fib :
5000 µV/Div
5 ms/Div
NCV [Right Peroneal Motor]
P
O
Ankle :
P
O
B Fib :
5000 µV/Div
5 ms/Div
NCV [Left Tibial Motor]
P
O
Ankle :
P
O
Knee :
5000 µV/Div
5 ms/Div
NCV [Right Tibial Motor]
P
O
Ankle :
P
O
Knee :
5000 µV/Div
5 ms/Div
FWave [Left Peroneal (Mrkrs)]
Tr 1
Tr 2
Tr 1
5000 µV/1500 µV/Div
10 ms/Div

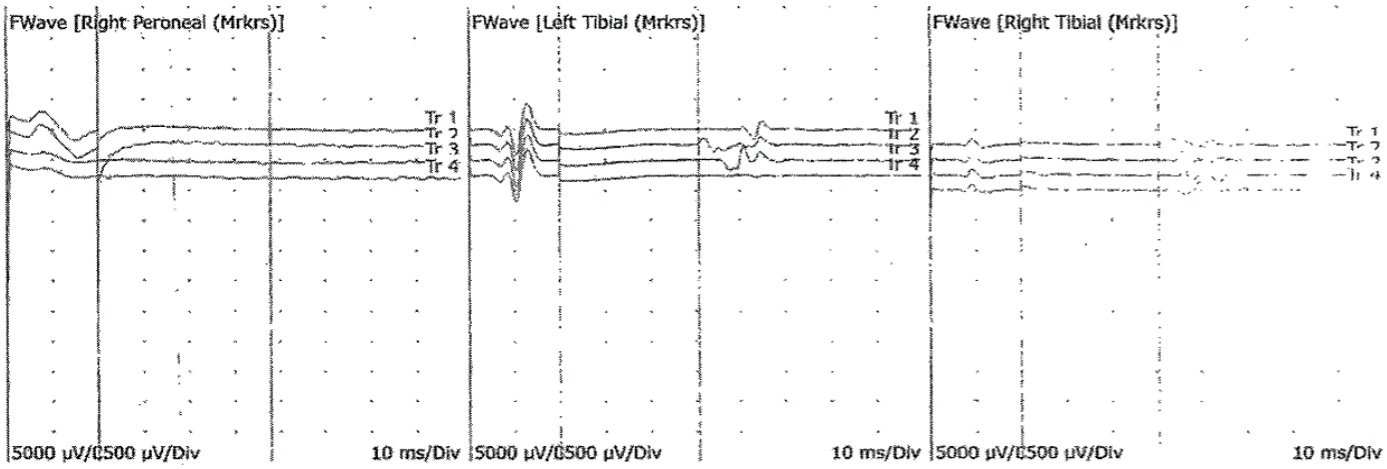
FWave [Right Peroneal (Mrkrs)]
Tr 1
Tr 2
Tr 3
Tr 4
5000 µV/0500 µV/Div
10 ms/Div
FWave [Left Tibial (Mrkrs)]
Tr 1
Tr 2
Tr 3
Tr 4
5000 µV/0500 µV/Div
10 ms/Div
FWave [Right Tibial (Mrkrs)]
5000 µV/0500 µV/Div
10 ms/Div

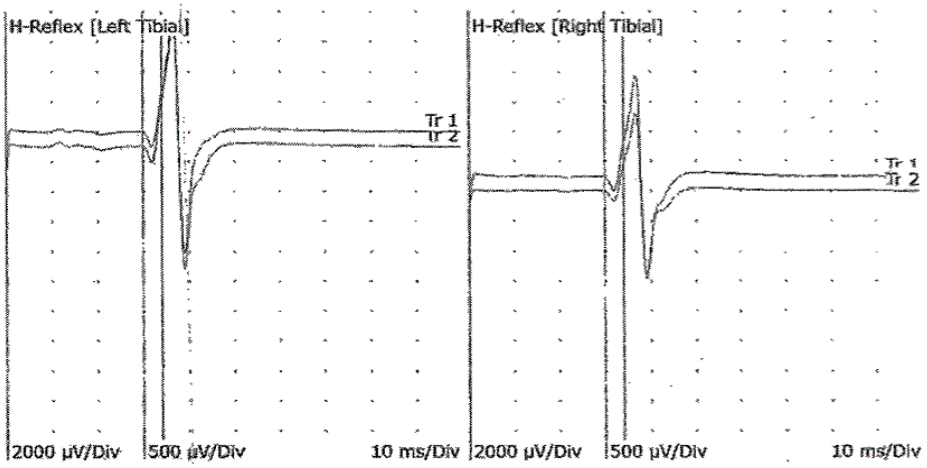
H-Reflex [Left Tibial]
Tr 1
Tr 2
2000 µV/Div
500 µV/Div
10 ms/Div
H-Reflex [Right Tibial]
Tr 1
Tr 2
2000 µV/Div
500 µV/Div
10 ms/Div

Cross Bay Orthopedic Surgery, PC

69-40 108th Street, Unit PR3
Forest Hills, NY 11375
Tel: 718-690-3966
Fax: 929-220-5608

INITIAL ORTHOPEDIC CONSULTATION

DATE: 12/06/2023

NAME: Kevin Brown
DOB: 07/06/1987
DOA: 10/13/2023
GENDER: Male
AGE: 36
CASE TYPE: NF

CHIEF COMPLAINT:

1. Right ankle pain

HISTORY OF PRESENT ILLNESS:

The history was provided by the patient. The patient is a right-hand dominant, 36-year-old male who presents to my office today, with the above-mentioned complaint, which he sustained as a result of a motor vehicle accident, which occurred on 10/13/2023.

The patient reports that he was the restrained driver of his car that was engaged in a rear-end by a second vehicle that was distracted driving. The airbags did not deploy. As a result of the accident, the patient was propelled forward and back. Subsequently, the patient began to experience the immediate onset of pain of the right ankle. The patient denies any loss of consciousness at the time of the accident.

The patient reports that EMS did not arrive at the scene and he was not taken to Hospital. The patient came to this facility for evaluation and treatment, as his pain persisted.

CURRENT COMPLAINTS:

The patient's reported right ankle pain is rated 5/10 (0-10 pain scale). The pain is described as intermittent and aching.

CURRENT TREATMENT:

ECN: 2024011905767 Received Date: 2024-01-18

The patient is doing physical therapy, 2 times a week.
The patient is utilizing Lidocaine cream (patch) and NSAIDs (forgot the name) for the management of pain.

PAST MEDICAL HISTORY:

The patient denies any history of significant medical illness.

PAST SURGICAL HISTORY:

The patient denies any past surgical history.

PAST/SUBSEQUENT ACCIDENT/INJURY HISTORY:

The patient denies any prior history of a motor vehicle accident, trauma injuries, or similar conditions. The patient reports that since the accident of record, no injuries have been sustained and no new accidents have occurred.

CURRENT MEDICATIONS:

NSAIDs and Lidocaine patches.

ALLERGIES:

NKDA

FAMILY HISTORY:

Noncontributory.

OCCUPATIONAL HISTORY:

The patient is currently working in Instacart.

SOCIAL HISTORY:

The patient denies smoking cigarettes. The patient denies the use of recreational drugs. The patient denies consumption of alcohol.

SELF-CARE ADL STATUS:

The patient is independent for self-care ADL.
Mode of transport: drive.

REVIEW OF SYSTEMS:

ECN: 2024011905767 Received Date: 2024-01-18

Constitutional:	Denies fever, chills and weight loss.
HEENT:	Denies dizziness, loss of vision and earaches.
Respiratory:	Denies shortness of breath, cough and wheezing.
Cardiovascular:	Denies chest pain and palpitations.
Gastrointestinal:	Denies abdominal pain, constipation, and nausea or vomiting.
Genitourinary:	Denies incontinence and inability to control urine.
Neurological:	Denies seizures, blackouts, headache, and spasticity.
Endocrine:	Denies excessive thirst and heat or cold intolerance.
Hematologic:	Denies bleeding disorder. Denies easy bruising/bleeding tendency.
Integumentary:	Denies itching. Denies rashes.

PHYSICAL EXAMINATION:

Vitals: **Height:** 6'0'' **Weight:** 160 lbs.

GENERAL APPEARANCE: Alert and oriented to person, place, and time. The patient is in no acute distress.

MUSCULOSKELETAL:

ANKLE:	NORMAL ROM	PATIENT'S ROM
		RIGHT
Dorsiflexion	20	20
Plantar flexion	40	40
Internal rotation	30	30
External rotation	20	20

Skin: Normal
Swelling: Negative swelling

Negative tenderness to palpation **medial malleolus**.
Negative tenderness to palpation **lateral malleolus.**
Negative tenderness to palpation **medial ligaments**.
Negative tenderness to palpation **lateral ligaments**.
Negative **Squeeze** test.
Positive pain with range of motion, right.

NEUROLOGIC:

Speech is coherent, judgment is intact, CN II-XII grossly intact.
Perfusion: Dorsalis pedis 2+, Posterior tibialis 2+, Capillary refill- brisk.

DEEP TENDON REFLEXES:	**RIGHT**	**LEFT**
Biceps	(2+)	(2+)

ECN: 2024011905767 Received Date: 2024-01-18

Triceps	(2+)	(2+)
BR	(2+)	(2+)
Quad	(2+)	(2+)
Achilles	(2+)	(2+)

REVIEW OF DIAGNOSTIC STUDIES:

1. MRI of the **right ankle**, dated 11/6/2023 revealed:
   IMPRESSION:
   a. 2mm osteochondral lesion is seen involving the medial talar dome with joint effusion.
   b. Sprain injury is present at the anterior tibial tendon.
   c. Sprain injury is seen at posterior talofibular ligament.

ASSESSMENT:

1. Right ankle internal derangement. (M24.871)

PLAN OF CARE:

1. We have discussed treatment options including NSAIDs, physical therapy, surgical intervention, and injections.
2. I am recommending the patient to enroll in a course of Physical Therapy 2-3 times a week, for 4 weeks, to decrease pain, increase strength and range of motion with modalities as needed. The patient will maintain a home exercise program 1-2 times per day, for 10-15 minutes/rep.
3. The patient is to continue current medications.
4. The patient's next follow-up visit is in 4 weeks.

CAUSALITY:

Based on my history, physical examination, review of diagnostic testing and of available medical records, patient's injuries, limitations, restrictions, disability and impairment, to a reasonable degree of medical certainty, are causally related to the accident.

TREATMENT RENDERED TODAY: This is an outpatient initial consultation: **99204.**

I, Peter Tomasello, D.O., being a physician duly licensed and practicing in the State of New York, pursuant to CPLR Section 2106, hereby affirm under the penalties of perjury, that the statements contained herein are true and accurate.



Peter Tomasello, D.O.
Orthopedic Surgeon
Supervising Provider

Yakov Shalamov PA-C
Physician Assistant
Rendering Provider

14 Pages via SFTP Mon, 22 Jan 2024 05:28:18 GMT

ECN: 2024011905767 Received Date: 2024-01-18

PATIENT NAME: BROWN, KEVIN
AGE: 36
DOB: 07/06/1987
DOA: 10/13/2023
SEX: Male
FACILITY: WAY TO REHAB PT PC
SERVICE LOCATION: 62-69 99th Street, Rego Park NY, 11374
SEEN BY: Vargas, Kathleen

DIAGNOSIS

M54.50 Low back pain, unspecified

Follow Up Visit (97164)

MVA The patient was a driver. The vehicle was moving and struck from behind. The patient was wearing a seat belt Patient was slowing down on the unpaved road when another vehicle approaches hitting the back of his car. Dec 13, 23 lumbar discectomy

COMPLAINTS

Patient presented today with the following complaints:

Pain scale: 8

Pain is aggravated by:

- Lying Down
- Prolonged Sitting
- Standing
- Walking

Injuries Sustained:

Pain in Lower back: 8 out of 10

Other Complains:

- Lower Back Pain with stiffness and restriction of motion

MEDICAL HISTORY

Patient had a previous MVA and reported a complete recovery.
Past Medical History: N/A
Surgical History: N/A
LMP: NA
LMP: NA Allergies: None or nka
Medications: None.
Drugs: No
ETOH: No
Smoking: No

5 Pages via SFTP Mon, 05 Feb 2024 07:51:01 GMT

PHYSICAL EXAM

Height: 6 FT
Dominant Hand: Right
General appearance: Well developed, well nourished, alert and cooperative, and appears to be in no acute distress.
Heent: Normocephalic, atraumatic, ENT grossly normal

Lumbar Lordosis: Normal
Muscle Spasm: +
Musculoskeletal: Denies muscle wasting. See HPI.

RANGE OF MOTION

Lumbosocral Spine

	L	R
Flexion	50	
Extension	--	
Lateral flexion	--	--
Lateral rotation	35	35
Lateral bending	20	20

PLAN OF CARE

Short-Term Goal:
- To increase strength
- To decrease pain
- To improve gait

Other Short-Term Goal:
To increase ROM.

Long-Term Goal:
- To increase strength & balance
- To gain pain free movement & enable the patient to return to his normal activities of daily living

Other Long-Term Goal:
To alleviate pain. To restore normal ROM.

Physical Therapy including:

- AROM/AAROM/PROM EX

5 Pages via SFTP Mon, 05 Feb 2024 07:51:01 GMT

- ROM EXERCISES
- EVALUATE AND TREAT
- MASSAGE
- STRENGTHENING EX
- MUSCLE REEDUCATION
- STRETCHING EXERCISES
- HEP
- TENS/EMS
- HOT/COLD PACKS
- INFRARED LAMP

Physical therapy recommended: 3 times per week for 6 weeks

The patient was given an appoinment to follow up: 6 Week

PATIENT SIGNATURE:

NAME:Brown, Kevin

PHYSICAL THERAPY SIGNATURE:

NAME: Kathleen Vargas
TITLE: PT
LICENSE: # 048699-01

5 Pages via SFTP Mon, 05 Feb 2024 07:51:01 GMT

Active Life Chiropractic PC
807 Egrets Landing, Carmel, NY 10512
Explanation of Billing

76999 – Unlisted Ultrasound Procedure – Diagnostic BR report

- Please see attached medical report which includes time for the procedure, skills of the doctor, equipment used, medical necessity rationale, description of the procedure performed, and test results.

Per the Introduction and Guidelines of the NYS Fee Schedule, a primary purpose of the schedule is to provide a precise description and coding of the services provided by New York physicians in the care of workers' compensation covered patients and to ensure the proper payment for such services by assuring that they are specifically identifiable. In addition, this edition of the Fee Schedule uses CPT procedure codes, modifiers, and descriptions. Users are referred to the CPT book for an explanation of coding rules and regulations not listed in this schedule. Per NYS Fee Schedule Introductions and General Guidelines, the Relative Value column lists the relative value units (RVU) used to calculate the fee amount for a service. Except as otherwise provided in the schedule, the maximum fee amount is calculated by multiplying the relative value units by the applicable conversion factor.

I am Dr. Diana Vavikova duly licensed to practice chiropractic in NY State since 1998. I am actively practicing Chiropractor for 24 years. Before my Chiropractic Carrie, I was working as a Neurologist in another country for more than 9 years. So total I am working field more than 33 years.

I received education in billing and collection for the chiropractic practice while I was taking business classes in Palmer college of Chiropractic in Davenport, Iowa. I also took additional classes for billing and coding as an additional to standard curriculum and passed exams for Business class and additional classes for billing and coding. I also attended professional nationwide certification courses for Musculoskeletal Diagnostic Ultrasound, where I had been taught billing and coding for this procedure in all details. I also was attending different conferences regarding ICD-9 & 10-CM, CPT, and HCPCS Level II coding rules and applications. In addition, I am knowledgeable of New York State laws and administrative regulations, including No-Fault and Workers' Compensation and the New York State Workers' Compensation Fee Schedule.

Based upon my training and experience, I have knowledge of the correct billing and the correct reimbursement under the New York State No-Fault Rules and Regulations and the New York State Workers Compensation Fee Schedule for services rendered to No-Fault Claimants. I was also an owner of Multispecialty Clinic for many years, where I supervised billing for all providers.
I am Proficient in ICD-9 Codes, ICD-10 Codes, CPT coding of different areas (Radiology, Chiropractic, Neurology, Surgery, Rehabilitation, Physical and Occupational Therapy), as well as HCPCS (Healthcare Common Procedure Coding System), which identify different supply, DME, ointments, testing, which is not included in the standard CPT jurisdiction.

Before my decision regarding billing of Musculoskeletal Diagnostic Ultrasound I review and get knowledge of the following:

1. 2022 AMA Current Procedural Terminology (CPT®) Professional Edition Codebook
2. New York State Workers' Compensation Chiropractic Fee Schedule and Guidelines
3. NYS Insurance Law § 68.1 Adoption of Certain Workers' Compensation Schedules and §68.5 Health Services Not Set Forth in Schedules
4. New York State Workers' Compensation Fee Schedule and Guidelines (Medical Fee Schedule)
5. Optum360 O® Encoder Pro coding software
6. National Correct Coding Initiative (NCCI) Edits and Guidelines
7. AMA CPT Assistant. CPT Assistant published by AMA (American Medical Association), which also publishes the CPT book. The CPT Assistant is IN DEPTH information for coding particular services or procedures performed by providers. The CPT Assistant is the widely-used coding supplement used by coders and providers. The CPT Assistant is indicated in the CPT book as a reference for proper coding a well.

We consulted with multiple our collection attorneys as well.

- Provider is a Doctor of Chiropractic providing services in Region IV. The Conversion factor for Radiology section of Chiropractic fee schedule is 39.82. To determine the proper RVU for the BR report, **Ground rules require us to look at other codes in the Worker's compensation fee schedule** that are similar in nature but do have an assigned RVU value. Total RVU combines three types of RVU: work RVU, practice expense (PE) RVU, and malpractice (MP) RVU before arriving at a final RVU value. MP RVU is a reflection of professional liability insurance cost based on the risk associated with a CPT code. PE RVU is the cost of clinical and nonclinical labor expenses to the practice. And it includes medical and office supplies and equipment. The Radiology section in the Chiropractic section of the fee schedule does not have any codes with assigned RVU value that would be similar in nature to

Ultrasound procedures performed. The codes that are included in this section are too distinct in nature and significantly lower in RVU than Ultrasound procedures. Specifically, Radiologic examination of pelvis, complete – CPT code 72190 is 1.84 RVU. However, Ultrasound of Pelvis, complete CPT code 76856 has RVU of 4.46. Therefore, to determine the proper RVU for the Ultrasound procedures performed under 76999, it is improper to use RVU factors of radiological procedures in the Radiology section of the Chiropractic fee schedule. There are codes in the general Radiology section of the fee schedule that best reflect services rendered. These codes can be used for cross walking the unlisted ultrasound code to determine the proper RVU

- 76800 Ultrasound spinal canal – 5.56 RVU
- 76881 Ultrasound Complete joint – 4.46 RVU
- 76604 Ultrasound of posterior chest _ 5.10 RVU
- 76536 Ultrasound of neck and head – 4.05 RVU
- 76856 Ultrasound of Pelvis – 4.46 RVU

To calculating total RVU, considering multiple procedure Ground Rule 2:

☑ 5.56 + 75% of 5.10 + 75% of 4.05 + 75% of 4.46 = 15.77 RVU x 39.82 conversion factor = $627.86

☐ 5.56 + 75% of 4.46 (1 joints) + 75% of 5.10 + 75% of 4.05 + 75% of 4.46 = 19.11 RVU x 39.82 conversion factor = $761.06

☐ 5.56 + 75% of 8.92 (2 joints) + 75% of 5.10 + 75% of 4.05 + 75% of 4.46 = 22.46 RVU x 39.82 conversion factor = $894.36

☐ 5.56 + 75% of 13.38 (3 joints) + 75% of 5.10 + 75% of 4.05 + 75% of 4.46 = 25.80 RVU x 39.82 conversion factor = $1027.46

☐ 5.56 + 75% of 17.84 (4 joints) +75% of 5.10 + 75% of 4.05 + 75% of 4.46 = 29.15 RVU x 39.82 conversion factor = $1160.75

☐ 5.56 + 75% of 22.30 (5 joints) +75% of 5.10 + 75% of 4.05 + 75% of 4.46 = 32.49 RVU x 39.82 conversion factor = $1293.85

☐ 5.56 + 75% of 26.76 (6 joints) +75% of 5.10 + 75% of 4.05 + 75% of 4.46 = 35.84 RVU x 39.82 conversion factor = $1427.05

☐ 5.56 + 75% of 26.76 (7 joints) +75% of 5.10 + 75% of 4.05 + 75% of 4.46 = 39.18 RVU x 39.82 conversion factor = $1560.25

☐ 5.56 + 75% of 26.76 (8 joints) +75% of 5.10 + 75% of 4.05 + 75% of 4.46 = 42.53 RVU x 39.82 conversion factor = $1693.45

Dr. Diana Vavikova, DC
MSC Diagnostic Ultrasound Certified

DIAGNOSTIC SONOGRAM REPORT

DOS: 11/06/2023

Patient's name: Brown, Kevin
DOB: 07/09/1987
Gender: Male
DOA: 10/13/2023

HISTORY: Mr. Kevin Brown is a 36-year-old-male, who was involved in a motor-vehicle accident as a driver. Emergency crew did not arrive at the scene of the accident. The patient was not brought to the emergency room. The patient had no medical issues before the accident, as he stated. Past/Family medical history: the patient denies any significant past medical history.

SUBJECTIVE COMPLAINTS: The patient reports stiffness and constant aching **neck pain** (6/10). The patient has difficulties turning the head. The pain exacerbates with increased activity. The patient has stiffness and aching pain in the **middle back** (6/10). The pain exacerbates by performing house activities, prolonged sitting. The patient also reports constant aching pain in the **lower back** (7/10). The pain exacerbates by prolonged sitting and standing, bending down.

MEDICAL NECESSITY: This report will additionally serve as medical necessity for providing ultrasound testing. A diagnostic ultrasonographic examination was performed in order to help confirm the severity of soft tissue nerve injury and quantify the possibility of a patient's concomitant neurophysiological status.

Benefits of ultrasound:

- **Dynamic imaging**: ultrasound evaluation can be directly guided by the patient's symptoms and findings at physical examination. This study is concentrated on the area of the concern of the patient, areas of tenderness and focal symptoms with feedback from the patient during exam. Doctors can diagnose "in real time" as they can see movement of a soft tissue structure such as tendon, joint or an extremity.
- **Sensitivity:** ultrasound is priceless in the assessing of the conditions, such as partial or full-thickness tears of muscles or ligaments, hemorrhages, snap tendon syndromes, bone injury's, infections, blood accumulations, cellulitis, arthritis, detection of soft tissue masses, ganglion cysts, soft tissues tumors. According to a Mayo clinic study, ultrasound appeared to be more sensitive than MRI in detecting injuries in the inflammation of certain structures as well as stages of healing: from active inflammation to resolved condition, such as resolved stage of healing fibrosis.
- **Availability:** widely available, easy-to-use and less expensive than most other imaging methods.
- **Safety:** extremely safe, non-invasive and does not use radiation, excellent alternative for claustrophobic patients and patients with cardiac pacemakers or metallic implants. Ultrasound has no known harmful effects on humans.

Ultrasound is sophisticated, quick, and efficient diagnostic procedure not only for making exact diagnosis but also for establishing stage of healing which is helping in the modification of the treatment process in a timely manner.

TIME OF PROCEDURE: 30 minutes.

SKILLS OF THE DOCTOR: Procedure is performed and interpreted by Chiropractor duly licensed in the state of New York who specializes in the Diagnostic Sonography and has multiple certifications from Sonogram schools. I had an extensive training and performed thousands of diagnostic sonograms in the traditional office setting as well as the surgical settings. I also was personally trained and certified by Dr. Steven Coppola

DIAGNOSTIC SONOGRAM REPORT

DOS: 11/06/2023

Patient's name: Brown, Kevin
DOB: 07/09/1987
Gender: Male
DOA: 10/13/2023

who is one of the leaders in this industry teaching all over United States. Furthermore, I am teaching myself at my own seminars intended for any medical professionals.

EQUIPMENT USED: GE Logiq E which includes a range of customization capabilities to speed workflow and provides excellent image quality for the diagnostics of the muscles, tendons, ligaments, nerves and joints throughout the body. It is used to help diagnose sprains, strains, tears, trapped nerves, arthritis and other musculoskeletal conditions. Ultrasound is safe, non-invasive, and does not use ionizing radiation.

STATUS OF THE PATIENT: Subacute status.

ULTRASOUND OF THE SPINE

FINDINGS: There is abnormal echogenicity of the bilateral paraspinal muscles of the cervical, thoracic, lumbar spine, which may be due to muscle spasms, inflammation, trauma, strain or facet subluxation.

Hyper-echoic images were noted of the following muscles: (c3-c7) Splenius Cervicis, Iliocostalis Cervicis, with bilateral edema of the deep muscles at the c5-c7 level; (t4-t8) Trapezius, Rhomboid Major, Iliocostalis Thoracis, with bilateral edema of the deep muscles at the t5-t8 level; (l2-l5) Latissimus Dorsi, Erector-Spinae, Multifidus, with bilateral edema of the middle and deep muscles at the l2-l4 level - more likely due to chronic facet subluxation, spinal misalignment, and muscle guarding /chronic spasms. No cystic lesions nor muscle tears were noted.

IMPRESSION: Abnormal echogenicity of the bilateral paraspinal muscles of the cervical, thoracic, lumbar spine, which may be due to muscle spasms, inflammation, trauma, strain, facet subluxation, spinal misalignment or developing of fibrotic changes as well as muscle guarding/chronic muscle spasm. No cystic lesions nor muscle tears were noted.

RECOMMENDATION FOR THE SPINE: Pain management consultation. Chiropractic treatment and Physical therapy for 2 months, 3-4 times a week, including EMS, such as interferential current 15-20 mA for control of the pain syndrome.

Evaluated and analyzed by Dr.Diana Vavikova, D.C.

Active Life Chiropractic PC
807 Egrets Landing, Carmel, NY 10512
Explanation of Billing

76999 – Unlisted Ultrasound Procedure – Diagnostic BR report

- Please see attached medical report which includes time for the procedure, skills of the doctor, equipment used, medical necessity rationale, description of the procedure performed, and test results.

Per the Introduction and Guidelines of the NYS Fee Schedule, a primary purpose of the schedule is to provide a precise description and coding of the services provided by New York physicians in the care of workers' compensation covered patients and to ensure the proper payment for such services by assuring that they are specifically identifiable. In addition, this edition of the Fee Schedule uses CPT procedure codes, modifiers, and descriptions. Users are referred to the CPT book for an explanation of coding rules and regulations not listed in this schedule. Per NYS Fee Schedule Introductions and General Guidelines, the Relative Value column lists the relative value units (RVU) used to calculate the fee amount for a service. Except as otherwise provided in the schedule, the maximum fee amount is calculated by multiplying the relative value units by the applicable conversion factor.

I am Dr. Diana Vavikova duly licensed to practice chiropractic in NY State since 1998. I am actively practicing Chiropractor for 24 years. Before my Chiropractic Carrie, I was working as a Neurologist in another country for more than 9 years. So total I am working field more than 33 years.

I received education in billing and collection for the chiropractic practice while I was taking business classes in Palmer college of Chiropractic in Davenport, Iowa. I also took additional classes for billing and coding as an additional to standard curriculum and passed exams for Business class and additional classes for billing and coding. I also attended professional nationwide certification courses for Musculoskeletal Diagnostic Ultrasound, where I had been taught billing and coding for this procedure in all details. I also was attending different conferences regarding ICD-9 & 10-CM, CPT, and HCPCS Level II coding rules and applications. In addition, I am knowledgeable of New York State laws and administrative regulations, including No-Fault and Workers' Compensation and the New York State Workers' Compensation Fee Schedule.

Based upon my training and experience, I have knowledge of the correct billing and the correct reimbursement under the New York State No-Fault Rules and Regulations and the New York State Workers Compensation Fee Schedule for services rendered to No-Fault Claimants. I was also an owner of Multispecialty Clinic for many years, where I supervised billing for all providers.
I am Proficient in ICD-9 Codes, ICD-10 Codes, CPT coding of different areas (Radiology, Chiropractic, Neurology, Surgery, Rehabilitation, Physical and Occupational Therapy), as well as HCPCS (Healthcare Common Procedure Coding System), which identify different supply, DME, ointments, testing, which is not included in the standard CPT jurisdiction.

Before my decision regarding billing of Musculoskeletal Diagnostic Ultrasound I review and get knowledge of the following:

1. 2022 AMA Current Procedural Terminology (CPT®) Professional Edition Codebook
2. New York State Workers' Compensation Chiropractic Fee Schedule and Guidelines
3. NYS Insurance Law § 68.1 Adoption of Certain Workers' Compensation Schedules and §68.5 Health Services Not Set Forth in Schedules
4. New York State Workers' Compensation Fee Schedule and Guidelines (Medical Fee Schedule)
5. Optum360 ®® Encoder Pro coding software
6. National Correct Coding Initiative (NCCI) Edits and Guidelines
7. AMA CPT Assistant. CPT Assistant published by AMA (American Medical Association), which also publishes the CPT book. The CPT Assistant is IN DEPTH information for coding particular services or procedures performed by providers. The CPT Assistant is the widely-used coding supplement used by coders and providers. The CPT Assistant is indicated in the CPT book as a reference for proper coding a well.

We consulted with multiple our collection attorneys as well.

- Provider is a Doctor of Chiropractic providing services in Region IV. The Conversion factor for Radiology section of Chiropractic fee schedule is 39.82. To determine the proper RVU for the BR report, **Ground rules require us to look at other codes in the Worker's compensation fee schedule** that are similar in nature but do have an assigned RVU value. Total RVU combines three types of RVU: work RVU, practice expense (PE) RVU, and malpractice (MP) RVU before arriving at a final RVU value. MP RVU is a reflection of professional liability insurance cost based on the risk associated with a CPT code. PE RVU is the cost of clinical and nonclinical labor expenses to the practice. And it includes medical and office supplies and equipment. The Radiology section in the Chiropractic section of the fee schedule does not have any codes with assigned RVU value that would be similar in nature to

12 Pages via SFTP Tue, 12 Mar 2024 08:18:55 GMT

Ultrasound procedures performed. The codes that are included in this section are too distinct in nature and significantly lower in RVU than Ultrasound procedures. Specifically, Radiologic examination of pelvis, complete – CPT code 72190 is 1.84 RVU. However, Ultrasound of Pelvis, complete CPT code 76856 has RVU of 4.46. Therefore, to determine the proper RVU for the Ultrasound procedures performed under 76999, it is improper to use RVU factors of radiological procedures in the Radiology section of the Chiropractic fee schedule. There are codes in the general Radiology section of the fee schedule that best reflect services rendered. These codes can be used for cross walking the unlisted ultrasound code to determine the proper RVU

- 76800 Ultrasound spinal canal – 5.56 RVU
- 76881 Ultrasound Complete joint – 4.46 RVU
- 76604 Ultrasound of posterior chest _ 5.10 RVU
- 76536 Ultrasound of neck and head – 4.05 RVU
- 76856 Ultrasound of Pelvis – 4.46 RVU

To calculating total RVU, considering multiple procedure Ground Rule 2:

- ☐ 5.56 + 75% of 5.10 + 75% of 4.05 + 75% of 4.46 = 15.77 RVU x 39.82 conversion factor = $627.86
- ☑ 5.56 + 75% of 4.46 (1 joints) + 75% of 5.10 + 75% of 4.05 + 75% of 4.46 = 19.11 RVU x 39.82 conversion factor = $761.06
- ☐ 5.56 + 75% of 8.92 (2 joints) + 75% of 5.10 + 75% of 4.05 + 75% of 4.46 = 22.46 RVU x 39.82 conversion factor = $894.36
- ☐ 5.56 + 75% of 13.38 (3 joints) + 75% of 5.10 + 75% of 4.05 + 75% of 4.46 = 25.80 RVU x 39.82 conversion factor = $1027.46
- ☐ 5.56 + 75% of 17.84 (4 joints) +75% of 5.10 + 75% of 4.05 + 75% of 4.46 = 29.15 RVU x 39.82 conversion factor = $1160.75
- ☐ 5.56 + 75% of 22.30 (5 joints) +75% of 5.10 + 75% of 4.05 + 75% of 4.46 = 32.49 RVU x 39.82 conversion factor = $1293.85
- ☐ 5.56 + 75% of 26.76 (6 joints) +75% of 5.10 + 75% of 4.05 + 75% of 4.46 = 35.84 RVU x 39.82 conversion factor = $1427.05
- ☐ 5.56 + 75% of 26.76 (7 joints) +75% of 5.10 + 75% of 4.05 + 75% of 4.46 = 39.18 RVU x 39.82 conversion factor = $1560.25
- ☐ 5.56 + 75% of 26.76 (8 joints) +75% of 5.10 + 75% of 4.05 + 75% of 4.46 = 42.53 RVU x 39.82 conversion factor = $1693.45

Dr. Diana Vavikova, DC
MSC Diagnostic Ultrasound Certified

DIAGNOSTIC SONOGRAM REPORT

DOS: 02/06/2024

Patient's name: Brown, Kevin
DOB: 07/09/1987
Gender: Male
DOA: 10/13/2023

Follow-up ultrasound diagnostic was performed to determine stages of healing, level of improvement of the patient, and new complaints, in order to adjust the treatment protocol.

HISTORY: Mr. Kevin Brown is a 36-year-old-male, who was involved in a motor-vehicle accident as a driver. Emergency crew did not arrive at the scene of the accident. The patient was not brought to the emergency room. The patient had no medical issues before the accident, as he stated. Past/Family medical history: the patient denies any significant past medical history.

SUBJECTIVE COMPLAINTS: The patient reports stiffness and constant aching **neck pain** (5/10). The patient has difficulties turning the head. The pain exacerbates with increased activity. The patient has stiffness and aching pain in the **middle back** (5/10). The pain exacerbates by performing house activities. The patient also reports constant aching pain in the **lower back** (6/10). The pain exacerbates by prolonged sitting, bending down. The patient complains of intermittent aching pain in **pelvis** (6/10), on the left side. The pain exacerbates when the patient tries to perform activities of a daily routine. Climbing stairs, walking causes pain and discomfort. The pain in pelvis worsens with physical activities.

MEDICAL NECESSITY: This report will additionally serve as medical necessity for providing ultrasound testing. A diagnostic ultrasonographic examination was performed in order to help confirm the severity of soft tissue nerve injury and quantify the possibility of a patient's concomitant neurophysiological status.

Benefits of ultrasound:

- **Dynamic imaging**: ultrasound evaluation can be directly guided by the patient's symptoms and findings at physical examination. This study is concentrated on the area of the concern of the patient, areas of tenderness and focal symptoms with feedback from the patient during exam. Doctors can diagnose "in real time" as they can see movement of a soft tissue structure such as tendon, joint or an extremity.
- **Sensitivity:** ultrasound is priceless in the assessing of the conditions, such as partial or full-thickness tears of muscles or ligaments, hemorrhages, snap tendon syndromes, bone injury's, infections, blood accumulations, cellulitis, arthritis, detection of soft tissue masses, ganglion cysts, soft tissues tumors. According to a Mayo clinic study, ultrasound appeared to be more sensitive than MRI in detecting injuries in the inflammation of certain structures as well as stages of healing: from active inflammation to resolved condition, such as resolved stage of healing fibrosis.
- **Availability:** widely available, easy-to-use and less expensive than most other imaging methods.
- **Safety:** extremely safe, non-invasive and does not use radiation, excellent alternative for claustrophobic patients and patients with cardiac pacemakers or metallic implants. Ultrasound has no known harmful effects on humans.

Ultrasound is sophisticated, quick, and efficient diagnostic procedure not only for making exact diagnosis but also for establishing stage of healing which is helping in the modification of the treatment process in a timely manner.

TIME OF PROCEDURE: 35 minutes.

12 Pages via SFTP Tue, 12 Mar 2024 08:18:55 GMT

DIAGNOSTIC SONOGRAM REPORT

DOS: 02/06/2024

Patient's name: Brown, Kevin
DOB: 07/09/1987
Gender: Male
DOA: 10/13/2023

SKILLS OF THE DOCTOR: Procedure is performed and interpreted by Chiropractor duly licensed in the state of New York who specializes in the Diagnostic Sonography and has multiple certifications from Sonogram schools. I had an extensive training and performed thousands of diagnostic sonograms in the traditional office setting as well as the surgical settings. I also was personally trained and certified by Dr. Steven Coppola who is one of the leaders in this industry teaching all over United States. Furthermore, I am teaching myself at my own seminars intended for any medical professionals.

EQUIPMENT USED: GE Logiq E which includes a range of customization capabilities to speed workflow and provides excellent image quality for the diagnostics of the muscles, tendons, ligaments, nerves and joints throughout the body. It is used to help diagnose sprains, strains, tears, trapped nerves, arthritis and other musculoskeletal conditions. Ultrasound is safe, non-invasive, and does not use ionizing radiation.

STATUS OF THE PATIENT: Chronic status. The patient is improving slowly in spite of intense treatment.

ULTRASOUND OF THE SPINE

FINDINGS: There is abnormal echogenicity of the bilateral paraspinal muscles of the lumbar, cervical, thoracic spine, and left paraspinal muscles of sacroiliac spine, which may be due to muscle spasms, inflammation, trauma, strain or facet subluxation. Intra-articular echoes were visualized extending deep into the joint margin as with active Sacroiliitis. Hyper-echoic images were noted of the following muscles: (c3-c7) Iliocostalis Cervicis, **with slightly decreased level of inflammation; granulation tissue noted; remaining bilateral edema of the middle muscles at the c6-c7 level;** (t3-t7) Rhomboid Major, Erector-Spinae, **with slightly decreased level of inflammation; granulation tissue noted; remaining bilateral edema of the middle muscles at the t6-t8 level;** (l1-l5) Erector-Spinae, **with decreased level of inflammation; fibrous tissue noted; remaining bilateral edema of the middle and deep muscles at the l2-l4 level;** (left SI joint) Piriformis, Multifidus, **with decreased level of inflammation; fibrous tissue noted; remaining edema of the deep muscles on the left side**. No cystic lesions nor muscle tears were noted.

IMPRESSION: There is an abnormal echogenicity of the bilateral paraspinal muscles of the lumbar, cervical, thoracic spine, and left paraspinal muscles of sacroiliac spine, which may be due to muscle spasms, inflammation, trauma, strain, facet subluxation, spinal misalignment or developing of fibrotic changes as well as muscle guarding/chronic muscle spasm. No cystic lesions nor muscle tears were noted. Mild improvement was demonstrated at the lumbar and sacroiliac spine, with slightly decreased level of inflammation and partially diminished area of muscle spasm. Fibrous tissue noted. Same level of inflammation was demonstrated at the cervical and thoracic spine, with remaining abnormal echogenicity of paraspinal muscles.

We compared this study with previous studies of 12/04/2023. We needed to determine the stages of healing and level of improvement of the patient in order to adjust the treatment protocol. Improvement is demonstrated, with decreased level of inflammation/edema. Chronic phase is noted, with signs of remodeling and fibrous tissue formation.

DIAGNOSTIC SONOGRAM REPORT

DOS: 02/06/2024

Patient's name: Brown, Kevin
DOB: 07/09/1987
Gender: Male
DOA: 10/13/2023

RECOMMENDATION FOR THE SPINE: Chiropractic treatment and Physical therapy for 2 months, 3-4 times a week, including PRE-MOD, therapeutic ultrasound, microwave therapy. Diathermy locally 20 mA (2-4 inch) for deep muscles. Stretching and McKenzie exercises. Myofascial release and trigger point therapy.

Evaluated and analyzed by Dr.Diana Vavikova, D.C.

PATIENT NAME: BROWN KEVIN
DOB: 07/06/1987
AGE: 36
SEX: Male

FACILITY: WAY TO REHAB PT PC
SERVICE LOCATION: 62-69 99th Street, Rego Park NY, 11374
SEEN BY: Kathleen Vargas (PHYSICAL THERAPY)
DOA: 10/13/2023

CHIEF COMPLAINT

Patient presented today with the following complaints
Pain in Lower Back is 6 out of 10
Pain in Right Ankle is 5 out of 10

SUBJECTIVE

Slight Improvement in Symptoms

OBJECTIVE

DIAGNOSES:
M54.50 Low back pain, unspecified, M25.571 Pain in right ankle and joints of right foot

OBJECTIVE:
Spasm
Decreased ROM

TREATMENT:
Infrared [97026]
Electrical Stim [97014]
Therapeutic Exercise [97110]
Manual Therapy [97140]

SUPER BILL:
97026 - 2.54,
97014 - 2.66,
97110 - 3.97,
97140 - 4.23

ASSESSMENT

Tolerated Tx. well

PLAN

Continue with current treatment plan

PATIENT SIGNATURE:

NAME: BROWN KEVIN

PHYSICAL THERAPY SIGNATURE:

NAME: Kathleen Vargas (PHYSICAL THERAPY)
TITLE: PT
LICENSE: #048699-01

2 Pages via SFTP Thu, 07 Dec 2023 15:52:18 GMT

PATIENT NAME: BROWN KEVIN
DOB: 07/06/1987
AGE: 36
SEX: Male

FACILITY: WAY TO REHAB PT PC
SERVICE LOCATION: 62-69 99th Street, Rego Park NY, 11374
SEEN BY: HAYDEE GANACE TSANG (PHYSICAL THERAPY)
DOA: 10/13/2023

CHIEF COMPLAINT

Patient presented today with the following complaints
Pain in Lower Back is 6 out of 10
Pain in Right Ankle is 5 out of 10

SUBJECTIVE

Slight Improvement in Symptoms

OBJECTIVE

DIAGNOSES:
M54.50 Low back pain, unspecified, M25.571 Pain in right ankle and joints of right foot

OBJECTIVE:
Spasm
Decreased ROM

TREATMENT:
Infrared [97026]
Electrical Stim [97014]
Therapeutic Exercise [97110]
Manual Therapy [97140]

SUPER BILL:
97026 - 2.54,
97014 - 2.66,
97110 - 3.97,
97140 - 4.23

ASSESSMENT

Tolerated Tx. well

PLAN

Continue with current treatment plan

PATIENT SIGNATURE:

NAME: BROWN KEVIN

PHYSICAL THERAPY SIGNATURE:

NAME: HAYDEE GANACE TSANG (PHYSICAL THERAPY)
TITLE: PT
LICENSE: #027166-01

4 Pages via SFTP Fri, 22 Dec 2023 13:59:15 GMT

PATIENT NAME: BROWN KEVIN
DOB: 07/06/1987
AGE: 36
SEX: Male

FACILITY: WAY TO REHAB PT PC
SERVICE LOCATION: 62-69 99th Street, Rego Park NY, 11374
SEEN BY: HAYDEE GANACE TSANG (PHYSICAL THERAPY)
DOA: 10/13/2023

CHIEF COMPLAINT

Patient presented today with the following complaints
Pain in Lower Back is 6 out of 10
Pain in Right Ankle is 5 out of 10

SUBJECTIVE

Slight Improvement in Symptoms

OBJECTIVE

DIAGNOSES:
M54.50 Low back pain, unspecified, M25.571 Pain in right ankle and joints of right foot

OBJECTIVE:
Spasm
Decreased ROM

TREATMENT:
Infrared [97026]
Electrical Stim [97014]
Therapeutic Exercise [97110]
Manual Therapy [97140]

SUPER BILL:
97026 - 2.54,
97014 - 2.66,
97110 - 3.97,
97140 - 4.23

ASSESSMENT

Tolerated Tx. well

PLAN

Continue with current treatment plan

PATIENT SIGNATURE:

NAME: BROWN KEVIN

PHYSICAL THERAPY SIGNATURE:

NAME: HAYDEE GANACE TSANG (PHYSICAL THERAPY)
TITLE: PT
LICENSE: #027166-01

4 Pages via SFTP Fri, 22 Dec 2023 13:59:15 GMT

PATIENT NAME: BROWN KEVIN
DOB: 07/06/1987
AGE: 36
SEX: Male

FACILITY: WAY TO REHAB PT PC
SERVICE LOCATION: 62-69 99th Street, Rego Park NY, 11374
SEEN BY: HAYDEE GANACE TSANG (PHYSICAL THERAPY)
DOA: 10/13/2023

CHIEF COMPLAINT

Patient presented today with the following complaints
Pain in Lower Back is 6 out of 10
Pain in Right Ankle is 5 out of 10

SUBJECTIVE

Slight Improvement in Symptoms

OBJECTIVE

DIAGNOSES:
M54.50 Low back pain, unspecified, M25.571 Pain in right ankle and joints of right foot

OBJECTIVE:
Spasm
Decreased ROM

TREATMENT:
Infrared [97026]
Electrical Stim [97014]
Therapeutic Exercise [97110]
Manual Therapy [97140]

SUPER BILL:
97026 - 2.54,
97014 - 2.66,
97110 - 3.97,
97140 - 4.23

ASSESSMENT

Tolerated Tx. well

PLAN

Continue with current treatment plan

PATIENT SIGNATURE:

NAME: BROWN KEVIN

PHYSICAL THERAPY SIGNATURE:

NAME: HAYDEE GANACE TSANG (PHYSICAL THERAPY)
TITLE: PT
LICENSE: #027166-01

2 Pages via SFTP Tue, 09 Jan 2024 13:54:27 GMT

PATIENT NAME: BROWN KEVIN
DOB: 07/06/1987
AGE: 36
SEX: Male

FACILITY: WAY TO REHAB PT PC
SERVICE LOCATION: 62-69 99th Street, Rego Park NY, 11374
SEEN BY: HAYDEE GANACE TSANG (PHYSICAL THERAPY)
DOA: 10/13/2023

CHIEF COMPLAINT

Patient presented today with the following complaints
Pain in Lower Back is 6 out of 10
Pain in Right Ankle is 2 out of 10

SUBJECTIVE

Slight Improvement in Symptoms

OBJECTIVE

DIAGNOSES:
M54.50 Low back pain, unspecified, M25.571 Pain in right ankle and joints of right foot

OBJECTIVE:
Spasm
Decreased ROM

TREATMENT:
Infrared [97026]
Electrical Stim [97014]
Therapeutic Exercise [97110]
Manual Therapy [97140]

SUPER BILL:
97026 - 2.54,
97014 - 2.66,
97110 - 3.97,
97140 - 4.23

ASSESSMENT

Tolerated Tx. well

PLAN

Continue with current treatment plan

PATIENT SIGNATURE:

NAME: BROWN KEVIN

PHYSICAL THERAPY SIGNATURE:

NAME: HAYDEE GANACE TSANG (PHYSICAL THERAPY)
TITLE: PT
LICENSE: #027166-01

5 Pages via SFTP Mon, 26 Feb 2024 07:48:15 GMT

PATIENT NAME: BROWN KEVIN
DOB: 07/06/1987
AGE: 36
SEX: Male

FACILITY: WAY TO REHAB PT PC
SERVICE LOCATION: 62-69 99th Street, Rego Park NY, 11374
SEEN BY: MOHAMED GALAL ZAYEN (PHYSICAL THERAPY)
DOA: 10/13/2023

CHIEF COMPLAINT

Patient presented today with the following complaints
Pain in Lower Back is 6 out of 10
Pain in Right Ankle is 2 out of 10

SUBJECTIVE

Slight Improvement in Symptoms

OBJECTIVE

DIAGNOSES:
M54.50 Low back pain, unspecified, M25.571 Pain in right ankle and joints of right foot

OBJECTIVE:
Spasm
Decreased ROM

TREATMENT:
Infrared [97026]
Electrical Stim [97014]
Therapeutic Exercise [97110]
Manual Therapy [97140]

SUPER BILL:
97026 - 2.54,
97014 - 2.66,
97110 - 3.97,
97140 - 4.23

ASSESSMENT

Tolerated Tx. well

PLAN

Continue with current treatment plan

PATIENT SIGNATURE:

NAME: BROWN KEVIN

PHYSICAL THERAPY SIGNATURE:

NAME: MOHAMED GALAL ZAYEN (PHYSICAL THERAPY)
TITLE: PT
LICENSE: #041110

2 Pages via SFTP Mon, 26 Feb 2024 07:48:35 GMT

PATIENT NAME: BROWN KEVIN
DOB: 07/06/1987
AGE: 36
SEX: Male

FACILITY: WAY TO REHAB PT PC
SERVICE LOCATION: 62-69 99th Street, Rego Park NY, 11374
SEEN BY: HAYDEE GANACE TSANG (PHYSICAL THERAPY)
DOA: 10/13/2023

CHIEF COMPLAINT

Patient presented today with the following complaints
Pain in Lower Back is 6 out of 10
Pain in Right Ankle is 1 out of 10

SUBJECTIVE

Slight Improvement in Symptoms

OBJECTIVE

DIAGNOSES:
M54.50 Low back pain, unspecified, M25.571 Pain in right ankle and joints of right foot

OBJECTIVE:
Spasm
Decreased ROM

TREATMENT:
Infrared [97026]
Electrical Stim [97014]
Therapeutic Exercise [97110]
Manual Therapy [97140]

SUPER BILL:
97026 - 2.54,
97014 - 2.66,
97110 - 3.97,
97140 - 4.23

ASSESSMENT

Tolerated Tx. well

PLAN

Continue with current treatment plan

PATIENT SIGNATURE:

NAME: BROWN KEVIN

PHYSICAL THERAPY SIGNATURE:

NAME: HAYDEE GANACE TSANG (PHYSICAL THERAPY)
TITLE: PT
LICENSE: #027166-01

5 Pages via SFTP Mon, 26 Feb 2024 07:48:15 GMT

PATIENT NAME: BROWN KEVIN
DOB: 07/06/1987
AGE: 36
SEX: Male

FACILITY: WAY TO REHAB PT PC
SERVICE LOCATION: 62-69 99th Street, Rego Park NY, 11374
SEEN BY: HAYDEE GANACE TSANG (PHYSICAL THERAPY)
DOA: 10/13/2023

CHIEF COMPLAINT

Patient presented today with the following complaints
Pain in Lower Back is 5 out of 10
Pain in Right Ankle is 1 out of 10

SUBJECTIVE

Slight Improvement in Symptoms

OBJECTIVE

DIAGNOSES:
M54.50 Low back pain, unspecified, M25.571 Pain in right ankle and joints of right foot

OBJECTIVE:
Spasm
Decreased ROM

TREATMENT:
Infrared [97026]
Electrical Stim [97014]
Therapeutic Exercise [97110]
Manual Therapy [97140]

SUPER BILL:
97026 - 2.54,
97014 - 2.66,
97110 - 3.97,
97140 - 4.23

ASSESSMENT

Tolerated Tx. well

PLAN

Continue with current treatment plan

PATIENT SIGNATURE:

NAME: BROWN KEVIN

PHYSICAL THERAPY SIGNATURE:

NAME: HAYDEE GANACE TSANG (PHYSICAL THERAPY)
TITLE: PT
LICENSE: #027166-01

5 Pages via SFTP Mon, 26 Feb 2024 07:48:15 GMT

PATIENT NAME: BROWN KEVIN
DOB: 07/06/1987
AGE: 36
SEX: Male

FACILITY: WAY TO REHAB PT PC
SERVICE LOCATION: 62-69 99th Street, Rego Park NY, 11374
SEEN BY: HAYDEE GANACE TSANG (PHYSICAL THERAPY)
DOA: 10/13/2023

CHIEF COMPLAINT

Patient presented today with the following complaints
Pain in Lower Back is 5 out of 10
Pain in Right Ankle is 1 out of 10

SUBJECTIVE

Slight Improvement in Symptoms

OBJECTIVE

DIAGNOSES:
M54.50 Low back pain, unspecified, M25.571 Pain in right ankle and joints of right foot

OBJECTIVE:
Spasm
Decreased ROM

TREATMENT:
Infrared [97026]
Electrical Stim [97014]
Therapeutic Exercise [97110]
Manual Therapy [97140]

SUPER BILL:
97026 - 2.54,
97014 - 2.66,
97110 - 3.97,
97140 - 4.23

ASSESSMENT

Tolerated Tx. well

PLAN

Continue with current treatment plan

PATIENT SIGNATURE:

NAME: BROWN KEVIN

PHYSICAL THERAPY SIGNATURE:

NAME: HAYDEE GANACE TSANG (PHYSICAL THERAPY)
TITLE: PT
LICENSE: #027166-01

4 Pages via SFTP Mon, 05 Feb 2024 07:51:09 GMT

PATIENT NAME: BROWN KEVIN
DOB: 07/06/1987
AGE: 36
SEX: Male

FACILITY: WAY TO REHAB PT PC
SERVICE LOCATION: 62-69 99th Street, Rego Park NY, 11374
SEEN BY: Kathleen Vargas (PHYSICAL THERAPY)
DOA: 10/13/2023

CHIEF COMPLAINT

Patient presented today with the following complaints
Pain in Lower Back is 8 out of 10

SUBJECTIVE

Slight Improvement in Symptoms

OBJECTIVE

DIAGNOSES:
M54.50 Low back pain, unspecified

OBJECTIVE:
Spasm
Decreased ROM

TREATMENT:
Infrared [97026]
Electrical Stim [97014]
Re-Evaluation [97164]
Therapeutic Exercise [97110]
Manual Therapy [97140]

SUPER BILL:
97026 - 2.54,
97014 - 2.66,
97110 - 3.97,
97140 - 4.23,
97164 - 4

ASSESSMENT

Tolerated Tx. well

PLAN

Continue with current treatment plan

PATIENT SIGNATURE:

NAME: BROWN KEVIN

PHYSICAL THERAPY SIGNATURE:

NAME: Kathleen Vargas (PHYSICAL THERAPY)
TITLE: PT
LICENSE: #048699-01

5 Pages via SFTP Mon, 05 Feb 2024 07:51:01 GMT

PATIENT NAME: BROWN KEVIN
DOB: 07/06/1987
AGE: 36
SEX: Male

FACILITY: WAY TO REHAB PT PC
SERVICE LOCATION: 62-69 99th Street, Rego Park NY, 11374
SEEN BY: HAYDEE GANACE TSANG (PHYSICAL THERAPY)
DOA: 10/13/2023

CHIEF COMPLAINT

Patient presented today with the following complaints
Pain in Lower Back is 8 out of 10

SUBJECTIVE

Slight Improvement in Symptoms

OBJECTIVE

DIAGNOSES:
M54.50 Low back pain, unspecified

OBJECTIVE:
Spasm
Decreased ROM

TREATMENT:
Infrared [97026]
Electrical Stim [97014]
Therapeutic Exercise [97110]
Manual Therapy [97140]

SUPER BILL:
97026 - 2.54,
97014 - 2.66,
97110 - 3.97,
97140 - 4.23

ASSESSMENT

Tolerated Tx. well

PLAN

Continue with current treatment plan

PATIENT SIGNATURE:

NAME: BROWN KEVIN

PHYSICAL THERAPY SIGNATURE:

NAME: HAYDEE GANACE TSANG (PHYSICAL THERAPY)
TITLE: PT
LICENSE: #027166-01

4 Pages via SFTP Mon, 05 Feb 2024 07:51:09 GMT

PATIENT NAME: BROWN KEVIN
DOB: 07/06/1987
AGE: 36
SEX: Male

FACILITY: WAY TO REHAB PT PC
SERVICE LOCATION: 62-69 99th Street, Rego Park NY, 11374
SEEN BY: Kathleen Vargas (PHYSICAL THERAPY)
DOA: 10/13/2023

CHIEF COMPLAINT

Patient presented today with the following complaints
Pain in Lower Back is 8 out of 10

SUBJECTIVE

Slight Improvement in Symptoms

OBJECTIVE

DIAGNOSES:
M54.50 Low back pain, unspecified

OBJECTIVE:
Spasm
Decreased ROM

TREATMENT:
Infrared [97026]
Electrical Stim [97014]
Therapeutic Exercise [97110]
Massage [97124]

SUPER BILL:
97026 - 2.54,
97014 - 2.66,
97110 - 3.97,
97124 - 2.62

ASSESSMENT

Tolerated Tx. well

PLAN

Continue with current treatment plan

PATIENT SIGNATURE:

NAME: BROWN KEVIN

PHYSICAL THERAPY SIGNATURE:

NAME: Kathleen Vargas (PHYSICAL THERAPY)
TITLE: PT
LICENSE: #048699-01

2 Pages via SFTP Mon, 05 Feb 2024 07:50:42 GMT

PATIENT NAME: BROWN KEVIN
DOB: 07/06/1987
AGE: 36
SEX: Male

FACILITY: WAY TO REHAB PT PC
SERVICE LOCATION: 62-69 99th Street, Rego Park NY, 11374
SEEN BY: HAYDEE GANACE TSANG (PHYSICAL THERAPY)
DOA: 10/13/2023

CHIEF COMPLAINT

Patient presented today with the following complaints
Pain in Lower Back is 8 out of 10

SUBJECTIVE

Exacerbation of Symptoms

OBJECTIVE

DIAGNOSES:
M54.50 Low back pain, unspecified

OBJECTIVE:
Spasm
Decreased ROM

TREATMENT:
Infrared [97026]
Electrical Stim [97014]
Therapeutic Exercise [97110]
Massage [97124]

SUPER BILL:
97026 - 2.54,
97014 - 2.66,
97110 - 3.97,
97124 - 2.62

ASSESSMENT

Tolerated Tx. well

PLAN

Continue with current treatment plan

PATIENT SIGNATURE:

NAME: BROWN KEVIN

PHYSICAL THERAPY SIGNATURE:

NAME: HAYDEE GANACE TSANG (PHYSICAL THERAPY)
TITLE: PT
LICENSE: #027166-01

5 Pages via SFTP Fri, 16 Feb 2024 13:48:16 GMT

PATIENT NAME: BROWN KEVIN
DOB: 07/06/1987
AGE: 36
SEX: Male

FACILITY: WAY TO REHAB PT PC
SERVICE LOCATION: 62-69 99th Street, Rego Park NY, 11374
SEEN BY: HAYDEE GANACE TSANG (PHYSICAL THERAPY)
DOA: 10/13/2023

CHIEF COMPLAINT

Patient presented today with the following complaints
Pain in Lower Back is 8 out of 10

SUBJECTIVE

Exacerbation of Symptoms

OBJECTIVE

DIAGNOSES:
M54.50 Low back pain, unspecified

OBJECTIVE:
Spasm
Decreased ROM

TREATMENT:
Infrared [97026]
Electrical Stim [97014]
Therapeutic Exercise [97110]
Massage [97124]

SUPER BILL:
97026 - 2.54,
97014 - 2.66,
97110 - 3.97,
97124 - 2.62

ASSESSMENT

Tolerated Tx. well

PLAN

Continue with current treatment plan

PATIENT SIGNATURE:

NAME: BROWN KEVIN

PHYSICAL THERAPY SIGNATURE:

NAME: HAYDEE GANACE TSANG (PHYSICAL THERAPY)
TITLE: PT
LICENSE: #027166-01

5 Pages via SFTP Fri, 16 Feb 2024 13:48:16 GMT

PATIENT NAME: BROWN KEVIN
DOB: 07/06/1987
AGE: 36
SEX: Male

FACILITY: WAY TO REHAB PT PC
SERVICE LOCATION: 62-69 99th Street, Rego Park NY, 11374
SEEN BY: Kathleen Vargas (PHYSICAL THERAPY)
DOA: 10/13/2023

CHIEF COMPLAINT

Patient presented today with the following complaints
Pain in Lower Back is 8 out of 10

SUBJECTIVE

Exacerbation of Symptoms

OBJECTIVE

DIAGNOSES:
M54.50 Low back pain, unspecified

OBJECTIVE:
Spasm
Decreased ROM

TREATMENT:
Infrared [97026]
Electrical Stim [97014]
Therapeutic Exercise [97110]
Massage [97124]

SUPER BILL:
97026 - 2.54,
97014 - 2.66,
97110 - 3.97,
97124 - 2.62

ASSESSMENT

Tolerated Tx. well

PLAN

Continue with current treatment plan

PATIENT SIGNATURE:

NAME: BROWN KEVIN

PHYSICAL THERAPY SIGNATURE:

NAME: Kathleen Vargas (PHYSICAL THERAPY)
TITLE: PT
LICENSE: #048699-01

4 Pages via SFTP Fri, 16 Feb 2024 13:48:46 GMT

PATIENT NAME: BROWN KEVIN
DOB: 07/06/1987
AGE: 36
SEX: Male

FACILITY: WAY TO REHAB PT PC
SERVICE LOCATION: 62-69 99th Street, Rego Park NY, 11374
SEEN BY: HAYDEE GANACE TSANG (PHYSICAL THERAPY)
DOA: 10/13/2023

CHIEF COMPLAINT

Patient presented today with the following complaints
Pain in Lower Back is 7 out of 10

SUBJECTIVE

Slight Improvement in Symptoms

OBJECTIVE

DIAGNOSES:
M54.50 Low back pain, unspecified

OBJECTIVE:
Spasm
Decreased ROM

TREATMENT:
Infrared [97026]
Electrical Stim [97014]
Therapeutic Exercise [97110]
Massage [97124]

SUPER BILL:
97026 - 2.54,
97014 - 2.66,
97110 - 3.97,
97124 - 2.62

ASSESSMENT

Tolerated Tx. well

PLAN

Continue with current treatment plan

PATIENT SIGNATURE:

NAME: BROWN KEVIN

PHYSICAL THERAPY SIGNATURE:

NAME: HAYDEE GANACE TSANG (PHYSICAL THERAPY)
TITLE: PT
LICENSE: #027166-01

5 Pages via SFTP Fri, 16 Feb 2024 13:48:16 GMT

PATIENT NAME: BROWN KEVIN
DOB: 07/06/1987
AGE: 36
SEX: Male

FACILITY: WAY TO REHAB PT PC
SERVICE LOCATION: 62-69 99th Street, Rego Park NY, 11374
SEEN BY: Kathleen Vargas (PHYSICAL THERAPY)
DOA: 10/13/2023

CHIEF COMPLAINT

Patient presented today with the following complaints
Pain in Lower Back is 7 out of 10

SUBJECTIVE

Slight Improvement in Symptoms

OBJECTIVE

DIAGNOSES:
M54.50 Low back pain, unspecified

OBJECTIVE:
Spasm
Decreased ROM

TREATMENT:
Infrared [97026]
Electrical Stim [97014]
Therapeutic Exercise [97110]
Massage [97124]

SUPER BILL:
97026 - 2.54,
97014 - 2.66,
97110 - 3.97,
97124 - 2.62

ASSESSMENT

Tolerated Tx. well

PLAN

Continue with current treatment plan

PATIENT SIGNATURE:

NAME: BROWN KEVIN

PHYSICAL THERAPY SIGNATURE:

NAME: Kathleen Vargas (PHYSICAL THERAPY)
TITLE: PT
LICENSE: #048699-01

4 Pages via SFTP Fri, 16 Feb 2024 13:48:46 GMT

PATIENT NAME: BROWN KEVIN
DOB: 07/06/1987
AGE: 36
SEX: Male

FACILITY: WAY TO REHAB PT PC
SERVICE LOCATION: 62-69 99th Street, Rego Park NY, 11374
SEEN BY: HAYDEE GANACE TSANG (PHYSICAL THERAPY)
DOA: 10/13/2023

CHIEF COMPLAINT

Patient presented today with the following complaints
Pain in Lower Back is 7 out of 10

SUBJECTIVE

Slight Improvement in Symptoms

OBJECTIVE

DIAGNOSES:
M54.50 Low back pain, unspecified

OBJECTIVE:
Spasm
Decreased ROM

TREATMENT:
Infrared [97026]
Electrical Stim [97014]
Therapeutic Exercise [97110]
Massage [97124]

SUPER BILL:
97026 - 2.54,
97014 - 2.66,
97110 - 3.97,
97124 - 2.62

ASSESSMENT

Tolerated Tx. well

PLAN

Continue with current treatment plan

PATIENT SIGNATURE:

PHYSICAL THERAPY SIGNATURE:

NAME: BROWN KEVIN

NAME: HAYDEE GANACE TSANG (PHYSICAL THERAPY)
TITLE: PT
LICENSE: #027166-01

7 Pages via SFTP Fri, 01 Mar 2024 07:48:36 GMT

PATIENT NAME: BROWN KEVIN
DOB: 07/06/1987
AGE: 36
SEX: Male

FACILITY: WAY TO REHAB PT PC
SERVICE LOCATION: 62-69 99th Street, Rego Park NY, 11374
SEEN BY: HAYDEE GANACE TSANG (PHYSICAL THERAPY)
DOA: 10/13/2023

CHIEF COMPLAINT

Patient presented today with the following complaints
Pain in Lower Back is 7 out of 10

SUBJECTIVE

Slight Improvement in Symptoms

OBJECTIVE

DIAGNOSES:
M54.50 Low back pain, unspecified

OBJECTIVE:
Spasm
Decreased ROM

TREATMENT:
Infrared [97026]
Electrical Stim [97014]
Therapeutic Exercise [97110]
Massage [97124]

SUPER BILL:
97026 - 2.54,
97014 - 2.66,
97110 - 3.97,
97124 - 2.62

ASSESSMENT

Tolerated Tx. well

PLAN

Continue with current treatment plan

PATIENT SIGNATURE:



NAME: BROWN KEVIN

PHYSICAL THERAPY SIGNATURE:

NAME: HAYDEE GANACE TSANG (PHYSICAL THERAPY)
TITLE: PT
LICENSE: #027166-01

7 Pages via SFTP Fri, 01 Mar 2024 07:48:36 GMT

PATIENT NAME: BROWN KEVIN
DOB: 07/06/1987
AGE: 36
SEX: Male

FACILITY: WAY TO REHAB PT PC
SERVICE LOCATION: 62-69 99th Street, Rego Park NY, 11374
SEEN BY: HAYDEE GANACE TSANG (PHYSICAL THERAPY)
DOA: 10/13/2023

CHIEF COMPLAINT

Patient presented today with the following complaints
Pain in Lower Back is 5 out of 10

SUBJECTIVE

Continued Improvement of Symptoms

OBJECTIVE

DIAGNOSES:
M54.50 Low back pain, unspecified

OBJECTIVE:
Spasm
Decreased ROM

TREATMENT:
Infrared [97026]
Electrical Stim [97014]
Therapeutic Exercise [97110]
Massage [97124]

SUPER BILL:
97026 - 2.54,
97014 - 2.66,
97110 - 3.97,
97124 - 2.62

ASSESSMENT

Tolerated Tx. well

PLAN

Continue with current treatment plan

PATIENT SIGNATURE:

NAME: BROWN KEVIN

PHYSICAL THERAPY SIGNATURE:

NAME: HAYDEE GANACE TSANG (PHYSICAL THERAPY)
TITLE: PT
LICENSE: #027166-01

7 Pages via SFTP Fri, 01 Mar 2024 07:48:36 GMT

PATIENT NAME: BROWN KEVIN
DOB: 07/06/1987
AGE: 36
SEX: Male

FACILITY: WAY TO REHAB PT PC
SERVICE LOCATION: 62-69 99th Street, Rego Park NY, 11374
SEEN BY: HAYDEE GANACE TSANG (PHYSICAL THERAPY)
DOA: 10/13/2023

CHIEF COMPLAINT

Patient presented today with the following complaints
Pain in Lower Back is 5 out of 10

SUBJECTIVE

Continued Improvement of Symptoms

OBJECTIVE

DIAGNOSES:
M54.50 Low back pain, unspecified

OBJECTIVE:
Spasm
Decreased ROM

TREATMENT:
Infrared [97026]
Electrical Stim [97014]
Therapeutic Exercise [97110]
Massage [97124]

SUPER BILL:
97026 - 2.54,
97014 - 2.66,
97110 - 3.97,
97124 - 2.62

ASSESSMENT

Tolerated Tx. well

PLAN

Continue with current treatment plan

PATIENT SIGNATURE:

NAME: BROWN KEVIN

PHYSICAL THERAPY SIGNATURE:

NAME: HAYDEE GANACE TSANG (PHYSICAL THERAPY)
TITLE: PT
LICENSE: #027166-01

7 Pages via SFTP Fri, 01 Mar 2024 07:48:36 GMT

PATIENT NAME: BROWN KEVIN
DOB: 07/06/1987
AGE: 36
SEX: Male

FACILITY: WAY TO REHAB PT PC
SERVICE LOCATION: 62-69 99th Street, Rego Park NY, 11374
SEEN BY: Kathleen Vargas (PHYSICAL THERAPY)
DOA: 10/13/2023

CHIEF COMPLAINT

Patient presented today with the following complaints
Pain in Lower Back is 5 out of 10

SUBJECTIVE

Continued Improvement of Symptoms

OBJECTIVE

DIAGNOSES:
M54.50 Low back pain, unspecified

OBJECTIVE:
Spasm
Decreased ROM

TREATMENT:
Infrared [97026]
Electrical Stim [97014]
Therapeutic Exercise [97110]
Massage [97124]

SUPER BILL:
97026 - 2.54,
97014 - 2.66,
97110 - 3.97,
97124 - 2.62

ASSESSMENT

Tolerated Tx. well

PLAN

Continue with current treatment plan

PATIENT SIGNATURE:

NAME: BROWN KEVIN

PHYSICAL THERAPY SIGNATURE:

NAME: Kathleen Vargas (PHYSICAL THERAPY)
TITLE: PT
LICENSE: #048699-01

2 Pages via SFTP Fri, 01 Mar 2024 07:50:01 GMT

PATIENT NAME: BROWN KEVIN
DOB: 07/06/1987
AGE: 36
SEX: Male

FACILITY: WAY TO REHAB PT PC
SERVICE LOCATION: 62-69 99th Street, Rego Park NY, 11374
SEEN BY: Mohamed Shehab (PHYSICAL THERAPY)
DOA: 10/13/2023

CHIEF COMPLAINT

Patient presented today with the following complaints
Pain in Lower Back is 5 out of 10

SUBJECTIVE

Continued Improvement of Symptoms

OBJECTIVE

DIAGNOSES:
M54.50 Low back pain, unspecified

OBJECTIVE:
Spasm
Decreased ROM

TREATMENT:
Infrared [97026]
Electrical Stim [97014]
Therapeutic Exercise [97110]
Massage [97124]

SUPER BILL:
97026 - 2.54,
97014 - 2.66,
97110 - 3.97,
97124 - 2.62

ASSESSMENT

Tolerated Tx. well

PLAN

Continue with current treatment plan

PATIENT SIGNATURE:

NAME: BROWN KEVIN

PHYSICAL THERAPY SIGNATURE:

NAME: Mohamed Shehab (PHYSICAL THERAPY)
TITLE: PT
LICENSE: #040174

2 Pages via SFTP Mon, 18 Mar 2024 06:52:49 GMT

PATIENT NAME: BROWN KEVIN
DOB: 07/06/1987
AGE: 36
SEX: Male

FACILITY: WAY TO REHAB PT PC
SERVICE LOCATION: 62-69 99th Street, Rego Park NY, 11374
SEEN BY: HAYDEE GANACE TSANG (PHYSICAL THERAPY)
DOA: 10/13/2023

CHIEF COMPLAINT

Patient presented today with the following complaints
Pain in Lower Back is 5 out of 10

SUBJECTIVE

Continued Improvement of Symptoms

OBJECTIVE

DIAGNOSES:
M54.50 Low back pain, unspecified

OBJECTIVE:
Spasm
Decreased ROM

TREATMENT:
Infrared [97026]
Electrical Stim [97014]
Therapeutic Exercise [97110]
Massage [97124]

SUPER BILL:
97026 - 2.54,
97014 - 2.66,
97110 - 3.97,
97124 - 2.62

ASSESSMENT

Tolerated Tx. well

PLAN

Continue with current treatment plan

PATIENT SIGNATURE:

NAME: BROWN KEVIN

PHYSICAL THERAPY SIGNATURE:

NAME: HAYDEE GANACE TSANG (PHYSICAL THERAPY)
TITLE: PT
LICENSE: #027166-01

4 Pages via SFTP Mon, 18 Mar 2024 06:53:01 GMT

PATIENT NAME: BROWN KEVIN
DOB: 07/06/1987
AGE: 36
SEX: Male

FACILITY: WAY TO REHAB PT PC
SERVICE LOCATION: 62-69 99th Street, Rego Park NY, 11374
SEEN BY: HAYDEE GANACE TSANG (PHYSICAL THERAPY)
DOA: 10/13/2023

CHIEF COMPLAINT

Patient presented today with the following complaints
Pain in Lower Back is 6 out of 10

SUBJECTIVE

Exacerbation of Symptoms

OBJECTIVE

DIAGNOSES:
M54.50 Low back pain, unspecified

OBJECTIVE:
Spasm
Decreased ROM

TREATMENT:
Infrared [97026]
Electrical Stim [97014]
Therapeutic Exercise [97110]
Massage [97124]

SUPER BILL:
97026 - 2.54,
97014 - 2.66,
97110 - 3.97,
97124 - 2.62

ASSESSMENT

Tolerated Tx. well

PLAN

Continue with current treatment plan

PATIENT SIGNATURE:

NAME: BROWN KEVIN

PHYSICAL THERAPY SIGNATURE:

NAME: HAYDEE GANACE TSANG (PHYSICAL THERAPY)
TITLE: PT
LICENSE: #027166-01

4 Pages via SFTP Mon, 18 Mar 2024 06:53:01 GMT

PATIENT NAME: BROWN KEVIN
DOB: 07/06/1987
AGE: 36
SEX: Male

FACILITY: WAY TO REHAB PT PC
SERVICE LOCATION: 62-69 99th Street, Rego Park NY, 11374
SEEN BY: Dilshad Bakhtawar (PHYSICAL THERAPY)
DOA: 10/13/2023

CHIEF COMPLAINT

Patient presented today with the following complaints
Pain in Lower Back is 6 out of 10

SUBJECTIVE

Exacerbation of Symptoms

OBJECTIVE

DIAGNOSES:
M54.50 Low back pain, unspecified

OBJECTIVE:
Spasm
Decreased ROM

TREATMENT:
Infrared [97026]
Electrical Stim [97014]
Therapeutic Exercise [97110]
Massage [97124]

SUPER BILL:
97026 - 2.54,
97014 - 2.66,
97110 - 3.97,
97124 - 2.62

ASSESSMENT

Tolerated Tx. well

PLAN

Continue with current treatment plan

PATIENT SIGNATURE:

NAME: BROWN KEVIN

PHYSICAL THERAPY SIGNATURE:

NAME: Dilshad Bakhtawar (PHYSICAL THERAPY)
TITLE: PT
LICENSE: #049766

2 Pages via SFTP Thu, 21 Mar 2024 15:07:13 GMT

PATIENT NAME: BROWN KEVIN
DOB: 07/06/1987
AGE: 36
SEX: Male

FACILITY: WAY TO REHAB PT PC
SERVICE LOCATION: 62-69 99th Street, Rego Park NY, 11374
SEEN BY: HAYDEE GANACE TSANG (PHYSICAL THERAPY)
DOA: 10/13/2023

CHIEF COMPLAINT

Patient presented today with the following complaints
Pain in Lower Back is 6 out of 10

SUBJECTIVE

Exacerbation of Symptoms

OBJECTIVE

DIAGNOSES:
M54.50 Low back pain, unspecified

OBJECTIVE:
Spasm
Decreased ROM

TREATMENT:
Infrared [97026]
Electrical Stim [97014]
Therapeutic Exercise [97110]
Massage [97124]

SUPER BILL:
97026 - 2.54,
97014 - 2.66,
97110 - 3.97,
97124 - 2.62

ASSESSMENT

Tolerated Tx. well

PLAN

Continue with current treatment plan

PATIENT SIGNATURE:

NAME: BROWN KEVIN

PHYSICAL THERAPY SIGNATURE:

NAME: HAYDEE GANACE TSANG (PHYSICAL THERAPY)
TITLE: PT
LICENSE: #027166-01

4 Pages via SFTP Fri, 29 Mar 2024 12:54:19 GMT

PATIENT NAME: BROWN KEVIN
DOB: 07/06/1987
AGE: 36
SEX: Male

FACILITY: WAY TO REHAB PT PC
SERVICE LOCATION: 62-69 99th Street, Rego Park NY, 11374
SEEN BY: Dilshad Bakhtawar (PHYSICAL THERAPY)
DOA: 10/13/2023

CHIEF COMPLAINT

Patient presented today with the following complaints
Pain in Lower Back is 6 out of 10

SUBJECTIVE

Exacerbation of Symptoms

OBJECTIVE

DIAGNOSES:
M54.50 Low back pain, unspecified

OBJECTIVE:
Spasm
Decreased ROM

TREATMENT:
Infrared [97026]
Electrical Stim [97014]
Therapeutic Exercise [97110]
Massage [97124]

SUPER BILL:
97026 - 2.54,
97014 - 2.66,
97110 - 3.97,
97124 - 2.62

ASSESSMENT

Tolerated Tx. well

PLAN

Continue with current treatment plan

PATIENT SIGNATURE:

NAME: BROWN KEVIN

PHYSICAL THERAPY SIGNATURE:

NAME: Dilshad Bakhtawar (PHYSICAL THERAPY)
TITLE: PT
LICENSE: #049766

4 Pages via SFTP Fri, 29 Mar 2024 12:54:00 GMT

PATIENT NAME: BROWN KEVIN
DOB: 07/06/1987
AGE: 36
SEX: Male

FACILITY: WAY TO REHAB PT PC
SERVICE LOCATION: 62-69 99th Street, Rego Park NY, 11374
SEEN BY: HAYDEE GANACE TSANG (PHYSICAL THERAPY)
DOA: 10/13/2023

CHIEF COMPLAINT

Patient presented today with the following complaints
Pain in Lower Back is 6 out of 10

SUBJECTIVE

Exacerbation of Symptoms

OBJECTIVE

DIAGNOSES:
M54.50 Low back pain, unspecified

OBJECTIVE:
Spasm
Decreased ROM

TREATMENT:
Infrared [97026]
Electrical Stim [97014]
Therapeutic Exercise [97110]
Massage [97124]

SUPER BILL:
97026 - 2.54,
97014 - 2.66,
97110 - 3.97,
97124 - 2.62

ASSESSMENT

Tolerated Tx. well

PLAN

Continue with current treatment plan

PATIENT SIGNATURE:

NAME: BROWN KEVIN

PHYSICAL THERAPY SIGNATURE:

NAME: HAYDEE GANACE TSANG (PHYSICAL THERAPY)
TITLE: PT
LICENSE: #027166-01

4 Pages via SFTP Fri, 29 Mar 2024 12:54:19 GMT

PATIENT NAME: BROWN KEVIN
DOB: 07/06/1987
AGE: 36
SEX: Male

FACILITY: WAY TO REHAB PT PC
SERVICE LOCATION: 62-69 99th Street, Rego Park NY, 11374
SEEN BY: Dilshad Bakhtawar (PHYSICAL THERAPY)
DOA: 10/13/2023

CHIEF COMPLAINT

Patient presented today with the following complaints
Pain in Lower Back is 6 out of 10

SUBJECTIVE

Exacerbation of Symptoms

OBJECTIVE

DIAGNOSES:
M54.50 Low back pain, unspecified

OBJECTIVE:
Spasm
Decreased ROM

TREATMENT:
Infrared [97026]
Electrical Stim [97014]
Therapeutic Exercise [97110]
Massage [97124]

SUPER BILL:
97026 - 2.54,
97014 - 2.66,
97110 - 3.97,
97124 - 2.62

ASSESSMENT

Tolerated Tx. well

PLAN

Continue with current treatment plan

PATIENT SIGNATURE:

NAME: BROWN KEVIN

PHYSICAL THERAPY SIGNATURE:

NAME: Dilshad Bakhtawar (PHYSICAL THERAPY)
TITLE: PT
LICENSE: #049766

4 Pages via SFTP Fri, 29 Mar 2024 12:54:00 GMT

PATIENT CONSULTATION & HISTORY

LAST NAME Brown FIRST NAME Kevin DOA 10/13/23
CONSULTATION EXAM DATE 10/16/23 DOB 7/6/87 AUTO
MALE / FEMALE AGE HEIGHT 6'0" WEIGHT 160 WORK
RESPIRATION BP OTHER

HISTORY OF PRESENT COMPLAINT(S):

Motor Vehicle Accident? Yes / No If Yes, Patient was: Driver / Pedestrian / Passenger: front / rear - left / right
Vehicle was struck from: Left / Right / Front / Rear Seatbelt? Yes / No / NA
Vehicle struck:
Patient description of accident: R45. Vehicle was rear-ended while in motion
Patient's Head & Torso Whipped in various directions: Yes / No
Patient Struck: head Against: seatbelt
Other:
Loss of Consciousness: Yes / No If Yes, was: Brief / Extended
Patient Experienced: Immediately thereafter / Later that day / Next day :
Shock / Nervousness / Dizziness / Nausea / Vomitting / Disorientation / Confusion / Headache / Sleep
Complaint(s) of Pain: Head / Face / Jaw / Neck / L or R Shoulder / L or R Upper Arm / L or R Fore Arm / Upper Back / Lower Back /
L or R Hip / L or R Thigh / L or R Knee / L or R Leg / L or R Ankle / L or R Foot / L or R Hand /
L or R Wrist / L or R Elbow / Other (write in):
Patient Injury a result of Accident at Work (WC)? Yes / No
Patient's Injury(s) resulted from:
Location & Time of Injury:
Report made to Supervisor? Yes / No Name: Phone #:
Company Name: Company Address:
After the incident/injury Patient:
Went home to rest
Went to ER
Ambulance Taken
If yes, any Home Therapy?
If Yes, what Hospital?
Treament received: Physical Exam / X-Ray / Neck, Back or Knee Brace / Sling / Cane / Crutches / Medication / Other:

CHIEF PRESENT COMPLAINT(S):

LOCATION	PAIN SEVERITY (0 - 10)	PAIN DURATION	PAIN QUALITY
HEAD	Severe / Moderate / Mild	Constant / Frequent	Sharp / Stabbing / Shooting / Throbbing / Burning / Aching / Stiff
FACE	Severe / Moderate / Mild	Constant / Frequent	Sharp / Stabbing / Shooting / Throbbing / Burning / Aching / Stiff
JAW	Severe / Moderate / Mild	Constant / Frequent	Sharp / Stabbing / Shooting / Throbbing / Burning / Aching / Stiff
NECK	Severe / Moderate / Mild	Constant / Frequent	Sharp / Stabbing / Shooting / Throbbing / Burning / Aching / Stiff
UPPER BACK	Severe / Moderate / Mild	Constant / Frequent	Sharp / Stabbing / Shooting / Throbbing / Burning / Aching / Stiff
LOWER BACK	Severe / Moderate / Mild	Constant / Frequent	Sharp / Stabbing / Shooting / Throbbing / Burning / Aching / Stiff
PELVIS	Severe / Moderate / Mild	Constant / Frequent	Sharp / Stabbing / Shooting / Throbbing / Burning / Aching / Stiff
L / R SHOULDER	Severe / Moderate / Mild	Constant / Frequent	Sharp / Stabbing / Shooting / Throbbing / Burning / Aching / Stiff
L / R UPR. ARM	Severe / Moderate / Mild	Constant / Frequent	Sharp / Stabbing / Shooting / Throbbing / Burning / Aching / Stiff
L / R FORE ARM	Severe / Moderate / Mild	Constant / Frequent	Sharp / Stabbing / Shooting / Throbbing / Burning / Aching / Stiff
L / R ELBOW	Severe / Moderate / Mild	Constant / Frequent	Sharp / Stabbing / Shooting / Throbbing / Burning / Aching / Stiff
L / R WRIST	Severe / Moderate / Mild	Constant / Frequent	Sharp / Stabbing / Shooting / Throbbing / Burning / Aching / Stiff
L / R HAND	Severe / Moderate / Mild	Constant / Frequent	Sharp / Stabbing / Shooting / Throbbing / Burning / Aching / Stiff
L / R HIP	Severe / Moderate / Mild	Constant / Frequent	Sharp / Stabbing / Shooting / Throbbing / Burning / Aching / Stiff
L / R THIGH	Severe / Moderate / Mild	Constant / Frequent	Sharp / Stabbing / Shooting / Throbbing / Burning / Aching / Stiff
L / R KNEE	Severe / Moderate / Mild	Constant / Frequent	Sharp / Stabbing / Shooting / Throbbing / Burning / Aching / Stiff
L / R LEG	Severe / Moderate / Mild	Constant / Frequent	Sharp / Stabbing / Shooting / Throbbing / Burning / Aching / Stiff
L / R ANKLE	Severe / Moderate / Mild	Constant / Frequent	Sharp / Stabbing / Shooting / Throbbing / Burning / Aching / Stiff
L / R FOOT	Severe / Moderate / Mild	Constant / Frequent	Sharp / Stabbing / Shooting / Throbbing / Burning / Aching / Stiff

Provocative Factors:
Standing
Sitting
Bending
Walking
Lifting
Lying Down
Exercising
Working

Palliative Factors:
Rest
Heat
Ice
Painkillers
Stretching
Other

Pain is worse in the:
Morning
Midday
Evening
Night
Always

Patient complains of associated: Radiation / Referred Pain / Stiffness / Paresthesia - Down to the:
L / R SHOULDER
L / R UPPER ARM
L / R ELBOW
L / R FOREARM
L / R WRIST
L / R HAND
L / R THIGH
L / R KNEE
L / R LEG
L / R ANKLE
L / R FOOT
L / R HIP
PELVIS

PAST MEDICAL HISTORY:

Patient denies any significant/related past personal medical history? Yes / No

Past Medical History of: MVA / TRAUMA / OTHER:

Date of Occurence(s): TX: Response to TX:

X-Ray / MRI / CT Results: Permanent Disability? Yes / No

Hospitalization / Illness:

Surgery(s):

Current Medications Yes / No If Yes, list:

Allergies Yes / No If Yes, list:

PAST FAMILY MEDICAL HISTORY:

Patient denies any significant/related past personal medical history? Yes / No

Past Family Medical History of: Cancer / Cardiac / HTN / Diabetes / CVA / Other:

PATIENT PROFILE:

Since accident/injury performing daily routine activities of living have been:

Impossible
Very Difficult
Difficult
Unaffected

EMERGENCY CONTACT:
NAME(s):
PHONE #s:
RELATIONSHIP:

Status:

Retired
Unemployed
Student
Employed As: Instructor Delivery
To work/school since injury?

Prior to accident Patient claims their General Health was:
Excellent / Very Good / Good / Fair / Poor
Comments:

Daily work activities involve: Sitting / Standing / Bending / Walking / Reaching / Lifting / Stooping / Climbing / Driving / Operating Machinery / Other:

Quality of Life - Difficulties: Bathing / Dressing / Cooking / Picking up Child / Carrying Child / Playing with Child / Shopping / Cleaning / Laundry / Taking out the Garbage / Negotiating Steps / Reaching Overhead / Bending / Driving / Relations / Sleep / Other:

PHYSICAL EXAMINATION:

General Appearance:

Patient appears to be: Well Nourished / Malnourished / Alert / Disoriented / Normally Developed / Under Developed
Comments:

Patient enters room with: Normal Gait / Abnormal Gait / Limp / Use of Assistive Device / Visible Scars / Cast / Sling / Contusions / Abrasions / Bandages / Visible Swelling / Cervical Collar / Other:

Distress/Discomfort Level:	Severe	Moderate	Mild	None
Pain Level:	Severe	Moderate	Mild	None

Posture:

Spinal curvatures grossly within normal limits
Inc / Dec Thoracic Kyphosis
Evidence of Scoliosis
Leg Deficiency L / R

Inc / Dec Cervical Lordosis
Inc / Dec Lumbar Lordosis
High Shoulder L / R
Muscle Hypertonicity:

Adam's Position
Head Tilt L / R
High Ilium L / R

Head & Neck:

Normocephalic
Thyroid Abnormality
Other:

PERRLA
Ear Canals Clear

Sclera / Conjunctiva Clear
Trachea Midline

Abdomen:

Not Performed / Deferred
Abnormalities of the Abdomen:
Referred to MD / Internist / Other:

Negative for masses, swelling, ascites, tenderness and lateralized aortic pulse

CERVICAL SPINE (Active Range of Motion):

	Normal	Degree	Pain (Ache/Dull/Sharp)	Throughout Motion	End of Motion
Flexion	60	60	N		
Extension	75	75			
RL Flexion	45	45			
LL Flexion	45	45			
R Rotation	80	80			
L Rotation	80	80			

Soft Tissue Palpation:

[ ] Revealed no Tenderness, Edema or Hypertonicity

[ ] Apprehension / Guarding of the Cervical Spine

[✓] Revealed Grade: I / II / III / IV Tenderness and Hypertonicity of the:

Posterior Cervical Paraspinals: [✓] *Trapezius:* [ ] *Levator Scapulae:* [ ]
Sternocleidomastoid: [✓] *Suboccipital:* [ ] *Supraspinatus:* [ ]
Rhomboid: [ ] *Infraspinatus:* [ ]

Static & Motion Palpation:

[ ] Revealed no evidence of Fixation, Restriction, Biomechanical Dysfunction or Pain

[ ] Revealed:

Painful Joint Motion: [ ] *Crepitus:* [ ] *Myospasm:* [ ] *Torticollis:* [ ]
Dyskinesia: [ ] *Stiffness:* [✓]

[✓] Revealed Fixation, Restriction, Biomechanical Dysfunction and/or Pain at the following vertebral levels:
OCC / C1 / C2 / C3 / C4 / C5 / C6 / C7

Orthopedic Testing:

Test	Finding	Location
Foraminal Compression	Negative / Positive	Left / Right / Bilateral
Jackson's Compression	Negative / Positive	Left / Right / Bilateral
Cervical Distraction	Negative / Positive	Left / Right / Bilateral
Shoulder Depression	Negative / Positive	Left / Right / Bilateral
Spurling's Maneuver	Negative / Positive	Left / Right / Bilateral
TMJ Dysfunction	Negative / Positive	Left / Right / Bilateral

Other:

SHOULDER (Active Range of Motion):

	Normal	Degree	Pain (Ache/Dull/Sharp)	Throughout Motion	End of Motion
Flexion	180				
Extension	45				
Abduction	180				
Adduction	45				
Internal Rot.	55				
External Rot.	45				

Orthopedic Testing:

Test	Finding	Location
Impingement Sign	Negative / Positive	Left / Right / Bilateral
Speed's Test	Negative / Positive	Left / Right / Bilateral

Other:

THORACIC SPINE:
Soft Tissue Palpation:

[ ] Revealed no Tenderness or Hypertonicity

Revealed:

Antaglia/Guarding [ ] *Radicular Chest Pain* [ ]
Breathing Pain [ ] *Shortness of Breath* [ ]

ECN: 2023110200905 Received Date: 2023-10-31

Revealed Grade: I / II / III / IV Tenderness and Hypertonicity of the:

Paraspinal Musculature: ✓ *Lower Trapezius:* *Latissimus Dorsi:*

Other:

Static & Motion Palpation:

☐ Revealed no evidence of Fixation, Restriction, Biomechanical Dysfunction or Pain

✓ Revealed Fixation, Restriction, Biomechanical Dysfunction and/or Pain at the following vertebral levels:
T1 / T2 / T3 / T4 / T5 / T6 / T7 / T8 / T9 / T10 / T11 / T12

Orthopedic/Special Tests:

LUMBAR SPINE (Active Range of Motion):

	Normal	Degree	Pain (Ache/Dull/Sharp)	Throughout Motion	End of Motion
Flexion	90	65	S	✓	✓
Extension	30	30	N		
RL Flexion	30	30	N		
LL Flexion	30	30	S	✓	✓
R Rotation	30	30	N		
L Rotation	30	30	S	✓	✓

Soft Tissue Palpation:

✓ Revealed no Tenderness, Edema or Hypertonicity

Revealed Grade: I / II / III / IV Tenderness and Hypertonicity of the:

✓ Apprehension / Guarding of the Lumbar Spine

Lumbar Paraspinals: *Piriformis* *Piriformis* *Gluteals* *Quadratus Lumborum* *Lumbar Erector Spinae* ✓

Static & Motion Palpation:

✓ Revealed NO evidence of Fixation, Restriction, Biomechanical Dysfunction or Pain

Revealed Fixation, Restriction, Biomechanical Dysfunction and/or Pain at the following vertebral levels:
L1 / L2 / L3 / L4 / L5 / Sac / Lt. SI / Rt. SI

Orthopedic Testing:

Test	Finding	Location	Observations
Kemp's Maneuver	Negative / Positive	Left / Right / Bilateral	
Lasegue's / SLR	Negative / Positive	Left / Right / Bilateral @ 20	
Braggard's Maneuver	Negative / Positive	Left / Right / Bilateral @	
Ely's	Negative / Positive	Left / Right / Bilateral	
Nachlas	Negative / Positive	Left / Right / Bilateral	
Gaenslens	Negative / Positive	Left / Right / Bilateral	
P. Faber	Negative / Positive	Left / Right / Bilateral	
Valsava / Dejarine's Triad	Negative / Positive	Left / Right / Bilateral	

HIP (Active Range of Motion):

	Normal	Degree	Pain (Ache/Dull/Sharp)	Throughout Motion	End of Motion
Flexion	120				
Extension	30				
Abduction	50				
Adduction	30				
Internal Rot.	35				
External Rot.	45				

Orthopedic Testing:

Test	Finding	Location
Thomas Test	Negative / Positive	Left / Right / Bilateral
Hibb's Test	Negative / Positive	Left / Right / Bilateral

Other:

Toe Walking: *Normal* ✓ *Difficult* *Unable*
Heel Walking: *Normal* ✓ *Difficult* *Unable*
Other:

ECN: 2023110200905 Received Date: 2023-10-31

NEUROLOGIC

CRANIAL NERVES:

☐ Cranial nerve I-XII were grossly intact and bilaterally equally reactive with no apparent deformities.
☐ Gross Abnormalities of the Cranial nerves: _____

MOTOR:

☐ Motor testing of the upper and lower extremities revealed normal musculature of equal strength bilaterally.
☐ Abnormalities: _____

PAIN SENSATION:

☐ Examination of the extremity dermatomes with Wartenberg wheel showed pain sensation to be intact.
☐ Abnormalities: _____

DEEP TENDON REFLEXES:

C5	0: Absent Reflex	1+: Trace	2+: Normal	3+: Brisk	4+: non-sustained clonus	5+: sustained clonus
C6	0: Absent Reflex	1+: Trace	2+: Normal	3+: Brisk	4+: non-sustained clonus	5+: sustained clonus
C7	0: Absent Reflex	1+: Trace	2+: Normal	3+: Brisk	4+: non-sustained clonus	5+: sustained clonus
C8	0: Absent Reflex	1+: Trace	2+: Normal	3+: Brisk	4+: non-sustained clonus	5+: sustained clonus
T1	0: Absent Reflex	1+: Trace	2+: Normal	3+: Brisk	4+: non-sustained clonus	5+: sustained clonus
L4	0: Absent Reflex	1+: Trace	2+: Normal	3+: Brisk	4+: non-sustained clonus	5+: sustained clonus
L5	0: Absent Reflex	1+: Trace	2+: Normal	3+: Brisk	4+: non-sustained clonus	5+: sustained clonus
S1	0: Absent Reflex	1+: Trace	2+: Normal	3+: Brisk	4+: non-sustained clonus	5+: sustained clonus

MUSCLE TESTING (0 = None; 1 = Trace; 2 = Poor; 3 = Fair; 4 = Good; 5 = Normal):

Biceps (C5 / C6)	L 5/5	R 5/5	Patellar (L4)	L 5/5	R 4/5
Brachioradialis	L 5/5	R 5/5	Hamstring (L5)	L 5/5	R 5/5
Triceps (C7)	L 5/5	R 5/5	Achilles (S1)	L 5/5	R 5/5

CENTRAL NERVOUS SYSTEM:

Romberg's test showed:

No Body Sway ☐ *Some Body Sway* ☐ *Considerable Body Sway* ☐

☐ *Babinski Sign, finger-to-finger and finger-to-nose tests were normal / abnormal.*

Abnormal findings of the Central Nervous System: _____

DIAGNOSTIC IMPRESSION / INITIAL CLINICAL DIAGNOSIS

HEAD - JAW:

☐ *M26.69 TMJ Disorder*
☐ *G44.209 Tension Headache*
☐ *G43.909 Migraine*
☐ *R42 Dizziness*
☐ *R11.2 Nausea / Vomiting*

CERVICAL:

☐ *M50.20 Cer. Interverebral Disc displacement w/o myelopathy*
☐ *M50.30 Cer. Disc Degeneration*
☐ *M99.01 Cervical Segmental Dysf.*
☐ *M54.2 Cervicalgia*
☐ *S13.4XXA Cervcial Strain/Sprain Whiplash IE*
☐ *M50.00 Cer. Interverebral Disc displacement with myelopathy*
☐ *M43.6 Torticollis*
☐ *M47.812 Cervical Spondylosis w/o myelopathy*
☐ *M47.12 Cervical Spondylosis with myelopathy*
☐ *M53.0 Cer. Cranial Syndrome*
☐ *M53.1 Cer. Brachial Syndrome*
☐ *T14.90 Cervical Strain /Sprain*

THORACIC:

☐ *M99.02 Thorac. Segmental Dysf.*
☐ *S23.9XXA Thoracic Strain/Sprain*
☐ *G54.0 Thoracic Outlet Syndrome*
☐ *S23.41XA Rib Sprain/Strain*
☐ *M54.6 Thoracic Pain*
☐ *722.11 Disc hern/rupture*
☐ *353.0 Thoracic Outlet Syndrome*
☐ *715.9 Osteoarthritis*
☐ *724.4 Radiculitis*
☐ *739.2 Subluxation*

LUMBAR:

☐ *M51.90 Lum. Interverebral Disc displacement w/o myelopathy*
☐ *M51.9 Lum. Disc Degeneration*
☐ *M99.03 Lumbar Segmental Dysf.*
☐ *M47.817 Lumbar Spondylosis w/o myelopathy*
☐ *M54.30 Sciatica*
☐ *M54.4 Lumbago*
☐ *M51.9 Lum. Interverebral Disc displacement with myelopathy*
☐ *S33.5XXA Lumbar Strain/Sprain*
☐ *M54.16 Lumbar Radiculopathy*

SACROILLIAC / COCCYX:

☐ *S33.6XXA Sacro. Joint Sprain IE*
☐ *Subluxation, Coccyx*
☐ *S33.6XXA Sacro Joint Sprain IE*

GENERAL DIAGNOSIS:

- [ ] 728.34 Lig. Instability
- [ ] M25.629 Shoulder Joint Pain
- [ ] S40.011A Contusion of the Right Shoulder IE
- [ ] S40.012A Contusion of the Left Shoulder IE
- [ ] R29.898 Other symptoms referable to Shoulder region
- [ ] S60.211A Contusion of the Right Wrist IE
- [ ] S60.212A Contusion of the Left Wrist IE
- [ ] M99.01 Curvature of the spine unspecified
- [ ] S50.01XA Contusion of the Right Elbow IE
- [ ] S50.02XA Contusion of the Left Elbow IE
- [ ] S90.01XA Contusion of the Right Ankle IE
- [ ] S90.02XA Contusion of the Left Ankle IE
- [ ] S80.01XA Contusion of the Right Knee IE
- [ ] S80.02XA Contusion of the Left Knee IE
- [ ] T78.8XXS Late Effects of Injury
- [ ] M24.569 Contra[illegible]re of the Joint Pelvis/Hip [illegible]tion
- [ ] S70.02XAQ Cont[illegible]on of the Left Hip IE
- [ ] S70.01XAQ Cont[illegible]on of the Right Hip IE
- [ ] M99.05 Segment[illegible] Joint dysfunction
- [x] M25.569 Unspec[illegible]d Joint Pain
- [x] M62.89 Muscle S[illegible]asm
- [x] M54.08 Facet Sy[illegible]rome

ASSESSMENT:

Causality:

- [x] There is a direct causal relationship between the given history and presenting symptoms.
- [x] Mechanism described in history is the competent causing factor for current condiiton.

Maximum Medical Improvement / Permanency:

- [ ] No Permanent Impairment
- [ ] Permanent Impairment
- [ ] Patient has not reached MMI status
- [ ] Undetermined Permanent Impairment
- [ ] Temporary Impairment
- [x] Chronicity cannot be ruled out at this time.

PROGNOSIS:

Symptomatic relief expected within:

- [ ] 2 Months
- [ ] 1 Week
- [x] 3 Months
- [ ] 2 Weeks
- [ ] 6 Months
- [ ] [illegible] Month
- [ ] [illegible]ear

MMI expected within:

- [x] 1, 2, 3, 4, 5, 6, 7, 8, 9, 10, 11, 12 month(s)
- [ ] >1 Year

PROGNOSIS is:

- [ ] Poor
- [ ] Fair
- [x] Guarded
- [ ] G[illegible]od

Due to:

- [ ] Pre-exising Conditions
- [ ] Unresolved Ortho Tests
- [ ] History of multiple episodes
- [ ] Degen. Changes/Radiculopathy
- [ ] Unresolved neuro[illegible]gns
- [ ] Possbie Surgical n[illegible]essity

- [ ] Patient is recommended to take leave of work and/or school at this time, until: _____

COMPLICATING FACTORS:

- [ ] Past history / injury
- [ ] Disc herniation / bulge
- [ ] Severe Pain Intensity
- [ ] Radiating arm / leg pain
- [ ] Poor general health / fitness
- [ ] Pre-existing structural pathology/skeletal anomoly
- [ ] More than 1 Week before presenting to Doctor
- [ ] Signs of nerve root encroachment
- [ ] Complicating health condition(s) as noted: _____

PRESCRIBED HOME HEALING AIDES:

- [ ] Cervical collar
- [ ] CTU w/pump
- [ ] SAM unit
- [ ] Lumbosacral support
- [ ] Orthoped. Lumbar seat cushion
- [ ] Paraffin bath
- [ ] Thermophore
- [ ] Massager
- [ ] Sling
- [ ] Wrist support
- [ ] Elbow Brace
- [ ] Knee support

Other: _____

DIAGNOSTIC IMAGING / DIAGNOSTIC TESTING:

- [ ] X-Ray Examination of the: Cervical / Thoracic / Lumbar spine to evaluate for: Fracture / Dislocation / Misalignment, [illegible]c.
- [ ] MRI or CT of the: Cervical / Thoracic / Lumbar spine to rule out herniated nucleus pulposi
- [ ] CT of the head to rule out subdural hematoma
- [ ] EMG / NCV testing of the: Upper / Lower extremities to verify, measure and isolate nerve root dysfunction
- [ ] PFNCS testing to rule out peripheral neuropathy in the small pain fibers in U/L extremities
- [ ] Diagnostic Spinal Ultrasound to determine location and extent of nerve root encroachment / involvement
- [ ] Computerized Range of Motion / Muscle testing to quantify and evaluate impairment

Other: _____

ECN: 2023110200905 Received Date: 2023-10-31

TREATMENT PLAN:

Treament protocol will include, but not necessarily be restricted to the following:

- [x] *Specific Spinal Adjustments at above stated biomechanically dysfunctional levels or until re-evaluation reveals change in treatment course.* 1-2 x a week, for 16 weeks,
- [ ] *Recommendation to decrease strenuous activity until further notice.*
- [ ] *Modified spinal adjustive procedures due to patient and/or nature of condition*
- [ ] *Referral / Consultation for: Neurology / Orthopedist / M.D. / L.M.T. / Pain Management / TMJ Specialist / MUA*

Other:

COMMENTS / OBSERVATIONS:

DOCTOR'S SIGNATURE:

ECN: 2023110200905 Received Date: 2023-10-31

S.O.A.P. Note

PATIENT NAME Kevin Brown DATE 10/16/23

SUBJECTIVE:

Symptoms:	Constant (76-100% of day)	Frequent (51-75% of day)	Intermittent (26-50% of day)	Occasional (1-25% of day)
Sharp	T, L			
Stabbing				
Shooting				(R) LE
Tingling				
Throbbing				
Dull				L-Spine
Numb				

Location:								
	Head	Cervical	Left Shoulder	Right Shoulder	Left Elbow	Right Elbow	Left Wrist	Right Wrist
	R / L Jaw	Thoracic	Left Upper Arm	Right Upper Arm	Left Forearm	Right Forearm	Left Knee	Right Knee
	Rib Cage	Lumbar	Left Hand	Right Hand	Left Thigh	Right Thigh	Left Hip	Right Hip
	Chest	Pelvis	Left Calf	Right Calf	Left Ankle	Right Ankle	Left Foot	Right Foot

Worsens Pain:	Standing	Sitting	Bending	Walking	Lifting	Lying Down	Exercising	Working
	Other (describe):							

Lessens Pain:	Standing	Sitting	Bending	Walking	Lifting	Lying Down	Exercising	Working
	Other (describe):							

OBJECTIVE:

Seg. Dysfunction	Tenderness	Spasm
C0	L / R	L / R
C1	L / R	L / R
C2	L / R	L / R
C3	L / R	L / R
C4	L / R	L / R
C5	L / R	L / R
C6	L / R	L / R
C7	L / R	L / R
T1	L / R	L / R
T2	L / R	L / R
T3	L / R	L / R
T4	L / R	L / R
T5	L / R	L / R
T6	L / R	L / R
T7	L / R	L / R
T8	L / R	L / R
T9	L / R	L / R
T10	L / R	L / R
T11	L / R	L / R
T12	L / R	L / R
L1	L / R	L / R
L2	L / R	L / R
L3	L / R	L / R
L4	L / R	L / R
L5	L / R	L / R
S1	L / R	L / R
SIJT	L / R	L / R

Positive / Negative – Maximum Foraminal Compression on the: Left / Right / Bilateral
& radiating to _____
Positive / Negative – Cervical Compression on the: Left / Right / Bilateral
& radiating to _____
Positive / Negative – Cervical Distraction Test
Positive / Negative – Spurling's Test
Positive / Negative – Shoulder Depression on the: Left / Right / Bilateral
Positive / Negative – Impingement Sign on the: Left / Right / Bilateral
Positive / Negative – Speed's Test on on the: Left / Right / Bilateral
Positive / Negative – Supraspinatus Press Test on on the: Left / Right / Bilateral
Positive / Negative – Soto-Hall Test.
Positive / Negative – Adam's Test
Positive / Negative – Patrick-Fabere on the: Left / Right / Bilateral
Positive / Negative – Kemp's on the: Left / Right / Bilateral
Positive / Negative – Ely's on the: Left / Right / Bilateral
Positive / Negative – Nachlas on the: Left / Right / Bilateral
Positive / Negative – Gaenslen's on the: Left / Right / Bilateral
Positive / Negative – Yeoman's on the: Left / Right / Bilateral
Positive / Negative – SLR at 20 degrees on the right
& radiating to _____
Positive / Negative – SLR at 20 degrees on the left
& radiating to _____
Positive / Negative – Thomas Test on the: Left / Right / Bilateral
Positive / Negative – Hibb's Test on the: Left / Right / Bilateral

ASSESSMENT:

Patient shows:	No Improvement	Some Improvement	Good Improvement	
				No more pain
Prognosis:	Guarded	Unstable	Poor	Fair	Good
				Excellent

Treatment:	Cervical	Thoracic	Lumbar
Heat / Ice	/	/	/
Stim			/
Manual Traction			
US			
MyoRel			
Exercises			
NM Reed	/	/	/
Massage	/	/	/

Notes: LE

Manipulation:	Cervical	Thoracic	Lumbar			
	L / R Shoulder	L / R Hip	Pelvis	Sacrum	Left SI Joint	Right SI Joint

Full Cavitation Partial Cavitation No Cavitation

PLAN:	3x per week	2x per week	1x per week	As Needed	Discontinue Treatment

Provider Signature: R Capelino DC

S.O.A.P. Note

PATIENT NAME Kevin Brown DATE 10/23/23

SUBJECTIVE:

Symptoms:	Constant (76-100% of day)	Frequent (51-75% of day)	Intermittent (26-50% of day)	Occasional (1-25% of day)
Sharp				
Stabbing				
Shooting				
Tingling				
Throbbing				
Dull				C-spine
Numb				

Location:								
	Head	Cervical	Left Shoulder	Right Shoulder	Left Elbow	Right Elbow	Left Wrist	Right Wrist
	R / L Jaw	Thoracic	Left Upper Arm	Right Upper Arm	Left Forearm	Right Forearm	Left Knee	Right Knee
	Rib Cage	Lumbar	Left Hand	Right Hand	Left Thigh	Right Thigh	Left Hip	Right Hip
	Chest	Pelvis	Left Calf	Right Calf	Left Ankle	Right Ankle	Left Foot	Right Foot

Worsens Pain:								
	Standing	Sitting	Bending	Walking	Lifting	Lying Down	Exercising	Working
	Other (describe):							

Lessens Pain:								
	Standing	Sitting	Bending	Walking	Lifting	Lying Down	Exercising	Working
	Other (describe): rest, stretching							

OBJECTIVE:

Seg. Dysfunction	Tenderness	Spasm
C0	L / R	L / R
C1	L / R	L / R
C2	L / R	L / R
C3	L / R	L / R
C4	L / R	L / R
C5	L / R	L / R
C6	L / R	L / R
C7	L / R	L / R
T1	L / R	L / R
T2	L / R	L / R
T3	L / R	L / R
T4	L / R	L / R
T5	L / R	L / R
T6	L / R	L / R
T7	L / R	L / R
T8	L / R	L / R
T9	L / R	L / R
T10	L / R	L / R
T11	L / R	L / R
T12	L / R	L / R
L1	L / R	L / R
L2	L / R	L / R
L3	L / R	L / R
L4	L / R	L / R
L5	L / R	L / R
S1	L / R	L / R
SI JT	L / R	L / R

Positive / Negative – Maximum Foraminal Compression on the: Left / Right / Bilateral
& radiating to _____
Positive / Negative – Cervical Compression on the: Left / Right / Bilateral
& radiating to _____
Positive / Negative – Cervical Distraction Test
Positive / Negative – Spurling's Test
Positive / Negative – Shoulder Depression on the: Left / Right / Bilateral
Positive / Negative – Impingement Sign on the: Left / Right / Bilateral
Positive / Negative – Speed's Test on on the: Left / Right / Bilateral
Positive / Negative – Supraspinatus Press Test on on the: Left / Right / Bilateral
Positive / Negative – Soto-Hall Test.
Positive / Negative – Adam's Test
Positive / Negative – Patrick-Fabere on the: Left / Right / Bilateral
Positive / Negative – Kemp's on the: Left / Right / Bilateral
Positive / Negative – Ely's on the: Left / Right / Bilateral
Positive / Negative – Nachlas on the: Left / Right / Bilateral
Positive / Negative – Gaenslen's on the: Left / Right / Bilateral
Positive / Negative – Yeoman's on the: Left / Right / Bilateral
Positive / Negative – SLR at _____ degrees on the right
& radiating to _____
Positive / Negative – SLR at _____ degrees on the left
& radiating to _____
Positive / Negative – Thomas Test on the: Left / Right / Bilateral
Positive / Negative – Hibb's Test on the: Left / Right / Bilateral

ASSESSMENT:

Patient shows:	No Improvement	Some Improvement	Good Improvement	
				No more pain
Prognosis:	Guarded	Unstable	Poor	Fair / Good / Excellent

Treatment:	Cervical	Thoracic	Lumbar
Heat / Ice			
Stim			
Manual Traction			
US			
MyoRel			
Exercises			
NM Reed			
Massage			

Notes: Pt reports no spasms today – slept well over wkt

Manipulation: Cervical / Thoracic / Lumbar
L / R Shoulder / L / R Hip / Pelvis / Sacrum / Left SI Joint / Right SI Joint

Full Cavitation / Partial Cavitation / No Cavitation

PLAN:	3x per week	2x per week	1x per week	As Needed	Discontinue Treatment

Provider Signature: R Capolino D.C

S.O.A.P. Note

PATIENT NAME Kevin Brown DATE 10/30/23

SUBJECTIVE:

Symptoms:	Constant (76-100% of day)	Frequent (51-75% of day)	Intermittent (26-50% of day)	Occasional (1-25% of day)
Sharp				
Stabbing				
Shooting				
Tingling				
Throbbing				
Dull				
Numb				

Location:								
	Head	Cervical	Left Shoulder	Right Shoulder	Left Elbow	Right Elbow	Left Wrist	Right Wrist
	R / L Jaw	Thoracic	Left Upper Arm	Right Upper Arm	Left Forearm	Right Forearm	Left Knee	Right Knee
	Rib Cage	Lumbar	Left Hand	Right Hand	Left Thigh	Right Thigh	Left Hip	Right Hip
	Chest	Pelvis	Left Calf	Right Calf	Left Ankle	Right Ankle	Left Foot	Right Foot

Worsens Pain:								
	Standing	Sitting	Bending	Walking	Lifting	Lying Down	Exercising	Working
	Other (describe):							

Lessens Pain:								
	Standing	Sitting	Bending	Walking	Lifting	Lying Down	Exercising	Working
	Other (describe):							

OBJECTIVE:

Seg. Dysfunction	Tenderness	Spasm
C0	L / R	L / R
C1	L / R	L / R
C2	L / R	L / R
C3	L / R	L / R
C4	L / R	L / R
C5	L / R	L / R
C6	L / R	L / R
C7	L / R	L / R
T1	L / R	L / R
T2	L / R	L / R
T3	L / R	L / R
T4	L / R	L / R
T5	L / R	L / R
T6	L / R	L / R
T7	L / R	L / R
T8	L / R	L / R
T9	L / R	L / R
T10	L / R	L / R
T11	L / R	L / R
T12	L / R	L / R
L1	L / R	L / R
L2	L / R	L / R
L3	L / R	L / R
L4	L / R	L / R
L5	L / R	L / R
S1	L / R	L / R
SI JT	L / R	L / R

Positive / Negative – Maximum Foraminal Compression on the: Left / Right / Bilateral
& radiating to _____
Positive / Negative – Cervical Compression on the: Left / Right / Bilateral
& radiating to _____
Positive / Negative – Cervical Distraction Test
Positive / Negative – Spurling's Test
Positive / Negative – Shoulder Depression on the: Left / Right / Bilateral
Positive / Negative – Impingement Sign on the: Left / Right / Bilateral
Positive / Negative – Speed's Test on on the: Left / Right / Bilateral
Positive / Negative – Supraspinatus Press Test on on the: Left / Right / Bilateral
Positive / Negative – Soto-Hall Test.
Positive / Negative – Adam's Test
Positive / Negative – Patrick-Fabere on the: Left / Right / Bilateral
Positive / Negative – Kemp's on the: Left / Right / Bilateral
Positive / Negative – Ely's on the: Left / Right / Bilateral
Positive / Negative – Nachlas on the: Left / Right / Bilateral
Positive / Negative – Gaenslen's on the: Left / Right / Bilateral
Positive / Negative – Yeoman's on the: Left / Right / Bilateral
Positive / Negative – SLR at _____ degrees on the right
& radiating to _____
Positive / Negative – SLR at _____ degrees on the left
& radiating to _____
Positive / Negative – Thomas Test on the: Left / Right / Bilateral
Positive / Negative – Hibb's Test on the: Left / Right / Bilateral

ASSESSMENT:

Patient shows:	No Improvement	Some Improvement	Good Improvement	
				No more pain
Prognosis:	Guarded	Unstable	Poor	Fair / Good / Excellent

Treatment:	Cervical	Thoracic	Lumbar
Heat / Ice			
Stim			
Manual Traction			
US			
MyoRel			
Exercises			
NM Reed			
Massage			

Notes: C-Spine

Manipulation:					
Cervical	Thoracic	Lumbar			
L / R Shoulder	L / R Hip	Pelvis	Sacrum	Left SI Joint	Right SI Joint

Full Cavitation Partial Cavitation No Cavitation

PLAN:	3x per week	2x per week	1x per week	As Needed	Discontinue Treatment

Provider Signature: R Capitino D.C.

S.O.A.P. Note

PATIENT NAME Kevin Brown DATE 11/6/23

SUBJECTIVE:

Symptoms:	Constant (76-100% of day)	Frequent (51-75% of day)	Intermittent (26-50% of day)	Occasional (1-25% of day)
Sharp				
Stabbing				
Shooting				
Tingling				
Throbbing				
Dull			✓	
Numb				

Location:

Head	Cervical	Left Shoulder	Right Shoulder	Left Elbow	Right Elbow	Left Wrist	Right Wrist
R / L Jaw	Thoracic	Left Upper Arm	Right Upper Arm	Left Forearm	Right Forearm	Left Knee	Right Knee
Rib Cage	Lumbar	Left Hand	Right Hand	Left Thigh	Right Thigh	Left Hip	Right Hip
Chest	Pelvis	Left Calf	Right Calf	Left Ankle	Right Ankle	Left Foot	Right Foot

Worsens Pain: Standing | Sitting | Bending | Walking | Lifting | Lying Down | Exercising | Working

Other (describe):

Lessens Pain: Standing | Sitting | Bending | Walking | Lifting | Lying Down | Exercising | Working

Other (describe):

OBJECTIVE:

Seg. Dysfunction	Tenderness	Spasm
C0	L / R	L / R
C1	L / R	L / R
C2	L / R	L / R
C3	L / R	L / R
C4	L / R	L / R
C5	L / R	L / R
C6	L / R	L / R
C7	L / R	L / R
T1	L / R	L / R
T2	L / R	L / R
T3	L / R	L / R
T4	L / R	L / R
T5	L / R	L / R
T6	L / R	L / R
T7	L / R	L / R
T8	L / R	L / R
T9	L / R	L / R
T10	L / R	L / R
T11	L / R	L / R
T12	L / R	L / R
L1	L / R	L / R
L2	L / R	L / R
L3	L / R	L / R
L4	L / R	L / R
L5	L / R	L / R
S1	L / R	L / R
SI JT	L / R	L / R

Positive / Negative – Maximum Foraminal Compression on the: Left / Right / Bilateral
& radiating to _____
Positive / Negative – Cervical Compression on the: Left / Right / Bilateral
& radiating to _____
Positive / Negative – Cervical Distraction Test
Positive / Negative – Spurling's Test
Positive / Negative – Shoulder Depression on the: Left / Right / Bilateral
Positive / Negative – Impingement Sign on the: Left / Right / Bilateral
Positive / Negative – Speed's Test on on the: Left / Right / Bilateral
Positive / Negative – Supraspinatus Press Test on on the: Left / Right / Bilateral
Positive / Negative – Soto-Hall Test.
Positive / Negative – Adam's Test
Positive / Negative – Patrick-Fabere on the: Left / Right / Bilateral
Positive / Negative – Kemp's on the: Left / Right / Bilateral
Positive / Negative – Ely's on the: Left / Right / Bilateral
Positive / Negative – Nachlas on the: Left / Right / Bilateral
Positive / Negative – Gaenslen's on the: Left / Right / Bilateral
Positive / Negative – Yeoman's on the: Left / Right / Bilateral
Positive / Negative – SLR at _____ degrees on the right
& radiating to _____
Positive / Negative – SLR at _____ degrees on the left
& radiating to _____
Positive / Negative – Thomas Test on the: Left / Right / Bilateral
Positive / Negative – Hibb's Test on the: Left / Right / Bilateral

ASSESSMENT:

Patient shows: No Improvement | Some Improvement | Good Improvement

Prognosis: Guarded | Unstable | Poor | Fair | No more pain | Good | Excellent

Treatment:

	Cervical	Thoracic	Lumbar
Heat / Ice	✓	✓	✓
Stim			✓
Manual Traction			
US			
MyoRel			
Exercises			
NM Reed			
Massage	✓	✓	✓

Notes: Pt c/o T LBP the past few days

Manipulation: Cervical | Thoracic | Lumbar | L / R Shoulder | L / R Hip | Pelvis | Sacrum | Left SI Joint | Right SI Joint

Full Cavitation | Partial Cavitation | No Cavitation

PLAN:	3x per week	2x per week	1x per week	As Needed	Discontinue Treatment

Provider Signature: H Capelino D.C.

S.O.A.P. Note

PATIENT NAME Kevin Brown DATE 11/13/23

SUBJECTIVE:

Symptoms:	Constant (76-100% of day)	Frequent (51-75% of day)	Intermittent (26-50% of day)	Occasional (1-25% of day)
Sharp				
Stabbing				
Shooting				(R) calf
Tingling				
Throbbing				
Dull		✓		
Numb				

Location:								
	Head	Cervical	Left Shoulder	Right Shoulder	Left Elbow	Right Elbow	Left Wrist	Right Wrist
	R / L Jaw	Thoracic	Left Upper Arm	Right Upper Arm	Left Forearm	Right Forearm	Left Knee	Right Knee
	Rib Cage	Lumbar	Left Hand	Right Hand	Left Thigh	Right Thigh	Left Hip	Right Hip
	Chest	Pelvis	Left Calf	Right Calf	Left Ankle	Right Ankle	Left Foot	Right Foot

Worsens Pain:								
	Standing	Sitting	Bending	Walking	Lifting	Lying Down	Exercising	Working
	Other (describe):							

Lessens Pain:								
	Standing	Sitting	Bending	Walking	Lifting	Lying Down	Exercising	Working
	Other (describe):							

OBJECTIVE:

Seg. Dysfunction	Tenderness	Spasm
C0	L / R	L / R
C1	L / R	L / R
C2	L / R	L / R
C3	L / R	L / R
C4	L / R	L / R
C5	L / R	L / R
C6	L / R	L / R
C7	L / R	L / R
T1	L / R	L / R
T2	L / R	L / R
T3	L / R	L / R
T4	L / R	L / R
T5	L / R	L / R
T6	L / R	L / R
T7	L / R	L / R
T8	L / R	L / R
T9	L / R	L / R
T10	L / R	L / R
T11	L / R	L / R
T12	L / R	L / R
L1	L / R	L / R
L2	L / R	L / R
L3	L / R	L / R
L4	L / R	L / R
L5	L / R	L / R
S1	L / R	L / R
SI-J	L / R	L / R

Positive / Negative – Maximum Foraminal Compression on the: Left / Right / Bilateral
& radiating to _____
Positive / Negative – Cervical Compression on the: Left / Right / Bilateral
& radiating to _____
Positive / Negative – Cervical Distraction Test
Positive / Negative – Spurling's Test
Positive / Negative – Shoulder Depression on the: Left / Right / Bilateral
Positive / Negative – Impingement Sign on the: Left / Right / Bilateral
Positive / Negative – Speed's Test on on the: Left / Right / Bilateral
Positive / Negative – Supraspinatus Press Test on on the: Left / Right / Bilateral
Positive / Negative – Soto-Hall Test.
Positive / Negative – Adam's Test
Positive / Negative – Patrick-Fabere on the: Left / Right / Bilateral
Positive / Negative – Kemp's on the: Left / Right / Bilateral
Positive / Negative – Ely's on the: Left / Right / Bilateral
Positive / Negative – Nachlas on the: Left / Right / Bilateral
Positive / Negative – Gaenslen's on the: Left / Right / Bilateral
Positive / Negative – Yeoman's on the: Left / Right / Bilateral
Positive / Negative – SLR at _____ degrees on the right
& radiating to _____
Positive / Negative – SLR at _____ degrees on the left
& radiating to _____
Positive / Negative – Thomas Test on the: Left / Right / Bilateral
Positive / Negative – Hibb's Test on the: Left / Right / Bilateral

ASSESSMENT:

Patient shows:	No Improvement	Some Improvement	Good Improvement	
				No more pain
Prognosis:	Guarded	Unstable	Poor	Fair / Good / Excellent

Treatment:	Cervical	Thoracic	Lumbar
Heat / Ice			
Stim			
Manual Traction			
US			
MyoRel			
Exercises			
NM Reed			
Massage			

Notes: Pts C-spine ⊕ intraset, is causing the c/o shooting radiating pain down his (R) calf/ankle when he crosses his legs (left over right)

Manipulation:						
	Cervical	Thoracic	Lumbar			
	L / R Shoulder	L / R Hip	Pelvis	Sacrum	Left SI Joint	Right SI Joint

Full Cavitation Partial Cavitation No Cavitation

PLAN:	3x per week	2x per week	1x per week	As Needed	Discontinue Treatment

Provider Signature: H Capitino DC

S.O.A.P. Note

PATIENT NAME Kevin Brown DATE 11/27/23

SUBJECTIVE:

Symptoms:	Constant (76-100% of day)	Frequent (51-75% of day)	Intermittent (26-50% of day)	Occasional (1-25% of day)
Sharp				
Stabbing				
Shooting				
Tingling				
Throbbing				
Dull				
Numb				

Location:

Head	Cervical	Left Shoulder	Right Shoulder	Left Elbow	Right Elbow	Left Wrist	Right Wrist
R / L Jaw	Thoracic	Left Upper Arm	Right Upper Arm	Left Forearm	Right Forearm	Left Knee	Right Knee
Rib Cage	Lumbar	Left Hand	Right Hand	Left Thigh	Right Thigh	Left Hip	Right Hip
Chest	Pelvis	Left Calf	Right Calf	Left Ankle	Right Ankle	Left Foot	Right Foot

Worsens Pain:

Standing	Sitting	Bending	Walking	Lifting	Lying Down	Exercising	Working
Other (describe):							

Lessens Pain:

Standing	Sitting	Bending	Walking	Lifting	Lying Down	Exercising	Working
Other (describe): LEST							

OBJECTIVE:

Seg. Dysfunction	Tenderness	Spasm
C0	L / R	L / R
C1	L / R	L / R
C2	L / R	L / R
C3	L / R	L / R
C4	L / R	L / R
C5	L / R	L / R
C6	L / R	L / R
C7	L / R	L / R
T1	L / R	L / R
T2	L / R	L / R
T3	L / R	L / R
T4	L / R	L / R
T5	L / R	L / R
T6	L / R	L / R
T7	L / R	L / R
T8	L / R	L / R
T9	L / R	L / R
T10	L / R	L / R
T11	L / R	L / R
T12	L / R	L / R
L1	L / R	L / R
L2	L / R	L / R
L3	L / R	L / R
L4	L / R	L / R
L5	L / R	L / R
S1	L / R	L / R
SIJ	L / R	L / R

Positive / Negative – Maximum Foraminal Compression on the: Left / Right / Bilateral
& radiating to _____
Positive / Negative – Cervical Compression on the: Left / Right / Bilateral
& radiating to _____
Positive / Negative – Cervical Distraction Test
Positive / Negative – Spurling's Test
Positive / Negative – Shoulder Depression on the: Left / Right / Bilateral
Positive / Negative – Impingement Sign on the: Left / Right / Bilateral
Positive / Negative – Speed's Test on on the: Left / Right / Bilateral
Positive / Negative – Supraspinatus Press Test on on the: Left / Right / Bilateral
Positive / Negative – Soto-Hall Test.
Positive / Negative – Adam's Test
Positive / Negative – Patrick-Fabere on the: Left / Right / Bilateral
Positive / Negative – Kemp's on the: Left / Right / Bilateral
Positive / Negative – Ely's on the: Left / Right / Bilateral
Positive / Negative – Nachlas on the: Left / Right / Bilateral
Positive / Negative – Gaenslen's on the: Left / Right / Bilateral
Positive / Negative – Yeoman's on the: Left / Right / Bilateral
Positive / Negative – SLR at _____ degrees on the right
& radiating to _____
Positive / Negative – SLR at _____ degrees on the left
& radiating to _____
Positive / Negative – Thomas Test on the: Left / Right / Bilateral
Positive / Negative – Hibb's Test on the: Left / Right / Bilateral

ASSESSMENT:

Patient shows:	No Improvement	Some Improvement	Good Improvement

Prognosis:	Guarded	Unstable	Poor	Fair	No more pain / Good / Excellent

Treatment:	Cervical	Thoracic	Lumbar
Heat / Ice			
Stim			
Manual Traction			
US			
MyoRel			
Exercises			
NM Reed			
Massage			

Notes: PT had LEST on 11/25 report ↓ in LBP

Manipulation:

Cervical	Thoracic	Lumbar			
L / R Shoulder	L / R Hip	Pelvis	Sacrum	Left SI Joint	Right SI Joint

Full Cavitation Partial Cavitation No Cavitation

PLAN:	3x per week	2x per week	1x per week	As Needed	Discontinue Treatment

Provider Signature: R Capolino D.C

S.O.A.P. Note

PATIENT NAME Kevin Brown DATE 12/4/23

SUBJECTIVE:

Symptoms:	Constant (76-100% of day)	Frequent (51-75% of day)	Intermittent (26-50% of day)	Occasional (1-25% of day)
Sharp				
Stabbing				
Shooting				
Tingling				
Throbbing				
Dull				
Numb			✓	

Location:

Head	Cervical	Left Shoulder	Right Shoulder	Left Elbow	Right Elbow	Left Wrist	Right Wrist
R / L Jaw	Thoracic	Left Upper Arm	Right Upper Arm	Left Forearm	Right Forearm	Left Knee	Right Knee
Rib Cage	Lumbar	Left Hand	Right Hand	Left Thigh	Right Thigh	Left Hip	Right Hip
Chest	Pelvis	Left Calf	Right Calf	Left Ankle	Right Ankle	Left Foot	Right Foot

Worsens Pain:

Standing	Sitting	Bending	Walking	Lifting	Lying Down	Exercising	Working
Other (describe):	massage legs						

Lessens Pain:

Standing	Sitting	Bending	Walking	Lifting	Lying Down	Exercising	Working
Other (describe):							

OBJECTIVE:

Seg. Dysfunction	Tenderness	Spasm
C0	L / R	L / R
C1	L / R	L / R
C2	L / R	L / R
C3	L / R	L / R
C4	L / R	L / R
C5	L / R	L / R
C6	L / R	L / R
C7	L / R	L / R
T1	L / R	L / R
T2	L / R	L / R
T3	L / R	L / R
T4	L / R	L / R
T5	L / R	L / R
T6	L / R	L / R
T7	L / R	L / R
T8	L / R	L / R
T9	L / R	L / R
T10	L / R	L / R
T11	L / R	L / R
T12	L / R	L / R
L1	L / R	L / R
L2	L / R	L / R
L3	L / R	L / R
L4	L / R	L / R
L5	L / R	L / R
S1	L / R	L / R
SI JT	L / R	L / R

Positive / Negative – Maximum Foraminal Compression on the: Left / Right / Bilateral
& radiating to _____
Positive / Negative – Cervical Compression on the: Left / Right / Bilateral
& radiating to _____
Positive / Negative – Cervical Distraction Test
Positive / Negative – Spurling's Test
Positive / Negative – Shoulder Depression on the: Left / Right / Bilateral
Positive / Negative – Impingement Sign on the: Left / Right / Bilateral
Positive / Negative – Speed's Test on on the: Left / Right / Bilateral
Positive / Negative – Supraspinatus Press Test on on the: Left / Right / Bilateral
Positive / Negative – Soto-Hall Test.
Positive / Negative – Adam's Test
Positive / Negative – Patrick-Fabere on the: Left / Right / Bilateral
Positive / Negative – Kemp's on the: Left / Right / Bilateral
Positive / Negative – Ely's on the: Left / Right / Bilateral
Positive / Negative – Nachlas on the: Left / Right / Bilateral
Positive / Negative – Gaenslen's on the: Left / Right / Bilateral
Positive / Negative – Yeoman's on the: Left / Right / Bilateral
Positive / Negative – SLR at _____ degrees on the right
& radiating to _____
Positive / Negative – SLR at _____ degrees on the left
& radiating to _____
Positive / Negative – Thomas Test on the: Left / Right / Bilateral
Positive / Negative – Hibb's Test on the: Left / Right / Bilateral

ASSESSMENT:

Patient shows:	No Improvement	Some Improvement	Good Improvement	
Prognosis:	Guarded	Unstable	Poor	Fair
				No more pain
				Good
				Excellent

Treatment:	Cervical	Thoracic	Lumbar
Heat / Ice	✓	✓	✓
Stim			✓
Manual Traction			
US			
MyoRel			
Exercises			
NM Reed	✓	✓	✓
Massage	✓	✓	✓

Notes: Pt reports ↑ in LBP

Manipulation:

Cervical	Thoracic	Lumbar			
L / R Shoulder	L / R Hip	Pelvis	Sacrum	Left SI Joint	Right SI Joint

Full Cavitation Partial Cavitation No Cavitation

PLAN:	3x per week	2x per week	1x per week	As Needed	Discontinue Treatment

Provider Signature: R Capelina D.C

PATIENT RE-EVALUATION EXAMINATION

LAST NAME Brown FIRST NAME Kevin
DATE OF RE-EVALUATION EXAMINATION 12/29/23 DOA DOB
PATIENT SEX: MALE FEMALE

CHIEF COMPLAINT:

	Localized Cervical Pain		Radiating to: Left / Right : Shoulder / Arm / Elbow / Hand
	Thoracic Pain		Radiating to: Ribcage / Sternum
✓	Localized Lumbar Pain		Radiating to Left / Right: Hip / Buttock / Thigh / Knee / Leg / Foot
	Difficulty Sleeping		Dizziness / Difficulty Sitting
	Difficulty Walking / Standing		Headaches / Difficulty Bending / Lifting
	Alleviated By:		
	Other Complaints:		

Cervical ROM

	Normal	Degree	Pain
Flex	60		
Ext	75		
RL Flex	45		
LL Flex	45		
R Rot	80		
L Rot	80		

Thoraco-Lumbar ROM

	Normal	Degree	Pain
Flex	90	85	L4/L5
Ext	30	30	N
RL Flex	30	30	
LL Flex	30	30	
R Rot	30	30	
L Rot	30	30	

PALPATORY FINDINGS

Seg. Dysfunction		Tenderness	Spasm
C0		L / R	L / R
C1		L / R	L / R
C2		L / R	L / R
C3		L / R	L / R
C4		L / R	L / R
C5		L / R	L / R
C6		L / R	L / R
C7		L / R	L / R
T1		L / R	L / R
T2		L / R	L / R
T3		L / R	L / R
T4		L / R	L / R
T5		L / R	L / R
T6		L / R	L / R
T7		L / R	L / R
T8		L / R	L / R
T9		L / R	L / R
T10		L / R	L / R
T11		L / R	L / R
T12		L / R	L / R
L1		L / R	L / R
L2		L / R	L / R
L3		L / R	L / R
L4		L / R	L / R
L5		L / R	L / R
S1		L / R	L / R
SI JT		L / R	L / R

ASSESSMENT - Patient shows: No Improvement / Some Improvement / Good Improvement / No More Pain

PROGNOSIS - At the present time the patient's condition is: Guarded / Unstable / Poor / Fair / Good / Excellent

TREATMENT PLAN - The patient is instructed regarding certain limitation of activities.

Recommendation for: PFNCS / MUA / PM / ROM / MMT / FCT / EMG / NCV / TMJ

Pt. had lumbar discectomy 12/20 ↓LBP

The patient should continue chiropractic treatment with adjunctive therapy:

3x/week	2x/week	1x/week

Follow-up visit in 3-4 weeks.

Doctor's Signature Date

S.O.A.P. Note

PATIENT NAME Kevin Brown DATE 12/29/23

SUBJECTIVE:

Symptoms:	Constant (76-100% of day)	Frequent (51-75% of day)	Intermittent (26-50% of day)	Occasional (1-25% of day)
Sharp				
Stabbing				
Shooting				
Tingling				
Throbbing				
Dull				
Numb				

Location:

Head	Cervical	Left Shoulder	Right Shoulder	Left Elbow	Right Elbow	Left Wrist	Right Wrist
R / L Jaw	Thoracic	Left Upper Arm	Right Upper Arm	Left Forearm	Right Forearm	Left Knee	Right Knee
Rib Cage	Lumbar	Left Hand	Right Hand	Left Thigh	Right Thigh	Left Hip	Right Hip
Chest	Pelvis	Left Calf	Right Calf	Left Ankle	Right Ankle	Left Foot	Right Foot

Worsens Pain: Standing | Sitting | Bending | Walking | Lifting | Lying Down | Exercising | Working

Other (describe):

Lessens Pain: Standing | Sitting | Bending | Walking | Lifting | Lying Down | Exercising | Working

Other (describe): L-spine discectomy 12/20

OBJECTIVE:

Seg. Dysfunction	Tenderness	Spasm
C0	L / R	L / R
C1	L / R	L / R
C2	L / R	L / R
C3	L / R	L / R
C4	L / R	L / R
C5	L / R	L / R
C6	L / R	L / R
C7	L / R	L / R
T1	L / R	L / R
T2	L / R	L / R
T3	L / R	L / R
T4	L / R	L / R
T5	L / R	L / R
T6	L / R	L / R
T7	L / R	L / R
T8	L / R	L / R
T9	L / R	L / R
T10	L / R	L / R
T11	L / R	L / R
T12	L / R	L / R
L1	L / R	L / R
L2	L / R	L / R
L3	L / R	L / R
L4	L / R	L / R
L5	L / R	L / R
S1	L / R	L / R
SI JT	L / R	L / R

Positive / Negative – Maximum Foraminal Compression on the: Left / Right / Bilateral
& radiating to _____
Positive / Negative – Cervical Compression on the: Left / Right / Bilateral
& radiating to _____
Positive / Negative – Cervical Distraction Test
Positive / Negative – Spurling's Test
Positive / Negative – Shoulder Depression on the: Left / Right / Bilateral
Positive / Negative – Impingement Sign on the: Left / Right / Bilateral
Positive / Negative – Speed's Test on on the: Left / Right / Bilateral
Positive / Negative – Supraspinatus Press Test on on the: Left / Right / Bilateral
Positive / Negative – Soto-Hall Test.
Positive / Negative – Adam's Test
Positive / Negative – Patrick-Fabere on the: Left / Right / Bilateral
Positive / Negative – Kemp's on the: Left / Right / Bilateral
Positive / Negative – Ely's on the: Left / Right / Bilateral
Positive / Negative – Nachlas on the: Left / Right / Bilateral
Positive / Negative – Gaenslen's on the: Left / Right / Bilateral
Positive / Negative – Yeoman's on the: Left / Right / Bilateral
Positive / Negative – SLR at _____ degrees on the right
& radiating to _____
Positive / Negative – SLR at _____ degrees on the left
& radiating to _____
Positive / Negative – Thomas Test on the: Left / Right / Bilateral
Positive / Negative – Hibb's Test on the: Left / Right / Bilateral

ASSESSMENT:

Patient shows: No Improvement | Some Improvement | Good Improvement

Prognosis: Guarded | Unstable | Poor | Fair | No more pain | Good | Excellent

Treatment:	Cervical	Thoracic	Lumbar
Heat / Ice			
Stim			
Manual Traction			
US			
MyoRel			
Exercises			
NM Reed			
Massage			

Notes: PT reports no C,T pain since last visit. He had L-spine discectomy on 12/20 and reports VM LBP

Manipulation:

Cervical	Thoracic	Lumbar			
L / R Shoulder	L / R Hip	Pelvis	Sacrum	Left SI Joint	Right SI Joint

Full Cavitation | Partial Cavitation | No Cavitation

PLAN:	3x per week	2x per week	1x per week	As Needed	Discontinue Treatment

Provider Signature: R Capelina D.C

S.O.A.P. Note

PATIENT NAME Kevin Brown DATE 1/12/24

SUBJECTIVE:

Symptoms:	Constant (76-100% of day)	Frequent (51-75% of day)	Intermittent (26-50% of day)	Occasional (1-25% of day)
Sharp				
Stabbing				
Shooting				
Tingling				
Throbbing				
Dull				
Numb				

Location:								
	Head	Cervical	Left Shoulder	Right Shoulder	Left Elbow	Right Elbow	Left Wrist	Right Wrist
	R / L Jaw	Thoracic	Left Upper Arm	Right Upper Arm	Left Forearm	Right Forearm	Left Knee	Right Knee
	Rib Cage	Lumbar	Left Hand	Right Hand	Left Thigh	Right Thigh	Left Hip	Right Hip
	Chest	Pelvis	Left Calf	Right Calf	Left Ankle	Right Ankle	Left Foot	Right Foot

Worsens Pain:								
	Standing	Sitting	Bending	Walking	Lifting	Lying Down	Exercising	Working
	Other (describe):							

Lessens Pain:								
	Standing	Sitting	Bending	Walking	Lifting	Lying Down	Exercising	Working
	Other (describe):							

OBJECTIVE:

Seg. Dysfunction	Tenderness	Spasm
C0	L / R	L / R
C1	L / R	L / R
C2	L / R	L / R
C3	L / R	L / R
C4	L / R	L / R
C5	L / R	L / R
C6	L / R	L / R
C7	L / R	L / R
T1	L / R	L / R
T2	L / R	L / R
T3	L / R	L / R
T4	L / R	L / R
T5	L / R	L / R
T6	L / R	L / R
T7	L / R	L / R
T8	L / R	L / R
T9	L / R	L / R
T10	L / R	L / R
T11	L / R	L / R
T12	L / R	L / R
L1	L / R	L / R
L2	L / R	L / R
L3	L / R	L / R
L4	L / R	L / R
L5	L / R	L / R
S1	L / R	L / R
SI JT	L / R	L / R

Positive / Negative – Maximum Foraminal Compression on the: Left / Right / Bilateral
& radiating to _____
Positive / Negative – Cervical Compression on the: Left / Right / Bilateral
& radiating to _____
Positive / Negative – Cervical Distraction Test
Positive / Negative – Spurling's Test
Positive / Negative – Shoulder Depression on the: Left / Right / Bilateral
Positive / Negative – Impingement Sign on the: Left / Right / Bilateral
Positive / Negative – Speed's Test on on the: Left / Right / Bilateral
Positive / Negative – Supraspinatus Press Test on on the: Left / Right / Bilateral
Positive / Negative – Soto-Hall Test.
Positive / Negative – Adam's Test
Positive / Negative – Patrick-Fabere on the: Left / Right / Bilateral
Positive / Negative – Kemp's on the: Left / Right / Bilateral
Positive / Negative – Ely's on the: Left / Right / Bilateral
Positive / Negative – Nachlas on the: Left / Right / Bilateral
Positive / Negative – Gaenslen's on the: Left / Right / Bilateral
Positive / Negative – Yeoman's on the: Left / Right / Bilateral
Positive / Negative – SLR at _____ degrees on the right
& radiating to _____
Positive / Negative – SLR at _____ degrees on the left
& radiating to _____
Positive / Negative – Thomas Test on the: Left / Right / Bilateral
Positive / Negative – Hibb's Test on the: Left / Right / Bilateral

ASSESSMENT:

Patient shows:	No Improvement	Some Improvement	Good Improvement	
				No more pain
Prognosis:	Guarded	Unstable	Poor	Fair / Good / Excellent

Treatment:	Cervical	Thoracic	Lumbar
Heat / Ice			
Stim			
Manual Traction			
US			
MyoRel			
Exercises			
NM Reed			
Massage			

Notes: Pt c/o L-Spine pain @ L5 (L) in AM ↓ intensity

Manipulation:					
Cervical	Thoracic	Lumbar			
L / R Shoulder	L / R Hip	Pelvis	Sacrum	Left SI Joint	Right SI Joint

Full Cavitation Partial Cavitation No Cavitation

PLAN:	3x per week	2x per week	1x per week	As Needed	Discontinue Treatment

Provider Signature: R Capolino D.C

S.O.A.P. Note

PATIENT NAME Kevin Brown DATE 1/15/24

SUBJECTIVE:

Symptoms:	Constant (76-100% of day)	Frequent (51-75% of day)	Intermittent (26-50% of day)	Occasional (1-25% of day)
Sharp			L-spine	
Stabbing				
Shooting				
Tingling				
Throbbing				
Dull				
Numb				

Location:								
	Head	Cervical	Left Shoulder	Right Shoulder	Left Elbow	Right Elbow	Left Wrist	Right Wrist
	R / L Jaw	Thoracic	Left Upper Arm	Right Upper Arm	Left Forearm	Right Forearm	Left Knee	Right Knee
	Rib Cage	Lumbar	Left Hand	Right Hand	Left Thigh	Right Thigh	Left Hip	Right Hip
	Chest	Pelvis	Left Calf	Right Calf	Left Ankle	Right Ankle	Left Foot	Right Foot

Worsens Pain:	Standing	Sitting	Bending	Walking	Lifting	Lying Down	Exercising	Working
	Other (describe): driving							

Lessens Pain:	Standing	Sitting	Bending	Walking	Lifting	Lying Down	Exercising	Working
	Other (describe):							

OBJECTIVE:

Seg. Dysfunction	Tenderness	Spasm
C0	L / R	L / R
C1	L / R	L / R
C2	L / R	L / R
C3	L / R	L / R
C4	L / R	L / R
C5	L / R	L / R
C6	L / R	L / R
C7	L / R	L / R
T1	L / R	L / R
T2	L / R	L / R
T3	L / R	L / R
T4	L / R	L / R
T5	L / R	L / R
T6	L / R	L / R
T7	L / R	L / R
T8	L / R	L / R
T9	L / R	L / R
T10	L / R	L / R
T11	L / R	L / R
T12	L / R	L / R
L1	L / R	L / R
L2	L / R	L / R
L3	L / R	L / R
L4	L / R	L / R
L5	L / R	L / R
S1	L / R	L / R
SI JT	L / R	L / R

Positive / Negative – Maximum Foraminal Compression on the: Left / Right / Bilateral
& radiating to _____
Positive / Negative – Cervical Compression on the: Left / Right / Bilateral
& radiating to _____
Positive / Negative – Cervical Distraction Test
Positive / Negative – Spurling's Test
Positive / Negative – Shoulder Depression on the: Left / Right / Bilateral
Positive / Negative – Impingement Sign on the: Left / Right / Bilateral
Positive / Negative – Speed's Test on on the: Left / Right / Bilateral
Positive / Negative – Supraspinatus Press Test on on the: Left / Right / Bilateral
Positive / Negative – Soto-Hall Test.
Positive / Negative – Adam's Test
Positive / Negative – Patrick-Fabere on the: Left / Right / Bilateral
Positive / Negative – Kemp's on the: Left / Right / Bilateral
Positive / Negative – Ely's on the: Left / Right / Bilateral
Positive / Negative – Nachlas on the: Left / Right / Bilateral
Positive / Negative – Gaenslen's on the: Left / Right / Bilateral
Positive / Negative – Yeoman's on the: Left / Right / Bilateral
Positive / Negative – SLR at _____ degrees on the right
& radiating to _____
Positive / Negative – SLR at _____ degrees on the left
& radiating to _____
Positive / Negative – Thomas Test on the: Left / Right / Bilateral
Positive / Negative – Hibb's Test on the: Left / Right / Bilateral

ASSESSMENT:

Patient shows:	No Improvement	Some Improvement	Good Improvement	
				No more pain
Prognosis:	Guarded	Unstable	Poor	Fair / Good / Excellent

Treatment:	Cervical	Thoracic	Lumbar
Heat / Ice			
Stim			
Manual Traction			
US			
MyoRel			
Exercises			
NM Reed			
Massage			

Notes: Pt is reporting an ↑ in his L-spine due to driving 2 hrs/day for work

Manipulation:	Cervical	Thoracic	Lumbar			
	L / R Shoulder	L / R Hip	Pelvis	Sacrum	Left SI Joint	Right SI Joint

Full Cavitation Partial Cavitation No Cavitation

PLAN:	3x per week	2x per week	1x per week	As Needed	Discontinue Treatment

Provider Signature: R Capolina DC

S.O.A.P. Note

PATIENT NAME Kevin Brown DATE 1/22/24

SUBJECTIVE:

Symptoms:	Constant (76-100% of day)	Frequent (51-75% of day)	Intermittent (26-50% of day)	Occasional (1-25% of day)
Sharp				
Stabbing				
Shooting				
Tingling				
Throbbing				
Dull				
Numb				

Location:								
	Head	Cervical	Left Shoulder	Right Shoulder	Left Elbow	Right Elbow	Left Wrist	Right Wrist
	R / L Jaw	Thoracic	Left Upper Arm	Right Upper Arm	Left Forearm	Right Forearm	Left Knee	Right Knee
	Rib Cage	Lumbar	Left Hand	Right Hand	Left Thigh	Right Thigh	Left Hip	Right Hip
	Chest	Pelvis	Left Calf	Right Calf	Left Ankle	Right Ankle	Left Foot	Right Foot

Worsens Pain:	Standing	Sitting	Bending	Walking	Lifting	Lying Down	Exercising	Working
	Other (describe):							

Lessens Pain:	Standing	Sitting	Bending	Walking	Lifting	Lying Down	Exercising	Working
	Other (describe):							

OBJECTIVE:

Seg. Dysfunction	Tenderness	Spasm
C0	L / R	L / R
C1	L / R	L / R
C2	L / R	L / R
C3	L / R	L / R
C4	L / R	L / R
C5	L / R	L / R
C6	L / R	L / R
C7	L / R	L / R
T1	L / R	L / R
T2	L / R	L / R
T3	L / R	L / R
T4	L / R	L / R
T5	L / R	L / R
T6	L / R	L / R
T7	L / R	L / R
T8	L / R	L / R
T9	L / R	L / R
T10	L / R	L / R
T11	L / R	L / R
T12	L / R	L / R
L1	L / R	L / R
L2	L / R	L / R
L3	L / R	L / R
L4	L / R	L / R
L5	L / R	L / R
S1	L / R	L / R
SI JT	L / R	L / R

Positive / Negative – Maximum Foraminal Compression on the: Left / Right / Bilateral
& radiating to _____
Positive / Negative – Cervical Compression on the: Left / Right / Bilateral
& radiating to _____
Positive / Negative – Cervical Distraction Test
Positive / Negative – Spurling's Test
Positive / Negative – Shoulder Depression on the: Left / Right / Bilateral
Positive / Negative – Impingement Sign on the: Left / Right / Bilateral
Positive / Negative – Speed's Test on on the: Left / Right / Bilateral
Positive / Negative – Supraspinatus Press Test on on the: Left / Right / Bilateral
Positive / Negative – Soto-Hall Test.
Positive / Negative – Adam's Test
Positive / Negative – Patrick-Fabere on the: Left / Right / Bilateral
Positive / Negative – Kemp's on the: Left / Right / Bilateral
Positive / Negative – Ely's on the: Left / Right / Bilateral
Positive / Negative – Nachlas on the: Left / Right / Bilateral
Positive / Negative – Gaenslen's on the: Left / Right / Bilateral
Positive / Negative – Yeoman's on the: Left / Right / Bilateral
Positive / Negative – SLR at _____ degrees on the right
& radiating to _____
Positive / Negative – SLR at _____ degrees on the left
& radiating to _____
Positive / Negative – Thomas Test on the: Left / Right / Bilateral
Positive / Negative – Hibb's Test on the: Left / Right / Bilateral

ASSESSMENT:

Patient shows:	No Improvement	Some Improvement	Good Improvement	
				No more pain
Prognosis:	Guarded	Unstable	Poor	Fair
				Good
				Excellent

Treatment:	Cervical	Thoracic	Lumbar
Heat / Ice			
Stim			
Manual Traction			
US			
MyoRel			
Exercises			
NM Reed			
Massage			

Notes: D P L4/L5

Manipulation:	Cervical	Thoracic	Lumbar			
	L / R Shoulder	L / R Hip	Pelvis	Sacrum	Left SI Joint	Right SI Joint

Full Cavitation Partial Cavitation No Cavitation

PLAN:	3x per week	2x per week	1x per week	As Needed	Discontinue Treatment

Provider Signature: R Capolino DC

S.O.A.P. Note

PATIENT NAME Kevin Brown DATE 2/12/24

SUBJECTIVE:

Symptoms:	Constant (76-100% of day)	Frequent (51-75% of day)	Intermittent (26-50% of day)	Occasional (1-25% of day)
Sharp				
Stabbing				
Shooting				
Tingling				
Throbbing				
Dull				
Numb				

Location:

Head	Cervical	Left Shoulder	Right Shoulder	Left Elbow	Right Elbow	Left Wrist	Right Wrist
R / L Jaw	Thoracic	Left Upper Arm	Right Upper Arm	Left Forearm	Right Forearm	Left Knee	Right Knee
Rib Cage	Lumbar	Left Hand	Right Hand	Left Thigh	Right Thigh	Left Hip	Right Hip
Chest	Pelvis	Left Calf	Right Calf	Left Ankle	Right Ankle	Left Foot	Right Foot

Worsens Pain:

Standing	Sitting	Bending	Walking	Lifting	Lying Down	Exercising	Working
Other (describe): Driving							

Lessens Pain:

Standing	Sitting	Bending	Walking	Lifting	Lying Down	Exercising	Working
Other (describe):							

OBJECTIVE:

Seg. Dysfunction	Tenderness	Spasm
C0	L / R	L / R
C1	L / R	L / R
C2	L / R	L / R
C3	L / R	L / R
C4	L / R	L / R
C5	L / R	L / R
C6	L / R	L / R
C7	L / R	L / R
T1	L / R	L / R
T2	L / R	L / R
T3	L / R	L / R
T4	L / R	L / R
T5	L / R	L / R
T6	L / R	L / R
T7	L / R	L / R
T8	L / R	L / R
T9	L / R	L / R
T10	L / R	L / R
T11	L / R	L / R
T12	L / R	L / R
L1	L / R	L / R
L2	L / R	L / R
L3	L / R	L / R
L4	L / R	L / R
L5	L / R	L / R
S1	L / R	L / R
SIJT	L / R	L / R

Positive / Negative – Maximum Foraminal Compression on the: Left / Right / Bilateral
& radiating to _____
Positive / Negative – Cervical Compression on the: Left / Right / Bilateral
& radiating to _____
Positive / Negative – Cervical Distraction Test
Positive / Negative – Spurling's Test
Positive / Negative – Shoulder Depression on the: Left / Right / Bilateral
Positive / Negative – Impingement Sign on the: Left / Right / Bilateral
Positive / Negative – Speed's Test on on the: Left / Right / Bilateral
Positive / Negative – Supraspinatus Press Test on on the: Left / Right / Bilateral
Positive / Negative – Soto-Hall Test
Positive / Negative – Adam's Test
Positive / Negative – Patrick-Fabere on the: Left / Right / Bilateral
Positive / Negative – Kemp's on the: Left / Right / Bilateral
Positive / Negative – Ely's on the: Left / Right / Bilateral
Positive / Negative – Nachlas on the: Left / Right / Bilateral
Positive / Negative – Gaenslen's on the: Left / Right / Bilateral
Positive / Negative – Yeoman's on the: Left / Right / Bilateral
Positive / Negative – SLR at _____ degrees on the right
& radiating to _____
Positive / Negative – SLR at _____ degrees on the left
& radiating to _____
Positive / Negative – Thomas Test on the: Left / Right / Bilateral
Positive / Negative – Hibb's Test on the: Left / Right / Bilateral

ASSESSMENT:

Patient shows:	No Improvement	Some Improvement	Good Improvement

Prognosis:	Guarded	Unstable	Poor	Fair	No more pain / Good / Excellent

Treatment:

	Cervical	Thoracic	Lumbar
Heat / Ice			
Stim			
Manual Traction			
US			
MyoRel			
Exercises			
NM Reed			
Massage			

Notes: PT drive and lifts pressure for walk instructed back 40 LBS out less increase today

Manipulation:

Cervical	Thoracic	Lumbar			
L / R Shoulder	L / R Hip	Pelvis	Sacrum	Left SI Joint	Right SI Joint

Full Cavitation Partial Cavitation No Cavitation

PLAN:	3x per week	2x per week	1x per week	As Needed	Discontinue Treatment

Provider Signature: H Capolino DC