PREETHI HOSPITALS
Transforming Healthcare to Health

Full NABH Accreditation

# DISCHARGE SUMMARY

**MRN NO :** 166942 **AGE** : 50 Year **DOA :** 13.02.2025 at 03:57 PM

**NAME** : Mr.SENTHILKUMAR.R **GENDER** : MALE **DOD :** 18.02.2025

**CONSULTANT:** Prof. Dr. R. SIVAKUMAR M.S.ORTHO., D. ORTHO.
Prof. DR. M.CHIDAMBARAM MS., ORTHO.,D.ORTHO
DR.PRAHALADKUMAR SINGHI D.ORTHO.,DNB.ORTHO.,MNAMS.,
DR. CHARU.S.R MD., (General Physician)
DR. SHANKAR MD., DM., (Cardiology)
DR. BALAJI MD., (Intensivist)

**DATE OF SURGERY:** 14.02.2025 **PATIENT TYPE: NON MLC**

**ICD CODE:** M23. 91, M23.611, S83. 54, S83. 242A, S83. 231A, M22. 2, M24.10, E0800, 110 **SPECIALITY: ARTHROSCPOY**

**DIAGNOSIS:**

IDK RIGHT KNEE - MYXOID DEGENERATION OF ACL
PARTIAL MID SUBSTANCE PCL TEAR
MEDIAL MENISCUS - COMPLEX TEAR
PATELLO FEMORAL CHONDRAL CHANGES - GRADE - III
MEDIAL FEMORAL CONDYLE GRADE - III CHONDRAL CHANGES
DIABETES MELLITUS
HYPERTENSION

**PRESENTING COMPLAINTS:**

C/o pain and giving away sensation in right knee since 2 1/2 months
H/o pain and instability in right knee since 2 1/2 months
H/o bike fell over right knee 2 1/2 months back, Initially treated at nearby hospital, first aid and brace given and then patient came here for further management
No H/o fever / No H/o multiple joint pain

**PAST HISTORY:**

Known case of DM / HTN on treatment
Not a known case of CAD / CKD /Asthma / Drug Allergy

**RELEVANT CLINICAL FINDINGS:**

**GENERAL EXAMINATION:**

Patient conscious, oriented, afebrile,

| | | | | | |
|---|---|---|---|---|---|
| **BP** | : | 120/ 70 mmHg | **PR** | : | 84 /min |
| **TEMP** | : | $98^0$ F | **RR** | : | 22/min |

# DISCHARGE SUMMARY

**ADVICE AT DISCHARGE:**

| | |
|---|---|
| T. ECOSPRIN 75MG | 0-1-0 |
| T. CTRAX 500MG | 1-0-1 |
| T. USEN DR | 1-0-1 |
| T. RABLET 20MG | 1-0-1 |
| T. ZINCOPVIT | 1-0-0 |
| T. ALZOLAM 0.5MG | 0-0-1 |
| T. GABANUERON 100MG | 0-0-1 |
| T. ETOFREE 600MG | 0-0-1 |
| T. OLMEZEST AM 40/5 | 1-0-0 |
| T. ISTAMET 50/500MG | 1-0-0 |
| T. AZTOR 20MG | 0-0-1 |

**FOLLOW UP:**

Review date:24.02.2025 at 10:00am (Unit - I)

Follow the advised medications regularly.

**DR. Prahalad Kumar Singhi D. Ortho., DNB., Ortho.,**
**(Consultant Orthopaedic Surgeon)**

**PROF.DR.R.SIVAKUMAR M.S ORTHO., D.ORTHO,**
**(Chief Consultant – Department of Orthopaedics)**

Please contact the hospital immediately if patient has the following symptoms.

Pain, Swelling, Fever, Bleeding from operated site, Urgent care

For Medical and Surgical Emergencies, please contact mobile 7810044444

For Hospital Ambulance services please contact mobile 9655661252

For appointment and other queries please contact mobile 9442233996

PIMS SUPER SPECIALITY International Healthcare Madurai

# Molecular Diagnosis Laboratory

unit of Preethi Hospitals

NABL Accredited for HCV Qualitative assay, ICMR Approved for COVID - 19 Testing

| | | | | | |
|---|---|---|---|---|---|
| Lab No. | : 25/02/001509 | MRN | : 166942 | | |
| Patient | : SENTHILKUMAR.R | IP/OP No | : IP/24007513 | Collected On | : 15/02/2025 7.13 AM |
| Age / Sex | : 50 Years / Male | Room No | : IMCU/IMCU | Reported On | : 15/02/2025 7.54 AM |
| Cons. By | : Dr. PRAHALADKUMAR.SINGHI D. | MobileNo | : 9486495964 | Validated On | : 15/02/2025 7.54 AM |
| | | | | Printed On | : 15/02/2025 7.55 AM |



## Final Report

| Specimen | Test Description | Result / Units | | Reference Range |
|---|---|---|---|---|
| **HAEMATOLOGY** | | | | |
| BLOOD | HAEMOGLOBIN<br>NON-CYANIDE HAEMOGLOBIN ANALYSIS | 12.9 g/dL | ↓ | 13.6 - 16.7 |
| **BIOCHEMISTRY** | | | | |
| **RFT** | | | | |
| SERUM | UREA<br>UREASE - GLDH | 15 mg/dL | | 15-39 |

Increased in: Renal failure (acute or chronic), urinary tract obstruction, dehydration, shock, burns, CHF, GI bleeding.Nephrotoxic drugs (eg, gentamicin).

Decreased in: Hepatic failure, nephrotic syndrome, cachexia (low-protein and high-carbohydrate diets).

| | | | | |
|---|---|---|---|---|
| SERUM | CREATININE<br>JAFFE KINETIC METHOD | 0.8 mg/dL | | 0.7 - 1.2 |

Increased in: Acute or chronic renal failure, urinary tract obstruction, nephrotoxic drugs, hypothyroidism.

Decreased in: Reduced muscle mass.

----------End of Report----------

Lab Technician

Dr.M.R.Vasanthapriyan,M.D.,
Consultant Microbiologist

| | | | | | |
|---|---|---|---|---|---|
| Lab No. | :25/02/001282 | MRN | :166942 | | |
| Patient | :Mr.SENTHILKUMAR.R | IP/OP No | :OP/24050164 | Collected On | :13/02/2025 4.03 PM |
| Age / Sex | :50 Years / MALE | Bill No | :24082510 | Reported On | :13/02/2025 8.10 PM |
| Cons. By | :Dr. PRAHALADKUMAR SINGHI D. | MobileNo | :9486495964 | Validated On | :13/02/2025 8.10 PM |
| | | | | Printed On | :13/02/2025 11.03 PM |



## Final Report

| Specimen | Test Description | Result / Units | Reference Range |
|---|---|---|---|
| **HAEMATOLOGY** | | | |
| BLOOD | ESR<br>manual | 47 mm / 1 hr ↑ | 0 - 15 |
| Male: ≤15 mm/hr. Female: ≤ 20 mm/hr. | | | |
| **BLOOD ROUTINE** | | | |
| BLOOD | Total WBC Count<br>FLUORESCENT FLOW CYTOMETRY | 8350 cells/cumm | 4000 - 11000 |
| BLOOD | NEUTROPHILS<br>FLUORESCENT FLOW CYTOMETRY | 62 % | 40 - 75 |
| BLOOD | LYMPHOCYTES<br>FLUORESCENT FLOW CYTOMETRY | 33 % | 15 - 45 |
| BLOOD | EOSINOPHILS<br>FLUORESCENT FLOW CYTOMETRY | 01 % | 0 - 7 |
| BLOOD | MONOCYTES<br>FLUORESCENT FLOW CYTOMETRY | 04 % | 4 - 13 |
| BLOOD | BASOPHILS<br>FLUORESCENT FLOW CYTOMETRY | 00 % | < 1.0 |
| BLOOD | HAEMOGLOBIN<br>NON-CYANIDE HAEMOGLOBIN ANALYSIS | 14.6 g/dL | 13.6 - 16.7 |
| BLOOD | PCV<br>ELECTRICAL IMPEDANCE (RBC PULSE HEIGHT DETECTION)) | 41 % | 39 - 49 |
| BLOOD | Red blood cell (RBC) count<br>ELECTRICAL IMPEDANCE | 4.79 milllion / cumm | 4.30 - 5.80 |
| BLOOD | MCV<br>CALCULATED | 85 fL | 80 - 97 |

Lab Technician

Dr.M.R.Vasanthapriyan,M.D.,
Consultant Microbiologist

# DISCHARGE SUMMARY

8. moderate joint effusion with synovial thickening and synovial loose bodies noted - synovitis.
9. No evidence of fracture or osteomyelitis noted.
10. Chondromalacia patella grade III involving eminence and patellar facets.
11. Subcutaneous oedema around knee region.
12. Dilated superficial veins seen in medial aspect of knee - varicosities.
13. Quadriceps and patellar tendon appears normal.
14. Iliotibial band and biceps femoris appears normal.
15. Neurovascular bundle appears normal.
16. No evidence of bony neoplasm.

Patient and patient attenders explained about the possibility of wound infection, restriction and stiffness of right knee movements,possibility of persistance of instability of may need revision surgery explained.Possiblity of DVT and pulmonary embolism explained. Possibility of secondary arthritis changes of right knee which may need replacement surgery later and need regular followup and physiotherapy.

**COURSE & MANAGEMENT:**

**PROCEDURE:**

RIGHT KNEE DIAGNOSTIC ARTHROSCOPY,
DEBULKING OF ACL,
ALL INSIDE PCL RECONSTRUCTION USING SEMI T GRAFT WITH PCL INTERNAL BRACING,
MEDIAL MENISCUS BALANCING, ,
MFC FRAYED OUT CHONDRAL DEBRIDEMENT WITH MICRO FRACTURE,
MCL REPAIR AND AUGMENTATION WITH GRACILIS, PATELLO FEMORAL CHONDRAL ABLATION

Under spinal anaesthesia,under sap, both lower limb painted and draped .standard arthroscopic portals made. acl myxoid degeneration found ,debulking done.PCL Midsubstance partial tear, PCL bundle sparing reconstruction done with Semi T graft lateral mensicus was found normal Medial meniscus complexe tear found, meniscal balancing done.Medial femoral condyl grade 3 chondral changes present, debridement with micro fracture done. Grade 3 patello femoral arthritic change found. Chondral ablation done . MCL strain with valgus grade 2 instabilit present , MCL repair and augmentation done with gracilis graft using tunneless technique ( suture anchor 2.8 mm biotek on femoral sise and staple on tibial side . For PCL reconstruction Semitendinosus quadrupled and graft was prepared . Femoral tunnel size of 9 mm and tibial tunnels of size 9mm were made. graft was fixed using tight rope ABS endobutton and osteowin screw on femoral side and tight rope ABS button 14 MM and swive lock (arthrex) on tibial side. Joint was stable .wash given and closure done after keeping drain situ. Dressing applied. Distal pulse felt. Long knee brace applied.

Check X Ray position satisfactory
Post operative period was uneventful
Post operatively physiotherphy given

| | | | | | |
|---|---|---|---|---|---|
| Lab No. | :25/02/001282 | MRN | :166942 | Collected On | :13/02/2025 4.03 PM |
| Patient | :Mr.SENTHILKUMAR.R | IP/OP No | :OP/24050164 | Reported On | :13/02/2025 8.10 PM |
| Age / Sex | :50 Years / MALE | Bill No | :24082510 | Validated On | :13/02/2025 8.10 PM |
| Cons. By | :Dr. PRAHALADKUMAR SINGHI D. | MobileNo | :9486495964 | Printed On | :13/02/2025 11.03 PM |



## Final Report

| Specimen | Test Description | Result / Units | Reference Range |
|---|---|---|---|
| BLOOD | CLOTTING TIME<br>CAPILLARY METHOD | **5 Minutes 30 Sec** | 3 -10 |

----------End of Report----------

Lab Technician

Dr.M.R.Vasanthapriyan,M.D.,
Consultant Microbiologist

# DISCHARGE SUMMARY

**CVS** : S1 S2 +
**R/S** : BAE +
**P/A** : Soft
**CNS** : NFND

**LOCAL EXAMINATION:**

**Right knee:**

**Inspection**

Swelling present / Thigh muscle wasting seen
No discharging sinus / wound

**Palpation**

No warmth
Medial joint line tenderness present
Range of movements $0^o$ - $120^o$
Lachman test positive
Anterior drawer grade II
Posterior drawer grade II
Posterior sag postive
Valgul instability grade II
Varus instability grade I
Mcmurray's test painful
Distal pulse present
Sensation intact

**INVESTIGATIONS:**

**Blood investigations -** Enclosed

**X-RAY: Right knee AP/LAT - NAD**

**3 TESLA-MRI REPORT: - RIGHT KNEE JOINT done on 10.02.2025**

**CONCLUSION: -**

1. Myxoid degeneration of ACL with diffuse hyperintense signals and intrasubstance tear noted.
2. Mid substance tear of PCL with diffuse hyperintense signals and hyper buckling noted.
3. Degeneration with horizontal tear seen in posterior horn of medial meniscus.
4. Radial tear seen in body of medial meniscus.
5. Grade II sprain of MCL with partial tear of meniscocapsular ligaments.
6. Postero lateral corner injury with partial tear of FCL, popliteus muscle, popliteo fibular ligament and arcuate ligament noted.
7. Lateral meniscus appears normal in signal intensity.

PIMS PREETHI HOSPITALS
Preethi Institute of Medical Science & Research
50, Melur Main Road, Uthangudi,
Madurai - 625 107
0452-421 9995 / 6 / 7, 78 100 44 444
Web : www.preethihospitals.com

| Name:Mr.Senthil kumar | Age/Sex: 50Yrs/Male | MRN No:166942 |
|---|---|---|
| Patient Type: IP | | Date:13.02.2025 |

# ECHOCARDIOGRAM

**DIMENSIONS:**

| | | |
|---|---|---|
| AO(ed) | 2.7cm | Normal(2.2-4.0cm) |
| LA(ed) | 2.8cm | Normal(2.7-4.0cm) |
| LVID(ed) | 4.4cm | Normal(3.9-5.7cm) |
| LVID(es) | 3.0cm | Normal(2.1-4.0cm) |
| IVS(ed) | 0.9cm | Normal(0.6-1.2cm) |
| IVS(es) | 1.1cm | Normal(0.8-1.4cm) |
| LVPW(ed) | 0.8cm | Normal(0.6-1.1cm) |
| EF | 60% | Normal(>=60%) |
| FS | 29% | Normal(>=28%) |

**MORPHOLOGICAL DATA**

AML : Normal
PML : Normal
Aortic Valve : Normal
Tricuspid Valve : Normal
Pulmonary Valve : Normal
Right Ventricle : Normal
Interataial Septum : Intact
Interventricular Septum :Intact
Pulmonary Artery : Normal
Aorta : Normal
Right Atrium : Normal
Left Atrium : Normal
Pericardium : Normal
Left Ventricle : Mild concentric LVH present. No RWMA. Normal LV systolic function.

| | | | | | |
|---|---|---|---|---|---|
| Lab No. | :25/02/001282 | MRN | :166942 | | |
| Patient | :Mr.SENTHILKUMAR.R | IP/OP No | :OP/24050164 | Collected On | :13/02/2025 4.03 PM |
| Age / Sex | :50 Years / MALE | Bill No | :24082510 | Reported On | :13/02/2025 8.10 PM |
| Cons. By | :Dr. PRAHALADKUMAR SINGHI D. | MobileNo | :9486495964 | Validated On | :13/02/2025 8.10 PM |
| | | | | Printed On | :13/02/2025 11.03 PM |



## Final Report

| Specimen | Test Description | Result / Units | Reference Range |
|---|---|---|---|
| BLOOD | MCH<br>CALCULATION | 30 pg | 26 - 33 |
| BLOOD | MCHC<br>CALCULATED | 35 % | 32 - 36 |
| BLOOD | Platelet count<br>ELECTRICAL IMPEDANCE | 2.37 Lakhs/ cumm | 1.5 - 4.0 |

**BIOCHEMISTRY**

**BLOOD ROUTINE**

| | | | |
|---|---|---|---|
| Plasma | RANDOM BLOOD GLUCOSE<br>GOD - POD METHOD | 157 mg/dL ↑ | 80 - 140 |
| SERUM | UREA<br>UREASE - GLDH | 17 mg/dL | 15-39 |

**Increased in: Renal failure (acute or chronic), urinary tract obstruction, dehydration, shock, burns, CHF, GI bleeding.Nephrotoxic drugs (eg, gentamicin).**

**Decreased in: Hepatic failure, nephrotic syndrome, cachexia (low-protein and high-carbohydrate diets).**

| | | | |
|---|---|---|---|
| SERUM | CREATININE<br>JAFFE KINETIC METHOD | 0.76 mg/dL | 0.7 - 1.2 |

**Increased in: Acute or chronic renal failure, urinary tract obstruction, nephrotoxic drugs, hypothyroidism.**

**Decreased in: Reduced muscle mass.**

| | | | |
|---|---|---|---|
| BLOOD | HBA1C<br>HBA1C HLC | 7.3 % | 4.0- 6.0 - Non -Diabetic<br>6.1 -7.0 - Good Control<br>7.1 - 10.0 - Unsatisfactory<br>>10.0 - Poor Control |
| BLOOD | EMG<br>CALCULATION | 163 mgs / dl | 68 - 125 - Excellent Control ,<br>128-154 - Good Control ,<br>157- 183 - Average Control ,<br>>241 - Panic Control |

Lab Technician

Dr.M.R.Vasanthapriyan,M.D.,
Consultant Microbiologist

| | | | | | |
|---|---|---|---|---|---|
| Lab No. | :25/02/001282 | MRN | :166942 | | |
| Patient | :Mr.SENTHILKUMAR.R | IP/OP No | :OP/24050164 | Collected On | :13/02/2025 4.03 PM |
| Age / Sex | :50 Years / MALE | Bill No | :24082510 | Reported On | :13/02/2025 8.10 PM |
| Cons. By | :Dr. PRAHALADKUMAR SINGHI D. | MobileNo | :9486495964 | Validated On | :13/02/2025 8.10 PM |
| | | | | Printed On | :13/02/2025 11.03 PM |



## Final Report

| Specimen | Test Description | Result / Units | Reference Range |
|---|---|---|---|
| BLOOD | CALCULATION | | |
| **BLOOD GROUP** | | | |
| **BLOOD ROUTINE** | | | |
| BLOOD | BLOOD GROUP<br>SLIDE METHOD | A | |
| Sample whole blood EDTA | | | |
| BLOOD | RH TYPE<br>SLIDE METHOD | Positive | |
| Sample whole blood EDTA | | | |
| **SEROLOGY** | | | |
| BLOOD | C - Reactive Protein<br>TURBIDIMETRY | 1.9 mg/L | 0 - 5.0 |
| Increased in: Inflammatory states. | | | |
| **BLOOD ROUTINE** | | | |
| BLOOD | HIV I & II<br>TRI-DOT METHOD | Non -Reactive | |
| BLOOD | HbsAg<br>RAPID CARD METHOD | Negative | |
| BLOOD | HCV<br>RAPID CARD METHOD | Negative | |
| *Note:It is A Screening Tests Only.So it should be Confirmed with ELISA (or)Other Superior Methods. | | | |
| **COAGULATION** | | | |
| **BLOOD ROUTINE** | | | |
| SKIN | BLEEDING TIME<br>CAPILLARY METHOD | 3 Minutes | 2 - 6 |

Lab Technician

Dr.M.R.Vasanthapriyan,M.D.,
Consultant Microbiologist

3-02-2025 04:01:53 PM

CARDIART

ID: 166942
MR.SENTHIL KUMAR
Male 50Years

| | | |
|---|---|---|
| HR | : 83 | bpm |
| P | : 112 | ms |
| PR | : 177 | ms |
| QRS | : 93 | ms |
| QT/QTc | : 351/413 | ms |
| P/QRS/T | : 58/45/48 | ° |
| RV5/SV1 | : 0.75/1.62 | mV |

Diagnosis Information:
Sinus Rhythm
Left Anterior Hemi Block
Poor R Wave Progression(V4)

Report Confirmed by:

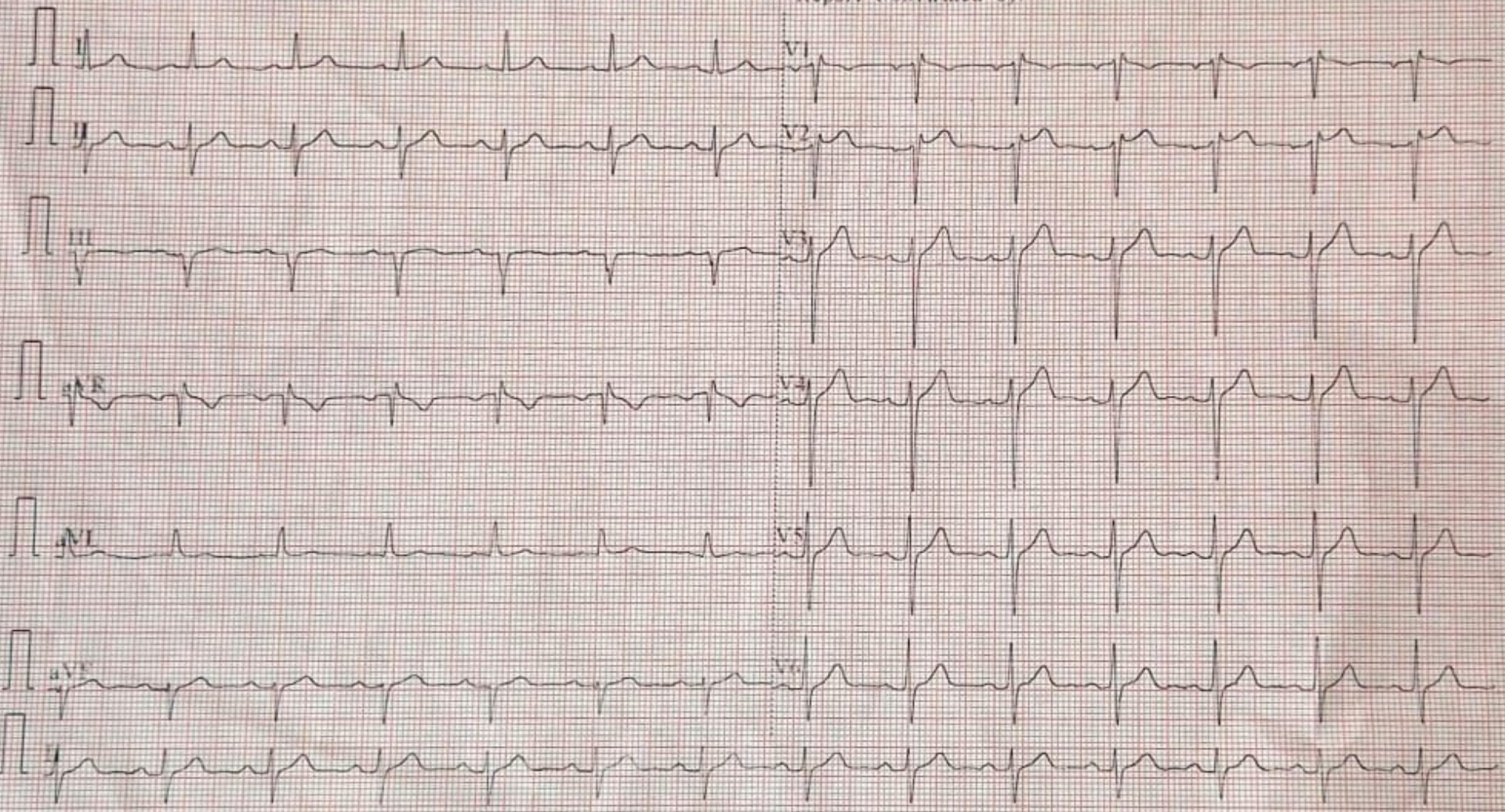


50Hz At 50 25mm/s (10mm/mV) 2.5cm/s ♥55 57.00 SEMIP V1.7 Preethi Multispecialty Hospital

BPL

IMS PREETHI HOSPITALS
Preethi Institute of Medical Science & Research
50, Melur Main Road, Uthangudi,
Madurai - 625 107
0452-421 9995 / 6 / 7, 78 100 44 444
Web : www.preethihospitals.com

**COLOUR AND DOPPLER STUDIES:**

| | | |
|---|---|---|
| Mitral valve in flow study | E | : 0.6 M/Sec |
| | A | : 0.8 M/Sec |
| Velocity across the aortic valve | | : 1.3 M/Sec |
| Velocity across the pulmonary valve | | : 1.2 M/Sec |
| Velocity across the Tricuspid valve | | : 1.8 M/Sec |

**IMPRESSION:**

**Mild concentric LVH present**

**Normal LV systolic function**

**EF: 60 %**

**Valves-Normal**

**Grade I diastolic dysfunction**

**Dr.P.SHANKAR MD.,DM(cardio)**
**Consultant Interventional Cardiologist**