DENT 3123 IMPLANT DENTISTRY

BASIC PRINCIPLES ON DENTAL IMPLANTS PRE-CLINICAL MANUAL 2025

Department of Prosthodontics
LSU School of Dentistry

Authors:
Deema Suleiman, BS
Lauren Schafer, BS

Dr. Jorge Palavicini, DDS
Dr. Alejandro Trevino, DDS, MSc

Grade Definition:

- Grade definitions for bench top lab and daily lab grades utilize the "1" to "4" Quality Point System grading scale as follows:

4 = 100

3 = 80

2 = 60

1 = 40

- **"4" Clinically Superior.**
- The lab procedure exceeds all criteria and needs no further changes. The student exemplified understanding of the lab project and presented exceptional work.
-
- **"3" Clinically Acceptable.**
- The lab procedure meets the minimum criteria to be clinically acceptable. The student needs to make minor changes to improve quality of work and recognizes their clinical errors.
-
- **"2" Clinically Unacceptable (Correctable).**
- The lab procedure was completed with major errors but correctable, exhibiting lack of understanding from student. This procedure must be corrected/redone to show knowledge of procedure.
-
- **"1" Clinically Unacceptable (Irreversible)**
- The lab procedure has critical errors that are irreversible and unacceptable due to lack of understanding. This procedure must be corrected/redone to show knowledge of procedure.

Part 1: Basics of Implant Dentistry

What is Dental Implantology?

During the last decade, implantology has become an indispensable part of mainstream dentistry, helping dentists to improve the quality of life of large patient populations. Dental implantology is the field of dentistry concerned with replacing missing teeth and their supporting structures with artificial prostheses anchored to the jawbone.

Edentulism has profound consequences that extend far beyond the mouth. It is not only a functional problem, but also a psychological, social, nutritional and esthetic one. Patients who lose teeth often suffer from:

- **Diminished chewing efficiency**
- **Collapse of the Vertical Dimension of Occlusion (VDO)**
- **Bone loss in the jaws**
- **Phonetic problems**
- **Altered facial esthetics**

This can lead to a cascade of issues, including social stigma, reduced self-esteem, poor nutrition due to dietary restrictions and even medical complications from the need to rely on softer, less nutritious foods.

Traditional solutions such as fixed dental prostheses (FDPs) and removable partial dentures (RPDs) have been used for decades to replace missing teeth, but both carry long term disadvantages. Bridges often sacrifice healthy abutment teeth and fail to prevent bone loss in the edentulous span, while removable partial dentures are poorly tolerated by many patients, accelerate bone resorption and have high failure rates of both the prothesis and supporting teeth. In contrast, dental implants have emerged as the gold standard for tooth replacement because of their superior ability to restore function, comfort, esthetics and long-term bone preservation.

Implant

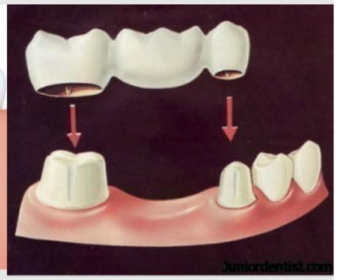

FDP

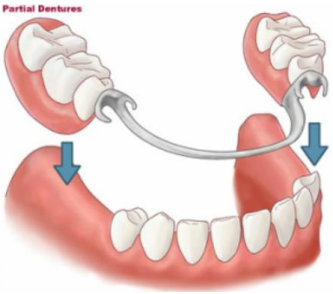

RPD

Throughout history, a variety of materials have been tested, however, the development of the most successful material, Titanium, was discovered by Brånemark, a Swedish orthopedic surgeon. Today, there are multiple materials, implants, components and techniques available.

What is a Dental Implant

A dental implant is defined as a prosthetic device made of alloplastic material, most commonly titanium or zirconia, that is surgically inserted into the oral tissues beneath the mucosa or periosteum and within bone. Its primary purpose is to provide support and retention for either a fixed or removable prosthesis, essentially serving as an artificial tooth root in edentulous or extraction sites. Titanium has become the material of choice because it is biologically inert, does not trigger a foreign body reaction and readily bonds with bone through the process of osseointegration. Zirconia implants have also been developed as a more esthetic option, though they are more brittle than titanium.

<u>Types of Implants</u>:

1. **Endosteal** (Endosseous Implants)
Surgically placed within bone. Tissue level or Bone level implants. (Most common)

2. **Eposteal** (Subperiosteal Implants)
Placed on top of bone, beneath periosteum. Retention is through fibrointegration only (implant floating, not osseointegrated). Very expensive, technique sensitive, need to raise a huge flap to be successful

3. **Transosteal** (Transmandibular Implants)
Implant runs through entire mandible. Very invasive, high complication risk and risk of mandibular fracture. Not used anymore.

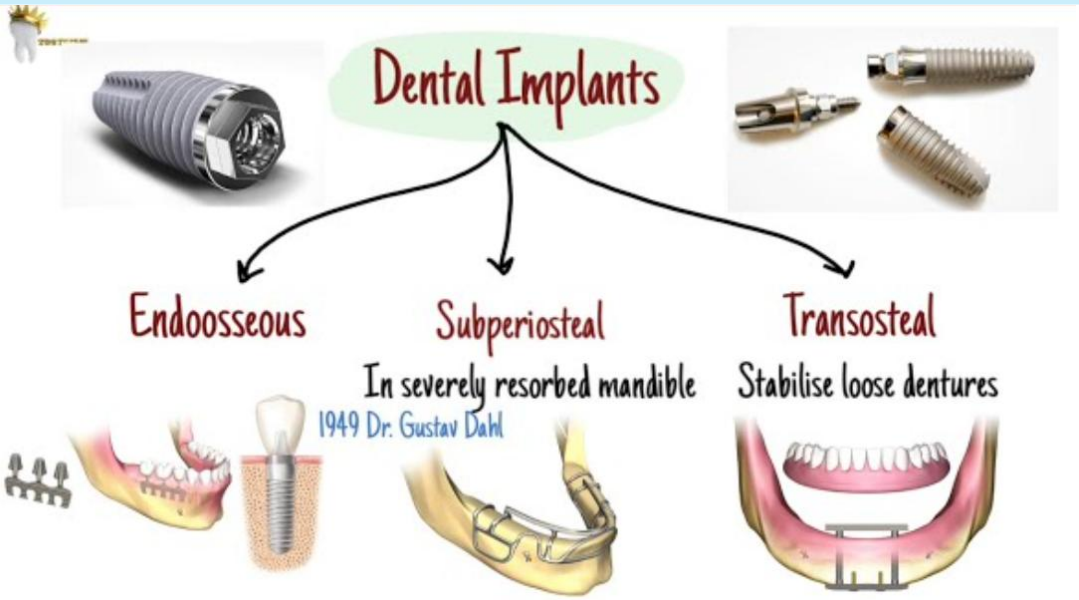

The design of an implant is crucial to its success. Most contemporary implants are **root-form, endosseous** implants which may be cylindrical, screw-shaped, or a combination of both.

Osseointegration

Branemark described the process of osseointegration as “a direct structural and functional connection between ordered living bone and the surface of a load-carrying implant”.

The biologic foundation of implantology is osseointegration, a direct, structural, and functional union between living bone and the surface of the implant without intervening connective tissue. This differs from fibrointegration, in which fibrous tissue encapsulates the implant, leading to failure.

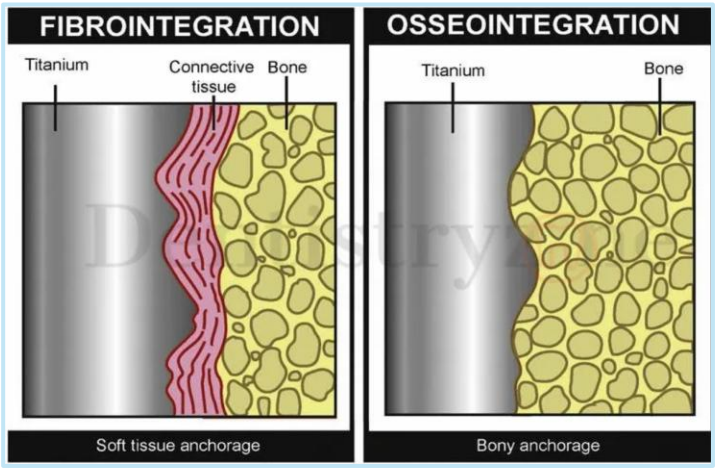

Osseointegration occurs through a healing process beginning with necrosis and resorption of traumatized bone, followed by new bone formation and remodeling. By two to three weeks, initial remodeling has begun, and by three to six weeks, osseointegration is actively progressing. Initially, implants rely on primary stability—mechanical tightness of the implant in bone. Over time, this transitions to secondary stability, the biologic bond as new bone forms at the interface. The “critical weak period” occurs between the third and fourth weeks, when primary stability decreases before secondary stability is fully established, and most implant failures occur during this time. Surface modifications such as SLA (sandblasted, large-grit, acid-etched) or SLActive (hydrophilic chemically treated surfaces) have shortened healing times by improving bone response (a shortened healing period shifts the critical weak phase to an earlier time, coinciding with greater patient motivation and adherence to post-operative guidelines).

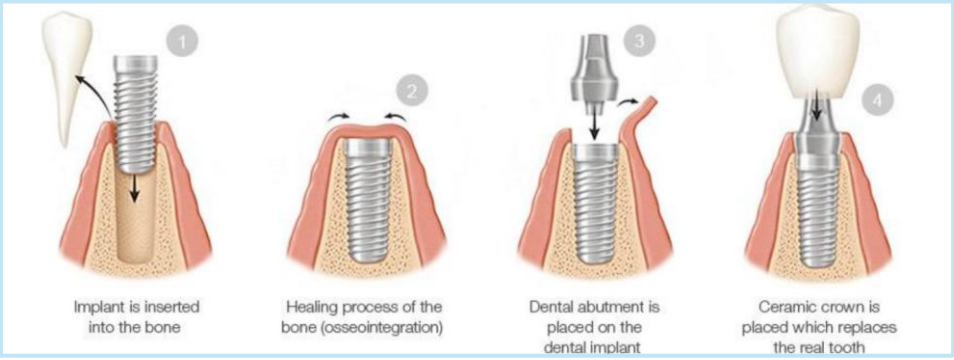

Tissue around a Tooth Vs. Implant

Although dental implants are designed to mimic natural teeth, the soft and hard tissues surrounding them are biologically different. These differences have important clinical implications for maintenance and long-term success.

Around a natural tooth, the periodontal ligament supplies a rich vascular network and supports an array of collagen fiber groups, including transseptal and gingivodental fibers, which insert into cementum and bone. This ligament not only nourishes the tissues but also provides a shock-absorbing function and sensory feedback. By contrast, peri-implant tissues have a reduced blood supply and lack the transseptal and gingivodental fiber insertions that are characteristic of periodontal tissues. Instead of inserting into a cementum layer, collagen fibers run parallel to the implant surface. A junctional epithelium does form and attaches to the implant abutment, creating a seal, but there is no true periodontal ligament around an implant. Instead, the implant is fused directly to bone through osseointegration.

Because of this direct bone contact, implants lack the sensory feedback of occlusal forces that natural teeth enjoy. Patients do not feel pressure or early overload in the same way, and clinicians cannot rely on the “physiologic give” of the periodontal ligament. This absence of proprioception and cushioning can contribute to mechanical complications such as screw loosening or fracture of the prosthesis if occlusion is not carefully monitored. For these reasons, ongoing clinical evaluation of implant restorations is essential, with particular attention to signs such as prosthesis fracture, accelerated attrition, and redness or swelling of the peri-implant mucosa, which may indicate overload or inflammation.

Understanding these fundamental differences between the tissues around teeth and implants help guide implant design, occlusal adjustment, and maintenance protocols to support long-term stability.

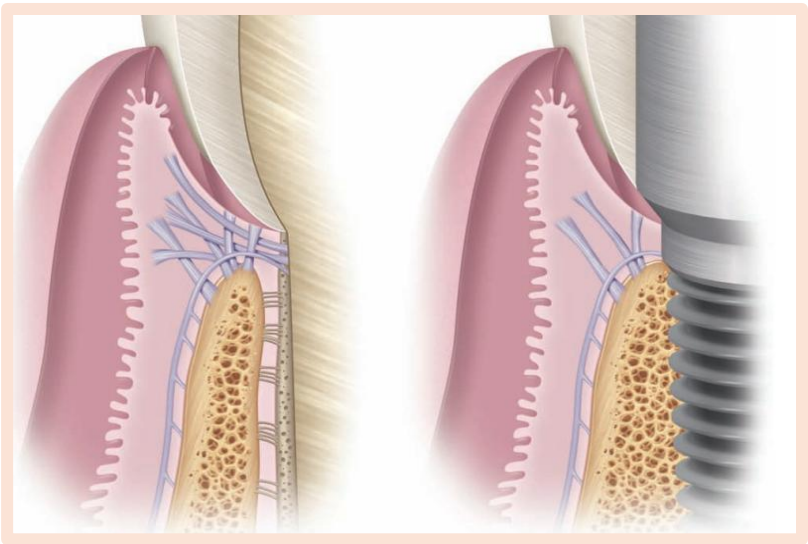

Advantages + Disadvantages of Implants

Advantages of Implant-Supported Prostheses:

- **Maintaining the heigh and weight of the alveolar bone**
- **Restoring and maintaining the occlusal vertical dimension**
- **Preserving facial esthetics**
- **Phonetics and occlusion**
- **Increasing prosthesis success rate**
- **Improving masticatory performance by maintaining the muscles of mastication and facial expression**

Disadvantages of Implant-Supported Prostheses:

- **Implant treatment is expensive**
- **Cannot be performed in patients who are medically unable to undergo surgery**
- **Usually takes longer to complete the conventional prostheses**
- **Requires adequate bone quality and volume**

Absolute Contraindications of Implants:

- **Patients receiving bisphosphonate therapy for osteoporosis or some cancers**
- **Patients with certain immunological diseases**
- **Patients undergoing immunosuppressant therapy or with clinical AIDS**
- **Patients on chronic steroid therapy**

These conditions compromise bone healing and increase the risk of implant failure.

Where can Implants be placed?

Bone density and quality are central to implant planning. CBCT is the standard tool for assessing bone width, height, length, and angulation (4D preparation). Bone density is measured in Hounsfield units: air measures –1024, water 0, and enamel +3000. D1 bone (>1000 HU) is dense cortical bone and offers excellent stability, while D4 bone (<150 HU) is soft, trabecular, and highly prone to implant failure. Planning also requires maintaining at least 1.5 mm between an implant and a natural tooth root, and 3 mm between adjacent implants. Anatomic limitations such as the maxillary sinus and inferior alveolar nerve must always be respected.



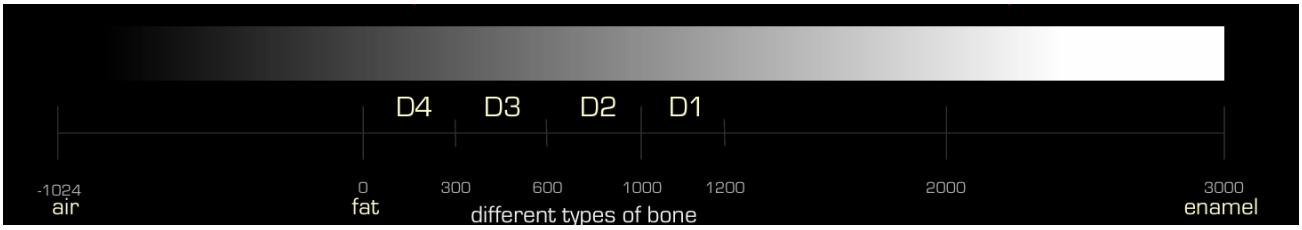

D1 – Thick compact bone Anterior segment of the atrophic, edentulous mandible	Advantages: – good primary stability of the implants – expansive implant-bone interface – use of short implants is possible Disadvantages: – reduced blood supply (longer healing phase) – often short bone height (implant–crown ratio) – difficult implant bed preparation (overheating)
D2 – Thick, porous compact bone – highly trabecular core Anterior and posterior segment of mandible Anterior maxillary segment (palatal aspect)	Advantages: – good primary stability – good healing tendency (blood supply) – easy implant bed preparation Disadvantages: – none
D3 – Thin, porous compact bone – loosely structured cancellous bone Anterior (facial aspect) and posterior segments of the maxilla Posterior segments of the mandible Condition following osteoplasty of Class D2 bone	Advantages: – good blood supply Disadvantages: – difficult implant bed preparation (widening) – optimum usage of available bone is necessary – reduced implant–bone interface (increased number of implants)
D4 – Loose, thin cancellous bone Maxillary tuberosities Condition following osteoplasty of Class D3 bone	Advantages: – none Disadvantages: – difficult implant bed preparation (primary stability) – optimum usage of available bone is necessary – reduced implant–bone interface (increased number of implants)

How Bone density Affects the Surgical Phase

The surgical phase of implant placement demands precision. A sterile surgical setup is essential, often with preoperative rinses or antibiotic prophylaxis. Local anesthesia is standard, with nerve blocks used safely when guided by CBCT planning. Incisions are commonly mid-crestal, and flaps must provide visibility without excessive trauma. Osteotomy preparation follows strict drilling protocols: sharp drills, intermittent pressure, low speed, copious irrigation, and respect for drill sequence. Protocols vary by bone type: Type 1 bone requires profiling and tapping, Type 2 requires profiling only, Type 3 requires only drilling, and Type 4 often requires under-preparation to maximize thread engagement. Implants may be submerged, requiring a second-stage uncovering, or non-submerged with healing abutments placed immediately. Postoperatively, patients should expect swelling, mild pain, and temporary function limitations, with sutures removed after one to two weeks.

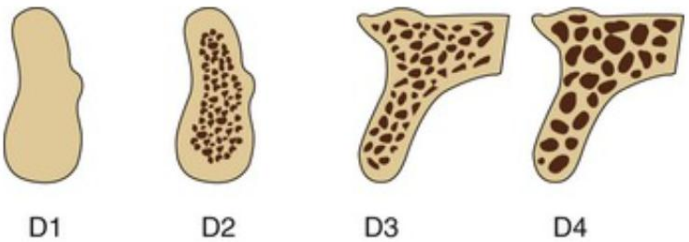

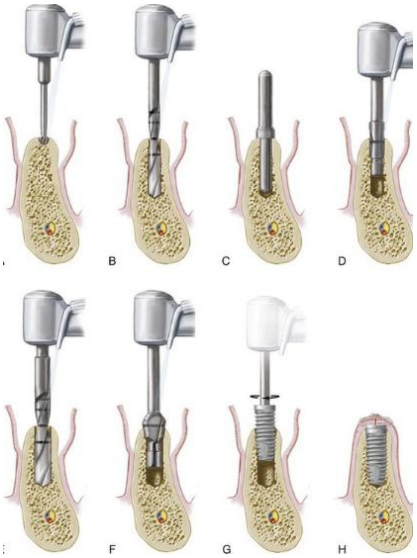

Osseointegration + loading

Osseointegration is the biologic mechanism by which bone forms a direct attachment to the implant surface without intervening soft tissue. Once an implant is placed, it should exhibit minimal movement while bone biologically adheres to its surface. An implant placed into bone with a high percentage of cortical component (D1/2) will have greater primary stability and be less susceptible to micromovement during osseointegration. In contrast, a site with predominantly cancellous bone (D4) provides less primary stability, making the interface more susceptible to occlusal and other forces. This difference is managed clinically by delaying loading: implants with borderline stability are covered by soft tissue and left unloaded until sufficient osseointegration has occurred. In areas where primary stability is good, **immediate loading**—connecting a prosthesis at the time of placement—is possible. Conventional loading, by contrast, defers restoration until after an initial three- to six-month healing period, depending on bone density.

Components of an Implant

The implant itself is composed of several parts: the crown, the abutment, the crest module or platform, the main body and the apex.

At the crest module (platform), the implant retains prosthetic components and may be polished to reduce bacterial invasion. The platform serves as the connection area for abutments and resists occlusal loads.

Several implant connections exist, including external hexagon, internal hexagon and conical connections. Most modern systems favor internal or conical connections, as external connections are more prone to micromovement and crestal bone loss.

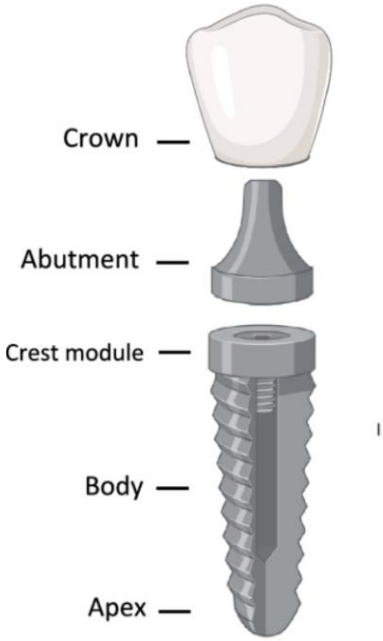

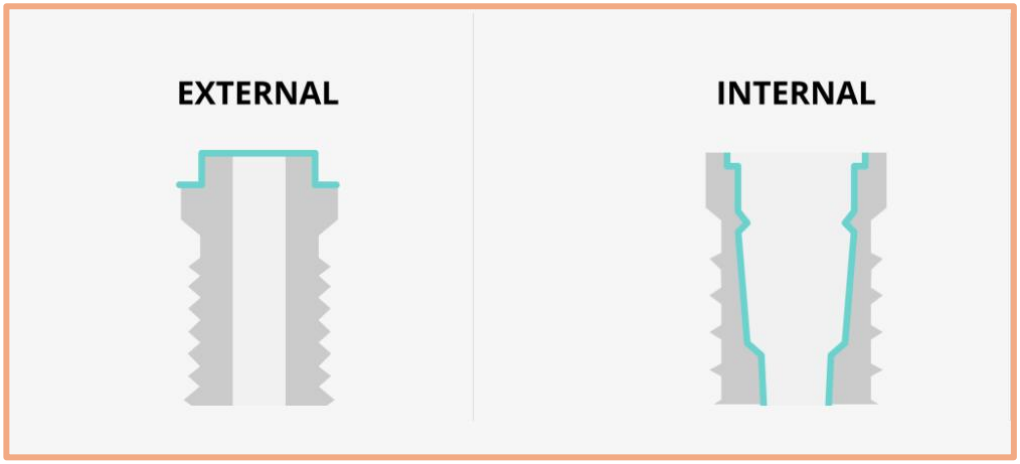



The diameter of implants can range from narrow to wide; the selection depends on mechanical demands, anatomical limitations and esthetic requirements. Narrow implants, for example, cannot reliably support molars, and placement of wide implants may not be possible in areas of poor bone quality.

More Classifications of Implants

Based on the implant **body** they may be cylindrical, threaded, plateau-form, perforated, solid, or vented. Based on **surface finish** they may be smooth, machined, textured, or coated. The **implant microstructure**—its surface structure and degree of roughness—has a major influence on osseointegration. Conventional machined surfaces can be modified using additive methods such as hydroxyapatite coating or plasma spraying, or subtractive methods such as acid-etching or sandblasting. These modifications increase the bio-affinity of titanium, accelerating bone response and improving the quality of the bone–implant interface.

Implants may be one-piece, in which the abutment is permanently attached to the implant body, or two-piece systems, in which the abutment and implant body are separate. One-piece implants eliminate the need for a second stage of surgery but require flawless placement since angulation cannot be corrected prosthetically. Two-piece implants are far more common, as they allow greater prosthetic flexibility including correction of angulation once implant has been placed.

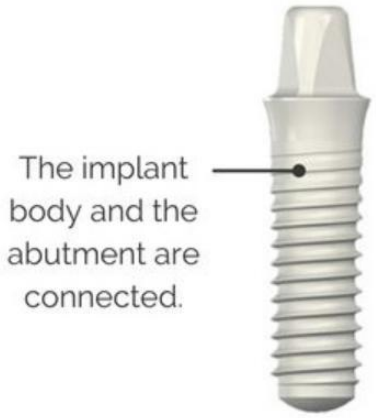

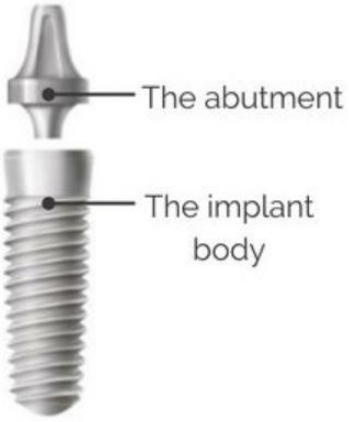

Different Abutments and Related Components

In implant dentistry, various components work together to ensure successful healing, accurate prosthetic fabrication, and long-term function. Among these, abutments play a central role, and each type has a distinct purpose and timing within treatment.

The **healing abutment** is a temporary component placed to assist both healing and the shaping of peri-implant soft tissues. Its main functions are to promote soft tissue healing following surgery and to shape the gingiva around the implant in preparation for the future prosthetic component. Healing abutments are available in different heights and widths to accommodate various tissue profiles. In a one-stage surgery, the healing abutment is placed immediately at the time of implant insertion, allowing the tissue to heal directly around it. In a two-stage surgery, a cover screw is placed and the site is closed initially; the clinician then returns at a later appointment to uncover the implant and insert the healing abutment. **cover screw** is often placed on the superior surface of the implant to allow the gingiva to grow over and seal it

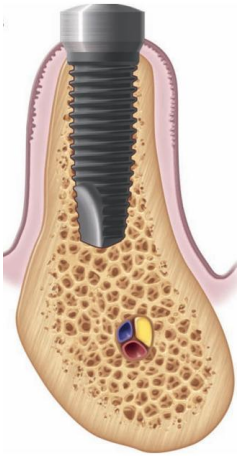

Healing abutment

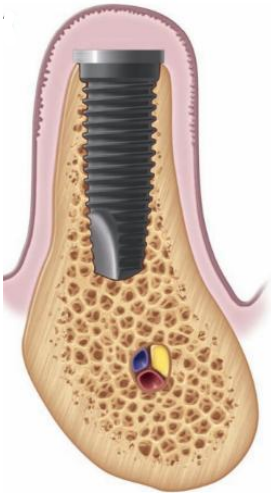

Cover screw

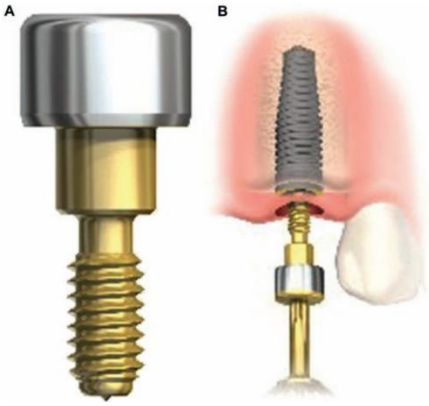

Placement of healing abutment

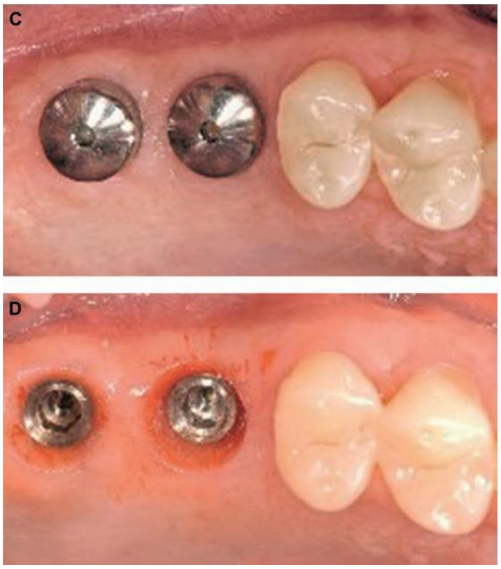

Removal of healing abutment

The **prosthetic abutment** is the permanent element that supports and retains the final prosthesis, resembles a prepared tooth and is screwed into the implant body to retain the prosthesis. Several types of prosthetic abutments are available. Prefabricated, or stock, abutments are manufacturer-made and intended for standard use. Customizable “UCLA” abutments consist of a plastic abutment with a titanium connection that can be waxed and cast to achieve a custom shape. CAD/CAM custom abutments are digitally designed and milled to match the individual patient’s requirements. Locator abutments are used specifically for removable overdentures, while transmucosal (multi-unit) abutments connect multi-unit prostheses through the soft tissues. The visible **crown**, made of porcelain or metal, replicates the original tooth’s biting surface and esthetics.



To accurately reproduce the intraoral position of the implant in the laboratory, **impression copings** are employed. These are components attached to the implant during impression taking so that the implant's position can be transferred to the working cast. Open-tray impression copings are long and retentive and are typically used in multiple-implant or angulated cases, whereas closed-tray impression copings are shorter and less retentive, making them more suitable for single implants with favorable angulation (discussed further in the next section).

When you take an impression of an implant, you're capturing location and orientation of the implant's connection (not body or apex).

Once the impression is made, an **analog or replica** of the implant platform and connection is placed into the impression to create the working cast. This analog must match the implant's connection type exactly—whether it is an external hex, internal hex, or another configuration—because mixing systems or brands can introduce inaccuracies. As a rule, implant components from different systems should never be interchanged. When the stone model is poured and set, the analog becomes embedded in the cast, and serves as a "stand-in" for the real implant in the mouth. Abutments and prosthetic components can then be tried, adjusted or fabricated on this model as if they were being done directly on the implant itself.

Analogs used to reproduce exact position and connection of dental implant inside mouth

Analog in a stone cast

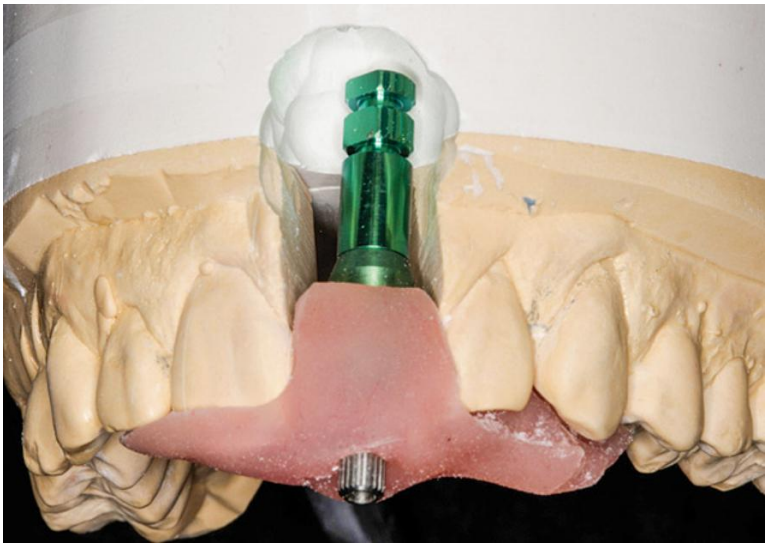

Taking Impressions for Implant Restorations

The purpose of an impression is to transfer the exact three-dimensional position of the implant connection from the patient's mouth to a working model. This working cast allows the laboratory to fabricate a restoration that fits precisely. The impression does not record the implant's body, apex, or thread design; rather, it captures the spatial relationship of the connection so the definitive prosthesis can be built on an accurate replica. Once the impression is taken intraorally, an implant analog is inserted into the impression to reproduce the connection within the cast, and the model is poured. In this way, the clinician and technician obtain an exact copy of the implant's location and orientation for prosthetic planning.

High-quality impression materials such as polyvinyl siloxane (PVS) or polyether are used because they can precisely reproduce implant and abutment details. The material must be accurate, rigid enough to retain the impression coping and implant analog during pouring, and viscous enough not to distort soft tissues. Accurate transfer of the implant position to the working cast is critical for prosthetic success.

Implant impressions can be made at two different levels. An **implant-level impression** is taken directly at the implant platform using an impression coping; the coping must be fully seated, and if soft tissue prevents seating, inaccuracies will result. An **abutment-level impression** is made after an abutment has been placed. In either case, the aim is the same: to transfer the precise position of the implant connection to the cast.

Two principal techniques are used for implant-level impressions: the closed-tray (indirect or transfer) technique and the open-tray (direct or pick-up) technique. Closed-tray copings stay in the mouth after taking the impression and must be repositioned into the impression (simpler, but less forgiving). Open-tray copings stay in the impression, are more accurate and require a special tray.

Closed-Tray Technique

The **closed-tray technique** involves an impression coping that is short, smooth and tapered. This method requires careful repositioning of the coping into the impression after it has been removed from the mouth and is most often indicated for single implants with good angulation and adequate inter-arch space. Once the impression tray is removed from the mouth, the impression coping stay attached to the implant and must be later unscrewed, connected to an implant analog, and then repositioned back into the impression before pouring the cast. Technique sequence is as follows:

1. Remove the healing abutment to expose implant platform
2. Place closed-tray impression coping into the implant
3. Take Radiograph to ensure coping is completely seated on implant connection
4. Take the impression using PVS or polyether
5. Remove impression tray (impression coping stays attached to implant in the mouth)
6. Unscrew and remove impression coping from the implant in the mouth
7. Replace healing abutment in the mouth
8. Attach the impression coping to the implant analog (outside the mouth)
9. Place the coping-analog unit into the impression at the exact location it occupied in the mouth
10. Duplicate soft tissue if required and pour the cast

Open-Tray Technique

The **open-tray technique** uses an impression coping that remains locked in the impression, eliminating the error associated with repositioning. This technique requires perforating the tray to allow access to the coping screws and is indicated for severely angled implants or multiple implants in an arch. It reduces the possibility of human error since the copings are picked up inside the impression rather than repositioned later, but is more time-consuming, needs a custom or plastic tray, and is not ideal in posterior regions where space is limited. Technique sequence is as follows:

1. Remove the healing abutment
2. Place the open-tray impression coping
3. Take Radiograph to ensure coping is completely seated on implant connection
4. Perforate impression tray so the coping screw can protrude through it
5. Take the impression using PVS or polyether
6. Unscrew each coping through the holes to loosen them
7. Remove the tray, copings remain embedded into the impression material
8. Replace healing abutments in the mouth
9. With the coping still embedded into the impression, attach analog to coping
10. Duplicate soft tissue if required and pour the cast

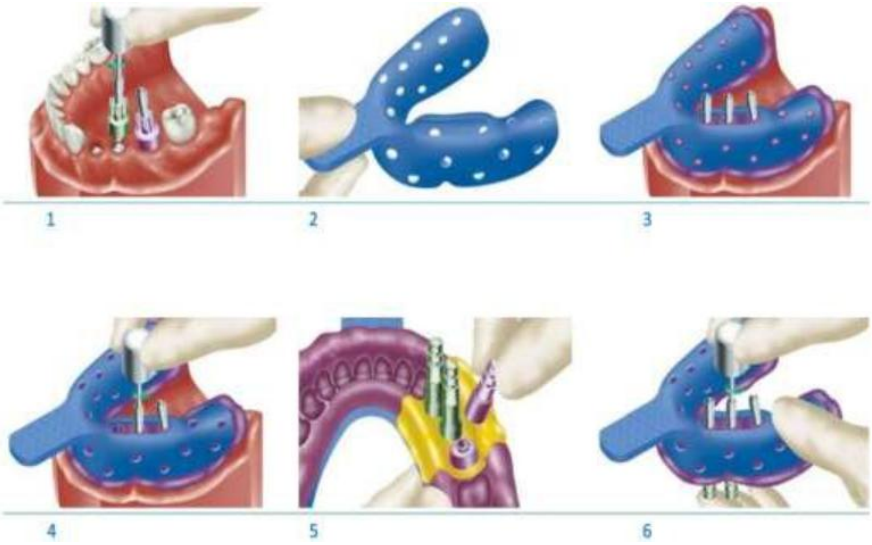

Cement- Retained vs. Screw-Retained Implants

One of the key decisions in treatment planning is whether to use a cement-retained or a screw-retained restoration. Each approach has distinct indications, advantages, and disadvantages that influence long-term success and maintenance.

Screw-retained prostheses are recommended in several clinical scenarios. They are particularly indicated for long-span prostheses and situations where inter-arch space is minimal. Because they do not require cement, screw-retained restorations eliminate the risk of residual cement and the peri-implantitis it can cause. They are also chosen when retrievability is important, since the prosthesis can be easily removed for maintenance or repair. Clinically, screw-retained prostheses are preferred whenever maintenance and retrievability are priorities, and they completely remove the risk of hidden cement. However, they do require ideal implant positioning to ensure the screw channel aligns properly, and the clinician must always check crown or framework seating and marginal fit on the working model with a dental explorer before finalizing. Their disadvantage lies in the potential esthetic compromise if the screw access hole emerges through a visible portion of the restoration.

Cemented restorations have their own set of advantages and disadvantages. Their primary advantages include superior esthetics, better occlusal control, lower cost, a more passive fit, and a simpler clinical procedure. The main disadvantage is the risk of excess cement around the implant, which can lead to peri-implantitis. They are also less retrievable than screw-retained restorations, making maintenance and repair more difficult. Cement-retained crowns therefore offer better esthetics and are typically cheaper, but they carry a higher biological risk if all excess cement is not meticulously removed.

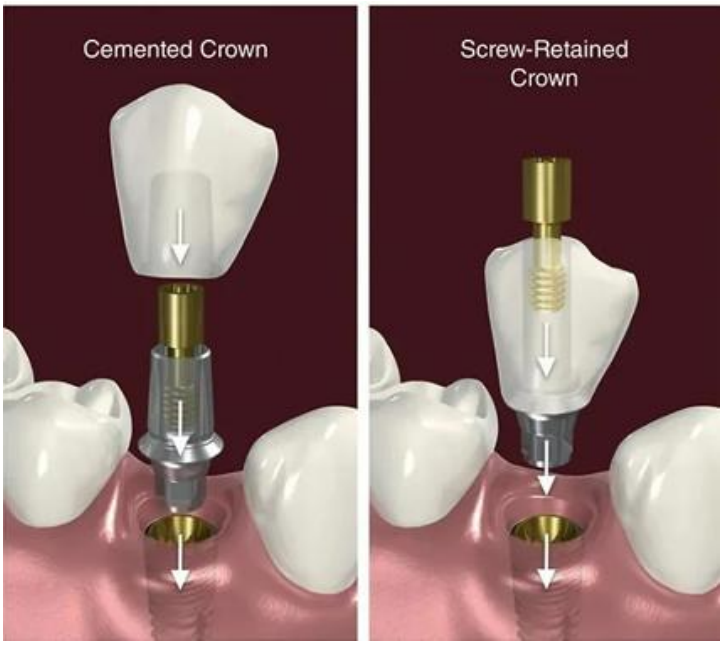

Feature	Cement-Retained	Screw-Retained
Retrievability	Poor (Removing crown usually requires complete replacement)	Good – easily removed for maintenance and cleaning
Cement/Peri-Implantitis Risk	Poor (excess cement is hard to remove → increase risk of peri-implantitis)	Good – no cement →decreased risk of peri-implantitis
Inter-Occlusal Space Requirement	Poor - Needs 6-7 mm (specify why)	Good - works with limited space
Occlusal Esthetics	Good (no access holes visible occlusally)	Poor (screw access holes are visible)

Cement-retained restorations tend to be favored for their esthetics and simplicity but require scrupulous cement removal to avoid biological complications. Screw-retained restorations are better suited for cases where retrievability, minimal space, and soft tissue management are paramount, though they demand precise implant positioning and may require esthetic compromises. Understanding these trade-offs allows clinicians to select the most appropriate retention method for each patient.

When restoring fully edentulous patients the treatment choices are:

Conventional Complete Dentures: Dentures have never been a good substitute for natural teeth. A conventional denture is reliant on the mucoperiosteum for support and retention. The dentures are resting on mucosal tissue and can be easily dislodged by the strong forces of the adjacent muscles. This is a particular issue in the mandible where instability of the denture in function is a common complaint. A stable conventional denture is one which moves little during function. Patients who are 'denture tolerant' often have developed good muscular control and this, rather than the surface fit, results in the successful wear of the prosthesis. Fundamental principles of complete prosthetic design apply whether a conventional or implant-based treatment is being considered.

Removable Implant Overdenture: A removable implant overdenture is a prosthesis removable by the patient and supported or retained by dental implants. The prosthesis has to be removed for the purpose of cleaning the implants. Patients who have been edentulous for a number of years are often 'denture tolerant' and seek treatment to stabilize their progressively loosening dentures rather than always demand the fixed option. These patients invariably present with hard and soft tissue deficit where the aesthetic benefit of acrylic flanges in 27 restoring facial support is crucial to a successful treatment outcome. Facial support and dental aesthetics are more readily restored in this group of patients with implant overdentures rather than a fixed prosthesis.

Screw Hybrid Retained Prosthesis: The hybrid implant restoration is a design which combines the acrylic flange component of a conventional denture with a screw retained restoration on dental implants. There is a metal framework either made from titanium or a cast precious metal and acrylic prosthetic teeth are used to complete the restoration. This reconstruction is non-removable by the patient but, being screw retained, is removable by the clinician. A hybrid implant restoration is typically supported by 4 to 6 implants depending on the available bone volume. The potential disadvantage of this design is the difficulty in access for cleaning. Aesthetics might be more difficult to achieve compared with a removable overdenture as spaces must be incorporated for adequate plaque control and oral hygiene purposes. In the maxilla, phonetics may also be an issue in some patients as the air can escape between the implants and the flange of the hybrid prosthesis. More-over, the acrylic teeth suffer from rapid differential wear or fractures during function. Although, given the operator removability repairs are usually easy, patients should be made aware of these disadvantages and should make provisions for repairs or remedial treatment in years to come.

Part 2: Laboratory Sessions

Lab #1: Duplicate Casts, Diagnostic Wax up and Guide Fabrication

Materials needed:

Impressions
- Rubber bowl
- Mixing spatula
- Impression trays
- Alginate
- Alginate adhesive

Casts
- Yellow dental stone
- Plaster spatula
- Vacuum mixer bowl
- Buffalo knife
- Vibrator
- Model trimmer

Wax up
- Electric Waxer
- Wax BLock
- Waxing instruments

Step 1: Take impression of given cast.

Step 2: Pour up impression in Type III yellow stone, then trim the cast. Make sure there are no bubbles/voids in your cast.

Duplicate Cast Grading:

1	2	3	4	Instructor Initials

Step 3: Wax up either #8 or #5 on your duplicate cast. You may wax up the tooth from scratch or use a denture tooth that fits in the area.

#8 Example with denture tooth:

#5 example with wax up:



Note: You can carefully fill bubbles prior to taking second impression to avoid further voids in second cast.

Diagnostic Wax Up Grading:

1	2	3	4	Instructor Initials

Step 4: Take an impression of your duplicate cast with alginate and pour up your final cast.

Step 5: Surgical Guide Fabrication

Step 1: Block out undercuts on cast with block out material cure using the curing units
Step 2: Scan the code on the machine
Step 3: Peel film off suck down material.
Step 4: Place the A+ suck down material on the left side and the cast on the right
Step 5: Move heat lamp over the material and follow instructions on the machine
Step 6: Pop cast out of Essix (don't worry if it breaks)
Step 7: Trim the guide at the CEJ level using scissors and slow speed handpiece
Step 8: Try on edentulous cast to ensure fit



Essix Grading:

1	2	3	4	Instructor Initials