NEUROIMAGE

# Late-Onset Status Epilepticus Associated With Isolated Leptomeningeal Angioma and Sturge-Weber Syndrome–Related *GNA11* Pathogenic Variation

Louis Cousyn, MD, PhD, Delphine Leclercq, MD, PhD, Minh Chau Ta, François Gilbert, Lucas Di Meglio, Clémence Marois, MD, Andrei Haddad, MD, Bertrand Mathon, MD, Mélanie Eyries, PhD, and Vincent Navarro, MD, PhD

**Correspondence**
Dr. Cousyn
louismarc.cousyn@aphp.fr

*Neurology*® 2023;101:1021-1022. doi:10.1212/WNL.0000000000207839

**Figure 1** Brain MRI Features

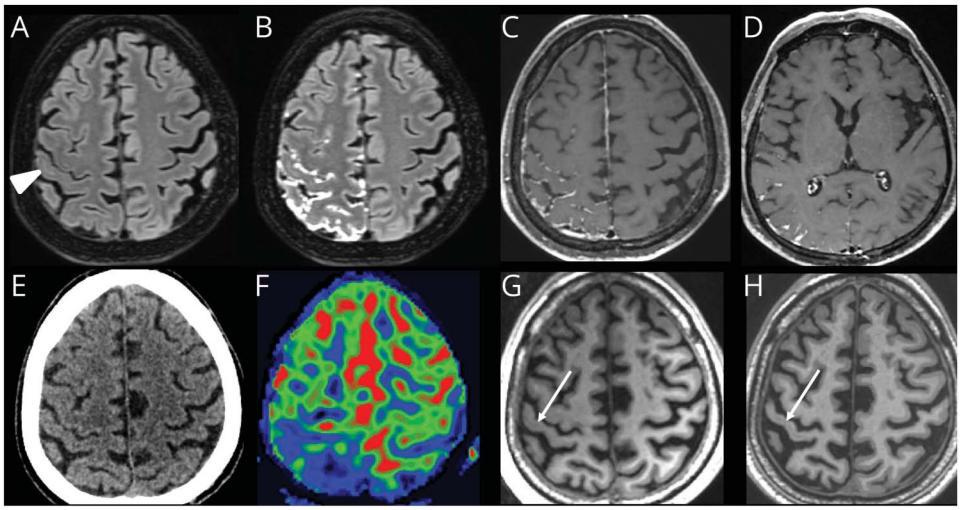


Subcortical hyperintensity on fluid-attenuated inversion recovery (FLAIR) images (A, arrowhead) with local leptomeningeal enhancement more prominent on postcontrast FLAIR images (B) than on T1 postcontrast images (C and D) without plexus choroid hypertrophy (D), uncalcified on CT (E). ASL perfusion map (F) showed local hypoperfusion and T1 images (G and H) showed progressive atrophy (arrows) over 6 months.

A 61-year-old man with no neurologic history presented with 2 episodes of super-refractory left-sided focal motor status epilepticus 5 months apart. He developed a prolonged postictal left hemiparesis each time that improved over several weeks. He also experienced recurrent and transient left hemiplegia independently of any seizure after hypovolemic and septic shocks.

Clinical examination found no facial port-wine stain, glaucoma, or choroidal hemangioma. Brain MRI exhibited a right temporal-parietal-occipital leptomeningeal angioma on contrast-enhanced images and the appearance of slight and focal cortical atrophy over 6 months, but no calcifications or choroid plexus hypertrophy (Figure 1). These features were consistent with a type III Sturge-Weber syndrome (SWS). Leptomeningeal biopsies highlighted an R183C *GNA11* somatic pathogenic variation (Figure 2) described in SWS.[1] After seizure and blood pressure control, we noticed a progressive clinical improvement with walking recovery.

Identification of SWS-related pathogenic variations in patients with isolated leptomeningeal angioma and late adult-onset epilepsy further confirmed the existence of type III SWS.[2]

From the Epilepsy Unit, Department of Neurology (L.C., F.G., V.N.), AP-HP, Pitié-Salpêtrière Hospital; Sorbonne Université (L.C., L.D.M., B.M., M.E., V.N.); Paris Brain Institute (ICM) (L.C., V.N.), Sorbonne Université, CNRS UMR 7225—Inserm U1127; Department of Neuroradiology (D.L.), Department of Neuropathology (M.C.T.), Neuro-intensive Care Unit, Department of Neurology (L.D.M., C.M., A.H.); and Departments Neurosurgery (B.M), and Genetics (M.E.), AP-HP, Pitié-Salpêtrière Hospital, Paris, France.

Go to Neurology.org/N for full disclosures. Funding information and disclosures deemed relevant by the authors, if any, are provided at the end of the article.

Copyright © 2023 American Academy of Neurology



Copyright © 2023 American Academy of Neurology. Unauthorized reproduction of this article is prohibited.

**Figure 2** Cortical and Meningeal Biopsy: Histopathologic and Genetic Features

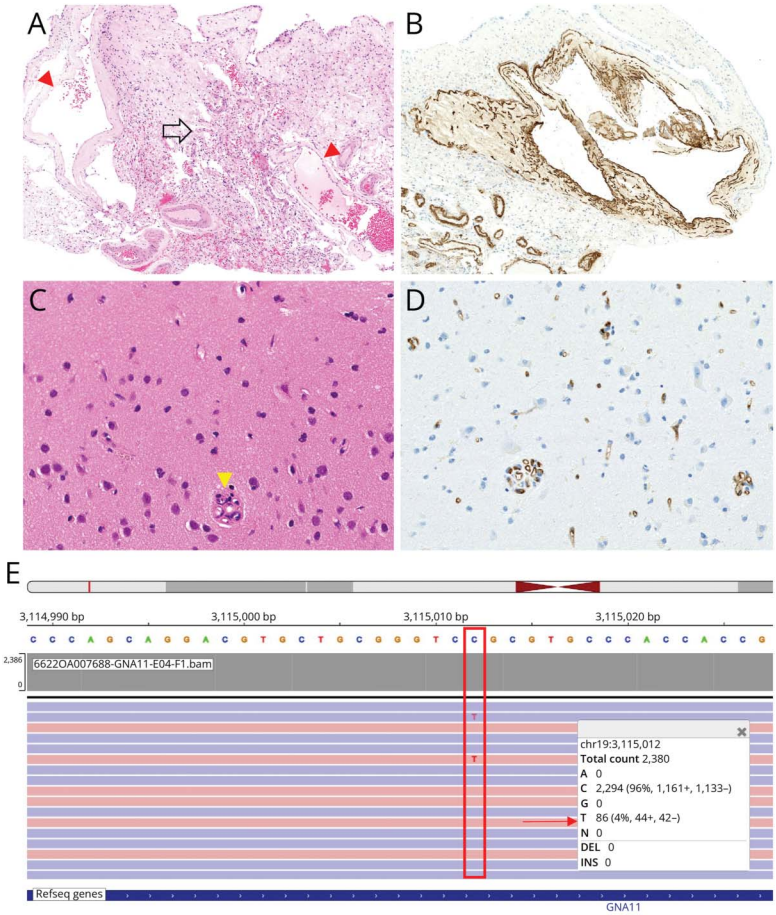


Leptomeninges: enlarged veins (A, red arrowheads) with angiomatosis (empty arrow) and abnormally expressed alpha-smooth muscle actin in vein wall (B). Cortex (II–III): glomeruloid vessels (C, yellow arrowhead) with CD34 staining (D), without neuronal loss, gliosis, or calcification (×200–400 magnification). R183C GNA11 somatic mutation (variant allele frequency: 4%) in leptomeningeal tissue (E, next-generation sequencing data in the Integrative Genomics Viewer).

## Author Contributions

L. Cousyn: drafting/revision of the manuscript for content, including medical writing for content; major role in the acquisition of data; Study concept or design; analysis or interpretation of data. D. Leclercq: drafting/revision of the manuscript for content, including medical writing for content; major role in the acquisition of data; analysis or interpretation of data. M.C. Ta: drafting/revision of the manuscript for content, including medical writing for content; major role in the acquisition of data; analysis or interpretation of data. F. Gilbert: drafting/revision of the manuscript for content, including medical writing for content; major role in the acquisition of data. L. Di Meglio: drafting/revision of the manuscript for content, including medical writing for content; major role in the acquisition of data. C. Marois: drafting/revision of the manuscript for content, including medical writing for content; major role in the acquisition of data. A. Haddad: drafting/revision of the manuscript for content, including medical writing for content; major role in the acquisition of data. B. Mathon: drafting/revision of the manuscript for content, including medical writing for content; major role in the acquisition of data. M. Eyries: drafting/revision of the manuscript for content, including medical writing for content; major role in the acquisition of data; analysis or interpretation of data. V. Navarro: drafting/revision of the manuscript for content, including medical writing for content; major role in the acquisition of data; study concept or design; analysis or interpretation of data.


## Study Funding

The authors report no targeted funding.


## Disclosure

The authors report no relevant disclosures. Go to Neurology.org/N for full disclosures.


## Publication History

Received by *Neurology* March 2, 2023. Accepted in final form August 4, 2023. The handling editor was Editor-in-Chief José Merino, MD, MPhil, FAAN.


## References


1. Yeom S, Comi AM. Updates on Sturge-Weber yndrome. *Stroke* 2022;53(12): 3769-3779. doi:10.1161/STROKEAHA.122.038585
2. Vellieux G, Frazzini V, Pichit P, Dupont S, Gourfinkel-An I, Navarro V. A review of the natural history of Sturge–Weber syndrome through adulthood. *J Neurol.* 2022; 269(9):4872-4883. doi:10.1007/s00415-022-11132-9





Copyright © 2023 American Academy of Neurology. Unauthorized reproduction of this article is prohibited.