Received: 10 September 2019 | Revised: 17 December 2019 | Accepted: 13 January 2020

DOI: 10.1002/humu.23986

Human Mutation HGVS HUMAN GENOME VARIATION SOCIETY WILEY

RESEARCH ARTICLE

Protein-elongating mutations in *MYH11* are implicated in a dominantly inherited smooth muscle dysmotility syndrome with severe esophageal, gastric, and intestinal disease

Melissa A. Gilbert[1] | Laura Schultz-Rogers[2,3] | Ramakrishnan Rajagopalan[1] | Christopher M. Grochowski[1] | Benjamin J. Wilkins[4] | Sawona Biswas[5] | Laura K. Conlin[1] | Kristin N. Fiorino[6,7] | Radhika Dhamija[8] | Michael A. Pack[9,10] | Eric W. Klee[2,3,11] | David A. Piccoli[6,7] | Nancy B. Spinner[1]

[1]Division of Genomic Diagnostics, Department of Pathology and Laboratory Medicine, The Children's Hospital of Philadelphia and The Perelman School of Medicine, University of Pennsylvania, Philadelphia, Pennsylvania

[2]Center for Individualized Medicine, Mayo Clinic, Rochester, Minnesota

[3]Department of Health Sciences, Mayo Clinic, Rochester, Minnesota

[4]Division of Anatomic Pathology, Department of Pathology and Laboratory Medicine, The Children's Hospital of Philadelphia and The Perelman School of Medicine, University of Pennsylvania, Philadelphia, Pennsylvania

[5]Division of Human Genetics, Department of Pediatrics, The Children's Hospital of Philadelphia, Philadelphia, Pennsylvania

[6]Division of Pediatric Gastroenterology, Hepatology and Nutrition, Department of Pediatrics, The Children's Hospital of Philadelphia and The Perelman School of Medicine, University of Pennsylvania, Philadelphia, Pennsylvania

[7]The Suzi and Scott Lustgarten Center for GI Motility, Division of Gastroenterology, Hepatology and Nutrition, The Children's Hospital of Philadelphia and The Perelman School of Medicine, University of Pennsylvania, Philadelphia, Pennsylvania

[8]Department of Medical Genetics, Mayo Clinic, Phoenix, Arizona

[9]Division of Gastroenterology, Department of Medicine, The Perelman School of Medicine, University of Pennsylvania, Philadelphia, Pennsylvania

[10]Department of Cell and Developmental Biology, The Perelman School of Medicine, University of Pennsylvania, Philadelphia, Pennsylvania

[11]Department of Clinical Genomics, Mayo Clinic, Rochester, Minnesota

Correspondence
Nancy B. Spinner, Division of Genomic Diagnostics, Department of Pathology and Laboratory Medicine, The Children's Hospital of Philadelphia and the Perelman School of Medicine, University of Pennsylvania, Philadelphia, PA 19104.
Email: spinner@mail.med.upenn.edu

Present address
Christopher M. Grochowski, Department of Molecular and Human Genetics, Baylor College of Medicine, Houston, TX.

Sawona Biswas, Department of Genetics, University of San Francisco, San Francisco, CA.

Funding information
Lustgarten Motility Center at the Children's Hospital of Philadelphia; Department of Pathology at the Children's Hospital of Philadelphia

Abstract

Gastrointestinal motility disorders include a spectrum of mild to severe clinical phenotypes that are caused by smooth muscle dysfunction. We investigated the genetic etiology of severe esophageal, gastric, and colonic dysmotility in two unrelated families with autosomal dominant disease presentation. Using exome sequencing, we identified a 2 base pair insertion at the end of the myosin heavy chain 11 (*MYH11*) gene in all affected members of Family 1 [NM_001040113:c.5819_5820insCA(p.Gln1941Asnfs*91)] and a 1 base pair deletion at the same genetic locus in Proband 2 [NM_001040113:c.5819del(p.Pro1940Hisfs*91)]. Both variants are predicted to result in a similarly elongated protein product. Heterozygous dominant negative *MYH11* pathogenic variants have been associated with thoracic aortic aneurysm and dissection while biallelic null alleles have been associated with megacystis microcolon intestinal hypoperistalsis syndrome. This report highlights heterozygous protein-elongating *MYH11* variants affecting the SM2 isoforms of MYH11 as a cause for severe gastrointestinal dysmotility,

 © 2020 Wiley Periodicals, Inc.

and we hypothesize that the mechanistic pathogenesis of this disease, dominant hypercontractile loss-of-function, is distinct from those implicated in other diseases involving MYH11 dysfunction.

KEYWORDS
dysmotility, gastroparesis, hiatal hernia, *MYH11*, pseudo-obstruction

1 | INTRODUCTION

Myopathic gastrointestinal (GI) motility disorders are due to smooth muscle dysfunction from increased or diminished contractility or propagation or from abnormal function of sphincters. These abnormalities result in a wide variety of clinical manifestations including dysphagia, hiatal hernia (HH), gastroesophageal reflux disease (GERD), esophagitis, esophageal dysmotility, gastroparesis, bowel pseudo-obstruction, and constipation. The majority of these motility disorders are acquired or idiopathic, and do not appear to have a genetic basis. Multigenerational studies, however, have occasionally highlighted the autosomal dominant inheritance of dysmotility phenotypes, which often display variable expressivity in symptom severity (Carre & Froggatt, 1970; Carre, Johnston, Thomas, & Morrison, 1999; Myles, 1939). In a study of a five-generation family with a primary complaint of HH, GERD, and dysphagia, 23 affected individuals displayed drastic variability in age of onset and severity of symptoms, with three presenting as asymptomatic despite the radiographic presence of a HH (Carre et al., 1999). The observation of dominant inheritance among multigenerational families suggests a genetic etiology for a subset of hereditary motility disorders.

We report on two unrelated families with severe gastric dysmotility identified following exome sequencing (ES) and participation in the GeneMatcher program (Sobreira, Schiettecatte, Valle, & Hamosh, 2015) with similar protein-elongating myosin heavy chain 11 (*MYH11*) variants.

2 | MATERIAL AND METHODS

2.1 | Editorial policies and ethical considerations

Family 1: This study was approved by the Institutional Review Board at the Children's Hospital of Philadelphia, and written informed consent was obtained from parents or subjects 18 years or older in accordance with the Declaration of Helsinki. Data from all patients were reviewed to obtain a complete clinical history.

Proband 2: This study was approved by the Mayo Clinic Institutional Review Board and written informed consent was obtained from the proband for genetic testing and to obtain a complete clinical history.

2.2 | Chromosomal microarray analysis (genome-wide single-nucleotide polymorphism array)

Single-nucleotide polymorphism (SNP) array data for Family 1 were produced using a custom Ilumina BeadChip array with 850,000 probes at an average genome-wide resolution of 4 kb (Illumina, San Diego, CA) at the Center for Applied Genomics core facility, Children's Hospital of Philadelphia. The gender identity of the samples were confirmed using heterozygosity rates in the X chromosome, and relationships among family members were confirmed using identity-by-descent (IBD) estimates from King software (Manichaikul et al., 2010). Copy-number variants (CNVs) were determined using the PennCNV algorithm (K. Wang et al., 2007) and annotated using in-house scripts. CNVs overlapping less than 10 SNP probes were excluded from downstream analysis.

2.3 | Exome sequencing and data analysis

ES for Family 1 was performed using the Agilent Exome Capture V5 capture kit at an average depth of 130× and 90% of the bases covered at 20× on an Illumina HiSeq 2000 (PerkinElmer, Branford, CT). Paired-end sequence reads of 100 bp were aligned to the GRCh37 reference genome using Novoalign v3.02 (Novocraft Technologies, Malaysia). Variants were called using the HaplotypeCaller routine in the GenomeAnalysisToolkit (GATK v. 3.4; Van der Auwera et al., 2013). The GATK variant calling pipeline identified a total of 202,945 variants in the exomes of all six family members (one monozygotic twin was not included). Gender identity of the samples were confirmed using heterozygosity rates in the X chromosome and relationships among family members were inferred using IBD estimates from King software (Manichaikul et al., 2010). Ingenuity Variant Analysis software (Qiagen, Redwood City, CA) was used for variant annotation and filtration (frameshift, in-frame indels, nonsense mutations, splice site variants up to three bases into the intron, and missense variants). A variant minor allele frequency (MAF) threshold of 0.5% in public genome databases (1000 genomes project: http://www.internationalgenome.org/1000-genomes-browsers/; Genomes Project et al., 2015) and the Exome Aggregation Consortium database, ExAC; Lek et al., 2016) was used. A dominant inheritance model was used to filter variants (Table S1). Additional filtration by phenotype (using the

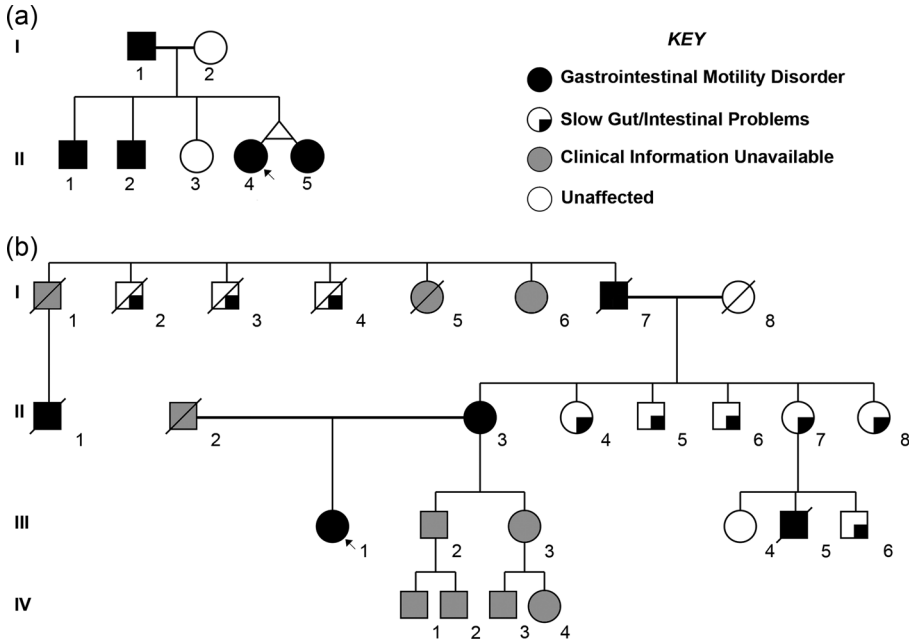

FIGURE 1 Family pedigrees. Pedigree of (a) Family 1 and (b) Family 2 showing autosomal dominant inheritance. In Family 1, all affected family members have the myosin heavy chain 11 (*MYH11*) insertion variant. Genetic testing in Family 2 was only performed in the proband. Arrow indicates proband

terms "hiatal hernia, esophagitis, GERD, and Barrett's esophagus") resulted in a final list of candidate variants (Table S2). The *MYH11* variant was validated by Sanger sequencing in all seven individuals using the following primers: 5′-CTC GTC AAG ATG CAG TGA TAA GG-3′ and 5′-TCA CTG CAA CGT TGA CTT AAG G-3′.

ES for the proband in Family 2 was performed by GeneDx (https://www.genedx.com; Gaithersburg, MD). A proprietary capture system was used for next-generation sequencing and targets were sequenced with paired-end reads on an Illumina platform. Reads were aligned to GRCH37/UCSC hg19. Sequence variants and deletions or duplications involving three or more coding exons were called with a XomeAnalyzer (GeneDx, Gaithersburg, MD). Variants were reported according to the Human Genome Variation Society guidelines and clinically confirmed by direct gene-specific polymerase chain reaction.

3 | RESULTS

3.1 | Clinical presentation

3.1.1 | Family 1

Family 1 is comprised of five affected individuals spanning two generations. The 56-year old father (I.1, Figure 1a) was diagnosed with GERD, HH, and reflux esophagitis in infancy, and underwent fundoplication with HH repair at age 11 (Table 1). He had significant improvement in reflux symptoms and is now controlled with medical therapy. Four children in this family have also had related gastroesophageal symptoms (Table 1).

A 19-year-old female twin (II.4, Figure 1a) born prematurely (29 weeks) was noted at 4-years old to have GERD. She developed dysphagia to solids at 6-years old, and an upper endoscopy later demonstrated mild esophagitis and an elevated Z-line with

TABLE 1 Summary of major clinical features of Family 1

Individual	*MYH11* variant	Hiatal hernia	Esophageal stricture	Abnormal HREM	Fundoplication with HH repair
I.1	Yes	Yes	Unknown	ND	Yes
I.2	No	No	No	No	No
II.1	Yes	Yes	Yes	ND	Yes
II.2	Yes	Yes	Yes	Abnormal	Yes
II.3	No	No	No	No	No
II.4	Yes	Yes	No	Abnormal	Yes
II.5	Yes	Yes	Yes	Abnormal	Yes

Abbreviations: HH, hiatal hernia; HREM, high-resolution esophageal manometry; ND, not done

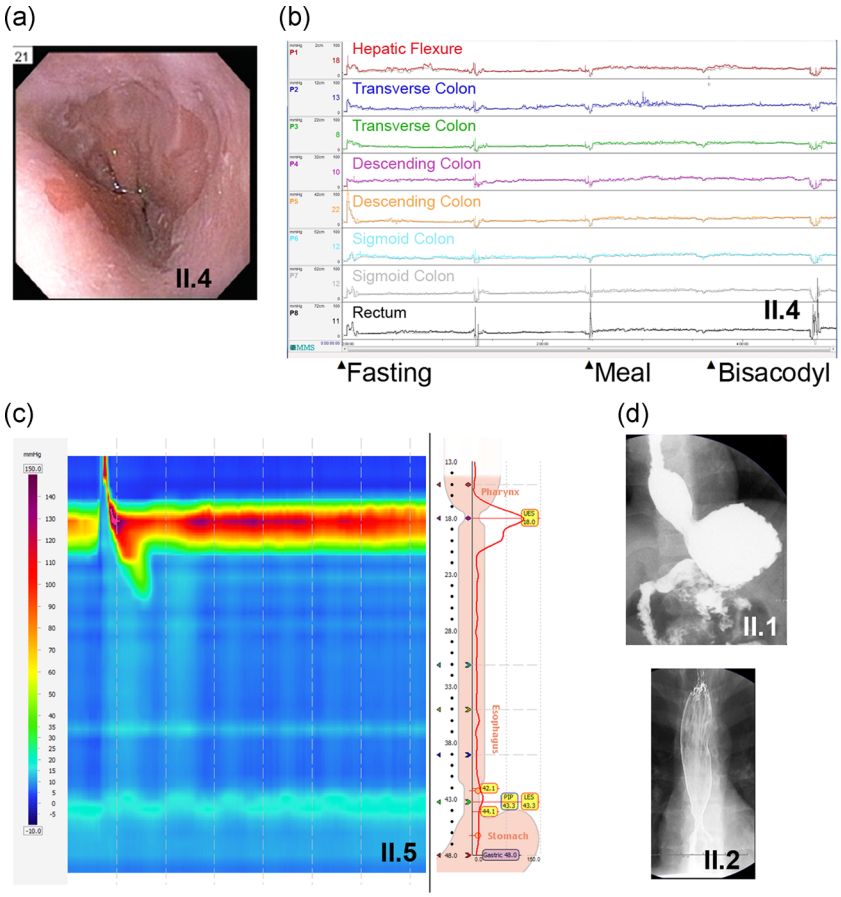

FIGURE 2 Clinical features of Family 1. (a) Hiatal hernia (HH) with irregular Z-line at the gastroesophageal junction visible at upper endoscopy in individual II.4. (b) Colonic manometry showing absence of fasting and drug-induced (bisacodyl) high amplitude propagating contractions in individual II.4. (c) High-resolution esophageal manometry showing aperistalsis in the mid and distal esophagus and decreased pressure of the lower esophageal sphincter following swallow-induced contraction of the proximal esophagus in individual II.5. (d) Radiographic images showing large HH in individual II.1 and an esophageal stricture in individual II.2. Representative control colonic manometry and esophageal manometry images are shown in Figure S1

severe gastroparesis and an HH (Figure 2a). Progressive duodenal dilatation led to a diagnosis of superior mesenteric artery syndrome that was surgically treated with a duodenojejunostomy, but complicated by duodenal stricture and recurrent nausea that persisted after stricture repair. An antroduodenal motility study demonstrated abnormal low amplitude duodenal and jejunal contractions. A colonic motility study demonstrated an absence of significant motor activity suggestive of colonic myopathy (Figure 2b). At age 17, she underwent fundoplication with repair of HH, pyloroplasty, and takedown of jejunostomy. An abdominal ultrasound at age 15 revealed a normal abdominal aorta.

Patient II.4's identical twin sister (II.5, Figure 1a) developed recurrent necrotizing enterocolitis requiring ascending and transverse colectomy. She presented with anemia and GI bleeding and was diagnosed with a severe distal esophageal stricture at age 4, attributed to chronic reflux esophagitis that required recurrent dilation despite maximal medical therapy for GERD. Endoscopy and upper GI studies demonstrated a HH. Manometric studies demonstrated markedly abnormal esophageal motor activity with absent peristalsis and markedly diminished amplitude in the mid and distal esophagus and decreased pressure of the lower esophageal sphincter, which are all comprised of smooth muscle, compared to the proximal esophagus, which is comprised of skeletal muscle (Figure 2c). Antroduodenal motility demonstrated normal migrating motor complexes, but with abnormally low amplitude duodenal and jejunal contractions. A fundoplication and HH repair were performed at age 18. Subsequently, a nuclear medicine scan demonstrated moderate gastroparesis. An abdominal ultrasound at age 19 revealed a normal abdominal aorta.

An older brother, age 24 (II.1, Figure 1a), was diagnosed with reflux esophagitis, esophageal ulceration, and HH at age 7 (Figure 2d). Barrett's esophagus was diagnosed at age 15, at which age, a fundoplication and HH repair were also performed. The patient's reflux symptoms resolved following fundoplication, however, he suffers from intermittent solid food dysphagia.

A second older brother, age 22 (II.2, Figure 1a), presented with dysphagia, GERD, a HH, and esophagitis at age 12. A distal esophageal stricture was diagnosed at age 16 (Figure 2d) and a fundoplication with repair of HH was performed at age 20. Manometric studies showed aperistalsis in the mid and distal esophagus following swallow-induced contraction of the proximal esophagus.

A fifth child (II.3, Figure 1a) is a 20-year old healthy female with a normal upper GI and no reports of vomiting, nausea, reflux, strictures, or obstruction. The children's mother (I.2, Figure 1a) is also unaffected.

3.1.2 | Family 2

Family 2 is comprised of five affected individuals spanning three generations. Detailed clinical characterization and sequencing data

are available for a 30-year old female (III.1, Figure 1b) diagnosed with constipation in infancy followed by intestinal pseudo-obstruction at age 11. Her symptoms improved for approximately 7 to 8 years until she developed volvulus near her distal ileum requiring surgical detorsion and lysis of adhesions. Postoperative recovery was complicated by small bowel obstruction. Recurrent terminal ileum volvulus occurred 2 months later that required repeat surgical detorsion with lysis of adhesions and resection of the suspected ischemic terminal ileum. The patient continues to suffer from recurrent episodic small bowel obstructions and *Clostridium difficile* (*C. difficile*) infections requiring hospitalization. Anal manometry performed at age 20 revealed weak internal anal sphincter tone consistent with smooth muscle myopathy. Small bowel manometry at age 20 showed abnormal fed conversion with prolonged sporadic activity and weakly propagated Phase III fronts felt to be due to a neurogenic abnormality.

Four maternal family members spanning three generations also display histories of a chronic intestinal motility disorder. The patient's mother, age 53 (II.3, Figure 1b) has suffered from recurrent colonic volvulus requiring surgical decompression and lysis of adhesions. Her maternal grandfather (I.7, Figure 1b) died at age 87 from recurrent intestinal obstruction. A maternal grandfather's nephew (II.1, Figure 1b) developed pseudo-obstruction at age 25 and died of complications at age 47. A maternal cousin (III.5, Figure 1b) died at age 12 from complications due to intestinal disease. Several other maternal family members were reported as having lifelong GI symptoms suggestive of a chronic motility disorder.

3.2 | Genomic analysis

3.2.1 | Family 1

Both chromosomal microarray analysis (CMA) by genome-wide SNP array and ES were performed. CMA was performed on all seven family members and did not identify deletions or duplications that fit our criteria for pathogenicity (deletions greater than 200 kb or duplications greater than 1 Mb or smaller CNVs with protein-coding genes overlapping within the deletion or duplication) in any of the affected or unaffected individuals.

ES was performed in six of the seven family members (one monozygotic twin was not included) and identified 11 heterozygous coding and/or splice variants present in all affected family members that were not present in the unaffected child or unaffected mother (Table S2). After filtration by gene function, MAF < 0.5% in ExAC (Lek et al., 2016), and predicted variant pathogenicity, only one variant was considered to be a strong candidate—a novel, heterozygous 2 base pair insertion on chromosome 16 [NM_001040113:c.5819_5820insCA (p.Gln1941Asnfs*91)] in the myosin heavy chain 11 (*MYH11*) gene (Figure 3). This identified variant was deposited in the ClinVar Database,

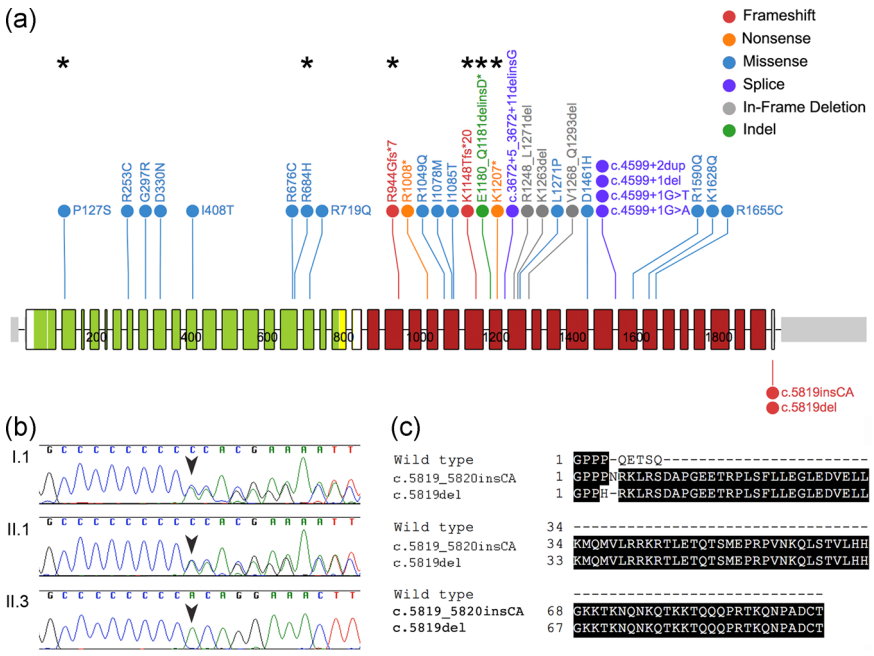

FIGURE 3 Molecular identification of *MYH11* mutations. (a) Protein schematic of *MYH11*. Mutations reported in the Human Gene Mutation Database, ClinVar, and PubMed are depicted above the schematic. Variants with questionable segregation and/or lack of functional data were excluded. Asterisks indicate variants identified in patients with megacystis-microcolon-intestinal hypoperistalsis syndrome, with the remaining variants identified in patients with thoracic aortic aneurysm and dissections (TAAD) and TAAD/patent ductus arteriosus. The two variants described in this study are shown below the protein schematic. Protein domains are color-coded: green, myosin head; yellow, IQ domain; red, coiled-coil domain. (b) Sanger sequencing confirmation of the 2 base pair insertion identified in Family 1 as well as the same region in the unaffected sibling (II.3). (c) Protein alignment showing wild-type *MYH11*, the mutation identified in Family 1 (c.5819_5820insCA), and the mutation identified in Family 2 (c.5819del). Protein schematic was prepared using ProteinPaint software from Saint Jude Children's Research Hospital–Pediatric Cancer Data Portal (Zhou et al., 2016). *MYH11* reference sequence NM_001040113

where it will be publicly available and can be found with accession number SCV000998889 at the following link: https://www.ncbi.nlm.nih.gov/clinvar/.

3.2.2 | Family 2

The proband in this family underwent clinical exome and mitochondrial sequencing. No pathogenic variants or variants of uncertain significance were identified through mitochondrial sequencing. From ES, three heterozygous variants of uncertain significance were clinically reported. This includes two variants in the gene *MYH11*, a single nucleotide deletion [NM_001040113:c.5819delC(p.Pro1940Hisfs*91] (Figure 3 and Figure S2) and a missense variant [NM_002474:c.4663C>G(p.Leu1555Val)]. These identified variants were deposited in the ClinVar Database, where they will be publicly available and can be found with accession numbers SCV000994586.1 and SCV000994585.1 at the following link: https://www.ncbi.nlm.nih.gov/clinvar/. A third, missense variant was identified in the *SPTLC2* gene [NM_004863.3:c.788A>G (p.His263Arg)].

4 | DISCUSSION

4.1 | Proposed pathomechanism

We studied two families with dominantly inherited esophageal, gastric, and intestinal dysmotility by ES and identified two similar frameshift mutations occurring at the same genomic locus in *MYH11* that were not present in unaffected first degree relatives in Family 1 (testing of members other than the proband was unavailable for Family 2). Both of these variants are located within a poly-cytosine tract in the last coding exon of the SM2 isoforms of *MYH11*. The insertion results in a synonymous substitution at the sixth to last amino acid, followed by the addition of 90 unique amino acids before termination. The deletion results in a missense substitution at the sixth to last amino acid, followed by an insertion of 89 amino acids, of which all are identical to those in Family 1. Neither variant affects the SM1 isoforms of *MYH11*, thus, the associated phenotypes are isoform-specific.

The mechanism underlying the clinical features of each family's motility phenotype is uncertain, however, it can likely be attributed to the *MYH11* variants' effect on myosin regulation (Alhopuro et al., 2008; Eddinger & Meer, 2007; Sweeney & Houdusse, 2010). Smooth muscle myosin filaments are comprised of heavy chain dimers (encoded by *MYH11*) that are bound by pairs of essential and regulatory myosin light chain proteins. Phosphorylation of the regulatory light chain activates the ATPase in the MYH11 head domain, thereby triggering contraction. In vitro studies indicate that SM1 and SM2 heavy chains, which have different terminal exons and 3′ untranslated regions due to alternative splicing, preferentially form homodimers in vivo, presumably because of the differences in the length of their carboxy termini (Kelley, Sellers, Goldsmith, & Adelstein, 1992). Given these considerations, it is likely that half of the SM2 myosin molecules in our motility syndrome families will be mutant homodimers. Alhopuro et. al. (2008) quantified the in vitro motility of actin filaments driven by the contraction of either wild type MYH11 or a construct containing the deletion variant (p.Pro1940Hisfs*91) and found that actin filaments retained a baseline level of motility that was unchanged when mutant MYH11 was phosphorylated, whereas actin filaments driven by wild-type MYH11 increased from nonmotile in the unphosphorylated state to highly motile in the phosphorylated state (Alhopuro et al., 2008). These data indicate that the p.Pro1940Hisfs*91 homodimers have motor activity when nonphosphorylated (nonregulated) (Alhopuro et al., 2008), which we hypothesize will reduce the strength and/or efficiency of smooth muscle contraction, thus accounting for the reported clinical and manometric findings (Alhopuro et al., 2008). Given that the predicted translation of the MYH11 protein for both the insertion variant and the deletion variant described in our report is similar, we believe it is reasonable to assume that the insertion mutant has a comparable if not identical effect on myosin physiology as the deletion variant. This predicted pathomechanism would also explain the remarkable esophageal manometry in Family 1, which shows normal amplitude and propagation of peristalsis in the proximal esophagus, which is comprised almost exclusively of skeletal muscle, with absent or nearly absent muscle activity in the smooth muscle lining the mid and distal esophagus, in three out of four siblings (not performed in one affected child). Normal peristalsis in skeletal muscle can likely be attributed to the near absent expression of MYH11 in this tissue, compared to the abundant expression of MYH11 in smooth muscle (http://www.proteinatlas.org; Uhlen et al., 2015).

Recessive phenotypes arising from targeted disruption of the murine SM2 Myh11 also provide clues to the mechanism of the dominant motility phenotypes (Chi, Zhou, Vedamoorthyrao, Babu, & Periasamy, 2008). Homozygous null animals die soon after weaning with bladder outlet obstruction and diffuse digestive tract dilation. Smooth muscle strips isolated from mutant bladders were shown to be hypercontractile in response to KCL and muscarinic agonists, suggesting that the normal role of SM2 isoforms is to regulate contractile force. The cause of stomach and intestinal dilation reported in this study was not determined, and we speculate that spasmodic hypercontractility of gastric and intestinal smooth muscle impairs interdigestive and post-meal motility, leading to chronic dilation and pseudo-obstruction. Under this hypothesis, it is conceivable that the heterozygous SM2 variants in our motility families function as dominant negative alleles with resultant hypercontractile physiology, possibly as a result of decreased stability of the mutant SM2 homodimers and or interaction with the SM1 heavy chain, which is 34 amino acids longer than wild type SM2 isoforms. Hypercontractility of longitudinal esophageal smooth muscle could also contribute to HH seen in all affected members of Family 1.

4.2 | Analysis of identified variants

The insertion variant has not been previously reported in the literature, the Genome Aggregation Database (gnomAD, http://gnomad.broadinstitute.org/), or in ExAC (Lek et al., 2016). The deletion variant is present in 46 heterozygous individuals in ExAC (AF = 0.0005653) and is absent from gnomAD, however, it is challenging to assess if the allele frequency of the deletion variant in ExAC is accurate given that it failed the quality filters due to the low sequence complexity of the region flanking the variant (Table S3). In addition, phenotype information is not provided for individuals in ExAC and gnomAD, and it is possible that these individuals may be asymptomatic or have mild symptoms, which is expected for this variably expressed condition. Functional evidence further strengthens the pathogenicity of the deletion variant, as it has been shown to result in unregulated motor activity of the encoded myosin and was recently implicated in Chronic Intestinal Pseudo-Obstruction (CIPO), a GI disorder affecting smooth muscle contractility that includes overlapping dysmotility phenotypes that we describe in our two families, although specific clinical manifestations in the recently reported individuals were not provided (Alhopuro et al., 2008; Dong et al., 2019; Jo, Kim, Yoo, & Lee, 2018).

These observations have also helped to rule against pathogenicity of the two other heterozygous missense variants identified in Proband 2, including one in *MYH11* and one in *SPTLC2*. The majority of patients with pathogenic autosomal dominant missense variants in *MYH11* present with thoracic aortic aneurysm and dissections (TAAD), which is not clinically described in our patient, and indeed, all nearby missense variants described in ClinVar and in HGMD are linked with TAAD. Furthermore, these nearby missense variants have all been submitted as either benign or likely benign (ClinVar) or with a DM classification (HGMD), suggesting that this region may be tolerant to variation. We were not able to phase the *MYH11* deletion and missense variants, and it is possible that they are both found on the same allele, which would decrease the pathogenic likelihood of the missense variant given the functional evidence supporting pathogenicity for the deletion variant. *Trans* expression of these two variants, however, also fails to provide causation for pathogenicity of the missense variant as all reports of biallelic loss-of-function variants have been associated with severe megacystis-microcolon-intestinal hypoperistalsis syndrome (MMIHS), which is usually fatal in infancy (Gauthier et al., 2015; Yetman & Starr, 2018). Finally, Proband 2 is Mexican and Arab, which could explain why the *MYH11* missense variant has not previously been observed in gnomAD, which is skewed toward European ethnicities. Missense variants in the *SPTLC2* gene have been shown to cause hereditary sensory and autonomic neuropathy, type IC (MIM# 613640), which is characterized by distal sensory dysfunction and muscle weakness (Rotthier et al., 2010), phenotypes that are not present in Proband 2.

4.3 | *MYH11* in disease

Mutations in *MYH11* have previously been associated with disease, including ~1% of cases of familial TAAD, a syndrome characterized by loss of elastic fibers and smooth muscle cells in the aorta that leads to sudden cardiac death (MIM# 132900; Harakalova et al., 2013; Milewicz et al., 2008; Pannu et al., 2007). There is an increased incidence of *MYH11* mutations in a subset of these patients who also have patent ductus arteriosus (TAAD/PDA), a condition that arises from failed closure of a fetal blood vessel in the heart (Pannu et al., 2007; Renard et al., 2013; Zhu et al., 2006). Reported pathogenic variants include missense, splice site, nonsense, and deletion variants, which are found in both the motor domain and the coiled-coil tail domain of *MYH11* (Pannu et al., 2007; Renard et al., 2013; Stenson et al., 2003; Zhu et al., 2006). Duplications of 16p13.1, which includes *MYH11*, have also been identified as a risk factor for aortic dissections, and patients harboring these duplications also have an increased likelihood of having a second rare CNV (Kuang et al., 2011). Limited functional studies and predicted effects on protein activity all support a dominant negative mechanism of disease pathogenesis (Milewicz et al., 2017; Pannu et al., 2007; Renard et al., 2013; Zhu et al., 2006).

In addition to the association with TAAD/PDA, four individuals with *MYH11* mutations have been reported with MMIHS, a recessive disease characterized by impaired intestinal motility likely caused by smooth muscle degeneration through a loss-of-function mechanism (MIM# 155310). *MYH11* mutations from this cohort include one homozygous nonsense variant, two compound heterozygous frameshift variants, a compound heterozygous missense variant and 1.3 Mb deletion in 16p13.11 that includes *MYH11*, and a compound heterozygous missense variant and indel (Gauthier et al., 2015; Kloth et al., 2019; Q. Wang et al., 2019; Yetman & Starr, 2018). Mutations in *ACTG2*, *MYL9*, *LMOD1*, and *MYLK*, which encode other smooth muscle proteins, have also been implicated in MMIHS disease pathogenesis (Halim, Brosens, et al., 2017; Halim, Wilson, et al., 2017; Moreno et al., 2018; Thorson et al., 2014; Wangler et al., 2014). Finally, a linkage analysis aimed to identify a genetic etiology for infantile hypertrophic pyloric stenosis (MIM# 179010), a disease characterized by projectile vomiting and hypothesized to occur via smooth muscle dysfunction, identified an 11 Mb linkage interval on chromosome 16p12-p13 in a large, multigenerational family that included the *MYH11* gene, although they were unable to identify a pathogenic mutation through sequencing (Capon, Reece, Ravindrarajah, & Chung, 2006). Of note, protein-elongating MYH11 variants, including our deletion variant (p.Pro1940Hisfs*91), have been described in colorectal cancers displaying microsatellite instability, however, an important distinction is that these cancers are defined by the presence of these variants specifically within the tumor and not within the germline (Alhopuro et al., 2008). It is not expected that the mutant alleles are expressed tissue-wide where they could elicit the same effects as described in our two families. In addition, these cancers are caused by an underlying defect in the DNA mismatch repair system, which we are not reporting here that is likely to

produce other alternatively-sized DNA repetitive sequences in coding and noncoding regions that could also be contributory to disease.

In contrast to the GI motility-associated variants reported here, the TAAD-associated *MYH11* variants affect both SM1 and SM2 isoforms. Within a large cohort of patients with TAAD (familial and sporadic), no variants were identified in the tail end of the protein that was consistent with a hypercontractile phenotype, and additionally, no individuals within that cohort reported GI dysmotility (Dianna Milewicz, *personal communication*). Introduction of a homozygous motor missense variant in mice, R247C, reduces myosin contractility without affecting regulation, and importantly these mice show no evidence of gut dysfunction (Kuang et al., 2012). The absence of significant GI motility symptoms in most TAAD families argues that the contractility defects present in their digestive tract smooth muscle, which undergoes phasic contraction, are tolerated. In contrast, the defect in myosin regulation imparted by the SM2 variants in our families does not appear to affect aortic wall integrity, either because of intrinsic differences in their effect on contractility and/or because SM2 myosin isoforms play a less significant role in vascular smooth muscle. Supporting the latter idea, aortic defects were not reported in SM2 mutant mice, however, these animals may not survive long enough to develop pronounced defects (Chi et al., 2008).

5 | CONCLUSIONS

The discovery of two, similar *MYH11* variants in two unrelated families and the recent identification of the deletion variant in seven affected individuals in a third family with CIPO (Dong et al., 2019), is strongly suggestive of pathogenicity given the smooth muscle deficiency that presents within the affected individuals. We hypothesize that the mechanism of pathogenesis and inheritance dictates the type of smooth muscle disease that arises from *MYH11* pathogenic variants, a hypothesis that has already been proposed (Gauthier et al., 2015). It is, therefore, crucial to understand the mode of inheritance and clinical presentation when classifying variants in this gene. This is of particular importance as *MYH11* is on the ACMG recommended gene list for reporting of incidental findings for its significance in TAAD (Kalia et al., 2017). We hypothesize that the variants described here alter the nonhelical tail of the SM2 isoforms, likely interfering with the required structure necessary for regulation and communication between the myosin head and the filament backbone. We propose that this results in hypercontractility, which functions to weaken the efficiency of smooth muscle contraction.

ACKNOWLEDGMENTS

The authors thank the Suzi and Scott Lustgarten Motility Center at the Children's Hospital of Philadelphia and the Braman Foundation for their support. The authors thank both the families for participating in this study. They also thank Alana Cecchi and Dianna Milewicz for their critical review of the manuscript. This study was supported in part by a grant from the Lustgarten Motility Center at the Children's Hospital of Philadelphia (D. A. P.) as well as the Department of Pathology at the Children's Hospital of Philadelphia (N. B. S.).

DATA AVAILABILITY STATEMENT

The *MYH11* variants reported in this study have been submitted to ClinVar (https://www.ncbi.nlm.nih.gov/clinvar/) where they are publicly available through the following accession numbers: SCV000998889, SCV000994586.1, and SCV000994585.1.

ORCID

Melissa A. Gilbert http://orcid.org/0000-0001-5345-1911
Nancy B. Spinner http://orcid.org/0000-0001-8109-3648

REFERENCES

Alhopuro, P., Phichith, D., Tuupanen, S., Sammalkorpi, H., Nybondas, M., Saharinen, J., … Aaltonen, L. A. (2008). Unregulated smooth-muscle myosin in human intestinal neoplasia. *Proceedings of the National Academy of Sciences of the United States of America*, *105*(14), 5513–5518. https://doi.org/10.1073/pnas.0801213105

Van der Auwera, G. A., Carneiro, M. O., Hartl, C., Poplin, R., Del Angel, G., Levy-Moonshine, A., … DePristo, M. A. (2013). From FastQ data to high confidence variant calls: The Genome Analysis Toolkit best practices pipeline. *Current Protocols in Bioinformatics*, *43*, 11. https://doi.org/10.1002/0471250953.bi1110s43. 11.10.11-33

Capon, F., Reece, A., Ravindrarajah, R., & Chung, E. (2006). Linkage of monogenic infantile hypertrophic pyloric stenosis to chromosome 16p12-p13 and evidence for genetic heterogeneity. *American Journal of Human Genetics*, *79*(2), 378–382. https://doi.org/10.1086/505952

Carre, I. J., & Froggatt, P. (1970). Oesophageal hiatus hernia in three generations of one family. *Gut*, *11*(1), 51–54.

Carre, I. J., Johnston, B. T., Thomas, P. S., & Morrison, P. J. (1999). Familial hiatal hernia in a large five generation family confirming true autosomal dominant inheritance. *Gut*, *45*(5), 649–652.

Chi, M., Zhou, Y., Vedamoorthyrao, S., Babu, G. J., & Periasamy, M. (2008). Ablation of smooth muscle myosin heavy chain SM2 increases smooth muscle contraction and results in postnatal death in mice. *Proceedings of the National Academy of Sciences of the United States of America*, *105*(47), 18614–18618. https://doi.org/10.1073/pnas.0808162105

Dong, W., Baldwin, C., Choi, J., Milunsky, J. M., Zhang, J., Bilguvar, K., … Milunsky, A. (2019). Identification of a dominant MYH11 causal variant in chronic intestinal pseudo-obstruction: Results of whole-exome sequencing. *Clinical Genetics*, *96*, 473–477. https://doi.org/10.1111/cge.13617

Eddinger, T. J., & Meer, D. P. (2007). Myosin II isoforms in smooth muscle: Heterogeneity and function. *American Journal of Physiology: Cell Physiology*, *293*(2), C493–C508. https://doi.org/10.1152/ajpcell.00131.2007

Gauthier, J., Ouled Amar Bencheikh, B., Hamdan, F. F., Harrison, S. M., Baker, L. A., Couture, F., … Soucy, J. F. (2015). A homozygous loss-of-function

variant in MYH11 in a case with megacystis-microcolon-intestinal hypoperistalsis syndrome. *European Journal of Human Genetics*, *23*(9), 1266–1268. https://doi.org/10.1038/ejhg.2014.256

Genomes Project, C., Auton, A., Brooks, L. D., Durbin, R. M., Garrison, E. P., Kang, H. M., … Abecasis, G. R. (2015). A global reference for human genetic variation. *Nature*, *526*(7571), 68–74. https://doi.org/10.1038/nature15393

Halim, D., Brosens, E., Muller, F., Wangler, M. F., Beaudet, A. L., Lupski, J. R., … Alves, M. M. (2017). Loss-of-function variants in MYLK cause recessive megacystis microcolon intestinal hypoperistalsis syndrome. *American Journal of Human Genetics*, *101*(1), 123–129. https://doi.org/10.1016/j.ajhg.2017.05.011

Halim, D., Wilson, M. P., Oliver, D., Brosens, E., Verheij, J. B., Han, Y., … Miano, J. M. (2017). Loss of LMOD1 impairs smooth muscle cytocontractility and causes megacystis microcolon intestinal hypoperistalsis syndrome in humans and mice. *Proceedings of the National Academy of Sciences of the United States of America*, *114*(13), E2739–E2747. https://doi.org/10.1073/pnas.1620507114

Harakalova, M., van der Smagt, J., de Kovel, C. G., Van't Slot, R., Poot, M., Nijman, I. J., … Baas, A. F. (2013). Incomplete segregation of MYH11 variants with thoracic aortic aneurysms and dissections and patent ductus arteriosus. *European Journal of Human Genetics*, *21*(5), 487–493. https://doi.org/10.1038/ejhg.2012.206

Jo, Y. S., Kim, M. S., Yoo, N. J., & Lee, S. H. (2018). Somatic mutations and intratumoral heterogeneity of MYH11 gene in gastric and colorectal cancers. *Applied Immunohistochemistry & Molecular Morphology*, *26*(8), 562–566. https://doi.org/10.1097/PAI.0000000000000484

Kalia, S. S., Adelman, K., Bale, S. J., Chung, W. K., Eng, C., Evans, J. P., … Miller, D. T. (2017). Recommendations for reporting of secondary findings in clinical exome and genome sequencing, 2016 update (ACMG SF v2.0): A policy statement of the American College of Medical Genetics and Genomics. *Genetics in Medicine*, *19*(2), 249–255. https://doi.org/10.1038/gim.2016.190

Kelley, C. A., Sellers, J. R., Goldsmith, P. K., & Adelstein, R. S. (1992). Smooth muscle myosin is composed of homodimeric heavy chains. *Journal of Biological Chemistry*, *267*(4), 2127–2130.

Kloth, K., Renner, S., Burmester, G., Steinemann, D., Pabst, B., Lorenz, B., … Rosenberger, G. (2019). 16p13.11 microdeletion uncovers loss-of-function of a MYH11 missense variant in a patient with megacystis-microcolon-intestinal-hypoperistalsis syndrome. *Clinical Genetics*, *96*, 85–90. https://doi.org/10.1111/cge.13557

Kuang, S. Q., Guo, D. C., Prakash, S. K., McDonald, M. L., Johnson, R. J., Wang, M., … Gen, T. A. C. I. (2011). Recurrent chromosome 16p13.1 duplications are a risk factor for aortic dissections. *PLoS Genetics*, *7*(6):e1002118. https://doi.org/10.1371/journal.pgen.1002118

Kuang, S. Q., Kwartler, C. S., Byanova, K. L., Pham, J., Gong, L., Prakash, S. K., … Milewicz, D. M. (2012). Rare, nonsynonymous variant in the smooth muscle-specific isoform of myosin heavy chain, MYH11, R247C, alters force generation in the aorta and phenotype of smooth muscle cells. *Circulation Research*, *110*(11), 1411–1422. https://doi.org/10.1161/CIRCRESAHA.111.261743

Lek, M., Karczewski, K. J., Minikel, E. V., Samocha, K. E., Banks, E., Fennell, T., … Exome Aggregation, C. (2016). Analysis of protein-coding genetic variation in 60,706 humans. *Nature*, *536*(7616), 285–291. https://doi.org/10.1038/nature19057

Manichaikul, A., Mychaleckyj, J. C., Rich, S. S., Daly, K., Sale, M., & Chen, W. M. (2010). Robust relationship inference in genome-wide association studies. *Bioinformatics*, *26*(22), 2867–2873. https://doi.org/10.1093/bioinformatics/btq559

Milewicz, D. M., Guo, D. C., Tran-Fadulu, V., Lafont, A. L., Papke, C. L., Inamoto, S., … Pannu, H. (2008). Genetic basis of thoracic aortic aneurysms and dissections: Focus on smooth muscle cell contractile dysfunction. *Annual Review of Genomics and Human Genetics*, *9*, 283–302. https://doi.org/10.1146/annurev.genom.8.080706.092303

Milewicz, D. M., Trybus, K. M., Guo, D. C., Sweeney, H. L., Regalado, E., Kamm, K., & Stull, J. T. (2017). Altered smooth muscle cell force generation as a driver of thoracic aortic aneurysms and dissections. *Arteriosclerosis, Thrombosis, and Vascular Biology*, *37*(1), 26–34. https://doi.org/10.1161/ATVBAHA.116.303229

Moreno, C. A., Sobreira, N., Pugh, E., Zhang, P., Steel, G., Torres, F. R., & Cavalcanti, D. P. (2018). Homozygous deletion in MYL9 expands the molecular basis of megacystis-microcolon-intestinal hypoperistalsis syndrome. *European Journal of Human Genetics*, *26*, 669–675. https://doi.org/10.1038/s41431-017-0055-5

Myles, R. B. (1939). Familial short oesophagus. *British Journal of Radiology*, *12*, 645–647.

Pannu, H., Tran-Fadulu, V., Papke, C. L., Scherer, S., Liu, Y., Presley, C., … Milewicz, D. M. (2007). MYH11 mutations result in a distinct vascular pathology driven by insulin-like growth factor 1 and angiotensin II. *Human Molecular Genetics*, *16*(20), 2453–2462. https://doi.org/10.1093/hmg/ddm201

Renard, M., Callewaert, B., Baetens, M., Campens, L., MacDermot, K., Fryns, J. P., … De Backer, J. (2013). Novel MYH11 and ACTA2 mutations reveal a role for enhanced TGFbeta signaling in FTAAD. *International Journal of Cardiology*, *165*(2), 314–321. https://doi.org/10.1016/j.ijcard.2011.08.079

Rotthier, A., Auer-Grumbach, M., Janssens, K., Baets, J., Penno, A., Almeida-Souza, L., … Timmerman, V. (2010). Mutations in the SPTLC2 subunit of serine palmitoyltransferase cause hereditary sensory and autonomic neuropathy type I. *American Journal of Human Genetics*, *87*(4), 513–522. https://doi.org/10.1016/j.ajhg.2010.09.010

Sobreira, N., Schiettecatte, F., Valle, D., & Hamosh, A. (2015). GeneMatcher: A matching tool for connecting investigators with an interest in the same gene. *Human Mutation*, *36*(10), 928–930. https://doi.org/10.1002/humu.22844

Stenson, P. D., Ball, E. V., Mort, M., Phillips, A. D., Shiel, J. A., Thomas, N. S., … Cooper, D. N. (2003). Human Gene Mutation Database (HGMD): 2003 update. *Human Mutation*, *21*(6), 577–581. https://doi.org/10.1002/humu.10212

Sweeney, H. L., & Houdusse, A. (2010). Structural and functional insights into the Myosin motor mechanism. *Annual Review of Biophysics*, *39*, 539–557. https://doi.org/10.1146/annurev.biophys.050708.133751

Thorson, W., Diaz-Horta, O., Foster, J., 2nd, Spiliopoulos, M., Quintero, R., Farooq, A., … Tekin, M. (2014). De novo ACTG2 mutations cause congenital distended bladder, microcolon, and intestinal hypoperistalsis. *Human Genetics*, *133*(6), 737–742. https://doi.org/10.1007/s00439-013-1406-0

Uhlen, M., Fagerberg, L., Hallstrom, B. M., Lindskog, C., Oksvold, P., Mardinoglu, A., … Ponten, F. (2015). Proteomics. Tissue-based map of the human proteome. *Science*, *347*(6220), 1260419. https://doi.org/10.1126/science.1260419

Wang, K., Li, M., Hadley, D., Liu, R., Glessner, J., Grant, S. F., … Bucan, M. (2007). PennCNV: An integrated hidden Markov model designed for high-resolution copy number variation detection in whole-genome SNP genotyping data. *Genome Research*, *17*(11), 1665–1674. https://doi.org/10.1101/gr.6861907

Wang, Q., Zhang, J., Wang, H., Feng, Q., Luo, F., & Xie, J. (2019). Compound heterozygous variants in MYH11 underlie autosomal recessive megacystis-microcolon-intestinal hypoperistalsis syndrome in a Chinese family. *Journal of Human Genetics*, *64*(11), 1067–1073. https://doi.org/10.1038/s10038-019-0651-z

Wangler, M. F., Gonzaga-Jauregui, C., Gambin, T., Penney, S., Moss, T., Chopra, A., … Beaudet, A. (2014). Heterozygous de novo and inherited mutations in the smooth muscle actin (ACTG2) gene underlie megacystis-microcolon-intestinal hypoperistalsis syndrome. *PLoS Genetics*, *10*(3): e1004258. https://doi.org/10.1371/journal.pgen.1004258

Yetman, A. T., & Starr, L. J. (2018). Newly described recessive MYH11 disorder with clinical overlap of multisystemic smooth muscle dysfunction and Megacystis microcolon hypoperistalsis syndromes. *American Journal of Medical Genetics. Part A*, *176*(4), 1011–1014. https://doi.org/10.1002/ajmg.a.38647

Zhou, X., Edmonson, M. N., Wilkinson, M. R., Patel, A., Wu, G., Liu, Y., … Zhang, J. (2016). Exploring genomic alteration in pediatric cancer using ProteinPaint. *Nature Genetics*, *48*(1), 4–6. https://doi.org/10.1038/ng.3466

Zhu, L., Vranckx, R., Khau Van Kien, P., Lalande, A., Boisset, N., Mathieu, F., … Jeunemaitre, X. (2006). Mutations in myosin heavy chain 11 cause a syndrome associating thoracic aortic aneurysm/aortic dissection and patent ductus arteriosus. *Nature Genetics*, *38*(3), 343–349. https://doi.org/10.1038/ng1721

SUPPORTING INFORMATION

Additional supporting information may be found online in the Supporting Information section.

How to cite this article: Gilbert MA, Schultz-Rogers L, Rajagopalan R, et al. Protein-elongating mutations in *MYH11* are implicated in a dominantly inherited smooth muscle dysmotility syndrome with severe esophageal, gastric, and intestinal disease. *Human Mutation*. 2020;41:973–982. https://doi.org/10.1002/humu.23986