Mitochondrial Neurogastrointestinal Encephalomyopathy: An Autosomal Recessive Disorder due to Thymidine Phosphorylase Mutations

Ichizo Nishino MD, PhD,* Antonella Spinazzola, MD,* Alexandros Papadimitriou, MD,† Simon Hammans, MD, FRCP,‡ Israel Steiner, MD,§ Cecil D. Hahn, MD,‖ Anne M. Connolly, MD,# Alain Verloes, MD,¶ João Guimarães, MD,** Ivan Maillard, MD, PhD,†† Hitoshi Hamano, MD,‡‡ M. Alice Donati, MD,§§ Carol E. Semrad, MD,‖‖ James A. Russell, DO,## Antonio L. Andreu, MD,* Giorgos M. Hadjigeorgiou, MD,† Tuan H. Vu, MD,* Saba Tadesse, BS,* Torbjoern G. Nygaard, MD,¶¶ Ikuya Nonaka, MD,*** Ikuo Hirano, MD,††† Eduardo Bonilla, MD,* Lewis P. Rowland, MD,* Salvatore DiMauro, MD,* and Michio Hirano, MD*

Mitochondrial neurogastrointestinal encephalomyopathy (MNGIE) is an autosomal recessive disorder defined clinically by severe gastrointestinal dysmotility; cachexia; ptosis, ophthalmoparesis, or both; peripheral neuropathy; leukoencephalopathy; and mitochondrial abnormalities. The disease is caused by mutations in the thymidine phosphorylase (TP) gene. TP protein catalyzes phosphorolysis of thymidine to thymine and deoxyribose 1-phosphate. We identified 21 probands (35 patients) who fulfilled our clinical criteria for MNGIE. MNGIE has clinically homogeneous features but varies in age at onset and rate of progression. Gastrointestinal dysmotility is the most prominent manifestation, with recurrent diarrhea, borborygmi, and intestinal pseudo-obstruction. Patients usually die in early adulthood (mean, 37.6 years; range, 26–58 years). Cerebral leukodystrophy is characteristic. Mitochondrial DNA (mtDNA) has depletion, multiple deletions, or both. We have identified 16 TP mutations. Homozygous or compound heterozygous mutations were present in all patients tested. Leukocyte TP activity was reduced drastically in all patients tested, 0.009 ± 0.021 μmol/hr/mg (mean ± SD; n = 16), compared with controls, 0.67 ± 0.21 μmol/hr/mg (n = 19). MNGIE is a recognizable clinical syndrome caused by mutations in thymidine phosphorylase. Severe reduction of TP activity in leukocytes is diagnostic. Altered mitochondrial nucleoside and nucleotide pools may impair mtDNA replication, repair, or both.

Nishino I, Spinazzola A, Papadimitriou A, Hammans S, Steiner I, Hahn CD, Connolly AM, Verloes A, Guimarães J, Maillard I, Hamano H, Donati MA, Semrad CE, Russell JA, Andreu AL, Hadjigeorgiou GM, Vu TH, Tadesse S, Nygaard TG, Nonaka I, Hirano I, Bonilla E, Rowland LP, DiMauro S, Hirano M. Mitochondrial neurogastrointestinal encephalomyopathy: an autosomal recessive disorder due to thymidine phosphorylase mutations. Ann Neurol 2000;47:792–800

Mitochondrial encephalomyopathies encompass a diverse and expanding group of disorders caused by defects of the mitochondrial respiratory chain. Mitochondrial enzymes are the products of two genomes, nuclear DNA (nDNA) and mitochondrial DNA (mtDNA). As a result, mitochondrial encephalomyopathies are caused by defects in either genome or in the intercommunication between the genomes. For more than a decade,

From the *Department of Neurology and ‖‖Division of Gastroenterology, Columbia University College of Physicians and Surgeons, New York, NY; †Department of Neurology, University of Thessalia Medical School, Larissa, Greece; ‡Wessex Neurological Centre, Southampton, UK; §Department of Neurology, Hadassah University Hospital, Jerusalem, Israel, ‖Division of Neurology, The Hospital for Sick Children, Toronto, Canada; #Department of Neurology, Washington University at St Louis, St Louis, MO; ¶Wallonia Centre for Human Genetics, Université de Liège, Liège, Belgium; **Department of Neurology, Serviço Universitàrio de Neurologia, Hospital de Egas Moniz, Lisboa, Portugal; ††Department of Internal Medicine, Centre Hospitalier Univeristaire Vaudois, Lausanne, Switzerland; ‡‡Department of Neurology, Tokai University School of Medicine, Kanagawa, Japan; §§Dipartimento di Pediatria "Cesare Cocchi," Firenze, Italy; ##Department of Neurology, Lahey Clinic, Burlington, MA; ¶¶Department of Neurology, University of Medicine and Dentistry in New Jersey, Newark, NJ; ***Department of Ultrastructural Research, National Institute of Neuroscience, National Center of Neurology and Psychiatry, Tokyo, Japan; and †††Division of Gastroenterology, Northwestern School of Medicine, Chicago, IL.

Received Dec 22, 1999, and in revised form Feb 14, 2000. Accepted for publication Feb 15, 2000.

Address correspondence to Dr Hirano, Department of Neurology, Columbia University College of Physicians and Surgeons, P&S 4-443, 630 West 168th Street, New York, NY 10032.

 Copyright © 2000 by the American Neurological Association

investigators have focused primarily on mtDNA and have identified more than 50 distinct point mutations as well as large-scale molecular rearrangements.[1] Since 1995, several mutations of nuclear DNA have been identified as causes of respiratory chain monoenzymopathies.[2,3] Until 1999, however, there were no known mutations of nDNA leading to depletion or multiple deletions of mtDNA.

Mitochondrial neurogastrointestinal encephalomyopathy (MNGIE) is an autosomal recessive disease associated with multiple deletions and depletion of mtDNA in skeletal muscle.[4,5] In 1976, Okamura and associates[6] reported the first case as "congenital oculoskeletal myopathy with abnormal muscle and liver mitochondria." Since then, more than 35 additional individuals with MNGIE have been described,[4,5,7–16] with several acronyms: myo-, neuro-, gastrointestinal encephalopathy (MNGIE)[8]; polyneuropathy, ophthalmoplegia, leukoencephalopathy, and intestinal pseudoobstruction (POLIP)[9]; oculogastrointestinal muscular dystrophy (OGIMD)[7]; and mitochondrial encephalomyopathy with sensorimotor polyneuropathy, ophthalmoplegia, and pseudo-obstruction (MEPOP).[17]

We have identified mutations in the gene encoding thymidine phosphorylase (TP), located on chromosome 13.32-qter, as the cause of MNGIE.[18,19] Normally, the enzyme catabolizes thymidine to thymine and 2-deoxy-D-ribose 1-phosphate.[20] In MNGIE patients, mutations in TP severely reduce the enzyme activity in leukocytes and presumably in other tissues.[19] As a consequence of the TP defect, average plasma levels of thymidine are elevated nearly 50-fold in patients (Spinazzola A, manuscript in preparation). The accumulation of thymidine is likely to alter deoxynucleoside and nucleotide pools and consequently impair mtDNA replication, repair, or both, leading to mtDNA abnormalities. To better understand the disorder, we reviewed the clinical features of 21 MNGIE probands with homozygous or compound heterozygous mutations and their affected siblings.

Methods

Subjects

We identified 21 probands with the six major features that define MNGIE: severe gastrointestinal dysmotility, achexia, ptosis with progressive external ophthalmoparesis, peripheral neuropathy, leukoencephalopathy, and laboratory evidence of mitochondrial dysfunction. Fourteen affected siblings were added. All patients were assessed by at least one neurologist and a gastroenterologist. We were unable to obtain complete clinical information or blood samples from many patients who had died. We also screened for TP defects in 13 individuals with some, but not all, of the clinical features of MNGIE. The study was performed under a protocol approved by the Columbia University Institutional Review Board.

Molecular Genetic Studies

The gene encoding TP has 10 exons and an open reading frame spanning from exons 2 to 10.[21] We amplified four fragments from genomic DNA, which encompassed exons 2–3, 4, 5–6, and 7–10. All primers were 20 nucleotides in length.[19] Their 5′ positions and directions (F indicates forward, and R reverse) are as follows: 267F and 952R for exons 2–3; 1283F and 1540R for exon 4; 2258F and 2959R for exons 5–6; and 3197F and 4254R for exons 7–10. We sequenced the fragments directly using the BigDye Terminator Cycle Sequencing Kit (PE Biosystems, Foster City, CA) and then electrophoresed the samples using an ABI PRISM 310 Genetic Analyzer (PE Biosystems). Southern blot analyses were probed with α-^{32}P-dATP–labeled total mtDNA and 18S ribosomal DNA.[22]

Biochemical Studies

The rate of conversion of thymidine to thymine was measured spectrophotometrically using modifications of protocols described elsewhere.[23–25] Peripheral leukocytes were homogenized in lysis buffer (50 mM Tris-HCl pH 7.2, containing 1% Triton X-100, 2 mM phenylmethylsulfonyl fluoride, and 0.02% 2-mercaptoethanol) and subjected to brief sonication. Samples were centrifuged at 20,000*g* for 30 minutes at 4°C, and the supernatants were used for the enzyme assay. From each supernatant, 100 to 250 μg of protein was incubated with 0.1 M Tris-arsenate buffer (pH 6.5) and 10 mM thymidine in a total volume of 0.1 ml. After incubation for 1 hour at 37°C, the reaction was terminated by adding 1 ml of 0.3 M NaOH. The amount of thymine formed was measured at 300 nm, based on a 3.4×10^3 difference in the molar extinction coefficient between thymidine and thymine at alkaline pH. Enzyme activity was expressed as the amount of thymine (μmol) generated per hour per milligram of protein. The protein content was determined as in Bradford's article.[26] Results were obtained from two independent experiments performed in duplicate.

Results

Clinical Features

All 21 probands and 13 of 14 affected siblings fulfilled the clinical criteria. The 18-year-old brother of Proband 4 did not have MNGIE, but he was thin and had ptosis, mild paresis of horizontal eye movements, decreased vibratory sense in his digits, and prominent bowel sounds without definite signs of gastrointestinal dysmotility. The 35 patients are summarized in Tables 1 and 2. Twelve patients (7 probands; Table 3) have been reported previously: Persons 1 and 3 in Family A by Steiner and colleagues[27]; two pairs of siblings, Patients 1, 2, 4, and 5, by Hirano and co-workers[4]; autosomal recessive progressive external ophthalmoplegia (PEO) Patients 2 and 3 by Carrozzo and associates[28]; 3 brothers by Papadimitriou and colleagues[5]; and individuals by Threlkeld[29] and Hamano[13] and their associates. The families were of diverse ethnic background (see Table 3). Parental consanguinity was noted in 10 of 21 families.

Table 1. Clinical Features of 35 Mitochondrial Neurogastrointestinal Encephalomyopathy Patients with Thymidine Phosphorylase Gene Mutations

Average age of living patients (n = 16)	35 yr (range, 18–53 yr)
Sex	15 men, 20 women
Age at onset (n = 24)	18.5 yr (range, 5 mo–43 yr)
Age at death (n = 17)	37.6 yr (range, 26–58 yr)
First symptom	
Gastrointestinal	14/31 (45%)
Extraocular	8/31 (26%)
Peripheral neuropathy	4/31 (13%)
Hearing loss/tinnitus	3/31 (10%)
Cachexia or weight loss	3/31 (10%)
Dry mouth	1/31 (3%)
Gastrointestinal manifestations	35/35 (100%)
Borborygmi	24/25 (96%)
Abdominal pain	17/18 (94%)
Diarrhea	27/29 (93%)
Early satiety	14/15 (93%)
Abdominal cramps	25/28 (89%)
Nausea/vomiting	23/31 (74%)
Diverticulosis	16/24 (67%)
Pseudo-obstruction	11/17 (65%)
Gastroparesis	4/7 (57%)
Dysphagia	12/28 (43%)
Hepatopathy	5/23 (22%)
Neurological manifestations	35/35 (100%)
Peripheral neuropathy	34/34 (100%)
Ptosis	34/34 (100%)
Ophthalmoparesis	35/35 (100%)
Areflexia	27/33 (82%)
Hearing loss	14/31 (45%)
Pigmentary retinopathy	2/33 (6%)
Mental retardation	1/35 (3%)
Dementia	0/35 (0%)
Other clinical features	
Thin	35/35 (100%)
Weight loss	19/19 (100%)
Men	
Average height (±SD)	170.0 ± 12.0 cm
Average weight (±SD)	40.3 ± 7.6 kg
Women	
Average height (±SD)	159.1 ± 7.1 cm
Average weight (±SD)	35.5 ± 6.8 kg
Consanguineous parents	10/21 families (48%)

The age at onset varied from 5 months to 43 years. Two patients had symptoms before age 1 year, 1 with diarrhea at 5 months and the other with intestinal invagination at 8 months. Twenty of 35 patients (57%) had symptoms before age 20. Some manifestations of MNGIE are subtle and insidious (eg, ptosis, ophthalmoparesis, sensory neuropathy), and the actual age at onset of some patients may have been earlier than reported. Gastrointestinal symptoms, particularly diarrhea (6 patients) and abdominal pain (5 patients), were the most common initial manifestations, followed by ptosis and ophthalmoparesis (see Table 1). In 4 individuals, peripheral neuropathy was the first symptom, suggesting that the neuropathy was not caused by nutritional deficiency.

Most patients were thin throughout their lives, and all reported weight loss averaging 15.2 kg (range, 5.9–30.0 kg). At least 1 patient was moderately obese in early adult years; her height was 163 cm and she weighed 72 kg, but she lost 30 kg. Weight loss generally coincided with the onset or worsening of gastrointestinal symptoms. Some patients were short; 5 of 15 men were less than 165 cm in height and 7 of 17 women were shorter than 155 cm. However, at least 2 men were taller than 185 cm.

All patients had gastrointestinal manifestations related to dysmotility: borborygmi, diarrhea, early satiety, abdominal cramps, nausea, vomiting, intestinal pseudo-obstruction, and gastroparesis (see Table 1). Diverticulosis was detected in 16 of 24 patients and was specifically localized to the small intestine in 7. At least 3 patients reported improvement of borborygmi and abdominal pain with antibiotic treatment, suggesting that bacterial overgrowth may have contributed to these symptoms. Dysphagia was common (11/25), and 1 person had aspiration, indicating oropharyngeal dysfunction. Hepatopathy was noted in 5 of 20 patients: 4 had a fatty liver attributed to parenteral nutrition and 1 had cryptogenic cirrhosis.

The most common neurological features of MNGIE were peripheral neuropathy, ptosis, ophthalmoparesis, and hearing loss. In general, the neuropathy was clinically mild, but 3 patients had debilitating distal limb weakness. Two patients had pigmentary retinopathy. Diffuse leukoencephalopathy was found in all 27 patients who underwent brain magnetic resonance imaging (MRI); relative sparing of the corpus callosum was noted in at least 3 patients (Fig). Dementia was not detected in any patient, and mental retardation was seen in only 1. Cerebrospinal fluid showed elevated protein content in 8 of 9 patients; in 3, the protein exceeded 100 mg/dl (normal, 15–45 mg/dl). Nerve conduction and electromyographic studies in all 28 patients tested revealed neurogenic changes, and 11 showed additional features of a myopathy. The nerve conduction velocities were consistent with a demyelinating neuropathy in all patients tested, and 13 also revealed abnormalities compatible with an axonal neuropathy (see Table 2).

Routine clinical evaluations revealed serum lactic acidosis in 12 of 18 patients. Despite the gastrointestinal dysfunction, 7 of 8 patients had normal serum content of vitamin E, and none had low folate or B_{12} levels (see Table 2). No patients had cardiovascular symptoms, but electrocardiograms in 3 of 18 patients were abnormal; 2 had left ventricular hypertrophy, and 1 had an incomplete right bundle branch block.

Sixteen patients died at an average age of 35 (range, 18–53 years). The cause of death was known in 9 pa-

Table 2. Laboratory Features of 35 Mitochondrial Neurogastrointestinal Encephalomyopathy Patients with Thymidine Phosphorylase Gene Mutations

Leukoencephalopathy	27/27 (100%)
Abnormal NCS/EMG	28/28 (100%)
Neurogenic only	17/28 (61%)
Neurogenic and myogenic	11/28 (39%)
Consistent with demyelinating neuropathy	13/28 (46%)
Consistent with mixed axonal and demyelinating neuropathy	15/28 (54%)
Myogenic only	0/28 (0%)
Lactic acidosis	12/19 (63%)
Muscle mitochondrial respiratory chain defect	7/14 (50%)
Complex IV deficiency	3/14 (21%)
Complex I+IV deficiency	3/14 (21%)
Multiple complex deficiencies	1/14 (7%)
Abnormal skeletal muscle biopsy	21/21 (100%)
COX-deficient fibers	16/16 (100%)
Neurogenic atrophy	18/21 (86%)
Increased SDH staining or RRFs	12/19 (63%)
Elevated CSF protein	8/9 (89%)
Abnormal electrocardiogram	3/18 (17%)
Left ventricular hypertrophy	2/18 (11%)
Heart block (incomplete RBBB)	1/18 (6%)
Vitamin E deficiency	1/8 (slight deficiency) (12.5%)
Vitamin B_{12} deficiency	0/5 (0%)
Folate deficiency	0/5 (0%)

NCS/EMG = nerve conduction studies/electromyography; COX = cytochrome *c* oxidase; SDH = succinate dehydrogenase; RRF = ragged red fibers; RBBB = right bundle branch block; CSF = cerebrospinal fluid.

tients. Two died of peritonitis due to intestinal rupture and 2 of aspiration pneumonia. One each died of cardiac arrest, malignant melanoma, suicide, postcolostomy complications, and esophageal variceal bleeding related to cirrhosis.

All 13 individuals who did not fulfill the clinical criteria for MNGIE had gastrointestinal dysmotility, including 4 with intestinal pseudo-obstruction. Six also had peripheral neuropathy, 5 were cachectic, 3 had ptosis, and 2 had PEO. Leukoencephalopathy was absent in brain MRIs of 7 patients.

Histology

Skeletal muscle biopsies were abnormal in all 21 samples. Group atrophy, fiber type grouping, or target/targetoid fibers were detected in 18 patients, reflecting the neuropathy. Morphological evidence of abnormal mitochondria was seen in most patients; 16 of 16 had cytochrome *c* oxidase (COX)-deficient fibers, and 12 of 19 showed focal mitochondrial proliferation with increased succinate dehydrogenase histochemical staining or ragged red fibers on Gomori trichrome stain.

Mitochondrial Respiratory Chain Activities

Measurement of muscle mitochondrial respiratory enzyme activities was abnormal in 7 of 12 patients. COX (complex IV of the mitochondrial respiratory chain) was low in 3 muscle samples, in isolation (3 patients), in combination with low complex I activity (3 patients), or in association with multiple respiratory chain enzyme defects (1 patient).

MtDNA Molecular Genetics

By Southern blot analysis, mtDNA abnormalities were detected in 16 of 18 muscle biopsies, but 8 samples were not screened for mtDNA depletion. Ten skeletal muscle biopsy specimens were analyzed with probes for nDNA and mtDNA; mtDNA depletion was identified in all. Relative to controls, the amount of muscle mtDNA in MNGIE patients ranged from 5 to 66%. Multiple mtDNA deletions were identified by Southern blot analysis in 9 of 18 patients. The amount of multiple deletions relative to total mtDNA was determined in 2 patients. The multiple deletions represented a small proportion of the total mtDNA: 6% in Proband 1 and 20% in Proband 3 (previously reported as Patients 2 and 3 by Carrozzo and colleagues[28]). Three siblings, 45 to 49 years old, screened by polymerase chain reaction had multiple deletions that were undetectable by Southern blot.[5]

We found a possible relationship between mitochondrial respiratory enzyme activities and mtDNA abnormalities in only 7 patients. COX deficiency seemed to be related to mtDNA depletion rather than multiple deletions of mtDNA (Table 4). Two muscle samples had levels of mtDNA that were less than 50% of normal (and no mtDNA deletions by Southern blot analysis); both had significantly decreased COX activity.

Table 3. Thymidine Phosphorylase Gene Mutations, Enzyme Activities, and mtDNA Abnormalities in 21 Mitochondrial Neurogastrointestinal Encephalomyopathy Probands[a]

Proband	Ethnic Origin	Mutation	Exon/ Intron	mRNA Alteration	Predicted aa Alteration	Leukocyte TP Activity (μmol/hr/mg[b])	Multiple mtDNA Deletions	mtDNA Depletion
1	Askenazi Jewish	A3371C	E7	ND	E289A			
		A3371C	E7	ND	E289A	0	+	+
2	German American	t1504c	I4	E4 skipping	Loss of 33 aa			
		A3371C	E7	ND	E289A	0	+	+
3	Puerto Rican	G1419A	E4	ND	G145R			
		G1419A	E4	ND	G145R	0.03	+	+
4	African American	A2744G	E6	ND	K222R			
		ins4196C	E10	ND	Frameshift	0.004	+	ND
5	Iranian Jewish	G1419A	E4	ND	G145R			
		G1419A	E4	ND	G145R	ND	ND	ND
6	Puerto Rican	G1419A	E4	ND	G145R			
		G1419A	E4	ND	G145R	0.003	+	+
7	European American	A3371C	E7	ND	E289A			
		g3867c	I8	E9 skipping	Loss of 47 aa	0	+	ND
8	German American	G1419A	E4	ND	G145R			
		4-bp del	I7	ND	?	ND	−	+
9	German Canadian	6-bp del	E9	ND	Loss of 2 aa			
		g4090a	I9	ND	?	ND	−	ND
10	European American	G1443A	E4	ND	G153S			
		A3371C	E7	ND	E289A	ND	+	+
11	English	G1443A	E4	ND	G153S			
		A3371C	E7	ND	E289A	ND	−	ND
12	English	G1443A	E4	ND	G153S			
		G1443A	E4	ND	G153S	ND	−	ND
13	Greek	g3867a	I8	E9 skipping	Loss of 47 aa		+ (by	
		g3867a	I8	E9 skipping	Loss of 47 aa	ND	PCR)	+
14	European American	G3370A	E7	ND	E289K			
		C4202T	E10	ND	S471L	ND	ND	ND
15	Belgian	A3371C	E7	ND	E289A			
		A3371C	E7	ND	E289A	ND	Single?	ND
16	Portuguese	T1464C	E4	ND	S160P			
		T1464C	E4	ND	S160P	0	+	ND
17	Italian (Sicilian)	g3867a	I8	ND	Loss of 47 aa			
		g3867a	I8	ND	Loss of 47 aa	ND	ND	ND
18	Dominican	T2293G	E5	ND	M173G			
		T2293G	E5	ND	M173G	0	ND	ND
19	Japanese	C4202T	E10	ND	S471L			
		C4202T	E10	ND	S471L	ND	ND	ND
20	Swiss	2-bp del	E2	ND	Frameshift			
		2-bp del	E2	ND	Frameshift	0	−	ND
21	Italian	g3867a	I8	E9 skipping	Loss of 47 aa			
		g3867a	I8	E9 skipping	Loss of 47 aa	ND	ND	ND

[a]Seven patients were described previously in clinical reports: Proband 1 (autosomal recessive PEO Patient 3[28]), Proband 2 (Patient 4[4]), Proband 3 (autosomal recessive PEO Patient 2[28]), Proband 5 (Patient 1 of family A[27]), Proband 8 (Patient 1[4]), Proband 10 (Patient[29]), Proband 13 (eldest sibling[5]), and Proband 19 (Patient[13]). Probands 1 to 4 are from 4 families reported in a linkage study.[18] The molecular genetic features of Probands 1 to 12 were described in an earlier report.[19]
[b]Control leukocyte TP activity is 0.67 ± 0.21 μmol/hr/mg (n = 19).

aa = amino acids; TP = thymide phosphorylase; PCR = polymerase chain reaction; ND = not determined; PEO = progressive external ophthalmoplegia.

By contrast, 5 samples had mtDNA multiple deletions on Southern blot and mtDNA levels over 50% of normal; 4 of the 5 had normal COX activities.

Thymidine Phosphorylase

We identified homozygous or compound heterozygous mutations in the thymidine phosphorylase gene in all 21 probands and 12 siblings tested (see Table 3). We were unable to obtain DNA samples from 2 patients. We identified 16 distinct mutations: 8 missense, 4 splice-site, 3 microdeletions, and 1 single nucleotide insertion (see Table 3). The g3867a splice acceptor site mutation was identified in 1 Greek and 2 Italian families; this mutation may be more common in the Med-

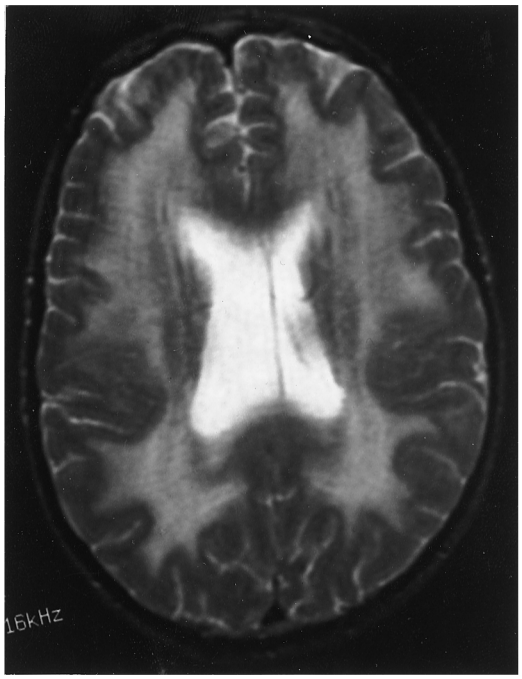

Fig. T2-weighted brain magnetic resonance imaging scan of Proband 18 demonstrating diffusely increased signal in the white matter with relative sparing of the corpus callosum.

iterranean region. We did not identify correlations between specific mutations and severity or type of mtDNA alteration.

Using our fixed-time assay, leukocyte TP activity was severely reduced in all patients tested, 0.009 ± 0.021 μmol/hr/mg (mean ± SD; n = 16), compared with controls, 0.67 ± 0.21 μmol/hr/mg (n = 19). TP activity in all patients was less than 5% of normal control mean. There was no relation between specific TP mutations and the severity of the enzymatic defect. In fact, patients sharing the same mutations showed variable enzyme activities. Because the assay was not linear over time, we cannot determine whether there was a correlation between the TP mutations and Vmax of the enzyme.

Thymidine phosphorylase activity in leukocytes was normal in 12 of 13 patients who did not fulfill the clinical criteria for MNGIE. Blood was not available from 1 of the 13 patients, but the DNA sequence of 9 protein coding exons of TP was normal.

Genotype and Phenotype Correlations

We found no correlation between specific TP mutations and the following clinical features: age at onset, age at death, body mass index, and presence or absence of specific clinical signs or symptoms (data not shown).

Discussion

To expand our understanding of MNGIE, we have reviewed clinical, biochemical, and molecular genetic features of 21 probands and 14 affected siblings, including 13 who fulfilled our clinical criteria for diagnosis. Only an 18-year-old brother of proband 4 does not have all of the clinical signs of MNGIE, but he had borborygmi, mild ptosis, and a thin body, and additional manifestations are likely to develop.

The identification of 34 MNGIE patients with homozygous or compound heterozygous TP gene mutations indicates that this multisystemic disorder is clinically homogeneous. Nevertheless, the age at onset varies from infancy to middle age (see Table 1). Most patients have symptoms in adolescence or early adulthood and die by age 58.

The most prominent and debilitating symptom is gastrointestinal dysmotility, which is due to neuromuscular dysfunction and which can affect any portion of the enteric system from the oropharynx[9,30] through the small intestine.[4,6–8,10,15,16,30] Decreased small intestine motility and delayed gastric emptying are the most common forms of dysmotility.[4] Histological abnor-

Table 4. Skeletal Muscle Mitochondrial Respiratory Chain Enzyme Activities and mtDNA Depletion and Multiple Deletions

Patient or Proband	mtDNA Deletions	mtDNA Depletion	NADH-Dehydrogenase	Complex II	Complex I+III	Complex II+III	Complex IV	Citrate Synthase
Proband 1	+	66%	32.9	2.1	1.1	0.84	4.6	14.3
Proband 2	+	64%	21.5	0.86	3.6	0.80	2.8	17.3
Patient 2a	+	53%	17.3	0.56	2.0	0.89	2.8	21.3
Proband 3	+	32%	27.2	1.3	1.0	0.4	**1.8**	11.9
Proband 8	−	58%	55.2	3.4	0.86	2.7	2.9	22.7
Patient 8a	−	20%	55.2	2.9	0.97	1.8	**1.5**	15.4
Proband 10	+	65%	26.4	1.9	1.5	1.5	1.9	14.9
Proband 14	N/D	N/D	**18.7**	1.6	**0.51**	**0.20**	**1.6**	16.4
Control	−	100%	35.5 ± 7.1	1.0 ± 0.53	1.0 ± 0.23	0.70 ± 0.23	2.8 ± 0.52	9.9 ± 2.6

Mitochondrial enzyme activities are expressed as μmol/min/g. Patients 2a and 8a are siblings of Probands 2 and 8, respectively. Results of mitochondrial respiratory chain enzyme activities and mtDNA abnormalities in Proband 7 and his siblings were previously reported.[5] Mitochondrial enzyme activities in Patient 21 were normal in another laboratory. Control values are means ± SD (n = 69). Values more than 2 SD below the control means are considered abnormal and are highlighted in bold.

malities affect both intestinal smooth muscles and the enteric nervous system.[4,7–10,15] Similarly, manometric studies of the gastrointestinal tract have given variable results. Enteric neuropathy was indicated by esophageal aperistalsis with spontaneous contraction in 1 patient[31] and low-amplitude nonpropagated short duration contractions of the striated portion of the esophagus in another patient.[30] By contrast, Mueller and associates[16] found diminished amplitude of small bowel contractions both in fasting and fed states; they attributed this to visceral myopathy. Regardless of the cause, small intestinal dysmotility presumably leads to the unusually frequent incidence of diverticula in the duodenum and jejunum in MNGIE patients, affecting at least 7 of 24 patients in our series. In 2 of our patients, ruptured diverticula resulted in fatal peritonitis.

It is not clear why MNGIE affects the enteric neuromuscular system severely; however, abnormalities of the gastrointestinal system are being increasingly recognized as manifestations of mitochondrial disorders.[32–36]

Cachexia is another striking feature of all MNGIE patients. The weight loss is, in part, attributable to the gastrointestinal dysfunction. The brother of Proband 2 recovered about 9 kg when receiving total parenteral nutrition (TPN), so bypassing the dysfunctional gastrointestinal system may help transiently. Nevertheless, the patient remained thin (178 cm in height and 50 kg in weight) despite the TPN therapy. At age 33, he died of pneumonia after a colostomy had been performed. One other patient (Proband 3) did not gain weight on TPN.

In contrast to the gastrointestinal problems, the neurological features are mild. Ptosis and ophthalmoparesis are evident to examiners but may be asymptomatic. The peripheral neuropathy causes stocking-glove sensory loss, and tendon reflexes are lost. The neuropathy is usually not severe, but 3 patients had debilitating weakness of the hands and feet. Similarly, the lack of muscle bulk in these thin patients is not associated with marked weakness and the striking leukoencephalopathy evident on brain MRI is not manifest as gross dementia or mental retardation. Although the white matter changes are diffuse, sparing of the corpus callosum has been noted in several patients.[9]

MNGIE is a mitochondrial disorder with lactic acidosis, histologically and biochemically abnormal mitochondria, and mtDNA defects. However, these changes were variably seen in our patients. Reduced mitochondrial respiratory chain enzyme activity was identified in both patients with mtDNA levels below 50% of normal and in 3 other patients,[5] but not in 4 of 5 patients with mtDNA deletions on Southern blot (see Table 4). These data suggest that mtDNA depletion is more significant than mtDNA multiple deletions in the pathogenesis of MNGIE. We did not attribute the multiple mtDNA deletions to aging because all of the probands were less than 50 years old.

The identification of loss-of-function TP gene mutations has enhanced understanding of the pathogenesis of MNGIE. The virtual absence of TP enzyme activity suggests that the genetic defects are equivalent to null mutations. The functional significance of TP protein has been well characterized in vitro.[20] TP is a homodimer that plays a role in homeostasis of cellular nucleotide pools. Normally, TP catalyzes the reversible phosphorolysis of thymidine plus phosphate to thymine and 2-deoxy-D-ribose 1-phosphate.[20] The forward reaction, conversion of thymidine to thymine, is important in the catabolism of the nucleoside, whereas the reverse reaction may be important for the pyrimidine salvage pathway in which thymidine is converted to deoxythymidine triphosphate (dTTP), an essential building block of DNA. Preliminary results have demonstrated that on-average plasma thymidine levels are elevated nearly 50-fold in MNGIE patients (Spinazzola A, manuscript in preparation).

In MNGIE patients, alterations of thymidine metabolism seem to affect deoxynucleoside triphosphate (dNTP) pools in mitochondria more severely than in nuclei. One possible reason for this effect on the mitochondria is that these organelles seem to have separate and independently regulated dNTP pools.[37–39] Bogenhagen and Clayton[37] showed that mitochondrial DNA replication in mouse L cells resists inhibition by methotrexate and 5-flurodeoxyuridine, which both block de novo thymidine synthesis by inhibiting the activity of thymidylate synthetase in converting deoxyuridine monophosphate (dUMP) to thymidylate (deoxythymidine monophosphate; dTMP). Mitochondrial nucleoside triphosphate pools expand in response to these antimetabolites.[39] Mitochondria are therefore more dependent on the thymidine salvage pathway than the de novo synthetic pathway.

Because mitochondria rely on the thymidine salvage pathway, the mitochondrial dTTP pools can be perturbed by alterations of thymidine levels. A mitochondrial-specific thymidine kinase (TK2), converts thymidine to thymidine monophosphate and probably contributes to the alterations of the mitochondrial dNTP pool.[38–41] TK2 is expressed constitutively, in contrast to the cytosolic TK1, which is upregulated during cell division.[41] The stochastic activity of TK2 is likely to contribute to the susceptibility of mitochondrial dNTP pools to altered thymidine levels. In turn, the altered mitochondrial dNTP pools may lead to mtDNA depletion and multiple deletions over the lifetime of patients with MNGIE. Therefore, because elevated thymidine levels might be directly deleterious to mtDNA rather than the loss of TP activity per se, increased extracellular thymidine pools might

account for the involvement of tissues, such as muscle, that do not express TP protein.

Nucleoside analogue therapy in patients has provided further evidence that alterations of nucleoside metabolism can impair mtDNA replication and produce mtDNA depletion.[42–45] Zidovudine therapy in human immunodeficiency virus–infected patients is associated with a mitochondrial myopathy caused by inhibition of mitochondrial DNA polymerase-γ and leading to mtDNA depletion.[42,43] In an aborted clinical trial for chronic hepatitis B virus infection, the nucleoside analogue fialuridine led to severe toxicity with lactic acidosis, hepatic failure, hepatic steatosis, skeletal and cardiac myopathy, peripheral neuropathy, and pancreatitis due to inhibition of mtDNA replication.[45,46]

The mechanism responsible for formation of multiple mtDNA deletions in MNGIE is unknown. The nucleotide imbalance might lead to lack of nucleotides that could cause stalling of mtDNA replication and, in turn, increase the probability of slip-replication events.[47]

The identification of TP defects in MNGIE expands our understanding of the complex interactions between the nDNA-encoded genes and mtDNA. Mitochondrial nucleoside and nucleotide metabolism may be a new mechanism for human disease.

This study was supported by grants from National Institutes of Health (RO1-HD-37529); the Uehara Memorial Foundation, Tokyo, Japan; Consiglio Nazionale dell Richerche, Rome, Italy; and the Columbia-Presbyterian Irving Scholars Program, New York, NY.

We acknowledge the following individuals who contributed to the clinical evaluations of the patients: Marcelo R. Olarte, MD, James A. Russell, DO, Julaine Florence, RN, MS, Glenn Lopate, MD, Laura Vilarinho, MD, PhD, Viani Baptista, MD, David R. Fine MD, Angelika F. Hahn, MD, FRCP(C), Ken Okamura, MD, Yukito Shinohara, MD, Giacomo P. Comi, Bernard Sadzot, MD, Marie-Denise Schaller, MD, José R. Carlo, MD, Larry M. Salberg, MD, Ian Butler, MD, Adam M. Bender, MD, David S. Younger, MD, and Robert E. Lovelace, MD. We thank Dr Eric A. Schon for critical advice.

References

1. Schon EA, Bonilla E, DiMauro S. Mitochondrial DNA mutations and pathogenesis. J Bioenerg Biomembr 1997;29:131–149
2. Bourgeron T, Rustin P, Chretien D, et al. Mutation of a nuclear succinate dehydrogenase gene results in mitochondrial respiratory chain deficiency. Nat Genet 1995;11:144–149
3. DiMauro S. Mitochondrial encephalomyopathies: back to mendelian genetics. Ann Neurol 1999;45:693–694
4. Hirano M, Silvestri G, Blake DM, et al. Mitochondrial neurogastrointestinal encephalomyopathy (MNGIE): clinical, biochemical, and genetic features of an autosomal recessive mitochondrial disorder. Neurology 1994;44:721–727
5. Papadimitriou A, Comi GP, Hadjigeorgiou GM, et al. Partial depletion and multiple deletions of muscle mtDNA in familial MNGIE syndrome. Neurology 1998;51:1086–1092
6. Okamura K, Santa T, Nagae K, Omae T. Congenital oculoskeletal myopathy with abnormal muscle and liver mitochondria. J Neurol Sci 1976;27:79–91
7. Ionasescu V. Oculogastrointestinal muscular dystrophy. Am J Med Gen 1983;15:103–112
8. Bardosi A, Creutzfeldt W, DiMauro S, et al. Myo-,neuro-,gastrointestinal encephalopathy (MNGIE syndrome) due to partial deficiency of cytochrome-c-oxidase: a new mitochondrial multisystem disorder. Acta Neuropathol (Berl) 1987;74:248–258
9. Simon LT, Horoupian DS, Dorfman LJ, et al. Polyneuropathy, ophthalmoplegia, leukoencephalopathy and intestinal pseudo-obstruction: POLIP syndrome. Ann Neurol 1990;28:349–360
10. Lowsky R, Davidson G, Wolman S, et al. Familial visceral myopathy associated with a mitochondrial myopathy. Gut 1993;34:279–283
11. Uncini A, Servidei S, Silvestri G, et al. Ophthalmoplegia, demyelinating neuropathy, leukoencephalopathy, myopathy, and gastrointestinal dysfunction with multiple deletions of mitochondrial DNA: a mitochondrial multisystem disorder in search of a name. Muscle Nerve 1994;17:667–674
12. Collier TG, Applegarth DA, Calne DB. Mitochondrial neurogastrointestinal encephalomyopathy with multiple deletions of mitochondrial DNA. Ann Neurol 1996;40:545
13. Hamano H, Ohta T, Takekawa Y, et al. Mitochondrial neurogastrointestinal encephalomyopathy presenting with protein-losing gastroenteropathy and serum copper deficiency: a case report. Rinsho Shinkeigaku 1997;10:917–922
14. Debouverie M, Wagner M, Ducrocq X, et al. MNGIE syndrome in 2 siblings. Rev Neurol (Paris) 1997;153:547–553
15. Perez-Atayde AR, Fox V, Teitelbaum JE, et al. Mitochondrial neurogastrointestinal encephalomyopathy: diagnosis by rectal biopsy. Am J Surg Pathol 1998;22:1141–1147
16. Mueller LA, Camilleri M, Emslie-Smith AM. Mitochondrial neurogastrointestinal encephalomyopathy: manometric and diagnostic features. Gastroenterology 1999;116:959–963
17. Rowland LP. Progressive external ophthalmoplegia. In: Vinkens PJ, Bruyn GW, Klawans HL, eds. Handbook of clinical neurology. Amsterdam: Elsevier, 1992:287–329
18. Hirano M, Yebenes J, Jones AC, et al. Mitochondrial neurogastrointestinal encephalomyopathy (MNGIE) syndrome maps to chromosome 22q13.32-qter. Am J Hum Genet 1998;63:526–533
19. Nishino I, Spinazzola A, Hirano M. Thymidine phosphorylase gene mutations in MNGIE, a human mitochondrial disorder. Science 1999;283:689–692
20. Brown NS, Bicknell R. Thymidine phosphorylase, 2-deoxy-D-ribose and angiogenesis. Biochem J 1998;334:1–8
21. Hagiwara K, Stenman G, Honda H, et al. Organization and chromosomal localization of the human platelet-derived endothelial cell growth factor gene. Mol Cell Biol 1991;11:2125–2132
22. Vu TH, Sciacco M, Tanji K, et al. Clinical manifestations of mitochondrial DNA depletion. Neurology 1998;50:1783–1790
23. Friedkin M, Roberts D. The enzymatic synthesis of nucleosides. I. Thymidine phosphorylase in mammalian tissue. J Biol Chem 1954;207:245–256
24. Marsh JC, Perry S. Thymidine catabolism by normal and leukemic human leukocytes. J Clin Invest 1964;43:267–278
25. Gallo RC, Perry S, Breitman TR. The enzymatic mechanisms for deoxythymidine synthesis in human leukocytes. I. Substrate inhibition by thymine and activation by phosphate or arsenate. J Biol Chem 1967;242:5059–5068
26. Bradford MM. A rapid and sensitive method for the quantitation of microgram quantities of protein utilizing the principle of protein-dye binding. Anal Biochem 1976;72:248–254
27. Steiner I, Steinberg A, Argov Z, et al. Familial progressive

neuronal disease and chronic idiopathic intestinal pseudo-obstruction. Neurology 1987;37:1046–1050
28. Carrozzo R, Hirano M, Fromenty B, et al. Multiple mtDNA deletions features in autosomal dominant and recessive diseases suggest distinct pathogeneses. Neurology 1998;50:99–106
29. Threlkeld AB, Miller NR, Golnik KC, et al. Ophthalmic involvement in Myo-neuro-gastrointestinal encephalopathy syndrome. Am J Ophthalmol 1992;114:322–328
30. Li V, Hostein J, Romero NB, et al. Chronic intestinal pseudoobstruction with myopathy and ophthalmoplegia: a muscular biochemical study of a mitochondrial disorder. Dig Dis Sci 1992;37:456–463
31. Cervera R, Bruix J, Bayes A, et al. Chronic intestinal pseudoobstruction and ophthalmoplegia in a patient with mitochondrial myopathy. Gut 1988;29:544–547
32. Ban S, Mori N, Saito K, et al. An autopsy case of mitochondrial encephalomyopathy (MELAS) with special reference to extra-neuromuscular abnormalities. Acta Pathol Jpn 1992;42:818–825
33. Nicholl JA, Moss TH, Love S, et al. Clinical and autopsy findings in two cases of MELAS presenting with stroke-like episodes but without clinical myopathy. Clin Neuropathol 1993;12:38–43
34. Zelnik N, Axelrod FB, Leshinsky E, et al. Mitochondrial encephalomyopathies presenting with features of autonomic and visceral dysfunction. Pediatr Neurol 1996;14:251–254
35. Verma A, Piccoli DA, Bonilla E, et al. A novel mitochondrial G8313A mutation associated with prominent initial gastrointestinal symptoms and progressive encephaloneuropathy. Pediatr Res 1997;42:448–454
36. Kuroiwa T, Kuwata T, Nakayama T, et al. Mitochondrial encephalomyopathy showing prominent microvacuolation and necrosis of intestinal smooth muscle cells: a case diagnosed by rectal biopsy. Acta Neuropathol (Berl) 1998;96:86–90
37. Bogenhagen D, Clayton DA. Thymidylate nucleotide supply for mitochondrial DNA synthesis in mouse L cells. J Biol Chem 1976;249:2938–2944
38. Bestwick RK, Mathews CK. Unusual compartment of precursors for nuclear and mitochondrial DNA in mouse L cells. J Biol Chem 1982;257:9305–9308
39. Bestwick RK, Moffett GL, Mathews CK. Selective expansion of mitochondrial nucleoside triphosphate pools in antimetabolite-treated HeLa cells. J Biol Chem 1982;257:9300–9304
40. Berk AJ, Clayton DA. A genetically distinct thymidine kinase in mammalian mitochondrial. Exclusive labeling of mitochondrial deoxyribonucleic acid. J Biol Chem 1973;248:2722–2729
41. Johansson M, Karlsson A. Cloning of the cDNA and chromosomal localization of the gene for human thymidine kinase 2. J Biol Chem 1997;13:8454–8458
42. Dalakas MC, Illa I, Pezeshkpour GH, et al. Mitochondrial myopathy caused by long-term zidovudine therapy. N Engl J Med 1990;322:1098–1105
43. Arnaudo E, Dalakas MC, Shanske S, et al. Depletion of muscle mitochondrial DNA in AIDS patients with zidovudine-induced myopathy. Lancet 1991;337:508–510
44. Lewis W, Dalakas MC. Mitochondrial toxicity of antiviral drugs. Nat Med 1995;1:417–422
45. Cui L, Toon S, Shininazi RF, Sommadossi J-P. Cellular and molecular events leading to mitochondrial toxicity of 1-[2′-deoxy-2′fluoro-β-D-arabinofuranosyl]-5-iodouracil in human liver cells. J Clin Invest 1995;95:555–563
46. Brahams D. Deaths in US fialuridine trial. Lancet 1994;343:1494–1495
47. Shoffner JM, Lott MT, Voljavec AS, et al. Spontaneous Kearns-Sayre/chronic external ophthalmoplegia plus syndrome associated with a mtDNA deletion: a slip-replication model and metabolic therapy. Proc Natl Acad Sci 1989;86:7952–7956