doi:10.1093/brain/awr245 Brain 2011: 134; 3326–3332 | 3326

BRAIN
A JOURNAL OF NEUROLOGY

Clinical and genetic spectrum of mitochondrial neurogastrointestinal encephalomyopathy

Caterina Garone,[1,2] Saba Tadesse[1] and Michio Hirano[1]

1 Department of Neurology, Columbia University Medical Centre, New York, NY 10032, USA
2 Human Genetics Joint PhD Programme, University of Turin, 10125 Turin, Italy and University of Bologna, 40125 Bologna, Italy

Correspondence to: Michio Hirano, MD,
Columbia University Medical Centre,
630 W. 168th St,
P&S 4-423 New York,
NY 10032, USA
E-mail: mh29@columbia.edu

Mitochondrial neurogastrointestinal encephalomyopathy is a rare multisystemic autosomic recessive disorder characterized by: onset typically before the age of 30 years; ptosis; progressive external ophthalmoplegia; gastrointestinal dysmotility; cachexia; peripheral neuropathy; and leucoencephalopathy. The disease is caused by mutations in the *TYMP* gene encoding thymidine phosphorylasethymine phosphorylase. Anecdotal reports suggest that allogeneic haematopoetic stem cell transplantation may be beneficial for mitochondrial neurogastrointestinal encephalomyopathy, but is associated with a high mortality. After selecting patients who fulfilled the clinical criteria for mitochondrial neurogastrointestinal encephalomyopathy and had severe thymidine phosphorylase deficiency in the buffy coat (<10% of normal activity), we reviewed their medical records and laboratory studies. We identified 102 patients (50 females) with mitochondrial neurogastrointestinal encephalomyopathy and an average age of 32.4 years (range 11–59 years). We found 20 novel *TYMP* mutations. The average age-at-onset was 17.9 years (range 5 months to 35 years); however, the majority of patients reported the first symptoms before the age of 12 years. The patient distribution suggests a relatively high prevalence in Europeans, while the mutation distribution suggests founder effects for a few mutations, such as c.866A>G in Europe and c.518T>G in the Dominican Republic, that could guide genetic screening in each location. Although the sequence of clinical manifestations in the disease varied, half of the patients initially had gastrointestinal symptoms. We confirmed anecdotal reports of intra- and inter-familial clinical variability and absence of genotype–phenotype correlation in the disease, suggesting genetic modifiers, environmental factors or both contribute to disease manifestations. Acute medical events such as infections often provoked worsening of symptoms, suggesting that careful monitoring and early treatment of intercurrent illnesses may be beneficial. We observed endocrine/exocrine pancreatic insufficiency, which had not previously been reported. Kaplan–Meier analysis revealed significant mortality between the ages of 20 and 40 years due to infectious or metabolic complications. Despite increasing awareness of this illness, a high proportion of patients had been misdiagnosed. Early and accurate diagnosis of mitochondrial neurogastrointestinal encephalomyopathy, together with timely treatment of acute intercurrent illnesses, may retard disease progression and increase the number of patients eligible for allogeneic haematopoetic stem cell transplantation.

Keywords: mitochondrial disease; MNGIE; encephalomyopathy; *TYMP*; BMT

Abbreviations: MNGIE = mitochondrial neurogastrointestinal encephalomyopathy

Received April 24, 2011. Revised July 10, 2011. Accepted July 18, 2011. Advance Access publication September 20, 2011
© The Author (2011). Published by Oxford University Press on behalf of the Guarantors of Brain. All rights reserved.
For Permissions, please email: journals.permissions@oup.com

Downloaded from http://brain.oxfordjournals.org/ by guest on November 15, 2015

Introduction

Defects of intergenomic communication are clinically and genetically diverse autosomal disorders with pathogenic secondary instability of mitochondrial DNA manifesting as multiple deletions, depletion and point mutations. The first defect of intergenomic communication to be molecularly defined, mitochondrial neurogastrointestinal encephalomyopathy (MNGIE), is caused by mutations in nuclear gene *TYMP*, encoding thymidine phosphorylase (Nishino *et al.*, 1999). Since the initial clinical description in 1976 (Okamura *et al.*, 1976), studies of MNGIE have followed a clear path from characterization of the clinical features, definition of the diagnostic clinical criteria, identification of the pathogenic *TYMP* mutations and characterization of the molecular pathogenesis (Hirano *et al.*, 1994, 1998; Papadimitriou *et al.*, 1998; Nishino *et al.*, 1999; Spinazzola *et al.*, 2002; Martí *et al.*, 2003; Nishigaki *et al.*, 2003). Moreover, remarkable therapeutic success has been obtained using allogeneic haematopoetic stem cell transplantation, the first example of stem cell therapy in mitochondrial diseases (Hirano *et al.*, 2006; Schüpbach *et al.*, 2009).

We update the epidemiological, genetic and clinical aspects of a large cohort of patients with MNGIE to highlight interesting new observations that refine the approach to diagnosis, follow-up and treatment of the disease. We also report 20 new pathogenetic *TYMP* gene mutations.

Materials and methods

We identified patients who fulfilled MNGIE clinical criteria (severe gastrointestinal dysmotility; cachexia; ptosis, ophthalmoparesis, or both; peripheral neuropathy; and leucoencephalopathy) with thymine phosphorylase activity <10% of the normal control mean. Measurement of thymine phosphorylase activity in the buffy coat, plasma thymidine and deoxyuridine levels and sequencing of the *TYMP* gene were performed using described methods (Nishino *et al.*, 2000; Marti *et al.*, 2004). Three previously reported patients have late-onset MNGIE with the buffy coat thymine phosphorylase activities 10–15% of the normal control mean (Martí *et al.*, 2005). Informed consent for anonymous publication of the patients' clinical features and analyses of blood and urine were obtained from all study participants under a Columbia University Institutional Review Board-approved protocol.

Clinical records and clinical laboratory results including blood lactate, CSF lactate and protein, brain MRI and magnetic resonance spectroscopy scans, electromyography and nerve conduction velocity and muscle biopsy histology were reviewed.

Results

Epidemiology

A cohort of 102 patients (50 females) with an average age of 32.4 years (range 11–59 years) was collected between 1988 and 2011. Of these, 59 were previously reported (Hirano *et al.*, 2004, 2006; Martí *et al.*, 2005; Kintarak *et al.*, 2007; Zimmer *et al.*, 2009).

In terms of geographic origin, Europeans comprised the largest group (53%), followed by Americans (13.7%) and Asians (13.7%). Only 3% of patients were Oceanic. Seventeen patients had mixed or unspecified ethnic backgrounds: eight European-American patients; three African-American patients; three Caucasian patients; one multi-racial patient; one German-Canadian patient; and one French-Canadian patient.

Genetic aspects

We identified *TYMP* mutations in 92 patients: 47/92 (51%) had point mutations (39 homozygotes and eight compound heterozygotes); 13/92 (14.1%) had splice site mutations (12 homozygotes and one compound heterozygote); 6/92 (6.5%) had deletion mutations (five homozygotes and one compound heterozygote); 3/92 (3.3%) had insertion mutations (two homozygotes and one compound heterozygote); and 23/92 (25%) had compound heterozygote mutations. Of these mutations, 20 are novel (Poulton *et al.*, 2009; Table 1). We could not confirm the genetic diagnosis in three affected siblings of known patients, because the siblings died prior to the identification of *TYMP* mutations. In seven patients, DNA samples were inadequate for sequencing.

In comparing the distribution of mutations in different countries and continents (Supplementary Table 1), we observed that three mutations were restricted to single families e.g. c.131G>A in a Spanish family, c.1159G>A in a Dutch family and c.1211insT in an Israeli family, while two mutations were restricted to one continent or country, i.e. c.866A>G was found only in European patients and c.518T>G only in Dominican patients.

Table 1 Novel *TYMP* gene mutations

DNA mutation	Protein/RNA alteration
c.1067T>C	p.Leu356Pro
c.401C>A	p.Ala134Glu
c.112G>T	p.Glu38X
c.893G>A	p.Gly298Asp
c.1360G>C	p.Ala454Pro
c.146T>G	p.Leu49Arg
c.1010_1019del_inAA;	p[Gly337Glu]fs
c.1319inG	p.[Gly440Val]fsX42
c.328C>T	p.Gln110X
c.1160-2A>G;c.1382insC	Exon 9 skipping
c.1160-2A>C;	Exon 9 skipping
c.1159G>A	p.Gly387Ser
c.1160-2G>A	Exon 9 skipping
c.931G>A	p.Gly311Ala
c.931G>T	p.Gly311Cys
c.1311delG	p.[Cys437Trp]fsX45
c.715G>A	p.Ala239Thr
c.623T>G	p.Val208Gly
c.263_264del	p.[Thr88Ile]fsX68
c.1394_1400del	p.[Phe468Pro]fs

Downloaded from http://brain.oxfordjournals.org/ by guest on November 15, 2015

Splice-site mutations were predominantly found in Europeans and present in six Italian patients, three siblings from a Greek family and one mixed European patient. Insertions were found only in Asian patients. No genotype–phenotype correlation was observed.

Clinical aspects

The average age of disease onset is 17.9 years (range 5 months to 35 years) but the majority of patients reported the first symptoms in childhood. Surprisingly, among patients with severe thymine phosphorylase deficiency in the buffy coat (<10% of normal control mean), early onset does not correlate with short life expectancy. In fact, patients with late onset can manifest rapidly progressive disease (Figs 1 and 2). In contrast, three previously diagnosed patients with late-onset and less severe deficiency of thymine phosphorylase in the buffy coat (10–15% of normal control mean) are alive in their sixties (Martí *et al*., 2005).

At least 34/102 (33%) patients had consanguineous parents. Moreover, 52 (51%) patients had siblings or other relatives with the same disease.

Gastrointestinal symptoms have been confirmed as the most frequent first feature of the disease as found in 36/63 (57.1%) patients. These symptoms included: diarrhoea (11/36); abdominal pain (8/36); nausea/vomiting (6/36); abdominal cramps (6/36); weight loss (4/36); borborygmi (3/36); wasting/failure to thrive/thin (2/36); intestinal pseudo-obstruction (2/36); bloating (1/36); and intestinal invagination (1/36). Ocular symptoms preceded gastrointestinal disease in 14/63 (22.2%) patients presenting with: ptosis (9/14); external ophthalmoplegia (3/14); eye wandering (1/14); or loss of vision (1/14).

Although gastrointestinal and ocular symptoms are common in the initial stages of the disease, peripheral neuropathy or hearing loss can be the initial manifestation. In our cohort, 9/63 (14%) patients presented with: peripheral neuropathy manifesting as numbness or foot drop (5/9); limb weakness and paraesthesia (1/9); leg cramps (1/9); tripping (1/9); or hearing loss (1/9).

Other initial symptoms have sporadically been reported in some (6/63, 10%) patients: dry mouth and tinnitus (1/6); tinnitus (2/6); or myopathy (3/6 with exercise intolerance or weakness).

All clinical criteria for MNGIE disease were met during the course of disease:

(i) gastrointestinal symptoms (102/102 patients): thinness (65/102), abdominal pain (46/102), vomiting/nausea (48/102), diarrhoea (47/102), borborygmi (46/102), abdominal cramps (42/102), pseudo-obstruction (32/102), early satiety (25/102), gastroparesis (22/102), dysphagia (21/102), bloating (11/102), distention (10/102), diverticulosis (7/102), aspiration (5/102), constipation (4/102) and malabsorption (3/102);
(ii) ocular symptoms: ptosis (66/69), external ophthalmoplegia (65/69);
(iii) neurological symptoms: peripheral neuropathy (69/71), absent reflexes (53/61), leucoencephalopathy (64/64) and hearing loss (23/59). The white matter lesions appear hyperintense on T_2-weighted or fluid-attenuated inversion recovery images and may initially be patchy, but eventually become diffuse and confluent.

Some clinical features are particularly noteworthy because they require medical care. Severe hypokalaemia recurred in two

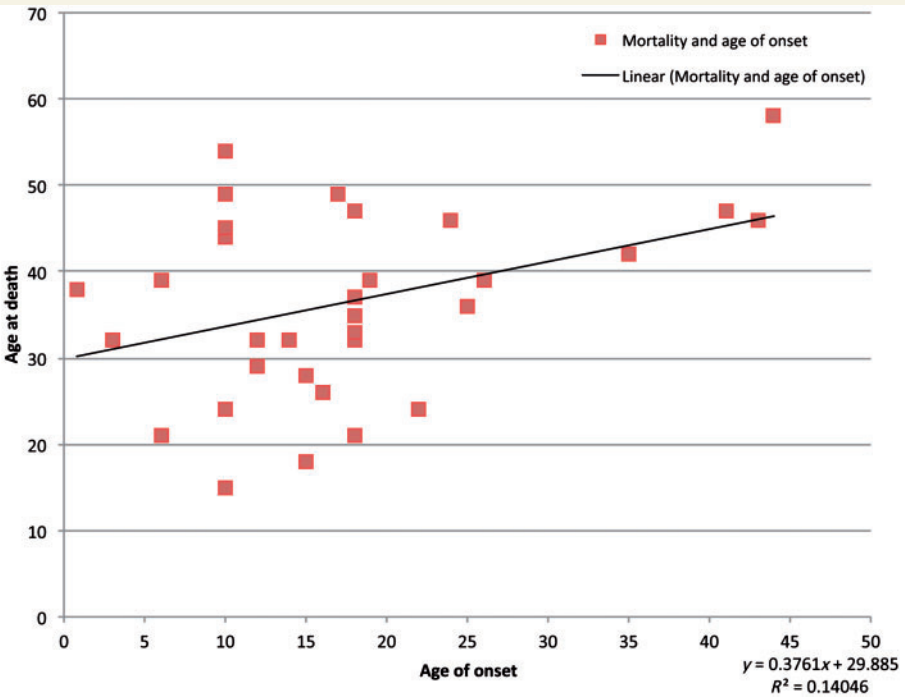

Figure 1 Relationship between age-at-onset and age-at-death.

Downloaded from http://brain.oxfordjournals.org/ by guest on November 15, 2015

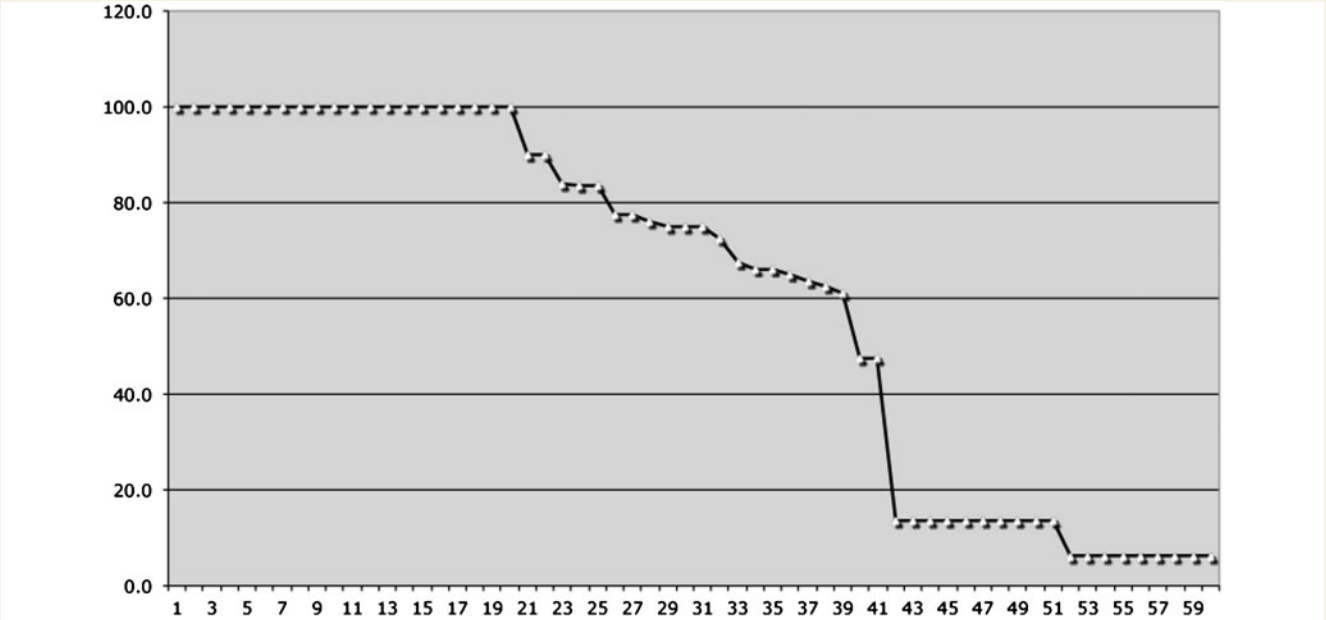

Figure 2 Kaplan–Meier analysis showed the high mortality rate between the ages of 20 and 40 years.

patients causing muscle tetany in one case and cardiac arrhythmia in the other. Infections recurred in seven patients due to rupture of diverticuli (peritonitis, three patients) or aspiration (pneumonia, four patients) and represented the most frequent cause of death. The clinical course was complicated by an endocrine or exocrine pancreatic insufficiency in nine patients: diabetes (four patients); amylase increase (two patients); glucose intolerance (one patient); or exocrine insufficiency (two patients). Severe hyperlipidaemia with marked hypertriglyceridaemia was noted in two patients.

Uncommon clinical features included short stature (five patients) and cardiopathy (three patients with prolonged QT interval, cardiac arrest or supraventricular tachycardia). Malnutrition caused anaemia in four patients and amenorrhea in two patients. Other sporadic findings included: pigmentary retinopathy (three patients); dry mouth/eyes (three patients); psoriasis (one patient); and coarse bronze skin (one patient).

Hepatopathy presented as: fatty liver (five patients); hepatomegaly (two patients); cirrhosis (one patient); and increased transaminases (one patient). Hepatic steatosis and elevated transaminases were observed particularly in association with total parenteral nutrition.

Plasma lactic acidosis (27/40 patients) and high CSF protein (19/21 patients) were frequently observed.

Kaplan–Meier analysis revealed significant mortality between the ages of 20 and 40 years (Fig. 2). The average age of death is 35 years (range 15–54 years) and identified causes included: pneumonia due to aspiration (eight patients); peritonitis due to intestinal rupture (two patients); suicide (two patients); electrolyte imbalance (two patients); sepsis (one patient); malignant melanoma (one patient); cardiac arrhythmia (one patient); metabolic acidosis (one patient); cardiopulmonary arrest (one patient); and oesophageal varicocoele bleeding (one patient).

Central and peripheral nervous system involvement

Our study confirmed that leucoencephalopathy is a main criterion for diagnosis and is asymptomatic in almost 80% of cases. Nevertheless, 20% of patients had manifestations in the CNS, which included: varying degrees of cognitive impairment (seven patients); dementia (two patients); seizures (three patients); or headache (six patients). A small number of patients reported depression (four patients) or anxiety (two patients), but it is unclear whether these psychiatric manifestations are due to CNS involvement or secondary reactions to the disease.

Brain MRI (Supplementary Table 2) typically revealed diffuse leucoencephalopathy involving the cerebral hemispheres, but basal ganglia, cerebellum and brainstem were often affected. Since the MRIs were obtained with varying protocols and were reviewed by multiple neuroradiologists, it is difficult to discern specific patterns of brain involvement.

Prominent demyelinating peripheral neuropathy has been confirmed by electromyography and nerve conduction studies (56 patients): demyelinating neuropathy (24/56, 43%); mixed axonal–demyelinating neuropathy (23/56, 41%); axonal neuropathy (1/56, 2%); and unspecified neuropathy (8/56; 14%). Additional signs of myopathy were noted in 16/56 (29%) patients.

In some patients, neuromuscular impairment was supported by the presence of proximal limb weakness (15 patients), exercise intolerance (nine patients), sensory ataxia (seven patients) and clawed hands (two patients).

Misdiagnoses

Although diagnostic criteria for MNGIE were defined in 1994 (Hirano *et al.*, 1994) and biochemical and molecular genetic

Downloaded from http://brain.oxfordjournals.org/ by guest on November 15, 2015

testing were available in 1999 (Nishino *et al.*, 1999), at least 21/101 (22%) patients had been misdiagnosed as having: psychiatric eating disorders (5/21); peripheral neuropathy: chronic inflammatory demyelinating neuropathy (6/21) or Charcot–Marie–Tooth disease (2/21); gastrointestinal disease: Crohn's disease (3/21), inflammatory bowel disease (2/21), superior mesenteric artery syndrome (2/21), coeliac disease, Whipple disease, bowel obstruction due to short ligament of Treiz and irritable bowel syndrome; and other mitochondrial diseases: autosomal dominant progressive external ophthalmoplegia and Kearns–Sayre syndrome; and Sjögren's syndrome.

Muscle biopsy

Since the introduction of thymine phosphorylase enzyme activity and plasma thymidine and deoxyuridine measurements and *TYMP* gene sequencing to diagnose MNGIE, patients rarely undergo diagnostic muscle biopsies. Muscle biopsies of 40 patients with MNGIE revealed mitochondrial abnormalities in the majority (32/38); however, muscle of six patients did not show ragged-red fibres or cytochrome *c* oxidase-deficient fibres (Supplementary Table 3). Histochemistry revealed cytochrome *c* oxidase-deficient fibres in 25 of 32 patients, while a lower proportion (21/37) showed ragged-red fibres. Defects of mitochondrial respiratory chain enzymes were detected in 9 of 14 patients (deficiency of cytochrome *c* oxidase in four, complexes I and IV in four and complexes I, III and IV in one). Molecular genetic analyses of muscle revealed mitochondrial DNA depletion of all 12 patients tested and multiple deletions of mitochondrial DNA in 13 of 19 patients. Somatic mitochondrial DNA point mutations in muscle were detected in both patients tested. Neurogenic changes evident as variable combinations of group atrophy, fibre type grouping and target/targetoid fibres were found on 23/38 samples analysed.

A possible relationship between tumours and thymine phosphorylase deficiency is suggested by the observation of tumours in 3% of patients: malignant melanoma (one patient); metastatic squamous cell carcinoma (one patient); or benign tumours (one patient). Only 2% of patients had family histories of cancer (lung and prostate cancer).

Discussion

More than three decades after the initial description by Okamura *et al.* (1976), MNGIE is a well-characterized disorder. Clinically, MNGIE is a multisystemic autosomic recessive disorder characterized by: onset typically in the first three decades of life, but as late as the fifth decade; ptosis; progressive external ophthalmoplegia; gastrointestinal dysmotility; cachexia; peripheral neuropathy; and diffuse leucoencephalopathy (Hirano *et al.*, 2004). MNGIE is caused by the *TYMP* gene mutations that cause severe biochemical defects of thymine phosphorylase activity, which, in turn, cause marked increases in thymidine and deoxyuridine nucleoside levels in blood, urine and tissues (Nishino *et al.*, 1999; Spinazzola *et al.*, 2002; Martí *et al.*, 2003; Valentino *et al.*, 2007). The increased nucleosides, in turn, cause mitochondrial DNA instability and respiratory chain dysfunction (Hirano *et al.*, 1994; Nishino *et al.*, 1999; Spinazzola *et al.*, 2002; Martí *et al.*, 2003; Nishigaki *et al.*, 2003, 2004; Pontarin *et al.*, 2006; López *et al.*, 2009).

There have been reports of patients with MNGIE-like clinical manifestations of gastrointestinal dysmotility, progressive external ophthalmoplegia, ptosis, cachexia and peripheral neuropathy due to the mitochondrial myopathy, encephalopathy, lactic acidosis and stroke, m.32443A>G, *POLG* or *RRM2B* mutations; however, all patients had patchy or absent white matter lesions in contrast to the diffuse leucoencephalopathy that is characteristic of MNGIE (van Goethem *et al.*, 2003; Chang *et al.*, 2004; Shaibani *et al.*, 2009).

In the 12 years since our identification of *TYMP* gene mutations in MNGIE (Nishino *et al.*, 1999), we have collected a cohort of 102 patients, showing a high incidence of MNGIE relative to other autosomal recessive mitochondrial disorders. The patient distribution suggests a relatively high prevalence in Europeans. The mutation distribution suggests founder effects for some mutations such as c.866A>G in Europe and c.518T>G in the Dominican Republic; this information can guide genetic screening in each area.

Although there is considerable variation in the age-at-onset and sequence of organ involvement in MNGIE, half of the patients initially reported gastrointestinal symptoms. As previously reported, peripheral neuropathy or extraocular muscle weakness were often the initial manifestations (Nishino *et al.*, 2000; Hirano *et al.*, 2004).

In the early stages of MNGIE, the neuropathy may resemble demyelinating forms of Charcot–Marie–Tooth disease or chronic inflammatory demyelinating polyneuropathy, while the gastrointestinal manifestations may be misdiagnosed as a psychiatric eating disorder, coeliac disease, inflammatory bowel disease, Whipple disease or other gastrointestinal disorder.

Diagnosis of an eating disorder requires an aberrant pattern of eating behaviour and weight regulation as well as disturbances in attitude to weight and perception of body shape, which patients with MNGIE do not manifest (American Psychiatric Association, 2000). When these criteria for eating disorders are absent, we recommend screening thymine phosphorylase activity for MNGIE. In a case of neuropathy or malabsorption syndrome, associated symptoms including ophthalmoparesis and leucoencephalopathy should be indicators for clinicians to screen thymine phosphorylase activity.

Demyelinating neuropathy has been reported in almost all patients of our cohort from electrophysiological studies and supported by nerve biopsy studies. Said *et al.* (2005) reported reductions of nerve fibre density and segmental abnormalities of myelin including demyelination, remyelination and clusters of regenerating fibres and tomacula-like irregularity in nerve biopsies of four patients. Petcharunpaisan and Castillo (2010) postulated that demyelinating neuropathy may contribute to progressive external ophthalmoplegia in MNGIE, based on the observation of post-contrast enhancement of cisternal portions of the oculomotor and trigeminal nerves on T_2-weighted images, in addition to multiple symmetric white matter changes on T_2 fluid-attenuated inversion recovery signals.

Although the leucoencephalopathy in MNGIE had been considered asymptomatic (Nishino *et al.*, 2000), an increasing

Downloaded from http://brain.oxfordjournals.org/ by guest on November 15, 2015

number of patients have been noted to have mild neurological symptoms such as cognitive impairment, dementia, seizure, headache or other psychiatric symptoms. Longitudinal neuropsychological studies should be performed to confirm a decline of cognitive functions during the course of the disease and to characterize the psychiatric disorders.

Absence of correlation between the clinical features and *TYMP* mutation and intra- and inter-familiar phenotype variability suggests a role for unknown nuclear modifier or mitochondrial genes (Nishino *et al.*, 2001). Nuclear gene modifiers have been hypothesized to contribute to the phenotypic expression of homoplasmic mitochondrial mutations causing Leber hereditary optic neuropathy, mitochondrial cardiomyopathy or sensorineural hearing loss (Davidson *et al.*, 2009).

We have noted endocrine and exocrine pancreatic insufficiency not previously reported in patients with MNGIE. Thymine phosphorylase is not expressed in the pancreas; therefore, we suspect that the accumulation of extracellular nucleosides, thymidine and deoxyuridine, exerts toxic effects in this tissue (Yoshimura *et al.*, 1990; Waltenberger *et al.*, 1992; Eccleston *et al.*, 1995; Fox *et al.*, 1995; Matsukawa *et al.*, 1996).

MNGIE can be diagnosed by demonstrating severely reduced thymine phosphorylase activity in the buffy coat, marked elevations of thymidine, deoxyuridine or both in plasma or urine, or by detecting *TYMP* gene mutations (Marti *et al*., 2004; Schüpbach *et al*., 2007). Muscle biopsies typically reveal mitochondrial alterations such as ragged-red fibres, cytochrome *c* oxidase-deficient fibres or decreased activities of mitochondrial respiratory chain enzymes; however, as previously reported (Szigeti *et al*., 2004) and confirmed in our series (Supplementary Table 3), skeletal muscle may not show mitochondrial abnormalities in patients with MNGIE. Thus, absence of mitochondrial pathology in a skeletal muscle biopsy does not exclude the diagnosis of MNGIE.

The reduction of circulating nucleosides, as achieved transiently by haemodialysis and platelet infusion, and long-term by successful allogeneic stem cell transplantation, should be therapeutic in MNGIE (Spinazzola *et al.*, 2002; Hirano *et al.*, 2006; Lara *et al.*, 2006). Preliminary data for enzyme replacement by allogeneic haematopoetic stem cell transplantation showed a biochemical improvement with a rapid restoration of enzyme activity and reduction or disappearance of plasma thymidine and deoxyuridine (Hirano *et al*., 2006; Schüpbach *et al*., 2009; Halter *et al*., 2011). Although follow-up is too short to evaluate clinical benefit, in all nine patients engrafted, 'considerable clinical improvement up to 3.5 years post-transplantation' has been reported (Schüpbach *et al*., 2009; Halter *et al*., 2011). However, most patients are not eligible for allogeneic haematopoetic stem cell transplantation because of their poor medical conditions at the time of diagnosis. Therefore, to maximize the benefits of treatment, diagnosis in children should be achieved to prevent organ damage and to reduce the risk of complications associated with transplantation (Halter *et al*., 2011).

Acknowledgements

We thank all of the clinicians who referred us the patients and samples: Yair Anikster, Richard Bedlack, Adam Bender, Ian Butler, Valerio Carelli, Jose I. Carlo, Carlo Casali, A. Nivelon Chevallier, Anne M. Connally, F. Guillaume Debray, Gulhis Deda, Ganka Douglas, M. Alice Donati, Tuba Eminoglu, Diane M. Escolar, Massimiliano Filostro, Julaine Florence, Josep Gamez, Carla Giordano, Anne Guichon-Mantel, João Guimarães, Angelika Hahn, Cecil D. Hahn, Simon Hammans, Ikuo Hirano, Jutatip Kintarak, Glenn Lopate, Ivan Maillard, Hanna Mandel, Ramon Martí, Hiroshi Mitsumoto, Russell K. Mosewich, Atchayaram Nalini, Ichizo Nishino, Ken Okamura, Ben J. H. M. Poorthuis, Lewis P. Rowland, James A. Russell, Larry M. Salberg, Fernando Scalia, Michael Schüpbach, Carole E. Semrad, Claudia Sobreira, Stephen Sparr, Israel Steiner, Carolyn Sue, Anisa Threlkeld, Haluk Topaloglu, Albert H. van Gennip, Alain Verloes, Jan J. G. M Verschuuren, Laura Vilarinho, Markus Weih, David R. Witt, Massimo Zeviani, Vincent Zimmer and Heinz Zoller.

Funding

This work was funded by National Institutes of Health grant (R01HD056103 to M.H.); Associazione Malattie Metaboliche Congenite ereditarie (AMMeC to C.G.); Marriott Mitochondrial Disorder Clinical Research Fund (MMDCRF). In addition, Dr. Hirano is funded by National Institutes of Health grants (R01HD057543, RC1NS070232 and P01HD032062); Muscular Dystrophy Association.

Supplementary material

Supplementary material is available at *Brain* online.

References

American Psychiatric Association. Diagnostic and statistical manual of mental disorders. Washington, DC: Author 2000.

Chang TM, Chi CS, Tsai CR, Lee HF, Li MC. Paralytic ileus in MELAS with phenotypic features of MNGIE. Pediatr Neurol 2004; 31: 374–7.

Davidson MM, Walker WF, Hernandez-Rosa E, Nesti C. Evidence for nuclear modifier gene in mitochondrial cardiomyopathy. J Mol Cell Cardiol 2009; 46: 936–42.

Eccleston PA, Funa K, Heldin CH. Neurons of the peripheral nervous system express thymidine phosphorylase. Neurosci Lett 1995; 192: 137–41.

Fox SB, Moghaddam A, Westwood M, Turley H, Bicknell R, Gatter KC, et al. Platelet-derived endothelial cell growth factor/thymidine phosphorylase expression in normal tissue: an immunohistochemical study. J Pathol 1995; 176: 183–190.

Halter J, Schüpbach WM, Casali C, Elhasid R, Fay K, Hammans S, et al. Allogeneic hematopoietic SCT as treatment option for patients with mitochondrial neurogastrointestinal encephalomyopathy (MNGIE): a consensus conference proposal for a standardized approach. Bone Marrow Transplant 2011; 46: 330–7.

Hirano M, Marti R, Casali C, Tadesse S, Uldrick T, Fine B, et al. Allogeneic stem cell transplantation corrects biochemical derangements in MNGIE. Neurology 2006; 67: 1458–60.

Hirano M, Nishigaki Y, Martí R. MNGIE: a disease of two genomes. Neurologist 2004; 10: 8–17.

Hirano M, Silvestri G, Blake DM, Lombes A, Minetti C, Bonilla E, et al. Mitochondrial neurogastrointestinal encephalomyopathy (MNGIE): clinical, biochemical, and genetic features of an autosomal recessive mitochondrial disorder. Neurology 1994; 44: 721–7.

Downloaded from http://brain.oxfordjournals.org/ by guest on November 15, 2015

Hirano M, Yebenes J, Jones AC, Nishino I, DiMauro S, Carlo JR, et al. Mitochondrial neurogastrointestinal encephalomyopathy (MNGIE) syndrome maps to chromosome 22q13.32-qter. Am J Hum Genet 1998; 63: 526–33.

Kintarak J, Liewluck T, Sangruchi T, Hirano M, Kulkantrakorn K, Muengtaweepongsa S. A novel ECGF1 mutation in a Thai patient with mitochondrial neurogastrointestinal encephalomyopathy (MNGIE). Clin Neurol Neurosurg 2007; 109: 613–6.

Lara MC, Weiss B, Illa I, Madoz P, Massuet L, Andreu A, et al. Infusion of platelets transiently reduces nucleoside overload in MNGIE. Neurology 2006; 67: 1461–3.

López LC, Akman HO, Garcia-Cazorla A, Dorado B, Marti R, Nishino I, et al. Unbalanced deoxynucleotide pools cause mitochondrial DNA instability in thymidine phosphorylase deficient mice. Hum Mol Genet 2009; 18: 714–22.

Martí R, Nishigaki Y, Hirano M. Elevated plasma deoxyuridine in patients with thymidine phosphorylase deficiency. Biochem Biophys Res Commun 2003; 303: 14–8.

Marti R, Spinazzola A, Tadesse S, Nishino I, Nishigaki Y, Hirano M. Definitive diagnosis of mitochondrial neurogastrointestinal encephalomyopathy by biochemical assays. Clin Chem 2004; 50: 120–4.

Martí R, Verschuuren JJ, Buchman A, Hirano I, Tadesse S, van Kuilenburg AB, et al. Late-onset MNGIE due to partial loss of thymidine phosphorylase activity. Ann Neurol 2005; 58: 649–52.

Matsukawa K, Moriyama A, Kawai Y, Asai K, Kato T. Tissue distribution of human gliostatin/platelet-derived endothelial cell growth factor (PD-ECGF) and its drug-induced expression. Biochim Biophys Acta 1996; 1314: 71–82.

Nishigaki Y, Marti R, Copeland WC, Hirano M. Site-specific somatic mitochondrial DNA point mutations in patients with thymidine phosphorylase deficiency. J Clin Invest 2003; 111: 1913–21.

Nishigaki Y, Martí R, Hirano M. ND5 is a hot-spot for multiple atypical mitochondrial DNA deletions in mitochondrial neurogastrointestinal encephalomyopathy. Hum Mol Genet 2004; 13: 91–101.

Nishino I, Spinazzola A, Hirano M. Thymidine phosphorylase gene mutations in MNGIE, a human mitochondrial disorder. Science 1999; 283: 689–92.

Nishino I, Spinazzola A, Hirano M. MNGIE: from nuclear DNA to mitochondrial DNA. Neuromuscul Disord 2001; 11: 7–10.

Nishino I, Spinazzola A, Papadimitriou A, Hammans S, Steiner I, Hahn CD, et al. MNGIE: an autosomal recessive disorder due to thymidine phosphorylase mutations. Ann Neurol 2000; 47: 792–800.

Okamura K, Santa T, Nagae K, Omae T. Congenital oculoskeletal myopathy with abnormal muscle and liver mitochondria. J Neurol Sci 1976; 27: 79–91.

Papadimitriou A, Comi GP, Hadjigeorgiou GM, Bordoni A, Sciacco M, Napoli L, et al. Partial depletion and multiple deletions of muscle mtDNA in familial MNGIE syndrome. Neurology 1998; 51: 1086–92.

Petcharunpaisan S, Castillo M. Multiple cranial nerve enhancement in mitochondrial neurogastrointestinal encephalomyopathy. J Comput Assist Tomogr 2010; 34: 247–8.

Pontarin G, Ferraro P, Valentino ML, Hirano M, Reichard P, Bianchi V. Mitochondrial DNA depletion and thymidine phosphate pool dynamics in a cellular model of mitochondrial neurogastrointestinal encephalomyopathy (MNGIE). J Biol Chem 2006; 281: 22720–8.

Poulton J, Hirano M, Spinazzola A, Arenas Hernandez M, Jardel C, Lombes A, et al. Collated mutations in mitochondrial DNA (mtDNA) depletion syndrome (excluding the mitochondrial gamma polymerase, POLG1). Biochim Biophys Acta 2009; 1792: 1109–12.

Said G, Lacroix C, Plante-Bordeneuve V, Messing B, Slama A, Crenn P, et al. Clinicopathological aspects of the neuropathy of neurogastrointestinal encephalomyopathy (MNGIE) in four patients including two with a Charcot-Marie-Tooth presentation. J Neurol 2005; 252: 655–62.

Schüpbach WM, Benoist JF, Casali C, Elhasid R, Fay K, Hahn D, et al. Allogeneic hematopoetic stem cell transplantation (HSCT) for mitochondrial neurogastrointestinal encephalomyopathy (MNGIE). Neurology 2009; 73: 332.

Schüpbach WM, Vadday KM, Schaller A, Brekenfeld C, Kappeler L, Benoist JF, et al. Mitochondrial neurogastrointestinal encephalomyopathy in three siblings: clinical, genetic and neuroradiological features. J Neurol 2007; 254: 146–53.

Shaibani A, Shchelochkov OA, Zhang S, Katsonis P, Lichtarge O, Wong LJ, et al. Mitochondrial neurogastrointestinal encephalopathy due to mutations in RRM2B. Arch Neurol 2009; 66: 1028–32.

Spinazzola A, Marti R, Nishino I, Andreu A, Naini A, Tadesse S, et al. Altered thymidine metabolism due to defects of thymidine phosphorylase. J Biol Chem 2002; 277: 4128–33.

Szigeti K, Wong LJ, Perng CL, Saifi GM, Eldin K, Adesina AM, et al. MNGIE with lack of skeletal muscle involvement and a novel TP splice site mutation. J Med Genet 2004; 41: 125–9.

Valentino ML, Marti R, Tadesse S, Lopez LC, Manes JL, Lyzak J, et al. Thymidine and deoxyuridine accumulate in tissues of patients with mitochondrial neurogastrointestinal encephalomyopathy (MNGIE). FEBS Lett 2007; 581: 3410–4.

Van Goethem G, Schwartz M, Lofgren A, Dermaut B, Van Broeckhoven C, Vissing J. Novel POLG mutations in progressive external ophthalmoplegia mimicking mitochondrial neurogastrointestinal encephalomyopathy. Eur J Hum Genet 2003; 11: 547–9.

Waltenberger J, Usuki K, Fellstrom B, Funa K, Heldin CH. Platelet-derived endothelial cell growth factor. Pharmacokinetics, organ distribution and degradation after intravenous administration in rats. FEBS Lett 1992; 313: 129–32.

Yoshimura A, Kuwazuru Y, Furukawa T, Yoshida H, Yamada K, Akiyama S. Purification and tissue distribution of human thymidine phosphorylase; high expression in lymphocytes, reticulocytes and tumors. Biochim Biophys Acta 1990; 1034: 107–13.

Zimmer V, Feiden W, Becker G, Zimmer A, Reith W, Raedle J, et al. Absence of the interstitial cell of Cajal network in mitochondrial neurogastrointestinal encephalomyopathy. Neurogastroenterol Motil 2009; 21: 627–31.

Downloaded from http://brain.oxfordjournals.org/ by guest on November 15, 2015