The New England
Journal of Medicine

©Copyright, 1989, by the Massachusetts Medical Society

Volume 320 MAY 18, 1989 Number 20

MITOCHONDRIAL DNA DELETIONS IN PROGRESSIVE EXTERNAL OPHTHALMOPLEGIA AND KEARNS–SAYRE SYNDROME

CARLOS T. MORAES, M.SC., SALVATORE DIMAURO, M.D., MASSIMO ZEVIANI, M.D., ANNE LOMBES, M.D., SARA SHANSKE, PH.D., ARMAND F. MIRANDA, PH.D., HIROFUMI NAKASE, M.D., EDUARDO BONILLA, M.D., LINEU C. WERNECK, M.D., SERENELLA SERVIDEI, M.D., IKUYA NONAKA, M.D., PH.D., YASUTOSHI KOGA, M.D., PH.D., ALFRED J. SPIRO, M.D., A. KEITH W. BROWNELL, M.D., BENY SCHMIDT, M.D., DONALD L. SCHOTLAND, M.D., MARY ZUPANC, M.D., DARRYL C. DEVIVO, M.D., ERIC A. SCHON, PH.D., AND LEWIS P. ROWLAND, M.D.

Abstract We investigated the correlations of deletions of mitochondrial DNA in skeletal muscle with clinical manifestations of mitochondrial myopathies, a group of disorders defined either by biochemical abnormalities of mitochondria or by morphologic changes causing a ragged red appearance of the muscle fibers histochemically. We performed genomic Southern blot analysis of muscle mitochondrial DNA from 123 patients with different mitochondrial myopathies or encephalomyopathies. Deletions were found in the mitochondrial DNA of 32 patients, all of whom had progressive external ophthalmoplegia. Some patients had only ocular myopathy, whereas others had Kearns–Sayre syndrome, a multisystem disorder characterized by ophthalmoplegia, pigmentary retinopathy, heart block, and cerebellar ataxia.

The deletions ranged in size from 1.3 to 7.6 kilobases and were mapped to different sites in the mitochondrial DNA, but an identical 4.9-kilobase deletion was found in the same location in 11 patients. Biochemical analysis showed decreased activities of NADH dehydrogenase, rotenone-sensitive NADH–cytochrome *c* reductase, succinate–cytochrome *c* reductase, and cytochrome *c* oxidase, four enzymes of the mitochondrial respiratory chain containing subunits encoded by mitochondrial DNA.

We conclude that deletions of muscle mitochondrial DNA are associated with ophthalmoplegia and may result in impaired mitochondrial function. However, the precise relation between clinical and biochemical phenotypes and deletions remains to be defined. (N Engl J Med 1989; 320:1293-9.)

MITOCHONDRIA are unique among intracellular organelles because they contain their own DNA, which can be transcribed and translated to form proteins. Human mitochondrial DNA is a small (16.5-kilobase [kb]), circular, double-stranded molecule that contains 13 structural genes, 22 transfer RNA genes, and 2 genes encoding the 16S and 12S mitochondrial ribosomal RNAs. All 13 peptides encoded by mitochondrial DNA are components of respiratory-chain complexes, including seven subunits of Complex I (NADH–coenzyme Q oxidoreductase), one subunit of Complex III (ubiquinol–cytochrome *c* oxidoreductase), three subunits of Complex IV (cytochrome *c* oxidase), and two subunits of Complex V (ATP synthase). Because all mitochondria are contributed by the ovum during the formation of the zygote, the mitochondrial genome is transmitted by maternal, nonmendelian inheritance. In theory, diseases resulting from mutations of mitochondrial DNA should also be transmitted by maternal inheritance; that is, an affected mother would pass the disease to all her children, but only her daughters would transmit the trait in subsequent generations.[1,2]

Mitochondrial diseases[2] include myopathies and multisystem disorders that are defined either by biochemical abnormalities of the mitochondria or by the presence of "ragged red fibers" in muscle-biopsy specimens stained with modified Gomori's trichrome stain. The abnormal appearance of the biopsy tissue indicates the excessive accumulation of mitochondria. Some mitochondrial myopathies involve extraocular muscles and cause progressive external ophthalmoplegia with or without limb weakness (ocular myopathy).

From the H. Houston Merritt Clinical Research Center for Muscular Dystrophy and Related Diseases, Columbia–Presbyterian Medical Center, New York (C.T.M., S.D., M. Zeviani, A.L., S.S., A.F.M., H.N., E.B., D.C.D., E.A.S., L.P.R.); the Federal University of Paraná, Curitiba, Brazil (L.C.W.); the Catholic University of Rome, Rome (S.S.); the National Center of Neurology and Psychiatry, Tokyo (I.N., Y.K.); the Albert Einstein College of Medicine, Bronx, N.Y. (A.J.S.); the University of Calgary, Alberta, Canada (A.K.W.B.); the Escola Paulista de Medicina, São Paulo (B.S.); the Hospital of the University of Pennsylvania, Philadelphia (D.L.S.); and the University of Wisconsin, Madison (M. Zupanc). Address reprint requests to Dr. DiMauro at 4-420 College of Physicians and Surgeons, Columbia–Presbyterian Medical Center, 630 W. 168th St., New York, NY 10032.

Supported by center grants from the National Institute of Neurological and Communicative Disorders and Stroke (NS-11766), the Muscular Dystrophy Association, and the Aaron Diamond Foundation. Mr. Moraes was supported by a grant from the Brazilian Research Council (CNPq), Dr. Lombes by a fellowship from the Muscular Dystrophy Association, and Dr. Nakase by a fellowship from Mr. and Mrs. Libero Danesi (through the Associazione Italiana per le Ricerche Neurologiche).

The New England Journal of Medicine
Downloaded from nejm.org at UNIVERSITY OF VIRGINIA on October 28, 2013. For personal use only. No other uses without permission.
From the NEJM Archive. Copyright © 2010 Massachusetts Medical Society. All rights reserved.

Multisystem disorders are usually dominated by brain and muscle dysfunction (mitochondrial encephalomyopathies) and may or may not include progressive external ophthalmoplegia. Several syndromes have been identified. Typical Kearns–Sayre syndrome is a sporadic condition that is characterized by an onset before the age of 20, progressive external ophthalmoplegia, pigmentary retinopathy, and one or more of the following: complete heart block, cerebrospinal fluid protein levels above 1 g per liter (100 mg per deciliter), and cerebellar syndrome. Myoclonus epilepsy with ragged red fibers (MERRF) is transmitted by maternal inheritance and is dominated by myoclonus, epilepsy, and ataxia. Mitochondrial encephalomyopathy with lactic acidosis and stroke-like episodes (MELAS) is a disease of childhood that is characterized by intermittent vomiting, proximal limb weakness, and recurrent cerebral insults resembling strokes and causing hemiparesis, hemianopia, or cortical blindness. Leigh syndrome is a childhood encephalopathy characterized clinically by psychomotor regression, brain-stem dysfunction, and optic atrophy. Neuropathological analysis shows focal symmetric spongiform lesions affecting mostly basal ganglia and the brain stem. Ragged red fibers are present in muscle-biopsy specimens from patients with Kearns–Sayre syndrome, MERRF syndrome, and MELAS syndrome, but not from those with Leigh syndrome. Lactic acidosis is present inconsistently in all four syndromes.

Deletions of mitochondrial DNA were reported by Holt et al.[3] in muscle-biopsy specimens from 9 of 25 patients with mitochondrial myopathies. Zeviani et al.[4] subsequently found deletions of mitochondrial DNA in seven patients with Kearns–Sayre syndrome. To define the clinical phenotypes associated with deletions of mitochondrial DNA in muscle, we performed Southern blot analysis of total muscle DNA from 123 patients with different mitochondrial myopathies and encephalomyopathies. We found deletions of mitochondrial DNA in 32 patients, all of whom had progressive external ophthalmoplegia with or without other signs of Kearns–Sayre syndrome.

Methods

Patients

The 123 patients with mitochondrial diseases were divided into four groups (Table 1). Group I consisted of 62 patients, all of whom had progressive external ophthalmoplegia, including the 7 patients with Kearns–Sayre syndrome described in an earlier report.[4] Of these patients, 14 had typical Kearns–Sayre syndrome, as defined by the presence of the invariable triad of an onset before the age of 20, progressive external ophthalmoplegia, and pigmentary retinopathy, as well as at least one of the following: complete heart block, cerebrospinal fluid protein levels above 1 g per liter (100 mg per deciliter), and cerebellar syndrome. All 14 of the patients with typical Kearns–Sayre syndrome had one or more of the common manifestations — short stature, hearing loss, mental retardation or dementia, and endocrinopathy (diabetes, delayed puberty, and amenorrhea). Four patients had probable Kearns–Sayre syndrome. Two (26 and 44 years old, respectively) had the invariable triad of symptoms but lacked the additional required feature. Symptoms had begun in the third patient at the age of 24. The fourth patient, a 27-year-old man, had the invariable triad of symptoms, but the cerebrospinal fluid protein level was only 0.65 g per liter (65 mg per deciliter), and neither heart block nor ataxia was present.

Table 1. Characteristics of Patients with Mitochondrial Diseases.*

Patients	No. of Patients	Sex	Ragged Red Fibers	mtDNA Deletions
		M/F	*no. of patients*	
Group 1: PEO				
Typical Kearns–Sayre syndrome	14	7/7	14	11
Probable Kearns–Sayre syndrome	4	2/2	4	4
Ocular myopathy	44	21/23	36	17
Group 2: defined mitochondrial encephalomyopathies				
MERRF syndrome	2	2/0	2	0
MELAS syndrome	13	8/5	13	0
Leigh syndrome	9	5/4	0	0
Group 3: undefined mitochondrial encephalomyopathies				
Congenital lactic acidosis	6	2/4	0	0
Other	8	5/3	4	0
Group 4: mitochondrial myopathies				
Luft's disease	1	0/1	1	0
Fatal infantile COX deficiency	2	2/0	2	0
Benign infantile COX deficiency	4	2/2	4	0
ATPase deficiency	1	0/1	1	0
Other	15	6/9	15	0

*mtDNA denotes mitochondrial DNA, PEO progressive external ophthalmoplegia, and COX cytochrome *c* oxidase.

All other patients in Group 1 had ocular myopathy that was often accompanied by proximal limb weakness. Ocular symptoms included ptosis and ophthalmoplegia in most patients; five had only ptosis. All but eight patients had ragged red fibers in the muscle-biopsy specimens. Two patients also had severe dysphagia and evidence of autosomal dominant inheritance that were compatible with the presence of oculopharyngeal muscular dystrophy.[5] None of the patients with ocular myopathy had evidence of multisystemic disorder — i.e., pigmentary retinopathy, heart block or congestive heart failure, mental retardation or dementia, ataxia, epilepsy, myoclonus, short stature, hearing loss, or endocrinopathy.

Group 2 included 24 patients with clinically defined mitochondrial encephalomyopathies. The two patients with MERRF syndrome had myoclonus, ataxia, epilepsy, ragged red fibers, and evidence of maternal transmission; both had cytochrome *c* oxidase deficiency. All but 1 of the 13 patients with MELAS syndrome were children. All 13 had intermittent vomiting, proximal limb weakness, stroke-like episodes, lactic acidosis, and ragged red fibers, and 7 had a deficiency of Complex I in muscle mitochondria.[6] Of the nine patients with Leigh syndrome, eight were children and one was a symptomatic 26-year-old woman whose sister had had the typical neuropathologic features of Leigh syndrome at autopsy. All patients with Leigh syndrome had psychomotor regression, brain-stem signs, and lactic acidosis. None had ragged red fibers. All but one had cytochrome *c* oxidase deficiency in muscle.

Group 3 was a heterogeneous group of 14 patients with mitochondrial encephalomyopathies that were clinically distinct from MERRF syndrome, MELAS syndrome, or Leigh syndrome. They had symptoms of brain and muscle disease, with lactic acidosis, ragged red fibers in the muscle-biopsy specimen, or both (Table 1). Six patients had congenital lactic acidosis. The other eight patients were children or adults with limb weakness and cerebral symptoms in patterns that did not conform to any of the encephalomyopathic syndromes described earlier.

Group 4 was composed of 23 patients with mitochondrial myopathies that were characterized by limb weakness and ragged red fibers but not progressive external ophthalmoplegia. Diagnoses based on biochemical analyses included nonthyroidal hypermetabolism with loose coupling of oxidation and phosphorylation (Luft's disease; 1 patient),[7] fatal infantile deficiency of cytochrome *c* oxidase (2), benign infantile myopathy due to a reversible deficiency of

The New England Journal of Medicine
Downloaded from nejm.org at UNIVERSITY OF VIRGINIA on October 28, 2013. For personal use only. No other uses without permission.
From the NEJM Archive. Copyright © 2010 Massachusetts Medical Society. All rights reserved.

cytochrome *c* oxidase (4), and a mitochondrial deficiency of ATPase (1)[8]; 15 patients had biochemically undefined myopathies.

A control group of 15 subjects was also included. Four of the controls were considered to be free of muscle abnormalities on the basis of muscle biopsies. Eleven of the controls had nonmitochondrial neuromuscular diseases: 2 had myophosphorylase deficiency, 1 had phosphofructokinase deficiency, 1 had acid maltase deficiency, 1 had a biochemically undefined glycogenosis, 2 had recurrent myoglobinuria of unknown cause, 1 had unexplained cramps, 1 had polymyositis, 1 had dermatomyositis, and 1 had Rett syndrome.

We also studied muscle-biopsy specimens from the asymptomatic mothers of three patients with Kearns–Sayre syndrome. Specimens from all three women were morphologically normal.

Preparation of DNA and Biochemical Analysis

Total DNA was isolated from 10 to 150 mg of frozen muscle obtained by biopsy. The method of Davis et al.[9] was scaled down 20-fold to accommodate the small samples we used. Two steps were modified as follows: the incubation with sodium dodecyl sulfate–proteinase K was performed for two hours at 50°C, and the DNA was precipitated with isopropanol, spooled, and then washed in 70 percent ethanol. We routinely recovered about 1 to 2 μg of total DNA per milligram of muscle. The same method was used to prepare DNA from tissues other than muscle.

The mitochondrial enzyme activities were analyzed as described elsewhere.[10]

Preparation of Mitochondrial DNA Probes

Mitochondria were isolated from normal frozen human liver,[11] and the mitochondrial DNA was then isolated by the method of Palva and Palva.[12] For the probes, 25 ng of mitochondrial DNA was linearized with *Pvu*II and then labeled in the presence of $\alpha[^{32}P]$deoxycytidine triphosphate with use of the random-primer method.[13]

Southern Blot Analysis

Five micrograms of total DNA was digested with a restriction enzyme, subjected to electrophoresis on a 0.8 percent agarose gel, transferred to nitrocellulose filters (Schleicher and Schuell), and hybridized as described elsewhere.[14] To ensure that the hybridization of sequences present in the nuclear genome[15] would not interfere with the Southern blot analysis of authentic mitochondrial DNA, the exposure times of autoradiograms were kept short, because only high copy-number sequences (i.e., mitochondrial DNA) are seen after brief exposures. The proportion of mitochondrial DNA that had deletions was estimated densitometrically.[4]

Localization of the Deletions in Mitochondrial DNA

To identify the site of the deletion, the DNA was digested with a battery of restriction enzymes: *Eco*RI, *Hind*III, *Pst*I, *Xba*I, and in some patients, *Kpn*I and *Stu*I. The mapping procedure has been described elsewhere.[4]

Materials

Restriction enzymes were obtained from Boehringer Mannheim and New England Biolabs; the Klenow fragment of *Escherichia coli* polymerase I from New England Biolabs; RNase A and hybridization chemicals from Sigma; and $\alpha[^{32}P]$deoxycytidine triphosphate (800 Ci per millimole) from New England Nuclear.

Results

We performed genomic Southern blot analysis of total muscle DNA isolated from 123 patients with mitochondrial myopathies or encephalomyopathies and from 15 controls; the entire mitochondrial DNA was used as the hybridization probe. With use of the restriction enzyme *Pvu*II, which makes only one cut in the mitochondrial DNA (and therefore produces a single 16.5-kb linear molecule in normal mitochondrial DNA), the hybridization analysis of mitochondrial DNA from 32 patients showed a pattern consistent with the presence of two populations of DNA, one corresponding to full-length molecules of mitochondrial DNA and the other, which migrated more rapidly in the electrophoretic gel, corresponding to a smaller mitochondrial DNA (Fig. 1).

All patients with deletions in their mitochondrial DNA had progressive external ophthalmoplegia and ragged red fibers (Tables 1 and 2). No deletions were found in patients who did not have progressive external ophthalmoplegia but who did have mitochondrial encephalomyopathies or mitochondrial myopathies (Table 1).

Of the 32 patients in Group 1 who had progressive external ophthalmoplegia and deletions of mitochondrial DNA, 11 had typical Kearns–Sayre syndrome, 4 had probable Kearns–Sayre syndrome (as defined in Methods), and 17 had ocular myopathy (progressive external ophthalmoplegia, with or without proximal limb weakness). The remaining 30 patients in Group 1 had no detectable deletions of mitochondrial DNA; 3 had typical Kearns–Sayre syndrome, and 27 had

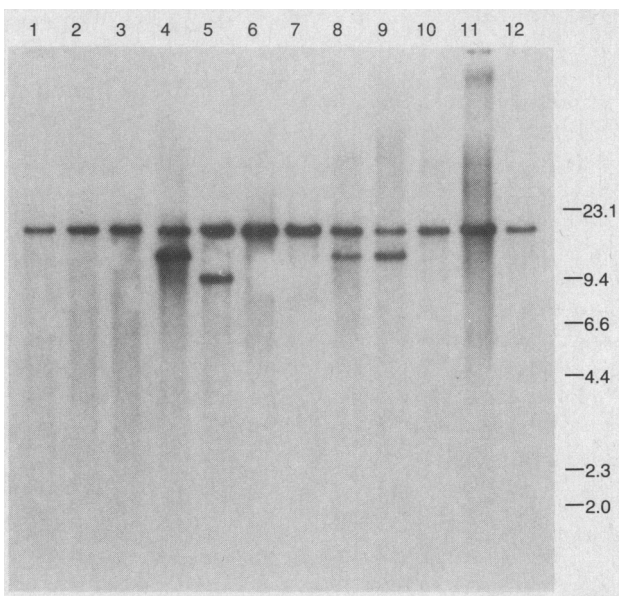

Figure 1. Autoradiogram of a Genomic Southern Blot Hybridization of Muscle Mitochondrial DNA from Selected Patients with Mitochondrial Myopathies or Encephalomyopathies and from Normal Controls.

Five micrograms of total DNA was digested with *Pvu*II, subjected to electrophoresis on a 0.8 percent agarose gel, transferred to nitrocellulose, and probed with labeled mitochondrial DNA[4]: MERRF syndrome in lane 1, MELAS syndrome in lane 2, Leigh syndrome in lane 3, ocular myopathies in lanes 4 and 6 through 9, Kearns–Sayre syndrome in lane 5, benign infantile myopathy with cytochrome *c* oxidase deficiency in lane 10, Luft's disease in lane 11, and normal control in lane 12. Marker sizes (lambda digested with *Hind*III) are shown at left, in kilobases.

The New England Journal of Medicine
Downloaded from nejm.org at UNIVERSITY OF VIRGINIA on October 28, 2013. For personal use only. No other uses without permission.
From the NEJM Archive. Copyright © 2010 Massachusetts Medical Society. All rights reserved.

ocular myopathy (Table 2). No mitochondrial DNA deletions were found in the muscle-biopsy specimens from the mothers of three patients with Kearns–Sayre syndrome, although all three of the patients had such deletions.

In comparing the clinical features of patients with progressive external ophthalmoplegia who had mitochondrial DNA deletions with those who did not have such deletions, we found that the patients with deletions represented isolated cases, whereas approximately half the patients without deletions had other affected relatives (Table 2). Also, ragged red fibers were present in the biopsy specimens of all patients with mitochondrial DNA deletions but were absent in six patients without such deletions. The size of the deletions ranged from 1.3 to 7.6 kb. To map the site of the deletions, we performed Southern blot analysis with other enzymes whose restriction sites on the mitochondrial DNA were known.[16] Of the 29 patients so studied, the deletion mapped to the same region of mitochondrial DNA in 11, in whom a 4.9-kb fragment was found to be deleted (2 with typical Kearns–Sayre syndrome, 1 with probable Kearns–Sayre syndrome, and 8 with ocular myopathy). Among these 11 patients were 2 in whom the deletion had initially been thought to be 4.5 kb,[4] but in whom the size of the deletion was later reassessed more accurately. Apparently identical deletions were also seen in each of two pairs of patients (7.5- and 7.6-kb deletions; in each pair, one patient had typical Kearns–Sayre syndrome and the other had ocular myopathy) (Fig. 2). Within the level of resolution of our analysis, the location of the deletions differed in each of the other 14 patients (Fig. 2).

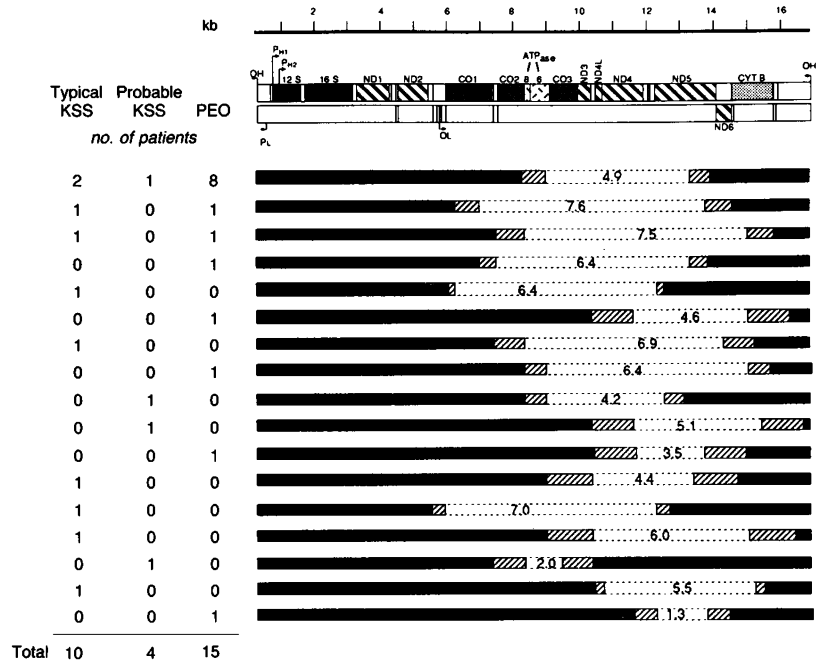

Figure 2. Localization of Mitochondrial DNA Deletions.

The maps at the top represent the heavy (upper map) and light (lower map) strands of linearized mitochondrial DNA,[16] showing the genes for the subunits of NADH–coenzyme Q oxidoreductase (ND1 through ND6), cytochrome *c* oxidase (CO1 through CO3), cytochrome *b* (CYT B), and ATP synthase (ATPase 8 and 6) and for the 12S and 16S ribosomal RNAs. The transfer RNAs are denoted by small open boxes. The origins of heavy-strand (OH) and light-strand (OL) replication and the promoters for the initiation of heavy-strand (P_{H1} and P_{H2}) and light-strand (P_L) transcription are indicated by arrows. Muscle mitochondrial DNAs from 29 patients, mapped as described elsewhere,[4] are represented by the bars. Intact regions are shown as solid areas. Deleted fragments are shown as open (dotted) areas; the numbers within these areas indicate the size of the deletion in kilobases. The areas of uncertainty[4] are indicated by the hatched regions. The table at left shows the distribution of deletions among clinical phenotypes. KSS denotes Kearns–Sayre syndrome, and PEO progressive external ophthalmoplegia.

The relative number of normal and affected mitochondrial genomes in each muscle-biopsy specimen was estimated by densitometry of the hybridizing fragments (Fig. 3). The relative proportion of affected genomes varied widely among patients, ranging from 27 to 85 percent. A similar degree of variability was observed within the clinical subgroups (Fig. 3) — typical Kearns–Sayre syndrome, probable Kearns–Sayre syndrome, and ocular myopathy — and among the 11 patients in whom a 4.9-kb fragment had been deleted (range of affected genomes, 41 to 80 percent). There was no significant difference in the proportion of affected genomes between the 11 patients with typical Kearns–Sayre syndrome and the 17 patients with ocular myopathy.

We also studied tissues other than muscle in some patients with deletions of mitochondrial DNA in muscle. Deletions were seen in leukocytes and plate-

Table 2. Characteristics of Patients with Progressive External Ophthalmoplegia with or without Deletions of Muscle Mitochondrial DNA .*

Patients	No. of Patients	Sex	Family History	Ragged Red Fibers
		M/F	*no. of patients*	
With mtDNA deletions				
Typical Kearns–Sayre syndrome	11	5/6	0	11
Probable Kearns–Sayre syndrome	4	2/2	0	4
Ocular myopathy	17	6/11	0	17
Without mtDNA deletions				
Typical Kearns–Sayre syndrome	3	2/1	0	3
Ocular myopathy	27	15/12	13	18†

*mtDNA denotes mitochondrial DNA.

†This information was available for only 24 patients.

The New England Journal of Medicine
Downloaded from nejm.org at UNIVERSITY OF VIRGINIA on October 28, 2013. For personal use only. No other uses without permission.
From the NEJM Archive. Copyright © 2010 Massachusetts Medical Society. All rights reserved.

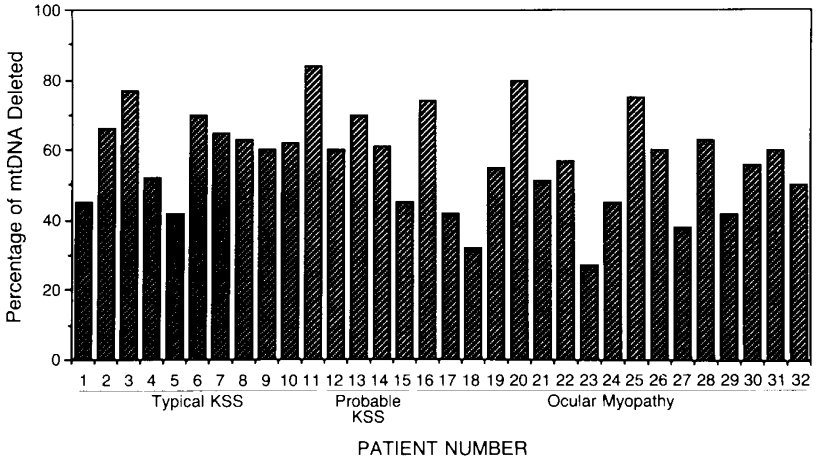

Figure 3. Relative Proportion of Mitochondrial DNA (mtDNA) with Deletions in Muscle-Biopsy Specimens from Patients with Typical or Probable Kearns–Sayre Syndrome (KSS) or with Ocular Myopathy.

Each bar represents the hybridization signal of the deleted mitochondrial DNA as a percentage of the total mitochondrial DNA signal.

lets from one patient with Kearns–Sayre syndrome, as well as in cultured fibroblasts from this patient and from two others with the disease (Fig. 4A). Although the deletions in the fibroblasts and blood cells were the same size and in the same location as those seen in the muscle of these patients, the percentage of deleted mitochondrial DNA was much lower in these cells (Fig. 4A). However, there were no detectable mitochondrial DNA deletions in fibroblasts from one patient with pure ocular myopathy and deletions in muscle mitochondrial DNA. In addition, brain, liver, and muscle specimens obtained two hours post mortem from a patient with Kearns–Sayre syndrome showed identical deletions (Fig. 4B), but barring sampling errors, the percentage of affected mitochondrial genomes was 72 percent in brain and 55 percent in liver, as compared with 85 percent in muscle.

Biochemical analysis of mitochondrial enzymes in muscle extracts from 22 patients with deletions of mitochondrial DNA and 20 without such deletions showed widely scattered values. Although there was extensive overlap between the two groups, the mean activities of four enzymes of the respiratory chain — cytochrome *c* oxidase, succinate–cytochrome *c* reductase, rotenone-sensitive NADH–cytochrome *c* reductase, and NADH dehydrogenase — were significantly lower in the patients with mitochondrial DNA deletions than in those without such deletions (Table 3). The activities of succinate dehydrogenase and citrate synthase were not different in the two groups.

Discussion

Clinical Phenotype

We found deletions of mitochondrial DNA in muscle specimens from 32 of 123 patients with mitochondrial myopathies or encephalomyopathies. All patients with mitochondrial DNA deletions had progressive external ophthalmoplegia and ragged red fibers. Of these, 15 had typical or probable Kearns–Sayre syndrome, and 17 had progressive external ophthalmoplegia with or without limb weakness (ocular myopathy). These results are similar to those of Holt et al.,[17] who found mitochondrial DNA deletions in 16 of 44 patients with mitochondrial myopathies, all of whom had progressive external ophthalmoplegia. Four of their 16 patients with deletions in mitochondrial DNA had Kearns–Sayre syndrome, and 1 more such patient has been described by Lestienne and Ponsot.[18]

The association of progressive external ophthalmoplegia and deletions of mitochondrial DNA appears to be specific because we found no such deletions in patients who did not have progressive external ophthalmoplegia but who did have mitochondrial myopathies or encephalomyopathies, including Leigh

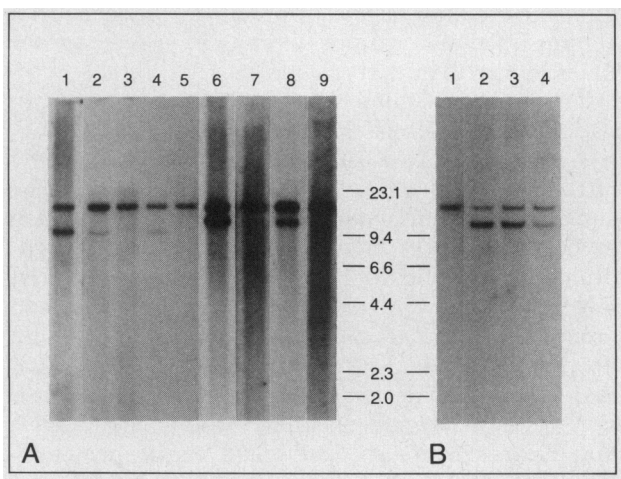

Figure 4. Deletions of Mitochondrial DNA in Muscle and Other Tissues from Patients with Typical Kearns–Sayre Syndrome.

Southern blotting was performed as described in Figure 1. In Panel A, lanes 1 and 2 show muscle and leukocyte mitochondrial DNA, respectively, from Patient 8 (patient's number corresponds to that shown in Figure 3); lane 3, mitochondrial DNA from control leukocytes; lane 4, platelet mitochondrial DNA from Patient 8; lane 5, mitochondrial DNA from control platelets; lanes 6 and 7, muscle and fibroblast mitochondrial DNA, respectively, from Patient 9; and lanes 8 and 9, muscle and fibroblast mitochondrial DNA, respectively, from Patient 29. In Panel B, lane 1 shows mitochondrial DNA from control muscle; and lanes 2, 3, and 4, muscle, brain, and liver mitochondrial DNA, respectively, from Patient 11. Marker sizes (lambda digested with *Hind*III) are shown in kilobases. Lanes 7 and 9 were deliberately overexposed to be sure of the absence of mitochondrial DNAs with deletions. If mitochondrial DNAs were present in lane 9, we estimated that they represented less than 2 percent of the total DNA.

The New England Journal of Medicine
Downloaded from nejm.org at UNIVERSITY OF VIRGINIA on October 28, 2013. For personal use only. No other uses without permission.
From the NEJM Archive. Copyright © 2010 Massachusetts Medical Society. All rights reserved.

Table 3. Activities of Mitochondrial Enzymes in Muscle Extracts.*

Enzyme	Patients with PEO		Controls (N = 29)
	mtDNA deletions (N = 22)	no mtDNA deletions (N = 20)	
	micromoles of substrate used/minute/gram of tissue		
Cytochrome *c* oxidase	1.15±0.89†	2.19±1.26	2.48±0.58
Succinate–cytochrome *c* reductase	0.61±0.17‡	1.06±0.84	0.97±0.48
Rotenone-sensitive NADH–cytochrome *c* reductase	1.21±0.47§	2.19±1.79	2.06±1.14
NADH dehydrogenase	22.36±8.08¶	31.88±13.17	44.51±31.47
Succinate dehydrogenase	1.72±0.74	2.09±1.08	2.12±0.69
Citrate synthase	12.26±3.76	15.16±7.37	20.05±9.02

*Plus–minus values are means ±SD. The values were compared with use of a two-tailed Student's t-test. PEO denotes progressive external ophthalmoplegia.

†P<0.001 for the comparison with values for patients without mitochondrial DNA deletions.

‡P<0.05 for the comparison with values for patients without mitochondrial DNA deletions.

§P<0.02 for the comparison with values for patients without mitochondrial DNA deletions.

¶P<0.01 for the comparison with values for patients without mitochondrial DNA deletions.

syndrome, MELAS syndrome, and MERRF syndrome (a maternally inherited condition). It is not known why ophthalmoplegia is the invariable manifestation of mitochondrial DNA deletions, but this association may be related to the high mitochondrial content of normal human extraocular muscles. Morphometric studies have shown that the mitochondrial volume fraction of extraocular muscles is three to four times higher than that of limb muscles.[19]

The finding of mitochondrial DNA deletions in 20 patients with Kearns–Sayre syndrome (15 in this series, 4 in the study of Holt et al.,[17] and 1 in the study of Lestienne and Ponsot[18]) but not in patients with the clinically different syndromes of MERRF, MELAS, or Leigh reinforces the view that Kearns–Sayre syndrome is a specific disorder. However, mitochondrial DNA deletions were also found in patients who had progressive external ophthalmoplegia and ragged red fibers but not brain or cardiac disorders, suggesting that Kearns–Sayre syndrome may be the full expression of a pleiotropic disorder. Additional evidence that Kearns–Sayre syndrome and ocular myopathy may be different clinical forms of a pleiotropic disorder comes from the observation that patients with apparently identical deletions had different clinical phenotypes.

All 32 patients with mitochondrial DNA deletions, including the 15 with Kearns–Sayre syndrome, were the only members of their family who were affected. The consistently sporadic occurrence of Kearns–Sayre syndrome has raised the question of whether this syndrome is inherited or acquired.[4] The deletions suggest that both Kearns–Sayre syndrome and some forms of ocular myopathy with ragged red fibers are genetic disorders. The deletions could arise from either of two mechanisms: the inheritance of a preexisting deletion in the mother, or the spontaneous mutation of mitochondrial DNA in the oocyte or in the zygote. Evidence against the first possibility, and in support of the second, is the absence of affected mothers or siblings and the absence of detectable mitochondrial DNA deletions in muscle-biopsy specimens from the mothers of three patients with Kearns–Sayre syndrome and deletions of mitochondrial DNA.

Except for a family history of the disease and the presence of ragged red fibers, there were no clinical differences between patients with ocular myopathy who had mitochondrial DNA deletions and those who did not have such deletions. None of the patients with deletions of mitochondrial DNA had a family history of the disease, whereas half the patients without deletions had such a history (including two with autosomal dominant oculopharyngeal muscular dystrophy), and ragged red fibers were invariably present in patients with deletions but were absent in some patients without deletions.

Deletions

All the mitochondrial DNA deletions were large enough to be easily differentiated from control mitochondrial DNA on agarose gels, and they ranged in size from 1.3 to 7.6 kb. The percentage of affected mitochondrial genomes in muscle ranged from 27 to 85 percent. Phenotypic expression of a mitochondrial disease may require a minimal threshold number of mutated mitochondrial DNAs.[1] Thus far, 18 percent is the lowest proportion of affected mitochondrial DNA reported in muscle of patients with mitochondrial disease.[17]

Although the site and size of the deletion differed among patients, there were some common features. All affected genomes preserved the promoters of the transcription of heavy and light strands, the 12S and 16S ribosomal RNA genes, and the origin of heavy-strand replication (Fig. 2).

The affected mitochondrial DNAs must be competent for replication to account for the high proportion of genomes with deletions. Also, the affected mitochondrial DNAs may be transcriptionally active, but they may lack some indispensable transfer RNAs; translation would not be possible in any mitochondrion that contained only mitochondrial DNAs with deletions. However, translation could take place in mitochondria that contained both normal and mutant genomes, because that would provide the opportunity for intraorganelle complementation. Normal mitochondria in differentiated tissues contain 2 to 10 mitochondrial DNA genomes,[20] and complementation has been documented in cultured cells.[1]

Eleven of the deletions were identical in size — 4.9 kb — and occurred in the same region, suggesting that there are "hot spots" in the mitochondrial genome that are especially prone to deletion. Direct DNA sequencing of the affected genomes may clarify this issue.

The New England Journal of Medicine
Downloaded from nejm.org at UNIVERSITY OF VIRGINIA on October 28, 2013. For personal use only. No other uses without permission.
From the NEJM Archive. Copyright © 2010 Massachusetts Medical Society. All rights reserved.

The multisystem nature of Kearns–Sayre syndrome suggests that deletions of mitochondrial DNA may not be confined to skeletal muscle but may affect other tissues. In fact, we found deletions of mitochondrial DNA in blood cells from one patient with Kearns–Sayre syndrome, in cultured fibroblasts from three patients, and in brain and liver from a fourth patient. The percentage of affected mitochondrial genomes differed in different tissues from the same patient. This kind of variation could explain the selective organ involvement in Kearns–Sayre syndrome. However, this hypothesis implies that different tissues may have different thresholds for phenotypic expression.

In contrast, the phenotypic expression of mitochondrial DNA deletions as pure ocular myopathy could be due to "mitotic segregation" in the oocyte or in the zygote, resulting in the uneven distribution of affected mitochondrial genomes in different tissues.[1] If so, only skeletal muscle would have a proportion of affected mitochondrial DNAs above the threshold necessary to produce symptoms.

Holt et al.[3] found no deletions in mitochondrial DNA from leukocytes of patients with deletions in muscle mitochondrial DNA. They attributed this pattern to the frequent cell division of leukocyte precursors, allowing selection against the survival of cells with deletions in mitochondrial DNAs. However, we found deletions in leukocyte mitochondrial DNA from one patient with Kearns–Sayre syndrome. This deletion was of the same size and in the same location as the muscle deletion, but the percentage of deleted mitochondrial DNA was much lower in the leukocytes. Thus, the selection process was incomplete.

Pathogenesis and Biochemistry

The activity of four of the six mitochondrial enzymes we studied in muscle was significantly lower in patients with deletions of mitochondrial DNA as a group than in patients with progressive external ophthalmoplegia and no deletions of mitochondrial DNA. All four of the affected enzymes are part of respiratory-chain complexes: rotenone-sensitive NADH–cytochrome *c* reductase (Complexes I and III), succinate–cytochrome *c* reductase (Complexes II and III), NADH dehydrogenase (Complex I), and cytochrome *c* oxidase (Complex IV). Also, all four affected enzymes contain one or more subunits encoded by mitochondrial DNA, whereas the two enzymes that were apparently unaffected — succinate dehydrogenase and citrate synthase — are not encoded by mitochondrial DNA.

Because these four enzymes were affected regardless of the site of the deletion or whether the clinical syndrome was restricted to progressive external ophthalmoplegia or extended to Kearns–Sayre syndrome, the entire mitochondrial genome may function as a single genetic unit rather than as a series of genes encoding individual enzymes. The transcription of mitochondrial DNA is polycistronic[21]; that is, all the genes encoded on the heavy and light strands are transcribed as two large RNAs that are later cleaved into the individual transfer RNAs and messenger RNAs. A deletion anywhere in the genome could affect transcription and translation, even of genes not directly encompassed by the deletion. However, some patients with deletions of mitochondrial DNA had normal mitochondrial-enzyme activities. Perhaps the precise location of a particular deletion, the segregation of affected and normal mitochondrial genomes among mitochondria, or both affect the level of enzyme activity.

We are indebted to Dr. C.P. Lee (Wayne State University, Detroit) for providing postmortem tissues from a patient with Kearns–Sayre syndrome, to Dr. Terry D. Heiman-Patterson (Hahnemann University, Philadelphia) for her collaboration, and to Ms. Shirley Susarchick for assistance in the preparation of the manuscript.

References

1. Wallace DC. Maternal genes: mitochondrial diseases. Birth Defects 1987; 23:137-90.
2. Zeviani M, Bonilla E, DeVivo DC, DiMauro S. Mitochondrial diseases. Neurol Clin 1989; 7:123-56.
3. Holt IJ, Harding AE, Morgan-Hughes JA. Deletions of muscle mitochondrial DNA in patients with mitochondrial myopathies. Nature 1988; 331:717-9.
4. Zeviani M, Moraes CT, DiMauro S, et al. Deletions of mitochondrial DNA in Kearns-Sayre syndrome. Neurology 1988; 38:1339-46.
5. Tome FMS, Fardeau M. Ocular myopathies. In: Engel AG, Banker BQ, eds. Myology: basic and clinical. Vol. 2. New York: McGraw-Hill, 1986: 1327-47.
6. Koga Y, Nonaka I, Kobayashi M, Tojyo M, Nihei K. Findings in muscle in complex I (NADH coenzyme Q reductase) deficiency. Ann Neurol 1988; 24:749-56.
7. DiMauro S, Bonilla E, Lee CP, et al. Luft's disease: further biochemical and ultrastructural studies of skeletal muscle in the second case. J Neurol Sci 1976; 27:217-32.
8. Schotland DL, DiMauro S, Bonilla E, Scarpa A, Lee CP. Neuromuscular disorder associated with a defect in mitochondrial energy supply. Arch Neurol 1976; 33:475-9.
9. Davis LG, Dibner MD, Battey JF, eds. Basic methods in molecular biology. New York: Elsevier, 1986:47-50.
10. DiMauro S, Servidei S, Zeviani M, et al. Cytochrome c oxidase deficiency in Leigh syndrome. Ann Neurol 1987; 22:498-506.
11. Bookelman H, Trijbels JM, Sengers RC, Janssen AJ. Measurement of cytochromes in human skeletal muscle mitochondria, isolated from fresh and frozen stored muscle specimens. Biochem Med 1978; 19:366-73.
12. Palva TK, Palva ET. Rapid isolation of animal mitochondrial DNA by alkaline extraction. FEBS Lett 1985; 192:267-70.
13. Feinberg AP, Vogelstein B. A technique for radiolabeling DNA restriction endonuclease fragments to high specific activity. Anal Biochem 1983; 132:6-13.
14. Zeviani M, Nakagawa M, Herbert J, et al. Isolation of a cDNA clone encoding subunit IV of human cytochrome c oxidase. Gene 1987; 55:205-17.
15. Kristensen T, Prydz H. The presence of intact mitochondrial DNA in HeLa cell nuclei. Nucleic Acids Res 1986; 14:2597-609.
16. Anderson S, Bankier AT, Barrell BG, et al. Sequence and organization of the human mitochondrial genome. Nature 1981; 290:457-65.
17. Holt IJ, Cooper JM, Morgan-Hughes JA, Harding AE. Deletions of muscle mitochondrial DNA. Lancet 1988; 1:1462.
18. Lestienne P, Ponsot G. Kearns-Sayre syndrome with muscle mitochondrial DNA deletion. Lancet 1988; 1:885.
19. Carry MR, Ringel SP, Starcevich JM. Mitochondrial morphometrics of histochemically identified human extraocular muscle fibers. Anat Rec 1986; 214:8-16.
20. Bogenhagen D, Clayton DA. The number of mitochondrial deoxyribonucleic acid genomes in mouse L and human HeLa cells: quantitative isolation of mitochondrial deoxyribonucleic acid. J Biol Chem 1974; 249:7991-5.
21. Clayton DA. Transcription of the mammalian mitochondrial genome. Annu Rev Biochem 1984; 53:573-94.

The New England Journal of Medicine
Downloaded from nejm.org at UNIVERSITY OF VIRGINIA on October 28, 2013. For personal use only. No other uses without permission.
From the NEJM Archive. Copyright © 2010 Massachusetts Medical Society. All rights reserved.