J Neurol (2012) 259:862–868
DOI 10.1007/s00415-011-6268-6

ORIGINAL COMMUNICATION

Mitochondrial neurogastrointestinal encephalomyopathy (MNGIE)-like phenotype: an expanded clinical spectrum of *POLG1* mutations

Sha Tang · Elliot L. Dimberg · Margherita Milone · Lee-Jun C. Wong

Received: 26 August 2011 / Revised: 23 September 2011 / Accepted: 26 September 2011 / Published online: 13 October 2011
© Springer-Verlag 2011

Abstract The aim of the study was to determine the prevalence of MNGIE-like phenotype in patients with recessive *POLG1* mutations. Mutations in the *POLG1* gene, which encodes for the catalytic subunit of the mitochondrial DNA polymerase gamma essential for mitochondrial DNA replication, cause a wide spectrum of mitochondrial disorders. Common phenotypes associated with *POLG1* mutations include Alpers syndrome, ataxia-neuropathy syndrome, and progressive external ophthalmoplegia (PEO). Mitochondrial neurogastrointestinal encephalomyopathy (MNGIE) is an autosomal recessive disorder characterized by severe gastrointestinal dysmotility, cachexia, PEO and/or ptosis, peripheral neuropathy, and leukoencephalopathy. MNGIE is caused by *TYMP* mutations. Rare cases of MNGIE-like phenotype have been linked to *RRM2B* mutations. Recently, *POLG1* mutations were identified in a family with clinical features of MNGIE but no leukoencephalopathy. The coding regions and exon–intron boundaries of *POLG1* were sequence analyzed in patients suspected of *POLG1* related disorders. Clinical features of 92 unrelated patients with two pathogenic *POLG1* alleles were carefully reviewed. Three patients, accounting for 3.3% of all patients with two pathogenic *POLG1* mutations, were found to have clinical features consistent with MNGIE but no leukoencephalopathy. Patient 1 carries p.W748S and p.R953C; patient 2 is homozygous for p.W748S, and patient 3 is homozygous for p.A467T. In addition, patient 2 has a similarly affected sibling with the same *POLG1* genotype. *POLG1* mutations may cause MNGIE-like syndrome, but the lack of leukoencephalopathy and the normal plasma thymidine favor *POLG1* mutations as responsible molecular defect.

Keywords *POLG1* · MNGIE · Mitochondrial DNA · Pseudo-obstruction · Leukoencephalopathy

S. Tang and E. L. Dimberg contributed equally to the work.

S. Tang · L.-J. C. Wong
Department of Molecular and Human Genetics,
Baylor College of Medicine, Houston, TX, USA

S. Tang · L.-J. C. Wong
Medical Genetics Laboratories,
Baylor College of Medicine, Houston, TX, USA

E. L. Dimberg
Department of Neurology, Mayo Clinic,
Jacksonville, FL, USA

M. Milone (✉)
Department of Neurology, Mayo Clinic,
Rochester, MN 55905, USA
e-mail: Milone.Margherita@mayo.edu

Introduction

POLG1 encodes the catalytic subunit of mitochondrial DNA (mtDNA) polymerase γ, the sole polymerase for mtDNA replication and repair. Mutations in *POLG1* can cause mtDNA depletion and/or multiple deletions and have emerged as one of the most common causes of autosomally inherited mitochondrial disorders. *POLG1*-related disorders are associated with a broad spectrum of clinical phenotypes involving multiple organs in both children and adults, with either autosomal recessive or autosomal dominant inheritance. Common clinical phenotypes of *POLG1* mutations include Alpers syndrome, progressive external ophthalmoplegia (PEO) with or without limb myopathy, ataxia-neuropathy, and epilepsy.

Mitochondrial neurogastrointestinal encephalomyopathy (MNGIE) is a progressive disorder characterized by

severe gastrointestinal (GI) dysmotility, intestinal pseudo-obstruction, cachexia or thin body habitus, PEO, peripheral neuropathy, leukoencephalopathy and lactic acidosis. The onset of MNGIE is usually between the first and fifth decades of life and, in about 60% of patients, symptoms start before the age of 20 years [1]. MNGIE is caused by mutations in the thymidine phosphorylase gene (*TYMP*) resulting in thymidine phosphorylase deficiency and elevated plasma thymidine levels [2]. Therefore, if MNGIE is considered, plasma levels of thymidine and deoxyuridine should be measured. Patients with clinical phenotype indistinguishable from MNGIE, but not linked to *TYMP* mutations, have been reported. MNGIE-like clinical phenotype has been occasionally linked to mutations in the ribonucleoside-diphosphate reductase subunit M2 B gene (*RRM2B*) [3]. This specific patient had patchy leukoencephalopathy by brain MRI, but also bilateral basal ganglia signal abnormality, versus the commonly observed diffuse leukoencephalopathy in MNGIE due to *TYMP* mutations. In addition, two autosomal recessive *POLG1* mutations, p.N846S and [p.P587L; p.T251I], have been reported in a family with clinical features of MNGIE [4]. The two patients in this family had onset of the gastrointestinal symptoms, including pseudo-obstruction, at the age of 15 years; they also had PEO, ataxia, muscle weakness, and cachexia [4]. The muscle specimen from these patients showed decreased enzymatic activities of respiratory chain complexes I and IV, and mtDNA depletion and multiple deletions [4]. Brain MRI of these two patients was normal. In particular, there was no leukoencephalopathy which is a finding otherwise characteristic of the classical MNGIE [4]. This report suggested that *POLG1* mutations can clinically mimic MNGIE.

To determine the prevalence of MNGIE-like clinical phenotype in patients with two pathogenic *POLG1* mutations, we reviewed the clinical phenotypes of 92 patients with two *POLG1* mutant alleles [5]. Three patients (3.3%) were found to have MNGIE-like syndrome. Their clinical, molecular, and mtDNA integrity findings are reported heres.

Materials and methods

Patients, *POLG1* sequencing, and review of clinical phenotype

The clinical features of 92 patients harboring two recessive pathogenic mutations were analyzed [5]. Specimen collection and molecular analysis of *POLG1* have been described [5, 6].

TYMP sequencing analysis

Sequence-specific primers with M13 tags were used to amplify the nine coding exons and the immediate flanking intron regions of *TYMP*. PCR products were purified on ExcelaPure 96-well UF PCR purification plates (Edge BioSystems, Gaithersburg, MD). Sequencing reactions were performed using the BigDye Terminator Cycle Sequencing kit (version 3.1) and analyzed on an ABI3730XL automated DNA sequencer with Sequencing Analysis Software v5.1.1 (Applied Biosystems, Foster City, CA, USA). DNA sequences were analyzed using Mutation Surveyor version 3.24 (SoftGenetics, PA, USA) and the GenBank ID NM_001953.3 was used as *TYMP* reference sequence.

Mitochondrial DNA deletion analysis

The MitoMet oligonucleotide comparative genomic hybridization (CGH) array was employed to investigate if there were large intragenic deletions in the *POLG1* locus and deletions in the mtDNA in the blood specimen of patients 2 and 3 [7, 8]. For patient 1, Southern blot hybridization analysis was used to detect mtDNA deletions in the muscle specimen [9]. In addition, PCR-based method was used to check for multiple mtDNA deletions that were not readily detectable by aCGH or Southern analysis [10].

Mitochondrial DNA copy number analysis

Mitochondrial DNA content in muscle or blood samples for the three patients was analyzed by real-time quantitative PCR and normalized to tissue and age matched controls [11, 12].

Results

Out of the 92 patients with two *POLG1* pathogenic alleles, three (3.3%) had clinical features consistent with MNGIE. The molecular findings of the three patients are summarized in Table 1.

Clinical reports

Patient 1

Patient 1 was a 50-year-old man who presented with problems with attention, language, and memory of unknown duration; exercise intolerance since his late 20s; and progressive ptosis over 5 years. He described arm and leg weakness and reduced sensation in his feet progressing

Table 1 Patients with two *POLG1* mutations and MNGIE-like phenotype

Patient	Age (years)	Gender	Allele 1	Allele 2	Domain	TYMP mutation	mtDNA content	mtDNA deletions
1	50	M	p.W748S	p.R953C	S/P	Negative	61% in blood 61% in muscle	Not detected in blood and muscle
2[a]	25	F	p.W748S	p.W748S	S/S	ND	83% in blood	Not detected in blood
3	46	M	p.A467T	p.A467T	P/P	Negative	75% in blood	Not detected in blood
Previously reported patient[a] [4]	15	F	p.T251I-p.P587L	p.N846S	E-S/P	Negative	Depletion in muscle	Multiple deletions in muscle

E Exonuclease domain, *S* Spacer domain, *P* Polymerase domain, *ND* not determined

[a] The proband had a sibling with the same *POLG1* genotype and similar clinical phenotype

to the mid shin over 5 years. He had persistent diarrhea and intermittent vomiting which had lead to a 50 kg weight loss over 3 years. Very limited family history was available; the mother and some siblings were described as having possible "droopy eyes", but they were not available for a neurological examination. His neurological examination revealed cognitive impairment with poor recall and expressive language difficulty. There was moderate ophthalmoparesis in all ranges of gaze, bilateral ptosis, and mild to moderate facial and proximal limb muscle weakness. He also had moderate distal panmodality sensory loss in a length-dependent manner with reduced muscle stretch reflexes at the knees and absent at the ankles. He had a cachectic appearance with diffuse muscle atrophy, including temporal muscle atrophy.

Neuropsychological testing showed mild to moderate cognitive impairment characterized by slow processing speed, executive dysfunction, slowed word retrieval, and memory deficits, including inefficient registration and retrieval, suggesting frontal subcortical dysfunction. Nerve conduction studies revealed low amplitude motor responses and mildly slow conduction velocities in the lower extremities; sensory responses had reduced amplitude in the upper extremities and were unobtainable in the lower extremities. Concentric needle electromyography demonstrated mildly short duration, low amplitude motor unit potentials in proximal and facial muscles, and mildly long duration potentials in distal leg muscles. There was no abnormal spontaneous activity. The electrophysiological findings were compatible with a mild proximal myopathy and a moderate length-dependent predominantly axonal sensorimotor peripheral neuropathy. Biceps brachii muscle biopsy showed very rare ragged-red fibers, few ragged-blue fibers and numerous cytochrome c oxidase negative fibers. Brain MRI demonstrated global cerebral atrophy but no leukoencephalopathy (Fig. 1). EEG showed 7–8 Hz posteriorly dominant rhythm which was at times more diffuse with minimal response to eye opening and alerting maneuvers. Audiogram showed right-sided low frequency sensorineural hearing loss. Resting lactate was 2.7 mmol/L (normal 0.9–1.7 nmol/L). Abdominal and pelvic CT scan demonstrated gas-distended distal small bowel; esophagogastroduodenoscopy, colonoscopy and intestinal biopsies were normal. CK values, electrocardiogram and transthoracic echocardiogram were normal. With the clinical suspicion of MNGIE, biochemical assay of plasma thymidine was performed and was normal (<300 nmol/L), suggesting normal TYMP activity. At the molecular level, no deleterious mutations were identified in *TYMP*. Sequence analysis of *POLG1* detected compound heterozygosity of two known *POLG1* mutations, c.2243G>C (p.W748S) and c.2857C>T (p.R953C). Mitochondrial DNA copy number analysis indicated moderate mtDNA depletion in both the muscle and blood specimen (61% compared to age-matched control mean in both). Southern blot analysis and PCR-based method did not find evidences for mtDNA large deletions in the muscle specimen.

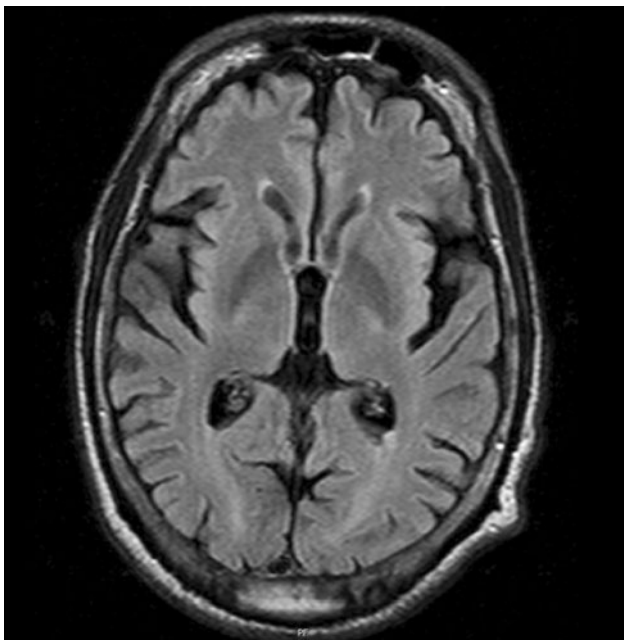

Fig. 1 Brain MRI for Patient 1. Flair imaging demonstrated global atrophy but no leukoencephalopathy

Patient 2

Patient 2 was a 25-year-old woman with migraine, ptosis, PEO, exercise intolerance, sensorimotor peripheral neuropathy, ataxia, pseudoobstruction, constipation, and sensorineural hearing loss. Brain MRI revealed increased T2 signal in the basal ganglia; brainstem auditory evoked potentials were abnormal. This patient had an apparently homozygous c.2243G>C (p.W748S) mutation and a heterozygous unclassified variant c.82A>T (p.S28C) in the *POLG1* gene. MitoMet aCGH analysis did not detect any copy number change in the *POLG1* locus. Major mtDNA deletions were not detected in the blood of this patient by both aCGH and PCR. Quantitative real-time PCR showed that this patient had normal mtDNA content (83% in blood compared to age-matched control mean). The patient's affected younger sibling had the same *POLG1* genotype.

Patient 3

Patient 3 was a 46-year-old man with ptosis, PEO, muscle weakness, fatigability, peripheral neuropathy, ataxia, lactic acidosis and diarrhea alternating with constipation. Motility study showed delayed gastric emptying. Muscle biopsy revealed scattered ragged-red fibers. Sequencing analysis of the *TYMP* gene did not reveal any deleterious mutations while a homozygous c.1399G>A (p.A467T) mutation was detected in the patient's *POLG1*. No large intragenic deletion in *POLG1* was detected by aCGH. This patient also had normal mtDNA copy number (75% compared to age-matched control mean) and no large mtDNA deletions in the blood.

Discussion

Molecular defects of *POLG1* causing MNGIE-like symptoms

Among 92 patients carrying two pathogenic *POLG1* mutations, we found three patients with a MNGIE-like phenotype. A total of five different *POLG1* mutations (Fig. 2) have been identified in four unrelated patients with MNGIE-like syndrome (Table 1): one p. A467T homozygous, one p.W748S homozygous, and two compound heterozygotes (p.W748S with p.R953C, and p.N846S with [p.T251I; p.P587L]) [4]. These mutations are located in the exonuclease domain, the spacer region, or the polymerase domain. The p.A467T, p.W748S, and (p.T251I; p.P587L) are the first, third, and fourth most frequent *POLG1* mutations, respectively [5]. Among our five patients with homozygous p.A467T mutation [5], only one patient (patient 3) manifested gastrointestinal dysfunction. Thus, there is no clear genotype-phenotype correlation. Patient 1 carries two known pathogenic mutations, one of which p.R953C has been reported as being dominant [13]. Because no DNA from family members was available, we are unable to confirm if the two mutations occur in trans in patient 1. Therefore, one cannot establish if the patient's phenotype is determined by p.R953C or by the combined effect of the two detected mutations. The limited family history does not help in confirming the dominant effect p.R953C, although the reported ptosis in some family members and the previously reported lack of clinical manifestations in p.W748S heterozygotes would favor a dominant inheritance of p.R953C.

Clinical spectrum of *POLG1* mutations

Clinical features of *POLG1* mutations are extremely heterogeneous with variable degree of severity and age of onset [5, 14, 15]. *POLG1*-related disorders may be autosomal recessive or autosomal dominant. The recessive *POLG1* diseases are more common than the dominant disorders, which include PEO. Alpers syndrome is the most common recessive *POLG1* disease, followed by sensory ataxia-neuropathy syndrome with or without epilepsy, and PEO with or without myopathy [15]. The latter two may occur during the second decade of life or late adulthood. Less frequent phenotypes include Leigh disease [16], MELAS-like phenotype [17], optic atrophy [18], parkinsonism [13], premature ovarian failure [13], demyelinating peripheral neuropathy [19], psychiatric illness, and diabetes [14]. A single family with MNGIE-like phenotype has been reported in association with *POLG1* mutations [4]. In our large cohort of patients with recessive *POLG1*-related

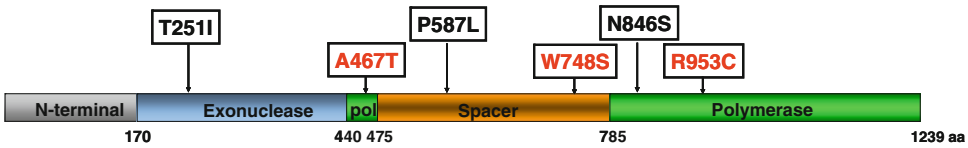

Fig. 2 *POLG1* mutations identified in patients with MNGIE-like symptoms. *Black* ones are the mutations identified in the published case. The *red* ones are from this study. The mature POLG1 protein can be divided into four functional domains: (1) the N-terminal domain (26–170), (2) the exonuclease domain (171–440), (3) the spacer region (476–785), and (4) the polymerase domain (441–475 and 786–1239)

disorders MNGIE-like features occurred in 3.3% of patients.

mtDNA instability and MNGIE

Point mutations and deletions in mtDNA may be secondary due to primary defects in the nuclear genes, which include genes involved in the replication of mtDNA (e.g., *POLG* and DNA helicase, *TWINKLE*), the balance of deoxynucleotide pools (*TP*, *DGUOK*, *TK2*, *RRM2B*), and the modulators of mitochondrial dynamics (*OPA1*). Deficiencies in these enzymes generally cause failure in the maintenance of mtDNA integrity and consequently lead to point mutations, deletions, and depletion. MNGIE is caused by defects in TYMP that result in increased levels of plasma thymidine and deoxyuridine. The imbalance of mitochondrial deoxynucleotide pools cause next-nucleotide effects leading to site-specific somatic mtDNA point mutations involving primarily T to C transitions preceded by 5′-AA sequences [20]. In addition to mtDNA point mutations, the nucleotide pool imbalance also causes mtDNA instability resulting in mtDNA multiple deletions and mtDNA depletion [21–23]. Previous reports showed that in skeletal muscle samples, multiple mtDNA deletions were detected in nine out of 20 patients and mtDNA depletion was observed in 65% of the MNGIE patients [23]. Recently, a patient with mutations in the *RRM2B* gene has been reported to manifest as MNGIE-like disorder [3]. The *RRM2B* gene encodes the p53-inducible subunit p53R2, essential for the biogenesis of deoxyribonucleotides [24]. Mutations in *RRM2B* have also been associated with mtDNA abnormalities, including mtDNA multiple deletions and depletion [25, 26]. Likewise, POLG1 dysfunction can cause accumulation of mtDNA mutations as well, although the mechanisms may be different [27]. *POLG1* encodes the catalytic subunit of the holoenzyme required for mtDNA replication and repair. Therefore, mutations in the catalytic or the exonuclease domain of POLG1 may result in mtDNA depletion, multiple deletions, and point mutations [5, 27, 28], suggesting that mtDNA defects play an important role in the etiology of disease.

However, mtDNA depletion or multiple deletions are not necessarily observed in patients with *POLG1* mutations [5]. Because of random hit of nucleotide mis-incorporation and repair efficiency, somatic mtDNA mutations may be at too low levels of heteroplasmy to be detected by current sequencing techniques, while mtDNA multiple deletions and depletion may be tissue specific and age dependent [5, 28, 29]. Although mtDNA depletion and multiple deletions in the muscle specimen of the MNGIE patients with *POLG1* mutations were described in the previous report, there were no experimental results to support the observation [4]. We did not observe significant mtDNA depletion or multiple deletion in the blood or muscle samples of all three patients in our study (61, 75, 83%, respectively in blood, and 61% in the muscle of patient 1), although blood mtDNA content is not informative for mtDNA depletion or multiple deletion analysis [11]. The mtDNA content of 61% in muscle in pateint 1 is not within the range observed in patients with definitive mtDNA depletion (6–50%) syndrome [11]. Whether or not accumulation of low levels of somatic mtDNA point mutations is present in these patients requires further investigation.

Lack of leukoencephalopathy in MNGIE-like phenotypes due to *POLG1* mutations

Leukoencephalopathy is one of the cardinal features of classical MNGIE caused by *TYMP* mutations [30]. In the MNGIE-like patient with *RRM2B* mutations, symmetric, hyper-intense, and nonenhancing lesions were identified in the basal ganglia and patchy signals were observed throughout the white matter, different from the confluent white matter abnormalities seen in classical MNGIE [3]. In contrast, our patient 1 presented with all symptoms characteristic of MNGIE but had no evidence for leukoencephalopathy. The only anatomical correlate to his cognitive deficit was the generalized cerebral atrophy. The two previously reported siblings with *POLG1* mutations and MNGIE-like phenotype also had no leukoencephalopathy by brain MRI [4]. These observations suggest that the presence or absence of leukoencephalopathy plays a critical role in distinguishing clinically MNGIE patients with *TYMP* mutations from MNGIE-like patients carrying *POLG1* mutations. However, patients with *POLG1* mutations and patients with other mitochondrial disorders may have abnormal brain MR findings, although the abnormalities were not as severe as those seen in MNGIE [31]. Gastrointestinal symptoms, including pseudo-obstruction, are common manifestations (~15%) in patients with mitochondrial disorders [32]. In a retrospective study for 80 patients with chronic intestinal pseudo-obstruction (CIPO), mitochondrial defects were identified in 15 patients, representing 19% of the study cohort [31]. Among these 15 subjects, five had mutations in the *TYMP* gene, five had mutations in the *POLG1* gene, and two had mtDNA tRNA gene mutations. It was proposed that visceral mitochondrial myopathy resulting from mtDNA depletion secondary to TYMP deficiency may be the cause of gastrointestinal dysmotility in MNGIE patients [21]. A similar mechanism can be hypothesized for patients with similar symptoms and *POLG1* mutations. Recently pathological specimens in four patients with Alpers syndrome and intestinal dysmotility showed eosinophilic cytoplasmic granules corresponding to abnormal mitochondria in

enteric and submucosal ganglion cells [33]. Smooth muscle atrophy and fibrosis signifying visceral myopathy were less common, limited to the muscularis externa, variable in severity, and not present in one of the four patients. Three of the four patients had confirmed *POLG1* mutations. Conversely, the leukoencephalopathy observed only in TYMP deficiency could be independent from mtDNA instability, and it could be related to the role of TYMP in glial cell proliferation or cortical neuron trophism [2, 4].

Conclusions

POLG1 mutations are associated with a broad spectrum of disorders and can result in severe gastrointestinal dysfunction due to smooth muscle myopathy and autonomic neuropathy. In our study, about 3.3% of all patients with two pathogenic *POLG1* mutations were found to have symptoms and signs of significant gastrointestinal dysmotility. These features can mimic some of the clinical features of MNGIE which is caused by mutations in *TYMP*. However, the lack of leukoencephalopathy, which is usually apparent and diffuse at the time of the clinical presentation in MNGIE, favors a POLG-related disorder over the true MNGIE due to *TYMP* mutations. The later onset of the symptoms would also favor a POLG-related disorder, as most MNGIE patients manifest before the age of 20 years and die before the age of 40 years [30]. Exceptions to the rule occur. True MNGIE can manifest late in life [2, 34] and can result in "patchy leukoencephalopathy" [34] and POLG-related disorders can be associated with patchy leukoencephalopathy [35], as proof of the phenotypic overlap among mitochondrial disorders caused by different molecular defects.

Acknowledgments We thank Drs. Laurence Walsh and Fernando Kok for referring patients 2 and 3 for the study.

Conflict of Interest None.

References

1. Nishino I, Spinazzola A, Papadimitriou A et al (2000) Mitochondrial neurogastrointestinal encephalomyopathy: an autosomal recessive disorder due to thymidine phosphorylase mutations. Ann Neurol 47(6):792–800
2. Nishino I, Spinazzola A, Hirano M (1999) Thymidine phosphorylase gene mutations in MNGIE, a human mitochondrial disorder. Science 283(5402):689–692
3. Shaibani A, Shchelochkov OA, Zhang S et al (2009) Mitochondrial neurogastrointestinal encephalopathy due to mutations in RRM2B. Arch Neurol 66(8):1028–1032
4. Van Goethem G, Schwartz M, Lofgren A et al (2003) Novel POLG mutations in progressive external ophthalmoplegia mimicking mitochondrial neurogastrointestinal encephalomyopathy. Eur J Hum Genet 11(7):547–549
5. Tang S, Wang J, Lee N, Milone M, Halberg MC, Schmitt ES, Craigen WJ, Zhang W, Wong LC (2011) Mitochondrial DNA polymerase γ mutations: an ever expanding molecular and clinical spectrum. J Med Genet 48(10):669–681
6. Wong LJ, Naviaux RK, Brunetti-Pierri N et al (2008) Molecular and clinical genetics of mitochondrial diseases due to POLG mutations. Hum Mutat 29(9):E150–E172
7. Chinault AC, Shaw CA, Brundage EK et al (2009) Application of dual-genome oligonucleotide array-based comparative genomic hybridization to the molecular diagnosis of mitochondrial DNA deletion and depletion syndromes. Genet Med 11(7):518–526
8. Wong LJ, Dimmock D, Geraghty MT et al (2008) Utility of oligonucleotide array-based comparative genomic hybridization for detection of target gene deletions. Clin Chem 54(7):1141–1148
9. Shanske S, Wong LJ (2004) Molecular analysis for mitochondrial DNA disorders. Mitochondrion 4(5–6):403–415
10. Bai RK, Wong LJ (2005) Simultaneous detection and quantification of mitochondrial DNA deletion(s), depletion, and over-replication in patients with mitochondrial disease. J Mol Diagn 7(5):613–622
11. Dimmock D, Tang LY, Schmitt ES et al (2010) Quantitative evaluation of the mitochondrial DNA depletion syndrome. Clin Chem 56(7):1119–1127
12. Venegas V, Wang J, Dimmock D, et al. (2011) Real-time quantitative PCR analysis of mitochondrial DNA content. Curr Protoc Hum Genet Chapter 19:Unit 19.7
13. Luoma P, Melberg A, Rinne JO et al (2004) Parkinsonism, premature menopause, and mitochondrial DNA polymerase gamma mutations: clinical and molecular genetic study. Lancet 364(9437):875–882
14. Milone M, Massie R (2010) Polymerase gamma 1 mutations: clinical correlations. Neurologist 16(2):84–91
15. Cohen BH, Naviaux RK (2010) The clinical diagnosis of POLG disease and other mitochondrial DNA depletion disorders. Methods 51(4):364–373
16. Taanman JW, Rahman S, Pagnamenta AT et al (2009) Analysis of mutant DNA polymerase gamma in patients with mitochondrial DNA depletion. Hum Mutat 30(2):248–254
17. Deschauer M, Tennant S, Rokicka A et al (2007) MELAS associated with mutations in the POLG1 gene. Neurology 68(20):1741–1742
18. Milone M, Wang J, Liewluck T et al (2011) Novel POLG splice site mutation and optic atrophy. Arch Neurol 68(6):806–811
19. Santoro L, Manganelli F, Lanzillo R et al (2006) A new POLG1 mutation with peo and severe axonal and demyelinating sensory-motor neuropathy. J Neurol 253(7):869–874
20. Nishigaki Y, Marti R, Copeland WC et al (2003) Site-specific somatic mitochondrial DNA point mutations in patients with thymidine phosphorylase deficiency. J Clin Invest 111(12):1913–1921
21. Giordano C, Sebastiani M, De Giorgio R et al (2008) Gastrointestinal dysmotility in mitochondrial neurogastrointestinal encephalomyopathy is caused by mitochondrial DNA depletion. Am J Pathol 173(4):1120–1128
22. Vissing J, Ravn K, Danielsen ER et al (2002) Multiple mtDNA deletions with features of MNGIE. Neurology 59(6):926–929
23. Hirano M, Lagier-Tourenne C, Valentino ML et al (2005) Thymidine phosphorylase mutations cause instability of mitochondrial DNA. Gene 354:152–156
24. Pontarin G, Fijolek A, Pizzo P et al (2008) Ribonucleotide reduction is a cytosolic process in mammalian cells independently of DNA damage. Proc Natl Acad Sci USA 105(46):17801–17806

25. Bourdon A, Minai L, Serre V et al (2007) Mutation of RRM2B, encoding p53-controlled ribonucleotide reductase (p53R2), causes severe mitochondrial DNA depletion. Nat Genet 39(6):776–780
26. Tyynismaa H, Ylikallio E, Patel M et al (2009) A heterozygous truncating mutation in RRM2B causes autosomal-dominant progressive external ophthalmoplegia with multiple mtDNA deletions. Am J Hum Genet 85(2):290–295
27. Spelbrink JN, Toivonen JM, Hakkaart GA et al (2000) In vivo functional analysis of the human mitochondrial DNA polymerase POLG expressed in cultured human cells. J Biol Chem 275(32): 24818–24828
28. Milone M, Brunetti-Pierri N, Tang LY et al (2008) Sensory ataxic neuropathy with ophthalmoparesis caused by POLG mutations. Neuromuscul Disord 18(8):626–632
29. Szigeti K, Sule N, Adesina AM et al (2004) Increased blood-brain barrier permeability with thymidine phosphorylase deficiency. Ann Neurol 56(6):881–886
30. Hirano M, Silvestri G, Blake DM et al (1994) Mitochondrial neurogastrointestinal encephalomyopathy (MNGIE): clinical, biochemical, and genetic features of an autosomal recessive mitochondrial disorder. Neurology 44(4):721–727
31. Amiot A, Tchikviladze M, Joly F et al (2009) Frequency of mitochondrial defects in patients with chronic intestinal pseudo-obstruction. Gastroenterology 137(1):101–109
32. Chinnery PF, Turnbull DM (1997) Clinical features, investigation, and management of patients with defects of mitochondrial DNA. J Neurol Neurosurg Psychiatry 63(5):559–563
33. Kapur RP, Fligner C, Maghsoodi B et al (2011) Gastrointestinal neuromuscular pathology in alpers disease. Am J Surg Pathol 35(5):714–722
34. Marti' R, Verschuuren JJGM, Buchman A et al (2005) Late-oset MNGIE due to partial loss of thymidine phosphorylase activity. Ann Neurol 58(4):649–652
35. Echaniz-Laguna A, Chassagne M, de Sèze J et al (2010) POLG1 variations presenting as multiple sclerosis. Arch Neurol 67(9): 1140–1143