Genetics in Medicine | BRIEF REPORTS

©American College of Medical Genetics and Genomics

# Congenital short bowel syndrome as the presenting symptom in male patients with *FLNA* mutations

Christine S. van der Werf, MD[1], Yunia Sribudiani, PhD[1,2], Joke B.G.M. Verheij, MD[1], Matthew Carroll, MD[3], Edward O'Loughlin, MD[3], Chien-Huan Chen, MD[4], Alice S. Brooks, MD, PhD[2], M. Kathryn Liszewski, MD[4], John P. Atkinson, MD[4] and Robert M.W. Hofstra, PhD[1,2]

**Purpose:** Autosomal recessive congenital short bowel syndrome is caused by mutations in *CLMP*. No mutations were found in the affected males of a family with presumed X-linked congenital short bowel syndrome or in an isolated male patient. Our aim was to identify the disease-causing mutation in these patients.

**Methods:** We performed mutation analysis of the second exon of *FLNA* in the two surviving affected males of the presumed X-linked family and in the isolated patient.

**Results:** We identified a novel 2-base-pair deletion in the second exon of *FLNA* in all these male patients. The deletion is located between two nearby methionines at the N-terminus of filamin A. Previous studies showed that translation of *FLNA* occurs from both methionines, resulting in two isoforms of the protein. We hypothesized that the longer isoform is no longer translated due to the mutation and that this mutation is therefore not lethal for males *in utero*.

**Conclusion:** Our findings emphasize that congenital short bowel syndrome can be the presenting symptom in male patients with mutations in *FLNA*.

*Genet Med* 2013:15(4):310–313

**Key Words**: chronic idiopathic intestinal pseudo-obstruction; *FLNA*; mutation; short small intestine; synovial lipomatosis

## INTRODUCTION

Congenital short bowel syndrome (CSBS) is characterized by a shortened small intestine and intestinal malrotation. Although the normal length of the small intestine at birth is ~275 cm,[1] patients with CSBS have a markedly shorter small intestinal length of ~50 cm, on average. CSBS has a high mortality rate within the first few months after birth, although some long-term survivors of CSBS have been reported.[2–5]

CSBS is an inherited disorder. The identification of homozygous and compound heterozygous mutations in Coxsackie- and adenovirus receptor-like membrane protein (CLMP) in CSBS patients confirmed an autosomal recessive pattern of inheritance in most affected families.[6] However, no *CLMP* mutations were identified in one Italian family[7,8] or in an isolated German-American male (**Table 1**) who presented with congenital short bowel syndrome.[5] In the affected family, only males developed the disease, consistent with an X-linked pattern of inheritance (**Figure 1**).[8]

In the literature, a family with X-linked chronic idiopathic intestinal pseudo-obstruction (CIIP) has been described.[9,10] The patients in this family have very similar features to those seen in patients with CSBS with mutations in *CLMP*, including a shortened small intestine. A 2-base-pair (bp) deletion in the second exon of filamin A (*FLNA*) (c.65-66delAC) was identified in this X-linked CIIP family. This deletion is located between two nearby methionines at the N-terminus of FLNA. It was shown that translation of *FLNA* can occur from either methionine *in vitro* and that the deletion affects only the longer form of FLNA.[10]

We hypothesized that the longer form of FLNA is essential for normal small intestinal development. Therefore, we performed mutation analysis of the second exon of *FLNA* in the X-linked CSBS family and in the isolated male patient.

## MATERIALS AND METHODS

### Patients

The presumed X-linked CSBS family was reported by Kern et al.[8] As described in their case report, the patients in this family presented with bile-stained vomiting and diarrhea, symptoms typically seen in patients with CSBS. The two patients in the Italian family who survived were included in our study. Patient II-6 was born with a small intestine of a total length of 60 cm. The family pedigree is presented in **Figure 1**. The isolated male patient (patient I, family 2) who presented with CSBS was described by Siva et al.,[5] who emphasized the extensive nature of a rare arthropathy known as synovial lipomatosis. The length of the small intestine in this patient was 90 inches (228.6 cm) at the age of 15 (one-third of normal length). This patient is a long-term survivor and is >40 years old. The arthropathy was reported, but it did resolve spontaneously.

[1]Department of Genetics, University Medical Centre Groningen, University of Groningen, Groningen, The Netherlands; [2]Department of Clinical Genetics, Erasmus MC, Erasmus University Rotterdam, Rotterdam, The Netherlands; [3]Department of Paediatric Gastroenterology, Hepatology and Nutrition, The Children's Hospital at Westmead, Westmead, Australia; [4]Department of Medicine, Divisions of Rheumatology and Gastroenterology, Washington University School of Medicine, St. Louis, Missouri, USA. Correspondence: Robert M.W. Hofstra (r.hofstra@erasmusmc.nl)

Submitted 22 June 2012; accepted 17 August 2012; advance online publication 4 October 2012. doi:10.1038/gim.2012.123

**Table 1** Clinical data on the X-linked patients with congenital short bowel syndrome

| Family | Patient | Ethnicity | Sex | Length of small bowel | Other features | Mutation |
|---|---|---|---|---|---|---|
| 1 | II-6 | Italian | Male | 60 cm at birth | Nil | c.16-17delCT |
| | III-6 (Refs. 7 and 8) | Italian | Male | Unknown | Nil | c.16-17delCT |
| 2 | 1 (Ref. 5) | German-American | Male | At age 15: 228.6 cm | Synovial lipomatosis | c.16-17delCT |

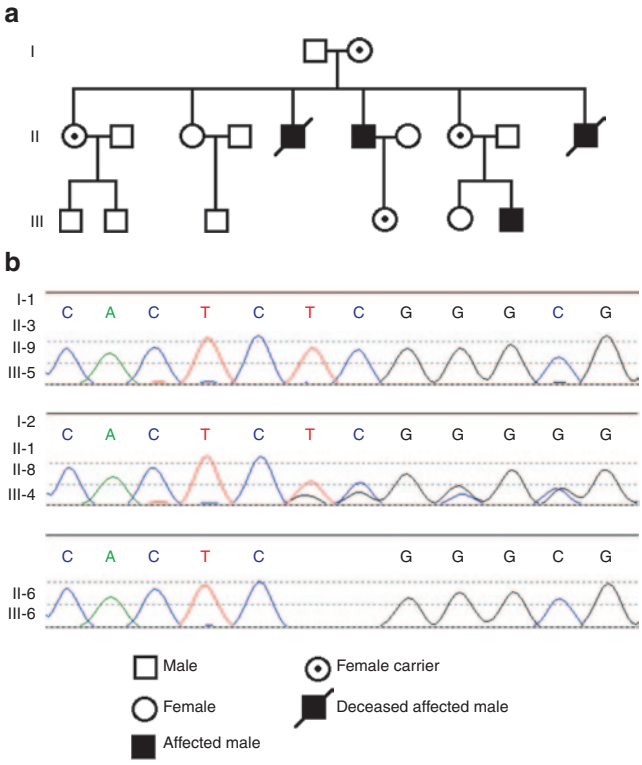


**Figure 1** Co-segregation of the 16-17delTC mutation in the X-linked family. (**a**) Pedigree of the X-linked congenital short bowel syndrome (CSBS) family. (**b**) Chromatogram showing filamin A exon 2 sequence around c.16-17delTC. Top: sequence of healthy family members, same as reference sequence. Middle: sequence of female carriers in the family; heterozygous for the c.16-17delTC mutation. Bottom: sequence of the male patients with CSBS carrying the c.16-17delTC mutation.

Our study protocol was approved by the institutional and national ethics review committees at the University Medical Centre Groningen (NL31708.042.10) and at the Washington University School of Medicine. Written informed consent was obtained from all the study participants.

### Genetic analysis

Genomic DNA was isolated from peripheral whole-blood lymphocytes by standard procedures. Mutation analysis of the exonic and flanking intronic regions of the second exon of *FLNA* (NG_011506.1) was performed using the primers FLNA forward, 5′-CGCAACCTCTGCTCCCTGCC-3′, and FLNA reverse, 5′-GCGCCACCGACACGTTCTCA-3′. PCR was performed as follows: 35 cycles with 100 ng of genomic DNA at 95 °C for 1 min, at an annealing temperature of 55 °C for 1 min and then at 72°C for 1 min. This was accomplished in two patients of the family and their unaffected relatives, in the isolated male patient (patient I, family 2) and his mother, and in 92 controls of Caucasian ethnicity.

## RESULTS

We identified a 2-bp deletion (c.16-17delTC) in the two surviving affected males in the family and also in the isolated male patient (**Figure 1**). We confirmed co-segregation of the 2-bp deletion in the X-linked family and showed that all the obligate carriers were heterozygous for this deletion. Because the mother of the isolated male patient did not carry the deletion, we concluded that his mutation had occurred *de novo*. Moreover, this mutation was absent in 92 controls and is not reported in any single-nucleotide polymorphism database or in the exome sequence variant database (http://evs.gs.washington.edu/EVS/).

The c.16-17delTC deletion results in a frameshift and a premature stop codon at amino acid 103. In the predicted protein, only the first six amino acids are retained, which are identical to the wild-type filamin A. They are followed by 97 different amino acids. As the c.16-17delTC mutation is located between the first and second methionine, it likely has a similar effect to the c.65-66delAC mutation (found in CIIP)[10] that results in loss of only the long form of FLNA.

## DISCUSSION

Mutations in *FLNA* are associated with a wide spectrum of disorders, including periventricular nodular heterotopia, otopalatodigital syndromes types 1 and 2, frontometaphyseal dysplasia and Melnick Needles syndrome, and X-linked cardiac valvular dystrophy.[11–13] Our findings add CSBS to this list as a possible presenting phenotype in male patients with a mutation in *FLNA*. We therefore emphasize the importance of *FLNA* in intestinal development. The index patient of the family described by Gargiulo et al.[10] developed asymmetrical spastic diplegia, and an abnormal intermediate signal in the peritrigonal white matter was seen on magnetic resonance imaging. We cannot exclude involvement of the central nervous system in our patients because no magnetic resonance imaging brain scans were available. However, they did not have any clinical neurological abnormalities such as seizures or spasticity; not all patients with mutations in *FLNA* have central nervous system involvement. The mother of the proband described by Kapur et al.[14] did have a duplication of the first 28 exons of *FLNA*, but had a normal cranial magnetic resonance imaging.

In addition to the finding of Gargiulo et al.[10] of a 2-bp deletion in *FLNA* in one male patient with CIIP, Kapur et al.[14] reported *FLNA* mutations in patients with CIIP. They identified a partial

duplication of the first 28 exons of *FLNA* in one family and a nonsense mutation (c.7021C→T; Q2341X) in exon 43 in another patient. However, these patients were diagnosed with multiple congenital anomalies, of which a congenital short bowel was only one feature.[14] These findings support our hypothesis that *FLNA* is important for normal small intestinal development.

As the mutations in the second exon are located between the first two methionines, they probably act as mild mutations, conserving the reading frame encoding the short isoform, associated with a rather mild phenotype. The mutations identified in the patients reported by Kapur et al.[14] were much more severe, explaining their more severe phenotype.

Our finding raised the question of whether CSBS patients with a mutation in the second exon of *FLNA* and CSBS patients with mutations in *CLMP* have the same phenotype. Clearly, the congenital short bowel is a feature they have in common, but pseudo-obstruction has also been described in CSBS patients with mutations in *CLMP*. Therefore, the bowel tissue of patients with CSBS has been studied to determine if there is an abnormality of the enteric nervous system underlying the reduced bowel movements. Although the bowel wall in patients with CSBS seems to be macroscopically normal, Tanner et al.[15] described abnormal histology of the bowel wall revealed by silver staining, in which there were too many neurons in the ganglia. The neuronal nuclei showed clumped chromatin, which is characteristic of neuroblasts. They observed that the intrinsic argyrophil ganglia were absent or much reduced in number, and argued that these histological findings might cause the motility abnormalities described in their patient as well as in other cases.[15] In addition, Schalamon et al.[16] observed an abnormal bowel wall with signs of neuronal intestinal dysplasia in a patient from a consanguineous Turkish family, in whom a truncating homozygous mutation in *CLMP* was detected.[6] In other cases, no abnormalities of the nerve plexus were observed on routine histology or by acetylcholinesterase staining.[17,18] However, histology specimens were not available for all cases.

To conclude, the clinical features of CSBS patients with *FLNA* mutations conserving the short isoform and CSBS patients with mutations in *CLMP* are very similar. Both have a congenital shortened small intestine and malrotation. In addition, all patients with CIIP described with *FLNA* mutations have a congenital short bowel as a common feature. Male patients with CSBS with either missense mutations or distal truncating mutations in *FLNA* have, in general, multiple congenital anomalies in addition to a congenital shortened small intestine. However, the male patients in our study and the male patient described by Gargiulo et al.[10] presented with a gastrointestinal phenotype, including malrotation, a shortened small intestine, and pseudo-obstruction, and they have a 2-bp deletion in the second exon of *FLNA*. Therefore, starting with screening of exon 2 of *FLNA* is recommended in male patients presenting with CSBS without mutations in *CLMP*. If no mutation is found in the second exon of *FLNA*, screening the entire *FLNA* gene might reveal another, more distal, nontruncating mutation. In male patients with CSBS and multiple major congenital anomalies, it is worth screening the entire *FLNA* gene for mutations. A family history of features associated with *FLNA* mutations, like periventricular nodular heterotopia and cardiac valvular dystrophy, can also point to *FLNA* mutations. Furthermore, as *FLNA* mutations have not been found in patients with only pseudo-obstruction, we argue that a diagnosis of CSBS rather than CIIP, with or without central nervous system involvement, should drive additional genetic screening for mutations in *FLNA* in male patients. These data also suggest that *FLNA* could be seen as the underlying gene for CSBS rather than for CIIP.[10] As mutations in either *FLNA* or *CLMP* can explain CSBS, further research is needed to understand a possible interaction of their gene products.

We do not know whether FLNA and CLMP are directly linked or are part of the same protein network. Raschperger et al.[19] showed that CLMP co-localizes with actin filaments. They speculated that CLMP interacts with a protein that directly binds to actin filaments, which would bring CLMP to the tight junction by anchoring CLMP in the actin cytoskeleton. They suggested that zonula occludens-1 (ZO-1) could be such an interacting protein. As FLNA also binds to actin filaments, we can speculate that FLNA is the link between CLMP and the actin cytoskeleton. It is known that FLNA interacts with other transmembrane proteins such as integrin beta and the cystic fibrosis transmembrane conductance regulator.[20] There is also supportive evidence that FLNA plays a role in anchoring transmembrane proteins in the cell membrane. It has been shown, e.g., that for the expression of cystic fibrosis transmembrane conductance regulator on the cell membrane, its interaction with FLNA is important.[20] Therefore, we might suspect that FLNA plays a role in the internalization of CLMP in the plasma membrane as well. It can be speculated that the mutations in *FLNA* influence the expression of CLMP on the plasma membrane. Further research is needed to determine whether CLMP and FLNA do indeed interact in the same protein network and, if so, which other proteins are involved in this network. We cannot exclude that different pathways underlie X-linked CSBS and autosomal recessive CSBS, with different disease mechanisms leading to a similar disease phenotype.

## ACKNOWLEDGMENTS

This work was funded by the Junior Scientific Masterclass (University of Groningen) and the J.K. de Cock Foundation. We thank the patients and their families for participating in this study, Jackie Senior for editing the manuscript, and Dineke S. Verbeek for critically reviewing the manuscript. C.S.v.d.W. and R.M.W.H. conceptualized and designed the study. C.S.v.d.W., Y.S., J.B.G.M.V., M.C., E.O., C.-H.C., A.S.B., M.K.L., J.P.A., and R.M.W.H. generated, collected, assembled, analyzed, and/or interpreted the data. C.S.v.d.W. and R.M.W.H. drafted and revised the manuscript. R.M.W.H. approved the final version of the manuscript.

## DISCLOSURE

The authors declare no conflict of interest.

## REFERENCES

1. Weaver LT, Austin S, Cole TJ. Small intestinal length: a factor essential for gut adaptation. *Gut* 1991;32:1321–1323.
2. Huysman WA, Tibboel D, Bergmeijer JH, Molenaar JC. Long-term survival of a patient with congenital short bowel and malrotation. *J Pediatr Surg* 1991;26:103–105.
3. Ordonez P, Sondheimer JM, Fidanza S, Wilkening G, Hoffenberg EJ. Long-term outcome of a patient with congenital short bowel syndrome. *J Pediatr Gastroenterol Nutr* 2006;42:576–580.
4. Hasosah M, Lemberg DA, Skarsgard E, Schreiber R. Congenital short bowel syndrome: a case report and review of the literature. *Can J Gastroenterol* 2008;22:71–74.
5. Siva C, Brasington R, Totty W, Sotelo A, Atkinson J. Synovial lipomatosis (lipoma arborescens) affecting multiple joints in a patient with congenital short bowel syndrome. *J Rheumatol* 2002;29:1088–1092.
6. Van Der Werf CS, Wabbersen TD, Hsiao NH, et al. CLMP is required for intestinal development, and loss-of-function mutations cause congenital short-bowel syndrome. *Gastroenterology* 2012;142:453–462.e3.
7. Kern IB, Harris MJ. Congenital short bowel. *Aust N Z J Surg* 1973;42:283–285.
8. Kern IB, Leece A, Bohane T. Congenital short gut, malrotation, and dysmotility of the small bowel. *J Pediatr Gastroenterol Nutr* 1990;11:411–415.
9. Auricchio A, Brancolini V, Casari G, et al. The locus for a novel syndromic form of neuronal intestinal pseudoobstruction maps to Xq28. *Am J Hum Genet* 1996;58:743–748.
10. Gargiulo A, Auriccio R, Barone MV, et al. Filamin A is mutated in X-linked chronic idiopathic intestinal pseudo-obstruction with central nervous system involvement. *Am J Hum Genet* 2007;80:751–758.
11. Robertson SP. Filamin A: phenotypic diversity. *Curr Opin Genet Dev* 2005;15:301–307.
12. Bernstein JA, Bernstein D, Hehr U, Hudgins L. Familial cardiac valvulopathy due to filamin A mutation. *Am J Med Genet A* 2011;155A:2236–2241.
13. Kyndt F, Gueffet JP, Probst V, et al. Mutations in the gene encoding filamin A as a cause for familial cardiac valvular dystrophy. *Circulation* 2007;115:40–49.
14. Kapur RP, Robertson SP, Hannibal MC, et al. Diffuse abnormal layering of small intestinal smooth muscle is present in patients with FLNA mutations and x-linked intestinal pseudo-obstruction. *Am J Surg Pathol* 2010;34:1528–1543.
15. Tanner MS, Smith B, Lloyd JK. Functional intestinal obstruction due to deficiency of argyrophil neurones in the myenteric plexus. Familial syndrome presenting with short small bowel, malrotation, and pyloric hypertrophy. *Arch Dis Child* 1976;51:837–841.
16. Schalamon J, Schober PH, Gallippi P, Matthyssens L, Höllwarth ME. Congenital short-bowel; a case study and review of the literature. *Eur J Pediatr Surg* 1999;9:248–250.
17. Hamilton JR, Reilly BJ, Morecki R. Short small intestine associated with malrotation: a newly described congenital cause of intestinal malabsorption. *Gastroenterology* 1969;56:124–136.
18. Erez I, Reish O, Kovalivker M, Lazar L, Raz A, Katz S. Congenital short-bowel and malrotation: clinical presentation and outcome of six affected offspring in three related families. *Eur J Pediatr Surg* 2001;11:331–334.
19. Raschperger E, Engstrom U, Pettersson RF, Fuxe J. CLMP, a novel member of the CTX family and a new component of epithelial tight junctions. *J Biol Chem* 2004;279:796–804.
20. Playford MP, Nurminen E, Pentikäinen OT, et al. Cystic fibrosis transmembrane conductance regulator interacts with multiple immunoglobulin domains of filamin A. *J Biol Chem* 2010;285:17156–17165.