Spine

SPINE Volume 40, Number 10, pp E601-E608
©2015, Wolters Kluwer Health, Inc. All rights reserved.

CASE REPORT

Effect of Denosumab on Recurrent Giant Cell Reparative Granuloma of the Lumbar Spine

Koji Akeda, MD, PhD,* Yuichi Kasai, MD, PhD,† Toshihiko Sakakibara, MD,† Akihiko Matsumine, MD, PhD,* Norihiko Takegami, MD,* Junichi Yamada, MD,* and Akihiro Sudo, MD, PhD*

Study Design. A case of recurrent giant cell reparative granuloma (GCRG) of the lumbar spine successfully treated with denosumab is reported; a fully human monoclonal antibody against the receptor activator of nuclear factor kappa B (RANK) ligand (RANKL).

Objective. To report the first case of recurrent GCRG of the lumbar spine treated with denosumab.

Summary of Background Data. GCRG is a non-neoplastic osteofibrous lesion usually found in the maxilla and mandible but rarely in the spine. It is clinically distinct from giant cell tumor of bone (GCTB), although common histological characteristics such as the proliferation of spindle-shaped stromal cells and multinucleated giant cells are shared. Denosumab has recently been reported to be effective for unresectable GCTB; however, there is only one report of its effect on GCRG. Moreover, the effect of denosumab on GCRG of the spine is unknown.

Methods. The clinical course, radiological features, pathology, and treatment outcome of a patient with recurrent GCRG of the lumbar spine treated with denosumab are documented.

Results. Denosumab treatment was used for this patient with unresectable recurrent GCRG of the lumbar spine. Follow-up lumbar radiography showed significant bone formations in the tumor lesion after 3 months of treatment. On follow-up computerized tomography scans of the L2 and L3 vertebral lesions, the replacement of osoteolytic lesions by the formation of cortical-like bone tissue was clearly identified.

Conclusion. We report the first case of recurrent GCRG of the spine successfully treated with denosumab. Treatment with denosumab induced significant bone formation in the unresectable lumbar lesion with stable clinical improvement during the 12-month follow-up period without apparent complications. Denosumab shows promise as a new alternative treatment option for osteoclastic giant cell-rich tumors, such as GCRG, especially for unresectable lesions of the spine.

Key words: giant cell reparative granuloma, denosumab, RANK ligand, primary bone tumor, lumbar spine.

Level of Evidence: 4

Spine 2015;40:E601–E608

Giant cell reparative granuloma (GCRG) is a relatively rare non-neoplastic osteofibrous lesion usually found in the maxilla and mandible, with the second most common region being the small bones of the hands and feet,[1–3] whereas GCRG of the spine is rare. Fibrous stromal tissue with hemorrhage, clustering osteoclast-like giant cells, and reactive bone formation are the histological characteristics of GCGR, both clinically and histologically different from giant cell tumor of bone (GCTB).[1–3]

The receptor activator of NF-κB (RANK) ligand (RANKL) is expressed on the surface of osteoblasts and is released into the bone microenvironment. RANKL binds to and activates its receptor, RANK, in immature osteoclasts;[4] therefore this signaling pathway plays a pivotal role in the regulation of matrix metabolism of normal bone tissue. The aberrant activation and proliferation of osteoclasts induced by an imbalance of the RANK/RANKL pathway is thought to be responsible for the development of osteoclastic giant cell-rich tumors, such as GCRG and GCTB.[5,6]

Denosumab, a novel human monoclonal antibody directed against RANKL, is currently approved for the treatment of osteoporosis, bone metastasis from solid tumors, and unresectable GCTB (see reviews by Dufresne *et al*[5] and Brown and Coleman[7]). It was recently reported that denosumab has a powerful effect on antitumor activity and new bone formation of GCTB of the spine.[8,9]

There has been only one case report on the effectiveness of denosumab for treating a patient with GCRG of the maxilla,[9] and the effect of denosumab on GCRG of the spine remains unknown. We report here a case of unresectable recurrent GCRG of the lumbar spine that displayed a marked response to denosumab treatment.

From the Departments of *Orthopaedic Surgery and †Spinal Surgery and Medical Engineering, Mie University Graduate School of Medicine, Mie, Japan.

Acknowledgment date: October 27, 2014. Acceptance date: February 13, 2015.

The legal regulatory status of the device(s)/drug(s) that is/are the subject of this manuscript is not applicable in our country.

Ministry of Education, Culture, Sports, Science and Technology (Japan) funds were received in support of this work.

Relevant financial activities outside the submitted work: Grants/grants pending

Address correspondence and reprint requests to Koji Akeda, MD, PhD, Department of Orthopaedic Surgery, Mie University Graduate School of Medicine, 2-174 Edobashi, Tsu city, Mie, Japan 514-8507; E-mail: k_akeda@clin.medic.mie-u.ac.jp

DOI: 10.1097/BRS.0000000000000862

Copyright © 2015 Wolters Kluwer Health, Inc. Unauthorized reproduction of this article is prohibited.

CASE REPORT

A 69-year-old female first noticed low back pain in 2007 when she pulled weeds by hand from a squatting position. She presented to the department of orthopedic surgery of an affiliated hospital complaining of progressive back pain and paresthesia of the right leg. No relevant history was noted, although she had complications of diabetes mellitus and hyperlipidemia.

Radiography of the lumbar spine showed obscuration of the right L3 pedicle (Figure 1A, B). Axial computed tomographic (CT) scans of the L3 vertebra revealed osteolysis in the right half of the L3 vertebra, including the right side of the pedicle and transverse process. Sagittal and axial magnetic resonance (MR) images showed a lesion in the L3 vertebra (Figure 2). The lesion exhibited low intensity on T1-weighted images (Figure 2A, D), intermediate-to-high intensity on T2-weighted images (Figure 2B, E), and diffuse enhancement on contrast-enhanced T1-weighted images (Figure 2C, F). MR axial (T2-weighted) images showed that the osteolytic lesion identified on axial CT scans was a fluid-containing cyst (Figure 2E). No abnormal laboratory test findings were identified in blood count, electrolytes, or biochemical and tumor marker tests.

At this time, the differential diagnoses were aneurysmal bone cyst, GCTB, spinal metastasis of unknown origin, and osteosarcoma. An open biopsy was then performed to obtain specimens from the lesion. Histologically, this tissue contained fibrous stromal tissue, hemorrhage, and bone formation (Figure 3A). High magnification images showed a number of multinucleated giant cells and a dense fibrous stroma with inflammatory cell infiltration (Figure 3B). The histological diagnosis was GCRG.

In February 2008, the patient underwent resection of the L3 tumor and placement of a hydroxyapatite block with spinal instrumentation. Three years 10 months later, the patient developed left leg pain with increasingly severe symptoms. Osteolytic bone lesions on the left L2 and L3 vertebrae were found on the sagittal and axial CT scans. Sagittal and axial T2-weighted MR images showed that the mass lesion identified in the L2 and L3 vertebrae compressed the cauda equine (Figure 4A, B). On axial MR (T2-weighted) images, the L3 lesion exhibited an intensity similar to that of the MR image before the surgery nearly 4 years ago. The cystic lesion-containing fluid on the L3 vertebra was seen again (Figure 4C). Therefore, we speculated that the osteolytic lesion was recurrent GCTB in the L3 vertebra and local infiltration to the L2 vertebra, and a second attempt at surgical resection was planned. In April 2013, the patient underwent decompression of the L2–L3 lamina, resection of the L2 tumor, and placement of a hydroxyapatite paste with spinal instrumentation (Figure 5A, B). Because of hemorrhaging from the tumor lesion, we could not accomplish resection of the recurrent L3 tumor; therefore, it remained intact. The histological analysis of the L2 and L3 lesions was similar to that of the open biopsy, confirming the diagnosis of GCRG. An immunohistochemical analysis of the lesion showed that the expression of RANK was clearly identifiable in multinucleated giant cells (Figure 3C), and RANKL expression was found in the fibroblastic stromal cells around the multinucleated giant cells (Figure 3D). Faint RANKL immunoreactivity was also identified at the outer boundary of giant cells (Figure 3D). One month after the second surgery (May 2013), the patient was started on monthly subcutaneous injections of denosumab (120 mg). Daily supplements of 500 mg of calcium and 400 IU of vitamin D were prescribed. After the second surgery, back and left leg pain improved and no recurrence of the symptoms appeared during denosumab treatment. Three months after initiation of treatment with

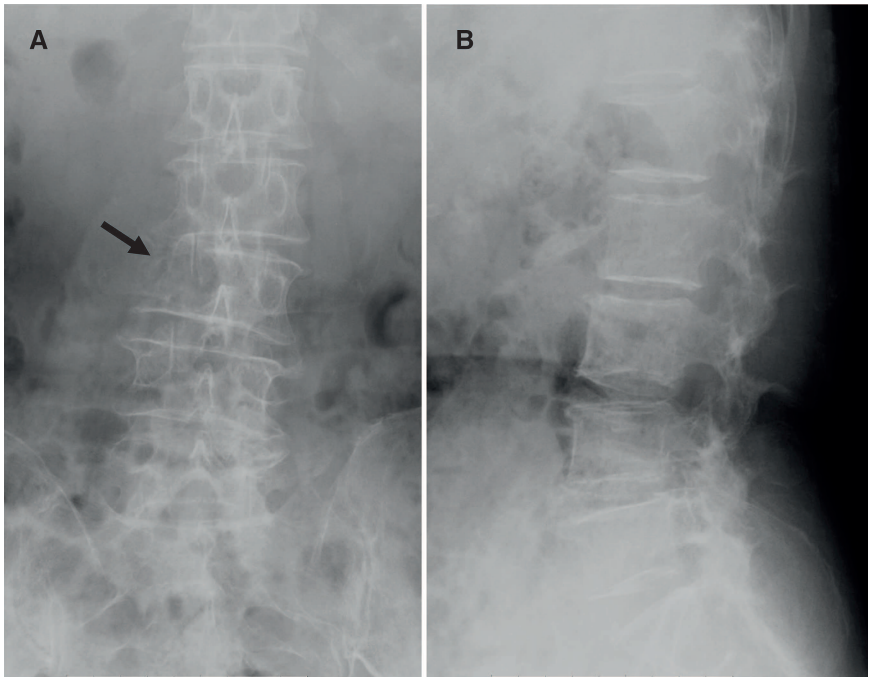

Figure 1. Lumbar spinal radiographs of a 69-year-old female with giant cell reparative granuloma of the L3 vertebra. A, Anteroposterior view. B, Lateral view. Arrow: L3 vertebra.

Copyright © 2015 Wolters Kluwer Health, Inc. Unauthorized reproduction of this article is prohibited.

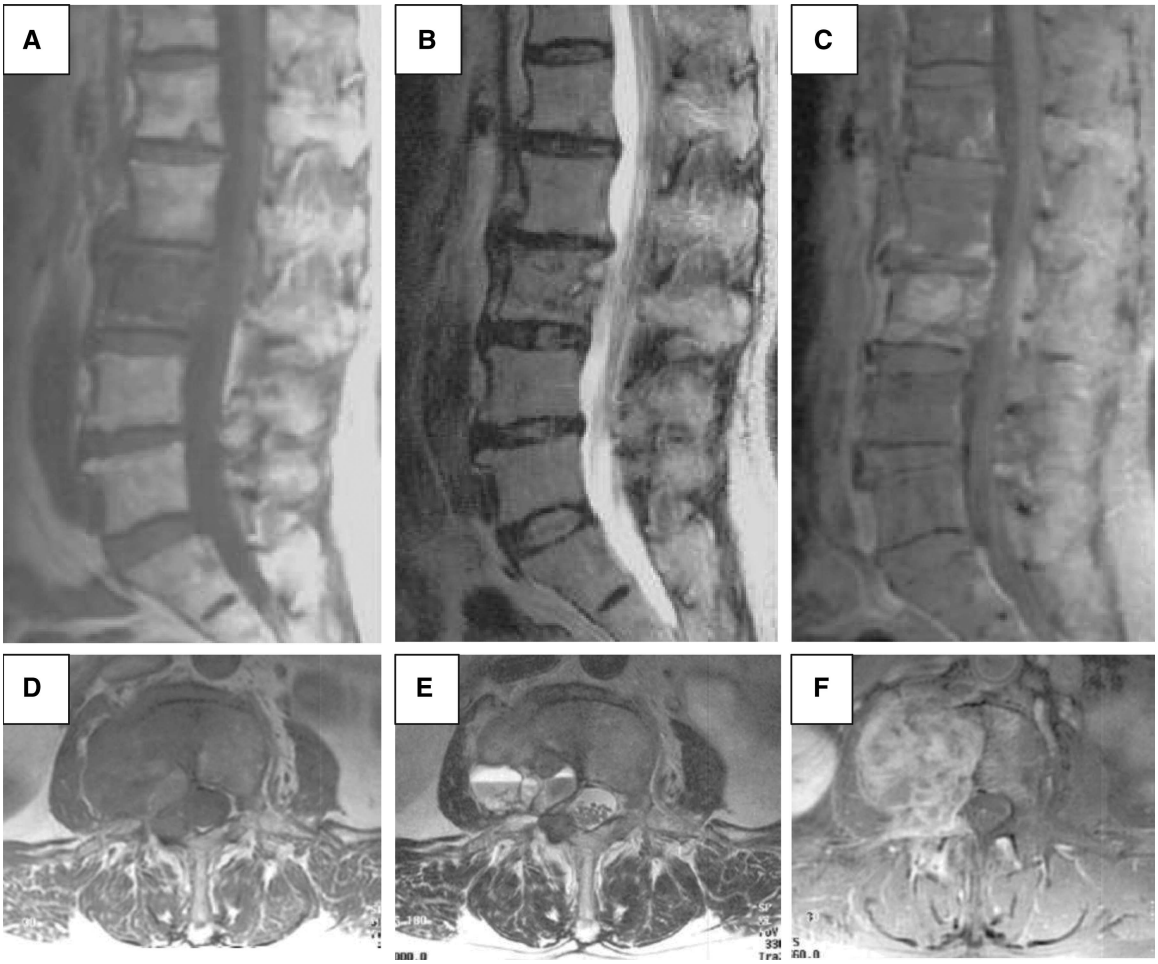

Figure 2. MR images of the lumbar spine of a 69-year-old female with giant cell reparative granuloma of the L3 vertebra. **A–C**, Midsagittal section. **D–F**, Axial section of the L3 vertebra. A, D, T1-weighted MR image. B, E, T2-weighted MR image. C, F, Contrast-enhanced T1-weighted MR image. MR indicates magnetic resonance.

denosumab, a follow-up lumbar radiograph showed bone formation focusing around the right L3 transverse process (Figure 6B). These radiographical changes progressed over time until 12 months after the initial treatment (Figure 6A–D). On sagittal CT reconstruction scans, marked bone formation in the L3 vertebra was identified at 6 and 12 months after starting denosumab (Figure 7B, C). Furthermore, a sclerotic rim formation bridging the posterior wall of the L2 and L3 vertebrae was identified (Figure 7B, C). Axial CT scans of the L2 vertebra showed progressive cortical-like bone formation around the hydroxyapatite paste (Figure 8A–C). The osteolytic lesion within the L3 vertebra was replaced by a new bone lesion 6 months after the treatment began (Figure 8D–E). The most recent MR image in July 2014 shows no evidence of disease recurrence. During the follow-up period, no serious complications, including hypocalcemia, occurred.

Immunohistochemistry

Tissues from the lumbar lesion were fixed in 4% paraformaldehyde and embedded in paraffin. Serial 5-μm sections were used for immunohistochemical analysis. After blocking endogenous peroxidase activity, the sections were heated with 0.01 M citrated buffer (pH 6.0) and incubated overnight at 4°C with primary antibodies anti-RANKL (ab9957; abcam, Cambridge, UK) and anti-RANK (ab12008; abcam). Mouse and rabbit isotype-matched IgG was used as a negative control. Primary antibodies were visualized using the Histofine Simple Stain MAX-PO (MULTI) kit (Nichirei Bioscience, Tokyo, Japan) according to the instruction manual, with some modification. Peroxidase activity was detected with 3,3′-diaminobenzidine tetrahydrochloride (Dojindo, Toyama, Japan). The sections were counterstained in Mayer's hematoxylin.

DISCUSSION

GCRG was first reported by Jaffe[10] as a reactive lesion to an intraosseous hemorrhage from jaw trauma. It is currently defined, both histologically and clinically, to be distinctly different from GCTB. GCRG, although containing multinucleate giant cells, is distinguished from GCTB by the histology of its granulomatous appearance characterized by bland fibroblasts and multinucleated giant cells surrounding foci of hemorrhage.[2,11] Osteoid production, an unusual feature of GCTB, is also commonly identified in GCRG. Although a wide range of patient ages has been reported, approximately

Copyright © 2015 Wolters Kluwer Health, Inc. Unauthorized reproduction of this article is prohibited.

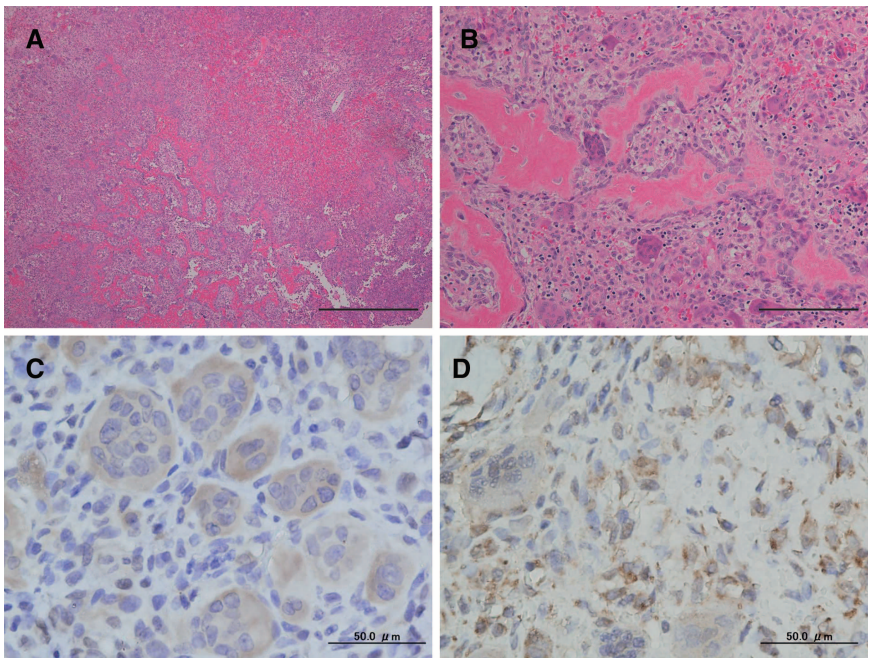

Figure 3. Histological section from an open biopsy of the L3 vertebral lesion of a 69-year-old female with giant cell reparative granuloma. **A, B**, Hematoxylin-eosin stain. **C, D**, Immunohistochemical analysis. A, The tissue contains fibrous stromal tissue, hemorrhage, and bone formation. Bar: 400 μm. B, A high magnification image shows a number of multinucleated giant cells and a dense fibrous stroma with inflammatory cell infiltration. Bar: 100 μm. C, Immunoreactivity against RANK is seen in osteoclast-like multinucleated giant cells. D, immunoreactivity against RANK ligand is observable on fibroblastic stromal-like cells. Bar: 50 μm.

70% of patients with GCRG are younger than 30 years. GCRG affects females more commonly than males, especially in those with jaw involvement. The standard treatment has been surgical removal, but local recurrence has been reported in 22% to 50% of patients.[12,13]

GCRG involvement of the spine is rare. Because the pathogenesis of GCRG is still debated, these lesions in the spine are also named as solid variants of aneurysmal bone cysts[14] or giant cell granulomas.[15] Using all these terms, a search of the literature revealed 11 articles reporting 14 cases of GCRG-related disorders occurring in the spine.[14–24] According to the World Health Organization classification of tumors of soft tissue and bone,[1] the original term "GCRG" is used as a synonym for giant cell lesions of small bones. However, in this report, we use "GCRG" to represent all GCRG-related disorders. Of the previously reported cases involving the

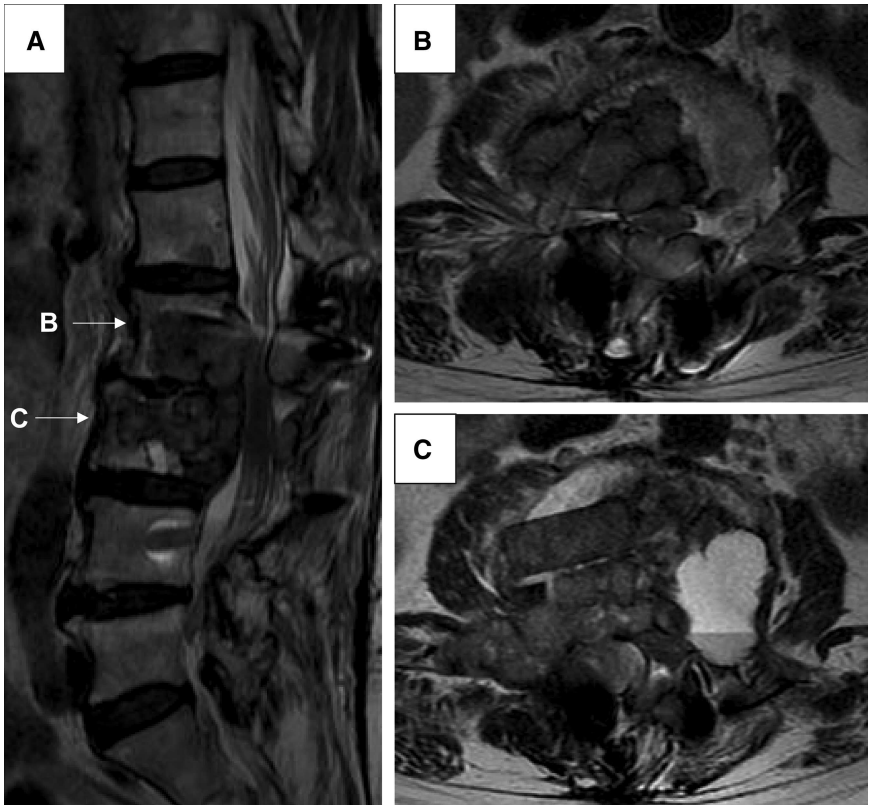

Figure 4. T2-weighted MR images of the lumbar spine 3 years and 10 months after the first operation of a female patient with giant cell reparative granuloma. **A**, Sagittal MR image. **B**, Axial MR image of the L2 vertebra. **C**, Axial MR image of the L3 vertebra. MR indicates magnetic resonance.

Copyright © 2015 Wolters Kluwer Health, Inc. Unauthorized reproduction of this article is prohibited.

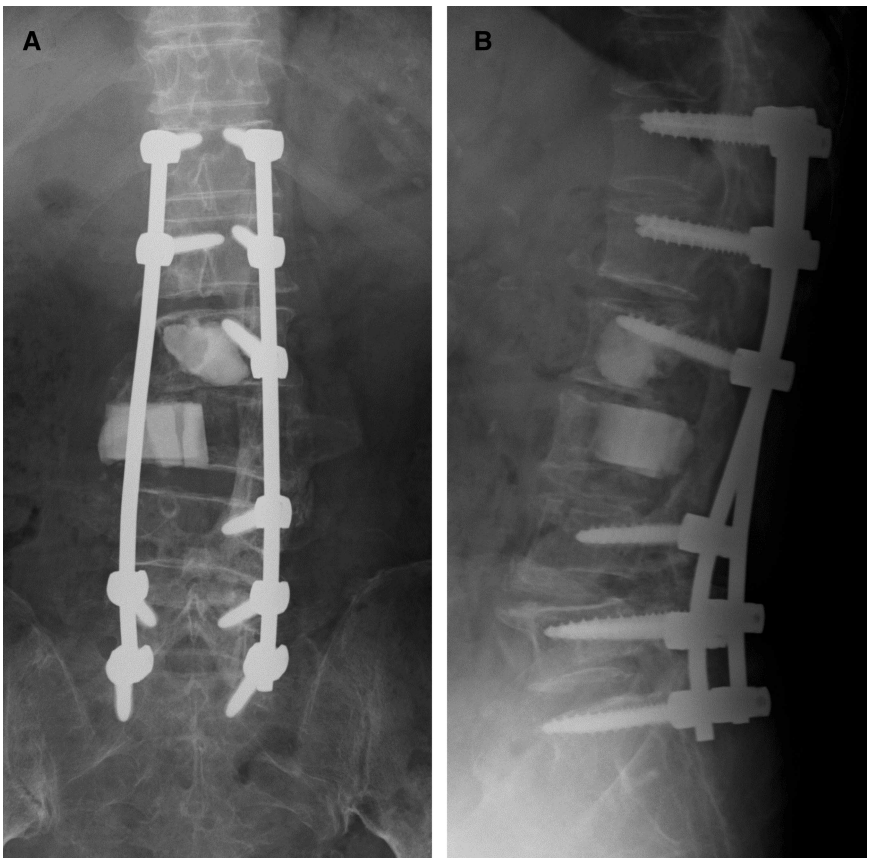

Figure 5. Lumbar spinal radiographs after the second operation of a female patient with giant cell reparative granuloma. **A**, Anteroposterior view. **B**, Lateral view. Decompression of the L2–L3 lamina, resection of the L2 tumor, and placement of the hydroxyapatite paste with spinal instrumentation were performed in April 2013.

spine, 12 were treated by surgical curettage with or without a bone graft, 1 case by radiation alone,[14–19,21–24] and 1 case was unknown.[20] During the average follow-up period of 35.7 months after treatment, local recurrence and/or residual masses were found in 38% of the cases (5/13).

RANKL, a member of the tumor necrosis factor superfamily, is expressed on the surface of osteoblasts and released into the bone microenvironment where it binds to and activates its receptor, RANK, in immature osteoclasts.[4] Therefore, the RANK/RANKL pathway plays an important role in the regulation of matrix metabolism of bone tissue. Various pathological states, including osteoporosis, bone metastasis of solid tumor, multiple myeloma, and GCTB, have been reported to be associated with the pathological activation of osteoclasts caused by an imbalance of the RANK/RANKL pathway.[25]

Denosumab is a fully human, synthetic IgG_2 monoclonal antibody that can bind to RANKL with high affinity, inhibiting its binding to RANK, thereby leading to reduced osteoclast-mediated bone destruction.[26] Denosumab has been clinically used and approved for the treatment of postmenopausal osteoporosis[26,27] and bone metastasis from solid tumor.[28–30] Denosumab was also approved by the Food and Drug Administration on June 2013 for the treatment of unresectable GCTB in adults and skeletally mature adolescents or when surgical resection is likely to result in severe morbidity. In an open-label, phase 2 study, 37 patients with recurrent or unresectable giant cell tumor who received 120 mg of denosumab per month were evaluated[31] and 30 of 35 of patients (86%) showed a tumor response assessed by either histology or radiology. Interestingly, the histological analysis of post-treatment tissue samples showed a significant reduction in the number of giant cells and spindle-shaped cell-dense stroma, which had been replaced by new osteoid formation. Fluorodenoxyglucose–positron emission tomography analysis showed a reduction in fluorodenoxyglucose uptake after denosumab treatment. In a larger subsequent phase 2 study, the same group reported the safety and efficacy of denosumab in patients who had salvageable or unsalvageable GCTB.[32] Of 282 patients, 1% had osteonecrosis of the jaw and 5% had hypocalcemia after treatment with denosumab. The study group concluded that this incidence of adverse events was consistent with the previously established safety profile of denosumab and that denosumab is capable of suppressing osteolytic activity and inhibiting disease progression of GCTB.

Therapeutic strategy for GCTB of the spine, the incidence rate of which is relatively rare, is controversial because of its unpredictable biological behavior and the anatomical complexity of the spine. Ideally, surgical resection *en block* has been recommended, but highly invasive or unresectable cases have been reported.[33,34] Mattei *et al*[35] recently reported the case of a 22-year-old female patient affected by a GCTB involving C2 who was successfully treated with denosumab. Radiographically, the osteolytic lesion largely disappeared, to be mostly replaced by newly formed cortical bone. Agarwal *et al*[8] reported the case of a 27-year-old female patient with recurrent GCTB in the thoracic spine that was previously

Copyright © 2015 Wolters Kluwer Health, Inc. Unauthorized reproduction of this article is prohibited.

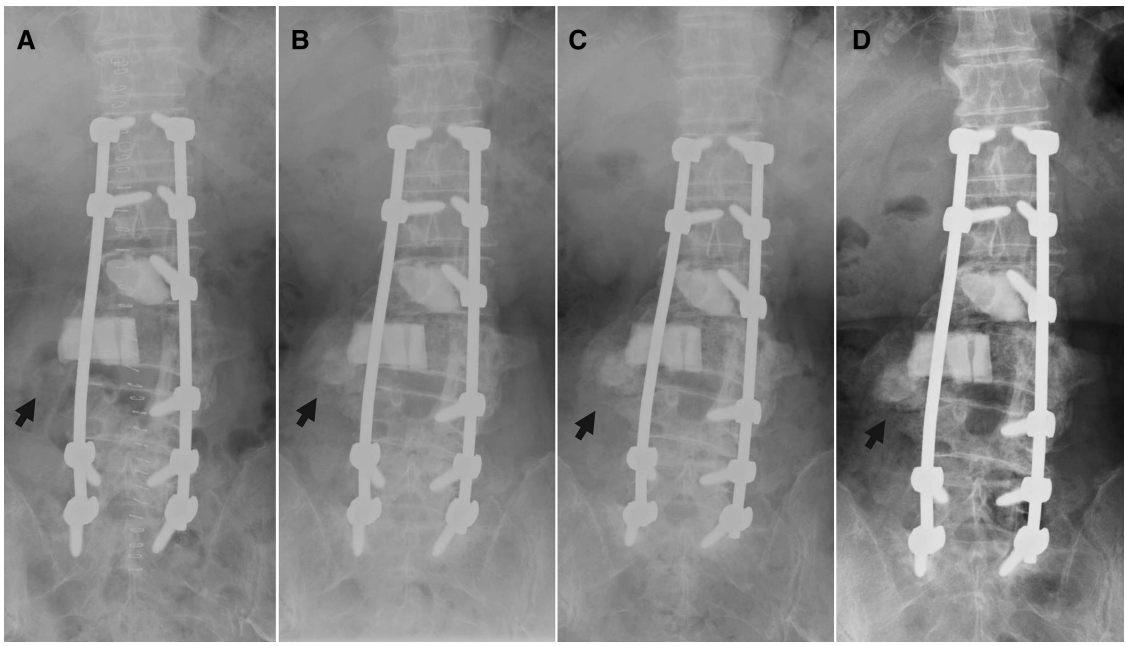

Figure 6. Time-dependent changes in lumbar spinal radiographs after treatment with denosumab, a monoclonal antibody against the RANK ligand (RANKL), of a female patient with giant cell reparative granuloma. Osteosclerotic changes are identified focusing around the right L3 transverse process (arrow). **A**, Pretreatment with denosumab. **B**, 3 months after starting treatment with denosumab. **C**, 6 months after the first treatment with denosumab. **D**, 12 months after the first treatment with denosumab.

deemed unresectable. The patient was treated with monthly dose of denosumab and showed a marked reduction of the tumor, which was subsequently completely removable surgically. These reports led us to believe that denosumab has the potential to not only shrink the tumor but also replace the lesions with new bone tissue, allowing us to speculate that denosumab provides an alternative less morbid treatment strategy for GCTB involving the spine.

Although GCTB and GCRG have been reported to be different entities, both tumors share histological characteristics, such as a stromal population of osteoblastic origin and a distinctive osteoclast-like population of multinucleated giant

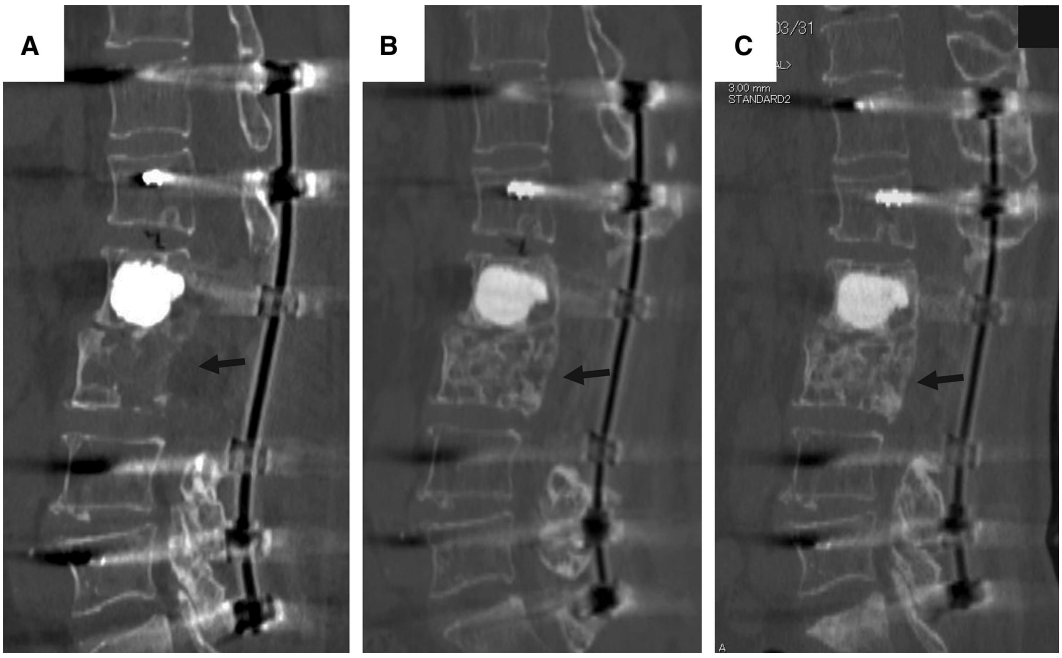

Figure 7. Time-dependent changes in sagittal computed tomographic scans of the lumbar spine after treatment of a female patient with giant cell reparative granuloma with denosumab, a monoclonal antibody against the RANK ligand (RANKL). The sclerotic rim formation that bridges the posterior wall of the L2 and L3 vertebrae is seen (arrow). **A**, Pretreatment with denosumab. **B**, 6 months after the first treatment with denosumab. **C**, 12 months after the first treatment with denosumab.

Copyright © 2015 Wolters Kluwer Health, Inc. Unauthorized reproduction of this article is prohibited.

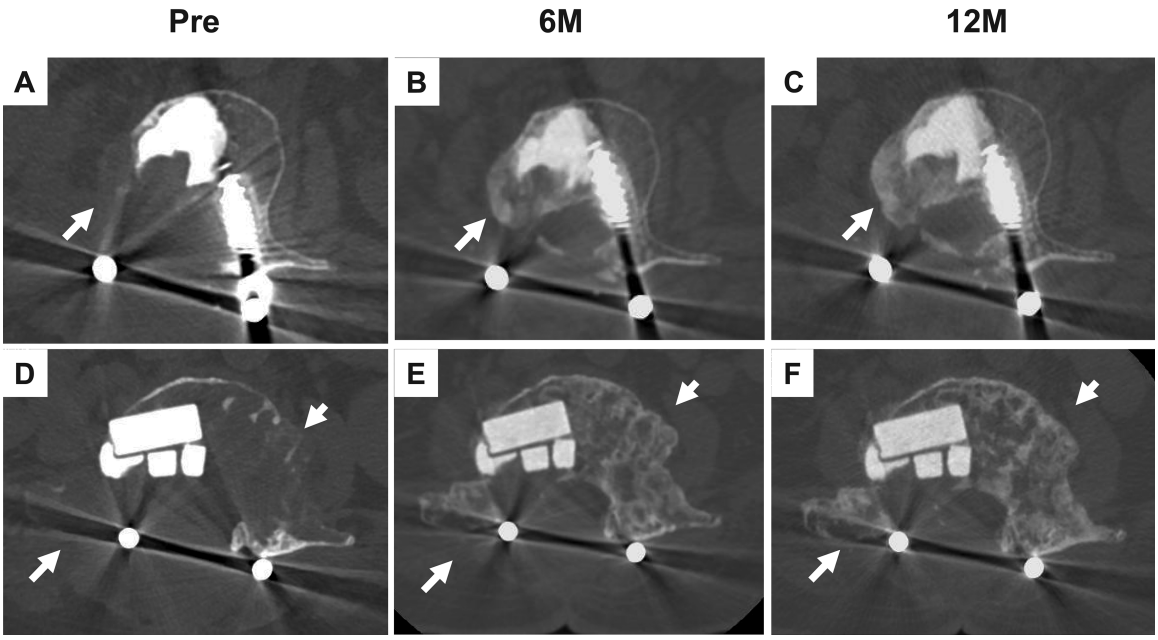

Figure 8. Time-dependent changes in axial CT scans of the lumbar spine after treatment of a female patient with giant cell reparative granuloma with denosumab, a monoclonal antibody against the RANK ligand (RANKL). Progressive bone formation is seen around the hydroxyapatite paste in the L2 vertebra (**A–C**, arrow), and within the L3 vertebra (**D–F**, arrow). A, D, Pretreatment with denosumab (Pre). B, E, 6 months after first treatment with denosumab (6M). C, F, 12 months after first treatment with denosumab (12M). A–C, Axial CT scans of the L2 vertebra. D–F, Axial CT scans of the L3 vertebra. CT indicates computed tomographic.

cells. It was recently reported that the expression of RANKL and OPG was identified in GCRG of the jaw.[6] In the present report, using immunohistochemical analyses, we confirm the expression of RANK in the osteoclast-like giant cells and RANKL in the spindle-shaped mononuclear stromal cells. These results suggest that denosumab may have an antitumor effect on GCRG. Schreuder *et al*[9] recently first reported the effect of denosumab for the patients with GCRG of the maxilla. The CT analysis showed significant regression of the tumor lesion and reformation of the bone cortex during 12 months of treatment, and, histologically, biopsy samples after treatment showed elimination of the giant cells.[9]

Our case is the first in which denosumab was used to treat a patient with unresectable recurrent GCRG of the spine. Follow-up lumbar radiographs show significant osteosclerotic changes in the tumor lesion at 3 months after treatment and thereafter. Follow-up CT scans of L2 and L3 vertebral lesions clearly identify that the osoteolytic lesion was replaced by cortical-like bone, as previously reported.[35] At present, 12 months after initiating treatment with denosumab, the patient remains free from neurological symptoms, including back pain, without apparent complications. However, longer-term effects of denosumab for patients with GCRG and/or GCTB remain unknown. The best treatment period and dosage for long-term administration of denosumab have not been evaluated. Nevertheless, denosumab has the real potential for changing the therapeutic approach to osteoclastic giant cell-rich tumors, such as GCTB and GCRG.

In conclusion, we report the first case of recurrent GCRG of the spine successfully treated with denosumab. Treatment with denosumab induced significant bone formation in the unresectable lumbar lesion, with stable clinical improvement during the 12-month follow-up period with no serious complications. The therapeutic progress of our case suggests that denosumab may be an effective and attractive treatment option for osteoclastic giant cell-rich tumors, including GCRG, notably for patients with unresectable lesions of the spine. Establishing an effective and safe therapeutic protocol for patients with GCRG and/or GCTB would be of great importance in future studies.

Acknowledgment

The authors thank Takahiro Iino for the preparation of histological samples and immunohistochemical analysis.

➢ Key Points

- ❑ A case of recurrent GCRG of the lumbar spine treated with denosumab is reported.
- ❑ Treatment with denosumab induced significant bone formation in the unresectable lumbar lesion and showed stable clinical improvement during the 12-month follow-up period without apparent complications.
- ❑ Denosumab shows promise as a new alternative treatment option for osteoclastic giant cell-rich tumors, such as GCRG, especially for unresectable lesions in the spine.

Copyright © 2015 Wolters Kluwer Health, Inc. Unauthorized reproduction of this article is prohibited.

References

1. Forsyth R, Jundt G, Athanasou N, et al. Osteoclastic giant cell-rich tumours. In: Fletcher C, Bridge JA, Hogendoorn P, et al., eds. *WHO Classification of Tumours of Soft Tissue and Bone*. 4th ed. Lyon, France: International Agency for Research on Cancer; 2013:319–24.
2. Murphey MD, Nomikos GC, Flemming DJ, et al. From the archives of AFIP. Imaging of giant cell tumor and giant cell reparative granuloma of bone: radiologic-pathologic correlation. *Radiographics* 2001;21:1283–309.
3. Wold LE, Dobyns JH, Swee RG, et al. Giant cell reaction (giant cell reparative granuloma) of the small bones of the hands and feet. *Am J Surg Pathol* 1986;10:491–6.
4. Boyle WJ, Simonet WS, Lacey DL. Osteoclast differentiation and activation. *Nature* 2003;423:337–42.
5. Dufresne A, Derbel O, Cassier P, et al. Giant-cell tumor of bone, anti-RANKL therapy. *Bonekey Rep* 2012;1:149.
6. Liu B, Yu SF, Li TJ. Multinucleated giant cells in various forms of giant cell containing lesions of the jaws express features of osteoclasts. *J Oral Pathol Med* 2003;32:367–75.
7. Brown JE, Coleman RE. Denosumab in patients with cancer—a surgical strike against the osteoclast. *Nat Rev Clin Oncol* 2012;9:110–8.
8. Agarwal A, Larsen BT, Buadu LD, et al. Denosumab chemotherapy for recurrent giant-cell tumor of bone: a case report of neoadjuvant use enabling complete surgical resection. *Case Rep Oncol Med* 2013:496351.
9. Schreuder WH, Coumou AW, Kessler PA, et al. Alternative pharmacologic therapy for aggressive central giant cell granuloma: denosumab. *J Oral Maxillofac Surg* 2014;72:1301–9.
10. Jaffe HL. Giant-cell reparative granuloma, traumatic bone cyst, and fibrous (fibro-osseous) dysplasia of the jawbones. *Oral Surg* 1953;6:159–75.
11. Hirschl S, Katz A. Giant cell reparative granuloma outside the jaw bone. Diagnostic criteria and review of the literature with the first case described in the temporal bone. *Hum Pathol* 1974;5:171–81.
12. Bertoni F, Biscaglia R, Bacchini P. Giant cell reparative granuloma of the phalanx of the hand with aggressive radiographic features. *Skeletal Radiol* 1998;27:584–7.
13. Lorenzo JC, Dorfman HD. Giant-cell reparative granuloma of short tubular bones of the hands and feet. *Am J Surg Pathol* 1980;4:551–63.
14. Suzuki M, Satoh T, Nishida J, et al. Solid variant of aneurysmal bone cyst of the cervical spine. *Spine* 2004;29:E376–81.
15. Gonzalez-Martinez E, Santamarta D, Lomas-Garcia J, et al. Giant-cell granuloma of the axis. *J Neurosurg Spine* 2012;16:191–4.
16. Al-Shamy G, Relyea K, Adesina A, et al. Solid variant of aneurysmal bone cyst of the thoracic spine: a case report. *J Med Case Rep* 2011;5:261.
17. Bayar MA, Erdem Y, Gokcek C, et al. Giant cell reparative granuloma of the axis. *Turk Neurosurg* 2009;19:423–7.
18. Inoue H, Tsuneyoshi M, Enjoji M, et al. Giant-cell reparative granuloma of the thoracic vertebra. *Acta Pathol Japn* 1986;36:745–50.
19. Karampalis C, Lenthall R, Boszczyk B. Solid variant of aneurysmal bone cyst on the cervical spine of a child: case report, differential diagnosis and treatment rationale. *Eur Spine J* 2013;22:523–31.
20. Neviaser JS, Eisenberg SH. Giant cell reparative granuloma of the cervical spine; case report. *Bull Hosp Joint Dis* 1954;15:73–8.
21. Oda Y, Tsuneyoshi M, Shinohara N. "Solid" variant of aneurysmal bone cyst (extragnathic giant cell reparative granuloma) in the axial skeleton and long bones. A study of its morphologic spectrum and distinction from allied giant cell lesions. *Cancer* 1992;70:2642–9.
22. Sanerkin NG, Mott MG, Roylance J. An unusual intraosseous lesion with fibroblastic, osteoclastic, osteoblastic, aneurysmal and fibromyxoid elements. "Solid" variant of aneurysmal bone cyst. *Cancer* 1983;51:2278–86.
23. Sato K, Sugiura H, Yamamura S, et al. Solid variant of an aneurysmal bone cyst (giant cell reparative granuloma) of the 3rd lumbar vertebra. *Nagoya J Med Sci* 1996;59:159–65.
24. Vester H, Wegener B, Weiler C, et al. First report of a solid variant of aneurysmal bone cyst in the os sacrum. *Skeletal Radiol* 2010;39:73–7.
25. Dougall WC. Molecular pathways: osteoclast-dependent and osteoclast-independent roles of the RANKL/RANK/OPG pathway in tumorigenesis and metastasis. *Clin Cancer Res* 2012;18:326–35.
26. Bekker PJ, Holloway DL, Rasmussen AS, et al. A single-dose placebo-controlled study of AMG 162, a fully human monoclonal antibody to RANKL, in postmenopausal women. *J Bone Miner Res* 2004;19:1059–66.
27. McClung MR, Lewiecki EM, Cohen SB, et al. Denosumab in postmenopausal women with low bone mineral density. *N Engl J Med* 2006;354:821–31.
28. Fizazi K, Carducci M, Smith M, et al. Denosumab *versus* zoledronic acid for treatment of bone metastases in men with castration-resistant prostate cancer: a randomised, double-blind study. *Lancet* 2011;377:813–22.
29. Henry DH, Costa L, Goldwasser F, et al. Randomized, double-blind study of denosumab *versus* zoledronic acid in the treatment of bone metastases in patients with advanced cancer (excluding breast and prostate cancer) or multiple myeloma. *J Clin Oncol* 2011;29:1125–32.
30. Stopeck AT, Lipton A, Body JJ, et al. Denosumab compared with zoledronic acid for the treatment of bone metastases in patients with advanced breast cancer: a randomized, double-blind study. *J Clin Oncol* 2010;28:5132–9.
31. Thomas D, Carriere P, Jacobs I. Safety of denosumab in giant-cell tumour of bone. *Lancet Oncol* 2010;11:815.
32. Chawla S, Henshaw R, Seeger L, et al. Safety and efficacy of denosumab for adults and skeletally mature adolescents with giant cell tumour of bone: interim analysis of an open-label, parallel-group, phase 2 study. *Lancet Oncol* 2013;14:901–8.
33. Boriani S, Bandiera S, Casadei R, et al. Giant cell tumor of the mobile spine: a review of 49 cases. *Spine* 2012;37:E37–45.
34. Luther N, Bilsky MH, Hartl R. Giant cell tumor of the spine. *Neurosurg Clin N Am* 2008;19:49–55.
35. Mattei TA, Ramos E, Rehman AA, et al. Sustained long-term complete regression of a giant cell tumor of the spine after treatment with denosumab. *Spine J* 2014;14:e15–21.

Copyright © 2015 Wolters Kluwer Health, Inc. Unauthorized reproduction of this article is prohibited.

Copyright of Spine is the property of Lippincott Williams & Wilkins and its content may not be copied or emailed to multiple sites or posted to a listserv without the copyright holder's express written permission. However, users may print, download, or email articles for individual use.