IMPERIAL

Machine Learning for Imaging

Coursework Introduction

Mammographic density prediction

Source: ESR eBook for Undergraduate Education in Radiology

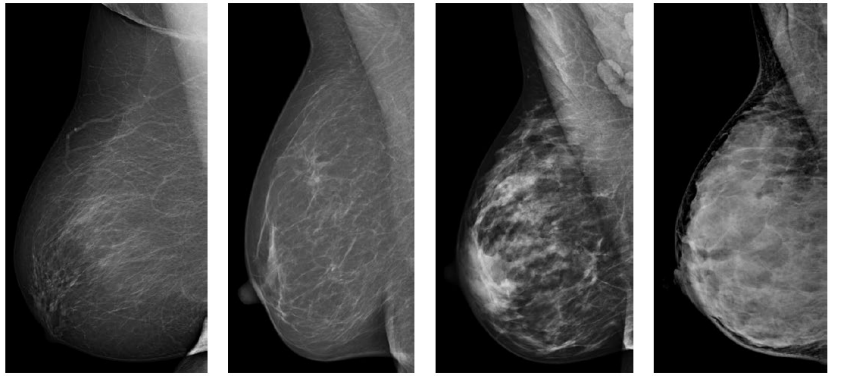

a
The breasts are almost entirely fatty

b
There are scattered areas of fibroglandular density

c
The breasts are heterogeneously dense, which may obscure small masses

d
The breasts are extremely dense, which lowers the sensitivity of Mammography

Breast density – Digital mammograms.

The coursework is divided into five parts:

- **Part A:** Choose a sensible data augmentation pipeline.
- **Part B:** Implement a sensible model for image classification.
- **Part C:** Conduct a subgroup performance analysis.
- **Part D:** Inspect the trained model by analysing feature embeddings.
- **Part E:** Write a short report about your coursework (using the provided template).

Important:

- Read the text descriptions carefully and look out for hints and comments indicating a specific **TASK**.
- Make sure to add sufficient documentation to your code.

Submission:

1. Submit the notebook in `.ipynb` format with *all outputs included*.
   Please name your file `notebook.ipynb`.
2. Submit a short report in `.pdf` format.
   Please name this file `report.pdf`.

Coursework notebook

Available on Scientia

coursework.ipynb

coursework.ipynb > Coursework: Mammographic density prediction > Part D: Inspect the trained model by analysing feature embeddings. > Extrac

Generate | Code | Markdown | Run All | Restart | Clear All Outputs | Jupyter Variables | .venv (3.10.12) (Python 3.10.12)

Coursework: Mammographic density prediction

In this coursework, you will implement a model for breast tissue density prediction from digital screening mammography data. Mammograms are X-ray images acquired as part of regular breast cancer screening programmes. Breast tissue density is an important risk factor and is categorised into four classes according to the BI-RADS (Breast Imaging Reporting and Data System) standard:

- Class A – Almost entirely fatty: The breast is composed mostly of fatty tissue with minimal fibroglandular density.
- Class B – Scattered areas of fibroglandular density: There are some dense areas, but most of the tissue is still fatty.
- Class C – Heterogeneously dense: Many areas of dense tissue are present, which may obscure small masses.
- Class D – Extremely dense: The breast is composed predominantly of dense tissue, making mammographic interpretation and cancer detection more challenging.

Your task is to develop and evaluate a predictive model capable of automatically assigning these density categories from mammographic images. You will be asked to assess the performance of the model across different subgroups, and conduct a model inspection using dimensionality reduction of feature embeddings.

The coursework is divided in the following parts:

- **Part A**: Choose a sensible data augmentation pipeline within the `MammoDataset` class.
- **Part B**: Implement a sensible model for image classification within the `MammoNet` class.
- **Part C**: Conduct a subgroup performance analysis.
- **Part D**: Inspect the trained model by analysing feature embeddings.
- **Part E**: Write a short report about your coursework (using the provided template).

Important: Read the text descriptions carefully and look out for hints and comments indicating a specific **TASK**. Make sure to add sufficient documentation and comments to your code.

Coursework submission

Deadline
Friday, 20 February, 19:00