leads to the **accumulation of secretions**, providing a rich medium for bacterial growth. **Bacterial colonizers** of the upper respiratory tract (eg, *S pneumoniae*, *Haemophilus influenzae*, *Moraxella catarrhalis*) then proliferate in the middle ear secretions. This overgrowth of bacteria and consequent immune response result in AOM.

Suppurative fluid accumulation increases middle ear pressure and causes the tympanic membrane to become inflamed and bulge outward. If the eustachian tube remains obstructed, this increased pressure can rupture the tympanic membrane.

**(Choice A)** Although *Klebsiella pneumoniae* can be a colonizer of the mouth and throat, it is unlikely to cause AOM in otherwise healthy children. Instead, it more often causes respiratory diseases in older, immunosuppressed patients (eg, pneumonia in patients with alcohol overuse).

**(Choice B)** *Moraxella catarrhalis* is also an upper respiratory colonizer that can cause AOM. However, infection with it is less common than with *S pneumoniae*.

**(Choice C)** *Proteus mirabilis* classically causes genitourinary infections; its ability to split urea alkalinizes the urine, increasing the formation of kidney stones.

**(Choice D)** *Pseudomonas aeruginosa* is more commonly implicated in otitis externa than AOM.

**(Choice E)** *Staphylococcus aureus* is typically found as a colonizer of the skin rather than the respiratory tract. Therefore, it is more often implicated in skin and soft tissue infections, including otitis externa.

**Educational objective:**
Acute otitis media usually occurs after a viral upper respiratory infection causes obstruction of the eustachian tube. This obstruction leads to the accumulation of secretions, which encourages bacterial growth. The most common bacterial causes are respiratory colonizers, including *Streptococcus pneumoniae*, *Haemophilus influenzae*, and *Moraxella catarrhalis*.


Scanned with CamScanner

1:49 PM Sun 4 Jun
52%
AA apps.uworld.com



A 3-month-old boy is brought to the office for follow-up due to a unilateral cleft lip and palate. The patient has been doing well feeding with specialized bottle nipples and is gaining weight. As part of his multidisciplinary care, the parents are told that he will need to be monitored for ear infections and hearing loss. This is because the patient most likely has dysfunction of which of the following muscles?

- A. Lateral pterygoid (5%)
- ✓ B. Levator veli palatini (43%)
- C. Orbicularis oris (0%)
- D. Stapedius (44%)
- E. Superior pharyngeal constrictor (5%)

Omitted
Correct answer
B

43%
Answered correctly

05 secs
Time Spent

2023
Version

## Explanation

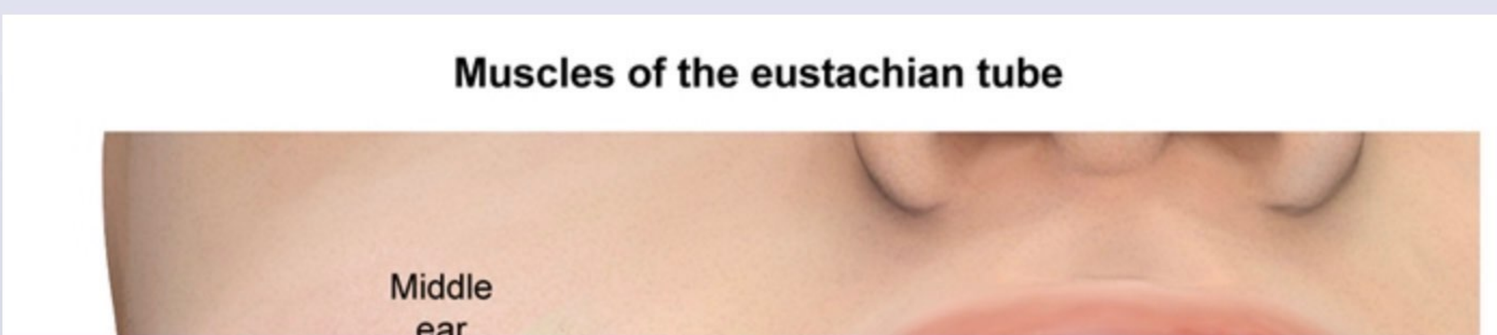




Scanned with CamScanner

1:49 PM Sun 4 Jun
52%
AA apps.uworld.com



**Muscles of the eustachian tube**

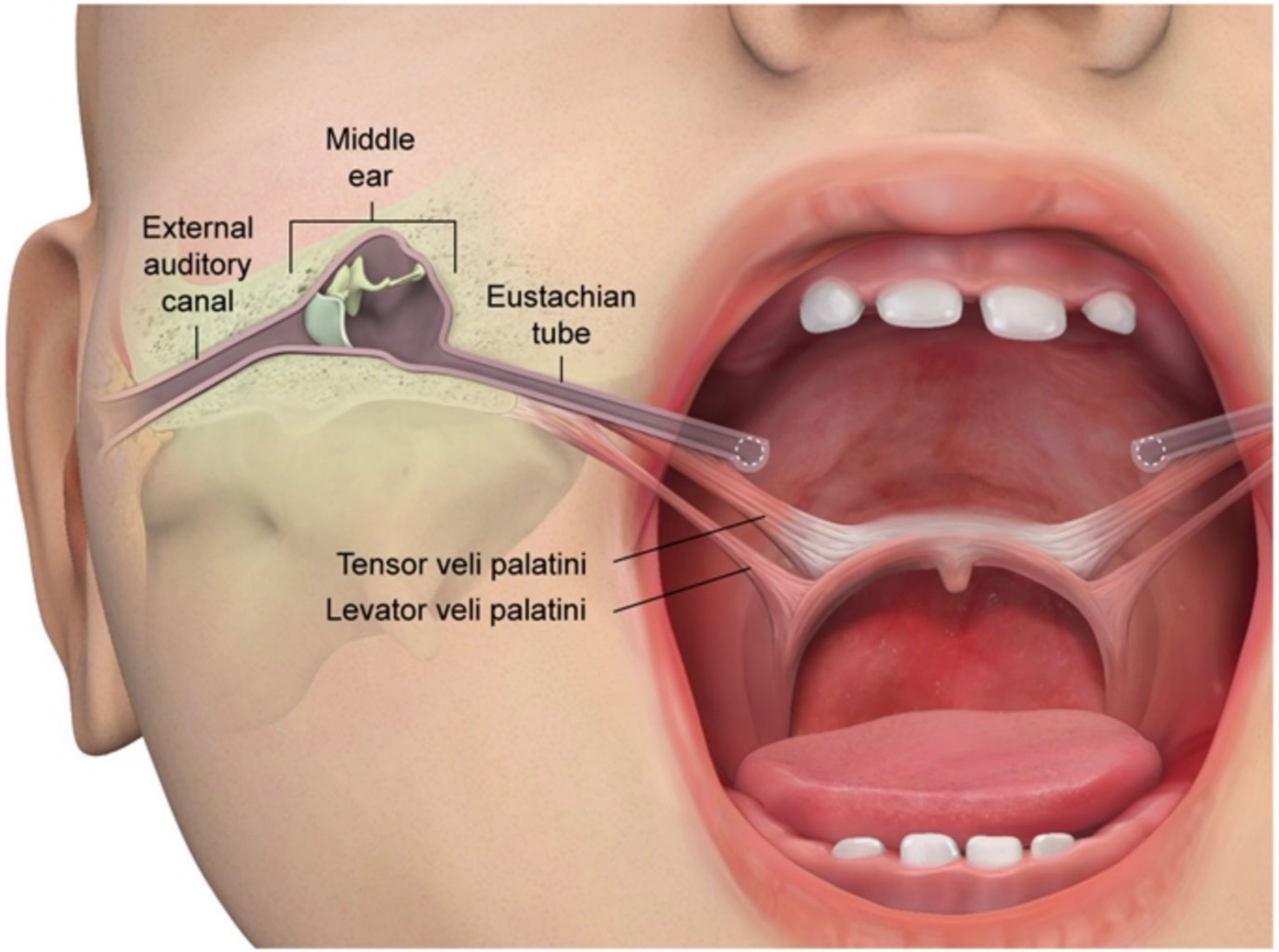


©UWorld

This patient has a **cleft lip and palate**, which can lead to problems with feeding, speech, and orthognathic (ie, jaw) development. Children with cleft palate often have **recurrent otitis media** due to **eustachian tube dysfunction**. The muscles primarily responsible for opening the eustachian tube include the **tensor veli**



Scanned with CamScanner

This patient has a **cleft lip and palate**, which can lead to problems with feeding, speech, and orthognathic (ie, jaw) development. Children with cleft palate often have **recurrent otitis media** due to **eustachian tube dysfunction**. The muscles primarily responsible for opening the eustachian tube include the **tensor veli palatini** and the levator veli palatini.

The **levator veli palatini** arises from the petrous portion of the temporal bone and medial part of the eustachian tube. Its fibers insert into the superior portion of the palatine aponeurosis (soft palate) and interdigitate in the midline with the contralateral muscle fibers. It **elevates the soft palate** during swallowing to prevent food from refluxing into the nasopharynx; contraction also **opens the eustachian tube**. With cleft palate, levator veli palatini insertion is no longer stable, so contraction does not lead to force on the eustachian tube.

**(Choice A)** The lateral pterygoid muscles depress the mandible (ie, open the jaw). They are not impacted in cleft lip or palate.

**(Choice C)** The orbicularis oris encircles the mouth, acting as a sphincter to close the mouth and pucker the lips. In cleft lip, it does not form a complete circle, but inserts into the base of the nose on either side of the cleft; however, it does not impact the function of the eustachian tube.

**(Choice D)** The stapedius muscle is innervated by the facial nerve (CN VII). It arises from the wall of the tympanic cavity and inserts on the neck of the stapes bone. It functions to stabilize the stapes. Contraction causes dampening of sound transmission in response to loud noises. It does not open the eustachian tube.

**(Choice E)** The superior pharyngeal constrictor forms portions of the posterior and lateral oropharyngeal walls. Contraction propels food and liquid inferiorly into the esophagus during swallowing. Together with the levator veli palatini, it elevates the palate to seal the nasal cavity during swallowing. Although both functions are impaired in cleft palate, the superior pharyngeal constrictor does not play a direct role in opening the eustachian tube.

**Educational objective:**


Scanned with CamScanner

The **levator veli palatini** arises from the petrous portion of the temporal bone and medial part of the eustachian tube. Its fibers insert into the superior portion of the palatine aponeurosis (soft palate) and interdigitate in the midline with the contralateral muscle fibers. It **elevates the soft palate** during swallowing to prevent food from refluxing into the nasopharynx; contraction also **opens the eustachian tube**. With cleft palate, levator veli palatini insertion is no longer stable, so contraction does not lead to force on the eustachian tube.

**(Choice A)** The lateral pterygoid muscles depress the mandible (ie, open the jaw). They are not impacted in cleft lip or palate.

**(Choice C)** The orbicularis oris encircles the mouth, acting as a sphincter to close the mouth and pucker the lips. In cleft lip, it does not form a complete circle, but inserts into the base of the nose on either side of the cleft; however, it does not impact the function of the eustachian tube.

**(Choice D)** The stapedius muscle is innervated by the facial nerve (CN VII). It arises from the wall of the tympanic cavity and inserts on the neck of the stapes bone. It functions to stabilize the stapes. Contraction causes dampening of sound transmission in response to loud noises. It does not open the eustachian tube.

**(Choice E)** The superior pharyngeal constrictor forms portions of the posterior and lateral oropharyngeal walls. Contraction propels food and liquid inferiorly into the esophagus during swallowing. Together with the levator veli palatini, it elevates the palate to seal the nasal cavity during swallowing. Although both functions are impaired in cleft palate, the superior pharyngeal constrictor does not play a direct role in opening the eustachian tube.

**Educational objective:**
Patients with cleft palate are at increased risk of chronic or recurrent acute otitis media, partly because of dysfunction of the muscles (eg, levator veli palatini) that contract against the soft palate to open the eustachian tube.


Scanned with CamScanner

A 56-year-old man comes to the office due to feeling "dizzy" over the past 2 weeks. He works in a warehouse and says he experiences a brief, severe spinning sensation when looking up at objects on a high shelf. Vital signs are normal. Examination shows normal hearing. Ocular movements in a sitting position are normal, but when the patient's head is rotated to the right side off the examination table, he develops vertigo and rotatory nystagmus. The remainder of the examination shows no abnormalities. Which of the following is the most likely cause of this patient's symptoms?

- A. Carotid baroreceptor dysfunction (2%)
- B. Elevated endolymphatic hydrostatic pressure (27%)
- C. Elevated hydrostatic pressure in the middle ear (6%)
- ✓ D. Loose semicircular canal debris (61%)
- E. Transient cerebellar hypoperfusion (3%)

Omitted
Correct answer
D

61%
Answered correctly

03 secs
Time Spent

2023
Version

Explanation

**Vestibular anatomy of the inner ear**

Scanned with CamScanner

1:50 PM Sun 4 Jun
52%
AA apps.uworld.com



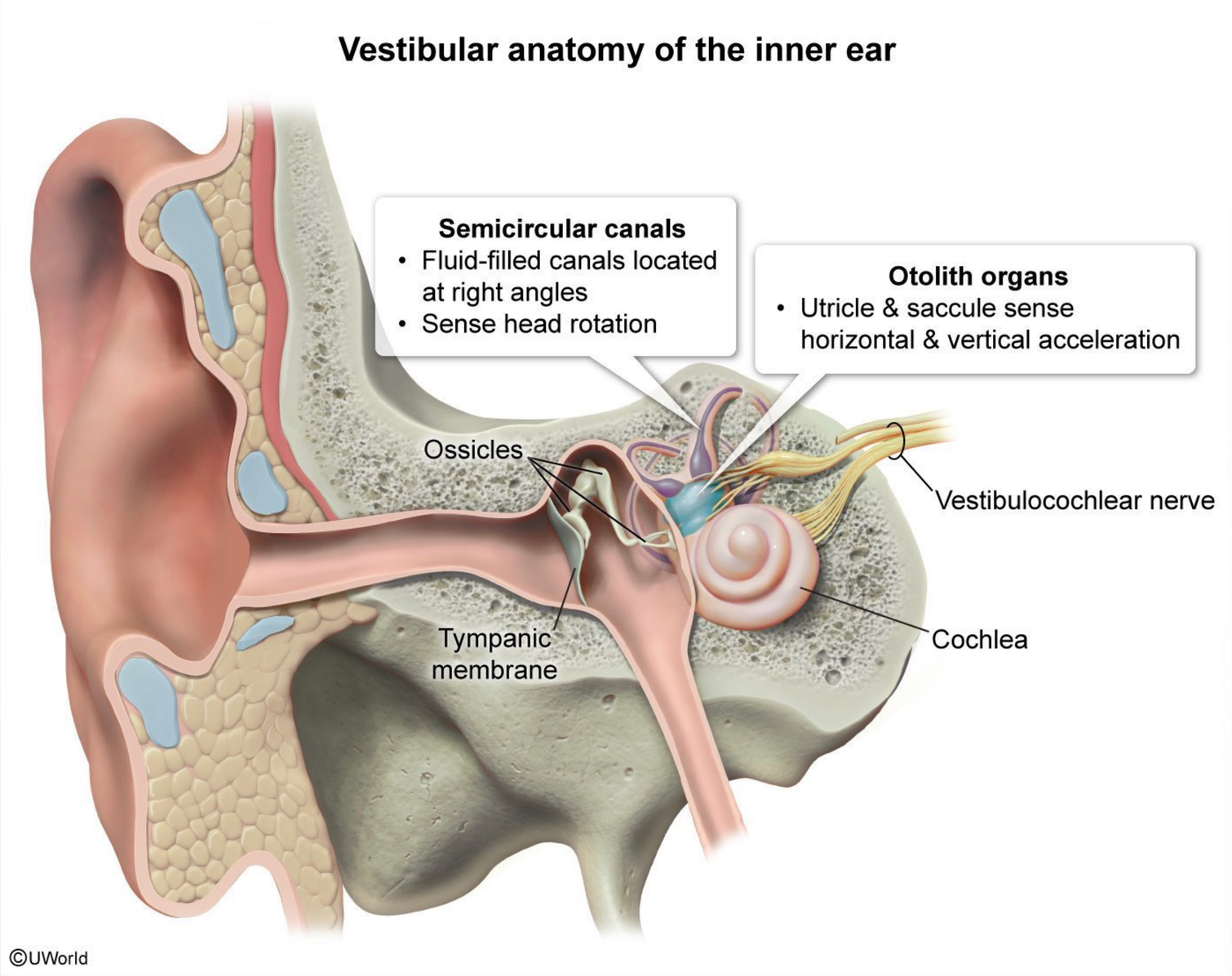


This patient has vertigo, often described as a spinning (as in this patient), whirling, or tilting sensation that can be due to an underlying disease in either the peripheral or central nervous system. This patient's **brief** (<1min), **episodic** vertigo triggered by **head position** changes (eg, sitting up from bed, looking around a kitchen) is



Scanned with CamScanner

This patient has vertigo, often described as a spinning (as in this patient), whirling, or tilting sensation that can be due to an underlying disease in either the peripheral or central nervous system. This patient's **brief** (<1min), **episodic** vertigo triggered by **head position** changes (eg, sitting up from bed, looking around a kitchen) is consistent with **benign paroxysmal positional vertigo** (BPPV), the most common cause of vertigo.

Rotational head movement is sensed by the semicircular canals, which are filled with endolymphatic fluid. The relative movement of this fluid stimulates hair cells that generate electrical impulses which are transmitted to the brain. BPPV is most often attributed to **canalithiasis**, or the presence of crystalline debris (canaliths) in the semicircular canals. These canaliths disrupt the normal flow of fluid in the semicircular canals, leading to contradictory signaling from the corresponding canals.

Diagnosis is based on clinical features. The Dix-Hallpike maneuver can help diagnose BPPV: vertigo and nystagmus are triggered as the patient quickly lies back into a supine position with the head rotated 45 degrees. No further workup is needed in patients with classic presentations. Treatment with **canalith repositioning maneuvers** (eg, Epley) is typically effective.

**(Choices A and E)** Carotid baroreceptor dysfunction can lead to wide fluctuations in blood pressure. Hypoperfusion due to this or other causes (eg, arterial stenosis) can lead to lightheadedness, which is frequently interpreted by patients as dizziness. However, this patient's positive Dix-Hallpike and spinning sensation (vs lightheadedness) are more consistent with BPPV.

**(Choice B)** Elevated endolymphatic pressure in the semicircular canals is thought to underly the development of Ménière disease. In contrast to this patient's presentation, Ménière disease classically presents with episodic vertigo lasting 20 minutes to 24 hours and is associated with unilateral hearing loss, tinnitus, and aural fullness.

**(Choice C)** Infected fluid in the middle ear (ie, acute otitis media) can lead to elevated hydrostatic pressure in the middle ear, causing a bulging tympanic membrane and sometimes leading to tympanic membrane rupture.


Scanned with CamScanner

contradictory signaling from the corresponding canals.

Diagnosis is based on clinical features. The Dix-Hallpike maneuver can help diagnose BPPV: vertigo and nystagmus are triggered as the patient quickly lies back into a supine position with the head rotated 45 degrees. No further workup is needed in patients with classic presentations. Treatment with **canalith repositioning maneuvers** (eg, Epley) is typically effective.

**(Choices A and E)** Carotid baroreceptor dysfunction can lead to wide fluctuations in blood pressure. Hypoperfusion due to this or other causes (eg, arterial stenosis) can lead to lightheadedness, which is frequently interpreted by patients as dizziness. However, this patient's positive Dix-Hallpike and spinning sensation (vs lightheadedness) are more consistent with BPPV.

**(Choice B)** Elevated endolymphatic pressure in the semicircular canals is thought to underly the development of Ménière disease. In contrast to this patient's presentation, Ménière disease classically presents with episodic vertigo lasting 20 minutes to 24 hours and is associated with unilateral hearing loss, tinnitus, and aural fullness.

**(Choice C)** Infected fluid in the middle ear (ie, acute otitis media) can lead to elevated hydrostatic pressure in the middle ear, causing a bulging tympanic membrane and sometimes leading to tympanic membrane rupture. However, acute otitis media presents with pain, fevers, and hearing loss, features absent in this patient.

**Educational objective:**
Benign paroxysmal positional vertigo causes brief (<1 min) episodes of vertigo triggered by changes in head position. Triggering an episode by using provocative head positioning maneuvers (eg, Dix-Hallpike) is diagnostic.

| Pathophysiology | Ear, Nose & Throat (ENT) | Benign paroxysmal positional vertigo |
|---|---|---|
| Subject | System | Topic |


Scanned with CamScanner

A 7-year-old boy is brought to the office for evaluation of a neck mass. A week ago, the patient was taken to an urgent care clinic for nasal congestion and sore throat. The symptoms resolved after a few days, but his parents noticed a persistent neck swelling. The patient has no prior medical conditions and immunizations are up to date. On physical examination, he appears active and playful and is well nourished. Neck examination shows a mildly tender, 2-cm, anterior midline mass that moves upward when the patient swallows. Which of the following is the most likely cause of this patient's lesion?

- A. Abnormal migration of neural crest cells
- B. Cervical implantation of thymic tissue
- C. Dilation of cervical lymphatic channels
- ✓ D. Incomplete obliteration of a duct
- E. Persistence of second branchial cleft structures
- F. Trapping of skin structures along embryonic fusion lines

Omitted
Correct answer
D

Collecting Statistics

01 sec
Time Spent

2023
Version

Explanation

**Thyroglossal duct cyst**



Scanned with CamScanner

1:50 PM Sun 4 Jun
52%
AA apps.uworld.com



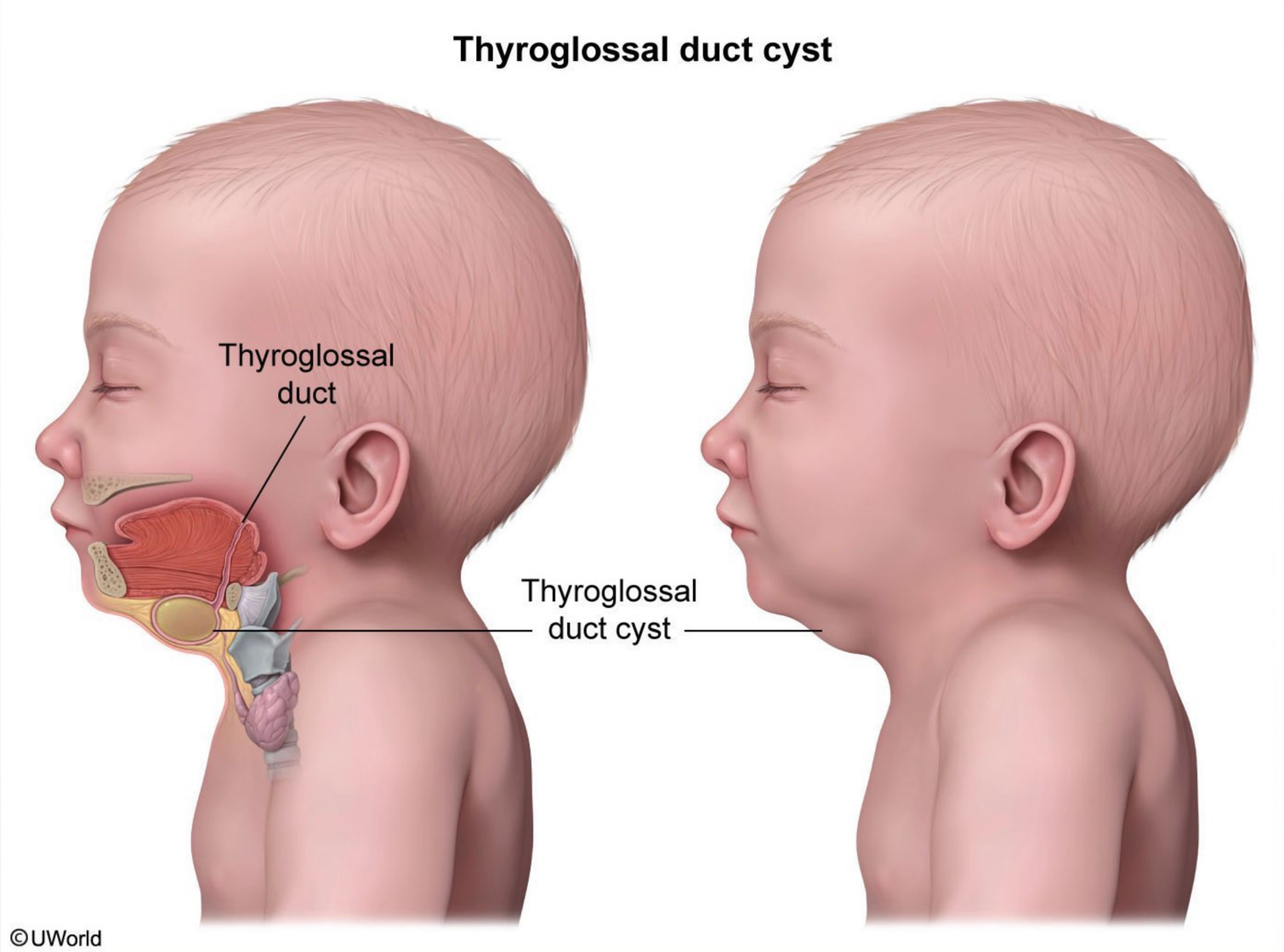


This patient has a **thyroglossal duct cyst** (TDC), which classically presents as a **midline neck mass** that moves superiorly with tongue protrusion or swallowing. A TDC may be identified incidentally during routine examination but is often first noticed when it becomes secondarily infected (eg, erythema, swelling, tenderness) after an upper respiratory infection.



Scanned with CamScanner

In utero, the thyroid gland forms from an outpouching of pharyngeal epithelium at the base of the tongue. It then descends to the base of the anterior neck via the thyroglossal duct, which extends from the foramen cecum at the base of the tongue to the superior border of the isthmus of the thyroid. Normally, the duct then atrophies.

**Failed atrophy** of the thyroglossal duct can result in a TDC from the epithelial remnants within the duct. Because the tract connects to the tongue, **tongue protrusion or swallowing** causes the TDC to **move superiorly**. Ectopic thyroid tissue may also be present and can form anywhere along the duct's path.

**(Choice A)** Abnormal migration of neural crest cells can cause paragangliomas, neuroendocrine tumors that develop from extraadrenal, autonomic paraganglia. They most commonly arise from the carotid body and typically present as a lateral neck mass.

**(Choice B)** Cervical implantation of thymic tissue is a rare cause of cystic neck mass. Ectopic thymic cysts can arise anywhere along the thymus' descent from the angle of the jaw to the mediastinum, but when they form in the neck they are most commonly found on the left side deep to the sternocleidomastoid muscle.

**(Choice C)** Cystic hygromas are fluid-filled sacs of dilated lymphatic vessels that result from abnormal lymphatic development. They present at birth as a soft mass at the posterior or lateral aspects of the neck, not the anterior midline.

**(Choice E)** Branchial cleft cysts are embryologic remnants of branchial cleft structures that often present as a neck mass after becoming secondarily infected. However, they are located laterally (anterior to the sternocleidomastoid muscle), not midline, and do not move with swallowing.

**(Choice F)** Trapped skin structures (eg, hair follicles, sebaceous glands) along embryonic fusion lines result in formation of dermoid cysts within subcutaneous tissue. They may be located in the midline (eg, submental region, neck), but would not rise with swallowing.


Scanned with CamScanner

**(Choice A)** Abnormal migration of neural crest cells can cause paragangliomas, neuroendocrine tumors that develop from extraadrenal, autonomic paraganglia. They most commonly arise from the carotid body and typically present as a lateral neck mass.

**(Choice B)** Cervical implantation of thymic tissue is a rare cause of cystic neck mass. Ectopic thymic cysts can arise anywhere along the thymus' descent from the angle of the jaw to the mediastinum, but when they form in the neck they are most commonly found on the left side deep to the sternocleidomastoid muscle.

**(Choice C)** Cystic hygromas are fluid-filled sacs of dilated lymphatic vessels that result from abnormal lymphatic development. They present at birth as a soft mass at the posterior or lateral aspects of the neck, not the anterior midline.

**(Choice E)** Branchial cleft cysts are embryologic remnants of branchial cleft structures that often present as a neck mass after becoming secondarily infected. However, they are located laterally (anterior to the sternocleidomastoid muscle), not midline, and do not move with swallowing.

**(Choice F)** Trapped skin structures (eg, hair follicles, sebaceous glands) along embryonic fusion lines result in formation of dermoid cysts within subcutaneous tissue. They may be located in the midline (eg, submental region, neck), but would not rise with swallowing.

**Educational objective:**
Failed atrophy of the thyroglossal duct in utero can result in thyroglossal duct cysts that can be located anywhere along the path of thyroid descent (from the tongue base to the thyroid isthmus). They usually present as an anterior midline neck mass that moves superiorly with swallowing or tongue protrusion.

| Embryology | Ear, Nose & Throat (ENT) | Thyroglossal duct cyst |
|---|---|---|
| Subject | System | Topic |

Copyright © UWorld. All rights reserved.



Scanned with CamScanner

A 3-year-old boy is brought to the office due to a 1-day history of fever and irritability. The mother states that the boy has been tugging at his right ear. The patient has had 2 previous episodes of acute otitis media. Temperature is 38.1 C (100.6 F). Otoscopic examination shows a perforated right tympanic membrane with erythema and purulent exudate. Cultures from the exudate yield small, oxidase-positive, gram-negative coccobacilli that grow on factor X– and factor V–supplemented media, consistent with *Haemophilus influenzae*. The patient's immunizations are up to date. Which of the following best explains this patient's susceptibility to the pathogen causing his current infection?

- A. No vaccine is effective against *H influenzae* (2%)
- B. The patient has defective cell-mediated immunity (17%)
- C. The patient has defective neutrophil function (9%)
- ✓ D. The strain responsible for this patient's disease does not produce a capsule (67%)
- E. The strain responsible for this patient's disease produces exotoxin (3%)

Omitted
Correct answer
D

67%
Answered correctly

02 secs
Time Spent

2023
Version

## Explanation

This patient with fever and an inflamed, perforated tympanic membrane with purulent otorrhea has **acute otitis media**. Middle ear infections occur most commonly in young children (age 6 months to 2 years) and are typically


Scanned with CamScanner

This patient with fever and an inflamed, perforated tympanic membrane with purulent otorrhea has **acute otitis media**. Middle ear infections occur most commonly in young children (age 6 months to 2 years) and are typically due to *Streptococcus pneumoniae* or ***Haemophilus influenzae***.

*H influenzae* is a small, oxidase-positive, gram-negative coccobacillus typically classified by the antigens in its polysaccharide capsule. However, there are **multiple strains** of *H influenzae* that **do not produce a capsule**; these **nontypeable** strains are part of the normal upper respiratory tract flora but can also cause acute otitis media, sinusitis, and bronchitis.

Vaccination against *H influenzae* is with the protein-conjugated **Hib vaccine**, which confers immunity only to the more invasive **type b** strain **(Choice A)**. The vaccine is recommended in all children to prevent Hib-associated bacteremia, pneumonia, epiglottitis, and meningitis. In countries with widespread Hib vaccination (eg, United States), most *H influenzae* strains isolated from children with respiratory mucosal infections (including acute otitis media) are nontypeable.

**(Choice B)** The Hib vaccine contains capsular polysaccharide components to induce anticapsular antibodies (humoral immune response). Because the antibody response is weak in children, the vaccine is also conjugated with toxoid protein, which stimulates a helper T-cell response to help activate B-cell antibody formation. A cell-mediated cytotoxic T-cell response is not induced.

**(Choice C)** Poor neutrophil function or a low neutrophil count predisposes to bacterial disease. However, neutrophil dysfunction (eg, chronic granulomatous disease, Chédiak-Higashi syndrome) typically presents with recurrent, severe bacterial infections such as pneumonia and abscesses. Ear infections due to *H influenzae* infection despite immunization with the Hib vaccine are more likely due to infection with a nontypeable strain than defective neutrophils.

**(Choice E)** Exotoxins are secreted by certain bacteria (eg, *Clostridium botulinum*, *Corynebacterium diphtheriae*)


Scanned with CamScanner

bacteremia, pneumonia, epiglottitis, and meningitis. In countries with widespread Hib vaccination (eg, United States), most *H influenzae* strains isolated from children with respiratory mucosal infections (including acute otitis media) are nontypeable.

**(Choice B)** The Hib vaccine contains capsular polysaccharide components to induce anticapsular antibodies (humoral immune response). Because the antibody response is weak in children, the vaccine is also conjugated with toxoid protein, which stimulates a helper T-cell response to help activate B-cell antibody formation. A cell-mediated cytotoxic T-cell response is not induced.

**(Choice C)** Poor neutrophil function or a low neutrophil count predisposes to bacterial disease. However, neutrophil dysfunction (eg, chronic granulomatous disease, Chédiak-Higashi syndrome) typically presents with recurrent, severe bacterial infections such as pneumonia and abscesses. Ear infections due to *H influenzae* infection despite immunization with the Hib vaccine are more likely due to infection with a nontypeable strain than defective neutrophils.

**(Choice E)** Exotoxins are secreted by certain bacteria (eg, *Clostridium botulinum*, *Corynebacterium diphtheriae*) to promote cell death but are not generally produced by any strain of *H influenzae*. The Hib vaccine is directed against capsular polysaccharide, not toxin.

**Educational objective:**
Nontypeable strains of *Haemophilus influenzae* are part of the normal upper respiratory tract flora and are a common cause of acute otitis media, sinusitis, and bronchitis. Because nontypeable strains do not form a polysaccharide capsule, immunity is not conferred by vaccination with the *H influenzae* type b vaccine.

**References**

- Non-capsulated and capsulated Haemophilus influenzae in children with acute otitis media in Venezuela: a prospective epidemiological study.


Scanned with CamScanner

1:50 PM Sun 4 Jun
51%
AA
apps.uworld.com



A 73-year-old woman comes to the physician complaining of progressive, severe pain and discharge from her left ear for the past 2 days. She has had type 2 diabetes for many years and has been noncompliant with her medications and follow-up appointments. On examination, moving or touching the pinna produces extreme pain. Otoscopic examination shows granulation tissue in the left ear canal with a scant amount of discharge. The tympanic membrane is clear, and there is no middle ear effusion. Initial cultures from the ear show a Gram-negative rod. Which of the following microbiological characteristics best describes the infecting organism?

- A. Comma-shaped and grows well in high pH (2%)
- B. Fast lactose fermenter (6%)
- ✓ C. Motile and oxidase positive (42%)
- D. Nonmotile and a lactose nonfermenter (25%)
- E. Requires factors V and X for growth (22%)

Omitted
Correct answer
C

42%
Answered correctly

02 secs
Time Spent

2023
Version

Explanation

| Distinguishing characteristics of *Pseudomonas aeruginosa* infections | |
|---|---|



Scanned with CamScanner

| Distinguishing characteristics of *Pseudomonas aeruginosa* infections | |
|---|---|
| **Types of infections** | • Pneumonia (especially in cystic fibrosis & ventilated patients)<br>• Life threatening infections in neutropenic & burn patients<br>• Otitis externa (particularly malignant)<br>• Hot tub folliculitis<br>• Ecthyma gangrenosum |
| **Microbiology** | • Motile aerobic gram-negative rod<br>• Nonlactose fermenting, oxidase positive<br>• Produces pyocyanin (blue green) pigment<br>• Emits a grape-like fruity odor<br>• Produces endotoxin (fever, shock) & exotoxin A (inactivates EF-2) |
| **Effective antibiotics** | • Aminoglycosides (gentamicin, tobramycin, amikacin)<br>• Antipseudomonal penicillins (ticarcillin, piperacillin)<br>• 3rd & 4th generation cephalosporins (ceftazidime, cefepime)<br>• Quinolones (ciprofloxacin)<br>• Monobactams (aztreonam)<br>• Carbapenems (imipenem, meropenem) |

This patient's presentation is consistent with malignant otitis externa (MOE), a severe infection most commonly seen in elderly diabetic patients. It is most frequently caused by *Pseudomonas aeruginosa*, a nonlactose-fermenting, oxidase-positive, motile Gram-negative rod. Patients typically present with exquisite ear pain and drainage. The granulation tissue seen within the ear canal is an important characteristic finding of MOE, and the


Scanned with CamScanner

This patient's presentation is consistent with malignant otitis externa (MOE), a severe infection most commonly seen in elderly diabetic patients. It is most frequently caused by *Pseudomonas aeruginosa*, a nonlactose-fermenting, oxidase-positive, motile Gram-negative rod. Patients typically present with exquisite ear pain and drainage. The granulation tissue seen within the ear canal is an important characteristic finding of MOE, and the tympanic membrane is usually intact. Progression of this infection can lead to osteomyelitis of the skull base and cranial nerve damage. Treatment consists of systemic antibiotics such as ciprofloxacin that are effective against *P aeruginosa*.

**(Choice A)** *Vibrio cholerae* is an oxidase-positive, Gram-negative, comma-shaped rod that can grow on an alkaline medium that kills most organisms. *V cholerae* causes a toxin-mediated (stimulates adenylyl cyclase) watery diarrhea.

**(Choice B)** Gram-negative rods that are fast lactose fermenters include *Klebsiella* and *Escherichia coli*. They commonly cause urinary tract infections.

**(Choice D)** *Shigella* is a Gram-negative, nonlactose-fermenting, nonmotile, rod-shaped bacterium. It causes shigellosis, a hemorrhagic diarrheal disease.

**(Choice E)** *Haemophilus influenza* is Gram-negative, rod-shaped bacterium that requires factor X (hematin) and factor V (NAD+) for growth. Nontypable (unencapsulated) *H influenzae* is a frequent cause of acute otitis media in children and adults. Acute otitis media is associated with an inflamed, erythematous, bulging, immobile tympanic membrane due to the presence of infected fluid in the middle ear.

**Educational objective:**
*Pseudomonas aeruginosa* is a nonlactose-fermenting, oxidase-positive, motile, Gram-negative rod. It is the most common cause of malignant otitis externa (MOE), a serious infection of the ear seen in elderly diabetic patients. MOE presents with exquisite ear pain and drainage, and granulation tissue is often seen within the ear canal.


Scanned with CamScanner

A 68-year-old man with a long history of using chewing tobacco comes to the office for follow up of squamous cell carcinoma (SCC) of the oral cavity. A month ago, the patient was diagnosed with SCC of the left lateral tongue. He underwent resection, the surgical specimen showed clear margins, and he started additional treatment. The patient recently noticed a second ulcerative lesion on the right lateral tongue. Biopsy is performed and it also shows SCC. The second tumor most likely arose from which of the following mechanisms?

- A. Chemotherapy-induced malignancy (3%)
- ✓ B. Field cancerization (57%)
- C. Hematogenous spread (9%)
- D. Immunologic privilege (3%)
- E. Impaired wound healing (1%)
- F. Lymphatic spread (23%)

Omitted
Correct answer
B

57%
Answered correctly

01 sec
Time Spent

2023
Version

## Explanation

This patient with mucosal head and neck squamous cell carcinoma (HNSCC) has developed a second primary tumor, which is common with HNSCC due to **field cancerization**.



Scanned with CamScanner

This patient with mucosal head and neck squamous cell carcinoma (HNSCC) has developed a second primary tumor, which is common with HNSCC due to **field cancerization**.

Field cancerization describes a large area of cells within a field (eg, upper aerodigestive tract) that are "primed" to develop cancer because of **widespread exposure to mutagens** (eg, tobacco). Mutations that affect many similar cells can increase the likelihood of developing multiple primary malignancies, analogous to germline mutations in tumor suppressor genes (eg, *BRCA1* or *BRCA2* in breast and ovarian cancer). Field cancerization likely underlies the development of many common cancers, including:

- HNSCC due to mucosal exposure to tobacco carcinogens
- Basal cell carcinoma of the skin due to skin exposure to ultraviolet light
- Colorectal carcinoma due to epithelial exposure to dietary carcinogens

Even with adequate treatment of a malignancy, the areas affected by field cancerization remain at higher risk of developing **multiple primary malignancies**, as seen in this patient. Therefore, patients diagnosed with any of these cancers require comprehensive evaluation and continued surveillance of the at-risk area (eg, colonoscopy, comprehensive skin examination, panendoscopy of the upper aerodigestive tract).

**(Choice A)** Chemotherapy can induce secondary malignancies, most commonly leukemia and lymphoma, in cancer survivors. In contrast to the tumors in this patient, secondary malignancies are seen years or even decades later.

**(Choices C and F)** Most carcinomas, including HNSCC, spread via the lymphatic system, leading to metastases in the regional (eg, ipsilateral anterior neck) lymph nodes. However, it is unlikely for the carcinoma to spread back up to a contralateral epithelial site. Hematogenous spread is less common with carcinomas and typically results in metastases to distant sites.


Scanned with CamScanner

- Basal cell carcinoma of the skin due to skin exposure to ultraviolet light
- Colorectal carcinoma due to epithelial exposure to dietary carcinogens

Even with adequate treatment of a malignancy, the areas affected by field cancerization remain at higher risk of developing **multiple primary malignancies**, as seen in this patient. Therefore, patients diagnosed with any of these cancers require comprehensive evaluation and continued surveillance of the at-risk area (eg, colonoscopy, comprehensive skin examination, panendoscopy of the upper aerodigestive tract).

**(Choice A)** Chemotherapy can induce secondary malignancies, most commonly leukemia and lymphoma, in cancer survivors. In contrast to the tumors in this patient, secondary malignancies are seen years or even decades later.

**(Choices C and F)** Most carcinomas, including HNSCC, spread via the lymphatic system, leading to metastases in the regional (eg, ipsilateral anterior neck) lymph nodes. However, it is unlikely for the carcinoma to spread back up to a contralateral epithelial site. Hematogenous spread is less common with carcinomas and typically results in metastases to distant sites.

**(Choice D)** Certain anatomic sites (eg, eyes, testes) display inherent immune privilege, in which foreign grafts or cancers that would otherwise induce immunologic rejection are tolerated. Cancers may establish local sites of immune privilege to evade destruction, but this does not cause new tumor formation.

**(Choice E)** Cancer treatment (eg, chemotherapy, radiation therapy) can result in impaired wound healing, which can result in acutely ulcerative oral lesions due to mucositis. However, these lesions would not be malignant.

**Educational objective:**
Field cancerization can occur when a large area of cells is exposed to carcinogens that induce mutations, leading to a higher risk of forming cancers.


Scanned with CamScanner

A 26-year-old woman comes to the office due to pain in her right jaw that is deep, achy, and worse in the morning. It radiates to her temple and is associated with headaches. The patient also has neck pain and stiffness, especially on the right side. When she chews, she hears a clicking noise in her right ear. The patient is in a competitive graduate study program and has been under significant stress. Her roommate says that she has been grinding her teeth at night. Physical examination will likely reveal spasms of which of the following muscles?

- A. Buccinator (6%)
- B. Levator veli palatini (2%)
- ✓ C. Masseter (89%)
- D. Mylohyoid (1%)
- E. Omohyoid (0%)

Omitted
Correct answer
C

89%
Answered correctly

01 sec
Time Spent

2023
Version

## Explanation

This patient has jaw pain, a clicking noise when she chews, and associated headaches and neck stiffness, which is suggestive of **temporomandibular joint (TMJ) syndrome**. The underlying etiology of TMJ syndrome is multifactorial and includes TMJ derangement (eg, jaw misalignment, trauma), and hypersensitivity of the


Scanned with CamScanner

multifactorial and includes TMJ derangement (eg, jaw misalignment, trauma), and hypersensitivity of the mandibular nerve (CN V3). **Mechanical derangement** of the TMJ can result in irritation and hypersensitivity of CN V3, leading to pathologic contraction of the **masseter** and **pterygoid** muscles (which worsens jaw pain and dysfunction). **Spasms** of these muscles can sometimes be palpated along the mandibular ramus.

Repetitive jaw motions (eg, gum chewing, teeth grinding) are thought to contribute to the development of TMJ syndrome due to increased workload and strain on the joint. Similar to some other musculoskeletal pain disorders (eg, tension headache), TMJ pain also seems to be related to psychiatric conditions and emotional distress.

**(Choice A)** The buccinator muscle underlies the cheek and holds it close to the teeth to control the food bolus when chewing. It is innervated by a branch of the facial nerve (CN VII).

**(Choice B)** The levator veli palatini elevates the soft palate during swallowing to prevent food from refluxing into the nasopharynx. It is innervated by the pharyngeal branch of the vagus nerve (CN X).

**(Choice D)** The mylohyoid runs from the mandible to the hyoid bone, forming the floor of mouth. Although it is innervated by a branch of CN V3, it does not help close the jaw. It acts during swallowing to elevate the tongue and hyoid bone, which propels the food bolus into the posterior oral cavity and oropharynx.

**(Choice E)** The omohyoid muscle travels from the hyoid bone to the clavicle and helps depress the hyoid during speech or swallowing. It is innervated by the ansa cervicalis, a branch of the cervical plexus.

**Educational objective:**
Temporomandibular joint disorder is associated with dysfunction of the temporomandibular joint and hypersensitivity of the mandibular nerve (CN V3). This can result in pathologic contraction of the muscles of mastication, including the masseter and pterygoids.


Scanned with CamScanner

A newborn girl is evaluated in the neonatal intensive care unit for difficulty breathing. The patient was born at term via spontaneous vaginal delivery. Since birth, she has had difficulty breathing with loud snoring sounds and intermittent oxygen desaturations. She has been unable to breastfeed due to her breathing problems. Breathing improves significantly when the patient is placed in a prone position. On examination, there is a small mandible, posteriorly displaced tongue, and U-shaped cleft palate. The abnormalities described represent an example of which of the following?

- A. Association (6%)
- B. Disruption (15%)
- C. Imprinting (1%)
- ✓ D. Sequence (35%)
- E. Syndrome (41%)

Omitted
Correct answer
D

35%
Answered correctly

02 secs
Time Spent

2023
Version

## Explanation

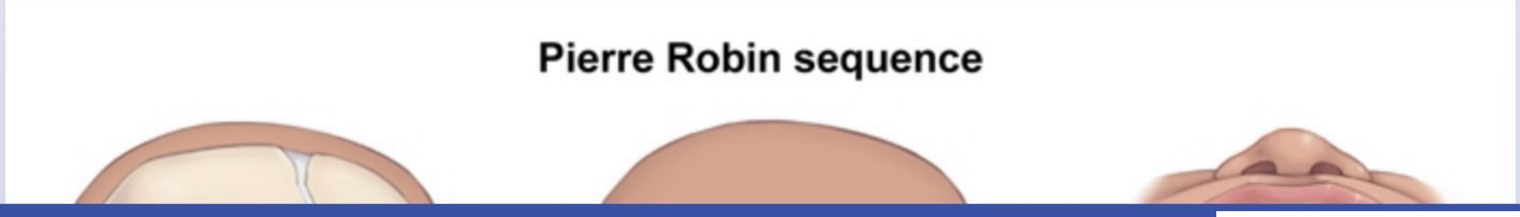




Scanned with CamScanner

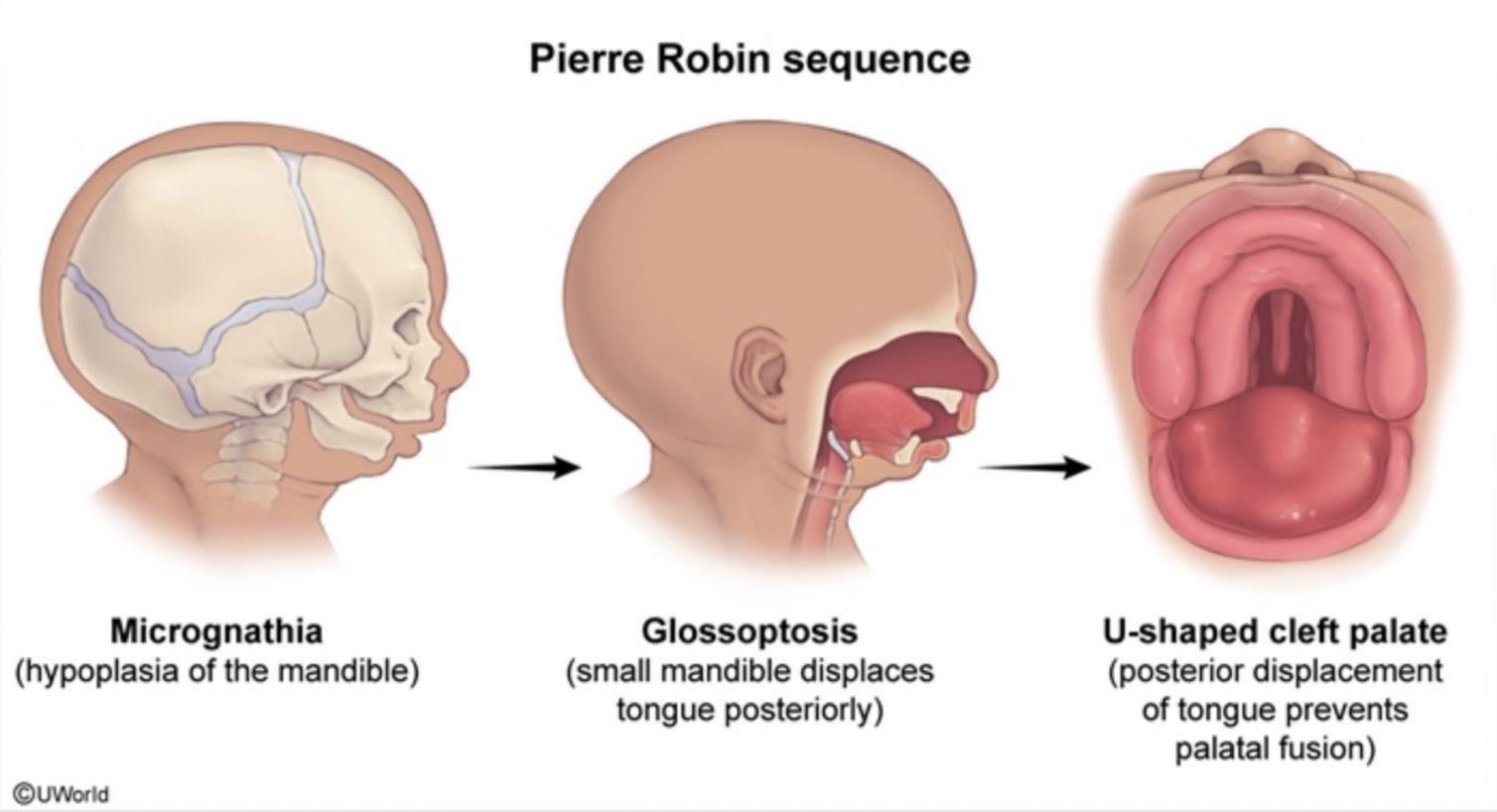


This patient has a small mandible, posteriorly displaced tongue, and U-shaped cleft palate, which is consistent with **Pierre Robin sequence**. A sequence occurs when a **single developmental defect** causes a **cascade of additional malformations**.

In Pierre Robin sequence, hypoplasia of the mandibular prominence leads to **micrognathia**. Severe micrognathia causes posterior displacement of the tongue **(glossoptosis)**, which blocks fusion of the palatine shelves, resulting in a **cleft palate** that is characteristically U-shaped. Difficulty breathing occurs because the tongue prolapses into the posterior oropharynx, blocking airflow. Breathing improves when the patient is in a prone position because gravity pulls the tongue anteriorly, opening the airway.

**(Choice A)** An association is a collection of malformations that are often seen together and do not have a


Scanned with CamScanner

tongue prolapses into the posterior oropharynx, blocking airflow. Breathing improves when the patient is in a prone position because gravity pulls the tongue anteriorly, opening the airway.

**(Choice A)** An association is a collection of malformations that are often seen together and do not have a known, common cause (eg, VACTERL association).

**(Choice B)** A disruption occurs when an external insult (rather than a genetic defect) interrupts and arrests normal fetal development (eg, when an amniotic band disrupts limb development). No specific external insult has been linked to Pierre Robin sequence, and most cases result from genetic abnormalities.

**(Choice C)** Genomic imprinting is a normal process that refers to selective activation of gene expression depending on the parent of origin. Aberrant imprinting occurs with uniparental disomy (ie, when a person receives 2 copies of a chromosome from the same parent and no copy from the other parent). Prader-Willi syndrome and Angelman syndrome (15q) are examples of conditions caused by dysfunctional imprinting.

**(Choice E)** A syndrome is a collection of malformations that have a common cause but are not related anatomically. For example, upslanting palpebral fissures, atrioventricular canal defect, and single palmar crease are all due to trisomy 21.

**Educational objective:**
Pierre Robin is characterized as a sequence because the primary defect (hypoplasia of the mandibular prominence) leads to a cascade of further malformations (ie, micrognathia, posteriorly displaced tongue, U-shaped cleft palate).

| Embryology | Ear, Nose & Throat (ENT) | Craniofacial anomalies |
|---|---|---|
| Subject | System | Topic |

Copyright © UWorld. All rights reserved.



Scanned with CamScanner

A 25-year-old woman comes to the office due to right ear pain that has worsened over the past 2 months. The pain is dull and constant and waxes and wanes. It is worse when she chews hard foods such as steak or almonds. In addition to ear pain, her ear feels stuffy and has some ringing. The patient grinds her teeth at night and previously wore a dental guard, but it broke several months ago. Ear examination is normal. Which of the following nerves is most likely responsible for this patient's ear pain?

- A. Glossopharyngeal (6%)
- B. Hypoglossal (0%)
- ✓ C. Trigeminal (75%)
- D. Vagus (4%)
- E. Vestibulocochlear (12%)

Omitted
Correct answer
C

75%
Answered correctly

13 secs
Time Spent

2023
Version

## Explanation

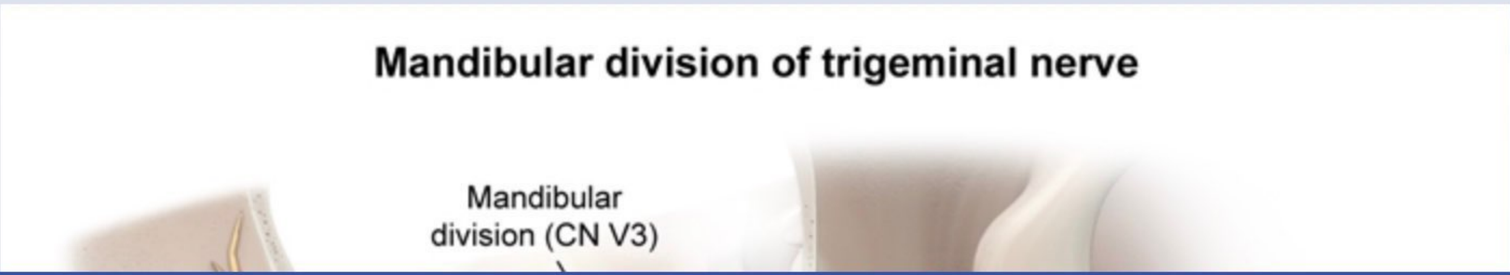




Scanned with CamScanner

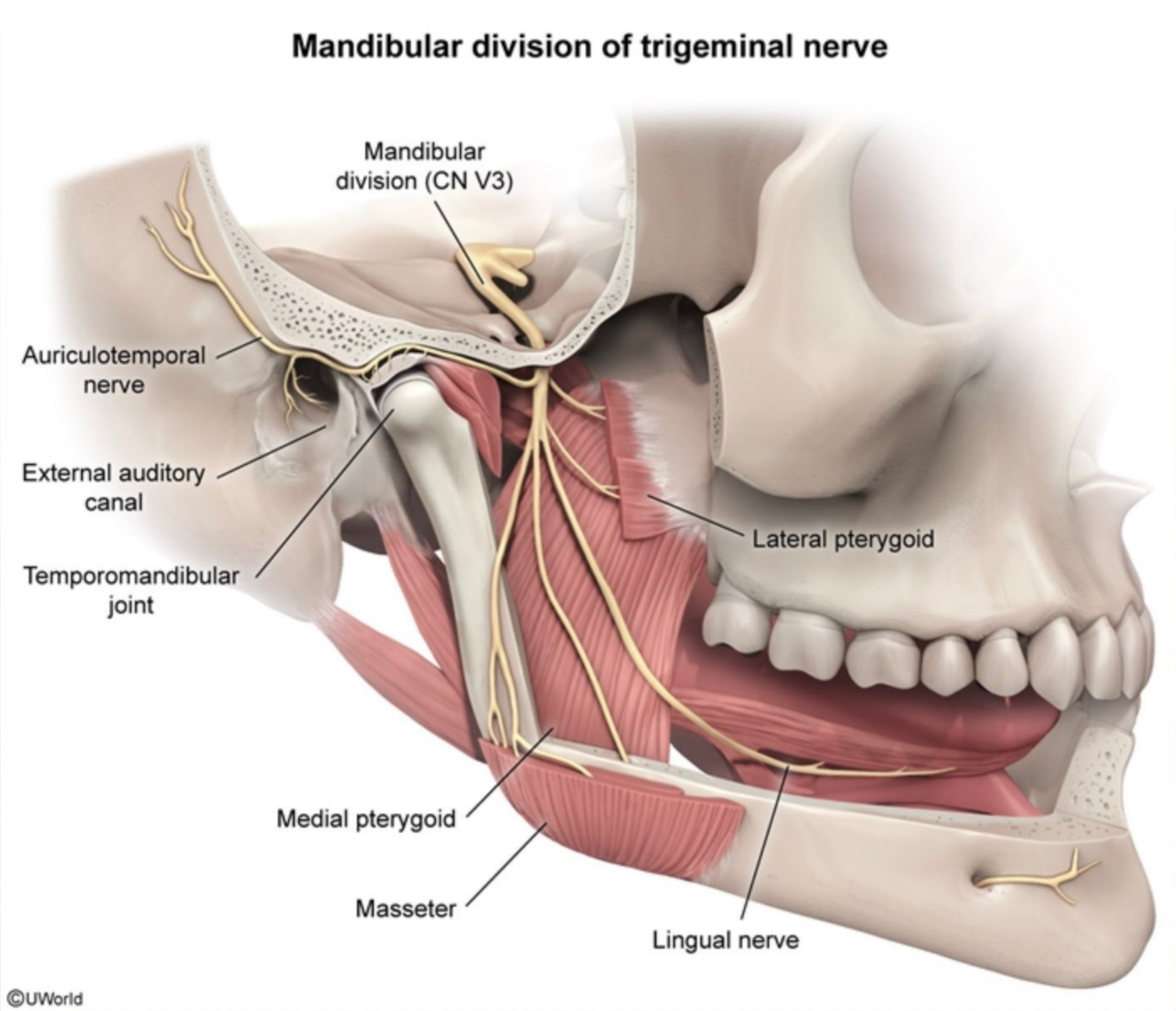


This patient's presentation is most consistent with **temporomandibular joint disorder** (TMD). The underlying etiology of TMD is multifactorial and includes temporomandibular joint derangement (eg, jaw misalignment, jaw


Scanned with CamScanner

This patient's presentation is most consistent with **temporomandibular joint disorder** (TMD). The underlying etiology of TMD is multifactorial and includes temporomandibular joint derangement (eg, jaw misalignment, jaw clenching/teeth grinding, trauma) and hypersensitivity of the mandibular nerve (CN V3). In addition to the classic symptoms of dull, waxing-and-waning face/jaw pain (worse with chewing) and clicking/popping noises with jaw movement, TMD can also present with ear-related symptoms (eg, ear pain, ear stuffiness, tinnitus).

Many of these clinical findings are due to involvement of the **mandibular nerve** (CN V3), which is the largest branch of the **trigeminal nerve**. It supplies sensation to the temporomandibular joint, floor of mouth, anterior tongue, and lower part of the face. In addition, it contributes to the sensory innervation of the **external auditory canal**; therefore, TMD can present with **ear pain** that is **referred** from the jaw joint. Ear stuffiness may be related to hypersensitivity affecting the tensor tympani. Theories regarding tinnitus in TMD include the proximity of the muscles of mastication to the ear and central connections between nerve supply of the temporomandibular joint and the areas of the brain involved in hearing.

**(Choice A)** The sensory component of the glossopharyngeal nerve (CN IX) carries general sensory information from the tonsils, pharynx, middle ear, and posterior third of the tongue; special sensory information (taste) from the posterior third of the tongue; and visceral sensory information from the carotid bodies and carotid sinus.

**(Choice B)** The hypoglossal nerve (CN XII) carries general motor efferent information to the intrinsic and extrinsic muscles of the tongue.

**(Choice D)** The auricular branch of the vagus nerve (CN X) conveys sensory information from the external auditory canal but is not thought to be involved in the pathogenesis of TMD.

**(Choice E)** The vestibulocochlear nerve (CN VIII) carries only special sensory information (auditory and balance) from the inner ear.

**Educational objective:**


Scanned with CamScanner

Many of these clinical findings are due to involvement of the **mandibular nerve** (CN V3), which is the largest branch of the **trigeminal nerve**. It supplies sensation to the temporomandibular joint, floor of mouth, anterior tongue, and lower part of the face. In addition, it contributes to the sensory innervation of the **external auditory canal**; therefore, TMD can present with **ear pain** that is **referred** from the jaw joint. Ear stuffiness may be related to hypersensitivity affecting the tensor tympani. Theories regarding tinnitus in TMD include the proximity of the muscles of mastication to the ear and central connections between nerve supply of the temporomandibular joint and the areas of the brain involved in hearing.

**(Choice A)** The sensory component of the glossopharyngeal nerve (CN IX) carries general sensory information from the tonsils, pharynx, middle ear, and posterior third of the tongue; special sensory information (taste) from the posterior third of the tongue; and visceral sensory information from the carotid bodies and carotid sinus.

**(Choice B)** The hypoglossal nerve (CN XII) carries general motor efferent information to the intrinsic and extrinsic muscles of the tongue.

**(Choice D)** The auricular branch of the vagus nerve (CN X) conveys sensory information from the external auditory canal but is not thought to be involved in the pathogenesis of TMD.

**(Choice E)** The vestibulocochlear nerve (CN VIII) carries only special sensory information (auditory and balance) from the inner ear.

**Educational objective:**
Temporomandibular joint disorder is associated with derangement of the temporomandibular joint and hypersensitivity of the mandibular nerve (CN V3).

**References**

- Temporomandibular disorder: otologic implications and its relationship to sleep bruxism.


Scanned with CamScanner

1:51 PM Sun 4 Jun
51%
AA apps.uworld.com



A 44-year-old man comes to the office for evaluation of a neck lump. The patient first noticed the lump 6 months ago while he was shaving and says that it seems to be growing in size. He has no pain, shortness of breath, cough, hoarseness, or difficulty swallowing. The patient had Hodgkin lymphoma 20 years ago, which was successfully treated with radiation therapy to his chest and neck. Physical examination shows a firm mass in the left thyroid lobe. There is no lymphadenopathy. Serum TSH level is normal. Fine-needle aspiration biopsy reveals papillary thyroid cancer. A total thyroidectomy is performed. During an attempt to ligate the inferior thyroid artery, a nervous structure in close proximity is inadvertently damaged. Which of the following was most likely injured during the surgery?

- A. Accessory nerve (0%)
- B. Ansa cervicalis (2%)
- C. Hypoglossal nerve (0%)
- D. Phrenic nerve (1%)
- ✓ E. Recurrent laryngeal nerve (81%)
- F. Superior cervical ganglion (0%)
- G. Superior laryngeal nerve (13%)

Omitted
Correct answer
E

81%
Answered correctly

02 secs
Time Spent

2023
Version

Explanation



Scanned with CamScanner

1:52 PM Sun 4 Jun
51%
AA apps.uworld.com



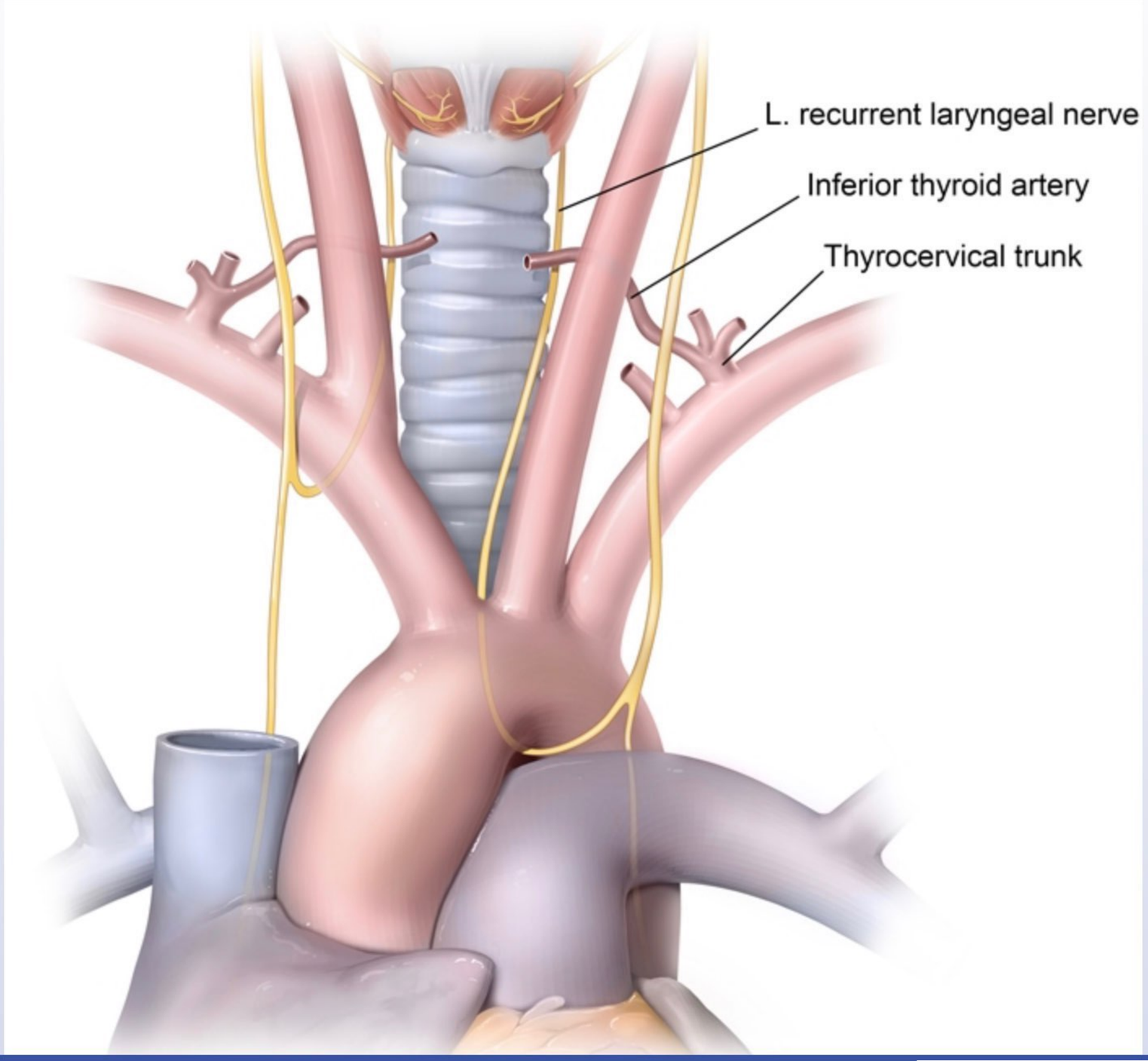




Scanned with CamScanner

The **inferior thyroid artery** arises from the thyrocervical trunk, a branch of the subclavian artery. Along with the superior thyroid arteries (branches of the external carotid arteries), the inferior thyroid arteries provide blood to the thyroid gland and other structures of the anterior neck. From the thyrocervical trunk, the inferior thyroid artery courses deep to the internal jugular vein, vagus nerve, and common carotid artery before turning toward the thyroid. As it approaches the thyroid, the artery comes in **close proximity** to the **recurrent laryngeal nerve**.

The recurrent laryngeal nerve is a branch of the vagus nerve that loops below the aortic arch on the left and below the subclavian artery on the right to provide motor innervation to the intrinsic muscles of the larynx (except the cricothyroid). During **thyroid surgery**, this nerve may be **damaged** due to its proximity to the inferior thyroid artery. Unilateral nerve injury often causes **hoarseness**, whereas bilateral injury may cause inspiratory stridor and respiratory distress due to complete **vocal cord paralysis**.

**(Choice A)** The spinal accessory nerve (CN XI) exits the jugular foramen and courses on top of the levator scapulae muscle to innervate the sternocleidomastoid and trapezius muscles on either side.

**(Choice B)** The ansa cervicalis is a loop of the cervical plexus that receives contributions from C1-C3. It courses deep to the sternocleidomastoid muscle and loops around the internal jugular vein. Branches from the ansa cervicalis innervate the sternohyoid, sternothyroid, and omohyoid muscles.

**(Choice C)** The hypoglossal nerve (CN XII) exits the cranium through the hypoglossal canal and innervates all the muscles of the tongue except the palatoglossus.

**(Choice D)** The phrenic nerve arises from the C3-C5 cervical nerves and innervates the diaphragm. The most common cause of iatrogenic phrenic nerve injury is cardiothoracic surgery, in which the nerve can be damaged where it passes between the pericardium and mediastinal pleura. Manifestations include diaphragmatic paralysis (inspiratory weakness).

**(Choice E)** The superior cervical ganglion is part of the sympathetic nervous system. It can be injured by an


Scanned with CamScanner

scapulae muscle to innervate the sternocleidomastoid and trapezius muscles on either side.

**(Choice B)** The ansa cervicalis is a loop of the cervical plexus that receives contributions from C1-C3. It courses deep to the sternocleidomastoid muscle and loops around the internal jugular vein. Branches from the ansa cervicalis innervate the sternohyoid, sternothyroid, and omohyoid muscles.

**(Choice C)** The hypoglossal nerve (CN XII) exits the cranium through the hypoglossal canal and innervates all the muscles of the tongue except the palatoglossus.

**(Choice D)** The phrenic nerve arises from the C3-C5 cervical nerves and innervates the diaphragm. The most common cause of iatrogenic phrenic nerve injury is cardiothoracic surgery, in which the nerve can be damaged where it passes between the pericardium and mediastinal pleura. Manifestations include diaphragmatic paralysis (inspiratory weakness).

**(Choice F)** The superior cervical ganglion is part of the sympathetic nervous system. It can be injured by an expanding lung cancer at the superior pulmonary sulcus (Pancoast tumor), leading to Horner syndrome (ie, ipsilateral ptosis, miosis, and anhydrosis).

**(Choice G)** The superior laryngeal nerve branches off the vagus nerve high in the neck and divides into an external branch, which supplies the cricothyroid muscle, and an internal branch, which provides sensation over the supraglottic area. The external branch of this nerve may be misligated during thyroid surgery due to its proximity to the superior thyroid artery.

**Educational objective:**
The recurrent laryngeal nerve travels in close proximity to the inferior thyroid artery and can be injured during thyroid surgery, resulting in vocal cord paralysis (eg, hoarseness).

**References**

- Anatomical relationship between recurrent laryngeal nerve and inferior thyroid artery in thyroidectomy


Scanned with CamScanner

A 65-year-old man comes to the office with a 4-month history of persistent left ear pain that is slowly worsening. He is also having some difficulty swallowing. The patient has no chronic medical conditions but has smoked 1 pack of cigarettes per day for the last 46 years. On examination, the external auditory canal is patent and the tympanic membrane is clear with no middle ear effusion. There is an enlarged lymph node in the left anterior neck. Flexible fiberoptic laryngoscopy reveals an ulcerative mass on the posterior pharyngeal wall of the hypopharynx. Involvement of which of the following nerves is most likely responsible for this patient's ear pain?

- A. Trigeminal nerve (11%)
- B. Facial nerve (13%)
- C. Vestibulocochlear nerve (2%)
- ✓ D. Vagus nerve (57%)
- E. Hypoglossal nerve (5%)
- F. Great auricular nerve (9%)

Omitted
Correct answer
D

57%
Answered correctly

09 secs
Time Spent

2023
Version

Explanation

**Referred otalgia**



Scanned with CamScanner

1:52 PM Sun 4 Jun
51%
AA apps.uworld.com



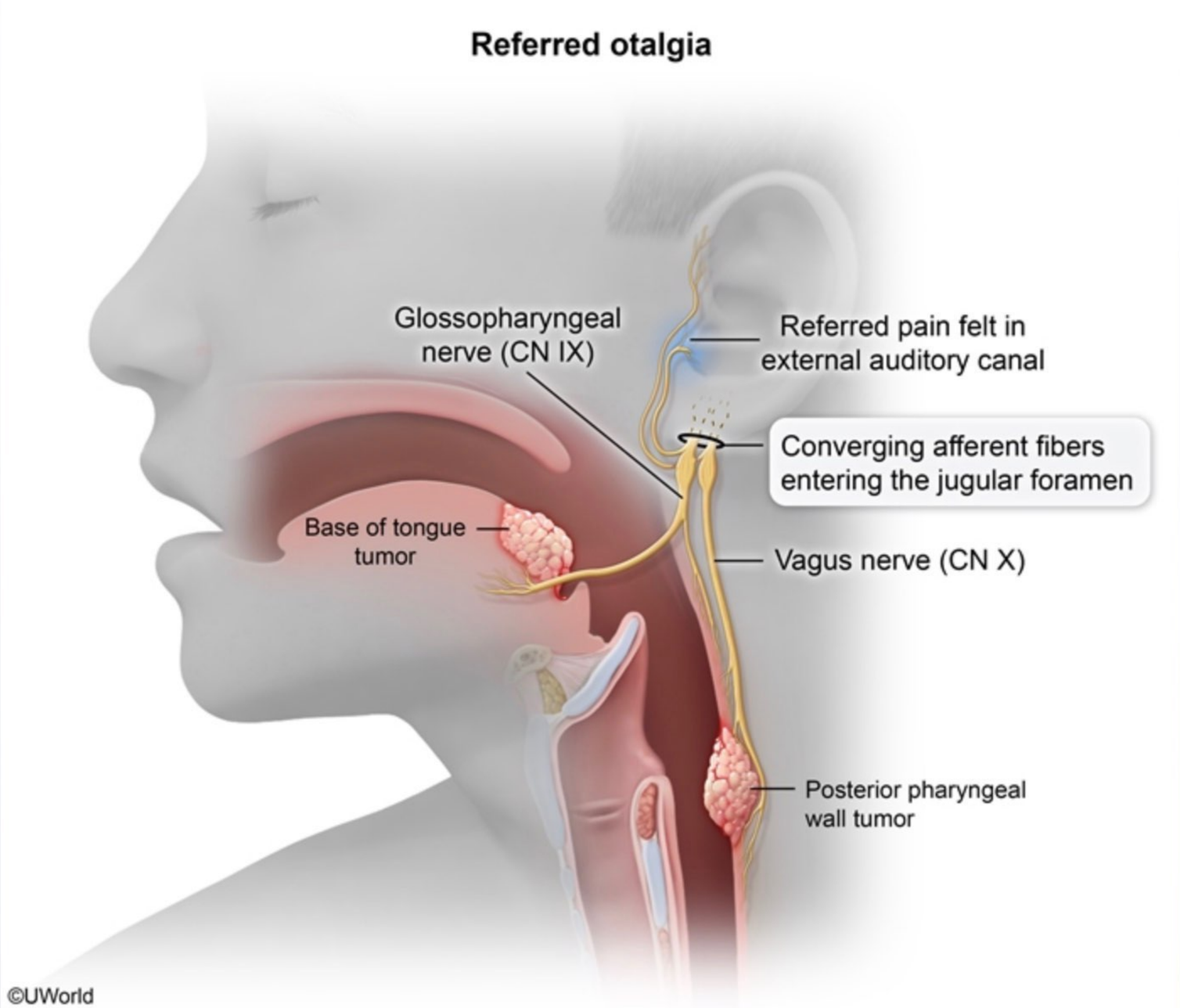


This patient has **otalgia** in the setting of a normal ear examination, which is likely **referred pain** (pain perceived at a different site than its true origin). Further evaluation shows an ulcerative mass in the hypopharynx with an enlarged lymph node, which is consistent with **mucosal head and neck squamous cell carcinoma** (HNSCC).



Scanned with CamScanner

This patient has **otalgia** in the setting of a normal ear examination, which is likely **referred pain** (pain perceived at a different site than its true origin). Further evaluation shows an ulcerative mass in the hypopharynx with an enlarged lymph node, which is consistent with **mucosal head and neck squamous cell carcinoma** (HNSCC).

Many sources of pain in the head and neck can be referred to the ear because several cranial nerves also innervate parts of the ear. Common causes of referred ear pain include temporomandibular joint disease, dental disease, or cancer affecting the tongue base, hypopharynx, or larynx.

This patient's referred otalgia is most likely due to his hypopharyngeal carcinoma causing irritation of the **vagus nerve** (CN X). The vagus nerve has afferent fibers innervating the larynx and **hypopharynx** and also has a branch that provides afferent sensory input from the external auditory canal. Similarly, the **glossopharyngeal nerve** (CN IX), which innervates the upper pharynx and base of tongue, also provides sensory innervation to the external auditory canal and can contribute to referred otalgia from tumors in these areas.

**(Choices A, B, and F)** The trigeminal nerve (CN V) provides sensory innervation for much of the face, including parts of the ear. The facial nerve (CN VII) and great auricular nerve (originates from C2 and C3) innervate portions of the external auditory canal. Although these nerves carry sensation from the ear, they do not provide innervation to the hypopharynx.

**(Choice C)** The vestibulocochlear nerve (CN VIII) contributes special sensory (hearing, balance) from the ear but does not contribute to general sensation. Therefore, lesions that impact the vestibulocochlear nerve tend to cause hearing loss or imbalance (eg, vertigo) rather than pain.

**(Choice E)** The hypoglossal nerve (CN XII) innervates the muscles of the tongue. It has motor function only, so dysfunction tends to produce weakness (eg, deviation of the tongue) rather than pain.

**Educational objective:**


Scanned with CamScanner

Many sources of pain in the head and neck can be referred to the ear because several cranial nerves also innervate parts of the ear. Common causes of referred ear pain include temporomandibular joint disease, dental disease, or cancer affecting the tongue base, hypopharynx, or larynx.

This patient's referred otalgia is most likely due to his hypopharyngeal carcinoma causing irritation of the **vagus nerve** (CN X). The vagus nerve has afferent fibers innervating the larynx and **hypopharynx** and also has a branch that provides afferent sensory input from the external auditory canal. Similarly, the **glossopharyngeal nerve** (CN IX), which innervates the upper pharynx and base of tongue, also provides sensory innervation to the external auditory canal and can contribute to referred otalgia from tumors in these areas.

**(Choices A, B, and F)** The trigeminal nerve (CN V) provides sensory innervation for much of the face, including parts of the ear. The facial nerve (CN VII) and great auricular nerve (originates from C2 and C3) innervate portions of the external auditory canal. Although these nerves carry sensation from the ear, they do not provide innervation to the hypopharynx.

**(Choice C)** The vestibulocochlear nerve (CN VIII) contributes special sensory (hearing, balance) from the ear but does not contribute to general sensation. Therefore, lesions that impact the vestibulocochlear nerve tend to cause hearing loss or imbalance (eg, vertigo) rather than pain.

**(Choice E)** The hypoglossal nerve (CN XII) innervates the muscles of the tongue. It has motor function only, so dysfunction tends to produce weakness (eg, deviation of the tongue) rather than pain.

**Educational objective:**
Referred otalgia is common in head and neck pathology because many cranial nerves innervate the ear (eg, CN V, VII, IX, X). In particular, tumors in the hypopharynx, larynx, or base of tongue cause referred otalgia due to sensory contributions from the glossopharyngeal and vagus nerves.


Scanned with CamScanner