The Journal of Emergency Medicine, Vol. 67, No. 4, pp. e346–e350, 2024
© 2024 Elsevier Inc. All rights are reserved, including those for text and data mining, AI training, and similar technologies.
0736-4679/$ - see front matter

https://doi.org/10.1016/j.jemermed.2024.05.003

Ultrasound in Emergency Medicine

It's Not Cyclic Vomiting Syndrome Until Dietl's is Ruled Out: A Case for Point of Care Renal Ultrasound

Christopher Thom, MD, RDMS, Michael Larsen, MD, Matthew Kongkatong, MD, Jakob Ottenhoff, DO, and James Moak, MD, RDMS

Department of Emergency Medicine, University of Virginia Health System, Charlottesville, Virginia
Corresponding Address: Christopher Thom, MD, RDMS, Department of Emergency Medicine, University of Virginia Health System, PO Box 800699, Charlottesville, VA 22908.

☐ **Abstract—Background: Abdominal pain and vomiting are frequent complaints for pediatric patients presenting to the Emergency Department (ED). When a diagnosis such as chronic abdominal pain, cyclic vomiting, or abdominal migraine has previously been made, it can lead to diagnostic momentum and confirmation bias on behalf of the treating physician. Dietl's crisis is a commonly missed diagnosis in the pediatric population that presents with intermittent episodes of pain and vomiting. It can be readily diagnosed at the bedside by the emergency physician (EP) through the employment of point of care ultrasound (POCUS). Case Series: We present two cases of pediatric patients with episodic abdominal pain and vomiting who were previously diagnosed with cyclic vomiting syndrome. In both cases, pediatric gastroenterology evaluations had occurred with negative diagnostic testing having been performed. Both patients also presented to their primary pediatrician and the ED multiple times with each encounter resulting in treatment of symptoms and discharge. Each patient eventually presented to the ED when an EP was present who performed a renal POCUS. In each patient, the POCUS revealed severe unilateral hydronephrosis. Subsequent workup confirmed the diagnosis of Dietl's crisis as the etiology of symptoms. Why Should an Emergency Physician Be Aware of This?: In pediatric patients, EPs should be wary of the diagnosis of cyclic vomiting syndrome until ureteral obstruction has been ruled out. A bedside POCUS can rapidly establish this diagnosis and potentially preclude recurrent health care visits, unnecessary diagnostic testing, and permanent loss of renal function.** **© 2024 Elsevier Inc. All rights are reserved, including those for text and data mining, AI training, and similar technologies.**

☐ **Keywords—hydronephrosis; Dietl's crisis; cyclic vomiting syndrome; point of care ultrasound**

Introduction

Chronic intermittent abdominal pain is a common presentation in the pediatric population. The differential diagnosis is extensive and can be challenging to identify in the emergency department (ED) (1). This is further complicated by the proportion of intermittent abdominal pain syndrome cases that have no clear diagnosis or are nonorganic in nature (2). Emergency physicians (EPs) should maintain an awareness of diagnoses that can present in a similar fashion to entities such as cyclical vomiting syndrome, abdominal migraine, and chronic abdominal pain. When such a diagnosis has been previously applied to a given patient, the EP should not anchor on this diagnosis, but should consider alternate etiologies as well.

An important reversible etiology of recurrent abdominal pain and cyclic vomiting in the pediatric population is ureteropelvic junction obstruction (UPJO), which leads to intermittent episodes of pain and vomiting. This results in hydronephrosis of the affected kidney and is termed a Dietl's crisis when the symptoms arise (3). Dietl's crisis

Received: 18 March 2024; Final submission received: 26 April 2024;
Accepted: 3 May 2024

was found to have a mean age of first attack in the 5th year of life and tends to have a male predominance (4,5). The most common cause of UPJO is an intrinsic ureteral narrowing (4,6). Other causes include fibroepithelial polyps, extrinsic compression by vasculature crossing the junction, and high ureter insertion (7). Regardless of the cause of obstruction, the resulting pain occurs due to delayed ureteral drainage, increased pressure, and dilation of the renal collecting system (3,7–9).

Several case reports and retrospective analyses paint a varying picture of how the symptoms of Dietl's crisis manifests on presentation (8,9). Episodic, intermittent abdominal pain appears to be present in nearly all cases. The pain is often diffuse and poorly localized. Exacerbation of the symptoms often occurs after excessive hydration, dehydration, or during periods of excessive ureteral flow, such as after diuretics for renal scintigraphic imaging (8,10). Along with the pain, other symptoms can include nausea, nonbilious vomiting, fatigue, decreased appetite and resultant failure to gain weight appropriately (11,12). Symptoms common with urinary tract infection can also occur. These symptomatic episodes are often of acute onset and last from minutes to hours interposed by periods of complete resolution (5). Many patients have a remarkably benign physical examination at presentation (12,13). Laboratory evaluation is generally unremarkable. Delays in diagnosis are common (11,12). Pyeloplasty is the treatment of choice and is effective in improving ureteral flow and resolving symptoms. However, the delay in diagnosis can lead to multiple unnecessary procedures and health care visits, as well as loss of renal function if the obstruction is not resolved in a timely fashion (9,14).

Point of care ultrasound (POCUS) is a readily available tool for the practicing EP and is able to detect hydronephrosis, the hallmark finding in UPJO, with good accuracy (15). Prior reports describe single patient cases in which ultrasound has made the diagnosis of UPJO and Dietl's crisis (9,11,12). Our case series highlights the role of renal POCUS, the importance of early diagnosis, and the frequent manner in which these patients have their true diagnosis masked by a prior determination of cyclic vomiting syndrome or abdominal migraine. Indeed, the EP should not anchor on such diagnoses in the pediatric population until organic pathologies including Dietl's crisis have been ruled out.

We present two pediatric patients with episodic abdominal pain and vomiting who were previously diagnosed with cyclic vomiting syndrome. In both cases, pediatric gastroenterology evaluations had occurred with negative diagnostic testing being performed. Both patients also presented to their primary pediatrician and the ED multiple times with each encounter resulting in treatment of symptoms and discharge. Each patient eventually presented to the ED when an EP was present who performed a renal POCUS. This revealed severe unilateral hydronephrosis in both patients. Subsequent workup confirmed the diagnosis of Dietl's crisis as the etiology of symptoms.

Case series

Case 1

A 14-year-old male presented to the ED with acute onset of vomiting and left flank pain. His family noted that he had experienced several years of intermittent episodic vomiting similar to the presentation on this visit. They stated that these episodes would last several hours, resolve, and not recur again for months. He was followed by both a neurologist and gastroenterologist and had been given a diagnosis of cyclic vomiting syndrome. No cross sectional or sonographic abdominal imaging was performed previously. On examination, he initially appeared in distress, with ongoing emesis and his abdominal exam was notable for mild left upper and left flank tenderness. Urinalysis testing and serologic studies were normal. He received a renal POCUS, which revealed severe left sided hydronephrosis (Figure 1). He was subsequently admitted and underwent computed tomography (CT) of the abdomen and pelvis, which revealed findings suggestive of chronic left-sided UPJ obstruction with severe left sided hydronephrosis (Figure 2). Urology was consulted during the inpatient stay and noted that his presentation was consistent with Dietl's crisis. The patient was discharged the following day with outpatient urologic follow up scheduled close to home.

Case 2

A 5-year-old female presented to the ED with acute onset of abdominal pain and vomiting. She had experienced about one year of similar intermittent episodes of severe vomiting and diffuse pain. She had multiple visits with her primary pediatrician in the preceding one year for this, along with three prior ED visits, and several gastroenterology clinic visits. She had undergone an endoscopy and plain radiography of the abdomen, both of which were unremarkable. Her symptoms had been diagnosed as cyclic vomiting syndrome and abdominal migraine. During her ED visit, urinalysis testing and serologic studies were normal. On ED evaluation, her symptoms had largely resolved. She reported mild ongoing abdominal discomfort diffusely, but had no tenderness to palpation. Renal POCUS by the EP revealed severe right sided hydronephrosis (Figure 3). Urology was consulted in the ED and recommended outpatient magnetic resonance imag-

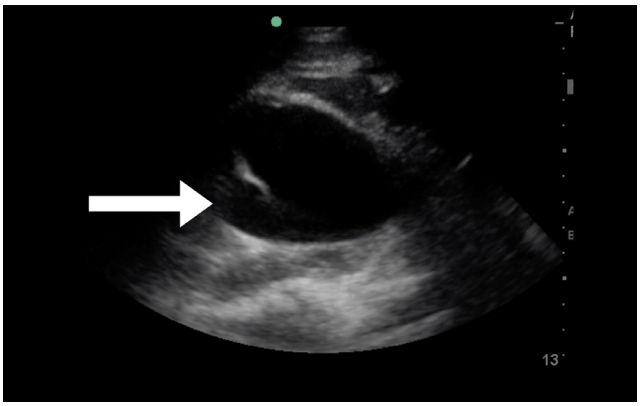

Figure 1. Point-of-care ultrasound of the left kidney demonstrating severe hydronephrosis. Arrow denotes the significant dilation of the renal pelvis seen in severe hydronephrosis.

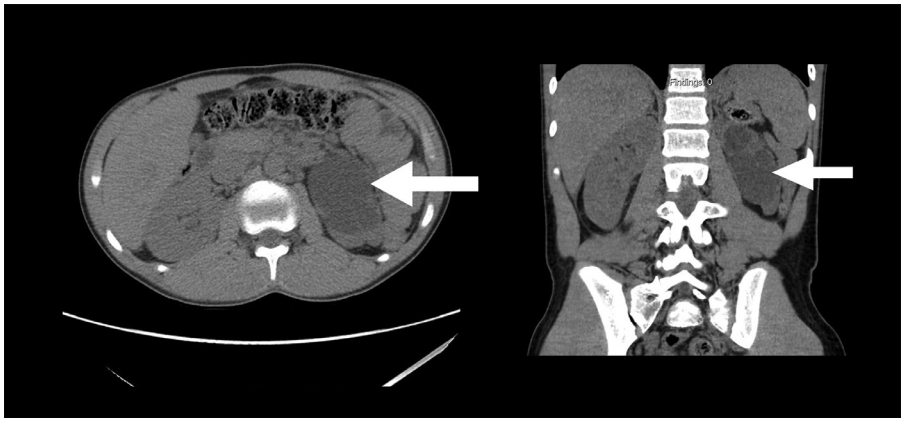

Figure 2. Axial (left) and coronal (right) images from the computed tomography study showing severe hydronephrosis of the left kidney. Arrows denote the dilation of the renal pelvis as seen in hydronephrosis.

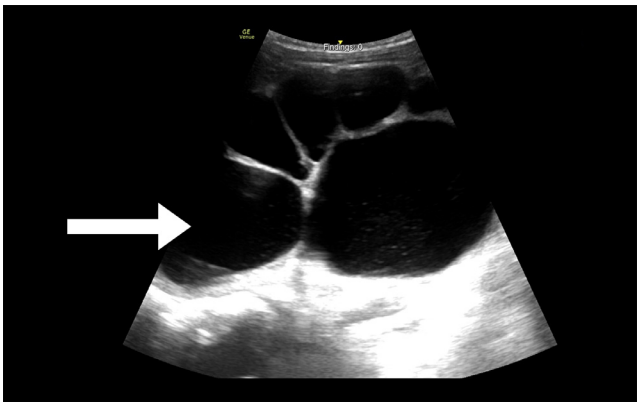

Figure 3. Point-of-care ultrasound of the right kidney demonstrating severe hydronephrosis. Arrow denotes the dilated collecting system as seen in severe hydronephrosis.

ing (MRI) urogram. This occurred one week later and confirmed right UPJO with loss of renal tissue and no measurable excretion of contrast into the right collecting system (Figure 4). One month later, she underwent pyeloplasty and ureteral stent placement.

Discussion

Dietl's crisis refers to intermittent episodes of abdominal pain and emesis secondary to a congenital UPJ obstruction. The disease can present throughout child-

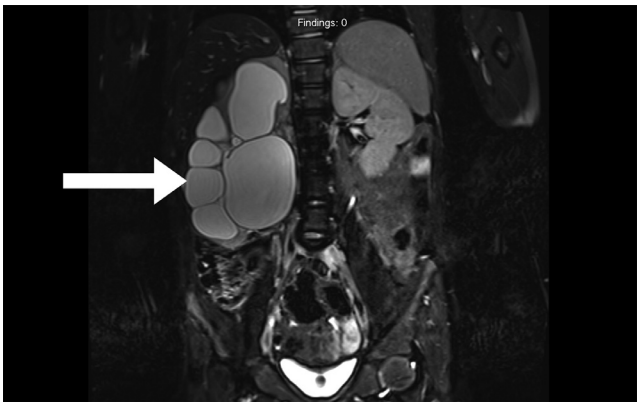

Figure 4. T2-weighted magnetic resonance imaging urogram demonstrating severe hydronephrosis. Arrow denotes the dilated collecting system as seen in severe hydronephrosis.

hood or early adulthood and is particularly common in the preschool population (5). It commonly features nonspecific complaints and is subject to misdiagnosis and delays in treatment. Patients can experience unneeded tests, clinic visits, hospitalizations, and procedures. Delays in care can also lead to permanent degradation in renal function when left undiagnosed and untreated (16,17). Timely interventions can resolve the episodes and reduce unnecessary health care visits and testing, as well as preserve renal function (10). However, treatment can only ensue when the diagnosis is considered and confirmed. Among pediatric patients with idiopathic chronic abdominal pain or a putative diagnosis of cyclic vomiting syndrome, the EP should always consider alternate pathologies such as ovarian torsion, testicular torsion, incarcerated hernia, intracranial pathology leading to neurogenic vomiting, diabetic ketoacidosis, and UPJ obstruction.

Prior case reports have discussed individual pediatric patients with a longstanding diagnosis of chronic abdominal pain, cyclic vomiting syndrome, or abdominal migraine who are subsequently found to have a UPJO as the cause of the episodes (9,11,12). Our two cases serve as a reminder that diagnostic momentum can be a powerful form of bias when evaluating patients with seemingly more chronic or ongoing complaints. Diagnostic momentum occurs when a previously established diagnosis made by another physician is more likely propagated by subsequent physicians (18,19). It has been identified as one of the most common biases in the field of emergency medicine (18). The closely related anchoring bias could also apply in the above cases, as the EP would have a tendency to arrive at the diagnosis considered first in the above cases. This form of bias is also common in emergency medicine, with 11.4% of cognitive bias cases in emergency medicine involving anchoring (20). Key to arriving at the correct diagnosis for both patients in our case series was setting aside these forms of bias and maintaining an open mind to less common and not established diagnoses.

In the first case, both neurological and gastroenterological diseases had been considered and specialist evaluations had occurred. However, one would not typically refer a cyclic vomiting patient to a urologist and UPJO is often underappreciated by many fields in medicine. In the second case, the patient's symptoms had resolved in the ED, she was tolerating orals and could have again been discharged from the ED with the established cyclic vomiting diagnosis that she had received in the pediatric gastroenterology clinic. However, the EP decided to evaluate the kidneys with renal POCUS to rule out this disease in particular. In our case series, both of the EPs who identified the correct diagnosis were ultrasound fellowship trained EPs. These EPs are more likely to employ POCUS in their routine practice and have improved test characteristics for hydronephrosis compared to nonultrasound fellowship trained peers (21). They can also perform POCUS exams more efficiently as part of their daily practice (22). With this said, renal POCUS can be readily employed by any EP with the practice and experience to reliably utilize this bedside tool.

In Dietl's crisis, the intermittent pain episodes can be associated with intermittent hydronephrosis that improves or resolves between pain crises (23). However, as in our second case where a subsequent outpatient MRI occurred during a pain free period, the hydronephrosis can also be persistent and not resolved between episodes. Dietl's crisis commonly refers to the constellation of symptoms that include flank pain, abdominal pain, nausea, and vomiting in the setting of an identified UPJO (24). This was consistent with both of our described cases above.

One should always consider the diagnosis of Dietl's crisis when evaluating a pediatric patient with a history of episodic vomiting or abdominal pain of unclear etiology. The EP should not allow for a diagnosis of cyclic vomiting

syndrome or abdominal migraine to go uncontested without first considering whether a UPJ obstruction might be present. Renal POCUS can readily identify this condition in suspected cases.

Declaration of competing interest

The authors declare that they have no known competing financial interests or personal relationships that could have appeared to influence the work reported in this paper.

CRediT authorship contribution statement

Christopher Thom: Writing – review & editing, Writing – original draft, Visualization, Validation, Software, Resources, Formal analysis, Conceptualization. **Michael Larsen:** Writing – review & editing, Writing – original draft, Conceptualization. **Matthew Kongkatong:** Writing – review & editing. **Jakob Ottenhoff:** Writing – review & editing. **James Moak:** Writing – review & editing, Writing – original draft, Conceptualization.

References

1. Rosman NP, Dutt M, Nguyen HT. A curable and probably often-overlooked cause of cyclic vomiting syndrome. Semin Pediatr Neurol 2014;21:60–5.
2. McGrath PJ, Goodman JT, Firestone P, Shipman R, Peters S. Recurrent abdominal pain: a psychogenic disorder? Arch Dis Child 1983;58:888–90.
3. Dietl J. Wandernde nieren and deren einklemmung. Wien Med Wochenschr 1864;14:153–66.
4. Chen Z, Lin H, Xu M, et al. The clinical manifestations of intermittent hydronephrosis and their relationship with renal function in pediatric patients. J Pediatr Urol 2020;16 458.e1–458.e6.
5. Fu K, Jia W, Fu W, et al. Abdominal pain as a result of intermittent hydronephrosis. Eur Rev Med Pharmacol Sci 2018;22:3126–9.
6. Sezer BT. Ureteropelvic junction obstruction. The ureter: a comprehensive review. Cham, Switzerland: Springer International Publishing; 2024. p. 93–111.
7. Flotte TR. Dietl syndrome: intermittent ureteropelvic junction obstruction causes of episodic abdominal pain. Pediatrics 1988;82:792–4.
8. Maddileti V, Gazula S, Dantala P, Srinivas M. Dietl's crisis: an under appreciated clinical entity in the paediatric population. BMJ Case Rep 2021;14:e244943.
9. Burhop J., Clingenpeel JM., Poirier MP. Emergency department diagnosis of Dietl crisis in a 7-year-old girl with abdominal pain: pediatric emergency care. 2016;32:386–7.
10. Alagiri M, Polepalle SK. Dietl's crisis: an under-recognized clinical entity in the pediatric population. Int Braz J Urol 2006;32:451–3.
11. Fox EM, Kasmire KE. Point-of-care ultrasound diagnosis of ureteropelvic junction obstruction in a child with recurrent abdominal pain and vomiting. Pediatr Emerg Care 2020;36:497–9.
12. Godambe SA, Boulden T. The use of an emergency physician-directed bedside ultrasound examination to clarify a diagnosis in an 8-year-old boy with chronic abdominal pain. Pediatr Emerg Care 2007;23:560–2. doi:10.1097/PEC.0b013e31812e578c.
13. Lahoud RM, Esker WD, Thurston SA, Kohanski M, Elder JS, Lim R. Dietl crisis: presentation and imaging findings in a 7-year-old boy. Radiol Case Rep 2021;16:555–9.
14. Melvin JE, Ost MC, Marin JR. Hydronephrosis from ureteropelvic junction obstruction discovered on point-of-care ultrasound in patients with trauma. Pediatr Emerg Care 2018;34:365–7.
15. Guedj R, Escoda S, Blakime P, Patteau G, Brunelle F, Cheron G. The accuracy of renal point of care ultrasound to detect hydronephrosis in children with a urinary tract infection. Eur J Emerg Med 2015;22:135–8.
16. Alberti C. Congenital ureteropelvic junction obstruction: physiopathology, decoupling of tout court pelvic dilatation-obstruction semantic connection, biomarkers to predict renal damage evolution. Eur Rev Med Pharmacol Sci 2012;16:213–19.
17. Rosen S, Peters CA, Chevalier RL, Huang WY. The kidney in congenital ureteropelvic junction obstruction: a spectrum from normal to nephrectomy. J Urol 2008;179:1257–63.
18. Frye KL, Adewale A, Martinez Martinez CJ, Mora Montero C. Cognitive errors and risks associated with provider handoffs. Cureus 2018;10:e3442.
19. Khadilkar SV, Khadilkar SS. Bias in clinical practice. J Obstet Gynaecol India 2020;70:1–5. doi:10.1007/s13224-019-01304-5.
20. Kunitomo K, Harada T, Watari T. Cognitive biases encountered by physicians in the emergency room. BMC Emerg Med 2022;22:148.
21. Herbst MK, Rosenberg G, Daniels B, et al. Effect of provider experience on clinician-performed ultrasonography for hydronephrosis in patients with suspected renal colic. Ann Emerg Med 2014;64:269–76.
22. Patrick DP, Bradley XG, Wolek C, Anderson B, Grady J, Herbst MK. Minutes matter: time it takes to perform point-of-care ultrasound. AEM Educ Train 2023;7:e10901.
23. Tsai JD, Huang FY, Lin CC, et al. Intermittent hydronephrosis secondary to ureteropelvic junction obstruction: clinical and imaging features. Pediatrics 2006;117:139–46.
24. Anderson CB, Tanaka ST, Pope 4th JC, Adams MC, Brock 3rd JW, Thomas JC. Acute pain crisis as a presentation of primary megaureter in children. J Pediatr Urol 2012;8:254–7.