

Clinical signs, reproduction of attaching/effacing lesions, and enterocyte invasion after oral inoculation of an O118 enterohaemorrhagic *Escherichia coli* in neonatal calves

Philippe Stordeur^{a*}, Bernard China^a, Gerard Charlier^b, Stefan Roels^b, Jacques Mainil^a

^aLaboratory of Bacteriology, Faculty of Veterinary Medicine, University of Liège, Sart Tilman B43a, B-4000 Liège, Belgium

^bSection of Pathology, Department of Biocontrol, Centre for Research in Veterinary Science and Agrochemistry, Groeselenberg 99, B-1180 Brussels, Belgium

(Received 8 July 1999; accepted 30 September 1999)

ABSTRACT – Attaching and effacing (AE) lesions are produced among others by enteropathogenic *Escherichia coli* and enterohaemorrhagic *E. coli* (EHEC), which differs from the former by the production of cytotoxins active on various cell cultures, the verocytotoxins, or shigacytotoxins. EHEC are associated with diarrhoea and dysentery in humans and in ruminants, mainly calves from two to eight weeks of age. Clinical signs and/or lesions have been reproduced experimentally with EHEC strains belonging to serotypes O5:K4/Nm, O26:K:-H11, O111:Nm, and O157:H7 which are isolated from cattle and/or humans. The purpose of this work was to develop an experimental model of infection in newborn calves with a bovine EHEC strain isolated from a calf which died of diarrhoea, and belonging to the O118:H16 serotype, which is also common to both cattle and humans. The bovine O118:H16 EHEC strain was able to colonize the gut of three newborn calves, and to induce diarrhoea twenty-four hours after challenge and to produce AE lesions in the small and/or large intestines. AE lesions were detected microscopically and ultrastructurally in the small intestine of one calf and in the whole intestinal track of two calves. Internalization of bacteria and also of pedestal-bacteria complex inside of the enterocyte was observed in two of the three calves. The significance of this stage is unknown but may be related to the invasion of the calf by the bacteria. The challenge strain was isolated from the mesenteric lymph nodes of the same two calves but not from other organs or from heart blood. No blood was observed in the faeces of any of the three calves, nor were any lesions in the internal organs, which may have been related to the production of a verotoxin whose role is still unknown in cattle. © 2000 Éditions scientifiques et médicales Elsevier SAS

enterohaemorrhagic *E.coli* (EHEC) / calf / attaching and effacing lesions (AE) / diarrhoea / invasion

1. Introduction

Since 1984 [2], attaching and effacing *Escherichia coli* is recognised as a cause of diarrhoea and dysentery in young calves, mainly from two to eight weeks of age [5, 16]. ‘Attaching and effacing’ was the term first used by Moon and collaborators [22] to describe an intestinal lesion (AE lesion) caused by specific strains of *E. coli*: ‘effacing’ because of the localized disappearance of the brush border microvilli; ‘attaching’ because of the inti-

mate attachment of the bacteria to the exposed cytoplasmic membrane of the enterocyte.

AE lesions are caused by enteropathogenic *E. coli* (EPEC), *Citrobacter rodentium*, *Hafnia alveii*, and enterohaemorrhagic *E. coli* (EHEC), which differ essentially from the EPEC by the production of cytotoxins active on various epithelial cells (Hela and Hep-2) in culture, the verocytotoxins (VT1 and VT2 families), also named shigacytotoxins (Stx1 and Stx2 families) [19, 21, 24]. EPEC causes diarrhoea in various animal species and in humans, whereas EHEC is associated with diarrhoea and dysentery in rumi-

* Correspondence and reprints

nants and in humans. In the latter, EHEC also causes the haemolytic-uraemic syndrome (HUS) [4, 16, 19, 24, 25].

The pathogenesis of EPEC/EHEC and the production of the AE lesions have been intensively studied *in vitro* on cells in culture with the human EPEC strain E2348/69, and a four-step model has been tentatively proposed [24], consisting of (i) initial adherence to the enterocyte microvilli; so far fimbrial adhesins have been described only for human EPEC [9] and rabbit EPEC [21]; (ii) type III secretion system-mediated signal transduction into the enterocyte resulting in increased levels of phosphorylation and calcium, as well as in cytoskeleton rearrangements. (In vivo, the most dramatic consequence is the effacement of the brush border microvilli); (iii) intimate attachment to the exposed enterocyte cytoplasmic membrane, mediated by an outer membrane protein, intimin, with polymerisation of actin filaments underneath the zone of adherence of the bacteria and enhancement of the cytoskeleton rearrangements; and (iv) penetration of the bacteria into the cells. The VT/Stx toxins play no role in the development of the AE lesions, but cause damage to the intestinal wall vessels resulting in haemorrhages and dysentery in humans and calves. In humans, they also cause damage to the arterioles of the kidneys, resulting in the HUS [19, 24, 25].

The first step is mediated by genes located on a plasmid or on the chromosome [21, 24]. Genes responsible for steps (ii) and (iii) are grouped together on the bacterial chromosome forming a pathogenesis island, the locus of enterocyte effacement, or LEE [20]. The genetic determinism of the fourth step is still unknown although chromosomal mutants deficient only in cell invasion have been described [8]. The genes coding for the VT/Sta are also located on the chromosome, but on phages for several of them [19].

The transposition *in vivo* of these *in vitro* models has been realized for the first three steps with human and rabbit EPEC by testing mutants [10, 21], but the *in vivo* significance of the fourth step, the cellular invasion, is still unknown. Bovine EPEC and EHEC also possess a LEE [12], and AE lesions and/or clinical signs have been experimentally reproduced in young calves and lambs, with bovine EHEC belonging to various serotypes: O5:K4:Nm, O26:K:H11, O111:Nm, and O157:H7 [1, 7, 18, 23, 29, 32]. Bovine EPEC and EHEC belonging to other serotypes have, however, not been tested *in vivo* yet.

The purpose of this work was to develop an experimental model of infection in newborn calves to confirm the pathogenicity of and follow the production of AE lesions by a bovine EHEC strain belonging to serotype O118:H16. This model will help to study mutants in various pathogenicity-associated genes of bovine EHEC in the future.

2. Material and methods

2.1 Bacterial strain

Strain 340S89 is an O118:H16 *E. coli* which was isolated in 1989 from a two-week-old Friesian calf which died of diarrhoea [27]. It tests positive with the gene

probes for intimin (Eae probe) and VT1, but not with the gene probe for VT2 [17] and is able to reproduce AE lesions in rabbits [4]. This strain is sensitive to kanamycin, gentamycin, tetracycline, chloramphenicol, and nalidixic acid, but resistant to streptomycin and tellurite.

2.2 Calf infection

Four naturally born calves were isolated immediately after birth in a box which had been washed and disinfected (Atlantol*, Ecosa, Ghent, Belgium). They received 300 millilitres of colostrum which was negative by ELISA and agglutination against strain 340S89. At six hours of age, three of them were challenged orally with 10^9 to 10^{10} CFU of strain 340S89 suspended in sterile saline and the fourth one with saline only. Strain 340S89 was grown on Meat extract Agar slants (Oxoid, Gent, Belgium) for six hours aerobically at 37 °C. The bacteria were resuspended in sterile saline and the optical density at 620 nm was adjusted to obtain a bacterial concentration between 10^9 to 10^{10} per 200 mL. The exact concentration was calculated after inoculation of tenfold dilutions of the suspension onto Gassner agar plates (Belgolabo, Overijse, Belgium). This medium was used to select enteric bacteria. Moreover, it provided the opportunity to make a differentiate between coliforms thanks to his lactose activity [11]. The calves were subsequently fed twice a day with two liters of UHT whole milk. Clinical investigations and faecal sampling were performed every four hours. Faecal samples were tested by ELISA (trousse ELISA digestive, BioX, Brussels, Belgium) for the presence of K99 enterotoxigenic *E. coli*, rotavirus, coronavirus, and *Cryptosporidium* sp. The excretion of the challenge strain was followed by bacteriological examination and by PCR.

2.3. Necropsy

The calves were euthanised between 44 and 64 h p.i. (p.i.) by intravenous administration of sodium pentobarbital. Necropsy was performed on a general routine basis at first and subsequently focused on the abdominal cavity. Samples were taken aseptically from various intestinal segments (duodenum, jejunum, ileum, caecum, spiral colon, descending colon, and rectum) and from internal organs (mesenteric lymph nodes, liver, spleen lungs, kidneys, heart blood, and brain) for bacteriology, histopathology, and electron microscopy.

2.4. Bacteriology

The faecal samples were collected in sterile containers. The postmortem faecal samples were taken aseptically (the sections of the gut had been sterilized using burning steel) with a Pasteur pipette. The samples were then diluted tenfold. Dilutions 10^{-4} to 10^{-6} were inoculated onto Gassner agar and Gassner agar supplemented with streptomycin sulphate (Sigma Aldrich, Steinheim, Germany, 100 µg per mL) and tellurite (Sigma Aldrich, Steinheim, Germany, 10^{-4} M) plates with a spiral plater system (LED Techno, Hechtel-Eksel, Holland), and incubated overnight aerobically at 37 °C. After one night of incubation, a calculation of the number of bacteria on the plate was realized and this result was transformed in CFU/g of intestinal content by a formula.

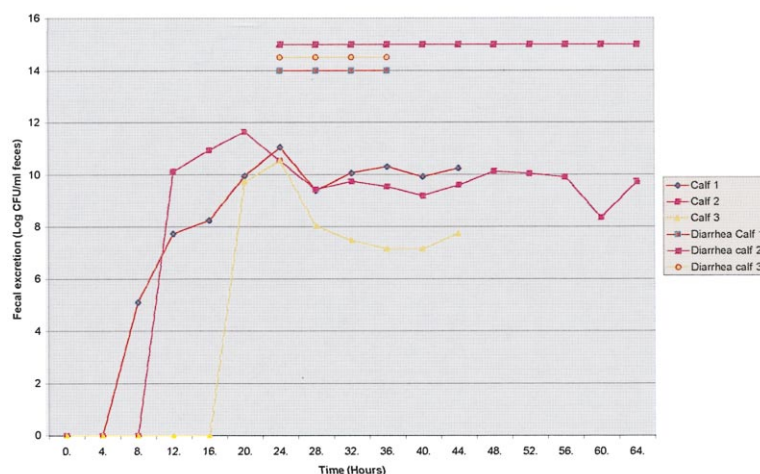


Figure 1. Faecal excretion of strain 340S89 (Log CFU/ mL of faeces) and appearance of diarrhoea as a function of p.i. time. The calves were euthanazied at 56 hours p.i. (calf 1), 64 hours p.i. (calf 2), and 44 hours p.i. (calf 3), respectively.

Each lymph node was investigated before intestines were opened. The content of this one (taken with a Pasteur pipette after sterilization of the surface using burning steel) was seeded directly onto the selective medium (Gassner agar plates supplemented with streptomycin sulfate and tellurite).

For each faecal sample, five colonies grown on the streptomycin-tellurite Gassner agar plates at 10^{-6} concentration were compared with strain 340S89 by tube agglutination with the O118 immuniserum, by determination of the antibiotic sensitivity, by PCR, and by pulsed-field gel electrophoresis (PFGE). In addition, colonies of one plate for each sample were tested by colony hybridization with the probes for intimin and VT1 after direct transfer onto filters.

2.5. Tube agglutination and antibiotic sensitivity

The tube agglutination test with an O118 immune serum was performed following standard procedure [30]. The antibiotic sensitivity was performed on Mueller-Hinton II agar (Becton Dickinson Benelux, Erembodegem, Belgium) with the following antibiotic discs according to the manufacturer's instructions: tetracyclin (30 µg), chloramphenicol (30 µg), streptomycin (10 µg), gentamycin (10 µg), kanamycin (30 µg), nalidixic acid (30 µg), ampicillin (10 µg), and rifampicin (5 µg).

2.6. Colony hybridization, PCR, and PFGE

The colony hybridization assay was performed with gene probes for the intimin (Eae probe) and for VT1 (VT probe) as described by Mainil and collaborators [17]. The probes were labelled with [α - 32 P] dCTP by random priming using the dCTP-labelling beads (Ready to go, Pharmacia, Uppsala, Sweden). A PCR specific for the *eae* gene was performed on the faecal samples and on the internal organs with a positive culture, and a multiplex PCR for the intimin and verotoxin genes was performed on the faecal samples as described by China and collaborators [3]. PFGE was performed on a CHEF mapper apparatus (Bio-

rad laboratories, Hercules, California, USA) using the following parameters: voltage of 6V/cm, migration time of 21 h, switch time of 2 to 20 s, angle of 120°, ramping factor of 1 379. The plugs were prepared using the Gen-path group 2 reagent kit (Bio-Rad) and digested for five hours with *Xba*I (Gibco, Paisley, Scotland, UK).

2.7. Histopathology and electron microscopy

Tissues were fixed in a phosphate-buffered formaldehyde/glyceraldehyde solution (4%/1%), processed routinely, and paraffin embedded, and sections of 5 µm were obtained. Tissue sections were stained with hematoxylin-eosin and examined for presence of bacteria and inflammatory lesions. For transmission and scanning electron microscopy, the samples were fixed in the same solution. Samples for transmission electron microscopy were embedded in Epon/Spurr (50/50) and ultrafine sections were examined in a Philips 208S electron microscope. Samples for scanning electron microscopy were critical point dried, gold sputtered and examined in a Philips 501 electron microscope.

3. Results

3.1 Clinical signs

The three calves inoculated with strain 340S89 had acute serous non-bloody diarrhoea beginning 24 h p.i., and which lasted for 12 h in two of them (calves 1 and 3) and until the euthanasia in calf 2 (figure 1). A mild hyperthermia was also noted (39.6 to 39.9 °C), but only calf 2 had general clinical signs such as inappetence, prostration, and congestion of mucosae. The control calf had neither diarrhoea nor general clinical signs.

3.2. Faecal excretion

The challenge *E. coli* strain 340S89 was detected in the faecal samples of the three challenged calves from between 8 to 20 h p.i. until euthanasia (figure 1), after

Table I. Concentration of the strain 340S89 (CFU/mL) in different segments of the gut.

	<i>Calf 1</i>	<i>Calf 2</i>	<i>Calf 3</i>	<i>Control</i>
Duodenum	0	0	0	0
Jejunum	0.2 10 ⁷	1.7 10 ⁹	0	0
Ileum	1.2 10 ⁸	2.6 10 ⁹	1.4 10 ⁸	0
Caecum	1 10 ⁷	1.3 10 ⁹	0.9 10 ⁹	0
Spiral colon	1.6 10 ⁸	2.6 10 ⁹	7 10 ⁸	0
Descending colon	3 10 ⁷	0.2 10 ⁷	0.2 10 ⁷	0

growth on streptomycin-tellurite gassner agar plates and identification by tube agglutination with an O118 immune serum, by antibiotic sensitivity determination, by DNA colony hybridization with the Eae and VT1 probes and by PFGE as described in the Material and methods section. The peak of faecal excretion was observed between 20 to 24 h p.i.. Strain 340S89 was excreted by most calves at concentration between 10⁵ and 10¹⁰ CFU/g of faeces (figure 1) and represented 65 to 100% of the total coliform population. In the samples, concentrations of 10¹¹ to 10¹² CFU/g of faeces were obtained (figure 1) but most probably result from a technical problem.

The PCR results for the *eae* gene on the faecal samples were positive from between 16 to 20 h p.i. until euthanasia.

The control calf never excreted the challenge strain nor an *eae* PCR-positive *E. coli*. All four calves remained negative for presence of coronavirus, *Cryptosporidium* and K99-enterotoxigenic *E. coli*. Only calf 2 was found positive for excretion of rotavirus as early as 24 h p.i..

3.3. Necropsy

The three calves presented lesions of acute serous enteritis and/or colitis: lesions were localized on the large intestine (calf 1) or extended throughout the whole intestinal tract (calves 2 and 3). No lesions were found in the internal organs with the exception of the mesenteric lymph nodes which were enlarged. The control calf showed no lesion at all.

3.4. Postmortem bacteriology

E. coli strain 340S89 was detected and identified, as in the faecal samples, in various intestinal segments of the three challenged calves (table I) and from the mesenteric lymph nodes of calves 2 and 3. Strain 340S89 was present at concentrations varying between 10⁶ to 10⁹ CFU/g of intestinal content and represented 60 to 85% of the total coliform population. Strain 340S89 was not detected in the control calf either from the intestine or from the intestinal organs. PCR performed on the mesenteric lymph nodes of calves 2 and 3 were positive, and negative on the mesenteric lymph nodes of the control calf.

3.5. Histopathology and electron microscopy

An important inflammatory reaction with neutrophil and lymphocyte infiltration (figure 2A) was observed in the wall of most segments of the intestine of the three challenged calves (table II). Adherent bacteria were vis-

ible in the large intestine of calf 1 and in the small and large intestine of calves 2 and 3. When adherent bacteria were present, the brush border was no longer visible (figure 2A). The Peyer's patches and the mesenteric lymph nodes showed low to intensive degrees of activation (table II). No lesion was observed in the internal organs including the brain. The control calf showed no lesion other than vascular congestion in all organs and some degree of cellular infiltration in parts of the intestine (table II).

Scanning and electron microscopy confirmed the presence of closely adherent bacteria and of localized effacement of the enterocyte microvilli where the bacteria attached (figure 2B, 2C). Pedestal and actin accumulation under the zone of adherence of the bacteria were also present (figure 2C). Moreover, internalization into the enterocytes of bacteria and of bacteria-pedestal complexes were evident in calf 2 (figure 2D). None of these lesions were observed in the control calf.

4. Discussion

In this work an O118:H16 EHEC strain was able not only to colonize the gut of three newborn calves, but also to induce diarrhoea 24 h after challenge and to produce AE lesions in the small and/or large intestines. The appearance of diarrhoea coincides with the peak of faecal excretion of the challenge strain, but lasted only for 12 h in two calves (figure 1). Faecal excretion of the challenge strain was detected earlier by growth on a selective agar containing streptomycin and tellurite than by PCR on faecal samples.

As no other classical diarrhoeagenic infectious agents were isolated from these two calves and as the control calf did not develop diarrhoea [7], the O118:H16 EHEC strain can be considered the cause of diarrhoea. It may be argued that challenge with any bacteria would cause the appearance of diarrhoea. Arguments in favour of a role of the O118:H16 EHEC strain are: (i) challenge with a non-toxigenic F17-producing *E. coli* strain resulted in the absence of any clinical signs (Van Bost and Mainil, unpublished data); (ii) the colonization of the gut was still high as attested by the faecal excretion even after the disappearance of the diarrhoea (figure 1). The direct cause of diarrhoea by EPEC/EHEC strains is believed not to be the AE lesions, however extended they can be, and is actually still unknown, although an active mechanism based on ion exchange and mediator perturbation is under consideration [24].

The severity and the length of the diarrhoea was thus not related to the degree of intestinal colonization, nor to the degree of extension of the macroscopic (acute serous enteritis) and microscopic (AE) lesions (small intestine for calf 1, small and large intestine for calves 2 and 3; table II). Other factors must thus be considered: the presence of other diarrhoeagenic agents, such as a rotavirus in calf 2; the age of the animal and its genetic background; loss of some bacterial virulence genes during storage. Coexistence between EPEC/EHEC strains and other diarrhoeagenic agents has already been noticed in field studies and

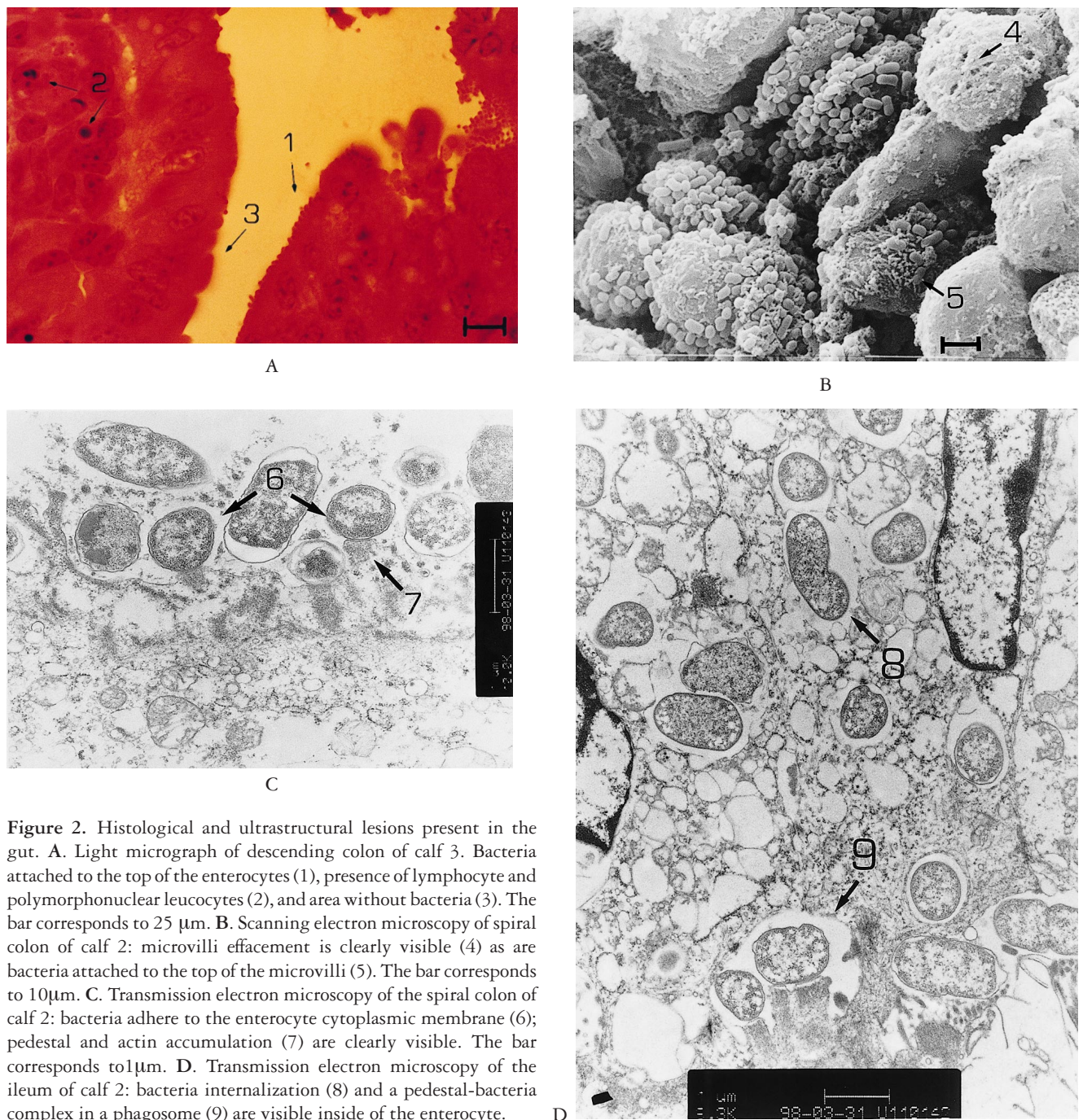


Figure 2. Histological and ultrastructural lesions present in the gut. **A.** Light micrograph of descending colon of calf 3. Bacteria attached to the top of the enterocytes (1), presence of lymphocyte and polymorphonuclear leucocytes (2), and area without bacteria (3). The bar corresponds to 25 μm . **B.** Scanning electron microscopy of spiral colon of calf 2: microvilli effacement is clearly visible (4) as are bacteria attached to the top of the microvilli (5). The bar corresponds to 10 μm . **C.** Transmission electron microscopy of the spiral colon of calf 2: bacteria adhere to the enterocyte cytoplasmic membrane (6); pedestal and actin accumulation (7) are clearly visible. The bar corresponds to 1 μm . **D.** Transmission electron microscopy of the ileum of calf 2: bacteria internalization (8) and a pedestal-bacteria complex in a phagosome (9) are visible inside of the enterocyte.

may be related to the severity and persistence of diarrhoea in farms [5]. The age of the animal is also important: with strains of serotypes O157:H7 and O26:H11 clinical signs could not be reproduced in calves aged one to two weeks but could be reproduced well in newborn calves [1, 6, 7, 18]. The opposite situation may exist for strains belonging to other serotypes, mimicking the situation of EPEC in rabbits [21, 26].

VT toxins are thought to cause the appearance of bloody diarrhoea at least in man [24], but the situation may be different in calves. No blood was indeed observed in the faeces of any of the three calves, nor were there any

lesions in the internal organs which may have been related to the production of a verotoxin, in the brain as in piglets suffering from oedema disease [19] or in the kidneys as in humans suffering from HUS [24]. The role of VT1 produced by most cattle EHEC [17, 19] is actually still unknown. Challenge experiments with the wild-type strain and isogenic mutants in the genes coding for the verotoxins may bring an answer to this question.

An often overlooked property of at least some EPEC/EHEC strains is their capacity to invade cells *in vitro* [8] and *in vivo* [28]. Internalization of bacteria and also of bacteria-pedestal complex inside the enterocyte was

Table II. Histological and ultrastructural lesions and observations.

		<i>Calf 1</i>	<i>Calf 2</i>	<i>Calf 3</i>	<i>Control</i>
Duodenum	Congestion	+ ^a	+	+	+
	Infl. Cells ^g .				
		PMN ^c , L ^d	PMN	L, M ^e	E ^f , M
	Villosity atrophy	+	-	+	-
	Abcess	- ^b	-	-	-
	AE lesions	-	-	-	-
	Internalization	-	-	-	-
Jejunum	Congestion	+	+	+	+
	Infl. cells.				
		L, M, PMN	L, M, PMN	L, M, PMN	E
	Abcess	+	-	-	-
	Peyer' spatches	+	-	+	-
	Villosity atrophy	-	+	+	-
	AE lesions	-	-	+	-
	Internalization	-	-	-	-
Ileum	Congestion	+	+	+	+
	Infl. cells.				
		PMN, L	PMN, L, M	PMN, M, L	E, M
	Abcess	+	-	-	-
	Peyer's patches	+	+	+	+
	Villosity atrophy	-	+	+	-
	AE lesions	-	+	+	-
	Internalization	-	+	+	-
Caecum	Congestion	+	+	+	-
	Infl. cells.	PMN	PMN	PMN, L, E	PMN
	Abcess	-	-	-	-
	Villosity atrophy	-	+	-	-
	AE lesions	+	+	+	-
	Internalization	-	+	+	-
Spiral colon	Congestion	+	+	-	+
	Infl. cells.	L	PMN	L, PMN, E	-
	Abcess	-	-	-	-
	Villosity atrophy	-	+	-	-
	AE lesions	+	+	-	-
	Internalization	-	+	-	-
Descending colon	Congestion	+	+	-	+
	Infl. cells.	PMN, L	PMN, M	L, PMN	-
	Abcess	-	-	-	-
	Villosity atrophy	-	+	-	-
	AE lesions	+	+	-	-
	Internalization	-	-	-	-
Lymph node	Congestion	+	+	+	+
	Bacteria	-	-	-	-
	Activity	Intensive	Intensive	Intensive	Restricted
	Infl. cells.	-	PMN	PMN, N	PMN
Brain	Congestion	+	+	-	+
	Infl. cells.	-	-	-	-
	Bacteria	-	-	-	-

^a presence; ^b absence; ^c polymorphonuclear leukocytes; ^d lymphocytes; ^e macrophages; ^f eosinophiles; ^g inflammatory cells.

observed in two of the three calves (*table II*). It is also worth noting that strain 340S89, and several other EHEC and EPEC bovine strains, give images of internalization into the enterocytes when tested in the rabbit ligated

intestinal loop assay [4, 12]. The significance of this stage is unknown but may be related to the invasion of the calf by the bacteria. Indeed, the challenge strain was isolated from the mesenteric lymph nodes of the same two calves.

However the challenge strain was never detected in other organs or in heart blood.

In summary, bovine EHEC strain 340S89 belonging to serotype O118:H16 and isolated from a calf with diarrhoea, was able to induce diarrhoea and to produce AE lesion in newborn calves. Presence of other infectious diarrhoeagenic agents can influence the severity and the length of the diarrhoea. This model can be used for further challenge experiments to study the role of the different genes of the LEE and of VT1 in the pathogenesis of bovine EHEC strains and to study the host specificity of EHEC strains belonging to the same serotype and isolated from both cattle and humans.

Acknowledgments

We thank Dr C. Manteca from Provincial Laboratory of Loncin (Liège, Belgium) for performing the Trousse ELISA digestive assay. Philippe Stordeur was supported by a studentship from the Ministry of Middle Classes and Agriculture. This work was also financially supported by the Ministry of Middle Classes and Agriculture (convention 5740 A).

References

- [1] Brown C.A., Harmon B.G., Zhao T., Doyle M.P., Experimental *Escherichia coli* O157:H7 carriage in calves, *Appl. Environ. Microbiol.* 63 (1997) 27–32.
- [2] Chanter N., Morgan J.H., Bridger J.C., Hall G.A., Reynolds D.R., Dysentery in gnotobiotic calves caused by atypical *Escherichia coli*, *Vet. Rec.* 114 (1984) 71.
- [3] China B., Pirson V., Mainil J., Typing of bovine attaching and effacing *Escherichia coli* by multiplex in vitro amplification of virulence-associated genes, *Appl. Environ. Microbiol.* 62 (1996) 3462–3465.
- [4] China B., Pirson V., Jacquemin E., Main et al., Pathotypes of bovine verotoxigenic *Escherichia coli* isolates producing attaching/effacing lesions in the ligated intestinal loop assay in rabbits, in : Paul et al. (Eds.), *Mechanisms in the pathogenesis of enteric diseases*, Plenum Press, New York, 1997, pp. 311–316.
- [5] China B., Pirson V., Mainil J., Prevalence and molecular typing of attaching and effacing *E. coli* among calf population in Belgium, *Vet. Microbiol.* 63 (1998) 249–259.
- [6] Cray W.C., Moon H.W., Experimental infection of calves and adult cattle with *Escherichia coli* O157:H7, *Appl. Environ. Microbiol.* 61 (1995) 1586–1590.
- [7] Dean-Nystrom E.A., Bosworth B.T., Cray W.C.J.R., Moon H.W., Pathogenicity of *Escherichia coli* O157:H7 in the intestines of neonatal calves, *Infect. Immun.* 65 (1997) 1842–1848.
- [8] Donnenberg M.S., Calderwood S.B., Donohue-Rolfé A., Keusch G.T., Kaper J.B., Construction and analysis of TnpHoA mutants of enteropathogenic *Escherichia coli* unable to invade Hep-2 cells, *Infect. Immun.* 60 (1990) 1565–1571.
- [9] Donnenberg M.S., Kaper J.B., Enteropathogenic *E. coli*, *Infect. Immun.* 60 (1992) 3953–3961.
- [10] Donnenberg M.S., Tacket C.O., Janes S.P., Losonsky G., Nataro J.P., Wasserman S.S., Kaper J.B., Levine M.M., Role of the *eaeA* gene in experimental enteropathogenic *E. coli* infection, *J. Clin. Invest.* 92 (1993) 1412–1417.
- [11] Gassner G., Ein neuer dreifarbenbennahrboden zur Typhus-Rhur-Diagnose, *Zbl. Bakt. Parasiten Infekt. Hyg. Abt. I. Orig.* 80 (1918) 219–222.
- [12] Goffaux F., Mainil J., Pirson V., Charlier G., Pohl P., Jacquemin E., China B., Bovine attaching and effacing *Escherichia coli* possess a pathogenesis island related to LEE of the human enteropathogenic *Escherichia coli* E2348/69, *FEMS Microbiol. Lett.* 154 (1997) 415–421.
- [13] Gonzales E.A., Blanco J., Serotypes and antibioresistance of verotoxigenic (VTEC) and necrotoxicogenic (NTEC) *Escherichia coli* strains isolated from calves with diarrhea, *FEMS Microbiol. Lett.* 60 (1989) 31–36.
- [14] Hall G.A., Reynolds D.J., Chanter N., Morgan J.H., Parsons K.R., Debney T.G., Bland A.P., Bridger J.C., Dysentery caused by *Escherichia coli* (S102-9) in calves: natural and experimental disease, *Vet Pathol.* 22 (1985) 156–163.
- [15] Knutton S., in: Gyles C.L. (Eds), *Escherichia coli* in domestic animals and humans, Cab International, Wallingford, 1994, pp. 567–591.
- [16] Mainil J., Pohl P., Les souches attachantes et effaçantes d'*Escherichia coli* d'origine bovine, *Ann. Méd. Vét.* 138 (1994) 419–429.
- [17] Mainil J., Shiga/Verocytotoxins and Shiga/verotoxigenic *Escherichia coli* in animals, *Vet. Res.* 30 (1999) 235–257.
- [18] Mainil J.G., Jacquemin E., Kaeckenbeek A., Pohl P., Association between the effacing gene (*eae*) and the Shiga-like toxin encoding genes in *Escherichia coli* isolates from cattle, *Am. J. Vet. Res.* 54 (1993) 1064–1068.
- [19] Mainil J.G., Duschesnes C.J., Whipp S.C., Marques L.R.M., O'Brien A.D., Casey T.A., Moon H.W., Shiga-like toxin production and attaching effacing activity of *Escherichia coli* associated with calf diarrhea, *Am. J. Vet. Res.* 48 (1987) 743–748.
- [20] McDaniel T.K., Jarvis G., Donnenberg M.S., Kaper J.B., A genetic locus of enterocyte effacement conserved among diverse enterobacterial pathogens, *Proc. Natl. Acad. Sci. USA* 92 (1995) 1664–1668.
- [21] Milon A., Oswald E., DeRycke J., Rabbit EPEC: a model for the study of enteropathogenic *Escherichia coli*, *Vet. Res.* 30 (1999) 203–219.
- [22] Moon H.W., Whipp S.C., Argenzio R.A., Levine M.M., Gianella R.A., Attaching and effacing activities of rabbit and human enteropathogenic *Escherichia coli* in pig and rabbit intestines, *Infect. Immun.* 53 (1983) 1340–1351.
- [23] Moxley R.A., Francis D.H., Natural and experimental infection with an attaching and effacing strain of *Escherichia coli* in calves, *Infect. Immun.* 53 (1986) 339–346.
- [24] Nataro J.P., Kaper J.B., Diarrheagenic *Escherichia coli*, *Clin. Microbiol. Rev.* 11 (1998) 142–201.
- [25] Paton J.C., Paton A.W., Pathogenesis and Diagnosis of Shiga Toxin-Producing *Escherichia coli* Infections, *Clin. Microbiol. Rev.* 11 (1998) 450–479.
- [26] Peeters J.E., Les *Escherichia coli* entéropathogènes (EPEC) du lapin, *Ann. Méd. Vét.* 137 (1993) 361–368.

- [27] Pohl P., Daube G., Lintermans P., Kaeckenbeeck A., Mainil J., Description de 70 souches D' *Escherichia coli* D' origine bovine possédant les gènes des vérotoxines, Ann. Méd. Vét. 135 (1991) 267–272.
- [28] Scaletsky I.C.A., Pedroso M.Z., Fagundes-Neto U., Attaching and effacing enteropathogenic *Escherichia coli* O18ab invades epithelial cells and causes persistent diarrhea, Infect. Immun. 64 (1996) 4876–4881.
- [29] Schoonderwoerd M., Clarke R.C., VanDreumel A.A., Rawluk S.A., Colitis in calves : natural and experimental infection with a verotoxin-producing strain of *Escherichia coli* O111:NM, Can. J. Vet. Res. 52 (1988) 484–487.
- [30] Sojka W.J., *Escherichia coli* in domestic animals and poultry, Review serie n° 7 of the commonwealth bureau of animal health, Weybridge, 1965.
- [31] Wieler L.H. Determination of virulence factors in bovine Shiga-Toxin-producing *Escherichia coli* (STEC) strains and a critical review of their clinical relevance to bovines and man, (Eds.), Shaker Verlag, Aachen, 1997.
- [32] Wray C., McLaren I., Pearson G.R., Occurrence of attaching and effacing lesions in the small intestine of calves experimentally infected with bovine isolates of verocytotoxic *E. coli*, Vet. Rec. 125 (1989) 365–366.