LAB 1: ANATOMICAL LANGUAGE

LAB 1: ANATOMICAL LANGUAGE

MEASURABLE OUTCOMES

- Understand what the standard anatomical position is.
- Correctly identify a given plane by its correct name.
- Relate different structures of the body using the directional terms provided.
- Correctly identify the anatomical regions of the body.
- Demonstrate how to properly focus histology slides and identify key structures.
- Demonstrate an adequate understand of the material in this section.

BACKGROUND

A solid foundation is essential when learning any new skill. Understanding anatomical directions, articulations, planes, and regions are the foundation for learning anatomy.

The standard anatomical position of the human body is facing towards the observer, legs hip-width apart, feet facing forward, arms out slightly at either side with palms facing forward. When determining a structure's relative position, be sure to use this frame of reference. For example, it can be easy to confuse which side is the anterior aspect of the hands, therefore, one might incorrectly assume that the thumb is medial to the little finger. Remember, the anterior aspect of the hand is the palm, therefore the thumb is furthest from the center of the body and is lateral.

The archetypal body planes are frontal, sagittal and transverse planes. The frontal plane splits the body into anterior and posterior halves. The sagittal plane splits the body into left and right halves. The transverse plane splits the body into superior and inferior (top and bottom) halves. It is important to be able to identify a given plane so that you can orient yourself when a specimen, model or diagram is depicted a certain way. This same reasoning applies to the necessity of understanding directional terms such as anterior, inferior, distal and medial. It is recommended that you read the content prior to attending lab to make the most of your time.

Vocabulary for Anatomical Language on page(s) 160-161.

PRE-LAB 1

(5 points)

Last Name: _____ First Name: _____

INSTRUCTIONS:

Fill in the table below with the appropriate terms. Note: For this lab only, you may use any anatomical structure of the human body to fill in the table.

For the remaining pages of the prelab, label the designated planes, regions, and directions.

(1 point)

Name of a structure	is	directional term	to	Name of the second structure
forearm*	is	proximal	to	hand*
head	is	superior	to	
	is	inferior	to	tibia
breast	is	anterior	to	
	is	distal	to	upper arm
brain	is	medial	to	
	is	lateral	to	trunk

Label the planes of the body. (1 point)

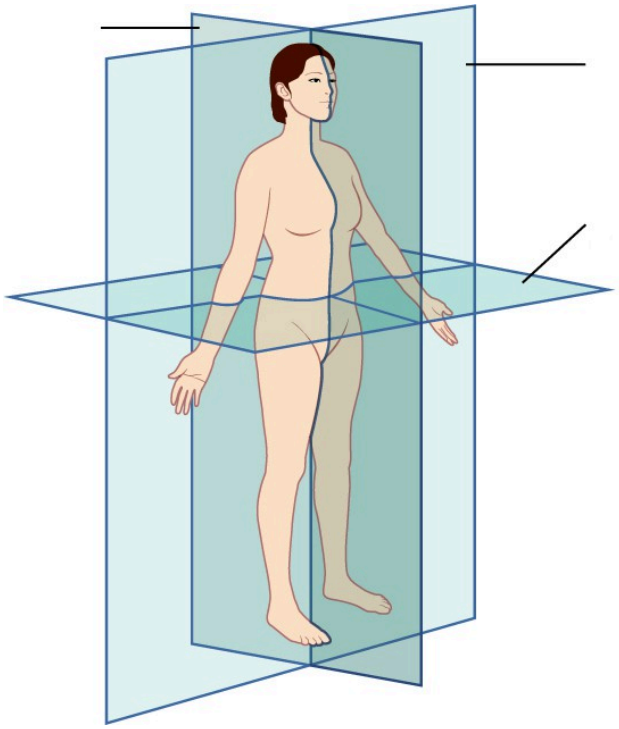

Planes of Body

Label all nine regions of the abdomen. (1 point)

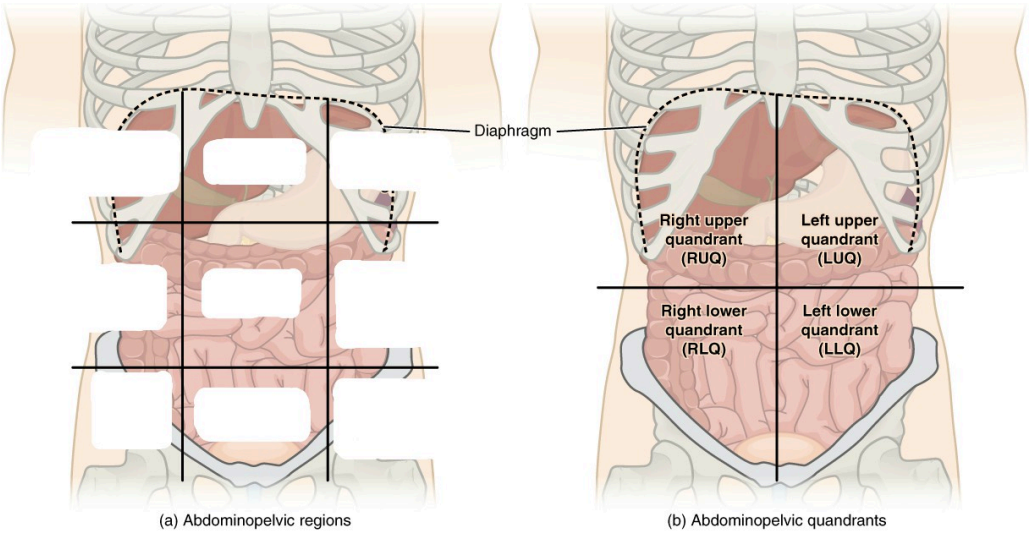

Label the anatomical directions designated by the lines and arrows. (1 point)

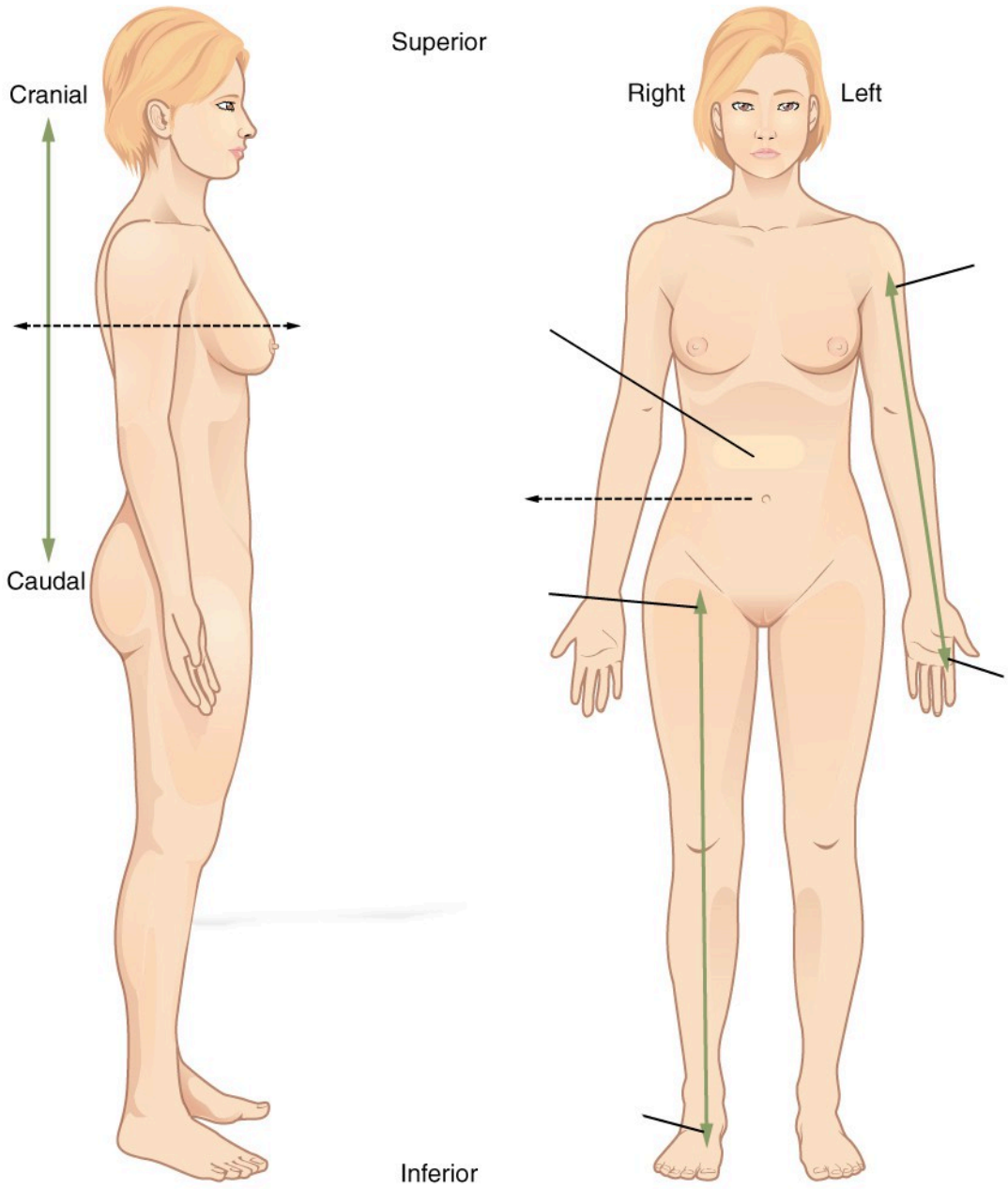

Label the regions of the body. (1 point)

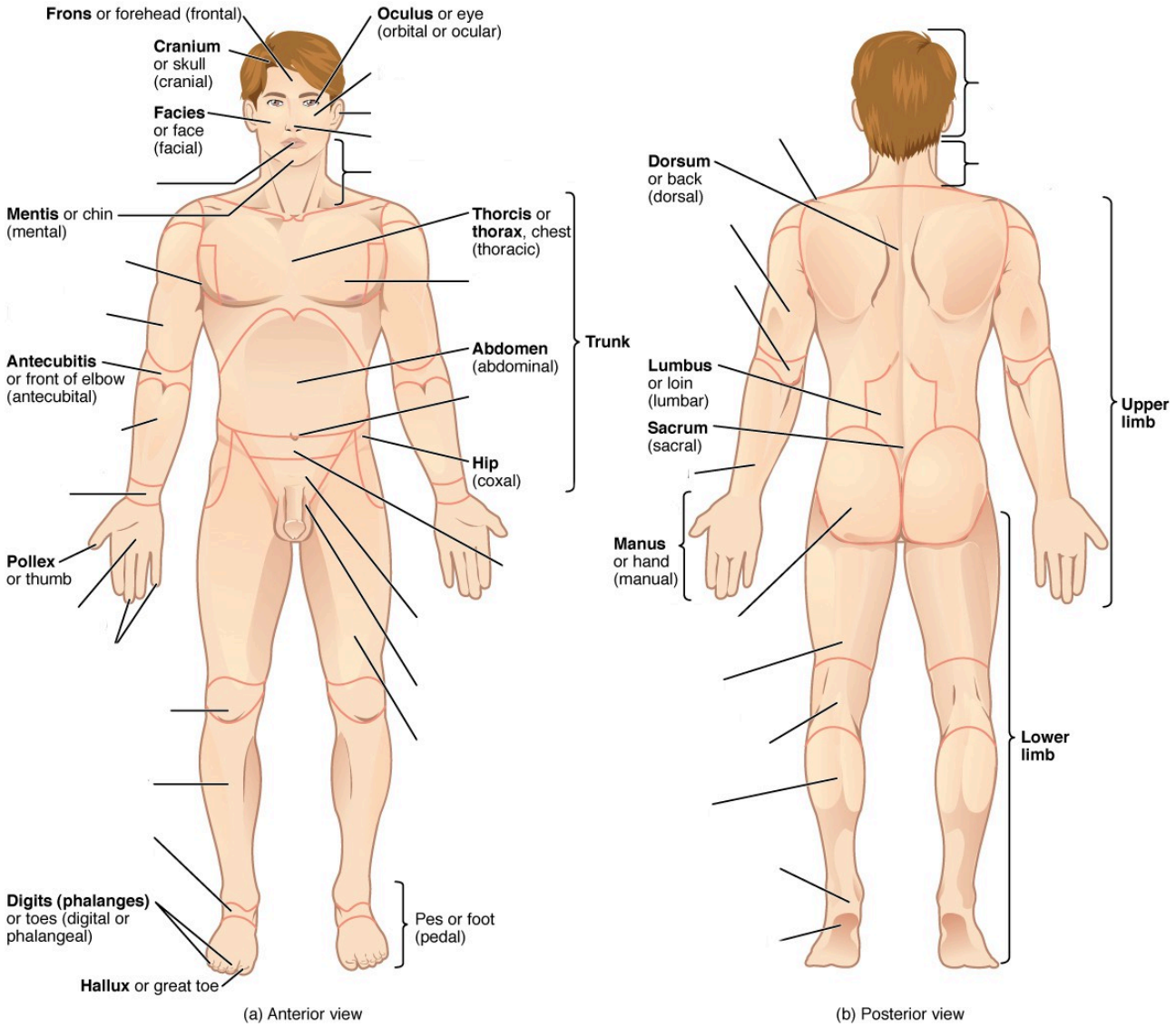

For this lab only, there will be three stations for each group to cycle through, stations one, two and three; stations four, five and six will mirror these stations for this lab only. A list of words is provided below that you are expected to identify, learn, and label on the models provided. You must use all the words provided. Using the colored tape provided, write the number that corresponds to the organ/structure and place it on your model. When complete, notify your TA so they may check your work.
Note: Do not simply label the models, it is crucial that you understand how to apply all of these terms in each system, for the rest of the semester!
For each additional station, directions will be provided for the particular activity.

STATIONS ONE AND SIX: HISTOLOGY

This is an advanced biology class, therefore you all likely have experience with microscopes. However, use these stations to refresh your memory of proper microscope etiquette, how to focus on a slide, and identify key features. For the remainder of this class, you will be expected to identify various tissues under the microscope. Be sure to ask your TA for assistance, and remember taking a picture of the slide to study later is not helpful if you don't take the time to study it in lab and understand which aspects are most important.

Basic instructions for use:

- Turn on the microscope. Move he stage down to its lowest setting and adjust the iris diaphragm until it allows the least amount of light in.
- Put the slide in position on the stage and be sure to start with the 5x objective to view it. While looking through the eyepiece, use the stage controls to move the specimen in line with the objective.
- Using the coarse adjustment knob, bring the stage up until you can see the specimen. Remember, it will not be in focus! If you bring the stage up too high, then switching to a higher objective, may touch the slide, scratch the lens, or even break the slide. Instead, use the fine adjustment knob to clarify the image and the iris diaphragm to allow as much light in as needed.
- Once the 5x is in focus, you can move to the next objective. Use the fine adjustment knob to focus before moving to the next objective. Do NOT touch the coarse adjustment knob.
- When you finish using the microscope, move the 5x objective to the start position and move the stage back down to its lowest position.

Sketch the slides available for today's lab and indicate the magnitude at which you are observing/sketching. Be sure to identify, include, and label your sketch with the corresponding structures listed beneath each slide. Use the images provided to guide you through this process.



Spinal Cord



Kidney

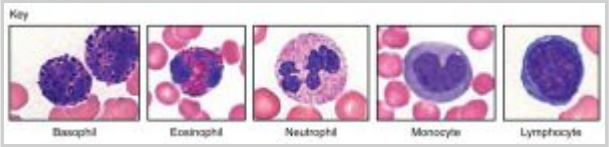

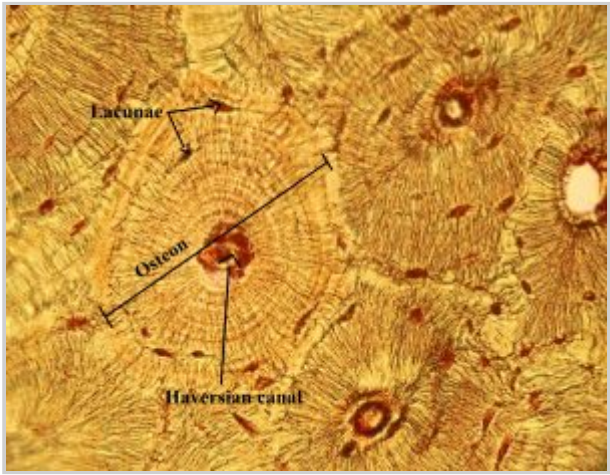





Spinal Cord

Kidney

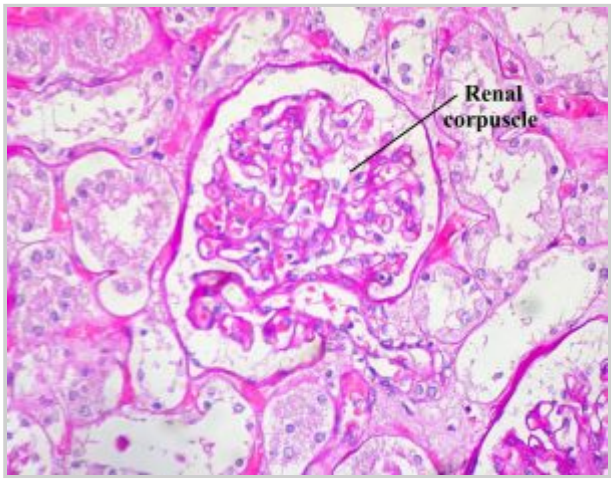



Monocyte

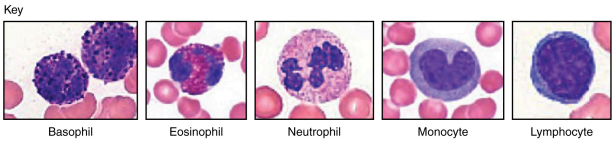



Compact Bone

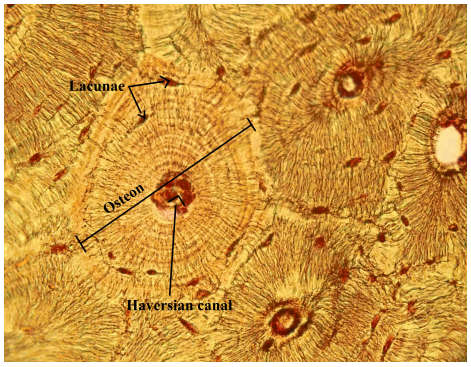



Spinal Cord

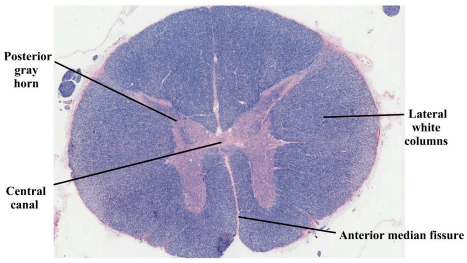



Kidney

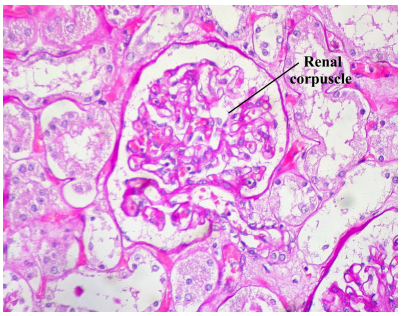

STATIONS TWO AND FIVE: THE BASICS

The terms in the following tables are important in understanding the relationship between different organs and structures of the body. Using the models and diagrams in your atlas, learn

how to identify the different body planes and the appropriate use of directional terms. When trying to understand body movements, it is helpful to act them out yourself.

Label the torso models of this station with the number that corresponds to the appropriate regions of the abdominal cavity using the colored tape. When you are finished, ask your TA to check your labeling. Before leaving the station, remove all of the labels you have placed on the model. Note the locus of each organ within each region.

Body Planes

#1 frontal	#2 transverse	#3 sagittal

Directional Terms

#4 anterior	#7 inferior	#10 proximal	#13 superficial
#5 posterior	#8 lateral	#11 distal	#14 parietal
#6 superior	#9 medial	#12 deep	#15 visceral

Abdominal Regions

#16 right hypochondriac region	#19 right lumbar region	#22 right iliac region
#17 epigastric region	#20 umbilical region	#23 hypogastric region
#18 left hypochondriac region	#21 left lumbar region	#24 left iliac region

STATIONS THREE AND FOUR: REGIONS OF THE BODY

Label the models of this station with the number that corresponds to the appropriate structure of the peripheral nervous system using the colored tape. When you are finished, ask your TA to check your labeling. Before leaving the station, remove all the labels you have placed on the model.

Anatomical Regions

#1 cephalic	#11 brachial	#21 abdominal	#31 femoral
#2 cranial	#12 cubital	#22 hepatic	#32 patellar
#3 ocular (orbital)	#13 antecubital	#23 renal	#33 popliteal
#4 auricular (otic)	#14 olecranal	#24 umbilical	#34 crural
#5 buccal	#15 antebrachial	#25 lumbar	#35 sural
#6 nasal	#16 carpal (carpus)	#26 pelvic	#36 tarsal (tarsus)
#7 oral	#17 palmar	#27 inguinal	#37 calcaneal
#8 cervical	#18 digital (phalangeal)	#28 pubic	#38 pedal
#9 acromial	#19 thoracic	#29 sacral	#39 plantar
#10 scapular	#20 mammary	#30 gluteal	

Common Anatomical Features

The following terms are useful to know and understand as they will reappear throughout this course.

#40 process	#45 sulcus	#50 facet	#54 septum
#41 tuberosity	#46 gyrus	#51 fossa	#55 raphe
#42 condyle	#47 foramen	#51 fundus	#56 ampulla
#43 epicondyle	#48 foramina	#52 hilum	
#44 fissure	#49 meatus	#53 isthmus	

POST-LAB 1 QUESTIONS

(2 points)

Last Name: _____ First Name: _____

1. Give the name of the anatomical region to which each of the following structures belongs. (0.5 points)
    a. Elbow
    b. Back of the knee
    c. Belly button
    d. Heel
    e. Back of the neck

2. Determine which body plane is described by each of the following scenarios. (0.5 points)
    a. If the human body were split into left and right halves.
    b. If the human body were split into anterior and posterior halves.
    c. If the human body were split into superior and inferior halves

3. There are nine abdominal regions. Name the three consecutive regions that run down the center of the abdomen. (0.5 points)

4. Fill in the blanks with the correct anatomical direction. (0.5 points)
    a. Phalanges (fingers) are _____ to the carpals (wrist).
    b. The tibia (medial bone of the lower leg) is _____ to the femur (large bone of the thigh).
    c. The sural region is _____ to the crural region.
    d. The left and right iliac regions are _____ to the hypogastric region of the abdominal cavity.
    e. The nose is _____ to the ears.
    f. The abdomen is _____ to the back.