LAB 2: BONES AND BONE MARKINGS

LAB 2: BONES AND BONE MARKINGS

MEASURABLE OUTCOMES

- Determine if a given bone is part of the axial or appendicular skeleton.
- Ascertain the major bones of the skull, as well as any markings or unique features, the regions of the vertebral column, parts of a typical vertebra, along with the other bones and features of the axial skeleton.
- Identify the bones of the appendicular skeleton and their unique features.
- Designate bones as either left or right when applicable. Examples include the ulna, humerus, femurs, scapulas, and clavicles.
- Understand how different bones fit together and articulate. Demonstrate this by assembling different regions of the body using the bones provided.
- Differentiate compact, spongy and dry bone histology slides. This includes identifying the unique characteristics of each.
- Demonstrate an adequate understand of the material in this section.

BACKGROUND

The skeletal system is the primary structural organ system of the body. Many people think of the skeletal system as being static in that it is unchanging, however, this is not the case. Bones, like other organ systems, have specialized cells which allow them to perform a variety of essential tasks. Osteoblast are responsible for secreting the bony matrix necessary for bone formation. Osteoclast, meanwhile, are large multinucleated cells responsible for the dissolution and reabsorption of bone. It is made mostly of collagen, which gives bone its soft framework, and calcium phosphate which adds strength and hardness to the structure. It is divided into the axial and the appendicular skeleton. The *axial skeleton* consists of the skull, hyoid bone, vertebral column, sternum, and ribs. Whereas the *appendicular skeleton* consists of the clavicle, scapula and the rest of the upper and lower limbs. Without the foundational structure of the skeletal system, there would be nothing to support the body and provide points of attachment for muscles. Bones function to protect internal organs, assist body movements, store and release calcium and phosphorous, participate in blood cell production and store fat in the yellow marrow. Bones also function to protect internal organs, assist body movements, and the storage and release of ions such as calcium and phosphorous. Furthermore, long bones contain both hemopoietic (red) and stromal (yellow) marrow which produce red blood cells and fat cells respectively. Each of these cells have specific functions that are key to the development and repair of a bone over time. The two types of bone tissue are compact and spongy bone. *Compact bone* is typically found along the perimeter of bones and makes up the majority of the diaphysis of long bones. It is stronger than spongy bone and provides more stability. Compact bone is made up of circular units called osteons. Osteons are composed of rings called *lamellae* that spiral down into a central canal, known as the *Haversian canal*. This central canal is the passage for nerves, blood vessels, and lymphatics. *Spongy bone*, on the other hand, is typically the deepest layer of a bone's composition. It is made of

trabeculae which give spongy bone its characteristic lighter weight. There are five classifications of bones based on their shape, long bones, short bones, flat bones, irregular bones and sesamoid bones. The shape and composition of each bone allow them to function as mentioned above.

Vocabulary for Bones and Bone Markings on page(s) 161-162.

PRE-LAB 2

(5 points)

Last Name: _____ First Name: _____

INSTRUCTIONS:

Fill in the table with the appropriate terms. For the remaining illustrations, label the structures indicated.

(1 point)

Name of a structure	is	directional term	to	Name of the second structure
radius*	is	proximal	to	ulna*
femur	is	superior	to	
	is	inferior	to	thoracic vertebrae
patella	is	anterior	to	
	is	distal	to	metacarpals
tibia	is	medial	to	
	is	lateral	to	sternum

Label the cranial structures and bones. (0.5 points)

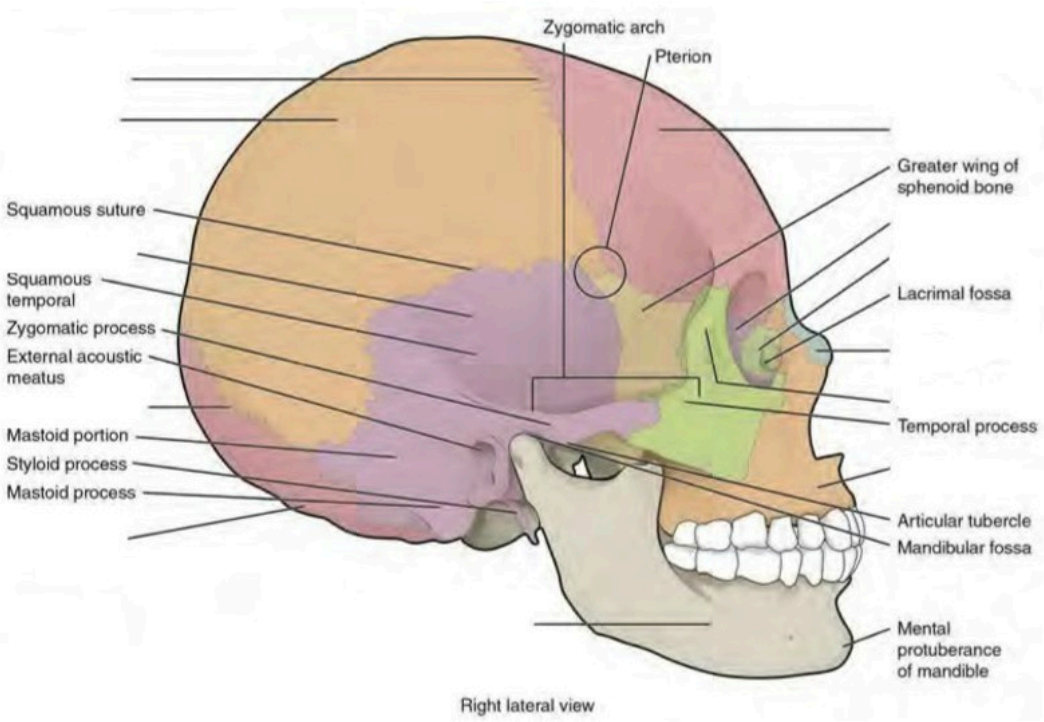

Label the cranial bones and special features. (0.5 points)

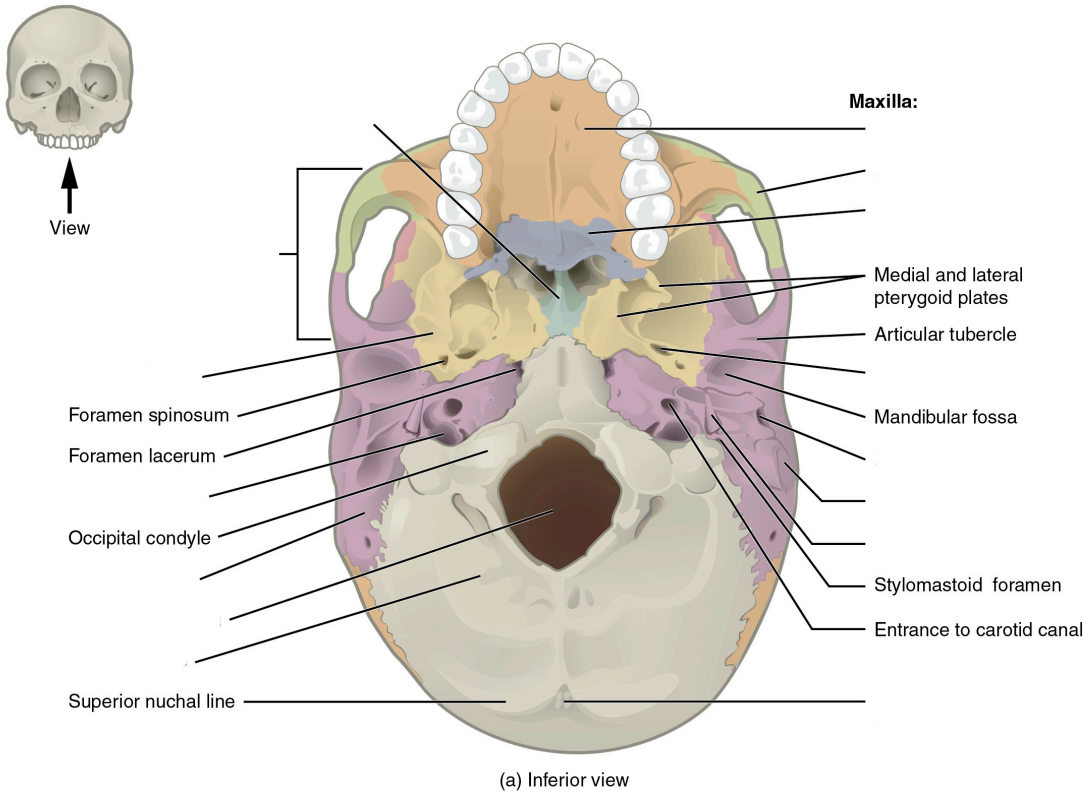

Label the distinctive parts of the vertebra. (0.5 points)

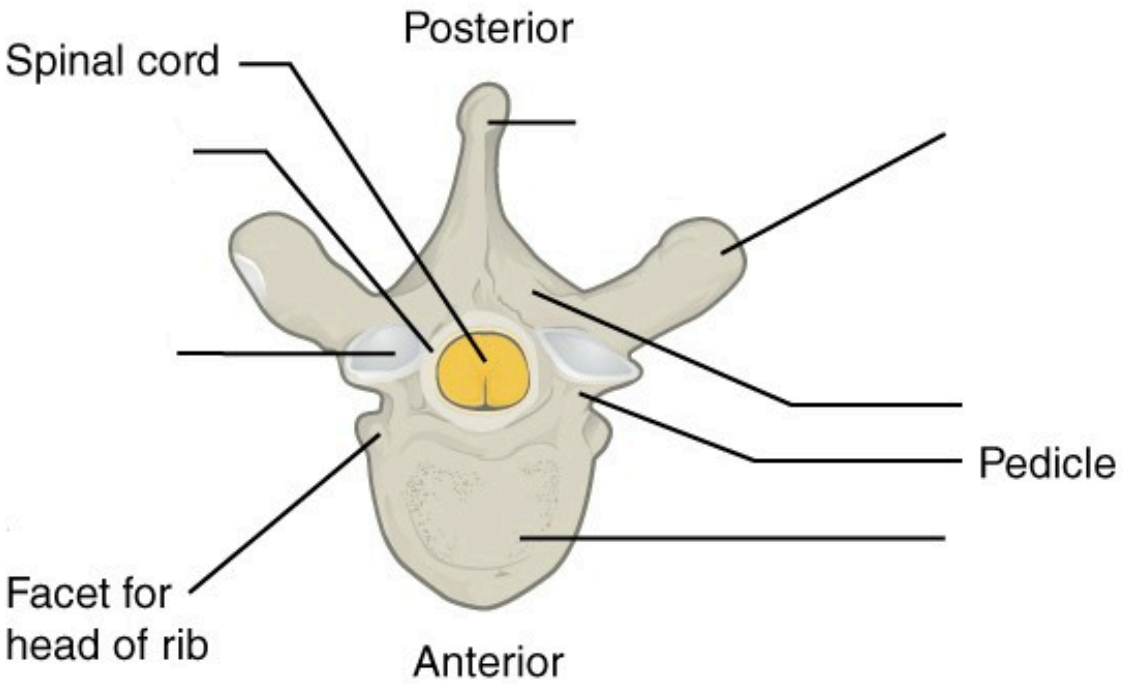

Label the features of the scapula. (0.5 point)

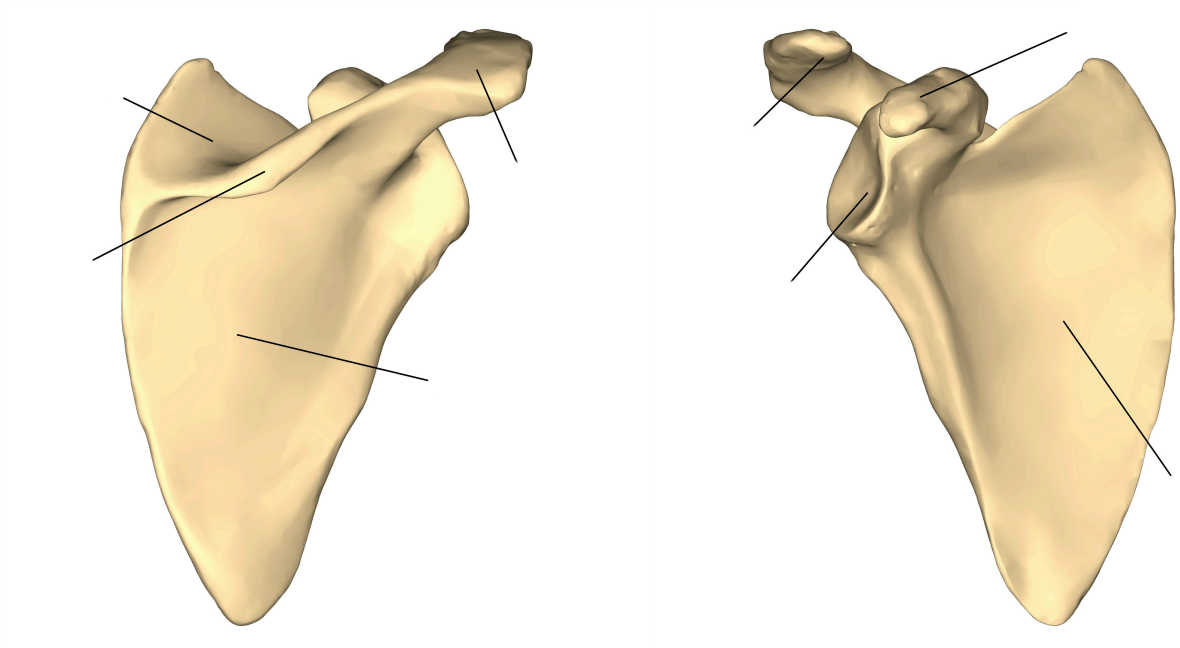

Label the features of the humerus. (0.5 points)

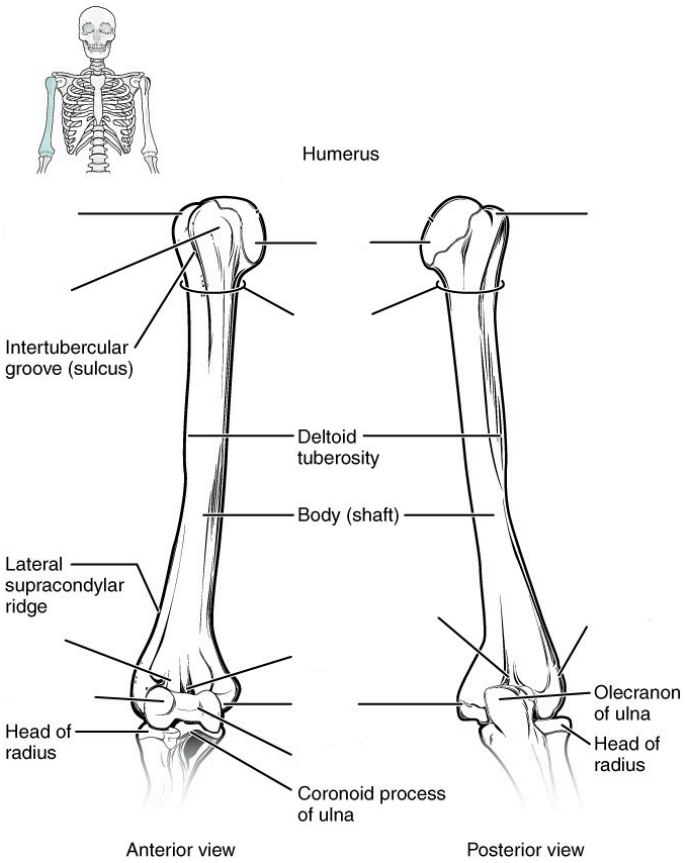

Label the features of the radius and ulna. (0.5 point)

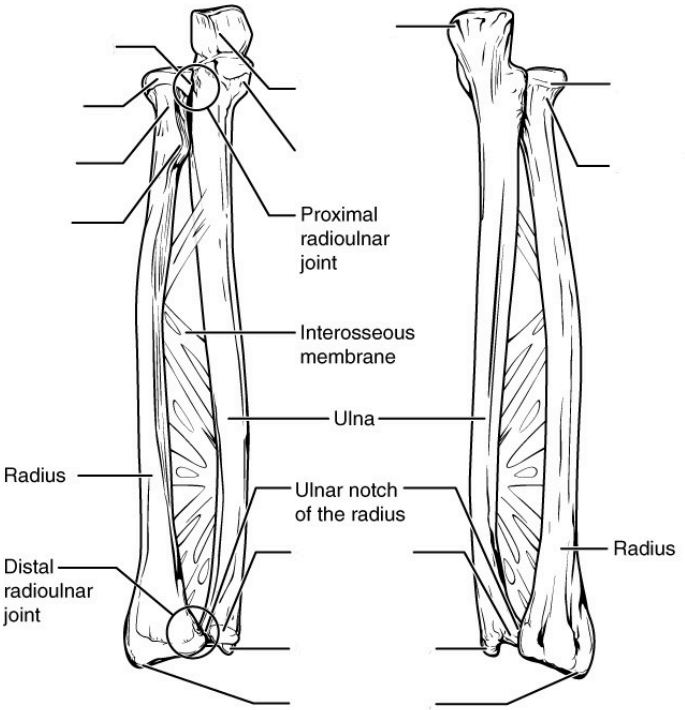

Label the features of the femur. (0.5 points)

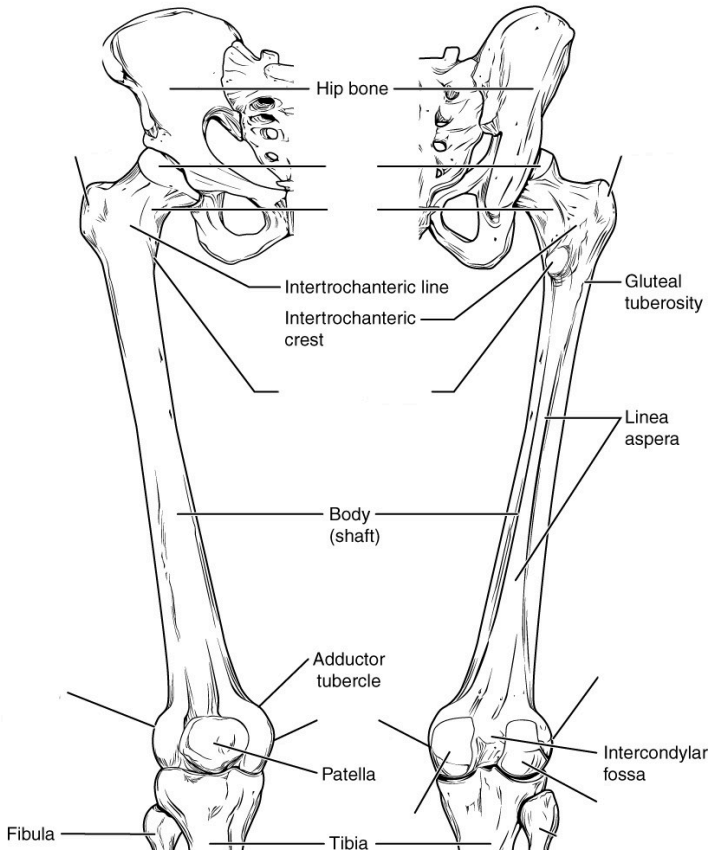

Label the features of the tibia and fibula. (0.5 points)

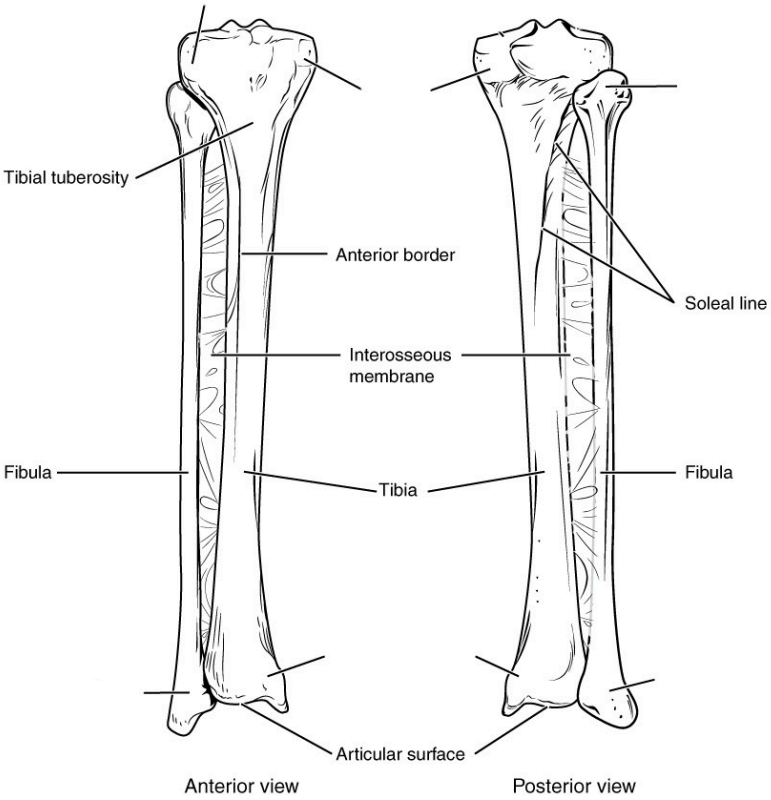

A list of words is provided below that you are expected to identify, learn, and label on the models provided. Note that not all models will have some of the organs/structures, so be sure to find them on an alternate model. You must use all the words provided. Using the colored tape provided, write the number that corresponds to the organ/structure and place them on your model. When complete, notify your TA so they may check your work.

For each additional station, directions will be provided for the activity.

STATION ONE: SKULL

Label the models of this station with the number that corresponds to the appropriate structure of the peripheral nervous system using the colored tape. When you are finished, ask your TA to check your labeling. Before leaving the station, remove all the labels you have placed on the model.

Note: For the following structures, be able to differentiate between left and right halves when applicable.

Bones of Skull

#1 frontal bone	#5 ethmoid bone	#9 zygomatic bone	#13 superior nasal conchae
#2 parietal bone	#6 sphenoid bone	#10 nasal bone	#14 middle nasal conchae
#3 temporal bone	#7 palatine bone	#11 vomer	#15 inferior nasal conchae
#4 occipital bone	#8 maxilla	#12 lacrimal bone	#16 mandible

Skull Bone Markings

#18 external auditory meatus	#20 styloid process	#22 cribriform plate of ethmoid bone	#24 zygomatic process of temporal bone
#19 mastoid process	#21 external occipital protuberance	#23 olfactory foramina	#25 temporal process of zygomatic bone

Special Features of Skull

#26 foramen magnum	#28 foramen ovale	#30 coronal suture	#32 lambdoid suture
#27 jugular foramen	#29 sella turcica	#31 sagittal suture	

STATION TWO: AXIAL SKELETON CONT.

Label the models of this station with the number that corresponds to the appropriate structure of the peripheral nervous system using the colored tape. When you are finished, ask your TA to check your labeling. Before leaving the station, remove all the labels you have placed on the model.

Note: For the following structures, be able to differentiate between left and right halves when applicable.

Vertebral Column

#1 hyoid Bone	#4 thoracic region	#7 coccyx
#2 vertebrae	#5 lumbar region	#8 intervertebral foramen
#3 cervical region	#6 sacrum	#9 intervertebral disc

Parts of Typical Vertebra

#10 body	#12 lamina	#14 transverse process	#16 inferior articular process	#18 facet of inferior articular process
#11 vertebral foramen	#13 spinous process	#15 superior articular process	#17 facet of superior articular process	

Unique Cervical Vertebrae and Characteristics

#19 bifid spinous process	#21 atlas	#23 dens
#20 transverse foramen	#22 axis	

Thoracic Cage

#24 sternum	#26 sternal body	#28 ribs
#25 manubrium	#27 xiphoid process	#29 costal cartilage

STATION THREE: LIMB ASSEMBLY

In this station, you will be given a bucket filled with random bones some of which you will use to assemble an arm and a leg. Note below which bucket you are working with. Your assignment is to lay out the bones of each limb in their correct positions relative to each other and determine which bones do not belong to either limb. Additionally, you will need to determine whether each limb is a right or left limb; circle your results below. When you are finished, ask your TA to check whether you have assembled and identified your limbs correctly.

Bucket # _____

Upper limb: Left / Right

Lower limb: Left / Right

STATION 4: HISTOLOGY

Sketch the slides available for today's lab and specify the magnitude at which you are observing/ sketching. Be sure to identify and label your sketch with the corresponding structures listed beneath each slide.

Compact Bone Osteon Lamellae, Lacunae, Volkmann's canals, Haversian canal	**Spongy Bone**

STATION FIVE: UPPER LIMBS

Label the models of this station with the number that corresponds to the appropriate structure of the peripheral nervous system using the colored tape. When you are finished, ask your TA to check your labeling. Before leaving the station, remove all the labels you have placed on the model.

Note: For the following structures, be able to differentiate between left and right halves when applicable.

Clavicle

#1 acromial end of clavicle	#2 sternal end of clavicle

Scapula

#3 glenoid cavity	#5 coracoid process	#7 supraspinous fossa	#9 subscapular fossa
#4 acromion	#6 spine of scapula	#8 infraspinous fossa	

Humerus

#10 head	#13 lesser tubercle	#16 coronoid fossa	#19 lateral epicondyle
#11 neck	#14 trochlea	#17 radial fossa	#20 olecranon fossa
#12 greater tubercle	#15 capitulum	#18 medial epicondyle	

Ulna

#21 head	#23 trochlear notch	#25 radial notch
#22 olecranon	#24 coronoid process	# 26 styloid process

Radius

#27 head	#29 radial tuberosity
#28 neck	#30 styloid process

Hand and Wrist

#31 carpals (8)	#33 phalanges	#35 middle phalanges
#32 metacarpals	#34 proximal phalanges	#36 distal phalanges

STATION SIX: LOWER LIMBS

Label the models of this station with the number that corresponds to the appropriate structure of the peripheral nervous system using the colored tape. When you are finished, ask your TA to check your labeling. Before leaving the station, remove all the labels you have placed on the model.

Note: For the following structures, be able to differentiate between left and right halves when applicable.

Pelvis

#1 ilium	#3 ischium	#5 pubis	#7 acetabulum
#2 iliac crest	#4 ischial spine	#6 pubic symphysis	

Femur

#8 head	#11 lesser trochanter	#14 medial condyle
#9 neck	#12 medial epicondyle	#15 lateral condyle
#10 greater trochanter	#13 lateral epicondyle	#16 intercondylar fossa

17 patella

Tibia

#18 lateral condyle	#19 medial condyle	#20 medial malleolus

Fibula

#21 head	#22 lateral malleolus

Foot and Ankle

#23 tarsals (7)	#25 metatarsals	#27 proximal phalanges	#29 distal phalanges
#24 calcaneus	#26 phalanges	#28 middle phalanges	

POST-LAB 2 QUESTIONS

(3 points)

Last Name: _____ First Name: _____

1. Replace the common name of following bones with their corresponding anatomical names. (0.5 points)
    a. Fingers
    b. Hip
    c. Head
    d. Bones of the lower arm
    e. Knee
    f. Ankle
    g. Bone of the thigh
    h. Upper jaw
    i. Lower jaw
    j. Shins
    k. Tailbone
    l. Toes
    m. Collarbone
    n. Shoulder blade

2. Name five bones of the axial and appendicular skeleton. (0.5 points)
    1.
    2.
    3.
    4.
    5.
    1.
    2.
    3.
    4.
    5.

3. What makes the atlas (C1) and axis (C2) different from the rest of the vertebrae? (0.5 points)

4. What is unique about the hyoid bone? (0.5 points)

5. When a person is seated on the floor "criss-cross" style, which bones are touching the ground? (0.5 points)

6. Name a bone that is inferior (1), superior (2) and medial (3) to the radius. (0.5 points)
    1.
    2.
    3.