NEUROVISION AI DIAGNOSTICS

Department of Automated Radiology

LONGITUDINAL PROGRESSION REPORT

Patient Name:	UIA	**Patient ID:**	MRN-2603211455
Age / Gender:	3 / Male	**Report Date:**	2026-03-21 14:55:57

	Scan A (Baseline)	Scan B (Follow-up)
Date:	2026-03-21 11:23	2026-03-21 11:25
Diagnosis:	Abnormal - Tumor Detected (100.0%)	Abnormal - Tumor Detected (100.0%)

AI PROGRESSION ASSESSMENT:

COMPARISON FINDINGS:

The MRI scans conducted on 2026-03-21 at 11:23 and 11:25 both show abnormalities consistent with tumor presence, maintaining a 100.0% detection rate. No significant changes in size, shape, or characteristics of the tumor have been noted between the two scans, suggesting stability in the lesion over this short interval.

IMPRESSION & RECOMMENDATION:

The findings indicate no evidence of disease progression at this moment, as there have been no changes in the identified tumor. Continued monitoring through regular imaging is recommended to ensure any future changes can be promptly addressed. Close coordination with oncology for potential therapeutic evaluation may also be warranted.

IMAGING COMPARISON (Scan A vs Scan B):

Detected Region (A) **Detected Region (B)**

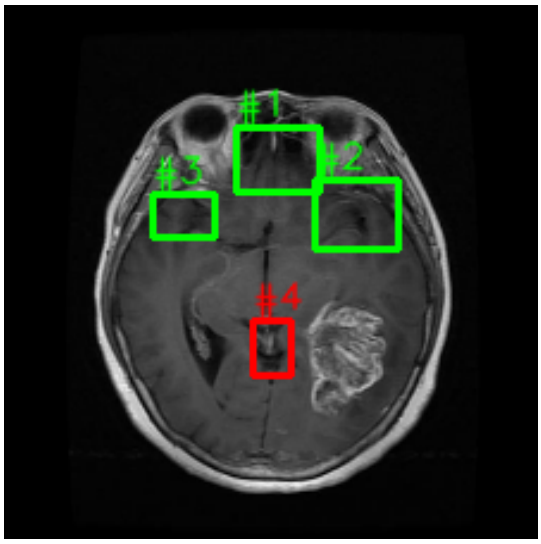

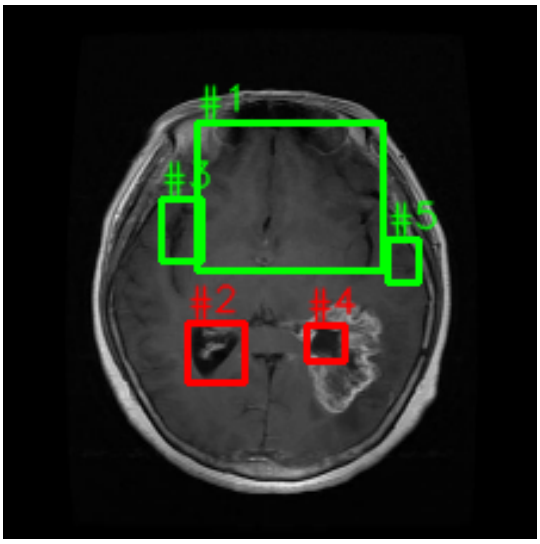

Heatmap (A)

Heatmap (B)

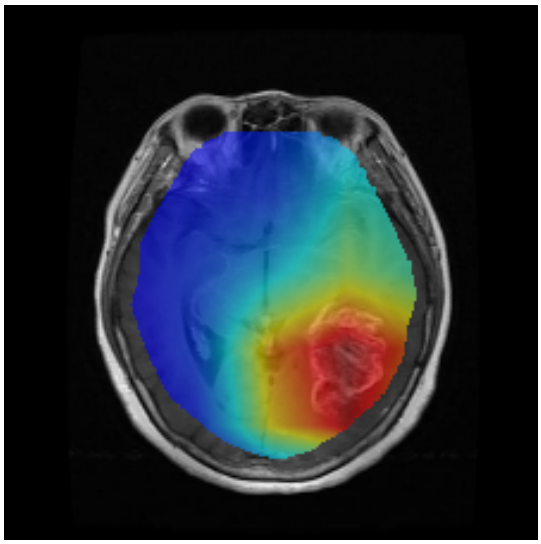

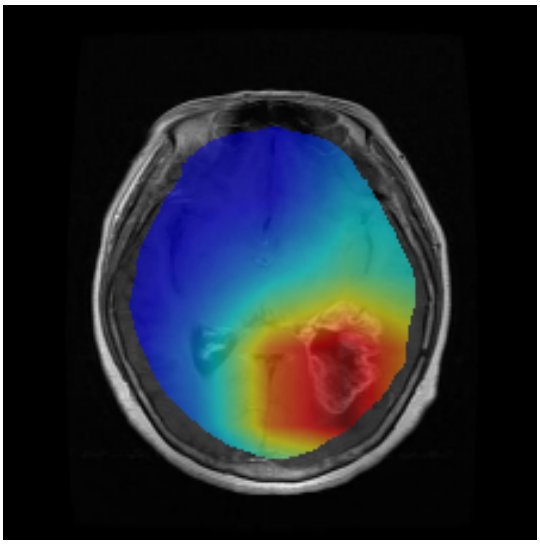

Electronically signed by:
NeuroVision Generative AI Model