NEUROVISION AI DIAGNOSTICS

Department of Automated Radiology

LONGITUDINAL PROGRESSION REPORT

Patient Name:	Master Goonway	**Patient ID:**	MRN-2603211508
Age / Gender:	500 / Male	**Report Date:**	2026-03-21 15:08:07

	Scan A (Baseline)	Scan B (Follow-up)
Date:	2026-03-21 12:09	2026-03-21 13:39
Diagnosis:	Normal (100.0%)	Abnormal - Tumor Detected (100.0%)

AI PROGRESSION ASSESSMENT:

COMPARISON FINDINGS:

The MRI results for patient Master Goonway show a significant change between the two scans. The previous scan dated March 21, 2026, at 12:09 was interpreted as normal, with no abnormalities detected. In contrast, the recent scan taken on the same day at 13:39 reveals an abnormality, specifically the presence of a tumor, which indicates a clear progression of disease status within a single day.

IMPRESSION & RECOMMENDATION:

The rapid development of an intracranial tumor in this patient signifies an aggressive disease process. Immediate further evaluation, including possible biopsy and consultation with oncology for treatment planning, is strongly recommended to address the newly identified tumor. Close monitoring and subsequent imaging may also be warranted to assess treatment response and disease progression.

IMAGING COMPARISON (Scan A vs Scan B):

Detected Region (A) **Detected Region (B)**

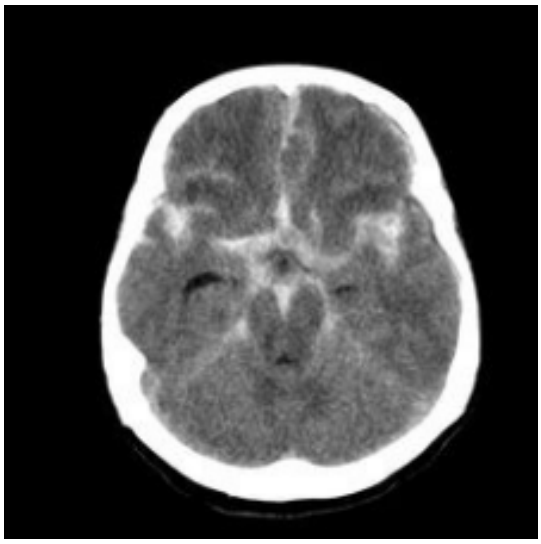

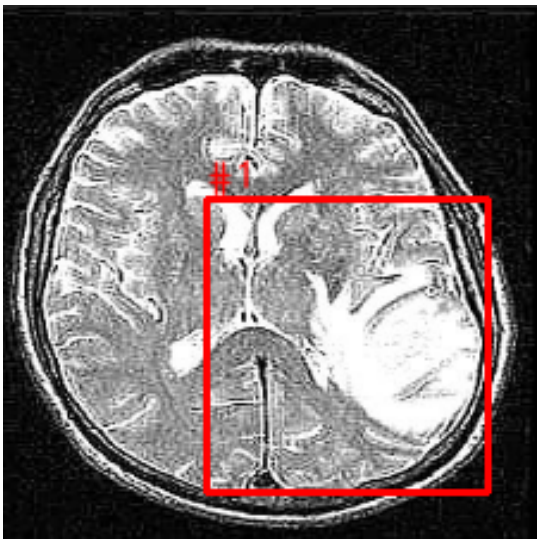

Heatmap (A)

Heatmap (B)

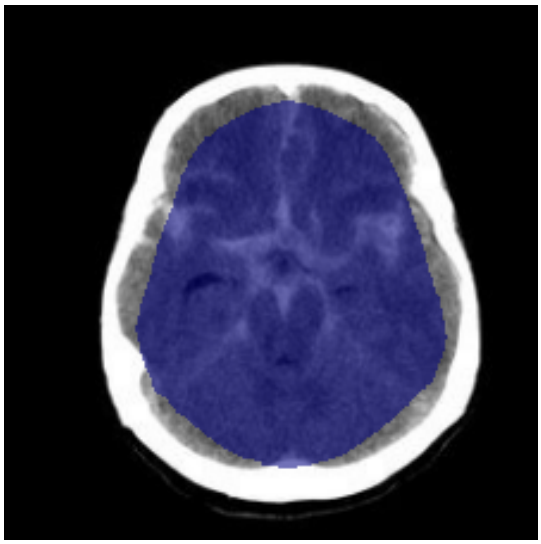

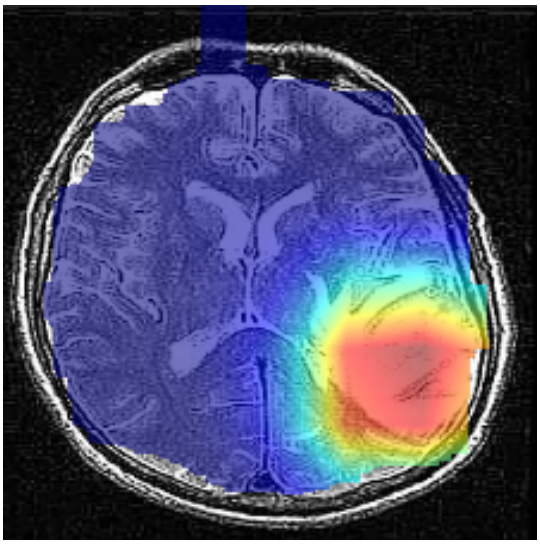

Electronically signed by:
NeuroVision Generative AI Model