NEUROVISION AI DIAGNOSTICS

Department of Automated Radiology

LONGITUDINAL PROGRESSION REPORT

Patient Name:	Master Goonway	**Patient ID:**	MRN-2603211545
Age / Gender:	500 / Male	**Report Date:**	2026-03-21 15:45:52

	Scan A (Baseline)	Scan B (Follow-up)
Date:	2026-03-21 13:39	2026-03-21 15:45
Diagnosis:	Abnormal - Tumor Detected (100.0%)	Normal (100.0%)

AI PROGRESSION ASSESSMENT:

COMPARISON FINDINGS:

The previous MRI scan dated March 21, 2026, identified an abnormality consistent with a tumor, which was confirmed with 100% accuracy. In contrast, the recent MRI scan, conducted later the same day, revealed no abnormalities, categorizing the scan as normal with 100% certainty. This significant change indicates a possible complete resolution or successful treatment of the previously detected tumor.

IMPRESSION & RECOMMENDATION:

The findings suggest an unexpected yet notable regression of the tumor previously identified. It is crucial to correlate these imaging results with clinical findings, particularly regarding any treatments administered between scans. Continuous monitoring through follow-up imaging is recommended to ensure stability and assess for any potential recurrence. Additionally, a multidisciplinary team approach is advised for ongoing management and support.

IMAGING COMPARISON (Scan A vs Scan B):

Detected Region (A) **Detected Region (B)**

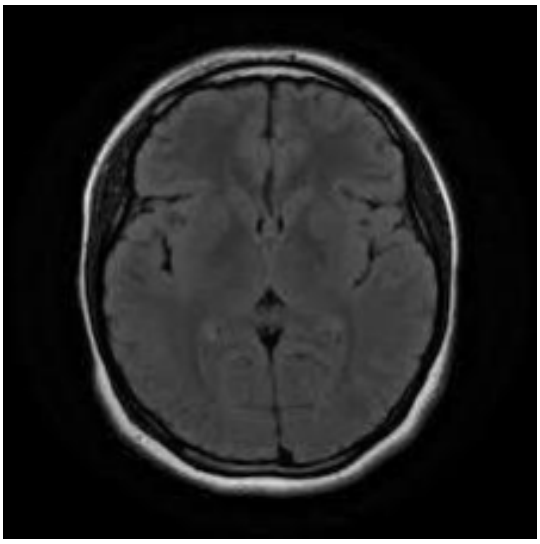

Heatmap (A)

Heatmap (B)

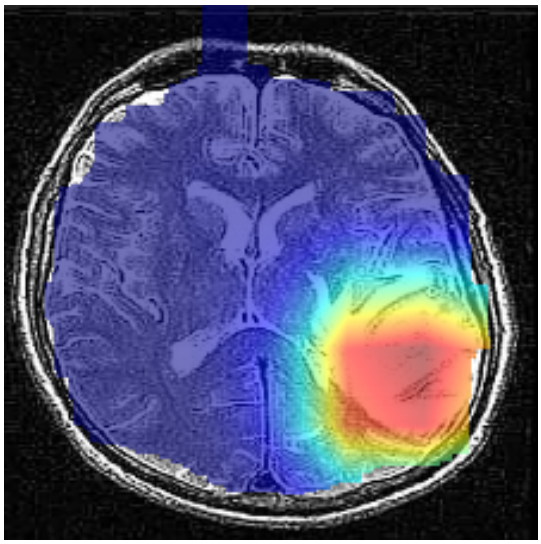

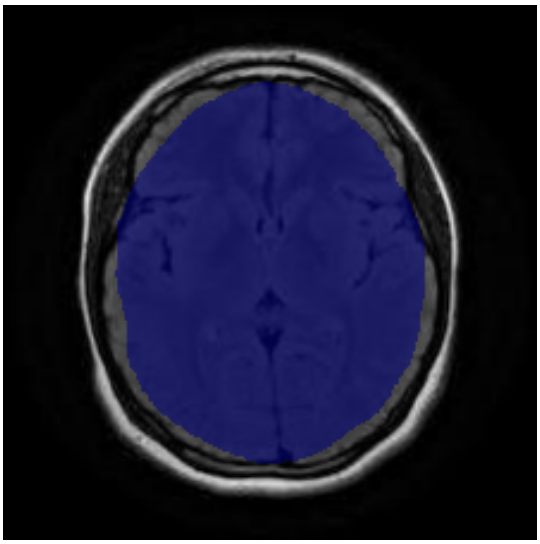

Electronically signed by:
NeuroVision Generative AI Model