NEUROVISION AI DIAGNOSTICS

Department of Automated Radiology

CLINICAL MRI REPORT

Patient Name:	vuong	**Patient ID:**	MRN-2603220034
Age / Gender:	2 / Male	**Exam Date:**	2026-03-22 00:34:49
Modality:	MRI Brain w/o Contrast	**Physician:**	Dr. NeuroVision AI
Primary Finding:	**Abnormal - Tumor Detected (100.0%)**		

FINDINGS:

The imaging reveals a well-defined mass located in the thalamic region of the brain in a 2-year-old male patient. The tumor demonstrates high signal intensity on T2-weighted images and corresponds to the AI-detected core, indicating a significant lesion with potential involvement of surrounding structures.

IMPRESSION:

The findings are consistent with a thalamic tumor, likely a glioma or a similar pediatric neoplasm. Further evaluation with advanced imaging techniques and a referral to a pediatric oncologist for management is recommended.

ATTACHED IMAGES (DETECTION & SEGMENTATION OVERLAY):

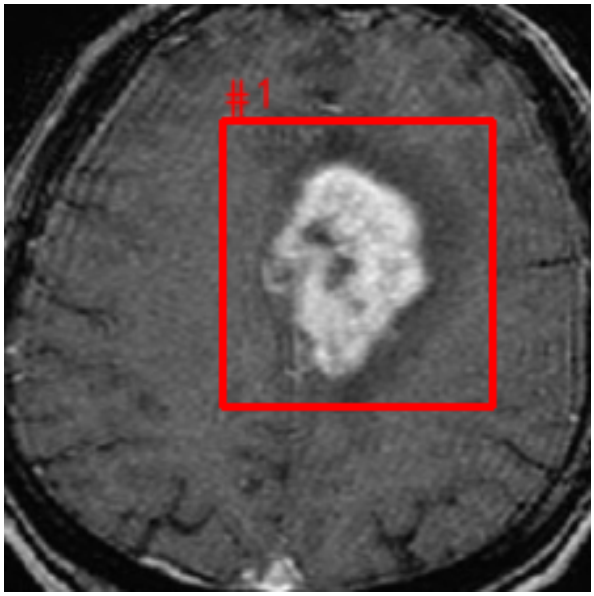

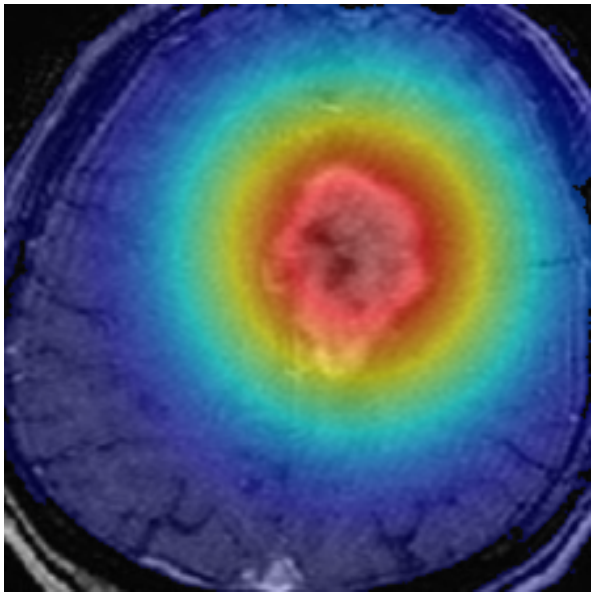

Electronically signed by:
NeuroVision Generative AI Model