AI X-RAY ANALYSIS REPORT

Report Date:	February 21, 2026
Report Time:	07:31 AM
Analysis Type:	Chest X-Ray (AI-Assisted)
Diagnosis:	Pneumonia
Confidence:	60.89%
Severity:	Moderate

Analysis Heatmap:

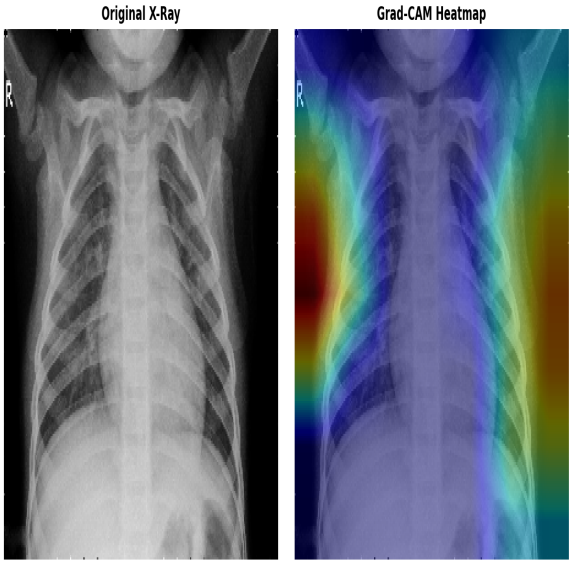

Detailed Medical Report:

RADIOLOGY REPORT
==========
EXAMINATION: Chest X-Ray (Posteroanterior View)
DATE: February 21, 2026
TIME: 07:31 AM

MODALITY: Digital Radiography
CLINICAL INDICATION:
Suspected pneumonia / AI-assisted analysis
TECHNIQUE:
Single frontal view of the chest was obtained.
FINDINGS:
There is evidence of airspace opacity in the lung fields
consistent with pneumonic consolidation.
The affected areas show increased density suggesting
active inflammatory process.
Cardiac silhouette size is within normal limits.
No pleural effusion or pneumothorax identified.
IMPRESSION:
Findings consistent with PNEUMONIA.
Airspace disease present in lung parenchyma.
AI CONFIDENCE: 60.89%
SEVERITY ASSESSMENT: Moderate
RECOMMENDATION:
- Immediate clinical correlation advised
- Consider antibiotic therapy as per clinical protocol
- Follow-up chest X-ray in 7-10 days recommended
- Consult pulmonologist if symptoms persist
NOTE: This is an AI-assisted preliminary report.
Urgent clinical correlation and confirmation by a
board-certified radiologist is strongly recommended.
==========

DISCLAIMER: This is an AI-assisted preliminary report. Final diagnosis must be confirmed by a board-certified radiologist.