MIA TEAM - AGENIX AI

MEDICAL IMAGE ANALYSIS REPORT

■ URGENCY: ROUTINE

PATIENT INFORMATION

QR N/A

Patient Name:	John Doe
Patient ID:	MIA-20260320-163434
Age:	45 years (Middle-aged Adult)
Gender:	Male
Height:	175.0 cm
BMI:	26.1 kg/m² (Overweight)
Profession:	Engineer

STUDY INFORMATION

Study Date:	2026-03-20 16:36
Study Type:	Brain MRI
Sequence:	T2
Imaging Plane:	Axial
Field Strength:	1.5T
Contrast Used:	No
Report ID:	MIA-20260320-163434
Generated By:	MIA Team - Agenix AI

■ CONFIDENTIAL MEDICAL DOCUMENT — FOR AUTHORISED PERSONNEL ONLY

TABLE OF CONTENTS

1.	Patient Information & Cover	1
2.	Table of Contents	2
3.	Findings Summary Table	3
4.	Medical Image	4
5.	Detailed Findings & Differential Dx	5-6
6.	Cross-Validation Results	7
7.	AI Confidence Breakdown	7
8.	Clinical Correlation	8
9.	Safety Analysis	9
10.	Recommendations & Follow-up	10
11.	Technical Details & QA	11

AI-ASSISTED ANALYSIS
Agenix AI

■ FINDINGS SUMMARY

ID	Location	Description	Severity	Measurements (mm)	Clinical Significance
1	Brain parenchyma	Normal gray-white matter differentiation is observed throughout the cerebral hemispheres. …	MILD	N/A	No acute or chronic parenchymal abnormalities detected.
2	Ventricular system	The lateral ventricles, including the frontal horns, bodies, trigones, and occipital horns…	MILD	N/A	Normal ventricular system, no signs of increased intracranial pressure
3	Basal ganglia and thalami	The caudate nuclei, putamen, globus pallidus, and thalami are symmetric and demonstrate no…	MILD	N/A	No abnormalities detected in the deep gray matter structures.
4	Midline structures	The midline structures are preserved, with no evidence of midline shift or mass effect.	MILD	N/A	Absence of significant space-occupying lesions or acute pathology caus

■ Critical/Severe	0	■■ Moderate	0	■ Mild	4	■ Total	4

MRI IMAGE

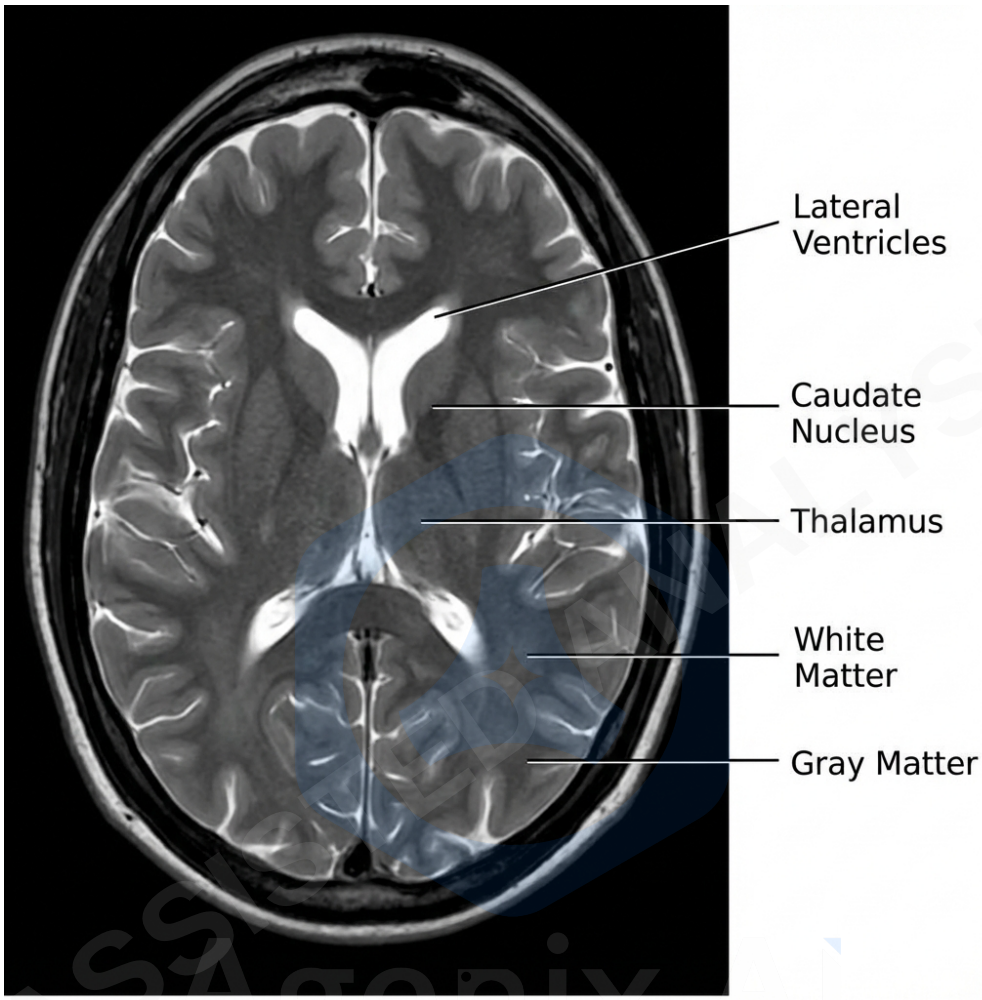

File: sample_brain.jpg | Modality: MRI

■ DETAILED FINDINGS

Finding 1: Brain parenchyma — MILD

Description: Normal gray-white matter differentiation is observed throughout the cerebral hemispheres. The cortical sulci and gyri demonstrate a normal pattern and depth for the patient's age. No focal areas of abnormal T2 signal intensity are identified within the gray or white matter.

Clinical Significance: No acute or chronic parenchymal abnormalities detected.

Finding 2: Ventricular system — MILD

Description: The lateral ventricles, including the frontal horns, bodies, trigones, and occipital horns, are symmetric and of normal size. The third ventricle is also of normal caliber. No evidence of hydrocephalus or ventricular effacement.

Clinical Significance: Normal ventricular system, no signs of increased intracranial pressure or atrophy.

Finding 3: Basal ganglia and thalami — MILD

Description: The caudate nuclei, putamen, globus pallidus, and thalami are symmetric and demonstrate normal morphology and T2 signal characteristics.

Clinical Significance: No abnormalities detected in the deep gray matter structures.

Finding 4: Midline structures — MILD

Description: The midline structures are preserved, with no evidence of midline shift or mass effect.

Clinical Significance: Absence of significant space-occupying lesions or acute pathology causing displacement.

■ IMPRESSION & CLINICAL SUMMARY

■■■

[redacted] Clinical Correlation: Patient is a 45-year-old Male. Analysis identified 4 verified finding(s). Detailed findings are documented in the report below.

AI-ASSISTED ANALYSIS
AgenixAI

CROSS-VALIDATION RESULTS

Validation Status: PASSED
Method: Dual-model consensus — Gemini 2.5 Flash (primary) + Groq LLM (secondary)
Verified Findings: All findings cross-validated using independent AI models

Consensus Score:	100.0%
Total Agreements:	0
Partial Agreements:	0
Disagreements:	0

AI CONFIDENCE BREAKDOWN

Task	Score	Confidence Bar
Gemini — Image Classification	99%	
Gemini — Vision Analysis	98%	
Groq — Report Generation	0%	

■ CLINICAL CORRELATION

Patient Profile:
• Age: 45 years (Middle-aged Adult)
• Gender: Male
• BMI: 26.1 kg/m² (Overweight)
• Profession: Engineer

Clinical Summary:
■■■

■■ SAFETY ANALYSIS

Urgency Level: ■ **ROUTINE**

Safety Score: 100.0/100

Critical Findings Identified: 0

Action Required: Routine follow-up recommended

Safety Recommendations:

- ✓ ROUTINE: Standard follow-up recommended

AI-ASSISTED ANALYSIS
Agenix AI

■ PERSONALISED RECOMMENDATIONS

• Consult with healthcare provider for detailed interpretation • Follow recommended treatment plan • Schedule follow-up imaging as advised • ✓ ROUTINE: Standard follow-up recommended

■ FOLLOW-UP PLAN

Recommended Next Steps:
• Schedule consultation with referring physician
• Discuss findings and treatment options
• Plan follow-up imaging if recommended
• Maintain regular health monitoring

Preventive Measures:
• Follow healthy lifestyle recommendations
• Adhere to prescribed medications
• Report any new or worsening symptoms immediately

AI-ASSISTED ANALYSIS
Agenix AI

TECHNICAL DETAILS & QUALITY ASSURANCE

Analysis System:	MIA - Medical Image Analysis
Version:	1.0.0
Organisation:	Agenix AI - MIA Team
Analysis Date:	2026-03-20 16:36:16
Report ID:	MIA-20260320-163434
Primary Model:	Google Gemini 2.5 Flash
Secondary Model:	Groq LLM (Llama / Mixtral)
Total Findings:	4

DISCLAIMER

This report is generated by an AI-powered medical image analysis system and is intended for informational purposes only. It should not be used as a substitute for professional medical advice, diagnosis, or treatment. Always seek the advice of qualified healthcare providers with any questions regarding medical conditions. AI analysis may contain errors and must be reviewed by a certified radiologist or physician before clinical use.