MIA TEAM - AGENIX AI

MEDICAL IMAGE ANALYSIS REPORT

■ URGENCY: ROUTINE

PATIENT INFORMATION

QR N/A

Patient Name:	John Doe
Patient ID:	MIA-20260320-172349
Age:	45 years (Middle-aged Adult)
Gender:	Male
Height:	175.0 cm
BMI:	26.1 kg/m² (Overweight)
Profession:	Engineer

STUDY INFORMATION

Study Date:	2026-03-20 17:25
Study Type:	Brain MRI
Sequence:	T2
Imaging Plane:	Axial
Field Strength:	1.5T
Contrast Used:	No
Report ID:	MIA-20260320-172349
Generated By:	MIA Team - Agenix AI

■ CONFIDENTIAL MEDICAL DOCUMENT — FOR AUTHORISED PERSONNEL ONLY

TABLE OF CONTENTS

1.	Patient Information & Cover	1
2.	Table of Contents	2
3.	Findings Summary Table	3
4.	Medical Image	4
5.	Detailed Findings & Differential Dx	5-6
6.	Cross-Validation Results	7
7.	AI Confidence Breakdown	7
8.	Clinical Correlation	8
9.	Safety Analysis	9
10.	Recommendations & Follow-up	10
11.	Technical Details & QA	11

AI-ASSISTED ANALYSIS
Agenix AI

■ FINDINGS SUMMARY

ID	Location	Description	Severity	Measurements (mm)	Clinical Significance
1	Brain parenchyma	Normal gray-white matter differentiation is preserved throughout the visible cerebral hemi…	MILD	N/A	No evidence of acute or chronic parenchymal pathology.
2	Ventricular system	The lateral ventricles are symmetric and of normal size. No evidence of hydrocephalus or v…	MILD	N/A	Normal ventricular system.
3	Basal ganglia and thalami	The caudate nuclei, putamen, globus pallidus, and thalami are symmetric and demonstrate no…	MILD	N/A	Normal appearance of deep gray matter structures.
4	Cerebral sulci and fissures	The cerebral sulci and Sylvian fissures are of normal prominence for the patient's age, wi…	MILD	N/A	No significant cerebral atrophy or mass effect.
5	Midline structures	No evidence of midline shift or herniation.	MILD	N/A	Indicates absence of significant space-occupying lesions or diffuse br

■ **Critical/Severe** 0 ■■ **Moderate** 0 ■ **Mild** 5 ■ **Total** 5

AI-ASSISTED ANALYSIS
AGENIX AI

MRI IMAGE

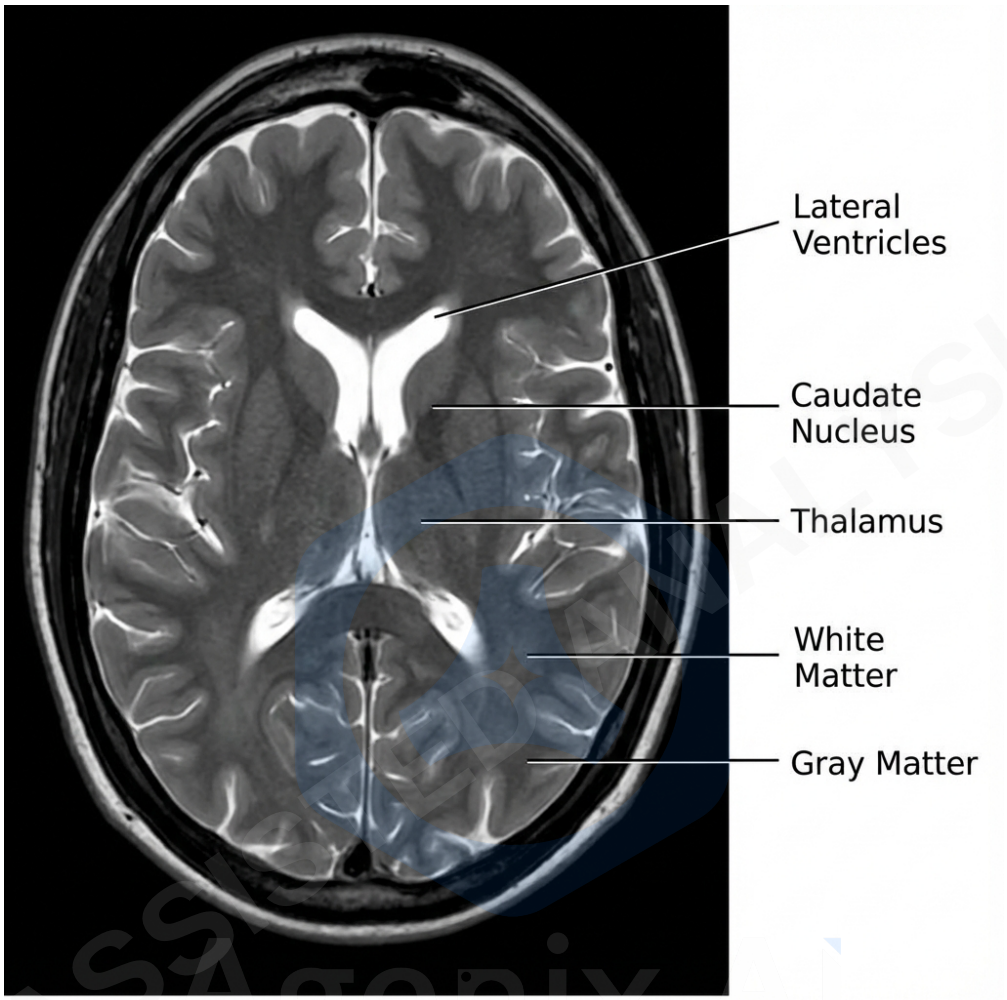

File: sample_brain.jpg | Modality: MRI

■ DETAILED FINDINGS

Finding 1: Brain parenchyma — MILD

Description: Normal gray-white matter differentiation is preserved throughout the visible cerebral hemispheres. No focal areas of abnormal T2 hyperintensity or hypointensity are identified within the brain parenchyma.

Clinical Significance: No evidence of acute or chronic parenchymal pathology.

Finding 2: Ventricular system — MILD

Description: The lateral ventricles are symmetric and of normal size. No evidence of hydrocephalus or ventricular asymmetry. The third ventricle is not fully visualized in this single slice but appears unremarkable.

Clinical Significance: Normal ventricular system.

Finding 3: Basal ganglia and thalami — MILD

Description: The caudate nuclei, putamen, globus pallidus, and thalami are symmetric and demonstrate normal morphology and signal characteristics.

Clinical Significance: Normal appearance of deep gray matter structures.

Finding 4: Cerebral sulci and fissures — MILD

Description: The cerebral sulci and Sylvian fissures are of normal prominence for the patient's age, without evidence of significant atrophy or mass effect.

Clinical Significance: No significant cerebral atrophy or mass effect.

Finding 5: Midline structures — MILD

Description: No evidence of midline shift or herniation.

Clinical Significance: Indicates absence of significant space-occupying lesions or diffuse brain swelling.

■ IMPRESSION & CLINICAL SUMMARY

■■■

Not Available Study Type: MRI Brain Sequence: T2-weighted Imaging Plane: Axial Report Date: 2026-03-20 Report ID: Unique Identifier CLINICAL INDICATION [redacted] Not Available [redacted] CONFIDENTIAL MEDICAL DOCUMENT [redacted] Clinical Correlation: Patient is a 45-year-old Male. Analysis identified 5 verified finding(s). Detailed findings are documented in the report below.

AI-ASSISTED ANALYSIS
Agenix AI

■ CROSS-VALIDATION RESULTS

Validation Status: PASSED
Method: Dual-model consensus — Gemini 2.5 Flash (primary) + Groq LLM (secondary)
Verified Findings: All findings cross-validated using independent AI models

Consensus Score:	100.0%
Total Agreements:	0
Partial Agreements:	0
Disagreements:	0

■ AI CONFIDENCE BREAKDOWN

Task	Score	Confidence Bar
Gemini — Image Classification	99%	
Gemini — Vision Analysis	98%	
Groq — Report Generation	0%	

■ CLINICAL CORRELATION

Patient Profile:
• Age: 45 years (Middle-aged Adult)
• Gender: Male
• BMI: 26.1 kg/m² (Overweight)
• Profession: Engineer

Clinical Summary:
■■■

■■ SAFETY ANALYSIS

Urgency Level: ■ **ROUTINE**

Safety Score: 100.0/100

Critical Findings Identified: 0

Action Required: Routine follow-up recommended

Safety Recommendations:

- ✓ ROUTINE: Standard follow-up recommended

AI-ASSISTED ANALYSIS
Agenix AI

■ PERSONALISED RECOMMENDATIONS

• Consult with healthcare provider for detailed interpretation • Follow recommended treatment plan • Schedule follow-up imaging as advised • ✓ ROUTINE: Standard follow-up recommended

■ FOLLOW-UP PLAN

Recommended Next Steps:
• Schedule consultation with referring physician
• Discuss findings and treatment options
• Plan follow-up imaging if recommended
• Maintain regular health monitoring

Preventive Measures:
• Follow healthy lifestyle recommendations
• Adhere to prescribed medications
• Report any new or worsening symptoms immediately

AI-ASSISTED ANALYSIS
Agenix AI

TECHNICAL DETAILS & QUALITY ASSURANCE

Analysis System:	MIA - Medical Image Analysis
Version:	1.0.0
Organisation:	Agenix AI - MIA Team
Analysis Date:	2026-03-20 17:25:37
Report ID:	MIA-20260320-172349
Primary Model:	Google Gemini 2.5 Flash
Secondary Model:	Groq LLM (Llama / Mixtral)
Total Findings:	5

DISCLAIMER

This report is generated by an AI-powered medical image analysis system and is intended for informational purposes only. It should not be used as a substitute for professional medical advice, diagnosis, or treatment. Always seek the advice of qualified healthcare providers with any questions regarding medical conditions. AI analysis may contain errors and must be reviewed by a certified radiologist or physician before clinical use.