MIA TEAM - AGENIX AI

MEDICAL IMAGE ANALYSIS REPORT

■ URGENCY: ROUTINE

PATIENT INFORMATION

QR N/A

Patient Name:	John Doe
Patient ID:	MIA-20260320-173434
Age:	45 years (Middle-aged Adult)
Gender:	Male
Height:	175.0 cm
BMI:	26.1 kg/m² (Overweight)
Profession:	Engineer

STUDY INFORMATION

Study Date:	2026-03-20 17:36
Study Type:	Brain MRI
Sequence:	T2
Imaging Plane:	Axial
Field Strength:	1.5T
Contrast Used:	No
Report ID:	MIA-20260320-173434
Generated By:	MIA Team - Agenix AI

■ CONFIDENTIAL MEDICAL DOCUMENT — FOR AUTHORISED PERSONNEL ONLY

TABLE OF CONTENTS

1.	Patient Information & Cover	**1**
2.	Table of Contents	**2**
3.	Findings Summary Table	**3**
4.	Medical Image	**4**
5.	Detailed Findings & Differential Dx	**5-6**
6.	Cross-Validation Results	**7**
7.	AI Confidence Breakdown	**7**
8.	Clinical Correlation	**8**
9.	Safety Analysis	**9**
10.	Recommendations & Follow-up	**10**
11.	Technical Details & QA	**11**

■ FINDINGS SUMMARY

ID	Location	Description	Severity	Measurements (mm)	Clinical Significance
1	Brain parenchyma	Normal gray-white matter differentiation is preserved. No focal areas of abnormal T2 hyper…	MILD	N/A	No significant parenchymal abnormalities detected.
2	Ventricular system	The lateral ventricles are symmetric and of normal size, without evidence of hydrocephalus…	MILD	N/A	Normal ventricular system, no signs of increased intracranial pressure
3	Midline structures	Midline structures are centrally located, with no evidence of midline shift.	MILD	N/A	Absence of mass effect or significant space-occupying lesions.
4	Cerebral sulci and fissures	The cerebral sulci and Sylvian fissures are patent and of normal caliber, without evidence…	MILD	N/A	No significant atrophy or acute swelling/edema.

■ Critical/Severe	0	■■ Moderate	0	■ Mild	4	■ Total	4

MRI IMAGE

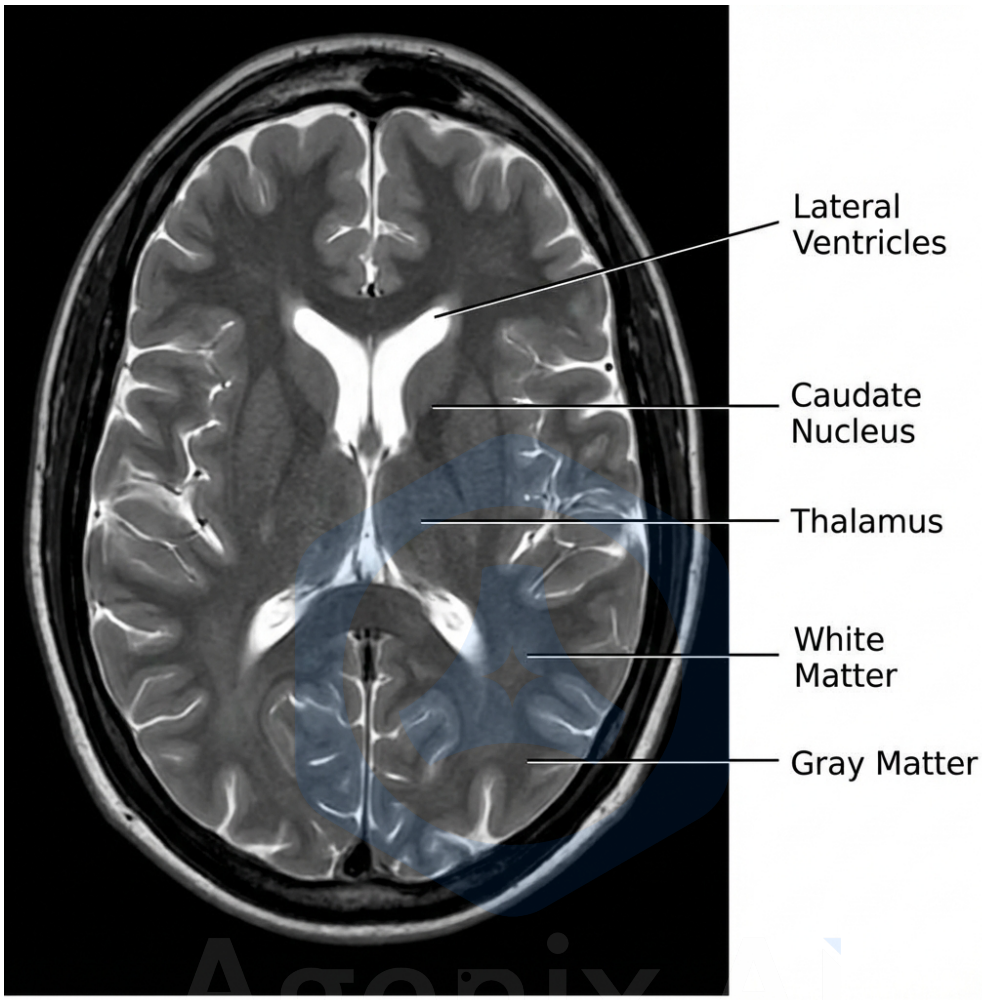

File: sample_brain.jpg | Modality: MRI

■ DETAILED FINDINGS

Finding 1: Brain parenchyma — MILD

Description: Normal gray-white matter differentiation is preserved. No focal areas of abnormal T2 hyperintensity or hypointensity are identified within the cerebral hemispheres, basal ganglia, or thalami. The cortical sulci and gyral patterns are appropriate for age.

Clinical Significance: No significant parenchymal abnormalities detected.

Finding 2: Ventricular system — MILD

Description: The lateral ventricles are symmetric and of normal size, without evidence of hydrocephalus or mass effect causing ventricular effacement or displacement. The third ventricle is not fully visualized at this level, but the visualized portions of the lateral ventricles appear unremarkable.

Clinical Significance: Normal ventricular system, no signs of increased intracranial pressure or mass effect.

Finding 3: Midline structures — MILD

Description: Midline structures are centrally located, with no evidence of midline shift.

Clinical Significance: Absence of mass effect or significant space-occupying lesions.

Finding 4: Cerebral sulci and fissures — MILD

Description: The cerebral sulci and Sylvian fissures are patent and of normal caliber, without evidence of abnormal widening or effacement.

Clinical Significance: No significant atrophy or acute swelling/edema.

■ IMPRESSION & CLINICAL SUMMARY

MIA TEAM - AGENIX AI ## MEDICAL IMAGE ANALYSIS REPORT ### PATIENT INFORMATION ■■■

[redacted] [MRI IMAGE EMBEDDED HERE] Image Details: • Sequence Type: Clinical Correlation: Patient is a 45-year-old Male. Analysis identified 4 verified finding(s). Detailed findings are documented in the report below.

■ CROSS-VALIDATION RESULTS

Validation Status: PASSED
Method: Dual-model consensus — Gemini 2.5 Flash (primary) + Groq LLM (secondary)
Verified Findings: All findings cross-validated using independent AI models

Consensus Score:	100.0%
Total Agreements:	0
Partial Agreements:	0
Disagreements:	0

■ AI CONFIDENCE BREAKDOWN

Task	Score	Confidence Bar
Gemini — Image Classification	99%	
Gemini — Vision Analysis	98%	
Groq — Report Generation	0%	

■ CLINICAL CORRELATION

Patient Profile:
• Age: 45 years (Middle-aged Adult)
• Gender: Male
• BMI: 26.1 kg/m² (Overweight)
• Profession: Engineer

Clinical Summary:
MIA TEAM - AGENIX AI ## MEDICAL IMAGE ANALYSIS REPORT ### PATIENT INFORMATION
■■■

■■ SAFETY ANALYSIS

Urgency Level: ■ **ROUTINE**

Safety Score: 100.0/100

Critical Findings Identified: 0

Action Required: Routine follow-up recommended

Safety Recommendations:

- ✓ ROUTINE: Standard follow-up recommended

■ PERSONALISED RECOMMENDATIONS

• Consult with healthcare provider for detailed interpretation • Follow recommended treatment plan • Schedule follow-up imaging as advised • ✓ ROUTINE: Standard follow-up recommended

■ FOLLOW-UP PLAN

Recommended Next Steps:
• Schedule consultation with referring physician
• Discuss findings and treatment options
• Plan follow-up imaging if recommended
• Maintain regular health monitoring

Preventive Measures:
• Follow healthy lifestyle recommendations
• Adhere to prescribed medications
• Report any new or worsening symptoms immediately

TECHNICAL DETAILS & QUALITY ASSURANCE

Analysis System:	MIA - Medical Image Analysis
Version:	1.0.0
Organisation:	Agenix AI - MIA Team
Analysis Date:	2026-03-20 17:36:07
Report ID:	MIA-20260320-173434
Primary Model:	Google Gemini 2.5 Flash
Secondary Model:	Groq LLM (Llama / Mixtral)
Total Findings:	4

DISCLAIMER

This report is generated by an AI-powered medical image analysis system and is intended for informational purposes only. It should not be used as a substitute for professional medical advice, diagnosis, or treatment. Always seek the advice of qualified healthcare providers with any questions regarding medical conditions. AI analysis may contain errors and must be reviewed by a certified radiologist or physician before clinical use.