Author Manuscript
Author Manuscript
Author Manuscript
Author Manuscript

HHS Public Access
Author manuscript
Annu Rev Anim Biosci. Author manuscript; available in PMC 2020 December 28.

Published in final edited form as:
Annu Rev Anim Biosci. 2018 February 15; 6: 157–175. doi:10.1146/annurev-animal-030117-014748.

Equine Intestinal Mucosal Pathobiology

Anthony Blikslager, **Liara Gonzalez**
Center for Gastrointestinal Biology and Disease, College of Veterinary Medicine, North Carolina State University, Raleigh, North Carolina 27607, USA;

Abstract

The equine intestinal mucosa is intimately involved in maintaining homeostasis both on a systemic level by controlling extracellular fluid movement and at the local level to maintain barrier function. Horses are particularly susceptible to the clinical syndrome of colic, with the most severe cases involving strangulating obstruction that induces ischemia. Because of the mucosal vascular architecture, the mucosal epithelium is particularly susceptible to ischemic injury. The potential for reperfusion injury has been investigated and found to play a minimal role. However, inflammation does affect mucosal repair. Mechanisms of repair, including villus contraction, epithelial restitution, and tight junction closure, are critical to reforming the mucosal barrier. Nonsteroidal anti-inflammatory drugs have an impact on this repair, particularly at the level of the tight junctions. Completion of mucosal regeneration requires proliferation, which is now being actively studied in equine enteroids. All of these aspects of equine mucosal pathobiology are reviewed in depth.

Keywords

horse; intestine; ischemia; barrier function; stem cell niche; enteroid

PHYSIOLOGICALLY CRITICAL FEATURES OF THE EQUINE DIGESTIVE TRACT

Horses use the digestive strategy of hindgut fermentation, during which ingested forage is rapidly passed from the stomach along the small intestine (in excess of 20 m in the average 500-kg adult horse, with a transit time of approximately 120–180 min) and into the cecum and large colon (1). This may be less efficient than the digestive strategy of foregut fermentation, noted in ruminants, where forage that has been partially digested in the forestomachs, including the rumen, can then enter the small intestine for efficient absorption of nutrients (2). However, selection pressure for speed in horses to run from predators (top speed of approximately 70 km/h) likely resulted in development of a hindgut, where a large gut chamber would not impede running. The equine hindgut is voluminous and folded to accommodate its length within the abdomen into a double-horseshoe configuration, with a

anthony_blikslager@ncsu.edu.

DISCLOSURE STATEMENT
The authors are not aware of any affiliations, memberships, funding, or financial holdings that might be perceived as affecting the objectivity of this review.

Author Manuscript Author Manuscript Author Manuscript Author Manuscript

ventral colon (the lower horseshoe) primarily functioning as the fermentation chamber and the dorsal colon (the upper horseshoe) taking on a predominant role in water absorption (Figure 1) (3). The ventral and dorsal colons of the horse are sometimes referred to as the ascending colon because of terminology used for the human colon, but anatomically this is problematic because the equine proximal colon both ascends and descends (4). The pelvic flexure, which connects the ventral and dorsal colons, includes a hairpin turn from the larger-diameter ventral colon to the smaller-diameter dorsal colon. Suboptimal management of captive horses, such as feeding of poor-quality forage, may lead to ingesta obstructions (impactions), which are most commonly found at the pelvic flexure (5). Impactions of indigestible luminal contents, most notably sand, tend to obstruct at a more distal flexure present between the right dorsal colon and the transverse colon (6). This is also the site where enteroliths, typically composed of struvite surrounding a small central mineral nidus (7), may develop and obstruct the flow of ingesta.

The rapid passage of digesta along the small intestinal tract requires relatively large volumes of fluid, which are primarily secreted by the salivary glands, pancreas, and small intestinal mucosa (1). The relative fluid volumes entering the equine digestive tract have been studied (Figure 1) and show that horses secrete approximately one extracellular volume of fluid into the digestive tract on a daily basis (1, 3). Clarke and colleagues (3, 8–11) have studied in depth the control of NaCl absorption and associated water movement across the equine colon at both the local and systemic levels. The endocrine-gut axis is critical to maintaining homeostasis considering the massive shift of fluid into and back out of the colon that occurs during the feeding of a meal, and this is accomplished by activating the renin-angiotensin-aldosterone system interacting with select colonic gut transporters (8, 9, 11). This system is maximally activated during feeding of meals (Figure 1), as might occur during intensive management of horses (rather than multiple meals or continuous grazing) (3). In response to a single meal comprising the full ration for a horse in the form of hay-grain pellets, plasma renin activity was increased by 0.5 h, followed by elevations in plasma aldosterone by 3 h. The renin release was attributed to transient hypovolemia, as suggested by increases in plasma protein and packed cell volume (10). This systemic hypovolemia is a consequence of fluid moving into the digestive tract. These investigators went on to show that an increase in aldosterone in the horse resulted in a doubling of Na^+ absorption in the proximal colon (ventral and dorsal colons) and a tripling of Na^+ absorption in the distal colon as a mechanism to retrieve the large volumes of fluid that are secreted into the digestive tract (11). From a clinical perspective, meal feeding places horses at risk of conditions such as colonic distension, which can lead to colonic displacement or volvulus. The latter is the most fatal form of colic, requiring rapid surgical intervention to increase the likelihood of survival (12).

THE EQUINE MICROBIOME

Considering the fact that horses are herbivores, and have an extensively developed hindgut for the purposes of fiber digestion, there has been recent interest in the microbiome and how it might be changed under differing management circumstances. For example, mares are at risk of colic in the peripartum period, possibly related to factors such as changes in feeding of lactating mares (13). Numerous differences that preceded colic have been described in the

Author Manuscript Author Manuscript Author Manuscript Author Manuscript

fecal microbiota of postpartum mares. In particular, one study found associations between changes in Firmicutes and Proteobacteria, most notably Lachnospiraceae and Ruminococcaceae, with the development of colic, and the authors suggested that select changes in the fecal microbiota could possibly be used to predict higher risk of colic (14). Although studies on equine microbiota have often focused on fecal microbiota, they are not reliably indicative of colonic microbiota (15). Nonetheless, another study evaluating the effect of concentrate diet on colonic microbiota collected at the time of slaughter has shown some similar results to the aforementioned fecal microbiota study. In particular, a feeding change to dietary concentrate resulted in a progressive and significant increase in Lachnospiraceae, as had been seen in the fecal microbiota of horses fed a concentrate diet (16). Another study showed that horses fed concentrate diet versus a grass-only diet had an increase in lactic acid-producing microbiota (the *Bacillus-Lactobacillus-Streptococcus* group) in their colonic contents (obtained following euthanasia), resulting in higher concentrations of lactic acid. Interestingly, the shift to lactic acid-producing microbiota was also associated with horses that developed colonic distension or impaction (16). Despite changes that appear to be selective enough to be used to detect horses at risk of colic, a great deal of variability in individual horse microbiota even when managed under similar circumstances has been shown (15), suggesting caution should be used when interpreting microbiome-related risk factors in individual or small groups of horses.

THE EQUINE STEM CELL NICHE

The interaction between intestinal mucosa and microbiota has become an area of great interest in human health-related research (17), but intense study of the makeup of the mucosa has been undertaken as a precursor to fully understanding host interactions with luminal contents. The luminal surface of the mucosa is composed of columnar epithelial cells that have the conflicting functions of water and nutrient transport, while simultaneously guarding against invasion of noxious luminal bacteria and bacterial toxins (18). Down the entire length of the small and large intestine, the epithelia are arranged into invaginations called crypts of Lieberkühn. The small intestine is further composed of fingerlike projections, called villi, which extend into the intestinal lumen, thereby increasing the absorptive surface area. This anatomic arrangement is referred to as the crypt-villus axis. At the base of each crypt are undifferentiated stem cells interspersed between Paneth cells. Immediately adjacent to these cells are partially differentiated progenitor cells, and collectively, this region of crypts is termed the stem cell niche (19).

To maintain a continuous epithelial barrier in the face of constant threat from luminal contents, the cells remain in a dynamic and rapid state of cellular turnover that continues throughout life. This requires a tightly regulated balance of cellular loss and cellular renewal and results in the creation of a largely new intestinal lining approximately every five to seven days. This capacity for self-renewal is attributed to the adult or somatic stem cells that reside within the intestinal mucosal lining deep within the base of each crypt. Intestinal epithelial stem cells were first described in the scientific literature by transmission electron microscopy in 1974 (20). Currently two populations of stem cells are thought to exist: fast-cycling crypt base columnar stem cells and slower-cycling, reserve quiescent stem cells (21, 22). Despite evidence that distinguishes between these two cell types, cells expressing

Author Manuscript Author Manuscript Author Manuscript Author Manuscript

biomarkers attributed to either fast- or slow-cycling stem cells clearly have the capacity to differentiate into all four postmitotic, mature epithelial cell types (22). These cell lineages include absorptive enterocytes, goblet cells, enteroendocrine cells, and Paneth cells. The latter do not ascend the crypt villus axis but remain parked near the crypt base and are thought to have a critical role in supporting crypt-based columnar cells (CBC, fast-cycling stem cells) via release of factors involved in CBC homeostasis, such as Wnt (23). In addition, Paneth cells release antibacterial peptides called defensins (24). In a study focused on identification of epithelial cell lineages in horses, all intestinal epithelial cell types were identified by means of immunostaining and morphological characterization with transmission electron microscopy (19).

Intestinal epithelial stem cells are distinct from mesenchymal stem cells commonly used in equine orthopedic research and therapy owing to a restricted capacity to differentiate. Although they are undifferentiated and self-renew (a prerequisite of all stem cells), they do not give rise to multiple tissue types, as is the case for mesenchymal stem cells, which may turn into bone, cartilage, connective tissue, and fat cells. Instead, intestinal epithelial stem cells differentiate only into those of intestinal epithelial lineage. Many recent and exciting advances in the field of intestinal stem cell biology have enabled the detailed study of the stem cell niche (Figure 2) as a potential source of novel therapeutic targets to enhance intestinal mucosal regeneration (25, 26). Stem cells are a renewable source of mature epithelial cells in the gut, and understanding their function is critical to developing clinical applications that may improve outcome in cases of severe mucosal injury. In addition, recent work on equine colonic tissues has focused on the level of proliferative cells that may be required to regenerate tissue following large colon volvulus (27). As-yet-unpublished data show that reduced numbers of stem cells expressing phosphohistone 3, a marker of the G2-M phase of the cell cycle (28), predict case fatality when counted in biopsies from horses with naturally occurring large colon volvulus.

COLIC AND ISCHEMIC INJURY IN HORSES

According to a US national survey conducted in 2001, approximately 4% of horses have an episode of colic annually, with a case fatality rate of 11% (29). Strangulating obstruction, a disease process in which simultaneous occlusion of the intestinal lumen and vasculature results in ischemic mucosal injury, is arguably the principal cause of colic-associated deaths in horses. For example, a study conducted in the United Kingdom in 1992 showed that 14 of 200 (7%) horses evaluated for colic over 2 years in a general equine practice died, and 12 of those 14 deaths were associated with intestinal strangulation (30). A more recent set of studies by the same authors has confirmed that horses with strangulating lesions had consistently higher mortality rates, a finding that was reflected by the fact that resection length and length of surgery had considerable prognostic value. Furthermore, a pattern of mortality was identified in which a high fatality rate was noted within the first few days after surgery, with continued mortality at lower rates after discharge from the hospital (31, 32). Horses with intestinal diseases other than strangulating obstruction may also suffer from ischemic disease. For example, horses suffering from simple obstruction ultimately succumb to ischemic necrosis if not attended to medically and sometimes surgically as increasing intraluminal pressure progressively occludes the circulation within the intestinal wall (33,

Author Manuscript Author Manuscript Author Manuscript Author Manuscript

34). In addition, horses may suffer from nonstrangulating infarction, which is most commonly associated with parasite migration (35). However, this disease process has become relatively rare with the advent of highly effective broad-spectrum anthelmintics.

The degree of mucosal injury that is noted in horses with ischemic disease of the intestine is highly variable, depending on the type and duration of intestinal obstruction (36, 37). Although most equine research to date has focused on either low-flow ischemia, during which intestinal blood flow is uniformly reduced to a static level (typically 20% of baseline flow) (38–40), or complete ischemia, in which the intestinal vasculature is completely occluded (41, 42), most natural cases of strangulating obstruction fit into neither of these categories. Instead, horses with intestinal strangulating obstruction are most likely to have a disparity in blood flow in which the venous circulation is occluded before the intestinal arterial blood supply because of the differences in vessel wall thickness and compliance. This results in a hemorrhagic lesion in which the arteries continue to supply blood to the tissues for a variable length of time before they ultimately collapse as a result of increases in tissue interstitial pressure (43). This explains the appearance of tissues commonly encountered during strangulating obstruction, including significant thickening of the tissue and marked discoloration, as a result of tissue filling with deoxygenated blood. Less commonly, strangulation may be so rapid in onset and so tightly twisted that the veins and arteries are occluded simultaneously. This type of lesion, known as ischemic strangulating obstruction, may be encountered in lesions like large colon volvulus, particularly those of rapid onset exceeding 360° of rotation (43). This lesion is pale, with little tissue edema, because of the complete lack of blood flow. The appearance of these distinct lesions can be deceiving when it comes to judging the degree of ischemic mucosal injury at surgery. The level of mucosal injury is a critical clinical judgement, because it is highly likely that the integrity of the mucosa largely dictates whether or not a horse can survive with a particular lesion (44). During the early stages of hemorrhagic strangulating obstruction, the degree of mucosal injury is reduced as compared with ischemic strangulating obstruction lesions despite the marked abnormal coloration of these lesions, most likely because of continued provision of oxygenated blood from an arterial blood supply that is initially patent during the early phases of obstruction. This has been modeled in equine intestine by occluding the veins (45), and in porcine intestine by 360° twisting of the jejunum and partial ligation of the twisted loop with a Penrose drain to create a segmental volvulus (46). In the case of porcine volvulus, the level of injury was time-dependently less severe than complete occlusion of the bowel and vasculature, based on histological findings. Conversely, ischemic strangulating lesions do not appear severe; they may readily become pink during reperfusion but may nonetheless have severe mucosal injury because of an absolute cessation of arterial blood flow during the ischemic phase.

The ultimate diagnostic test to ascertain the degree of injury is mucosal histology, which can be accomplished during surgery with frozen sections (47) but is not possible in most hospitals because of the emergency nature of colic cases. In the absence of such a definitive test, caution is suggested at surgery in suspected cases of ischemic strangulating obstruction in favor of resecting intestine when there is concern that the mucosa may be severely compromised. Conversely, in horses with hemorrhagic strangulating obstruction in which resection is not possible, such as obstructions involving the terminal ileum, surgeons should

Author Manuscript Author Manuscript Author Manuscript Author Manuscript

realize that the ischemic injury may appear more severe than it actually is and that many of these horses can be saved with the intestine left in situ. This has been highlighted recently in clinical studies, where horses with strangulated small intestine that might have typically been resected have recovered well without resection (48). The judgment of whether to resect intestine in cases of hemorrhagic strangulating obstruction has recently been based on a grading system, which reduces subjectivity (48). In addition, in a study of biopsies from horses with large colon volvulus, histological analyses showed that the most predictive tissue index linked to case fatality was hemorrhage score (Figure 3), with a hemorrhage score of ≥3 placing horses in excess of eightfold at risk of nonsurvival (44). This may become clinically useful in the future in a methodology to quantify or semiquantify the level of hemorrhage within the tissue at surgery.

MECHANISMS OF ISCHEMIC MUCOSAL INJURY

A reduction in blood flow during ischemia results in cellular necrosis as tissues are starved of oxygen (49). Mechanisms of intestinal mucosal injury are more complex than this, however. In particular, the design of the mucosal vascular supply in the small intestine, which is species specific, may predispose distinct regions to greater degrees of injury during ischemia (50). The surface area of the small intestinal mucosa is amplified by fingerlike projections called villi; in the horse, these villi have a central arteriole that arborizes near the tip of the villus, draining into peripheral venules (51). This vascular architecture sets up a countercurrent exchange mechanism in which oxygen diffuses from the arteriole into the tissue and adjacent peripheral venules, resulting in a relatively hypoxic villus tip. When arterial blood flow is reduced, for example, during the early phases of strangulating obstruction, the villus tip becomes progressively more hypoxic, resulting in epithelial injury (50). Therefore, ischemic mucosal injury results in time-dependent sloughing of epithelium from the tip of the villus toward the crypts (52). Although there are no villi in the large intestine, surface epithelium is lost initially during ischemia, followed by crypt epithelial injury as ischemia progresses (42, 53). A great deal of recent work has extensively characterized experimental ischemic strangulating obstruction in the colon (53–55), which has revealed evidence of epithelial swelling and detachment from the basement membrane during the early stages of ischemia (within 1 h). Epithelial cells also had ultrastructural evidence of organelle swelling, and some were clearly undergoing either apoptosis or autophagy. Interestingly, there was also extensive evidence of dilatation of the tight junctions (53), the most critical component of the epithelial barrier, prior to complete epithelial sloughing (56).

REPERFUSION INJURY

The concept of reperfusion injury centers on experimental findings in which mucosal injury is worsened by reperfusing an ischemic lesion. This concept seems counterintuitive given the fact that ischemic mucosal injury results largely from a lack of oxygenated blood supply. Nevertheless, reperfused lesions rapidly become infiltrated with neutrophils, and neutrophils resident within the mucosa become activated in rodent models of ischemia/reperfusion injury, which injure tissues as a result of release of reactive oxygen metabolites and proteases (57). The reason neutrophils seem to infiltrate or become activated in postischemic

Author Manuscript Author Manuscript Author Manuscript Author Manuscript

mucosa is the swift generation of chemoattractants in response to oxidants released by tissue enzymes, most notably, xanthine oxidase (50). This enzyme is typically present in its dehydrogenase form but becomes converted to xanthine oxidase during ischemia by tissue proteases (58). As the tissue is reperfused, xanthine oxidase begins to metabolize hypoxanthine that has accumulated as a result of end-stage metabolism of adenosine triphosphate, using oxygen as an electron acceptor (50). This results in superoxide formation. Although superoxide is not in itself particularly damaging because it is not highly lipid soluble, it triggers the formation of chemoattractants, such as leukotriene B_4 and platelet-activating factor (59). There are also other possible sources of oxidant-producing enzymes in intestinal tissues that may initiate injury. For instance, in the large colon of the horse, although there are low concentrations of xanthine dehydrogenase/xanthine oxidase, other oxidant-generating enzymes, such as aldehyde oxidase, may be present (57). Oxidant-induced release of chemoattractants results in rapid aggregation of neutrophils within the postischemic lesion. Neutrophils are the final common mediator of intestinal mucosal reperfusion injury, which is why inhibition of neutrophil infiltration with antibodies directed toward neutrophil adhesion molecules markedly attenuates reperfusion injury in rodent models (50).

Horses differ from rodents in several important ways. Firstly, levels of xanthine dehydrogenase/xanthine oxidase in the small intestine are approximately 10-fold lower than those of rodents, and there are also progressive reductions in mucosal xanthine oxidase levels from the duodenum to the ileum (58, 60). In addition, horses have fewer mucosal neutrophils than rodents (Table 1) (60). This is important because resident neutrophils that are already present in the mucosal lamina propria are responsible for most of the reperfusion injury noted in rodents (61). Finally, most of the literature on reperfusion injury uses a low-flow model, rather than a strangulating obstruction model. This appears to maximally prime tissues for reperfusion injury by triggering conversion of xanthine dehydrogenase to xanthine oxidase, with minimal damage to the tissues. However, most injury in strangulating obstruction occurs during the ischemic phase (62).

It is important to note that there are probably other mechanisms of reperfusion injury aside from injury induced by reactive oxygen metabolites and neutrophils. For example, one study in horses showed marked mucosal metabolic abnormalities induced by 3 h of ischemia, including mitochondrial dysfunction, which persisted during reperfusion because of the inability of tissues to regain normal function (49). However, in another equine study, ultrastructural evidence of ischemic epithelial injury in the colon was rapidly followed by evidence of epithelial repair during reperfusion, although the period of ischemia was brief (1 h) (53). Another population of inflammatory cells has received extensive attention in horses: eosinophils. Under normal circumstances, eosinophils are predominantly located beneath the muscularis mucosa (63). However, during ischemia/reperfusion, eosinophils have been shown to migrate from the intestinal lumen through the mucosa to the luminal surface, though this does not happen after ischemia alone in experimental studies (64). Eosinophils have also been shown to accumulate in the mucosa in horses with naturally occurring strangulating obstruction (64). In experimental trials in horses using a large colon model of colonic strangulating obstruction, eosinophil production of nitrotyrosine, which contributes to reactive oxygen metabolite-induced injury, was associated with colon epithelial apoptosis

Author Manuscript Author Manuscript Author Manuscript Author Manuscript

during the recovery period. This suggests that eosinophils also contribute to disruption of repairing intestinal epithelium (65).

MECHANISMS OF MUCOSAL REPAIR

Acute Mechanisms of Repair

In the small intestine, the acute phase of repair involves marked contraction of the villi, which can dramatically reduce the surface area of the denuded segment of the intestinal mucosa (Figure 4). This villus contraction is regulated by enteric nerves, because experimental studies in guinea pigs have shown the ability of the nonspecific neurotoxin tetrodotoxin to abolish contraction (66). Furthermore, there seems to be a role for prostanoids in villus contraction (67), although it is uncertain if prostaglandin (PG)-stimulated contraction results in more rapid mucosal repair (68). This may result from the fact that there are two components to villus contraction: contraction of contractile elements adjacent to the central arteriole and contraction of myofibroblasts adjacent to the epithelial basement membrane. The latter is apparently not influenced by PGs (67) and is intimately involved in restitution (66). Although all of these findings are in species other than the horse, equine studies have shown reproducible evidence of villus contraction that is initiated during ischemia, and which continues during early mucosal repair as blood flow is restored (69–71). However, the relative contribution of villus contraction to repair in ischemic-injured small intestine is unknown.

Contraction of the villi is accompanied by concurrent epithelial restitution, during which intact epithelial cells shouldering the mucosal wound progressively flatten and crawl across denuded basement membrane that appears intact following ischemic injury. This was first described in the equine literature during studies on ponies (72) and involves amoeba-like movement of epithelia (73). Restitution is initiated by integrins expressed on the cell membrane of migrating epithelia that interact with critical elements within the basement membrane, including collagen, hyaluronic acid, and proteoglycans (74, 75). In experimental in vitro cell studies, epithelial migration was hastened by providing the appropriate types of collagen (75) and by adding select proteoglycans and hyaluronic acid (76). The latter treatments (proteoglycans and hyaluronic acid) have been used extensively in equine orthopedic regenerative medicine but have not been tested in equine intestinal mucosal repair. Restitution is also strongly stimulated by specific growth factors, which are peptides released locally by mucosal elements that interact with specific receptors expressed on epithelium. In particular, transforming growth factor β (TGFβ), TGFα (which is not related to TGFβ), insulin-like growth factor, and fibroblast growth factors have been found to speed epithelial migration in vitro and in vivo (77). Furthermore, a group of peptides called trefoil factors, because of their cloverleaf-like structure, strongly stimulate epithelial migration (78). Provision of these factors has hastened the repair process in cell and murine studies but has not been tried on equine injured mucosal tissues. Other factors that facilitate epithelial migration are a group of compounds called polyamines. These have been found to be critical to the process of epithelial restitution, although their mechanism of action is unclear. One possibility is that the long positively charged nature of these compounds might facilitate repair of the basement membrane (79). Components of feed may also stimulate mucosal

Author Manuscript Author Manuscript Author Manuscript Author Manuscript

repair. For example, in one study in which a lesion similar to that noted with ischemic injury was induced by addition of bile salts, restitution was hastened by addition of the amino acid arginine (67). However, these factors have not been extensively investigated in horses or equine tissues.

Although restitution was once thought to be the defining event in mucosal repair, studies have shown that the mucosa remains leaky to clinically relevant molecules such as lipopolysaccharide until the tight junctions have been repaired and closed. This process was initially described in pigs (80) and has been shown to involve rapid reinsertion of tight junction proteins, including occludin and sealing claudins at the region of the apical lateral membranes of adjacent epithelial cells (81). The primary mediator of tight junction repair is PGE_2, which became of particular interest to equine researchers because prostanoids are typically inhibited in horses with intestinal injury with the use of the nonselective cyclooxygenase inhibitor and visceral analgesic flunixin meglumine (82, 83). The target of PGE_2 is a relatively understudied chloride channel called ClC-2, which unlike other chloride channels is expressed in villus epithelium and within the tight junctions. Its mechanism of action is thought to involve enhanced trafficking of tight junction proteins to the apical lateral membrane, although the precise mechanism of action remains under study (84).

Role of Acute Inflammation in Mucosal Injury and Repair

Evaluation of mucosal repair following ischemic injury in pigs revealed a different time course of neutrophil infiltration as compared with murine and feline studies. In particular, ischemia in rodents and cats showed peak infiltration of neutrophils within 1 h of reperfusion injury (61, 85–87), whereas in porcine studies, peak neutrophil infiltration occurred 6 h after ischemic injury (88). The importance of this finding was that rather than exacerbating injury, this delayed neutrophil infiltration may hamper restitution, particularly tight junction repair, as neutrophils coursed through the paracellular spaces of restituting epithelium. Of translational significance, inhibiting neutrophil adhesion or treating with superoxide dismutase could restore optimal repair (88). Based on these findings, an equine model of jejunal strangulating obstruction was developed in horses in which discrete segments of the jejunum were subjected to 2 h of complete segmental jejunal ischemia by cross-clamping the bowel and clamping the associated vasculature, followed by removal of the clamps, recovery of the horse from general anesthesia, and euthanasia for collection of tissues after 18 h (89). Evaluation of intestinal tissues revealed all of the elements of acute mucosal repair, including villus contraction and restitution, as well as evidence of inflammation (90). As has been previously stated, neutrophil infiltration during mucosal repair is different from reperfusion injury shown in rodents, during which neutrophils maximally infiltrate within 1–3 h of reperfusion, causing further mucosal injury prior to reparative events (60). The equine model has proven invaluable in researching equine intestinal repair, including its use by other investigators to study colonic ischemic injury and mucosal recovery (83).

Impact of Clinical Medications on Equine Acute Mucosal Repair

The role of PGs in reassembly of interepithelial tight junctions shown in basic science work performed principally in porcine ischemic-injured tissues (80) suggested that administration

Author Manuscript Author Manuscript Author Manuscript Author Manuscript

of nonsteroidal anti-inflammatory drugs (NSAIDs), which is commonplace in horses with the clinical syndrome of colic, may be problematic (91). Ex vivo trials in horses showed that the nonselective COX inhibitor flunixin meglumine did indeed retard recovery of barrier function (92–94). Subsequently, in vivo trials using the 2-h ischemia/18-h recovery model in horses showed that a clinical dosage regime of flunixin meglumine [1.1 mg/kg, intravenously (IV), every 12 h (q12h)] consistently reduced barrier function recovery (70, 71, 89). This was not associated with measurable histological differences in mucosal repair, including villus height and percentage of mucosal epithelialization. Instead, flunixin meglumine's effect appeared to be paracellular in nature (i.e., associated with the integrity of tight junctions) based on reduced recovery of transepithelial electrical resistance and increased permeability to the paracellular probe mannitol (89). To heighten the potential clinical relevance of these findings, mucosal-to-serosal-labeled *Escherichia coli* lipopolysaccharide fluxes were performed, which confirmed that flunixin meglumine also resulted in a permeability defect after the 18-h recovery period (70, 71). Interestingly, flunixin meglumine also caused a significant increase in mucosal inflammation, measured by the numbers of counted neutrophils within the lamina propria beneath repairing epithelium (90). The cause of this inflammation was presumed to be the increased leakiness of the recovering mucosa. In contrast, use of NSAIDs with selectivity for COX-2 allowed for repair of the mucosa, either ex vivo (deracoxib, robenacoxib) (92, 94) or in vivo (firocoxib) (70). In addition, meloxicam, which has an approximately threefold selectivity for COX-2, also allowed full mucosal recovery. To confirm COX selectivity in vivo, equine trials comparing either meloxicam or firocoxib with flunixin meglumine showed that the latter inhibited both TXB_2 (from COX-1) and PGE_2 (from COX-2) in whole blood taken during the trial, whereas meloxicam and firocoxib did not inhibit TXB_2. In other words, the COX-2 selective medications were COX-1 sparing. This property is presumed to be the reason that ischemic-injured equine mucosa repairs unabated in the presence of medications that principally inhibit COX-2, with the presence of reparative prostanoids elaborated by mucosally expressed COX-1 (95). In a recent as-yet-unpublished randomized clinical trial, horses with small intestinal strangulating obstruction were randomly assigned to treatment with either flunixin meglumine (1.1 mg/kg, IV, q12h) or the COX-2 inhibitor firocoxib (2.7-mg/kg loading dose, 0.9 mg/kg, IV, q24h). Horses receiving flunixin meglumine were at greater risk of having excessive levels of the sepsis biomarker soluble CD14 (96), suggesting measurable differences in recovery of barrier function. How this will translate to clinical outcome has not yet been determined.

The mucosal inflammation that had been increased in the presence of flunixin meglumine was significantly diminished in the presence of COX-2-selective NSAIDs (70, 71). In addition, trials evaluating the effects of systemically administered lidocaine in horses with the 2-h ischemia/18-h recovery (1.3-mg/kg loading dose, 0.05 mg/kg/min controlled rate infusion) revealed that this medication prevented mucosal inflammation in horses concurrently treated with flunixin meglumine (69). This is of particular clinical relevance because horses are frequently treated with both of these medications following surgery for strangulating small intestinal obstruction, with lidocaine being used to reduce the prevalence and duration of postoperative ileus. However, the mechanism for the action of lidocaine, in terms of its effects on mucosal inflammation, remains elusive. In vitro trials assessing the

Author Manuscript Author Manuscript Author Manuscript Author Manuscript

effect of lidocaine on equine neutrophils showed no effect of lidocaine on either adhesion or migration (97). One possibility is that lidocaine alters the function of intestinal epithelial electrolyte transporters to reduce epithelial injury and potentially enhance repair (98). However, this will take additional work to fully explore.

Subacute Mucosal Repair and Epithelial Proliferation

Once tissues have fully restituted, epithelium that has been sloughed during the initial injury must be replaced to restore normal mucosal architecture. During this subacute period of repair, cellular proliferation, differentiation, and the onset of inflammation predominate (99). Epithelial proliferation in the small and large intestine is derived from stem cells within the crypt compartment, with escalation of newly formed cells along the crypt-villus axis. In homeostatic conditions, a newly formed cell may take anywhere from 3 to 7 days to reach the tip of the villus or the surface epithelial compartment in the colon, during which time the epithelial cells progressively mature and attain specific functions related to surface epithelium. For example, epithelial secretion takes place largely in crypts, whereas mature epithelium at the surface has a more dominant absorptive role. Such absorption includes electrolytes and nutrients, including glucose and amino acids (in the small intestine) and short-chain fatty acids (in the colon). After mucosal injury, the crypt compartment is greatly enlarged, with dramatic increases in crypt proliferation. The lag phase before an increased proliferative rate is approximately 12 to 18 h, so that by 48 to 72 h, the crypt may be many times the size of the crypt immediately following injury (99). This process is likely driven by elaboration of increased concentrations of local growth factors, although the signals involved in these events continue to be an area of intensive study. After amplification of the crypt, the villus gradually reforms, so that the surface area of the villus has been restored by 4 to 6 days after a severe mucosal ischemic event (77). The process of reformation of normal mucosal structure may be more rapid in the colon, where there are no villi. Factors known to stimulate mucosal epithelial proliferation include peptide growth factors, such as TGFα, polyamines, and gut-specific nutrients like glutamine in the small intestine and butyrate in the colon (56). Thus, as with epithelial restitution, early refeeding likely hastens restoration of normal mucosal structure and function.

EQUINE STEM CELL CULTURE AND ORGANOIDS

Recent advances in the field of stem cell biology have enabled the growth of intestinal stem cells in culture from murine, porcine, human, and most recently horse intestinal epithelium (100–103). The process of stem cell culture begins with the isolation of intestinal crypts. In short, crypts are dissociated and isolated from whole tissue through a process of shaking the tissue immersed initially in ethylenediaminetetraacetic acid. The tissue is then repeatedly transferred, with continued shaking, into multiple solutions of ice-cold phosphate-buffered saline until crypt/villi units separate from the underlying basement membrane. This process minimizes the amount of debris and maximizes the number of crypts present in the final solution. The remnant intestinal tissue is removed and the solution is filtered through a 100-micron sterile cell strainer to remove any remaining villi. The final solution is then centrifuged, and the pelleted crypts are resuspended directly into Matrigel supplemented with multiple growth factors.

Author Manuscript Author Manuscript Author Manuscript Author Manuscript

The intestinal stem cells in these cultures develop into three-dimensional structures that consist of all of the components of native intestine. These include outwardly budding crypts, all mature epithelial cell types, and a pseudo-lumen where dead cells are extruded (Figure 5). They are therefore referred to as mini-guts but may also be called enteroids or organoids. These culture systems provide an advanced tool to study intestinal epithelial dynamics during homeostasis and disease. To date, they have been used to model tissue morphogenesis, stem cell lineage selection, tissue plasticity, cellular signaling, and both bacterial and viral infection (104). Furthermore, these mini-guts have been shown to adhere and form crypt structures within denuded mucosa when infused into the intestinal lumen of a mouse with colitis (105). Despite these significant advances in the field, intestinal stem cells have yet to be used clinically. Furthermore, studies that evaluate the impact of injury and the regenerative response of stem cells are few.

At this time, work in the field of equine intestinal stem cells and their culture remains limited (106). In horses, a treatment that hastens mucosal repair may help to prevent the common sequela of severe intestinal injury, including sepsis, bacteremia, laminitis, ileus, and diarrhea. Together with existing treatments, novel therapies derived from intestinal stem cell research and the use of the stem cell culture system may help shorten recovery times and facilitate enhanced repair following severe mucosal damage.

ACKNOWLEDGMENTS

Supported in part by the Center for Gastrointestinal Biology and Disease, Large Animal Models Core, NIH P30 DK34987 (to A.B. and L.G.).

LITERATURE CITED

1. Argenzio R 1990 Physiology of digestive, secretory, and absorptive processes In The Equine Acute Abdomen, ed. White NA, pp. 25–35. Philadelphia: Lea & Febiger 1st ed.
2. Janis C 1976 The evolutionary strategy of the Equidae and the origins of rumen and cecal digestion. Evolution 30:757–74 [PubMed: 28563331]
3. Clarke LL, Roberts MC, Argenzio RA. 1990 Feeding and digestive problems in horses: physiologic responses to a concentrated meal. Vet. Clin. N. Am. Equine Pract 6:433–50
4. Krunkosky TM, Jarrett CL, Moore JN. 2017 Gross and microscopic anatomy of the equine gastrointestinal tract In The Equine Acute Abdomen, ed. Blikslager AT, White NA, Moore JN, Mair TS, pp. 3–18. Hoboken, NJ: Wiley-Blackwell 3rd ed.
5. Dabareiner RM, White NA. 1995 Large colon impaction in horses: 147 cases (1985–1991). J. Am. Vet. Med. Assoc 206:679–85 [PubMed: 7744691]
6. Ragle CA, Meagher DM, Lacroix CA, Honnas CM. 1989 Surgical treatment of sand colic: results in 40 horses. Vet. Surg 18:48–51 [PubMed: 2929138]
7. Hassel DM, Schiffman PS, Snyder JR. 2001 Petrographic and geochemic evaluation of equine enteroliths. Am. J. Vet. Res 62:350–58 [PubMed: 11277199]
8. Clarke LL, Argenzio RA. 1990 NaCl transport across equine proximal colon and the effect of endogenous prostanoids. Am. J. Physiol 259:G62–69 [PubMed: 2372066]
9. Clarke LL, Argenzio RA, Roberts MC. 1990 Effect of meal feeding on plasma volume and urinary electrolyte clearance in ponies. Am. J. Vet. Res 51:571–76 [PubMed: 2327617]
10. Clarke LL, Ganjam VK, Fichtenbaum B, Hatfield D, Garner HE. 1988 Effect of feeding on reninangiotensin-aldosterone system of the horse. Am. J. Physiol 254:R524–530 [PubMed: 3279828]

Author Manuscript Author Manuscript Author Manuscript Author Manuscript

11. Clarke LL, Roberts MC, Grubb BR, Argenzio RA. 1992 Short-term effect of aldosterone on Na-Cl transport across equine colon. Am. J. Physiol 262:R939–46 [PubMed: 1621872]
12. Hackett ES, Embertson RM, Hopper SA, Woodie JB, Ruggles AJ. 2015 Duration of disease influences survival to discharge of Thoroughbred mares with surgically treated large colon volvulus. Equine Vet. J 47:650–54 [PubMed: 25257041]
13. Suthers JM, Pinchbeck GL, Proudman CJ, Archer DC. 2013 Risk factors for large colon volvulus in the UK. Equine Vet. J 45:558–63 [PubMed: 23414461]
14. Weese JS, Holcombe SJ, Embertson RM, Kurtz KA, Roessner HA, et al. 2014 Changes in the faecal microbiota of mares precede the development of *post partum* colic. Equine Vet. J 47:641–49 [PubMed: 25257320]
15. Schoster A, Arroyo LG, Staempfli HR, Weese JS. 2013 Comparison of microbial populations in the small intestine, large intestine and feces of healthy horses using terminal restriction fragment length polymorphism. BMC Res. Notes 6:91 [PubMed: 23497580]
16. Daly K, Proudman CJ, Duncan SH, Flint HJ, Dyer J, Shirazi-Beechey SP. 2012 Alterations in microbiota and fermentation products in equine large intestine in response to dietary variation and intestinal disease. Br. J. Nutr 107:989–95 [PubMed: 21816118]
17. Zhang K, Hornef MW, Dupont A. 2015 The intestinal epithelium as guardian of gut barrier integrity. Cell. Microbiol 17:1561–69 [PubMed: 26294173]
18. Kararli TT. 1995 Comparison of the gastrointestinal anatomy, physiology, and biochemistry of humans and commonly used laboratory animals. Biopharm. Drug Dispos 16:351–80 [PubMed: 8527686]
19. Gonzalez LM, Kinnin LA, Blikslager AT. 2015 Characterization of discrete equine intestinal epithelial cell lineages. Am. J. Vet. Res 76:358–66 [PubMed: 25815577]
20. Cheng H, Leblond CP. 1974 Origin, differentiation and renewal of the four main epithelial cell types in the mouse small intestine. V. Unitarian theory of the origin of the four epithelial cell types. Am. J. Anat 141:537–61 [PubMed: 4440635]
21. Barker N, Van Es JH, Kuipers J, Kujala P, van den Born M, et al. 2007 Identification of stem cells in small intestine and colon by marker gene *Lgr5*. Nature 449:1003–7 [PubMed: 17934449]
22. Yan KS, Chia LA, Li X, Ootani A, Su J, et al. 2012 The intestinal stem cell markers Bmi1 and Lgr5 identify two functionally distinct populations. PNAS 109:466–71 [PubMed: 22190486]
23. Clevers HC, Bevins CL. 2013 Paneth cells: maestros of the small intestinal crypts. Annu. Rev. Physiol 75:289–311 [PubMed: 23398152]
24. Sankaran-Walters S, Hart R, Dills C. 2017 Guardians of the gut: enteric defensins. Front. Microbiol 8:647 [PubMed: 28469609]
25. Markel TA, Crisostomo PR, Lahm T, Novotny NM, Rescorla FJ, et al. 2008 Stem cells as a potential future treatment of pediatric intestinal disorders. J. Pediatr. Surg 43:1953–63 [PubMed: 18970924]
26. Lin SA, Barker N. 2011 Gastrointestinal stem cells in self-renewal and cancer. J. Gastroenterol 46:1039–55 [PubMed: 21728000]
27. Smith L, Gonzalez LM, Blikslager AT. 2013 Impact of ischemia on components of the equine stem cell niche as determined by immunofluorescence. Vet. Surg 42:E108
28. Gerring Z, Pearson JF, Morrin HR, Robinson BA, Harris GC, Walker LC. 2015 Phosphohistone H3 outperforms Ki67 as a marker of outcome for breast cancer patients. Histopathology 67:538–47 [PubMed: 25728258]
29. Traub-Dargatz JL, Kopral CA, Seitzinger AH, Garber LP, Forde K, White NA. 2001 Estimate of the national incidence of and operation-level risk factors for colic among horses in the United States, spring 1998 to spring 1999. J. Am. Vet. Med. Assoc 219:67–71 [PubMed: 11439773]
30. Proudman CJ. 1992 A two year, prospective survey of equine colic in general practice. Equine Vet. J 24:90–93 [PubMed: 1582399]
31. Proudman CJ, Smith JE, Edwards GB, French NP. 2002 Long-term survival of equine surgical colic cases. Part 2: modelling postoperative survival. Equine Vet. J 34:438–43 [PubMed: 12358044]

Author Manuscript Author Manuscript Author Manuscript Author Manuscript

32. Proudman CJ, Smith JE, Edwards GB, French NP. 2002 Long-term survival of equine surgical colic cases. Part 1: patterns of mortality and morbidity. Equine Vet. J 34:432–37 [PubMed: 12358043]
33. Allen D Jr., White NA 2nd, Tyler DE. 1988 Morphologic effects of experimental distention of equine small intestine. Vet. Surg 17:10–14 [PubMed: 3256138]
34. Dabareiner RM, Sullins KE, Snyder JR, White NA 2nd, Gardner IA. 1993 Evaluation of the microcirculation of the equine small intestine after intraluminal distention and subsequent decompression. Am. J. Vet. Res 54:1673–82 [PubMed: 8250393]
35. White NA 2nd. 1981 Intestinal infarction associated with mesenteric vascular thrombotic disease in the horse. J. Am. Vet. Med. Assoc 178:259–62 [PubMed: 7228781]
36. Gerard MP, Blikslager AT, Roberts MC, Tate LP Jr., Argenzio RA. 1999 The characteristics of intestinal injury peripheral to strangulating obstruction lesions in the equine small intestine. Equine Vet. J 31:331–35 [PubMed: 10454093]
37. Meschter CL, Tyler DE, White NA, Moore J. 1986 Histologic findings in the gastrointestinal tract of horses with colic. Am. J. Vet. Res 47:598–606 [PubMed: 3963560]
38. Moore RM, Hardy J, Muir WW. 1995 Mural blood flow distribution in the large colon of horses during low-flow ischemia and reperfusion. Am. J. Vet. Res 56:812–18 [PubMed: 7653893]
39. Dabareiner RM, Snyder JR, White NA, Pascoe JR, Harmon FA, et al. 1995 Microvascular permeability and endothelial cell morphology associated with low-flow ischemia/reperfusion injury in the equine jejunum. Am. J. Vet. Res 56:639–48 [PubMed: 7661461]
40. Hilton H, Nieto JE, Moore PF, Harmon FA, Naydan DK, Snyder JR. 2011 Expression of cyclooxygenase genes in the jejunum of horses during low-flow ischemia and reperfusion. Am. J. Vet. Res 72:681–86 [PubMed: 21529221]
41. Reeves MJ, Vansteenhouse J, Stashak TS, Yovich JV, Cockerell G. 1990 Failure to demonstrate reperfusion injury following ischaemia of the equine large colon using dimethyl sulphoxide. Equine Vet. J 22:126–32 [PubMed: 2318177]
42. Snyder JR, Olander HJ, Pascoe JR, Holland M, Kurpershoek CJ. 1988 Morphologic alterations observed during experimental ischemia of the equine large colon. Am. J. Vet. Res 49:801–9 [PubMed: 3400917]
43. Snyder JR, Pascoe JR, Olander HJ, Hinds DM, Young R, Tyler WS. 1990 Vascular injury associated with naturally occurring strangulating obstructions of the equine large colon. Vet. Surg 19:446–55 [PubMed: 2264283]
44. Gonzalez LM, Fogle CA, Baker WT, Hughes FE, Law JM, et al. 2015 Operative factors associated with short-term outcome in horses with large colon volvulus: 47 cases from 2006 to 2013. Equine Vet. J 47:279–84 [PubMed: 24735170]
45. Laws EG, Freeman DE. 1995 Significance of reperfusion injury after venous strangulation obstruction of equine jejunum. J. Investig. Surg 8:263–70 [PubMed: 8519742]
46. Blikslager AT, Roberts MC, Rhoads JM, Argenzio RA. 1997 Is reperfusion injury an important cause of mucosal damage after porcine intestinal ischemia? Surgery 121:526–34 [PubMed: 9142151]
47. Van Hoogmoed L, Snyder JR, Pascoe JR, Olander H. 2000 Use of pelvic flexure biopsies to predict survival after large colon torsion in horses. Vet. Surg 29:572–77 [PubMed: 11098791]
48. Freeman DE, Schaeffer DJ, Cleary OB. 2014 Long-term survival in horses with strangulating obstruction of the small intestine managed without resection. Equine Vet. J 46:711–17 [PubMed: 24237247]
49. McAnulty JF, Stone WC, Darien BJ. 1997 The effects of ischemia and reperfusion on mucosal respiratory function, adenosine triphosphate, electrolyte, and water content in the ascending colon of ponies. Vet. Surg 26:172–81 [PubMed: 9150554]
50. Gonzalez LM, Moeser AJ, Blikslager AT. 2015 Animal models of ischemia-reperfusion-induced intestinal injury: progress and promise for translational research. Am. J. Physiol. Gastrointest. Liver Physiol 308:G63–G75 [PubMed: 25414098]
51. Dart AJ, Snyder JR, Julian D, Hinds DM. 1992 Microvascular circulation of the small intestine in horses. Am. J. Vet. Res 53:995–1000 [PubMed: 1626791]

Author Manuscript Author Manuscript Author Manuscript Author Manuscript

52. Chiu CJ, McArdle AH, Brown R, Scott HJ, Gurd FN. 1970 Intestinal mucosal lesion in low-flow states. I. A morphological, hemodynamic, and metabolic reappraisal. Arch. Surg 101:478–83 [PubMed: 5457245]
53. Grosche A, Morton AJ, Graham AS, Sanchez LC, Blikslager AT, et al. 2011 Ultrastructural changes in the equine colonic mucosa after ischaemia and reperfusion. Equine Vet. J. Suppl 2011(39):8–15
54. Graham AS, Grosche A, Morton AJ, Polyak MM, Freeman DE. 2011 In vitro and in vivo responses of mucosa from the large colon of horses to ischemia and reperfusion. Am. J. Vet. Res 72:982–89 [PubMed: 21728860]
55. Grosche A, Morton AJ, Graham AS, Polyak MM, Freeman DE. 2013 Effect of large colon ischemia and reperfusion on concentrations of calprotectin and other clinicopathologic variables in jugular and colonic venous blood in horses. Am. J. Vet. Res 74:1281–90 [PubMed: 24066912]
56. Blikslager AT, Moeser AJ, Gookin JL, Jones SL, Odle J. 2007 Restoration of barrier function in injured intestinal mucosa. Physiol. Rev 87:545–64 [PubMed: 17429041]
57. Moore RM, Muir WW, Granger DN. 1995 Mechanisms of gastrointestinal ischemia-reperfusion injury and potential therapeutic interventions: a review and its implications in the horse. J. Vet. Intern. Med 9:115–32 [PubMed: 7674213]
58. Prichard M, Ducharme NG, Wilkins PA, Erb HN, Butt M. 1991 Xanthine oxidase formation during experimental ischemia of the equine small intestine. Can. J. Vet. Res 55:310–14 [PubMed: 1790484]
59. Moore RM, Muir WW, Bertone AL, Oliver JL. 1998 Effect of platelet-activating factor antagonist L-691,880 on low-flow ischemia-reperfusion injury of the large colon in horses. Vet. Surg 27:37–48 [PubMed: 9449176]
60. Blikslager AT, Roberts MC, Gerard MP, Argenzio RA. 1997 How important is intestinal reperfusion injury in horses? J. Am. Vet. Med. Assoc 211:1387–89 [PubMed: 9394886]
61. Kubes P, Hunter J, Granger DN. 1992 Ischemia/reperfusion-induced feline intestinal dysfunction: importance of granulocyte recruitment. Gastroenterology 103:807–12 [PubMed: 1323498]
62. Park PO, Haglund U, Bulkley GB, Falt K. 1990 The sequence of development of intestinal tissue injury after strangulation ischemia and reperfusion. Surgery 107:574–80 [PubMed: 2159192]
63. Rotting AK, Freeman DE, Constable PD, Eurell JA, Wallig MA. 2008 Mucosal distribution of eosinophilic granulocytes within the gastrointestinal tract of horses. Am. J. Vet. Res 69:874–79 [PubMed: 18593236]
64. Rotting AK, Freeman DE, Constable PD, Eurell JA, Wallig MA. 2016 Effects of ischemia and reperfusion on eosinophilic accumulation and distribution in mucosa of equine jejunum and colon. Am. J. Vet. Res 77:534–39 [PubMed: 27111021]
65. Grosche A, Freeman DE, Morton AJ, Polyak MM, Matyjaszek SA. 2012 Effects of ischemia and reperfusion on production of nitrotyrosine, activation of eosinophils, and apoptosis in the large colonic mucosa of horses. Am. J. Vet. Res 73:53–61 [PubMed: 22204288]
66. Moore R, Carlson S, Madara JL. 1989 Villus contraction aids repair of intestinal epithelium after injury. Am. J. Physiol 257:G274–83 [PubMed: 2764111]
67. Gookin JL, Rhoads JM, Argenzio RA. 2002 Inducible nitric oxide synthase mediates early epithelial repair of porcine ileum. Am. J. Physiol. Gastrointest. Liver Physiol 283:G157–68 [PubMed: 12065303]
68. Erickson RA, Tarnawski A, Dines G, Stachura J. 1990 16,16-Dimethyl prostaglandin E2 induces villus contraction in rats without affecting intestinal restitution. Gastroenterology 99:708–16 [PubMed: 2116342]
69. Cook VL, Jones Shults J, McDowell M, Campbell NB, Davis JL, Blikslager AT. 2008 Attenuation of ischaemic injury in the equine jejunum by administration of systemic lidocaine. Equine Vet. J 40:353–57 [PubMed: 18321812]
70. Cook VL, Meyer CT, Campbell NB, Blikslager AT. 2009 Effect of firocoxib or flunixin meglumine on recovery of ischemic-injured equine jejunum. Am. J. Vet. Res 70:992–1000 [PubMed: 19645580]

Author Manuscript Author Manuscript Author Manuscript Author Manuscript

71. Little D, Brown SA, Campbell NB, Moeser AJ, Davis JL, Blikslager AT. 2007 Effects of the cyclooxygenase inhibitor meloxicam on recovery of ischemia-injured equine jejunum. Am. J. Vet. Res 68:614–24 [PubMed: 17542694]
72. White NA, Moore JN, Trim CM. 1980 Mucosal alterations in experimentally induced small intestinal strangulation obstruction in ponies. Am. J. Vet. Res 41:193–98 [PubMed: 7369591]
73. Moore R, Carlson S, Madara JL. 1989 Rapid barrier restitution in an in vitro model of intestinal epithelial injury. Lab. Investig 60:237–44 [PubMed: 2915518]
74. Moore R, Madara JL, MacLeod RJ. 1994 Enterocytes adhere preferentially to collagen IV in a differentially regulated divalent cation-dependent manner. Am. J. Physiol 266:G1099–107 [PubMed: 8023941]
75. Moore R, Madri J, Carlson S, Madara JL. 1992 Collagens facilitate epithelial migration in restitution of native guinea pig intestinal epithelium. Gastroenterology 102:119–30 [PubMed: 1727745]
76. McCormack SA, Viar MJ, Johnson LR. 1992 Migration of IEC-6 cells: a model for mucosal healing. Am. J. Physiol 263:G426–35 [PubMed: 1415554]
77. Blikslager AT, Roberts MC. 1997 Mechanisms of intestinal mucosal repair. J. Am. Vet. Med. Assoc 211:1437–41 [PubMed: 9394896]
78. Podolsky DK. 1999 Mucosal immunity and inflammation. V. Innate mechanisms of mucosal defense and repair: The best offense is a good defense. Am. J. Physiol 277:G495–99 [PubMed: 10484372]
79. Wang JY, Johnson LR. 1992 Role of transglutaminase and protein cross-linking in the repair of mucosal stress erosions. Am. J. Physiol 262:G818–25 [PubMed: 1350421]
80. Moeser AJ, Haskell MM, Shifflett DE, Little D, Schultz BD, Blikslager AT. 2004 ClC-2 chloride secretion mediates prostaglandin-induced recovery of barrier function in ischemia-injured porcine ileum. Gastroenterology 127:802–15 [PubMed: 15362036]
81. Nighot PK, Blikslager AT. 2012 Chloride channel ClC-2 modulates tight junction barrier function via intracellular trafficking of occludin. Am. J. Physiol. Cell Physiol 302:C178–87 [PubMed: 21956164]
82. Tomlinson J, Blikslager A. 2003 Role of nonsteroidal anti-inflammatory drugs in gastrointestinal tract injury and repair. J. Am. Vet. Med. Assoc 222:946–51 [PubMed: 12685784]
83. Morton AJ, Grosche A, Matyjaszek SA, Polyak MM, Freeman DE. 2011 Effects of flunixin meglumine on the recovery of ischaemic equine colonic mucosa in vitro. Equine Vet. J. Suppl 2011(39):112–16
84. Nighot PK, Leung L, Ma TY. 2017 Chloride channel ClC-2 enhances intestinal epithelial tight junction barrier function via regulation of caveolin-1 and caveolar trafficking of occludin. Exp. Cell Res 352:113–22 [PubMed: 28161538]
85. Grisham MB, Hernandez LA, Granger DN. 1986 Xanthine oxidase and neutrophil infiltration in intestinal ischemia. Am. J. Physiol 251:G567–74 [PubMed: 3020994]
86. Krieglstein CF, Cerwinka WH, Laroux FS, Salter JW, Russell JM, et al. 2001 Regulation of murine intestinal inflammation by reactive metabolites of oxygen and nitrogen: divergent roles of superoxide and nitric oxide. J. Exp. Med 194:1207–18 [PubMed: 11696587]
87. Kurtel H, Fujimoto K, Zimmerman BJ, Granger DN, Tso P. 1991 Ischemia-reperfusion-induced mucosal dysfunction: role of neutrophils. Am. J. Physiol 261:G490–96 [PubMed: 1887895]
88. Gayle J, Jones SL, Argenzio RA, Blikslager AT. 2002 Neutrophils increase paracellular permeability of restituted ischemic-injured porcine ileum. Surgery 132:461–70 [PubMed: 12324760]
89. Tomlinson JE, Wilder BO, Young KM, Blikslager AT. 2004 Effects of flunixin meglumine or etodolac treatment on mucosal recovery of equine jejunum after ischemia. Am. J. Vet. Res 65:761–69 [PubMed: 15198216]
90. Cook VL, Jones Shults J, McDowell MR, Campbell NB, Davis JL, et al. 2009 Anti-inflammatory effects of intravenously administered lidocaine hydrochloride on ischemia-injured jejunum in horses. Am. J. Vet. Res 70:1259–68 [PubMed: 19795941]
91. Blikslager AT. 1999 Do we need cyclooxygenase-2 inhibitors in equine practice? Comp. Contin. Educ. Pract. Vet 21:548–50

Author Manuscript Author Manuscript Author Manuscript Author Manuscript

92. Marshall JF, Bhatnagar AS, Bowman SG, Howard CM, Morris NN, et al. 2011 Evaluation of the cyclooxygenase selectivity of robenacoxib and its effect on recovery of ischemia-injured jejunal mucosa in horses. Am. J. Vet. Res 72:226–32 [PubMed: 21281197]

93. Tomlinson JE, Blikslager AT. 2004 Effects of ischemia and the cyclooxygenase inhibitor flunixin on in vitro passage of lipopolysaccharide across equine jejunum. Am. J. Vet. Res 65:1377–83 [PubMed: 15524324]

94. Tomlinson JE, Blikslager AT. 2005 Effects of cyclooxygenase inhibitors flunixin and deracoxib on permeability of ischaemic-injured equine jejunum. Equine Vet. J 37:75–80 [PubMed: 15651739]

95. Marshall JF, Blikslager AT. 2011 The effect of nonsteroidal anti-inflammatory drugs on the equine intestine. Equine Vet. J. Suppl 43(39):140–44

96. Fogle J, Jacob M, Blikslager A, Edwards A, Wagner B, et al. 2016 Comparison of lipopolysaccharides and soluble CD14 measurement between clinically endotoxaemic and nonendotoxaemic horses. Equine Vet. J 49:155–59 [PubMed: 27060869]

97. Cook VL, Neuder LE, Blikslager AT, Jones SL. 2009 The effect of lidocaine on in vitro adhesion and migration of equine neutrophils. Vet. Immunol. Immunopathol 129:137–42 [PubMed: 19136156]

98. Cook VL, Blikslager AT. 2008 Use of systemically administered lidocaine in horses with gastrointestinal tract disease. J. Am. Vet. Med. Assoc 232:1144–48 [PubMed: 18412523]

99. Blikslager AT, Rhoads JM, Bristol DG, Roberts MC, Argenzio RA. 1999 Glutamine and transforming growth factor-alpha stimulate extracellular regulated kinases and enhance recovery of villous surface area in porcine ischemic-injured intestine. Surgery 125:186–94 [PubMed: 10026753]

100. Sato T, Vries RG, Snippert HJ, van de Wetering M, Barker N, et al. 2009 Single Lgr5 stem cells build crypt-villus structures in vitro without a mesenchymal niche. Nature 459:262–65 [PubMed: 19329995]

101. Gonzalez LM, Williamson I, Piedrahita JA, Blikslager AT, Magness ST. 2013 Cell lineage identification and stem cell culture in a porcine model for the study of intestinal epithelial regeneration. PLOS ONE 8:e66465 [PubMed: 23840480]

102. Sato T, Stange DE, Ferrante M, Vries RG, Van Es JH, et al. 2011 Long-term expansion of epithelial organoids from human colon, adenoma, adenocarcinoma, and Barrett's epithelium. Gastroenterology 141:1762–72 [PubMed: 21889923]

103. Jacobs C, Southwood L, Lindborg S. 2014 Development of an in-vitro three-dimensional culture system for equine gastrointestinal crypts. Presented at 11th Equine Colic Res. Symp., Dublin, Irel.

104. Kretzschmar K, Clevers H. 2016 Organoids: modeling development and the stem cell niche in a dish. Dev. Cell 38:590–600 [PubMed: 27676432]

105. Yui S, Nakamura T, Sato T, Nemoto Y, Mizutani T, et al. 2012 Functional engraftment of colon epithelium expanded *in vitro* from a single adult $Lgr5^{+}$ stem cell. Nat. Med 18:618–23 [PubMed: 22406745]

106. Powell RH, Behnke MS. 2017 WRN conditioned media is sufficient for in vitro propagation of intestinal organoids from large farm and small companion animals. Biol. Open 6:698–705 [PubMed: 28347989]

Author Manuscript Author Manuscript Author Manuscript Author Manuscript

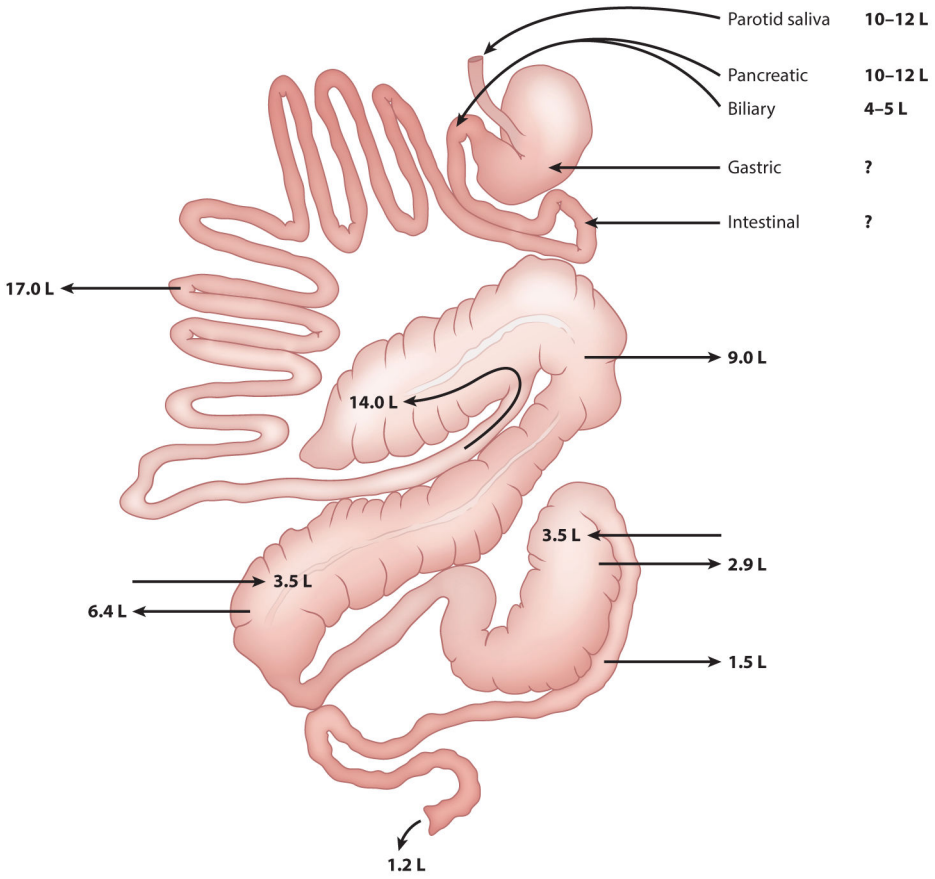

Figure 1.

Enterosystemic cycle of fluid in a 100-kg pony. Proximal secretions approximate the animal's entire extracellular fluid volume during a 24-h period. In animals fed twice daily (meal fed), periods of net secretion alternate with net absorption (L) in the large colon, as shown by the sets of opposite pointing arrows. Adapted from Reference 1.

Author Manuscript Author Manuscript Author Manuscript Author Manuscript

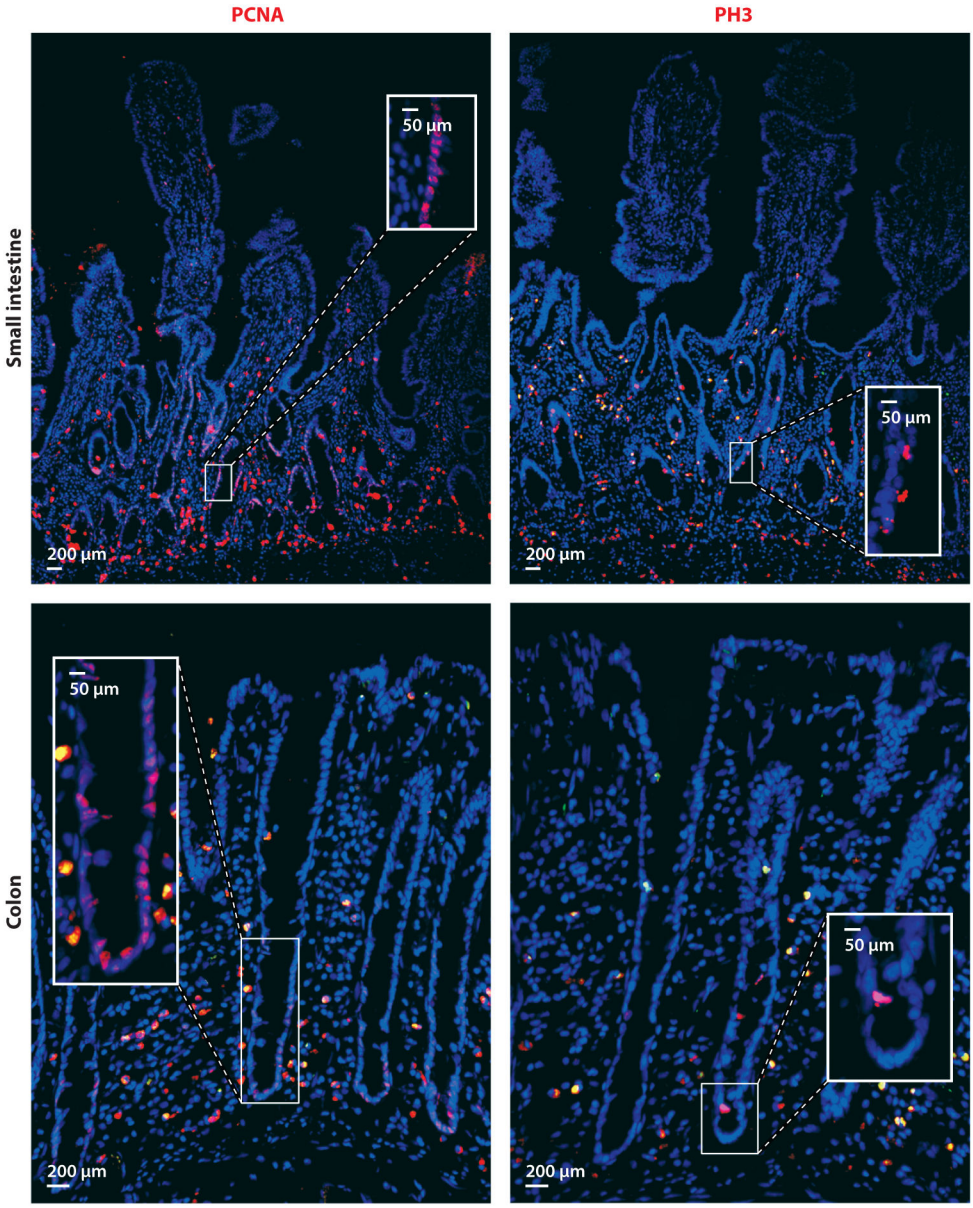

Figure 2.

Appearance of the stem cell niche in equine small intestine and colon. Cells undergoing proliferation can be identified using several markers, including proliferating cell nuclear antigen (PCNA) and phosphohistone 3 (PH3). The latter marks cells in the G2-M phase of the cell cycle, an important marker of colonic viability in the horse. Note pink staining in each image, indicative of co-localization of blue staining of nuclei with bisbenzamide and the respective stem cell marker. Red and yellow staining within the lamina propria is attributable to autofluorescence. Adapted with permission from a figure originally published in Reference 19.

Author Manuscript Author Manuscript Author Manuscript Author Manuscript

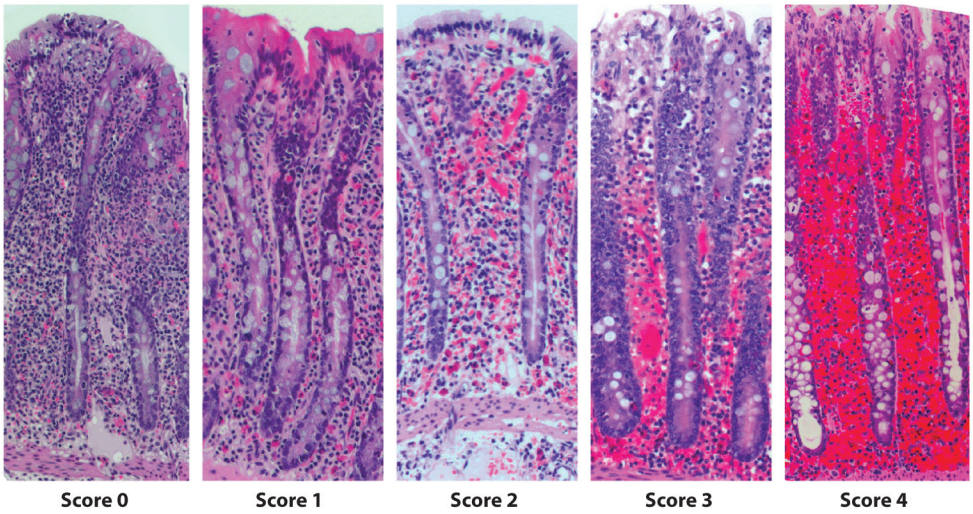

Figure 3.

Hemorrhage score within the lamina propria is assigned a score from 0 to 4: 0, no hemorrhage; 1, few individual red blood cells (RBCs) within the lamina propria; 2, increased number of individual RBCs; 3, appearance of clumps of RBCs; and 4, no clear demarcation between RBCs, obscuring the lamina propria. Adapted from a figure originally published in Reference 44.

Author Manuscript Author Manuscript Author Manuscript Author Manuscript

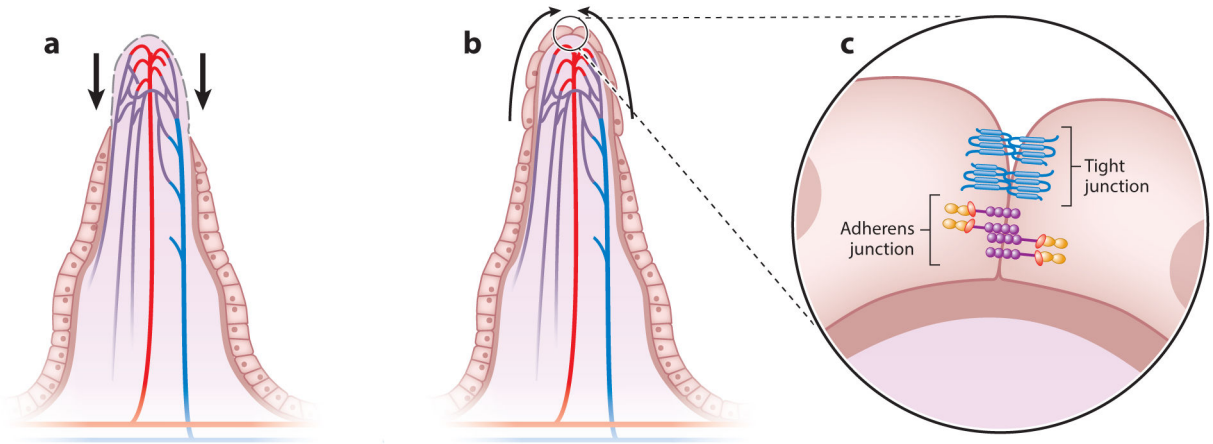

Figure 4.

Diagram of the reparative events that occur following ischemic injury in horses. (*a*) Initially, the villi in the small intestine contract (*arrows*), reducing the surface area of the mucosal wound. (*b*) At the same time, healthy cells adjacent to the wound flatten and crawl across intact basement membrane using a process called epithelial restitution. (*c*) Finally, interepithelial junctional structures (tight junctions and adherens junctions) are reformed to seal the intestinal barrier. Adapted from artwork originally provided by North Carolina State University.

Author Manuscript Author Manuscript Author Manuscript Author Manuscript

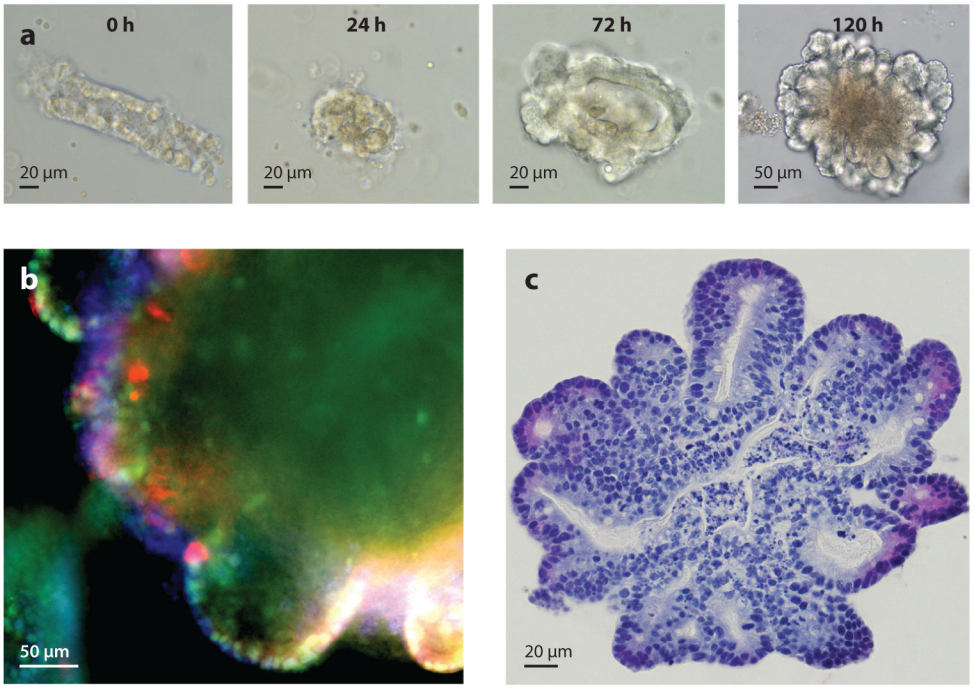

Figure 5.

Equine enteroid culture. (*a*) Time course crypt culture 0–120 h postplating. (*b*) Whole mount imaged enteroid with fluorescently labeled enteroendocrine cells (*red*), proliferative cells (*green*), and general nuclear stain (*blue*). Outwardly budding crypts are visible peripherally with formation of a pseudolumen centrally. Three-dimensionality creates multiple visual planes with cells visible both in and out of focus. (*c*) Formalin-fixed, paraffin-embedded, sectioned, and hematoxylin- and eosin-stained 7-day cultured enteroid.

Author Manuscript Author Manuscript Author Manuscript Author Manuscript

Table 1

Comparative levels of oxidant enzymes in intestinal tissues[a]

Species	Intestinal segment	Total XO/XDH (mU/g tissue)	Myeloperoxidase (U/g tissue)
Cat (adult)	Jejunum	80	12
	Ileum	-	-
Rat (adult)	Jejunum	405–523	1.9
	Ileum	150	-
Pig (6–8 weeks)	Jejunum	3.4 (0)[b]	-
	Ileum	0.4 (0.9)[b]	2.2
Horse (adult)	Jejunum	100–131 (60)[b]	0.02
	Ileum	30–48 (0)[b]	0.1
Human (adult)	Jejunum	29–56 (0)[b]	-

[a]Levels of xanthine oxidase/xanthine dehydrogenase (XO/XDH), the enzyme system thought to be responsible for triggering reperfusion injury, and myeloperoxidase as a surrogate marker for neutrophils, the immune cells responsible for amplifying reperfusion injury.

[b]Neonatal levels.