Journal of Veterinary Internal Medicine

Journal of Veterinary Internal Medicine Open Access
ACVIM American College of Veterinary Internal Medicine

STANDARD ARTICLE OPEN ACCESS

Small Animal Internal Medicine Nephrology/Urology

In Vivo Radiographic Characteristics Associated With the Mineral Composition of Calcium Oxalate, Struvite, and Cystine Lower Urinary Tract Uroliths in Dogs

Diego Pulido Vega[1] | Mathieu Motteau-Lévêque[2] | Christelle Maurey[3] | Jeremy Mortier[1]

[1]Service of Diagnostic Imaging, École Nationale Vétérinaire d'Alfort, Maisons-Alfort, France | [2]École Nationale Vétérinaire d'Alfort, Maisons-Alfort, France | [3]Service of Internal Medicine, École Nationale Vétérinaire d'Alfort, INRAE, ANSES, UMR Virology, Laboratoire de Santé Animale, Maisons-Alfort, France

Correspondence: Diego Pulido Vega (diego.pulido-vega@vet-alfort.fr)

Received: 2 April 2025 | **Revised:** 12 September 2025 | **Accepted:** 12 September 2025

Funding: The authors received no specific funding for this work.

Keywords: bladder | calculi | mineral prediction | urethra | urinary stones | urolithiasis

ABSTRACT

Background: Identifying urolith mineral composition (UMC) is crucial for treatment and prevention; however, current data rely on macroscopic or ex vivo studies.

Objectives: To describe in vivo radiographic characteristics of canine lower urinary tract (LUT) uroliths and identify discriminating radiographic features among UMC types.

Animals: Two hundred and two dogs with LUT uroliths composed of ≥ 70% calcium oxalate ($n = 109$), struvite ($n = 58$), or cystine ($n = 35$).

Methods: Retrospective cross-sectional study. Radiographs were evaluated for urolith size, shape, surface, borders, internal architecture, and quantitative radiopacity, and also assessed using a ratio of urolith-to-L5 vertebra pixel values (UOR). The diagnostic performance of urolith size and UOR was assessed with receiver operating characteristics (ROC) curves, calculating the area under the ROC curve (AUC).

Results: Calcium oxalate uroliths were often highly radiopaque, associated with concurrent nephroliths, had unique shapes such as bosselated or spiculated, and less commonly ovoid. Struvite uroliths were larger (median: 15 mm; IQR: 8.1–25.8 mm) with a cut-off of ≥ 11 mm (AUC = 0.82, $p < 0.001$; specificity: 91%, sensitivity: 67%) and were associated with pyramidal shapes or solitary cystoliths. Cystine uroliths had lower radiopacity (median UOR: 0.71; IQR: 0.63–0.80), with a cut-off of UOR ≤ 0.83 (AUC = 0.81, $p < 0.001$; specificity: 67%, sensitivity: 84%).

Conclusions and Clinical Importance: In vivo radiographic characteristics such as size, shape, and radiopacity can help differentiate LUT mineral compositions, enabling non-invasive diagnosis and guiding treatment.

Abbreviations: ANCOVA, analysis of covariance; AUC, area under the ROC curve; CFU, colony-forming units; CI, confidence interval; ICC, intraclass correlation coefficient; IQR, interquartile range; LUT, lower urinary tract; MPV, mean pixel value; OR, odds ratio; ROC, receiver operating characteristic; UMC, urolith mineral composition; UOR, urolith-to-L5 mean pixel value ratio; UUT, upper urinary tract.

This is an open access article under the terms of the Creative Commons Attribution-NonCommercial-NoDerivs License, which permits use and distribution in any medium, provided the original work is properly cited, the use is non-commercial and no modifications or adaptations are made.

© 2025 The Author(s). *Journal of Veterinary Internal Medicine* published by Wiley Periodicals LLC on behalf of American College of Veterinary Internal Medicine.

1 | Introduction

Urolithiasis is a common and often recurring condition in dogs, with calcium oxalate and struvite (magnesium ammonium phosphate) uroliths being the most prevalent, followed by urate, silica, and cystine uroliths [1–4]. An accurate diagnosis of the urolith mineral composition (UMC) is critical for selecting appropriate therapeutic and prevention strategies [5]. Struvite, urates, and cystine uroliths should be treated with medical dissolution and dietary therapies [6, 7] before considering invasive removal. Calcium oxalate and silica uroliths require removal by surgery, endoscopy, voiding urohydropropulsion, or lithotripsy [5, 8, 9]. Identification of UMC is also valuable to detect concurrent disease, as evidenced by the association of calcium-containing uroliths with hyperadrenocorticism [10]. Urolith mineral composition prediction in vivo is based on a combination of several factors, including epidemiological data, urinalysis characteristics, and imaging features [11–16]. Radiography, a cost-effective, widely available, and non-invasive modality, allows detection of radiopaque uroliths in most portions of the urinary tract in a single examination and provides various pieces of information (e.g., number, size, location, radiopacity, shape, surface contour, internal architecture) [17]. Radiography also provides some insight into urolith type, although there is considerable overlap between types of uroliths [18]. Computed tomography can also be useful in UMC prediction with the use of mean beam attenuation but is not widely used for this purpose in veterinary medicine [19, 20].

Current data on the radiographic characteristics of canine uroliths and the prediction of UMC are based either on macroscopic or ex vivo film radiographic observations on pure mineral composition uroliths within a bladder phantom [21–23] or on specialists' experience [17, 24, 25]. In vivo studies reflect clinical conditions, where radiographic features might differ from ex vivo [23], but have primarily focused on urolith visibility rather than describing features such as shape, size, or quantitative opacity [26, 27]. In addition, studying pure mineral composition uroliths seems inappropriate, as 73% of uroliths contain at least 2 mineral substances [28], and impurities alter crystal morphologies [29]. Assessing predominant UMC uroliths (i.e., ≥70% of a mineral composition) [30] provides a more clinically relevant perspective. To the authors' knowledge, no study has documented an in vivo radiographic description or prediction of the most common canine uroliths characterized by their predominant UMC.

The purpose of this retrospective cross-sectional study was to describe the in vivo radiographic characteristics of common canine uroliths, to identify discriminating criteria, and provide thresholds to help differentiate UMC without invasive procedures. We hypothesized that radiographic features, including size, number, surface and border characteristics, concurrent nephroliths, and opacity, would vary by mineral composition, based *on* ex vivo literature. We further hypothesized that calcium oxalate uroliths would more often appear bosselated or spiculated, and struvite uroliths would more often be pyramidal. Finally, and based on our clinical experience, we hypothesized that infected struvite LUT uroliths would be larger than sterile struvite uroliths.

2 | Materials and Methods

2.1 | Study Design and Selection of Animals

Medical records of dogs with lower urinary tract urolithiasis (LUT) presenting to the small animal hospital of École nationale vétérinaire d'Alfort between September 1, 2009 and August 31, 2023 were retrospectively searched and reviewed. Dogs were included if they had a lateral abdominal radiograph taken within a week before urolith removal and laboratory confirmation of a LUT urolith with a predominant UMC (i.e., ≥70% [30]) of calcium oxalate, struvite, or cystine. Dogs were classified into 3 groups according to these criteria. Dogs with mixed uroliths (i.e., those with a UMC < 70%) or of a different UMC than those studied were excluded from the study. The latter criterion was selected to guarantee adequate group sizes and comparability for statistical analysis. Quantitative UMC analysis was performed by infrared spectroscopy by Vet'Analys laboratories using a Fourier transform infrared spectrometer (Spectrum Two; PerkinElmer, UK) with a resolution of $4\,cm^{-1}$ and a measurement range of 4000 to $450\,cm^{-1}$. The urolith was sectioned if larger than 5 mm and observed under a binocular microscope to determine the presence of different layers. If necessary, each layer was removed and analyzed separately. When multiple uroliths were removed, UMC was determined based on the analysis of all retrieved uroliths. Demographic data collected included sex, neuter status, breed, age, and weight at diagnosis. When no antimicrobial treatment was ongoing and urine collected by cystocentesis was available, bacterial culture results were recorded. A part of the urine sample was placed in a sterile tube and either immediately sent to the microbiology laboratory or temporarily stored at 4°C before transfer. An aliquot of 10 to 100 μL of well-mixed urine was inoculated onto blood agar, spread to isolate single colonies, and incubated aerobically at 37°C for up to 72 h. Bacterial growth and purity were assessed every 24 h, with any growth of ≥1000 colony-forming units (CFU)/mL considered significant. Identification of bacterial isolates was performed using matrix-assisted laser desorption/ionization time-of-flight mass spectrometry.

2.2 | Radiographic Data Collection

Radiographic studies included at least one lateral projection of the abdomen. They were anonymized, blinded from any signalment or clinical information, and presented in random order to a veterinary radiology resident (DPV). Standard image viewing software (Osirix v.11.0.3) was used to assess the radiographs. For each dog, the blinded observer assessed the number of radiopaque uroliths within the kidney, the ureters, the urinary bladder, and the urethra. If no LUT urolith was visible, this was noted, and no other characteristics were assessed. If visible, the largest LUT urolith was measured and classified according to shape (ovoid, bosselated, pyramidal, faceted, spiculated, cylindrical, irregular), internal architecture (uniform or non-uniform), surface characteristics (smooth or rough), and border characteristics (rounded or sharp) [21, 22]. The opacity of the largest LUT urolith was subjectively graded as mild, moderate, or marked. To quantitatively assess cystolith opacity, x-ray signal intensity was estimated using the mean pixel value (MPV) [31] within a circular region of interest (ROI) placed to include

as much of the largest cystolith as possible, taking care to avoid urolith peripheral margins as well as superimposition with other uroliths, gastrointestinal tract, and potential bubbles of gas from prior catheterization (Figure 1). The MPV within a circular ROI placed at the caudal third of the L5 vertebra was also measured, taking care to avoid superimposition with cortical bone and with vertebral transverse processes. Finally, a ratio of urolith's MPV to L5 MPV (labeled UOR) was calculated. To limit bias related to soft tissue superimposition, dogs with urethroliths without cystoliths were excluded from UOR measurements. To avoid any influence between the assessments, the quantitative evaluation of opacity was performed 3 months after the initial subjective assessment. To evaluate inter-observer agreement for UOR measurements, a veterinary radiology specialist assessed a subset of 40 randomly selected radiographs initially reviewed by a veterinary radiology resident. To evaluate intra-observer repeatability, the same veterinary radiology resident measured UOR again on a subset of 40 randomly selected radiographs after a 6-month interval, presented in a newly randomized order.

2.3 | Statistical Analysis

Continuous variables were assessed for normality using the Shapiro–Wilk test. As no numerical variable followed a normal distribution, the quantitative and ordinal results were reported as medians and interquartile ranges (IQR). Analyses of epidemiologic data were descriptive only. Odds ratios (OR) were given relative to a reference UMC, and confidence intervals for the 95% level of confidence (95% CI) were calculated using the Wald method. For UOR measurements, inter-observer agreement was quantified using the intraclass correlation coefficient (ICC) based on a two-way random-effects model assessing absolute agreement and reported with 95% CI. Inter-observer repeatability was assessed using ICC calculated under a two-way mixed-effects model for absolute agreement with 95% CIs. ICC values were interpreted according to established guidelines [32, 33]: <0.50: poor, 0.50 to 0.75: moderate, 0.76 to 0.90: good, and >0.9: excellent reliability. Associations between radiographic characteristics and UMC were evaluated based solely on a priori hypotheses derived from pre-existing literature or authors' experience in a confirmatory way. Otherwise, no statistical test was performed. Therefore, no correction for multiple testing was deemed necessary [34]. The Mann–Whitney U test was used for continuous data and either the χ^2 test or Fisher's exact test for categorical data. To determine whether UMC was associated with UOR independently of urolith size, we performed an analysis of covariance (ANCOVA) using UOR as the dependent variable, mineral type as the independent variable, and log-transformed urolith size as a covariate. Pairwise comparisons were tested using Tukey's test. Receiver operating characteristic (ROC) curves were used to assess the diagnostic utility of quantitative radiographic parameters (UOR and urolith size) to differentiate dogs between groups. The generalized Youden index was used to identify optimal cut-off values. Area under the ROC curve (AUC; with 95% CI), sensitivity, specificity, and likelihood ratios (LR) were calculated for optimal cut-off values. An AUC of >0.9 was interpreted as excellent, 0.8 to 0.89 as good, 0.7 to 0.79 as fair, 0.6 to 0.69 as poor, and 0.5 to 0.59 as failure [35]. Statistical analysis was performed using a statistical package [36]. For all analyses, p-values <0.05 were considered significant.

3 | Results

3.1 | Study Cohort and Signalment

Two hundred and fifty-five dogs with IR-confirmed LUT uroliths were recruited for the study, with each urolith obtained from a different dog. 26 dogs were excluded due to a lack of preoperative radiographs. Of the remaining 229 cases, 16 dogs were excluded because they presented mixed uroliths and 15 because they were predominantly composed of a different UMC (calcium phosphate: 7/229; urate: 6/229; silica: 1/229; pure protein: 1/229). The remaining 202 cases were included in the study, of which 133 were intact males, 29 were neutered males, 18 were intact

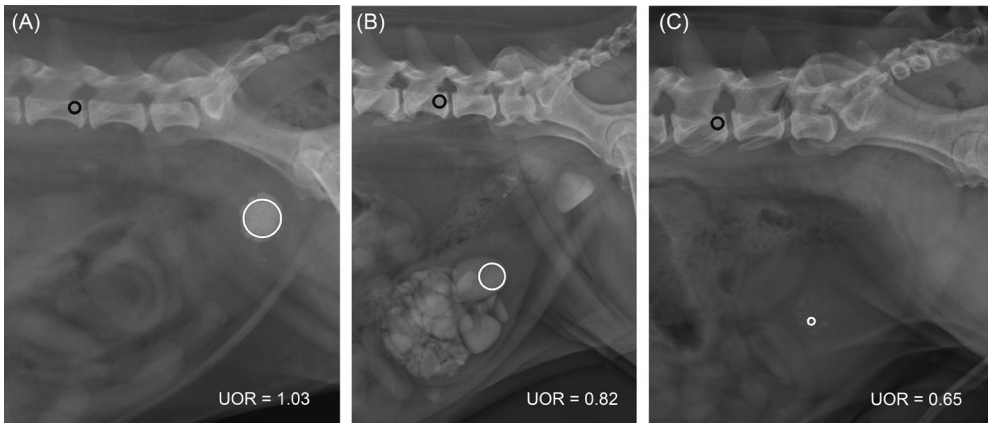

FIGURE 1 | Measurements of the ratio (labeled UOR) of the mean pixel value (MPV) of the largest cystolith to the L5 MPV on lateral abdominal radiographs in three dogs. A circular ROI is positioned at the caudal third of L5 vertebra (black circle) with care to avoid superimposition with cortical bone and vertebral transverse processes, and a circular ROI is placed on the largest cystolith (white circle) with care to incorporate as much of the urolith as possible without including its peripheral margins and to avoid superimposition with other uroliths, digestive structures and potential bubbles of gas due to prior catheterization. (A) Bosselated calcium oxalate cystolith in a dog. The MPV of urolith is 2015; the MPV of L5 is 1952; the UOR value is 1.03. (B) Large pyramidal struvite cystoliths and one similar urethrolith in a dog. The MPV of urolith is 1542; The MPV of L5 is 1875; The UOR value is 0.82. (C) Multiple small faceted cystine cystoliths in a dog. The MPV of urolith is 1253; The MPV of L5 is 1914; The UOR value is 0.65.

females, and 22 were neutered females. Breeds represented by ≥10 dogs were Yorkshire Terrier (36), Jack Russell Terrier (14), French Bulldog (13), Bichon (12), and Shi Tzu (12). Median age at presentation was 8 (IQR, 5–10) years and median weight was 9.2 (IQR, 5.2–15.2) kg.

3.2 | Urolith Mineral Composition

The UMC of the population consisted of calcium oxalate uroliths in the majority of dogs (54%, 109/202), followed by struvite uroliths (27%, 58/202), and cystine uroliths (17%, 35/202). The median proportion of the primary component of the urolith was 96.5 (IQR, 90–100)%.

3.3 | Urine Culture Results

Aerobic bacterial culture was available for 165 dogs (82%), of which 54 (33%) were positive. *Staphylococcus* spp. was the most commonly identified bacteria (36/54; 67%). In the remaining cases, *Escherichia coli* (8/54; 15%), *Enterococcus* spp. (4/54; 7%), *Streptococcus* spp. (3/54; 6%), *Proteus* spp. (2/54; 4%), and *Acinetobacter* spp. (1/54; 2%) were cultured. Bacterial culture was positive in 67% (37/55) of dogs with struvite uroliths, 17.5% (14/80) of those with calcium oxalate uroliths, and 10% (3/30) of those with cystine uroliths. Dogs with struvite uroliths had significantly higher odds of a positive culture compared to dogs with calcium oxalate uroliths (OR = 9.69; 95% CI: 4.33–21.70; $p < 0.001$) or cystine uroliths (OR = 18.50; 95% CI: 4.95–69.19; $p < 0.001$). Among dogs with no bacterial culture available, dogs with calcium oxalate were overrepresented (78%, 29/37). Of 37 struvite uroliths with a positive urolith culture, urease-producing bacteria were cultured in 32 cases (87%), with 31 *Staphylococcus* spp. (84%) and one *Proteus* spp. The remaining cases included three *Enterococcus* spp. (8%) and one each of *Escherichia coli* and Streptococcus (3%).

3.4 | General Radiographic Features

Preoperative abdominal radiographs were reviewed in all cases. Uroliths were radiopaque in 197 dogs (98%) and 5 dogs (2%) had radiolucent cystoliths not visible on radiographs, which were confirmed during surgery. Of the dogs with radiopaque uroliths, 192 had cystoliths and the remaining 5 dogs had a urethrolith without a cystolith. Concurrent urethroliths were identified in 32% (64/202) of the dogs with bladder uroliths. Concurrent nephroliths were identified in 31% (62/202) of dogs, of which 2% (4/202) also had ureteral uroliths. The median maximum size of LUT uroliths was 5.6 (IQR, 3.7–10) mm. A solitary LUT urolith was present in 17% (34/197) of dogs while 52% (102/197) of dogs presented ≥10 LUT uroliths.

3.5 | Comparison of Radiographic Features Between Groups

Descriptive radiographic characteristics are presented in Table 1, and significant differences between groups are presented in Figure 2 and Figure 3. The prevalence of radiopaque upper urinary tract (UUT) uroliths (Figure 4A) was significantly higher in dogs with calcium oxalate LUT uroliths (51%, 56/109) compared with dogs with struvite (10%, 6/58; OR = 9.16; 95% CI: 3.63–23.09; $p < 0.001$) and cystine LUT uroliths in which no UUT urolith was found ($p < 0.001$). The prevalence of urethroliths was significantly higher in dogs with calcium oxalate LUT uroliths (40%, 44/109) than struvite (17%, 10/58; OR = 3.25; 95% CI: 1.49–7.10; $p = 0.002$), but not in dogs with cystine LUT uroliths (29%, 10/35; OR = 1.69; 95% CI: 0.74–3.87; $p = 0.21$). A solitary cystolith (Figure 5A) was significantly more frequent in dogs with struvite (28%, 15/54) compared to dogs with calcium oxalate (14%, 15/109; OR = 2.41; 95% CI: 1.08–5.40; $p = 0.03$). A similar trend was noted when compared to dogs with cystine uroliths (12%, 4/34; OR = 2.88; 95% CI: 0.87–9.59), though this difference was not statistically significant ($p = 0.08$). Dogs with ≥10 LUT uroliths were identified in 46% (50/109) of calcium oxalate uroliths, 57% (31/54) of struvite uroliths, and 62% (21/34) of cystine uroliths, with no statistical difference between groups ($p = 0.06$).

The median maximum size of struvite uroliths (median, 15 mm; IQR, 8.1–25.8 mm) was significantly higher compared to cystine uroliths (median, 4.5 mm; IQR, 3.6–6.2 mm; $p < 0.001$) and calcium oxalate uroliths (median, 4.9 mm; IQR, 3.5–7 mm; $p < 0.001$; Figure 3A). Through ROC curve analysis, the maximum size of the LUT urolith was a good discriminator (AUC = 0.82, $p < 0.001$, 95% CI: 0.74–0.90) with an optimal cut-off value to identify struvite of 11 mm (specificity: 91%; sensitivity: 67%). This value was associated with a positive likelihood ratio of 7.3 (95% CI: 4.2–12.7). Uroliths smaller than 3 mm were of all types with no significant difference between groups ($p = 0.14$). Among struvite uroliths, no significant difference was found between infected and sterile uroliths ($p = 0.52$).

Faceted shape was common in the 3 groups, described in 41% (14/34) of cystine uroliths, in 48% (26/54) of struvite uroliths, and in 34% (37/109) of calcium oxalate uroliths. Calcium oxalate uroliths were bosselated (Figure 4B) in 19% (21/109), whereas this morphology was not observed in any of the struvite and cystine uroliths, allowing for a significant difference ($p < 0.001$). Spiculated shape (Figure 4C), although uncommon in calcium oxalate uroliths (11%, 12/109), was observed more frequently in this group compared to struvite uroliths, in which none were identified ($p = 0.01$), and to cystine uroliths (3%, 1/34; OR = 4.08; 95% CI: 0.51–32.61), although the latter comparison was not statistically significant ($p = 0.30$). A cylindrical shape was observed in four calcium oxalate uroliths (Figure 4D), while no such shape was identified in the struvite and cystine uroliths. A pyramidal shape was described in 9% (5/54) of struvite uroliths (Figure 5B), which was significantly more frequent than in calcium oxalate uroliths, where it was not observed ($p = 0.004$). The odds of a pyramidal shape were also higher in struvite uroliths compared to cystine uroliths (3%, 1/34; OR = 3.37; 95% CI: 0.38–30.15) with no statistical significance reached ($p = 0.40$). The prevalence and odds of an ovoid shape were higher in cystine uroliths (47%, 16/34; OR = 4.49; 95% CI: 1.94–10.43) and struvite uroliths (35%, 19/54; OR = 2.74; 95% CI: 1.29–5.83) compared to calcium oxalate uroliths (17%, 18/109). Sharp borders and rough surface were significantly associated with calcium oxalate (35%, 38/109 and 30%, 33/109, respectively) compared to struvite (11%, 6/54; OR = 4.28; 95% CI: 1.68–10.91; $p = 0.001$ and 15%, 8/54;

TABLE 1 | Radiographic findings of cystine, calcium oxalate, and struvite lower urinary tract uroliths in 202 dogs. The percentages are shown in parentheses. Numbers in brackets represent interquartile range.

	Cystine	Calcium oxalate	Struvite
	***N*=35**	***N*=109**	***N*=58**
Presence of UUT uroliths	0 (0%)	56 (51%)	6 (10%)
Presence of urethroliths	10 (29%)	44 (40%)	10 (17%)
Subjective opacity			
Non visible	1 (3%)	0 (0%)	4 (7%)
Mild	15 (43%)	5 (5%)	9 (16%)
Moderate	18 (51%)	47 (43%)	28 (48%)
Marked	1 (3%)	57 (52%)	17 (29%)
	***N*=34**	***N*=109**	***N*=54**
Median UOR	0.71 [0.63–0.80]	0.94 [0.82–1.02]	0.85 [0.71–0.96]
Median maximal size (mm)	4.5 [3.6–6.2]	4.9 [3.5–7.0]	15 [8.1–25.8]
Number of LUT uroliths			
Single LUT urolith	4 (12%)	15 (14%)	15 (28%)
≥10 LUT uroliths	21 (62%)	50 (46%)	31 (57%)
Shape			
Bosselated	0 (0%)	21 (19%)	0 (0%)
Faceted	14 (41%)	37 (34%)	26 (48%)
Irregular	2 (6%)	17 (16%)	4 (7%)
Ovoid	16 (47%)	18 (17%)	19 (35%)
Pyramidal	1 (3%)	0 (0%)	5 (9%)
Spiculated	1 (3%)	12 (11%)	0 (0%)
Cylindrical	0 (0%)	4 (4%)	0 (0%)
Internal architecture			
Uniform	30 (88%)	89 (82%)	40 (74%)
Non-uniform	4 (12%)	20 (18%)	14 (26%)
Surface characteristics			
Smooth	28 (82%)	76 (70%)	46 (85%)
Rough	6 (18%)	33 (30%)	8 (15%)
Border characteristics			
Rounded	26 (76%)	71 (65%)	48 (89%)
Sharp	8 (24%)	38 (35%)	6 (11%)

Abbreviations: LUT: Lower urinary tract; UUT: Upper urinary tract.

OR = 2.50; 95% CI: 1.06–5.87; $p = 0.03$, respectively). However, no significant differences were observed when compared to cystine uroliths (24%, 8/34; OR = 1.74; 95% CI: 0.72–4.21; $p = 0.22$ and 18%, 6/34; OR = 2.03; 95% CI: 0.77–5.36; $p = 0.15$, respectively). Internal architecture was not significantly different between groups ($p = 0.24$).

The majority of cystine uroliths was subjectively classified as mildly or moderately radiopaque (94%, 33/35), whereas most calcium oxalate uroliths were classified as moderately to markedly radiopaque (95%, 104/109). Uroliths subjectively classified as mildly radiopaque were significantly more common in cystine uroliths (43%, 15/35) compared to struvite (16%, 9/58; OR = 4.08; 95% CI: 1.54–10.84; $p = 0.004$) and calcium oxalate uroliths (5%, 5/109; OR = 15.60; 95% CI: 5.09–47.79; $p < 0.001$). Uroliths subjectively classified as markedly radiopaque were significantly more frequent in calcium oxalate uroliths (52%, 57/109) compared to struvite (29%, 17/58; OR = 2.64; 95% CI:

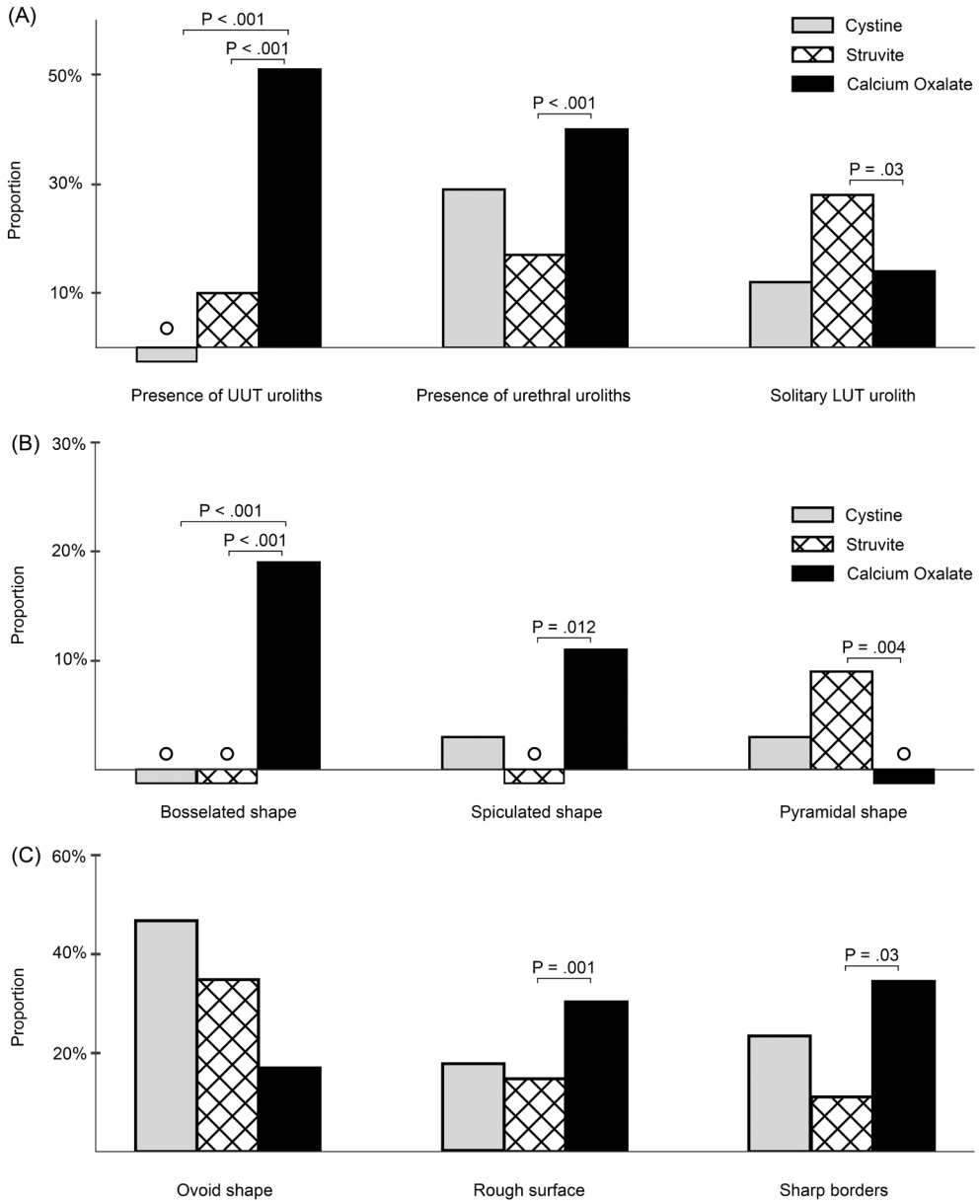

FIGURE 2 | Proportions of relevant radiographic features depending on the mineral compositions in 202 dogs with lower urinary tract uroliths. Significant differences between groups are indicated with brackets. White circles indicate that no dog showed the studied feature. UUT: Upper urinary tract; LUT: Lower urinary tract.

1.34–5.21; $p = 0.004$) and cystine uroliths (3%, 1/35; OR = 37.27; 95% CI: 4.93–282.02; $p < 0.001$). Of the five radiolucent uroliths, four were composed of struvite, representing 7% (4/58) of this UMC. This was significantly more frequent than in calcium oxalate, in which none were described ($p = 0.014$). One (3%) cystine urolith was completely radiolucent. The UOR measurement showed excellent intra-observer repeatability and good inter-observer reliability, with ICC values of 0.95 and 0.90, respectively (95% CI: 0.92–0.98 and 0.83–0.95). Similarly, cystine uroliths had a median UOR of 0.71 (IQR, 0.63–0.80), which was significantly lower than the median UOR of struvite uroliths (median, 0.85; IQR, 0.71–0.96; $p < 0.001$). The latter was significantly lower than the median UOR of calcium oxalate uroliths (median, 0.94; IQR, 0.82–1.02; $p = 0.001$). The differences in uroliths' quantitative opacity are illustrated in Figure 1 and Figure 3B. Analysis of covariance revealed a significant effect of mineral nature ($p < 0.001$) and urolith size ($p < 0.001$) on UOR. After adjusting for urolith size, pairwise comparisons showed that calcium oxalate uroliths had higher UOR than both struvite ($p < 0.001$) and cystine ($p < 0.001$). Struvite uroliths also had significantly higher UOR than cystine uroliths ($p < 0.001$). Through ROC curve analysis, UOR was a good discriminator of cystine uroliths compared to struvite and calcium oxalate uroliths (AUC = 0.81, $p < 0.001$, 95% CI: 0.74–0.89) with an optimal cut-off value of UOR ≤ 0.83 (specificity: 67%; sensitivity: 84%). This value was associated with a negative likelihood ratio of 4.3 (95% CI: 1.9–9.6). The UOR was only a fair discriminator of calcium oxalate uroliths compared to struvite and cystine uroliths (AUC = 0.73, $p < 0.001$, 95% CI: 0.66–0.80) and therefore no optimal cut-off value was determined.

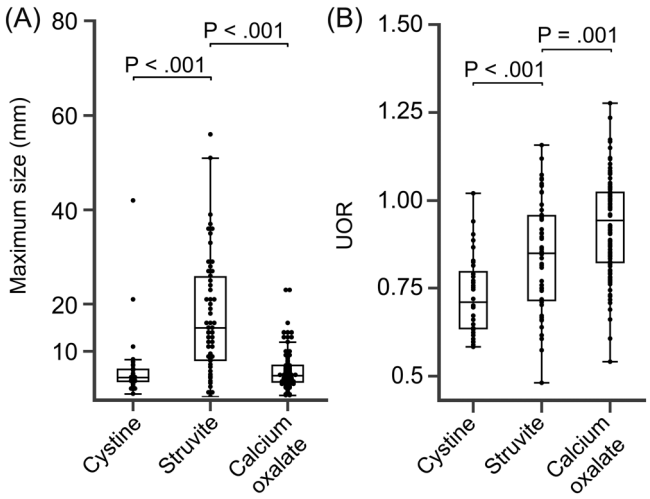

FIGURE 3 | Box and whisker plots of (A) the maximum size of the lower urinary tract urolith and (B) the ratio of the mean pixel value (MPV) of the largest cystolith to the L5 MPV, labeled UOR, measured on radiographs of dogs compared by mineral type. The dots represent values for each individual dog. Medians are shown as horizontal lines. The boxes represent the interquartile range (25th–75th percentiles) and whiskers represent 1.5 times the interquartile range. Significant differences among mineral compositions are indicated by brackets and reflect unadjusted pairwise comparisons. When adjusted for urolith size using analysis of the covariance, the UOR difference remained statistically different between calcium oxalate and struvite uroliths ($p < 0.001$) and between struvite and cystine uroliths ($p < 0.001$).

4 | Discussion

This retrospective study provides a detailed in vivo analysis of the radiographic characteristics of calcium oxalate, struvite, and cystine LUT uroliths in dogs, confirming and extending previous macroscopic and ex vivo findings on uroliths with pure UMC [21, 22]. Significant radiographic differences among UMC included opacity, shape, and size, with specific thresholds established for urolith size and the ratio of urolith-to-L5 vertebra mean pixel value (UOR). Some shapes, such as bosselated and cylindrical, were uniquely associated with calcium oxalate uroliths. These radiographic findings, together with epidemiological data, biochemical analysis, urinalysis, and culture, are valuable for improving the non-invasive diagnosis of canine LUT uroliths and guiding targeted therapeutic strategies.

Calcium oxalate uroliths were the most common mineral nature in our study cohort and presented singular radiographic features, particularly when compared to struvite uroliths. Their distribution along the urinary tract, particularly the presence of radiopaque UUT uroliths, was significantly associated with calcium oxalate uroliths. Although not described in dogs, this process, as reported in humans and cats, likely relates to the formation of calcium-containing uroliths on interstitial calcium plaques (Randall's plaques), which lead to nephroliths [37, 38]. Urethroliths were also significantly more frequent in dogs with calcium oxalate uroliths compared to dogs with struvite uroliths. This finding should be interpreted cautiously, as their smaller size and the lack of standardized urethral catheterization might have influenced this variable. As in macroscopic studies [21], certain radiographic morphological features, such as a bosselated or spiculated shape, were suggestive of calcium oxalate uroliths, confirming that the urolith composition is a strong determinant in its shape. The wide variety of urolith morphologies is influenced by several factors such as location, crystal growth rate, urine characteristics, or nidus shape [29]. Ovoid and faceted shapes were the most common, regardless of chemical composition. This occurs because crystals grow outward in all directions at similar rates, forming spheres that might be imperfect and develop into faceted shapes [23]. The nidus is also known to influence the shape of uroliths, with cylindrical uroliths showing outward growth around a surgical suture nidus [39]. In this study, all four dogs with cylindrical uroliths had calcium oxalate uroliths, and three had a history of cystotomy performed between 370 and 730 days before radiographs. The fourth dog had no recorded history of cystotomy but was adopted at 7 years of age. These findings are consistent with reports linking cylindrical calcium oxalate cystoliths to suture-associated nidus formation after cystotomy [40].

Struvite uroliths predominantly exhibited a faceted shape in 48% of cases, consistent with macroscopic reports [21]. However, this shape was also common in other urolith types, with no statistically significant difference noted. A pyramidal shape, though occasionally described, was significantly associated with struvite compared to calcium oxalate, where no pyramidal shapes were observed. This finding aligns with macroscopic and ex vivo studies [21, 23]. These pyramidal struvite uroliths were notably large, ranging from 14 to 25 mm, and were often found as multiple cystoliths. In fast-growing minerals such as struvite, multiple large uroliths are commonly observed, constraining urolith growth at points of mutual contact, while chemicals precipitate in the open spaces [17, 41]. This rapid growth of struvites might also explain their large size and occurrence as solitary cystoliths. The latter feature had not been previously reported to the authors' knowledge. Struvite uroliths should be dissolved rather than surgically removed, except in cases of urinary tract obstruction. Therefore, predicting the mineral nature of struvite is clinically valuable, as it ensures that the use of a calculolytic diet is appropriate and that unnecessary invasive procedures are avoided.

This study identifies an 11 mm cut-off value for predicting struvite UMC, with a specificity of 91% and a sensitivity of 67%. This finding aligns with macroscopic results from a previous study, where a cut-off value of 10 mm had a 93% likelihood of identifying struvite [21]. This result might be explained by their association with urease-positive bacteria, whose metabolism induces supersaturation of magnesium ammonium phosphate and facilitates rapid crystal aggregation and urolith growth [29]. Among struvite uroliths, this study reports a prevalence of bacteriuria in 67%, higher than a recent report of 42% [4]. However, the latter was based on urolith culture, which is known to lack sensitivity, as more than half of the urolith samples with a positive urine culture result do not yield bacterial growth [42].

The radiopacity of struvite uroliths was significantly lower than that of calcium oxalate and higher than that of cystine uroliths, but no clinically useful threshold could be identified to discriminate this UMC on the basis of UOR. Interestingly, four struvite uroliths were radiolucent and included uroliths measuring macroscopically 0.5, 2, 3, and 5 mm, with a range of 1 to > 10 uroliths per animal submitted to the laboratory. This highlights

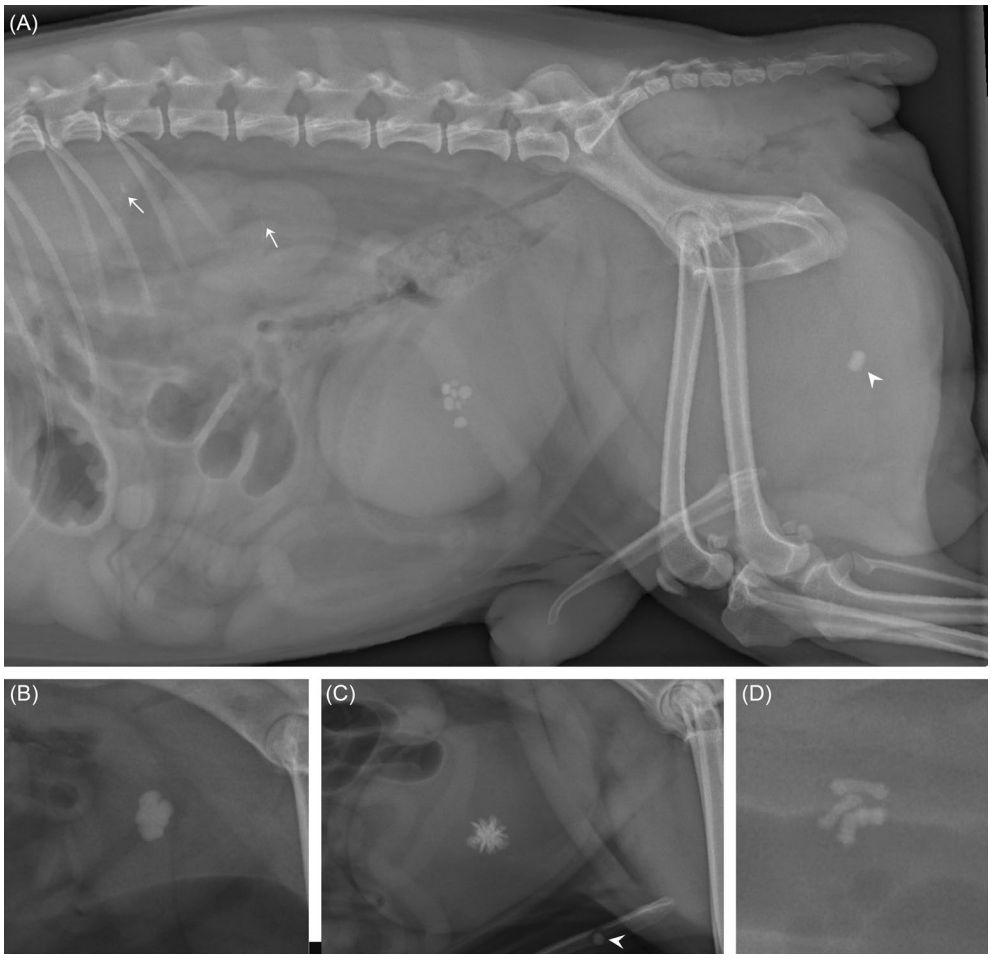

FIGURE 4 | Representative radiographic features of calcium oxalate uroliths in dogs. (A) Several cystoliths associated with irregularly shaped uroliths within both kidneys (arrows) and urethra (arrowhead). (B) Calcium oxalate bosselated cystolith. (C) Calcium oxalate spiculated cystolith presenting sharp borders and a rough surface. Note the rounded urethrolith (arrowhead). (D) Cylindrical cystoliths in a dog with a history of cystotomy 370 days prior to radiograph.

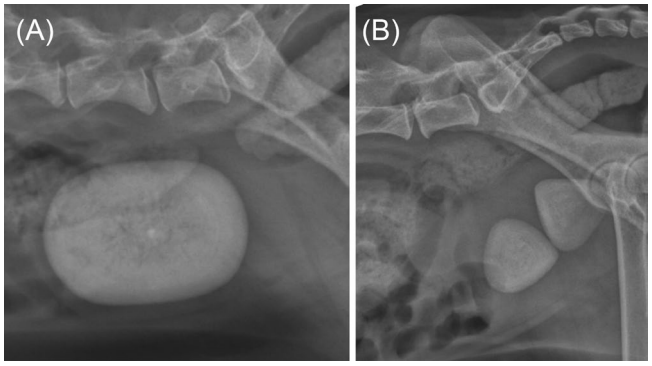

FIGURE 5 | Representative radiographic features of struvite uroliths in dogs. (A) Solitary ovoid struvite cystolith measuring 3.6 cm, with a smooth surface and rounded borders. (B) Pyramidal struvite cystoliths presenting a maximal size of 2 cm.

that struvite uroliths > 1 mm might still be missed on abdominal radiographs in vivo, in contrast to a recent ex vivo study [43], and highlights the need to study uroliths in vivo rather than with ex vivo phantom bladders. However, the detection rate of struvites (93%) was also inferior to that of calcium oxalate uroliths and similar to that found in this study (94%).

The proportion of cystine uroliths identified in this study is higher than previously reported [4, 44], which might be attributed to the tertiary nature of our referral hospital and the regional popularity of breeds such as the American Staffordshire terrier. Although historically considered radiolucent or marginally radiopaque, cystine uroliths were radiopaque in 97% of cases in our study population. This finding corroborates two recent studies that reported radiographically visible cystine uroliths in 92% and 97% of cases in vivo and ex vivo, respectively [26, 43], and in our study the only radiolucent urolith macroscopically measured 1 mm. Shape was not a distinguishing criterion for cystine uroliths, as common shapes such as faceted and ovoid accounted for 88% of cases for this mineral type. Radiopacity was a key feature for identifying cystine uroliths, with 43% classified as mildly radiopaque. To enhance the differentiation of uroliths based on radiopacity, we quantified this feature by evaluating their MPV as adopted from human literature [31]. Due to the lack of standardization in pixel value intensity scales for digital radiography [45] and to minimize technique-related biases, a ratio of the MPV of the urolith and L5 vertebra was proposed. A cut-off value of UOR ≤ 0.83 enabled the identification of cystine uroliths with a specificity of 67% and a sensitivity of 84%, indicating that uroliths with higher opacity are unlikely to be cystine. However, this threshold resulted in a notable number

of false positives. Although intra- and inter-observer reliability was good to excellent for UOR measurement, it is also likely to be influenced by patient body condition and the degree of bone mineralization.

Limitations of this study are inherent to its retrospective design. When the radiographs were acquired, no standardized diagnostic or medical protocols were in place, meaning prevention or dissolution diets might have already been implemented by the referring vet. This might have contributed to both an underestimation of the size and radiopacity of uroliths, as well as the under-detection of some uroliths on radiographs. Although no antimicrobial treatment was ongoing at the time of urine collection, previous antibiotic therapy implemented by the referring veterinarian was not recorded, which might have led to an underestimation of bacteriuria. Previous urethral catheterization might have also influenced the position of urethroliths. Limiting the study to cases requiring UMC analysis and invasive removal might have introduced selection bias, under-representing struvite uroliths, which are typically managed medically. The inclusion of non-pure uroliths could have affected the interpretation of their morphology, particularly when the outward appearance masked the central part of the urolith. However, this likely had minimal influence on our data, as the median proportion of the urolith's primary component was 97%. Furthermore, the small number of cystine uroliths could have limited the statistical power of the analysis. Other UMC, such as urate or silica, were excluded from the study due to their relatively low prevalence and insufficient sample sizes for meaningful statistical analysis. The reviewed radiographs were acquired on different digital systems over an extended period of time, with no standardization of exposure factors, object-to-image-detector distance, or source-to-image distance, which could have introduced variability in measured urolith size and opacity. Some radiographic characteristics, such as surface and border features, might be associated with urolith size and are harder to evaluate in smaller uroliths. This study aimed to identify a combination of distinctive radiographic criteria to predict UMC and guide therapeutic strategies, like medical dissolution. However, a significant overlap of these features remains, particularly in moderately radiopaque uroliths of millimetric size, highlighting the need to rely on additional non-radiographic criteria in such cases. The evaluation of epidemiological, clinical, and other para-clinical characteristics among urolith types was beyond the scope of this study, as these aspects have been extensively studied in larger populations [3, 4].

Acknowledgments

The authors acknowledge Aurélie Bogey for spectrophotometric analysis and Loïc Desquilbet for his assistance with statistical analysis.

Disclosure

Authors declare no off-label use of antimicrobials.

Ethics Statement

Authors declare no institutional animal care and use committee or other approval was needed. Authors declare human ethics approval was not needed.

Conflicts of Interest

The authors declare no conflicts of interest.

References

1. A. Blavier, A. Sulter, A. Bogey, K. Novelli, and B. Billiemaz, "Résultats des analyses par spectrométrie infrarouge de 1131 calculs urinaires canins prélevés de 2007 à 2010, en France," *Pratique Médicale et Chirurgicale De L'animal De Compagnie* 47, no. 1 (2012): 7–16.

2. K. Roe, A. Pratt, J. Lulich, C. Osborne, and H. M. Syme, "Analysis of 14,008 Uroliths From Dogs in the UK Over a 10-Year Period," *Journal of Small Animal Practice* 53, no. 11 (2012): 634–640.

3. C. A. Osborne, J. P. Lulich, J. M. Kruger, L. K. Ulrich, and L. A. Koehler, "Analysis of 451,891 Canine Uroliths, Feline Uroliths, and Feline Urethral Plugs From 1981 to 2007: Perspectives From the Minnesota Urolith Center," *Veterinary Clinics of North America: Small Animal Practice* 39, no. 1 (2009): 183–197.

4. L. Kopecny, C. A. Palm, G. Segev, and J. L. Westropp, "Urolithiasis in Dogs: Evaluation of Trends in Urolith Composition and Risk Factors (2006-2018)," *Journal of Veterinary Internal Medicine* 35, no. 3 (2021): 1406–1415.

5. J. P. Lulich, A. C. Berent, L. G. Adams, J. L. Westropp, J. W. Bartges, and C. A. Osborne, "ACVIM Small Animal Consensus Recommendations on the Treatment and Prevention of Uroliths in Dogs and Cats," *Journal of Veterinary Internal Medicine* 30, no. 5 (2016): 1564–1574.

6. Y. Queau, "Nutritional Management of Urolithiasis," *Veterinary Clinics of North America. Small Animal Practice* 49, no. 2 (2019): 175–186.

7. A. M. Wingert, O. A. Murray, J. P. Lulich, A. M. Hoelmer, L. K. Merkel, and E. Furrow, "Efficacy of Medical Dissolution for Suspected Struvite Cystoliths in Dogs," *Journal of Veterinary Internal Medicine* 35, no. 5 (2021): 2287–2295.

8. A. Cléroux, "Minimally Invasive Management of Uroliths in Cats and Dogs," *Veterinary Clinics of North America: Small Animal Practice* 48, no. 5 (2018): 875–889.

9. C. Job, J. Lecavalier, M. Dunn, et al., "Comparison of Percutaneous Cystolithotomy and Open Cystotomy for Removal of Urethral and Bladder Uroliths in Dogs: Retrospective Study of 81 Cases (2014-2018)," *Journal of Veterinary Internal Medicine* 36, no. 6 (2022): 2063–2070.

10. R. S. Hess, P. H. Kass, and C. R. Ward, "Association Between Hyperadrenocorticism and Development of Calcium-Containing Uroliths in Dogs With Urolithiasis," *Journal of the American Veterinary Medical Association* 212, no. 12 (1998): 1889–1891.

11. G. V. Ling, C. E. Franti, D. L. Johnson, and A. L. Ruby, "Urolithiasis in Dogs. III: Prevalence of Urinary Tract Infection and Interrelations of Infection, Age, Sex, and Mineral Composition," *American Journal of Veterinary Research* 59, no. 5 (1998): 643–649.

12. S. M. Kennedy, J. P. Lulich, M. G. Ritt, and E. Furrow, "Comparison of Body Condition Score and Urinalysis Variables Between Dogs With and Without Calcium Oxalate Uroliths," *Journal of the American Veterinary Medical Association* 249, no. 11 (2016): 1274–1280.

13. G. V. Ling, C. E. Franti, D. L. Johnson, and A. L. Ruby, "Urolithiasis in Dogs. IV: Survey of Interrelations Among Breed, Mineral Composition, and Anatomic Location of Calculi, and Presence of Urinary Tract Infection," *American Journal of Veterinary Research* 59, no. 5 (1998): 650–660.

14. I. To, A. C. Berent, C. W. Weisse, et al., "Preoperative Parameters (Signalment, Digital Radiography, Urinalysis, Urine Microbiological Culture) and Novel Algorithm Improve Prediction of Canine Urocystolith Composition," *Journal of the American Veterinary Medical Association* 262, no. 8 (2024): 1039–1046.

15. V. Hunprasit, P. J. Schreiner, J. B. Bender, and J. P. Lulich, "Epidemiologic Evaluation of Calcium Oxalate Urolithiasis in Dogs in the United States: 2010-2015," *Journal of Veterinary Internal Medicine* 33, no. 5 (2019): 2090–2095.

16. C. C. Okafor, D. L. Pearl, S. L. Lefebvre, et al., "Risk Factors Associated With Struvite Urolithiasis in Dogs Evaluated at General Care Veterinary Hospitals in the United States," *Journal of the American Veterinary Medical Association* 243, no. 12 (2013): 1737–1745.

17. J. P. Lulich and C. A. Osborne, "Changing Paradigms in the Diagnosis of Urolithiasis," *Veterinary Clinics of North America: Small Animal Practice* 39, no. 1 (2009): 79–91.

18. D. A. Feeney, R. C. Weichselbaum, C. R. Jessen, and C. A. Osborne, "Imaging Canine Urocystoliths," *Veterinary Clinics of North America: Small Animal Practice* 29, no. 1 (1999): 59–72.

19. A. Bruwier, B. Godart, L. Gatel, D. Leperlier, and A. S. Bedu, "Computed Tomographic Assessment of Retrograde Urohydropropulsion in Male Dogs and Prediction of Stone Composition Using Hounsfield Unit in Dogs and Cats," *Journal of Veterinary Science* 23, no. 5 (2022): e65.

20. B. M. Pressler, L. A. Mohammadian, E. Li, et al., "In Vitro Prediction of Canine Urolith Mineral Composition Using Computed Tomographic Mean Beam Attenuation Measurements," *Veterinary Radiology & Ultrasound* 45, no. 3 (2004): 189–197.

21. R. C. Weichselbaum, D. A. Feeney, C. R. Jessen, C. A. Osborne, L. Koehler, and L. Ulrich, "Evaluation of the Morphologic Characteristics and Prevalence of Canine Urocystoliths From a Regional Urolith Center," *American Journal of Veterinary Research* 59, no. 4 (1998): 379–387.

22. R. C. Weichselbaum, D. A. Feeney, C. R. Jessen, C. A. Osborne, and J. Holte, "An Integrated Epidemiologic and Radiographic Algorithm for Canine Urocystolith Mineral Type Prediction," *Veterinary Radiology & Ultrasound* 42, no. 4 (2001): 311–319.

23. R. C. Weichselbaum, D. A. Feeney, C. R. Jessen, C. A. Osborne, V. Dreytser, and J. Holte, "Loss of Urocystolith Architectural Clarity During in Vivo Radiographic Simulation Versus in Vitro Visualization," *Veterinary Radiology & Ultrasound* 41, no. 3 (2000): 241–246.

24. G. R. Johnston, P. A. Walter, and D. A. Feeney, "Radiographic and Ultrasonographic Features of Uroliths and Other Urinary Tract Filling Defects," *Veterinary Clinics of North America: Small Animal Practice* 16, no. 2 (1986): 261–292.

25. D. A. Feeney and K. L. Anderson, "Radiographic Imaging in Urinary Tract Disease," in *Nephrology and Urology of Small Animals [Internet]*, 1st ed., ed. J. Bartges and D. J. Polzin (Wiley, 2011), 97–127, https://doi.org/10.1002/9781118785546.ch15.

26. C. Andrews, R. Williams, A. Arjoonsingh, and F. R. Vilaplana Grosso, "Cystine and Urate Cystoliths in Dogs Are Frequently Visible on Radiographs Prior to Surgical or Nonsurgical Removal," *Journal of the American Veterinary Medical Association* 262, no. 10 (2024): 1338–1342.

27. L. A. Faria, A. É. W. B. Meirelles, T. R. Froes, et al., "Comparison of Radiographic Methods for Detecting Radiolucent Uroliths in Dogs," *PLoS One* 17, no. 9 (2022): e0274087.

28. W. W. Low, J. M. Uhl, P. H. Kass, A. L. Ruby, and J. L. Westropp, "Evaluation of Trends in Urolith Composition and Characteristics of Dogs With Urolithiasis: 25,499 Cases (1985–2006)," *Journal of the American Veterinary Medical Association* 236, no. 2 (2010): 193–200.

29. A. Razi, A. Ghiaei, F. K. Dolatabadi, et al., "Unraveling the Association of Bacteria and Urinary Stones in Patients With Urolithiasis: An Update Review Article," *Frontiers in Medicine* 11 (2024): 1401808.

30. A. B. Cannon, J. L. Westropp, A. L. Ruby, and P. H. Kass, "Evaluation of Trends in Urolith Composition in Cats: 5,230 Cases (1985–2004)," *Journal of the American Veterinary Medical Association* 231, no. 4 (2007): 570–576.

31. T. Saiki and E. Yumoto, "Quantification of X-Ray Opacity of the Maxillary Sinus in the Waters' View," *Auris, Nasus, Larynx* 24, no. 3 (1997): 289–297.

32. T. K. Koo and M. Y. Li, "A Guideline of Selecting and Reporting Intraclass Correlation Coefficients for Reliability Research," *Journal of Chiropractic Medicine* 15, no. 2 (2016): 155–163.

33. D. V. Cicchetti, "Guidelines, Criteria, and Rules of Thumb for Evaluating Normed and Standardized Assessment Instruments in Psychology," *Psychological Assessment* 6, no. 4 (1994): 284–290.

34. R. Bender and S. Lange, "Adjusting for Multiple Testing—When and How?," *Journal of Clinical Epidemiology* 54, no. 4 (2001): 343–349.

35. F. S. Nahm, "Receiver Operating Characteristic Curve: Overview and Practical Use for Clinicians," *Korean Journal of Anesthesiology* 75, no. 1 (2022): 25–36.

36. BiostaTGV Pierre Louis Institute of Epidemiology and Public Health UMR S 1136, https://biostatgv.sentiweb.fr.

37. F. Tamborino, R. Cicchetti, M. Mascitti, et al., "Pathophysiology and Main Molecular Mechanisms of Urinary Stone Formation and Recurrence," *International Journal of Molecular Sciences* 25, no. 5 (2024): 3075.

38. A. Alford, E. Furrow, M. Borofsky, and J. Lulich, "Animal Models of Naturally Occurring Stone Disease," *Nature Reviews. Urology* 17, no. 12 (2020): 691–705.

39. S. L. Appel, S. L. Lefebvre, D. M. Houston, et al., "Evaluation of Risk Factors Associated With Suture-Nidus Cystoliths in Dogs and Cats: 176 Cases (1999–2006)," *Journal of the American Veterinary Medical Association* 233, no. 12 (2008): 1889–1895.

40. J. M. Hickey, A. C. Berent, A. J. Fischetti, and A. B. Le Roux, "Radiographic Features of Suspected Suture-Associated Cystic Calculi in Dogs," *Veterinary Radiology & Ultrasound* 61, no. 4 (2020): 394–398.

41. B. Finlayson, "Physicochemical Aspects of Urolithiasis," *Kidney International* 13, no. 5 (1978): 344–360.

42. L. A. Perry, P. H. Kass, D. L. Johnson, A. L. Ruby, R. Shiraki, and J. L. Westropp, "Evaluation of Culture Techniques and Bacterial Cultures From Uroliths," *Journal of Veterinary Diagnostic Investigation* 25, no. 2 (2013): 199–202.

43. P. DeBow, M. Auger, C. Fazio, et al., "The Most Common Types of Uroliths Larger Than 1 Mm Are Readily Visible and Accurately Measured in an in Vitro Setting Mimicking the Canine Abdomen Using Digital Radiography," *Veterinary Radiology & Ultrasound* 64, no. 5 (2023): 806–812.

44. E. M. Stavroulaki, C. Ortega, A. Lawlor, J. Lulich, and B. Cuq, "Trends in Urolith Composition and Factors Associated With Different Urolith Types in Dogs From the Republic of Ireland and Northern Ireland Between 2010 and 2020," *Journal of Small Animal Practice* 65, no. 1 (2024): 30–38.

45. J. K. Choi, G. J. Kim, D. H. Hong, et al., "Study on the Standardization of Signal Intensity Scale of Pixel Value in Digital Radiography," *Indian Journal of Science and Technology* 9, no. S1 (2016): 1–5.