Journal of Veterinary Internal Medicine

Journal of Veterinary Internal Medicine
Open Access
ACVIM
American College of Veterinary Internal Medicine

STANDARD ARTICLE OPEN ACCESS

Equine Cardiology

Multiple Catheter Recording in Horses to Investigate Atrial Depolarization Pattern During Sinus Rhythm and Induced Premature Atrial Complexes

Eva Buschmann[1] | Glenn Van Steenkiste[1] | Ingrid Vernemmen[1] | Marie Demeyere[1] | Stijn Schauvliege[2] | Annelies Decloedt[1] | Gunther van Loon[1]

[1]Equine Cardioteam Ghent, Department of Internal Medicine, Reproduction and Population Medicine, Faculty of Veterinary Medicine, Ghent University, Merelbeke, Belgium | [2]Department of Large Animal Surgery, Anaesthesia and Orthopaedics, Faculty of Veterinary Medicine, Ghent University, Merelbeke, Belgium

Correspondence: Eva Buschmann (eva.buschmann@ugent.be)

Received: 28 May 2025 | **Revised:** 4 August 2025 | **Accepted:** 14 August 2025

Funding: This work was supported by Bijzonder Onderzoeksfonds UGent, 01B05818; Fonds Wetenschappelijk Onderzoek, 1S71521N, 1SA2223N, 1SE9122N.

Keywords: ablation | arrhythmias | electrocardiography | electrophysiology | equine cardiology | mapping

ABSTRACT

Background: Detailed characterization of arrhythmias can be performed by multiple catheter mapping; but this has not yet been explored in horses.

Objectives: Perform ultrasound-guided multiple catheter mapping of the right heart during sinus rhythm and right and left atrial pacing to identify activation patterns characteristic of the origin of ectopy. Obtain His signals and effective refractory periods (ERP).

Animals: Eight healthy adult horses.

Methods: Experimental study. Recording catheters were placed at the terminal crest, intervenous tubercle, caudal vena cava, and coronary sinus. Right atrial pacing was performed in standing, sedated horses from each catheter and from the cranial vena cava, right atrial appendage, and right atrial free wall. Left atrial pacing was performed during general anesthesia at the four pulmonary vein ostia, left atrial appendage, and interatrial septum. Atrial activation patterns were recorded from the catheters during sinus rhythm and during pacing at the different sites. During sinus rhythm, the His bundle was recorded, and ERP at different sites was determined.

Results: Characteristic activation maps during sinus rhythm and pacing were identified. Late coronary sinus activation indicated ectopy originating from the right atrium or ostium III. The direction of coronary sinus electrode activation aided in differentiating left atrial ectopy locations. His signals were recorded in 5/8 horses. Atrial ERP varied between 170 and 420 ms with inter-horse and intra-horse variation.

Conclusions and Clinical Importance: Performing an electrophysiological study in horses, including multiple catheter recording, was feasible. Pacing-induced ectopy resulted in characteristic activation patterns, which might aid in identifying the site of atrial ectopy.

Abbreviations: 3D EAM, three-dimensional electro-anatomical mapping; AF, atrial fibrillation; AV, atrioventricular; Bpm, beats per minute; CaVC, caudal vena cava; CrVC, cranial vena cava; CS, coronary sinus; cTnI, cardiac troponin I; ECG, electrocardiogram; ERP, effective refractory period; IAS, interatrial septum; IVT, intervenous tubercle; LA, left atrium; LAA, left atrial appendage; LBB, left bundle branch; PAC, premature atrial complexes; RA, right atrium; RAA, right atrial appendage; RAFW, right atrial free wall; RBB, right bundle branch; TC, terminal crest; VCG, vectorcardiogram.

This is an open access article under the terms of the Creative Commons Attribution-NonCommercial-NoDerivs License, which permits use and distribution in any medium, provided the original work is properly cited, the use is non-commercial and no modifications or adaptations are made.

© 2025 The Author(s). *Journal of Veterinary Internal Medicine* published by Wiley Periodicals LLC on behalf of American College of Veterinary Internal Medicine.

1 | Introduction

Atrial arrhythmias are common in horses and can impair performance as well as horse and rider safety. Catheter ablation has been successfully used to treat frequent premature atrial complexes (PAC), atrial tachycardia [1–3] and an accessory pathway [4] in horses. In order to treat the arrhythmia by ablation, the mechanism and anatomical origin need to be elucidated. Configurations for a 12-lead electrocardiogram (ECG) are described for horses [5, 6] and the derived vectorcardiogram (VCG) is useful to differentiate right from left atrial ectopy, but prediction of the origin within the atrium was limited to a large area [7].

More detailed information can be obtained through electrophysiological studies. Because of the large chest cavity of horses, standard imaging techniques such as CT, MRI or fluoroscopy are not applicable or provide too little anatomical detail [8]. Therefore, echocardiography remains the main imaging modality to visualize and guide catheters, making advanced electrophysiological studies challenging [9]. Recently, three-dimensional electroanatomical mapping (3D EAM) has been successfully applied in horses. This system acquires the 3D anatomy of the heart, the electrical activation pattern and provides the real-time catheter location [10–12]. It has been successfully applied to identify the origin and mechanism of supraventricular arrhythmias in horses [1, 2, 4]. Although being a promising technique, 3D EAM requires general anesthesia, expensive equipment and expertise.

In humans and dogs, activation mapping using four recording catheters is described as a standard procedure to characterize supraventricular arrhythmias. Catheters are typically placed at the high right atrium (RA), coronary sinus (CS), His bundle, and right ventricular apex. The electrical signals from those four catheters are recorded simultaneously, allowing comparison of the activation timings and correlation to the surface ECG. This allows to determine the origin and propagation pattern of the arrhythmia [9, 13]. This technique can be a cost-effective alternative for 3D EAM to characterize supraventricular arrhythmias in horses. In addition, it can facilitate the ablation procedure by identifying the anatomical area of origin in the standing horse, allowing a targeted approach for detailed 3D mapping under general anesthesia, thereby shortening anesthesia time. Transthoracic ultrasound guidance to place multiple intracardiac catheters is technically feasible in horses, which was a part of this study [14].

The first aim of our study was to perform multiple catheter recording during right and left atrial pacing, in order to identify specific activation patterns characteristic for the origin of ectopy. The second aim was to obtain baseline values, including His bundle recordings and effective refractory periods (ERP) at different intra-atrial locations.

2 | Materials and Methods

This study was part of a larger study, including follow-up of transseptal puncture [15], evaluating the feasibility of transthoracic ultrasound guidance of intracardiac catheters [14] and exploring the use of 12-lead ECG and VCG. Eight horses, consisting of 5 mares and 3 geldings, including 4 warmbloods, 2 warmblood crossbreeds, and 2 standardbreds with a mean age of 16 ± 8 years and mean body weight of 510 ± 40 kg, were used. Echocardiography was performed, and only mild valvular regurgitations were found. A 24-h ECG showed normal sinus rhythm in all horses.

2.1 | Right Atrium

Acepromazine was administered 30 min before the start of the procedure and after 4 h (0.03 mg/kg IM, Tranquinervin 10 mg/mL, Dechra, Herentals, Belgium). After administration of detomidine (10 μg/kg IV, Domidine 10 mg/mL, Dechra, Herentals, Belgium) and methadone (0.1 μg/kg IV, Comfortan 10 mg/mL, Dechra, Herentals, Belgium), sedation was maintained by a continuous rate infusion of 10 μg/kg/h detomidine (Domidine 10 mg/mL, Dechra, Herentals, Belgium).

In the right jugular vein, a decapolar catheter (Webster CS Catheter, Biosense Webster, Diegem, Belgium) was placed through a fixed curve sheath (HeartSpan, Merit Medical, Etterbeek, Belgium) into the CS and advanced into the great cardiac vein to measure left atrial (LA) signals [2, 14]. In the left jugular vein, an 8.5 Fr bi-directional deflectable guiding sheath (Senovo Bi-Flex, Biotronik, Vilvoorde, Belgium) was introduced, through which a 7 Fr loop electrophysiology catheter (Inquiry Optima, Abbott, Zaventem, Belgium) was inserted to map the RA using the EnSite Precision Cardiac Mapping system (Abbott, Zaventem, Belgium). Electrodes to create the impedance field were placed as previously described [1]. A 12-lead ECG was recorded throughout the procedure (Labsystem Pro v2.6, Boston Scientific, Diegem, Belgium) [6].

After completion of the 3D EAM of the RA, the loop catheter was exchanged for a decapolar catheter to obtain His bundle recordings in the RA. The right bundle branch (RBB) was recorded at the moderator band in the right ventricle.

Additional sheaths for insertion of the decapolar recording catheters were placed in the left jugular vein. A fixed curve sheath was introduced for catheter placement at the medially located myocardial sleeves of the caudal vena cava (CaVC), caudal to the oval fossa, at the site of the most caudally obtainable electrogram [16]. Two 9 Fr introducer sheaths (IntroFlex, Edward Lifesciences, Dilbeek, Belgium) were inserted for introduction of two decapolar catheters placed at the cranial side of the intervenous tubercle (IVT), with the tip curved against and pointing toward the base of the tubercle and at the terminal crest (TC), with the tip curved around the TC. The normal atrial activation pattern was investigated by simultaneously recording the electrograms from the catheters at the TC, IVT, CaVC, and CS. After recording in sinus rhythm, PACs were induced by pacing at each decapolar catheter at electrode 1–2 with a current of 15 mA and pulse width of 2 ms at a rate of 45 beats per minute (bpm) and 120 bpm. Pacing was performed for 10–20 beats. Care was taken that P′ waves were not buried in a QRS complex or T wave, and if necessary, additional pacing was performed. Subsequently, a 5th catheter was introduced through the 8.5 Fr bi-directional deflectable guiding sheath to pace at the right atrial free wall (RAFW),

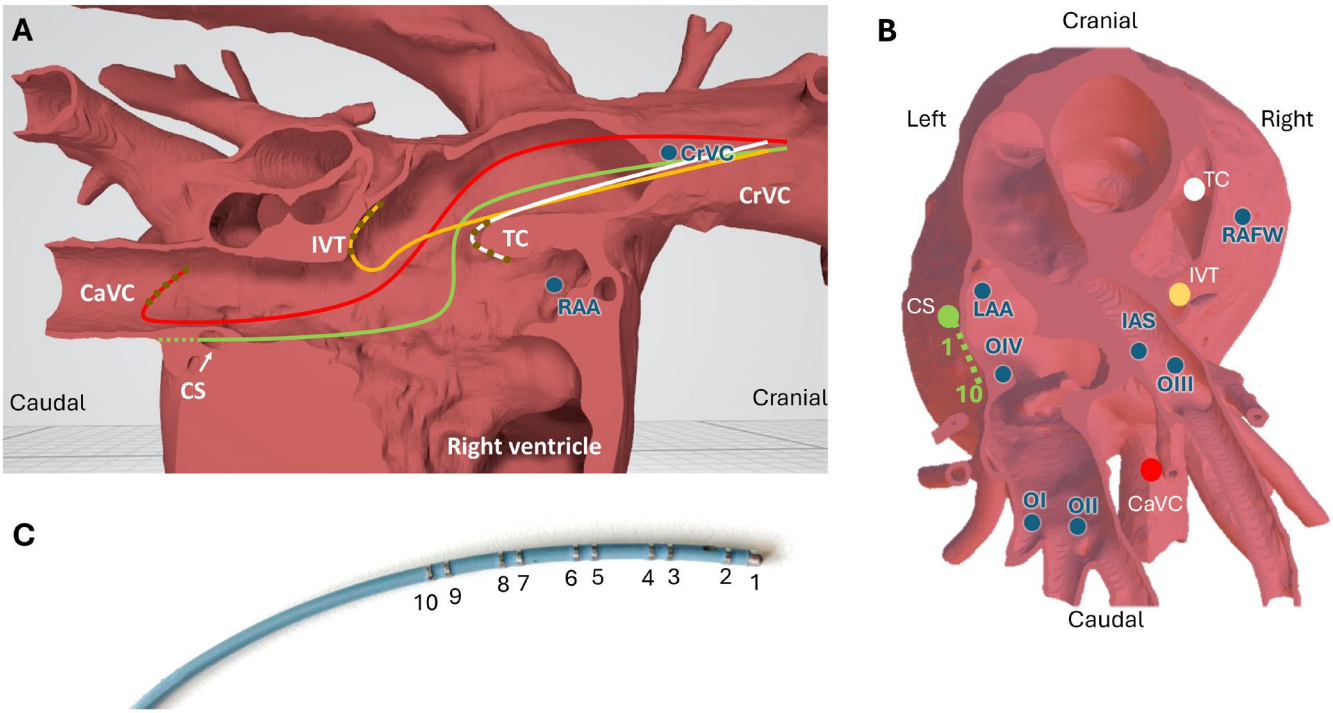

FIGURE 1 | (A) Right lateral view on the opened right atrium and caudal vena cava, showing the positions of the recording catheters at the terminal crest (TC, white), intervenous tubercle (IVT, yellow), caudal vena cava (CaVC, red) and in the coronary sinus (CS, green). The tip of the CS catheter was inserted into the vena cordis magna to record left atrial signals. Additional pacing was performed at the right atrial appendage (RAA) and cranial vena cava (CrVC) in order to induce premature atrial complexes from that area. (B) Dorsal view on the heart, top is cranial. Recording catheters are shown by the dots: white is TC, yellow is IVT, red is CaVC and green is CS. Electrodes of the CS are shown with 1 being the distal (tip) electrode and 10 the proximal one. Additional pacing sites were the right atrial free wall (RAFW), ostium I (OI), ostium II (OII), ostium III (OIII), ostium IV (OIV), left atrial appendage (LAA) and the interatrial septum (just dorsal to the septal mitral valve leaflet; IAS). (C) Example of a decapolar deflectable catheter as used in our study. Electrode distance between paired electrodes is 2 mm while spacing between electrode pairs is 8 mm. Electrode 1 is the distal electrode, while electrode 10 is the proximal one.

the right atrial appendage (RAA) and the cranial vena cava (CrVC). Figure 1 shows positions of the recording catheters and pacing locations in the RA. Catheters were placed using transthoracic echocardiographic guidance as described by Vernemmen et al. [14] and a correct location was confirmed by the 3D EAM.

Atrial ERPs were measured at the TC, IVT, CaVC, and CS. In the first three horses, ERP was measured by pacing a drive cycle of eight beats at a fixed coupling interval of 600 ms (S1–S1), followed by an extrastimulus, starting with a coupling interval above the expected ERP (S1–S2). Subsequently, S1–S2 was decreased by 10 ms until S2 failed to capture the atrial myocardium. Since short episodes of atrial fibrillation (AF) were induced using this protocol, in the next five horses, S1–S2 was started with a coupling interval below the expected ERP and increased by 10 ms until the extrastimulus captured the myocardium [17]. The ERP is defined as the longest coupling interval that fails to capture the myocardium.

2.2 | Left Atrium

Left atrial pacing was performed under general anesthesia at least one month after the right-sided procedure. Prior to anesthesia, a fixed curve sheath with protruding J-tipped guidewire was inserted in the left jugular vein and positioned in the CS under transthoracic echocardiographic guidance. Subsequently, general anesthesia was induced, and the horse was positioned in left lateral recumbency. The surface electrodes for the EnSite system and for the 12-lead ECG were placed on shaved skin, similar as in the standing procedure. Dilator and guidewire of the fixed curve sheath were exchanged for a decapolar deflectable catheter to be inserted into the CS and great cardiac vein. An intracardiac echocardiography catheter (Acuson AcuNav 5.0–10.0 MHz ultrasound catheter, Biosense Webster, Diegem, Belgium) was inserted through a 9 Fr introducer sheath. A transseptal puncture was performed under intracardiac echocardiography guidance to allow insertion of a deflectable guiding sheath into the LA [15, 18]. Subsequently, the 7 Fr loop electrophysiology catheter was introduced through the sheath to make a 3D EAM of the LA. Another guiding sheath was inserted for introduction of the same loop catheter to make a 3D EAM of the RA. Subsequently, the loop catheter was exchanged with a decapolar catheter and positioned at the myocardial sleeves of the CaVC. Two other decapolar catheters were introduced, each through a 9 Fr introducer sheath, and positioned at the TC and IVT. Catheters were placed at the same location as during the standing procedure. Electrograms from the catheter at the TC, IVT, CaVC, and CS were recorded during sinus rhythm. A decapolar catheter was introduced through the guiding sheath in the LA to induce PACs by pacing with a current of 15 mA and pulse width of 2 ms at a rate of 45 and 120 bpm. Ectopy was induced at ostium I, II, III, IV, left atrial appendage (LAA) and interatrial septum (IAS) just

dorsal to the septal mitral valve leaflet (Figure 1). Subsequently, the left bundle branch (LBB) was recorded ventral to the aortic valve. The maximum duration of general anesthesia was set at 5 h 30 min. When possible within the time frame of anesthesia, atrial ERP was determined at ostium I, II, III, IV. Finally, pacing at 45 and 120 bpm was performed via the recording catheters located in the RA to record activation patterns in general anesthesia. The last step of the procedure consisted of RA ERP measurements from each RA catheter. At the end of the procedure, catheters were withdrawn and horses were recovered using rope-assistance.

Both in the standing horses and under general anesthesia, 80 IU/kg bodyweight of unfractionated heparin (Heparine LEO, LEO pharma, Lier, Belgium) was administered intravenously at the start of the procedure. Activated clotting time (ACT) was measured at least every 2 h. If ACT was below 300 ms, a bolus of 40 IU/kg of heparin was administered. Throughout the procedures, all sheaths and introducers were flushed with heparinized saline (1 IU/mL) every 15 min. Serum cTnI was measured at the start, at the end, and 4 h after the end of the procedure (Alinity, i-STAT Sensitivity Troponin-I assay, Abbott, Zaventem, Belgium). Horses received penicillin (20 000 IU/kg IM q24, Peni-Kel, Kela) and flunixin meglumine on the day of the procedure (1.1 mg/kg; IV; Emdofluxin, Emdoka, Hoogstraten, Belgium) and the 2 days after (1.1 mg/kg q24; PO; Finadyne, Intervet International, Brussels, Belgium). Enoxaparin (40 IU/kg SC q24; Clexane, Sanofi, Diegem, Belgium) was administered after the procedure under general anesthesia until closure of the transseptal puncture [15].

2.3 | Measurements

Recordings of the 12-lead ECG and intracardiac electrograms were stored digitally and analyzed offline (Labsystem Pro v2.6, Boston Scientific, Diegem, Belgium). The intervals between the earliest electrogram (for sinus rhythm) or the pacing spike, set as 0 ms, and the onset of the first sharp deflection from baseline from the recording catheters were measured. Each measurement was performed on and averaged over three beats. In addition, the direction of activation along the electrodes of the CS catheter was noted as distal-to-proximal (from electrode 1–2 to 9–10), proximal-to-distal (from electrode 9–10 to 1–2), or curved activation (from the distal and proximal electrode toward the middle electrodes, from the middle electrodes toward the distal and proximal electrodes; Figure 1C). During sinus rhythm and for each pacing location, the time between the earliest electrogram and the onset, mid, and end of the P wave on lead II of the 12-lead ECG was measured. Subsequently, the time between the onset of the P wave and the electrogram of the recording catheter was measured.

Basic intervals of His bundle recordings were measured during sinus rhythm in the standing horses, following guidelines from human medicine [19], as shown in Figure 2. The PA interval was measured between the onset of the P wave and the atrial electrogram on the His bundle catheter. The AH interval was measured between the atrial electrogram on the His bundle catheter and the beginning of the His electrogram. The duration of the His bundle electrogram was the time from the beginning of the first component of the His bundle electrogram to the end of the last component. The HV interval was measured between the His bundle electrogram and the earliest recorded ventricular activation (beginning of the surface QRS complex) [19]. The interval between the LBB and RBB signal and the ventricular electrogram on the same catheter was measured. Each measurement was repeated on and averaged over three beats.

2.4 | Data Analysis

Normality of continuous variables was evaluated by inspection of histograms and Q–Q plots, using SPSS (SPSS Statistics 25, IBM). Normally distributed data are reported as mean ± SD and non-normally distributed data as median and range.

3 | Results

3.1 | Activation Patterns

Normal and paced activation patterns were recorded in eight standing, sedated horses and in seven horses under general anesthesia. In one horse, the procedure under general anesthesia had to be prematurely interrupted due to hyperkalemia of unknown origin.

Median activation timings during sinus rhythm and pacing at 45 bpm are given in Table 1 and those during pacing at 120 bpm in Table S1. Pacing at 120 bpm resulted in similar activation timings. Table 2 presents the timing of the electrograms relative to the P wave. Figures 3 and 4 show typical activation patterns during RA and LA pacing, respectively.

Some horses showed a slightly different activation sequence, as described below. During the standing procedure in one horse, activation in sinus rhythm usually started at the IVT, followed by TC activation and only occasionally started at the TC. No activation patterns during general anesthesia were recorded in this horse due to hyperkalemia. When pacing the IVT during the standing procedure, the impulse conducted to the TC and the CaVC, reaching the TC first in five horses, while the CaVC was activated first in the other three. When pacing the CaVC, the last activation alternated between the TC and CS, but activation timings occurred almost simultaneously. In one horse during CaVC pacing in general anesthesia, the first activation occurred at the CS, instead of the IVT. Pacing from the CS activated the CaVC first in one horse, instead of the IVT, and last activation varied between the TC and CaVC. Pacing at the RAFW was performed in seven horses and first activated the TC ($n = 4$) or IVT ($n = 3$). Pacing of the CrVC was performed in six horses and activated first the IVT ($n = 3$) or TC ($n = 3$). When pacing ostium I, last activation varied between the TC ($n = 5$) and IVT ($n = 2$). When pacing ostium II, activation spread first to the CS in five horses and to the CaVC in the other two. Last activation varied between TC ($n = 5$) and IVT ($n = 2$). First activation when pacing ostium III varied between the CaVC ($n = 4$) and IVT ($n = 3$), while the last activation varied between the CS ($n = 6$) and TC ($n = 1$). Pacing ostium IV activated first the CS ($n = 5$) or CaVC ($n = 2$). Pacing the LAA first activated the CS in six horses, while in one horse

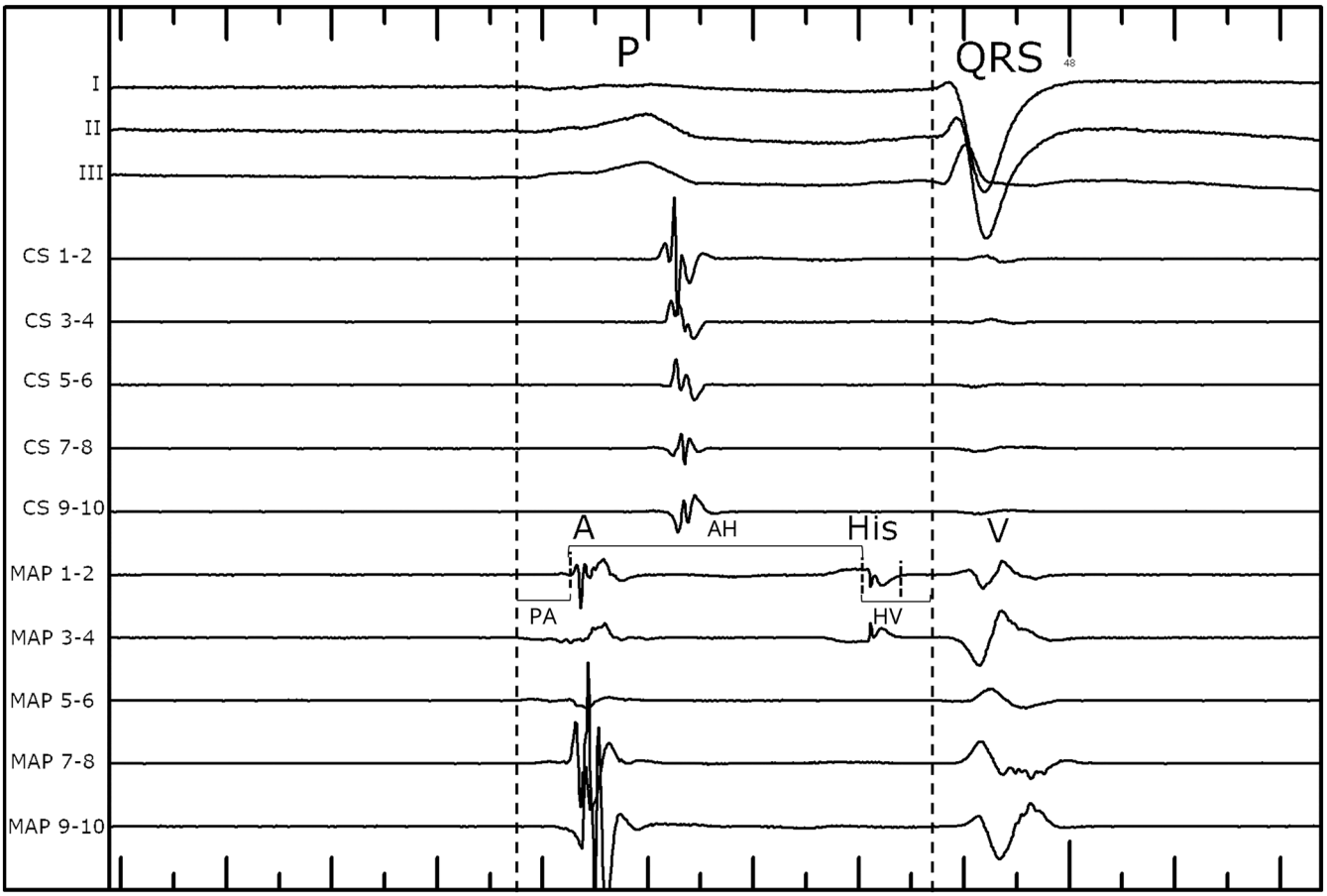

FIGURE 2 | His bundle recordings and basic intervals from Horse 5. The first three traces represent lead I, II and III of the surface 12-lead ECG [6], followed by five traces of intracardiac electrograms recorded by the catheter in the coronary sinus (CS). The last five traces are recorded by the exploring mapping catheter (MAP), of which the first two traces (electrode 1–2 and 3–4) show a His signal. The long-dashed lines represent the onset of the P wave and QRS complex. The short-dashed lines mark the beginning of the atrial deflection and beginning and end of the His signal. Measurements were performed from the onset of the P wave to the atrial deflection (PA interval), from the onset of the atrial deflection to the onset of the His signal (AH interval), the duration of the His signal (two small dashed lines at the start and end of the His signal), and from the onset of the His signal to the onset of the QRS complex (HV).

the IVT was activated first, followed by the CS. Interatrial septal pacing activated the CaVC first in five horses, and the IVT in two horses.

3.2 | His Bundle Recordings

The His signal, as shown in Figure 2, could be recorded in 5/8 horses. The median PA interval was 78 [39–114] ms, AH 196 [120–264] ms, His bundle duration 24 [14–78] ms, and HV 62 [52–198] ms. The RBB could be recorded in four horses, with a P-RBB interval of 364 [252–394] ms and RBB-V interval of 38 [32–52] ms. The LBB was recorded in five horses and had a P-LBB interval of 291 [230–382] ms and LBB-V of 34 [14–44] ms.

3.3 | Effective Refractory Period

Results of ERP measurements for each pacing site are presented in Table 3. Missing values are due to time restrictions of general anesthesia. The mean overall ERP was 287 ± 54 ms and varied between 170 and 420 ms. The ERP showed inter-horse and intra-horse variation, as shown in Table S2. The extrastimulus induced AF in five horses (Horse 1, 2, 3, 6 and 7) when pacing at the CS ($n = 5$), IVT ($n = 1$), TC ($n = 1$), CrVC ($n = 1$), ostium I ($n = 3$), ostium II ($n = 3$) and ostium IV ($n = 1$). Atrial ERP at these sites ranged between 170 and 350 ms. Median duration of the AF episodes was 8 s [range 1 s—45 min]. All AF episodes cardioverted spontaneously, except the AF episodes of 45 min, which were cardioverted using a bolus of lidocaine (0.5 mg/kg IV; Lidor, Ecuphar, Oostkamp, Belgium).

3.4 | Cardiac Troponin I and Complications

The cTnI data of Horse 3 was excluded as this horse repeatedly showed elevated serum cTnI concentrations over a period of 1 year before the study in the absence of detectable cardiac disease, which was diagnosed as a falsely elevated value [20]. Missing data include 4 h after the standing procedure in Horse 6 and 4 h after general anesthesia in Horse 5. Baseline cTnI, measured at the start of the procedure, was within the reference range (< 0.06 ng/mL) in the 7 included horses. At the end of both

TABLE 1 | Median [range] activation timings in ms from each recording catheter during sinus rhythm and pacing at a rate of 45 beats per minute.

Pacing site	Procedure	TC	IVT	CaVC	CS	CS electrode activation	Most common activation pattern (number of horses)
Sinus rhythm	S	0	46 [−32–73]	88 [50–130]	132 [95–154]	7 DP; 0 PD; 1 C	TC—IVT—CaVC—CS (7/8)
	A	0	62 [23–76]	95 [70–138]	121 [110–145]	7 DP; 0 PD; 0 C	TC—IVT—CaVC—CS (6/7)
TC	S	0	66 [54–90]	111 [81–144]	147 [111–173]	8 DP; 0 PD; 1C	TC—IVT—CaVC—CS (8/8)
	A	0	66 [37–91]	106 [76–114]	146 [124–173]	3 DP; 1 PD; 2 C	TC—IVT—CaVC—CS (7/7)
IVT	S	55 [43–92]	0	67 [40–100]	114 [81–129]	7 DP; 0 PD; 1 C	IVT—TC—CaVC—CS (5/8)
	A	63 [45–76]	0	95 [68–117]	141 [102–185]	2 DP; 2 PD; 2 C	IVT—TC—CaVC—CS (6/6)
CaVC	S	104 [90–135]	66 [23–93]	0	112 [93–150]	3 DP; 3 PD; 2 C	CaVC—IVT—TC ≈ CS (8/8)
	A	106 [94–137]	76 [32–115]	0	104 [72–149]	0 DP; 5 PD; 2 C	CaVC—IVT—CS ≈ TC (6/7)
CS	S	148 [124–168]	116 [86–140]	131 [86–157]	0		CS—IVT—CaVC—TC (5/8)
RAFW	S	66 [18–91]	58 [21–76]	117 [74–172]	153 [127–199]	6 DP; 0 PD; 2 C	RAFW—IVT ≈ TC—CaVC—CS (6/7)
RAA	S	37 [17–62]	97 [47–138]	148 [99–178]	173 [148–213]	7 DP; 0 PD;1 C	RAA—TC—IVT—CaVC—CS (8/8)
CrVC	S	77 [54–115]	91 [21–162]	156 [126–196]	183 [153–206]	6 DP; 0 PD; 1 C	CrVC—TC—IVT—CaVC—CS (3/6)
Ostium I	A	145 [134–161]	124 [83–171]	103 [64–121]	60 [45–98]	1 DP; 5 PD; 1C	Ostium I—CS—CaVC—IVT—TC (5/7)
Ostium II	A	131 [91–166]	119 [64–176]	84 [46–138]	76 [52–97]	0 DP; 5 PD; 2 C	Ostium II—CS ≈ CaVC—IVT—TC (3/7)
Ostium III	A	93 [82–140]	66 [23–108]	70 [48–91]	123 [94–143]	4 DP; 3 PD; 0 C	Ostium III—IVT ≈ CaVC—TC—CS (6/7)
Ostium IV	A	139 [112–154]	107 [88–160]	119 [66–132]	81 [36–117]	0 DP; 7 PD; 0 C	Ostium IV—CS—IVT—CaVC—TC (2/7)
LAA	A	115 [83–172]	100 [78–170]	127 [81–181]	36 [6–97]	6 DP; 1 PD; 0 C	LAA—CS—IVT—TC—CaVC (3/7)
IAS	A	102 [69–145]	71 [44–129]	67 [41–99]	87 [65–110]	2 DP; 3 PD; 2 C	IAS—CaVC ≈ IVT—TC—CS (3/7)

Note: Activation timing is the time between the electrograms from the terminal crest catheter (during sinus rhythm) or pacing spike (during pacing) and the onset of the first rapid deflection from the baseline of the electrogram recorded by the respective catheter. Locations that were activated almost simultaneously, less than 10 ms apart, are indicated by the '≈' symbol. The direction of activation along the electrodes of the CS catheter was noted as distal-to-proximal (DP; from electrode 1–2 to 9–10), proximal-to-distal (PD; from electrode 9–10 to 1–2), or curved activation (C; from the distal and proximal electrode toward the middle electrodes, from the middle electrodes toward the distal and proximal electrodes). The number of horses showing the most common activation pattern is shown.
Abbreviations: A: anesthesia; CaVC: caudal vena cava; CrVC: cranial vena cava; CS: coronary sinus; IVT: intervenous tubercle; LAA: left atrial appendage; RAA: right atrial appendage; RAFW: RIGHT atrial free wall; S: standing procedure; TC: terminal crest.

TABLE 2 | Timing of the electrograms from the catheters at the terminal crest (TC), intervenous tubercle (IVT), caudal vena cava (CaVC) and coronary sinus (CS) relative to the P wave during sinus rhythm and pacing at 45 beats per minute.

Pacing location	Pacing/TC—onset P*	Pacing—mid P	Pacing—end P	Onset P—TC	Onset P—IVT	Onset P—CaVC	Onset P—CS
Sinus rhythm	18 [−24–48]	94 [50–144]	193 [160–218]	NA	27 [−70–56]	66 [32–124]	103 [72–138]
TC	27 [11–48]	102 [93–131]	206 [189–236]	NA	45 [20–54]	90 [51–118]	117 [88–150]
IVT	54 [41–89]	114 [95–139]	164 [134–193]	5 [−24–35]	NA	6 [−24–35]	53 [2–104]
CaVC	74 [24–94]	119 [99–138]	170 [134–207]	40 [22–79]	−9 [−22–27]	NA	40 [4–86]
CS	80 [0–101]	166 [57–199]	233 [103–258]	71 [38–142]	31 [6–119]	60 [29–107]	NA
RAFW	88 [36–153]	142 [112–200]	214 [190–251]	−16 [−89–15]	−52 [−82–26]	19 [−31–75]	72 [41–102]
RAA	67 [23–112]	147 [115–175]	228 [119–282]	−19 [−72–6]	35 [−19–72]	77 [36–114]	123 [61–142]
CrVC	57 [10–139]	151 [89–216]	236 [200–276]	24 [−52–63]	11 [−46–121]	103 [−6–131]	119 [52–181]
Ostium I	50 [38–74]	170 [124–188]	242 [235–269]	91 [70–121]	65 [51–122]	49 [24–76]	6 [−15–47]
Ostium II	46 [24–75]	139 [74–194]	206 [187–270]	87 [57–105]	66 [34–119]	37 [21–79]	22 [6–63]
Ostium III	53 [30–78]	111 [68–152]	176 [143–220]	7 [3–67]	9 [−25–38]	8 [−24–56]	65 [43–108]
Ostium IV	49 [39–68]	158 [121–183]	222 [192–261]	88 [63–134]	58 [39–120]	66 [36–82]	28 [20–63]
LAA	69 [20–82]	154 [119–192]	223 [160–270]	55 [29–97]	48 [10–88]	59 [26–91]	−35 [−58–48]
Interatrial septum	54 [3–97]	127 [83–181]	161 [120–250]	44 [9–107]	26 [−11–38]	6 [−11–33]	27 [8–67]

Note: The first electrograms could occur before the onset of the P wave. Timings are shown as median and range, in ms. Onset, mid, and end of the P wave were determined on lead II of the 12-lead ECG. For pacing locations in the right atrium, timings are displayed from the standing procedure. *During sinus rhythm, the electrogram recorded at the terminal crest relative to the P wave was measured, while during right atrial pacing, the pacing spike relative to the P wave was measured. NA: Not applicable, because the pacing spike occurs before the onset of the P wave.
Abbreviations: CrVC: cranial vena cava; LAA: left atrial appendage; RAA: right atrial appendage; RAFW: right atrial free wall.

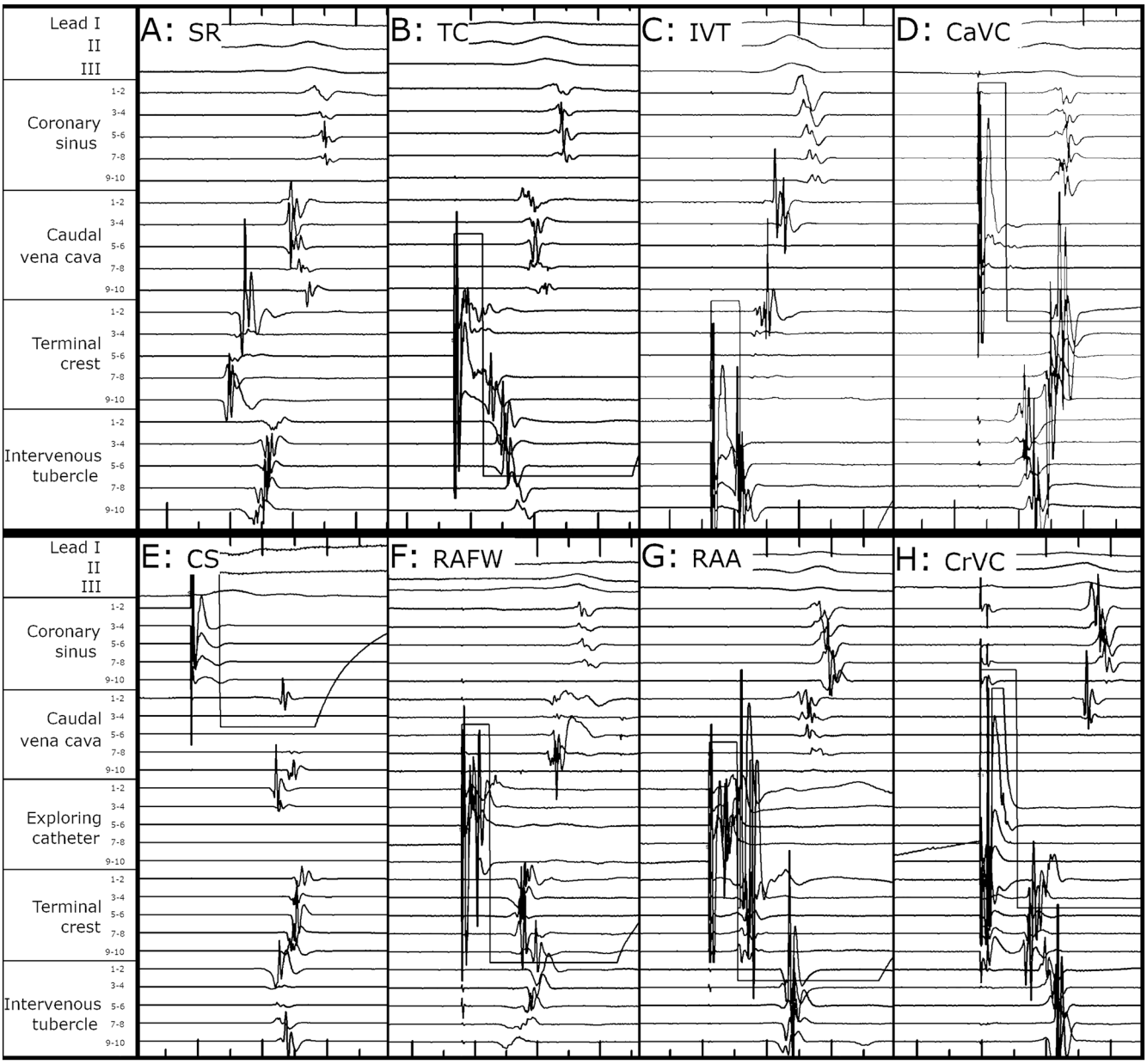

FIGURE 3 | Examples of typical activation patterns during sinus rhythm (A) and right atrial pacing (B–H), including coronary sinus pacing (CS, E). These activation maps can be best appreciated when viewed together with the catheter positions in Figure 1. The upper three traces of each panel represent the surface 12-lead ECG [6] lead I, II and III, while all other traces show intracardiac electrograms of the recording catheters. During sinus rhythm (A), activation started at the terminal crest (TC), followed by the intervenous tubercle (IVT), caudal vena cava (CaVC) and the CS, with a distal-to-proximal electrode activation. Pacing was performed at each of the recording catheters: TC (B), IVT (C), CaVC (D) and CS (E), with the first activation at the respective catheter, visible as the pacing spike. Pacing the TC (B) was followed by IVT activation and subsequent CaVC activation. Pacing the IVT (C) resulted in activation of the TC, followed by the CaVC. Pacing the CaVC (D) activated the IVT, followed by an almost simultaneous activation of the TC and CS. Pacing in the CS (E) resulted in late activation of the IVT, followed by the CaVC and TC. The exploring catheter, present in the bottom panels (F–H), paced at additional sites. Pacing at the right atrial free wall (RAFW, F) first activated the IVT, followed by TC. Pacing the right atrial appendage (RAA, G) resulted in a fast activation of the TC. Pacing the cranial vena cava (H) activated the TC first, followed by the IVT. Note that the CS catheter is activated last with a distal-to-proximal electrode activation, making it indicative for right atrial pacing. Note the small spikes on the IVT traces on panel D, F and G. These spikes coincide with the pacing spike and should be distinguished from the true IVT electrograms.

procedures, cTnI remained within the reference range for all horses. Four hours after the standing and anesthesia procedure, cTnI increased to 0.088 ng/mL in Horse 2 and to 0.079 ng/mL in Horse 1, respectively, and remained within the reference range in the remainder.

No complications occurred during the standing procedure. During general anesthesia, the current study was combined with other studies, including pacing in the ventricles, resulting in a long anesthesia time. During anesthesia, one horse developed idiopathic hyperkalemia and hyperglycemia with atrial standstill,

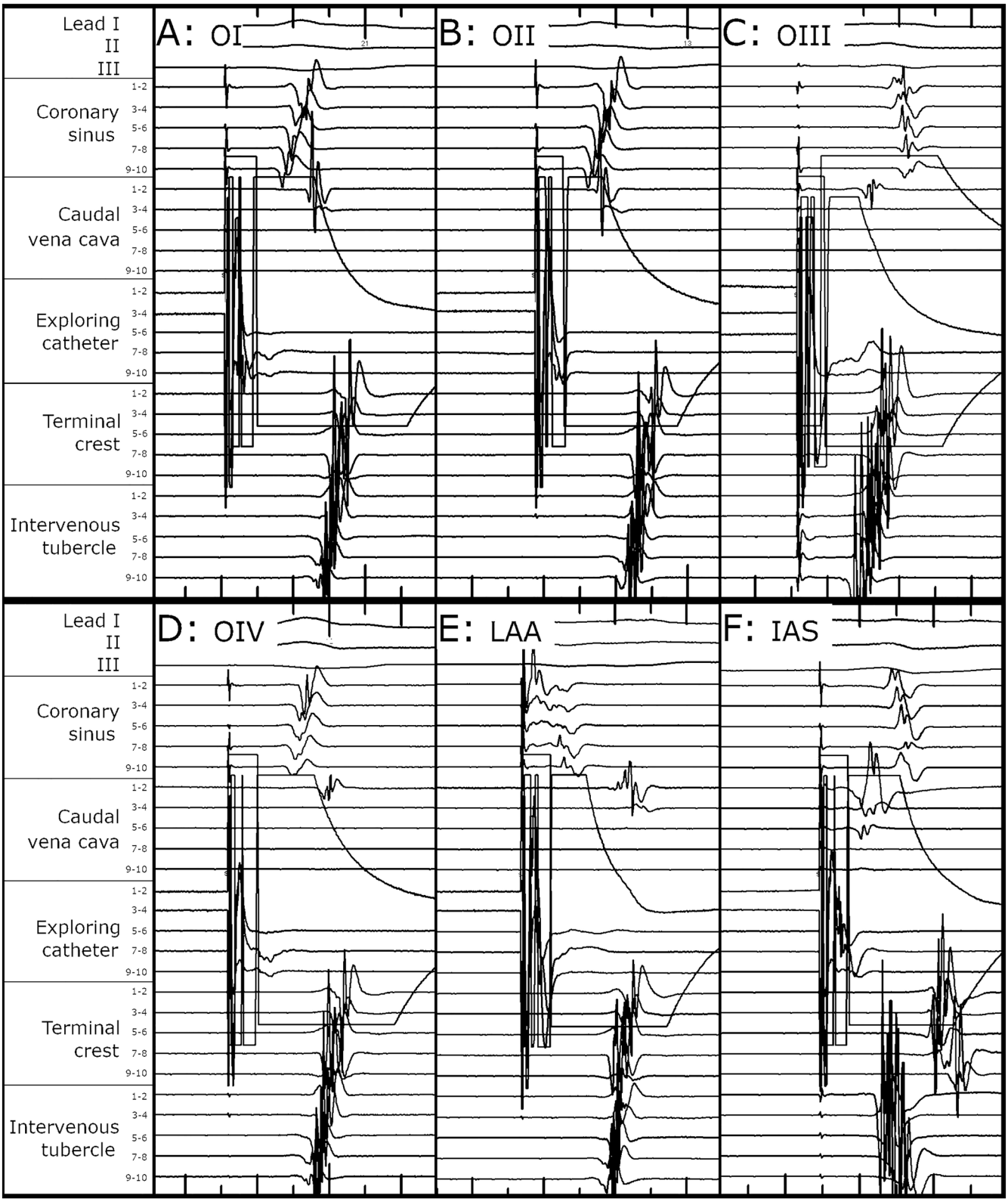

FIGURE 4 | Legend on next page.

necessitating immediate termination of the study. Complications after the anesthesia procedure included left triceps myopathy ($n=1$) and eventful recovery ($n=2$) associated with hemoabdomen ($n=1$) and left carpal fracture ($n=1$), as described and discussed elsewhere [15].

The mean procedure time for the standing procedure was 5 h 39 ± 59 min. The mean time to place the recording catheters, starting from making the first skin incision to confirming the correct location, was 117 ± 27 min; this corresponds to the time needed for a clinical case.

FIGURE 4 | Examples of typical activation patterns during left atrial pacing. These activation maps can be best appreciated when viewed together with the catheter positions in Figure 1. The upper three traces of each panel represent the surface 12-lead ECG [6] lead I, II and III, followed by traces of intracardiac electrograms of the recording catheters. The exploring catheter was inserted in the left atrium and paced at different left atrial sites. Pacing at ostium I (A) and II (B) resulted in similar activation patterns, with the coronary sinus catheter being activated first with a proximal-to-distal activation. Pacing ostium III (C) exhibited a later activation timing of the coronary sinus compared to other left atrial pacing sites. The intervenous tubercle and caudal vena cava were activated almost simultaneously. The activation pattern during ostium IV pacing (D) resembles the one from ostium I and II, with the coronary sinus activated first and in a proximal-to-distal direction. However, the intervenous tubercle was activated before the caudal vena cava. Left atrial appendage pacing (E) typically resulted in a very fast activation of the coronary sinus in a distal-to-proximal direction. Pacing the interatrial septum (F) resulted in an almost simultaneous activation of the caudal vena cava and intervenous tubercle. The coronary sinus was activated earlier than during ostium III pacing, which is helpful in differentiating these two. Note the small spikes on the intervenous tubercle traces on panel C and F. These spikes coincide with the pacing spike and should be distinguished from the true intervenous tubercle electrograms.

4 | Discussion

We explored the use of multiple catheter recording to investigate normal and abnormal atrial activation patterns. Pacing-induced atrial ectopy resulted in characteristic activation patterns. Recognizing those patterns is important to identify the origin of ectopy in clinical cases. In addition, His bundle recordings and ERPs at different pacing sites were obtained.

Multiple catheter recording to map atrial activation was based on the four wire technique as commonly used in humans and dogs [19]. It has been shown to allow identification of the anatomical origin of RA and LA tachycardia in human patients [21–23]. In these studies, ectopy from each pulmonary vein resulted in characteristic RA activation patterns and a typical direction of CS activation, which can allow rapid identification of the ectopic pulmonary vein [21, 22]. Catheter positions were slightly adapted in our study to focus on atrial activation. Similar to people and dogs, a catheter was placed at the TC and into the CS to record earliest activation at the region of the sinus node [11, 24] and LA, respectively. Instead of recording the His bundle and right ventricular apex, the other two catheters were positioned at the IVT and CaVC myocardial sleeves, a region that is known to be arrhythmogenic in horses [1–3, 16].

Activation patterns and timings during sinus rhythm were similar as previously described by 3D EAM [11], except for the CaVC, which was activated earlier in our study (95 ms vs. 127 ms). Our catheter was placed by ultrasound guidance, obtaining a more dorsal catheter position, while myocardial sleeves are the longest on the medial side, where a later activation can be obtained. Earliest activation during sinus rhythm was recorded by the catheter at the TC in 7/8 horses, as expected. In one horse, activation started at the IVT catheter and alternated with the TC throughout the procedure. This can be attributed to two different sinus node exit sites, as previously described in a horse during 3D EAM [11], as well as in humans and dogs [25–27]. Pacing at the IVT in this horse did not induce the same activation timings as during sinus rhythm, with a slower conduction to the TC and a faster conduction to the CaVC and CS, indicating that the sinus node exit was not exactly located at the IVT catheter. In all horses, pacing at the TC resulted in a similar but slightly slower activation pattern as during sinus rhythm. This might be because pacing was not exactly on the sinus node and, depending on catheter location, slightly more toward the RAA or CrVC. Similar activation timings were obtained when pacing at 45 and 120 bpm. This is in accordance with another study in people that showed no significant effect of pacing cycle length on the pace map [21].

TABLE 3 | Effective refractory periods (ERP) measured at different locations in the right and left atrium, in standing, sedated horses or under general anesthesia.

Pacing site	Standing	Range	Number of horses	Anesthesia	Range	Number of horses
TC	299 ± 34	250–350	7	287 ± 46	260–340	3
IVT	267 ± 38	220–320	7	247 ± 61	180–300	3
CaVC	290 ± 34	230–340	8	330 ± 14	310–340	4
CS	247 ± 74	170–320	6	180	NA	1
CrVC	265 ± 34	230–310	4	240	NA	1
Ostium I	NA	NA	NA	288 ± 92	170–420	5
Ostium II	NA	NA	NA	280 ± 34	240–320	5
Ostium III	NA	NA	NA	328 ± 36	300–380	4
Ostium IV	NA	NA	NA	354 ± 24	320–380	5

Note: Mean ERP ± standard deviation and range are reported. In the first 3 horses, ERP was measured by pacing a drive cycle of 8 beats at a fixed coupling interval of 600 ms (S1–S1), followed by an extrastimulus, starting with a coupling interval above the expected ERP (S1–S2). S1–S2 was decreased with 10 ms until S2 failed to capture atrial myocardium. In the next 5 horses, S1–S2 was started with a coupling interval below the expected ERP and was increased with 10 ms until the extrastimulus captured the myocardium. The ERP is defined as the longest coupling interval that fails to capture the myocardium. Left atrial ERPs were only determined during anesthesia. Missing values are due to the maximum time frame of anesthesia, which was set at 5 h 30 min.
Abbreviations: CaVC: caudal vena cava; CrVC: cranial vena cava; IVT: intervenous tubercle; NA: not applicable; TC: terminal crest.

Pacing-induced ectopic beats from the RA and LA resulted in characteristic activation patterns. First of all, the activation timing of the CS is an important feature to distinguish an RA or LA location of ectopy. A late CS activation suggests an RA location or ostium III. Further differentiation can be made based on the timing of the TC. A very early activation of the TC is characteristic for ectopy at the RAA since pacing at this site entailed the fastest activation of the TC. Ectopy originating from the RAFW first activated the IVT, followed by the TC, while this was the other way around for ectopy at the CrVC. However, first activation varied between TC and IVT for RAFW and CrVC pacing, making it difficult to differentiate the two. However, compared to CrVC ectopy, RAFW ectopy activated the CaVC earlier, which might help to identify the origin. Ectopy from ostium III can be recognized by the almost simultaneous activation of the IVT and CaVC.

Early CS activation suggests ectopy from the LA, except ostium III. Ectopy from ostium I, II, IV, and the LAA activated the CS catheter first. A very early CS activation, with a distal-to-proximal electrode activation, suggests LAA ectopy. Ectopy from ostium I and II activated the CS later compared to the LAA, and a proximal-to-distal electrode activation was present. Since ostium I and II are located close to each other, they showed similar activation patterns. However, ostium II ectopy shows a more rapid activation of the CaVC compared to ostium I due to a more medial location of ostium II. Ostium IV showed a similar activation as ostium I and II; however, after the CS, the IVT was typically activated second, and the CaVC only after that. Finally, ectopy from the IAS can be recognized by an almost simultaneous activation of the CaVC and IVT, followed by the CS. For IAS ectopy, the CS is activated more rapidly compared to ectopy from ostium III. It is important to note that the timings of the electrograms were measured relative to the pacing spike. In naturally occurring arrhythmias, no pacing spike is present, and the electrograms should be compared to the onset of the P wave. In human medicine, the local activation time at the site of origin should precede the onset of the P wave on the surface ECG by an average of 10–40 ms, which represents the target of ablation of a focal supraventricular arrhythmia [13]. In our study, the pacing spike, so the site of earliest activation, preceded the onset of the P wave by an average of 27–84 ms.

Variations in activation patterns did occur, which can lead to difficulties in interpreting the map. Slight variations in catheter positioning can influence the activation map. The depth of the recording catheter into the CS might have an effect on the activation timing or direction of electrode activation. Our CS catheter was placed deep into the great cardiac vein and thereby measured LA signals, which led to a distal-to-proximal activation during sinus rhythm. This is different than in humans and dogs, in which the CS catheter is placed at the ostium of the CS, thereby obtaining a proximal-to-distal activation during sinus rhythm. Another example is the position of the catheter at the TC, which can be positioned more into the RAA or more toward the CrVC, leading to slight differences in activation. Variations in our data might also be caused by pacing catheter position. Cranial vena cava pacing at a more dorsolateral location might explain more rapid activation of the IVT instead of the TC. Pacing the ventral wall of ostium III might favor conduction through the oval fossa and more rapid activation of the IVT. For LA ectopy, the RA activation pattern is dependent on the nature of left-to-right atrial conduction [21]. In humans, three major communications between RA and LA have been described, namely the Bachmann bundle, oval fossa and CS musculature [28]. Similarly, breakthrough at the Bachmann bundle and a caudal breakthrough site have been described in horses [7]. Left-to-right atrial conduction might vary between horses, leading to differences in the activation maps.

Since all recording catheters are placed in the RA, multiple catheter recording can be performed in the standing horse, which is helpful to select an optimal treatment strategy, such as ablation. With this information, the region of interest can be immediately targeted during anesthesia, obviating the need to map the whole heart and reducing total anesthesia time. Multiple catheter recording could also be helpful to identify the origin of ectopy in relation to AF. In human medicine, ectopy from the pulmonary veins has been identified as the main trigger for initiation of AF and can be eliminated by pulmonary vein isolation [29]. Indications of a similar mechanism have arisen in horses [30–32] and pulmonary vein isolation has been performed experimentally [33] and in selected cases of horses with recurrent AF (personal data). This is a very challenging procedure, requiring a long anesthesia time, rendering it currently unfeasible to isolate all four ostia during one procedure. Multiple catheter recording might reveal which pulmonary veins or atrial sites are most often arrhythmogenic in horses, which could allow the development of a horse-specific ablation procedure in order to reduce recurrence risk of AF and still limit anesthesia time. Keeping anesthesia time short reduces anesthesia-related risks [2, 3]. During our general anesthesia study, several studies were combined, resulting in a long anesthesia duration, up to 5 h 30 min, leading to a considerable complication rate.

In our study, a His signal could be recorded in five horses. Since it remains difficult to obtain a stable His signal, this was not included in the multiple catheter mapping. His signals are important to assess atrioventricular (AV) conduction abnormalities and to understand arrhythmias involving the AV node or His-Purkinje system [34]. The His bundle has been recorded in horses previously in the right and left ventricle under general anesthesia [11] and in the RA in standing horses [35]. Basic intervals have been reported in horses using allometric scaling [36] and in seven standing sedated horses [35]. Intervals were comparable to our study, except for the HV interval measured in the study of Nissen et al. [35], which was 134 ms and therefore longer than predicted by allometric scaling (84 ms) and by our study (62 ms). This is probably because the HV interval was measured from the His signal to the earliest recorded ventricular activation, instead of the earliest recorded ventricular activation, which is almost always the beginning of the QRS complex [19, 37]. In addition to the His bundle, RBB and LBB signals were recorded in four standing sedated horses and five horses under general anesthesia, respectively. Bundle branch signals can be distinguished from a true His signal by a smaller or absent atrial electrogram and a shorter HV interval [38].

We determined ERPs at different atrial locations. Atrial ERP has been determined previously in horses to study the pathophysiology of AF [17, 39, 40] or evaluate anti-arrhythmic drugs [41–45]. In healthy horses, ERP ranged between 200 and 300 ms, depending on the pacing cycle length [9]. This has, however, only been measured in the RA, without specifications of the exact pacing

site. Our study is the first to report ERP at specific locations in the RA and LA in horses and showed ERPs between 170 and 420 ms. Sites with shorter ERPs might permit faster reentrant circuits [46] and might be related to arrhythmogenic tissue. The ERP values varied widely, both between and within horses, and there appeared no specific location with a consistently shorter ERP in the small study sample. In contrast to human patients and dogs, ERP measurement with decreasing S1–S2 intervals induced AF episodes in several horses, highlighting their susceptibility to AF. To avoid AF-induced electrical remodeling during subsequent S1–S2 pacing, further measurements were performed by increasing the S1–S2 intervals to obtain more reliable ERP measurements.

Our study had some limitations. Only a small number of horses was used. The study was performed in horses with pacing-induced PACs, so the applicability for naturally occurring arrhythmias remains to be demonstrated. In addition, only healthy horses were included. Structural abnormalities, such as areas of fibrosis, can be present in horses with naturally occurring arrhythmias, which might influence the activation pattern. The predictive ability of the activation patterns depends on careful and precise placement of the recording catheters. Inaccurate catheter positioning or displacement of catheters during the procedure might create a misleading activation map [21]. Horses were sedated or under general anesthesia during activation mapping, which might influence conduction. Sedation might also have an impact on the sinus node and AV node, thereby possibly influencing basic intervals. A standardized sedation protocol with a continuous rate infusion was used in order to minimize variation on conduction throughout the procedure.

In conclusion, mapping the RA activation using multiple catheters was shown to be feasible in horses. Characteristic RA activation maps during sinus rhythm and RA and LA pacing could be identified. The electrograms recorded by the CS were an important feature to differentiate the site of ectopy, with a late CS activation indicating ectopy originating from the RA or ostium III, while an early CS activation indicates a LA origin. In addition, the direction of CS electrode activation further aids in differentiating LA ectopic locations. Data from our study might help to identify the origin of supraventricular arrhythmias in horses and facilitate mapping and ablation procedures.

Acknowledgments

Eva Buschmann, Ingrid Vernemmen, and Marie Demeyere are PhD fellows funded by the Research Foundation Flanders (FWO Vlaanderen; Grant number 1SE9122N, 1S71521N and 1SA2223N, respectively). Funding was received for ultrasound equipment by the Special Research Fund Ghent University (Grant number 01B05818).

Disclosure

Authors declare no off-label use of antimicrobials.

Ethics Statement

Approved by the Ethical Committee of the Faculty of Veterinary Medicine, Ghent University. Approval number: 2022-004. Authors declare human ethics approval was not needed.

Conflicts of Interest

The authors declare no conflicts of interest.

References

1. E. Buschmann, G. Van Steenkiste, I. Vernemmen, et al., "Lesion Size Index-Guided Radiofrequency Catheter Ablation Using an Impedance-Based Three-Dimensional Mapping System to Treat Sustained Atrial Tachycardia in a Horse," *Equine Veterinary Journal* 57 (2025): 1009–1016.

2. E. Buschmann, G. Van Steenkiste, I. Vernemmen, et al., "Caudal Vena Cava Isolation Using Ablation Index-Guided Radiofrequency Catheter Ablation (CARTO 3) to Treat Sustained Atrial Tachycardia in Horses," *Journal of Veterinary Internal Medicine* 39 (2025): e17251.

3. G. Van Steenkiste, T. Boussy, M. Duytschaever, et al., "Detection of the Origin of Atrial Tachycardia by 3D Electro-Anatomical Mapping and Treatment by Radiofrequency Catheter Ablation in Horses," *Journal of Veterinary Internal Medicine* 36 (2022): 1481–1490.

4. E. Buschmann, G. Van Steenkiste, T. Boussy, et al., "Three-Dimensional Electro-Anatomical Mapping and Radiofrequency Ablation as a Novel Treatment for Atrioventricular Accessory Pathway in a Horse: A Case Report," *Journal of Veterinary Internal Medicine* 37 (2023): 728–734.

5. E. M. Hesselkilde, J. L. Isaksen, B. V. Petersen, et al., "A Novel Approach for Obtaining 12-Lead Electrocardiograms in Horses," *Journal of Veterinary Internal Medicine* 35 (2021): 521–531.

6. G. van Loon and A. Decloedt, "Arrhythmias and Abnormalities of the Cardiac Conduction System in Athletic Horses," in *Equine Sports Medicine and Surgery*, 3rd ed., ed. K. Hinchcliff, A. Kaneps, R. Geor, and E. van Erck-Westergem (Elsevier, 2024), 831–865.

7. G. Van Steenkiste, T. Delhaas, B. Hermans, et al., "An Exploratory Study on Vectorcardiographic Identification of the Site of Origin of Focally Induced Premature Depolarizations in Horses, Part I: The Atria," *Animals* 12 (2022): 549.

8. A. Avison, A. R. Gelzer, V. B. Reef, et al., "Twenty-Four Hour Continuous Transvenous Temporary Right Ventricular Pacing in Healthy Horses," *Journal of Veterinary Internal Medicine* 38 (2024): 1751–1764.

9. G. van Loon, G. Van Steenkiste, L. Vera, et al., "Catheter-Based Electrical Interventions to Study, Diagnose and Treat Arrhythmias in Horses: From Refractory Period to Electro-Anatomical Mapping," *Veterinary Journal* 263 (2020): 105519.

10. G. Van Steenkiste, D. De Clercq, T. Boussy, et al., "Three Dimensional Ultra-High-Density Electro-Anatomical Cardiac Mapping in Horses: Methodology," *Equine Veterinary Journal* 52 (2020): 765–772.

11. G. Van Steenkiste, L. Vera, A. Decloedt, et al., "Endocardial Electro-Anatomic Mapping in Healthy Horses: Normal Sinus Impulse Propagation in the Left and Right Atrium and the Ventricles," *Veterinary Journal* 258 (2020): 105452.

12. E. Hesselkilde, D. Linz, A. Saljic, et al., "First Catheter-Based High-Density Endocardial 3D Electroanatomical Mapping of the Right Atrium in Standing Horses," *Equine Veterinary Journal* 53 (2021): 186–193.

13. Z. M. Issa and D. P. Zipes, "Conventional Intracardiac Mapping Techniques," in *Clinical Arrhythmology and Electrophysiology*, 3rd ed., ed. J. M. Issa (Elsevier, 2019), 125–154.

14. I. Vernemmen, E. Buschmann, M. Demeyere, et al., "Feasibility of Transthoracic Echocardiographic Guidance for Multi-Catheter Electrophysiological Mapping Studies in Horses," *Journal of Veterinary Internal Medicine* 38 (2024): 2686–2697.

15. I. Vernemmen, E. Buschmann, G. Van Steenkiste, et al., "Intracardiac Ultrasound-Guided Transseptal Puncture in Horses: Outcome,

Follow-Up and Peri-Operative Anticogulant Treatment," *Journal of Veterinary Internal Medicine* 38 (2024): 2707–2717.

16. L. Ibrahim, E. Buschmann, G. van Loon, and P. Cornillie, "Morphological Evidence of a Potential Arrhythmogenic Substrate in the Caudal and Cranial Vena Cava in Horses," *Equine Veterinary Journal* 57 (2024): 256–264.

17. G. van Loon, M. Duytschaever, R. Tavernier, W. Fonteyne, L. Jordaens, and P. Deprez, "An Equine Model of Chronic Atrial Fibrillation: Methodology," *Veterinary Journal* 164 (2002): 142–150.

18. I. Vernemmen, G. Van Steenkiste, E. Buschmann, et al., "Development of an Atrial Transseptal Puncture Procedure in Horses to Access the Left Heart: An Ultrasound-Guided Jugular Vein and Transhepatic Approach," *Equine Veterinary Journal* 57 (2025): 243–255.

19. F. D. Murgatroyd and A. D. Krahn, *Handbook of Cardiac Electrophysiology* (Remedica, 2002), 250.

20. J. Dauvillier, M. C. Tricaud, T. Hermange, et al., "Falsely Increased Troponin I Values in Horses With No Evidence of Myocardial Disease," 2023, In Cardio Retreat – International Meeting on Equine Cardiology, New Bolton, Pensylvannia, USA.

21. V. R. Deen, J. B. Morton, J. K. Vohra, et al., "Pulmonary Vein Paced Activation Sequence Mapping: Comparison With Activation Sequences During Onset of Focal Atrial Fibrillation," *Journal of Cardiovascular Electrophysiology* 13 (2002): 101–107.

22. P. M. Kistler, P. Sanders, S. P. Fynn, et al., "Electrophysiological and Electrocardiographic Characteristics of Focal Atrial Tachycardia Originating From the Pulmonary Veins – Acute and Long-Term Outcomes of Radiofrequency Ablation," *Circulation* 108 (2003): 1968–1975.

23. C. M. Tracy, J. F. Swartz, R. D. Fletcher, et al., "Radiofrequency Catheter Ablation of Ectopic Atrial Tachycardia Using Paced Activation Sequence Mapping," *Journal of the American College of Cardiology* 21 (1993): 910–917.

24. S. P. Bishop and C. R. Cole, "Morphology of the Specialized Conducting Tissue in the Atria of the Equine Heart," *Anatomical Record* 158 (1967): 401–415.

25. M. E. Josephson, D. L. Scharf, J. A. Kastor, and J. G. Kitchen, III, "Atrial Endocardial Activation in Man – Electrode Catheter Technique for Endocardial Mapping," *American Journal of Cardiology* 39 (1977): 972–981.

26. R. J. Hariman, B. F. Hoffman, and R. E. Naylor, "Electrical-Activity From the Sinus Node Region in Conscious Dogs," *Circulation Research* 47 (1980): 775–791.

27. R. B. Schuessler, J. P. Boineau, and B. I. Bromberg, "Origin of the Sinus Impulse," *Journal of Cardiovascular Electrophysiology* 7 (1996): 263–274.

28. F. X. Roithinger, J. Cheng, A. SippensGroenewegen, et al., "Use of Electroanatomic Mapping to Delineate Transseptal Atrial Conduction in Humans," *Circulation* 100 (1999): 1791–1797.

29. M. Haissaguerre, P. Jais, D. C. Shah, et al., "Spontaneous Initiation of Atrial Fibrillation by Ectopic Beats Originating in the Pulmonary Veins," *New England Journal of Medicine* 339 (1998): 659–666.

30. D. Linz, E. Hesselkilde, R. Kutieleh, T. Jespersen, R. Buhl, and P. Sanders, "Pulmonary Vein Firing Initiating Atrial Fibrillation in the Horse: Oversized Dimensions but Similar Mechanisms," *Journal of Cardiovascular Electrophysiology* 31 (2020): 1211–1212.

31. S. T. Kjeldsen, S. D. Nissen, A. Saljic, et al., "Structural and Electro-Anatomical Characterization of the Equine Pulmonary Veins: Implications for Atrial Fibrillation," *Journal of Veterinary Cardiology* 52 (2024): 1–13.

32. T. Vandecasteele, W. Van den Broeck, H. Tay, et al., "3D Reconstruction of the Porcine and Equine Pulmonary Veins, Supplemented With the Identification of Telocytes in the Horse," *Anatomia, Histologia, Embryologia* 47 (2018): 145–152.

33. E. Buschmann, G. Van Steenkiste, M. Duytschaever, et al., "Successful Caudal Vena Cava and Pulmonary Vein Isolation in Healthy Horses Using 3D Electro-Anatomical Mapping and a Contact Force-Guided Ablation System," *Equine Veterinary Journal* 56 (2023): 1068–1076.

34. S. Koulouris and M. Cascella, "Electrophysiologic Study Interpretation," in *StatPearls* (StatPearls, 2025).

35. S. D. Nissen, R. Weis, E. K. Krag-Andersen, et al., "Electrocardiographic Characteristics of Trained and Untrained Standardbred Racehorses," *Journal of Veterinary Internal Medicine* 36 (2022): 1119–1130.

36. S. F. Noujaim, E. Lucca, V. Muñoz, et al., "From Mouse to Whale: A a Universal Scaling Relation for the PR Interval of the Electrocardiogram of Mammals," *Circulation* 110 (2004): 2802–2808.

37. J. H. McAnulty, W. P. Nichol, C. Morris, L. Nichol, and S. H. Rahimtoola, "Measurement of the AH and HV Interval and His Bundle Duration: Interobserver and Intraobserver Variation," *American Journal of Cardiology* 57 (1986): 960–963.

38. Z. M. Issa and D. P. Zipes, "Electrophysiological Testing: Tools and Techniques," in *Clinical Arrhythmology and Electrophysiology*, 3rd ed., ed. J. M. Issa (Elsevier, 2019), 81–124.

39. D. De Clercq, G. Van Loon, R. Tavernier, et al., "Atrial and Ventricular Electrical and Contractile Remodeling and Reverse Remodeling Owing to Short-Term Pacing-Induced Atrial Fibrillation in Horses," *Journal of Veterinary Internal Medicine* 22 (2008): 1353–1359.

40. H. Carstensen, S. D. Nissen, A. Saljic, et al., "Long-Term Training Increases Atrial Fibrillation Sustainability in Standardbred Racehorses," *Journal of Cardiovascular Translational Research* 16 (2023): 1205–1219.

41. C. C. Schwarzwald, R. L. Hamlin, J. D. Bonagura, Y. Nishijima, C. Meadows, and C. A. Carnes, "Atrial, SA Nodal, and AV Nodal Electrophysiology in Standing Horses: Normal Findings and Electrophysiologic Effects of Quinidine and Diltiazem," *Journal of Veterinary Internal Medicine* 21 (2007): 166–175.

42. M. F. Fenner, H. Carstensen, S. Dalgas Nissen, et al., "Effect of Selective I(K,ACh) Inhibition by XAF-1407 in an Equine Model of Tachypacing-Induced Persistent Atrial Fibrillation," *British Journal of Pharmacology* 177 (2020): 3778–3794.

43. M. M. Haugaard, S. Pehrson, H. Carstensen, et al., "Antiarrhythmic and Electrophysiologic Effects of Flecainide on Acutely Induced Atrial Fibrillation in Healthy Horses," *Journal of Veterinary Internal Medicine* 29 (2015): 339–347.

44. M. M. Haugaard, E. Z. Hesselkilde, S. Pehrson, et al., "Pharmacologic Inhibition of Small-Conductance Calcium-Activated Potassium (SK) Channels by NS8593 Reveals Atrial Antiarrhythmic Potential in Horses," *Heart Rhythm* 12 (2015): 825–835.

45. H. Carstensen, L. Kjær, M. M. Haugaard, et al., "Antiarrhythmic Effects of Combining Dofetilide and Ranolazine in a Model of Acutely Induced Atrial Fibrillation in Horses," *Journal of Cardiovascular Pharmacology* 71 (2018): 26–35.

46. I. B. Kim, M. D. Rodefeld, R. B. Schuessler, et al., "Relationship Between Local Atrial Fibrillation Interval and Refractory Period in the Isolated Canine Atrium," *Circulation* 94 (1996): 2961–2967.

Supporting Information

Additional supporting information can be found online in the Supporting Information section. **Table S1.** Median [range] activation timings in ms from each catheter during pacing at a rate of 120 beats per minute. Activation timing is the time between the pacing spike and the electrogram recorded by the respective catheter. Locations that were activated almost simultaneously, less than 10 ms apart, are indicated by the '≈' symbol. The number of horses showing the most common activation pattern is shown. A: anesthesia; CaVC: caudal vena cava;

CrVC: cranial vena cava; CS: coronary sinus; IAS: interatrial septum; IVT: intervenous tubercle; LAA: left atrial appendage; RAA: right atrial appendage; RAFW: right atrial free wall; S: standing procedure; TC: terminal crest. **Table S2.** Effective refractory periods (ERP) measured at different locations in the right and left atrium, in standing, sedated horses or under general anesthesia. In the first three horses, ERP was measured by pacing a drive cycle of eight beats at a fixed coupling interval of 600 ms (S1–S1), followed by an extrastimulus, starting with a coupling interval above the expected ERP (S1–S2). S1–S2 was decreased with 10 ms until S2 failed to capture atrial myocardium. In the next five horses, S1–S2 was started with a coupling interval below the expected ERP and was increased with 10 ms until the extrastimulus captured the myocardium. The ERP is defined as the longest coupling interval that fails to capture the myocardium. Missing values are due to the maximum time frame of anesthesia, which was set at 5 h 30 min. CaVC: caudal vena cava; CrVC: cranial vena cava; IVT: intervenous tubercle; TC: terminal crest.