Journal of Veterinary Internal Medicine
Open Access
ACVIM
American College of Veterinary Internal Medicine

**STANDARD ARTICLE** OPEN ACCESS

Small Animal Internal Medicine Immunology

# Multicenter, Retrospective Determination of the Clinical Utility of Screening Tests in Dogs With Immune-Mediated Hemolytic Anemia in the United Kingdom and Ireland

Tyler Morrison[1] | Ioannis L. Oikonomidis[2] | Hannah K. Walker[3] | Nuno Sousa Santos[4] | Sophie A. Conway[5] | Benoît Cuq[6] | Carolina S. C. Albuquerque[4] | Claudia Gil-Morales[5] | Glynn Woods[1]

[1]Hospital for Small Animals, University of Edinburgh, Edinburgh, UK | [2]Department of Veterinary Anatomy, Physiology and Pathology, Institute of Infection, Veterinary and Ecological Sciences, University of Liverpool, Liverpool, UK | [3]North Downs Specialist Referrals, Bletchingley, UK | [4]Wear Referrals Veterinary Hospital, Bradbury, Stockton-on-tees, UK | [5]School of Veterinary Sciences, University of Bristol, Bristol, UK | [6]Section of Small Animal Clinical Studies, University College Dublin School of Veterinary Medicine, Dublin, Ireland

**Correspondence:** Tyler Morrison (tyler.morrison@ed.ac.uk)

**Received:** 28 May 2024 | **Revised:** 6 August 2025 | **Accepted:** 14 August 2025

**Funding:** The authors received no specific funding for this work.

**Keywords:** autoimmune | canine | diagnostic imaging | IMHA | screening

## ABSTRACT

**Background:** Potential triggers of immune-mediated hemolytic anemia (IMHA) are often identified, but their frequency and the benefit of extensive screening for these to individual dogs is uncertain.

**Objective:** To assess the frequency of non-associative IMHA in dogs undergoing screening in Britain and Ireland and identify where specific tests could be beneficial.

**Animals:** Two hundred twenty-two client-owned dogs with IMHA.

**Methods:** Multicenter, retrospective cohort study of dogs with IMHA. Medical records and blood, urine, imaging, and pathology reports were reviewed. Cases were assessed for associative IMHA, and multivariable analysis was performed to define those.

**Results:** Associative IMHA was present in 73/222 (33%) dogs. Diagnoses included toxic (24/222, 11%); infectious (17/222, 8%); neoplastic (16/222, 7%) and non-infectious inflammatory (13/222, 6%) conditions. A further 102 dogs (46%) had a finding most likely incidental, with no pertinent findings in 47/222 (21%) dogs. Associative IMHA was more likely as patients aged (odds ratio 1.108 per year, 95% CI: 1.012–1.218, $p = 0.03$).

**Conclusions and Clinical Importance:** The benefit of extensive diagnostic screening and implication of detected abnormalities remains uncertain for individual dogs with IMHA in Britain and Ireland. However, older dogs are more likely to have pertinent findings after a diagnosis of IMHA.

**Abbreviations:** ACVIM, American College of Veterinary Internal Medicine; BSAVA, British Small Animal Veterinary Association; CT, computed tomography; FNA, fine needle aspirate; HCT, hematocrit; IMHA, immune-mediated hemolytic anemia; IQR, inter-quartile range; PARR, polymerase chain reaction for antigen receptor rearrangement; PCR, polymerase chain reaction; PLI, pancreatic lipase immunoreactivity; PT, prothrombin time; aPPT, activated partial thromboplastin time; RBC, red blood cell; UK, United Kingdom; VERC, veterinary ethical review committee.

This is an open access article under the terms of the Creative Commons Attribution-NonCommercial License, which permits use, distribution and reproduction in any medium, provided the original work is properly cited and is not used for commercial purposes.

© 2025 The Author(s). *Journal of Veterinary Internal Medicine* published by Wiley Periodicals LLC on behalf of American College of Veterinary Internal Medicine.

## 1 | Introduction

Immune-mediated hemolytic anemia (IMHA) is frequently encountered in dogs and carries a high case fatality rate and cost of hospitalization [1]. The mechanisms by which an inappropriate immunological response to host erythrocytes develops are uncertain. Those proposed include molecular mimicry by infectious agents, introduction of haptens, or epitope unmasking leading to subsequent loss of immunological tolerance [2–4]. Specific concurrent diseases have been associated with the development of IMHA in dogs and have been recently reviewed [2]. This includes varying strengths of evidence for secondary IMHA for specific infectious diseases (*Babesia* spp. [5, 6], *Anaplasma* spp., or *Leishmania* spp. [7, 8]), antibiotic administration [9]; recent vaccination [10]; neoplasia [11] and sterile inflammatory diseases including pancreatitis [12].

A limitation of veterinary studies is the absence of direct evidence demonstrating causality for many triggers of IMHA in dogs [2, 9]. Specific terminology has therefore emerged to categorize findings after screening [2]. Cases without concurrent findings are deemed non-associative and include both primary and cryptogenic IMHA. It is generally accepted that around two thirds of dogs have non-associative IMHA [13], but this might vary geographically. Associative IMHA, where any finding is identified contemporaneously, could be secondary to a putative trigger and, as such, dogs are subjected to screening to identify these. But whether such findings are co-incidental or driving secondary IMHA can be unclear.

Identifying dogs most likely to benefit from screening would be advantageous as secondary IMHA might benefit from specific treatment. Furthermore, co-incidental findings could assist decision making by informing prognosis, or additional necessary steps for successful management. However, investigations can be costly and potentially invasive. Few studies have attempted to define the benefit of screening dogs, particularly in the UK. One recent study supported the notion that 1/3 of dogs might have an associative finding, although this was based predominantly on imaging findings [12]. Another demonstrated associative IMHA in 21% of dogs but did not focus on the diagnostics leading to those [14]. Studies performed globally have been largely limited to imaging findings [15] or do not report all associative cases that could benefit from screening [16], and ultimately do not reflect the infectious disease landscape of the UK and Ireland. Further study is therefore required to support decision making in IMHA, particularly in a global climate where costs are under scrutiny and there exists a need for transparent veterinary care.

We therefore aimed to assess the frequency of non-associative disease in dogs undergoing screening in referral practice, after diagnosis of IMHA, in the UK and Republic of Ireland. Furthermore, we sought to assess where screening had the potential to inform case management after identification of at least one notable abnormality. We hypothesized that many dogs with IMHA would have coincidental or associative findings, but that extensive screening would rarely lead to a change in management.

## 2 | Materials and Methods

### 2.1 | Study Design

Medical records from five referral hospitals within the UK and Republic of Ireland were electronically searched for dogs with a final diagnosis of hemolytic anemia, IMHA, primary IMHA, or secondary IMHA between 2018 and 2022. Dogs with anemia (hematocrit [HCT] < 35%) were diagnosed with IMHA as per consensus criteria; confidence of diagnosis retrospectively assigned, and included if confidence was 'suspicious' or greater (S1A) [2]. Signalment and travel history, a hematology with smear review, biochemistry, and sufficient testing to define the confidence of IMHA diagnosis had to be available for inclusion. Screening for associative findings by thoracic and abdominal imaging was required for all cases unless an associative IMHA had already been identified.

Additional historical data was collected where disclosed, including recent vaccination or estrus within the month before diagnosis. Medications administered within the preceding month were recorded and categorized as either prophylactic or chronic. Additionally, medications administered were noted to 'recent' where there was a novel indication or 'contemporaneous' where it could be reasonably concluded that clinical signs of IMHA were already present (S1A). Physical examination findings were only noted where documented by the primary clinician as leading to a change in the diagnostic or treatment plan or had the potential to have severe consequences (e.g., a new heart murmur).

Thoracic imaging included either a thoracic computed tomography (CT) or orthogonal radiographs, and abdominal imaging either an abdominal CT or ultrasonography (US) at the primary clinician's discretion. Additional imaging, including echocardiography or head CT, tests such as urine analysis/culture, infectious disease screening, or tests of pancreatic injury were undertaken on a case-by-case basis. More invasive sampling, including fine needle aspirates (FNA), tissue biopsy, or bone marrow cytology/histopathology were similarly discretional. Results of these were categorized as diagnostic; non-specific; or non-diagnostic (S1A).

Cases of IMHA were classified as associative or non-associative, with the latter being assessed for coincidental findings. IMHA was considered non-associative (primary or cryptogenic) when there were no relevant historical or investigative findings. Associative IMHA was considered present where a specific finding/diagnosis was identified that could reasonably precipitate IMHA or where this could not be excluded (neoplasia, infectious disease, sterile inflammatory disease). Classification was supported by integrating published systematic review [2], clinical judgment (principal authors) as well as follow-up data (where available) or resolution of IMHA after treatment of a primary condition (where available). Follow-up data were reviewed and classified as long-term (4 months or greater), short-term (less than 4 months, responding to treatment and alive at last point of contact), died during hospitalization or shortly after discharge (less than 4 months) or not available. For analysis, only the most pertinent finding among comorbidities was considered for

associative IMHA, prioritizing in order neoplasia, infectious disease, inflammatory disease, and others based on the authors' clinical judgment. Finally, a dog with non-associative IMHA was considered to have a coincidental finding where an abnormality was found but was likely an age-related natural finding, or a consequence of IMHA such as a thrombus. Analysis of contemporaneous findings was based on authors' clinical judgment, supported by published systematic review. Bacteriuria was considered subclinical where a positive urine culture was obtained in the absence of clinical signs of pyuria, and therefore non-associative. Pyuria, with or without a positive culture, was considered an associative finding regardless of clinical signs given a possible inflammatory focus.

### 2.2 | Data Analysis

Continuous data were assessed for normality and presented as mean ± standard deviation where normally distributed, or range for age. If not normally distributed, data were presented as median, range, and interquartile range. Categorical data were reported as frequencies. Tests were performed in GraphPad Prism version 10.0 for Mac, GraphPad Software. Additional data analysis and manipulation were performed in Microsoft Excel version 16.89.1 for Mac, Microsoft Software. Logistic regression analysis was used to determine the effects of the 16 variables (age, sex, murmur, PCV/HCT, neutrophilia, left shift, thrombocytopenia, spherocytes, ghost cells, agglutination, Coombs' test, hemoglobinemia, hemoglobinuria, hyperbilirubinemia, hyperglobulinemia and the confidence of IMHA diagnosis) on a final classification of associative IMHA. Variables were initially evaluated by univariable logistic regression analysis, and all those with a $p < 0.2$ were carried into the multivariable logistic regression model. A $p < 0.05$ was considered significant in the multivariable analysis. Data were presented as odds ratio (OR), 95% confidence interval (CI), $p$ value. Final logistic regression model fit was evaluated using Nagelkerke's $R^2$. The statistical analysis was performed using the *glm* function of the statistical language R (version 4.3.0, R Foundation for Statistical Computing, Austria).

## 3 | Results

### 3.1 | Study Cohort

Two-hundred seventy-two cases from five centers had a diagnosis of IMHA recorded. Of these, 222 were included (Figure 1) and comprised 119 females (94 neutered, 25 entire) and 103 males (60 neutered, 42 entire and 1 unknown). The mean age at presentation was 6.93 (range 0.18–15.3 years). Spaniel breeds were most common (57 cases, 25.7%), with other breeds in smaller numbers (Table S1). Cases originated from Scotland (center A, $n = 70$, 32%), Republic of Ireland (center B, $n = 53$, 24%) and England (center C, Southwest, $n = 43$, 19%; center D, Northeast, $n = 29$, 13% and center E, Southeast, $n = 27$, 12%). All had a hematology performed, with a median HCT at presentation of 15.8% (3%–32%, IQR ±7.0%). Confidence of IMHA [2] was 'diagnostic' in 123, 'supportive' in 79, and 'suspicious' in 20 dogs (Table 1, and summarized in S1B).

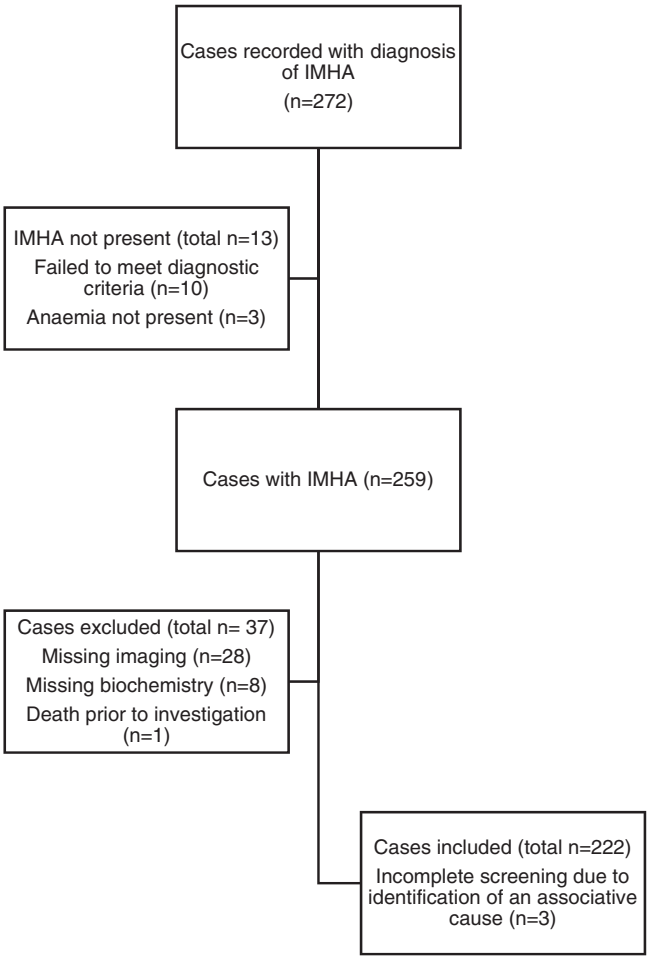


**FIGURE 1** | Cases with IMHA included for analysis.

### 3.2 | Historical and Physical Examination Findings

Two-hundred eighteen dogs originated from the UK or Ireland and 4 from another country (Cyprus, Brazil, Hungary and Poland). Seven had traveled to European countries. Eleven dogs had vaccination, 7 estrus, and 0 envenomation within the preceding month. Fifty-nine dogs received medications in the preceding month, including 19 on chronic medication (two receiving biologics lokivetmab, 1; bedinvetmab, 1), 11 received parasite prophylaxis; and 11 were given medications contemporaneous to clinical signs likely caused by IMHA. Eighteen dogs received novel medication, including three treated with immunosuppressives for suspected IMHA. The remaining 15 dogs received antibiotics (beta-lactam, 11; fluroquinolone, 1; tetracycline, 1; lincosamide, 1) or analgesia (non-steroidal anti-inflammatory drug, 1).

Physical examination findings recorded included vaginal discharge (2); skin mass (suspected arthropod bite, 1); mammary nodule (1); wounds after a badger fight (1), mucopurulent nasal discharge (1), and lesions consistent with onychomycosis (1). A novel heart murmur was noted in 77 dogs (34.6%).

**TABLE 1** | Diagnostic certainty of cases presented for investigation and management of IMHA as per ACVIM consensus [2].

| | | Diagnostic certainty | | | | | |
|---|---|---|---|---|---|---|---|
| | | Diagnostic | | Supportive | | Suspicious | |
| **Hemolysis** | | **Present** | **Absent** | **Present** | **Absent** | **Present** | **Absent** |
| Signs of IM destruction | 3 | 27 (12%) | | | 7 (3%) | | |
| | 2 | 96 (43%) | | | 40 (18%) | | |
| | 1 | | | 32 (14%) | | | 20 (9%) |
| | | 123 (55%) | | 79 (36%) | | 20 (9%) | |

*Note:* Number of cases *n* (% of 222) with signs of immune-mediated (IM) destruction, with or without hemolysis as defined in the methods. Bold values indicates total of the column.

### 3.3 | Investigations

Diagnostic tests performed are summarized in Table 2. Hematology and smear analysis identified thrombocytopenia (below the lower limit of the laboratory reference interval, confirmed by smear analysis) in 42 dogs (18.9%). Pertinent biochemistry findings included hyperbilirubinemia (109/222, 49%), raised alanine aminotransferase activity in 33 dogs (14.9%), one hypoglycemic dog, 4 (1.8%) with creatinine above the upper reference interval, and 22 (9.9%) with elevated urea. Hypoalbuminemia was identified in 42 dogs (18.9%), hypoglobulinaemia in 3 (1.35%) and hyperglobulinemia in 25 dogs (11.3%). Ionized calcium was measured in 103 dogs (46.4%), and within the reference interval for all. Urine analysis was performed in 159 dogs (71.6%) with 77 urine cultures yielding a positive culture in 8 cases, of which 1 had an active sediment (without clinical signs recorded). Fecal analysis was performed in 6 dogs with a negative parasitology and culture in 5 and 1 dog, respectively. Fecal occult blood was tested in 1 dog and was negative. Coagulation was assessed (prothrombin time (PT)/activated partial thromboplastin time (aPTT) or viscoelastic test) in 105 cases (47.3%). Delayed PT/aPTT was present in 15/105. Eight had viscoelastic testing, of which one was hypercoagulable and the rest within acceptable limits.

A point of care vector-borne infection test (4DX SNAP, IDEXX) was performed in 148/222 (66.7%) and was negative in all but 1 imported (Cyprus) dog (positive for *Ehrlichia* spp.). Blood *Ehrlichia* spp. PCR was negative, but a concurrent low titer for Leishmania antibodies was present. One dog out of 69 tested (1/69, 1.4%) positive for *Angiostrongylus vasorum* (AngioDetect, IDEXX). Additional infectious disease testing is summarized in Table 2 and yielded negative results. Of the dogs that had spent time abroad, 10/11 had a 4DX SNAP (IDEXX) and 5/11 had Babesia PCR performed. All 4 dogs born outside the UK or Ireland had a 4DX SNAP (IDEXX) and 3/4 a Babesia PCR.

Additional specific testing in 22/222 dogs (9.9%) included serological assessment for pancreatitis with 14 canine specific pancreatic lipase SNAP (IDEXX) and 8 quantitative canine specific pancreatic lipase (spec cPLI, IDEXX) tests performed. These resulted in 3 positive SNAP tests and 2 spec cPLI results considered consistent with pancreatitis (> 400 μg/L) (mean 303 ± 316.2 μg/L).

### 3.4 | Imaging and Specific Sampling

Thoracic imaging (CT, $n = 12$ or radiograph, $n = 208$) identified at least 1 abnormality in 45 dogs (20.2%) the findings of which are summarized in Table 3. A total of 56 abnormalities were reported with 1 in 35 dogs, 2 in 9 dogs, and 3 in 1 dog. Most common were identification of abnormal lung patterns (18/220, 8.1%), radiographic cardiomegaly (10/220, 4.5%), cavitary effusion (10/220, 4.5%) and lymphadenomegaly (7/220, 3.2%). Additionally, 2 dogs were suspected to have an esophageal mass; 1 had suspected multifocal neoplasia within the thoracic cavity; and 1 had an intrathoracic gas lesion of uncertain importance. Imaging of the thorax identified lesions in the included extra-thoracic structures in seven dogs. No thoracic lymph nodes were sampled. One dog with a suspected esophageal mass had endoscopy with no lesion found and died after discharge. The other had no sampling but entered long-term remission. The dog with multifocal skeletal hypoattenuating lesions had no specific sampling of these and was discharged with short follow-up. The dog with a subcutaneous mass identified did not have FNA performed and entered long-term remission although required ongoing immunosuppression. Finally, 2 dogs did not have thoracic imaging as a putative trigger had been identified by the primary clinician (severe onychomycosis (1), pyometra (1)).

Abdominal imaging (CT, $n = 7$ or US, $n = 214$) identified at least 1 abnormality in 155 dogs (69.8%) the findings of which are summarized in Table 4. One dog did not have abdominal imaging, as thoracic imaging raised concern for neoplasia and euthanasia was performed. A total of 341 abnormalities were reported, with 1 in 51, 2 in 52, 3 in 33, 4 in 11, 5 in 5, and 6 in 3 dogs. The most common findings were non-specific and included hepatic (46/221, 20.8%) and splenic (41/221, 18.6%) enlargement; splenic (39/221, 17.6%) and hepatic (36/221, 16.2%) parenchymal changes; biliary sedimentation (21/221, 9.5%) or gall bladder wall oedema (14/221, 6.3%); peritoneal free fluid (26/221, 11.8%) and lymphadenopathy (18/221, 8.1%). One dog with a nodular splenopathy was suspected to have round cell neoplasia.

Abdominal imaging identified specific lesions including 9 (9/221, 4.1%) mass lesions (adrenal, 6; splenic, 1; hepatic, 1; prostatic, 1 (benign prioritized)); 6 with uterine fluid, of which 2 were suspected to have pyometra; 3 suspicious for cholangiohepatitis (1 emphysematous); and 2 with features of acute nephropathy

**TABLE 2** | Diagnostic tests performed in 222 dogs diagnosed with IMHA.

| Diagnostic test | Dogs in which test was performed |
|---|---|
| CBC and blood smear | 222 (100%) |
| Biochemistry | 222 (100%) |
| Ionized calcium | 103 (46.4%) |
| Coagulation testing | 105 (47.3%) |
| PT/aPTT | 97 (43.7%) |
| Viscoelastic testing | 8 (3.6%) |
| IMHA diagnostics | |
| Saline dispersion | 195 (87.8%) |
| Coombs test | 109 (49.1%) |
| Both Coombs and saline dispersion | 87 (39.2%) |
| Pancreatic | |
| SNAP cPL | 14 (6.3%) |
| Spec cPL | 8 (3.6%) |
| Urine | |
| Urine analysis | 159 (71.6%) |
| Urine culture | 77 (34.7%) |
| Fecal | |
| Fecal parasitology and giardia | 5 (2.3%) |
| Fecal culture | 1 (0.5%) |
| Fecal occult blood | 1 (0.5%) |
| Parvovirus POC | 1 (0.5%) |
| Infectious Disease Testing | |
| 4DX SNAP | 148 (66.7%) |
| Serology | |
| *Angiostrongylus vasorum* | 69 (31.1%) |
| Leptospira MAT | 2 (0.9%) |
| Leishmania | 2 (0.9%) |
| *Bartonella* Spp. | 1 (0.5%) |
| *Brucella canis* | 1 (0.5%) |
| Toxoplasma/neospora | 1 (0.5%) |
| PCR (blood/urine) | |
| *Babesia* spp. | 21 (9.5%) |
| *Leptospira* spp. | 5 (2.3%) |
| *Haemotropic mycoplasmae* spp. | 5 (2.3%) |
| Rickettsial diseases | 3 (1.4%) |
| Blood culture | 1 (0.5%) |

Abbreviations: 4DX SNAP, 4DX™ point of care SNAP test for vector borne disease, IDEXX; aPTT, activated partial thromboplastin time; CBC, complete blood count; MAT, microagglutination titer; POC, point of care; PT, prothrombin time; SNAP cPL, point of care canine pancreatic lipase, IDEXX; spec cPL, canine specific pancreatic lipase, IDEXX.

**TABLE 3** | Thoracic imaging findings from 220 dogs with IMHA.

| | ***n*** | **(TX/CT)** |
|---|---|---|
| No abnormal findings | 177 | (174/3) |
| Lung pattern | 18 | |
| Alveolar | | (7/1) |
| Interstitial | | (4/1) |
| Bronchial | | (2/-) |
| Osteomata or mineralization | | (2/1) |
| Cardiac | 10 | |
| Radiographic cardiomegaly | | (10/-) |
| Cavitary | 10 | |
| Pleural effusion | | (9/-) |
| Bicavitary effusion | | (1/-) |
| Lymphadenomegaly | 7 | (4/3) |
| Mass lesion | 3 | |
| Esophageal | | (-/2) |
| Multifocal (neoplastic) | | (1/-) |
| Miscellaneous | 1 | |
| Intrathoracic gas lesion | | (1/-) |
| Extrathoracic findings | 7 | |
| Hepatomegaly | | (2/-) |
| Foreign body | | (2/-) |
| Intraabdominal mass | | (1/-) |
| Skeletal hypoattenuating lesions | | (-/1) |
| Subcutaneous mass | | (-/1) |

*Note:* Intra-thoracic and extra-thoracic findings (*n*) identified after thoracic radiographs (TX) or computed tomography (CT). Bold values indicates total of the group.

(medullary rim sign, 1; pyelectasia, 1). Additional notable findings included those consistent with degenerative renal disease (7/221, 3.2%), cholelith (3/221, 1.4%), prostatomegaly (3/221, 1.4%), gall bladder mucocele (2/221, 0.9%), urolithiasis (1/221, 0.5%) and non-obstructive gastrointestinal foreign material (bone) (1/221, 0.5%). Finally, the included extra-abdominal areas during investigations allowed identification of a femoral (suspected plasmacytoma) and subcutaneous mass (not sampled due to thrombocytopenia).

Abdominal imaging also identified overt thromboembolic disease or suspected a hypercoagulable state in 13 dogs (13/221, 5.9%). This included infarcts (splenic, 5; renal, 2), thrombi (aortic, 1; femoral, 1; portal-venous, 1) and spontaneous echo contrast (1).

At least 1 FNA was performed in 49 cases (49/222, 22%) with a total of 72 samples. This included 1 FNA from 30, 2 from 16, 3 from 2, and 4 from 1 dog (Table 5). Specific lesions that were sampled included a gastrointestinal, mammary, and subcutaneous mass,

**TABLE 4** | Abdominal imaging findings from 222 dogs with IMHA.

| | | Modality | | Sampling | |
|---|---|---|---|---|---|
| | ***n*** | **(US/CT)** | ***n*** | **FNA** | **Histo or centesis** |
| Organomegaly | 93 | | 23 | | |
| Hepatic | | (46/-) | | 11 | |
| Splenic | | (39/2) | | 12 | |
| Adrenomegaly | | (2/1) | | — | |
| Prostatomegaly | | (3/-) | | — | |
| Biliary | 45 | | 3 | | |
| Sediment | | (21/-) | | | 2 |
| Wall oedema | | (14/-) | | | — |
| Cholelith | | (3/-) | | | — |
| Wall thickening (unspecified) | | (2/-) | | | — |
| Mucocoele | | (1/1) | | | — |
| Cholangiohepatitis (suspected) | | (2/-) | | | — |
| Emphysematous cholangiohepatitis | | (1/-) | | | 1 |
| Splenic parenchymal | 39 | | 13 | | |
| Nodular | | (20/-) | | 7 | |
| Heterogenous | | (16/-) | | 4 | |
| Hyperechoic | | (2/-) | | 1 | |
| Hypoechoic | | (1/-) | | 1 | |
| Hepatic parenchymal | 36 | | 10 | | |
| Nodular | | (16/1) | | 5 | |
| Heterogenous | | (8/-) | | 3 | |
| Hyperechoic | | (7/-) | | 1 | |
| Hypoechoic | | (3/-) | | 1 | |
| Cyst | | (1/-) | | — | |
| Peritoneal | 26 | | 7 | | |
| Free fluid | | (25/1) | | | 7 |
| Lymphadenopathy | 18 | (17/1) | 6 | 6 | |
| Pancreas | 16 | | — | | |
| Pancreatitis (suspected) | | (15/1) | | — | |
| Vascular | 13 | | — | | |
| Splenic Infarct | | (5/1) | | — | |
| Renal Infarct | | (2/1) | | — | |
| Thrombus (aortic/femoral) | | (1/1) | | — | |
| Thrombus (venous) | | (1/-) | | — | |
| Spontaneous echo contrast | | (1/-) | | — | |
| Urinary | 12 | | 8 | | |
| Sediment | | (11/-) | | | 7 |

(Continues)

**TABLE 4** | (Continued)

| | | Modality | | Sampling | |
|---|---|---|---|---|---|
| | ***n*** | **(US/CT)** | ***n*** | **FNA** | **Histo or centesis** |
| Urolithiasis | | (1/-) | | | 1* |
| Renal | 12 | | — | | |
| Degenerative change | | (6/1) | | — | |
| Cyst | | (1/-) | | — | |
| Loss of CM definition | | (1/-) | | — | |
| Medullary rim sign (acute nephropathy) | | (1/-) | | — | |
| Mineralization | | (1/-) | | — | |
| Pyelectasia | | (1/-) | | — | |
| Gastrointestinal | 12 | | 1 | | |
| Gastric wall thickening | | (4/-) | | 1 | |
| Intestinal wall thickening | | (2/-) | | — | |
| Luminal distension | | (2/-) | | — | |
| Mucosal striations | | (2/-) | | — | |
| Small intestine corrugation | | (1/-) | | — | |
| Foreign body | | (1/-) | | — | |
| Mass lesion | 9 | | 2 | | |
| Adrenal | | (6/-) | | 1 | |
| Splenic | | (1/-) | | -[a] | |
| Hepatic | | (1/-) | | — | 1 |
| Prostate (benign prioritized) | | (1/-) | | — | |
| Reproductive | 6 | | — | | |
| Cystic endometrial hyperplasia | | (5/-) | | — | |
| Uterine fluid distension | | (1/-) | | — | |
| Miscellanous | 2 | | — | | |
| Bilateral adrenal atrophy | | (1/-) | | — | |
| Unilateral adrenal atrophy | | (1/-) | | — | |
| Extra-abdominal | 2 | | — | | |
| Suspected neoplasia (femur) | | (0/1) | | — | |
| Subcutaneous mass (cavitated) | | (1/-) | | -[a] | |

*Note:* Intra-abdominal and extra-abdominal findings (*n*) reported during abdominal ultrasonography (US) or computed tomography (CT). Sampling was performed after identification of specific abnormalities in some cases by fine needle aspirate (FNA), biopsy or histopathology (histo) and needle fluid sampling (centesis). Bold values indicates total of the group.
[a]Same dog.
*stone analysis.

each of which yielded a non-diagnostic sample. An FNA of one adrenal mass was considered diagnostic but did not raise concern for malignant neoplasia. Of the remaining samples taken, 27/27 spleen, 16/24 hepatobiliary, and 7/8 lymph node yielded non-specific results and, importantly, no direct evidence of neoplasia. This included one dog with splenic parenchymal changes on US suspicious for round cell neoplasia having aspirates of liver, spleen, and lymph nodes. Four dogs were found to have inflammatory cells within their liver, although it was otherwise non-specific. One dog undergoing cholecystocentesis (1/3) had bactibilia without evidence of neutrophilic inflammation. One sample from one dog with macrophagic lymphadenitis had a positive PCR for *Actinomyces* spp. (negative for mycobacteria).

In total, 26 (11.7%) dogs had cavitary effusion. Four had mild effusion in both the thoracic and abdominal cavities and had severe bicavitary effusion which was not sampled before death. Of the remaining 5 dogs with pleural effusion, 2 were mild, 1 was moderate,

**TABLE 5** | Cytology findings of dogs diagnosed with IMHA.

| | *n* |
|---|---|
| Spleen (FNA) | 27 |
| Extramedullary hematopoiesis | 23 |
| Erythrophagocytosis | 2 |
| Cytologically unremarkable | 1 |
| Lymphoid hyperplasia | 1 |
| Hepatobiliary (FNA) | 24 |
| Extramedullary hematopoiesis | 12 |
| Inflammation (neutrophilic) | 3 |
| Vacuolar hepatopathy or cholestasis | 2 |
| Lymphoid hyperplasia | 1 |
| Cytologically unremarkable | 1 |
| Inflammation (mixed) | 1 |
| Choleocystocentesis | |
| Cytologically unremarkable | 3 |
| (Bacterial culture negative) | (3) |
| Bactibilia | 1 |
| Cavitary fluid | 9 |
| Abdominocentesis—protein rich transudate | 8 |
| Pleurocentesis—transudate | 1 |
| Lymph Nodes (FNA) | 8 |
| Reactive hyperplasia | 6 |
| Cytologically unremarkable | 1 |
| Inflammation (macrophagic) | 1 |
| (PCR for infectious disease—Actinomycosis) | (1) |
| Specific Lesions (FNA) | 4 |
| Mass (subcutaneous)—non-diagnostic | 1 |
| Mass (adrenal)—non neoplastic | 1 |
| Mass (mammary)—non-neoplastic | 1 |
| Mass (gastrointestinal)—non diagnostic | 1 |
| Specific lesions (histopathology) | 3 |
| Mass (liver)—nodular regeneration | 1 |
| Wall thickening (stomach) - within normal limits | 1 |
| Skin, histopathology - eosinophilic, mastocytic inflammation | 1 |

Abbreviations: FNA, fine needle aspirate; PCR, polymerase chain reaction. Bold values indicates total of the group.

and 2 were not quantified. Abdominal effusion without pleural effusion was noted in 21 dogs (12 mild, 1 moderate, 1 severe and 7 unquantified). Effusions were sampled in 1 dog with unquantified pleural effusion (transudate), and in 8 dogs with abdominal effusion (mild (1), moderate (1), severe (1) and in unquantified effusions (6)) of which all were a protein-rich transudate.

Further specific investigations were undertaken on an individual basis (S1C) and led to a suspected diagnosis of endocarditis ($n=1$), pituitary mass ($n=1$) and arthropod bite ($n=1$). Finally, 8 dogs had bone marrow sampling (8/222, 3.6%) with 2 demonstrating an appropriate regenerative response to peripheral hemolysis and 6 showing erythropoietic maturation arrest (suspected precursor targeted IMHA, PIMA). A further 2 dogs had a poorly regenerative anemia, but a bone marrow sample was not acquired.

### 3.5 | Outcomes After Investigation

Follow up data were available for 208 dogs. Forty-five (45/208, 22%) did not survive to discharge (S1D), and 8 (4%) died shortly after an initial response. One hundred five dogs (105/208, 50%) had long-term, and 50 dogs (50/208, 24%) had short-term follow up.

Findings were integrated to define cases with associative IMHA (Table 6). Of 222 cases, 47 (21%) fulfilled criteria to be classed non-associative, whilst an abnormality was present in 175 (79%). Of these, 73 (33%) were considered to have associative IMHA, where a potential trigger could not be excluded. One hundred two (46%) had a finding which was on balance considered to be incidental or consequential. For cases with associative IMHA, 24 were considered toxic or drug related; 17 infectious; 16 neoplastic; 13 inflammatory; and 3 were unclassified (Table 6). Of the incidental findings, most common were hepatosplenomegaly (31) and nodular or other parenchymal changes (31). Of these, 39 had long follow up (14 FNA), 10 had short follow up (4 FNA), 12 died (1 FNA), and 1 had no follow up. Lymphadenopathy was present in 8 dogs, 2 of which had needle aspiration. Other findings are summarized (Table 6). Although likely coincidental, at least 20 of these findings were still pertinent (effusions (10); urolithiasis/sedimenturia (3); radiographic cardiomegaly (2); and 1 each of bone gastrointestinal foreign body, gall bladder mucocele, cholecystolithiasis, and splenic infarct) (Table 6). Considering 73 dogs with associative IMHA, 27 (12%) diagnoses were identified during anamnesis or physical exam, and 46 (21%) during investigation (imaging, 40; blood test, 3; urinalysis).

To assess features predictive of associative IMHA, univariable analysis was performed (Table S2). This identified age, presence of a left shift, and agglutination, which were carried forward to the multivariable model (Table 7). Only age was positively associated with the likelihood of an associative finding (OR 1.108 for each increase in year, 95% CI: 1.012–1.218, $p=0.03$). A test of the full model against a constant only model was significant, indicating that the predictors distinguish between IMHA cases with or without associative IMHA ($\chi^2=9.3$, $p=0.026$). The Nagelkerke's $R^2$ was 0.060, indicating a weak relationship between prediction and grouping.

## 4 | Discussion

An important challenge for clinicians is assigning importance to findings identified alongside IMHA, particularly since many dogs are middle-aged with co-morbidities. Our study reviews the screening performed in dogs with IMHA in the United Kingdom and Republic of Ireland. 175 (79%) had at least one abnormality

**TABLE 6** | Final classification of cases with IMHA, and the follow up period available.

| | | | | Follow up | | | |
|---|---|---|---|---|---|---|---|
| | ***n*** | | **%** | **Deceased < 4mo** | **Short follow up** | **Long follow up** | **No follow up** |
| Non-associative IMHA | 47 | | 21% | | | | |
| Primary or cryptogenic | | 47 | | 13 | 14 | 15 | 5 |
| Associative IMHA | 73 | | 33% | | | | |
| Toxic/drug | 24 | | 11% | | | | |
| Recent vaccination | | *8* | 4% | | *3* | *5* | |
| Beta lactam antibiotic | | *6* | 3% | *1* | *2* | *3* | |
| Recent estrus | | *5* | 2% | | *3* | *2* | |
| Biologic administration | | *2* | 1% | *1* | | *1* | |
| Gastrointestinal foreign body (metallic) | | *1* | | | | *1* | |
| Lincosamide | | *1* | | | | *1* | |
| Recent vaccination and estrus | | *1* | | *1* | | | |
| Infectious | 17 | | 8% | | | | |
| Pathological lung pattern | | *6* | 3% | *3* | | *3* | |
| Cholangitis | | *2* | 1% | | | *2* | |
| Pyometra | | *2* | 1% | | *1* | *1* | |
| Suspected aspiration pneumonia | | *1* | | | | | *1* |
| Actinomycosis | | *1* | | *1* | | | |
| Angiostrongyliasis | | *1* | | | | *1* | |
| Ehrlichiosis | | *1* | | | *1* | | |
| Endocarditis | | *1* | | *1* | | | |
| Pyuria | | *1* | | | | | *1* |
| Onychomycosis | | *1* | | *1* | | | |
| Neoplastic | 16 | | 7% | | | | |
| Adrenal | | *6* | 3% | *1* | *1* | *3* | *1* |
| Subcutaneous mass | | *2* | 1% | | | *2* | |
| Liver mass | | *1* | | | | *1* | |
| Mammary mass | | *1* | | *1* | | | |
| Leukemia (myeloid) | | *1* | | *1* | | | |
| Plasmacytoma (suspected) | | *1* | | | *1* | | |
| Round cell neoplasia (splenic, suspected) | | *1* | | | | *1* | |
| Pituitary mass | | *1* | | | *1* | | |
| Thoracic neoplasia | | *1* | | *1* | | | |

(Continues)

**TABLE 6** | (Continued)

| | | | | Follow up | | | |
|---|---|---|---|---|---|---|---|
| | ***n*** | **%** | | **Deceased < 4mo** | **Short follow up** | **Long follow up** | **No follow up** |
| Splenic mass | *1* | | | | *1* | | |
| Inflammatory | 13 | | 6% | | | | |
| Pancreatitis (suspected) | *12* | | 5% | *5* | *4* | *3* | |
| Suspected arthropod bite | *1* | | | | | *1* | |
| Unclassified | 3 | | 1% | | | | |
| Prostatomegaly | *1* | | | | *1* | | |
| Badger bite, antibiotic administration | *1* | | | *1* | | | |
| Multifocal skeletal hypoattenuating lesions | *1* | | | | *1* | | |
| Likely incidental finding | 102 | 46% | | | | | |
| Hepatosplenomegaly | *31* | | 14% | 5 | 7 | 18 | 1 |
| Hepatosplenic nodular/parenchymal change | *31* | | 14% | *7* | *3* | *21* | |
| Lymphadenopathy | *8* | | 4% | | *2* | *3* | *3* |
| Protein rich transudate[a] | 5 | | 2% | 3 | | 2 | |
| Uncharacterised effusion[b] | 5 | | 2% | 1 | 1 | 3 | |
| Gall bladder wall change/edema | 4 | | 2% | *1* | *1* | *1* | *1* |
| Urolithiasis (non-obstructive)/sedimenturia | 3 | | 1% | *2* | | *1* | |
| Radiographic cardiomegaly | *2* | | 1% | *1* | | *1* | |
| Gastrointestinal foreign body (bone) | *1* | | | | | *1* | |
| Gall bladder mucocele | *1* | | | | | *1* | |
| Cholecystolithiasis (non-obstructive)/sediment | 1 | | | | | *1* | |
| Non-steroidal medication | *1* | | | | | *1* | |
| Others[c] | *9* | | 4% | *1* | *2* | *5* | *1* |

*Note:* Bold values indicates optically distinguish the major three categories. Italic values indicates the final diagnosis under the headings.
[a](Pleural (1), abdominal (4)).
[b](Pleural (1), abdominal (3), bicavitary (1)).
[c]Focal GI thickening (4), elevated alanine aminotransferase (2), hepatic cyst (1), possible esophageal mass with long-term follow-up (1), splenic infarct (1).

**TABLE 7** | Multivariable regression analysis results.

| Variable | Type of variable | *p* | Odds ratio (95% confidence intervals) |
|---|---|---|---|
| Age (per year) | Continuous | 0.030 | 1.108 (1.012–1.218) |
| Left shift | Categorical | 0.110 | 0.621 (0.343–1.124) |
| Agglutination | Categorical | 0.158 | 1.671 (0.915–3.053) |

*Note:* Variables significant ($p < 0.2$) in a univariable analysis were included in the final model as follows.

identified; of these, 73 (33%) ultimately had associative IMHA after critical review of clinical findings.

Veterinary medicine is lacking clear evidence for what may trigger the development of secondary IMHA [2]. Since such triggers do appear to exist, individual cases often undergo investigation to identify them. Yet, clear attribution of cause and effect is often challenging. Therefore, a distinction is made between these associative findings and true secondary IMHA. This is further complicated by the relatively common occurrence of incidental findings in any older patient undergoing imaging. We sought to retrospectively disentangle the presence of associative IMHA, which included possible secondary IMHA, and incidental findings with a view to optimizing diagnostic stewardship.

Approximately 1/3 of cases in this study fulfilled criteria for associative IMHA, which is broadly in line with the literature; although derivation of these values is not always clear or applicable across geographical populations. It is generally stated that around 75% of cases of IMHA are primary; although the origin of this number is unclear. An often-cited, small, historical study noted an associative finding in 13/29 (45%) cases of IMHA [13]. A more recent UK study of dogs with IMHA defined 32% (16/50) as associative, and a study from Australia, that shares a similar low vector-born infectious disease pressure, classified 13% of dogs (10/78) as having associative IMHA [16]. In the latter study, the authors were able to classify based on the presence of a putative trigger and remission after treatment; but while such secondary IMHA cases are of interest, the specific triggers were not wholly defined, and remission could have followed the natural disease course. The range of the frequency of findings through these studies is wide and entirely dependent on how they are defined; however, taken together with our data, around 1/3 dogs are likely to have associative IMHA.

Currently, the most robust evidence for secondary IMHA in dogs is for infectious disease, specifically piroplasms and rickettsiae, with evidence more limited for other species [2, 6, 8, 17–20]. In our cohort, only two dogs were confirmed to have vector-borne infectious disease: one Angiostrongylus infection and one with Ehrlichia after travel to continental Europe. This is unsurprising given the local infectious disease landscape [21], and so the need for indiscriminate infectious disease screening for all dogs with IMHA is unclear in this area. Additionally, whether these infections resulted in secondary IMHA or were concurrent conditions cannot be concluded; this could represent the background prevalence, as opposed to the prevalence specifically in dogs with IMHA. Vector exposure and prophylaxis should therefore inform diagnostic planning.

A range of other infectious and inflammatory conditions were suspected in dogs undergoing investigation for IMHA in this cohort. Seven dogs had abnormal lung patterns, one suspicious for aspiration pneumonia and the other 6 unexplained. These included both alveolar and interstitial patterns and might have been incidental due to exhalation, an aspiration event, a hospitalization, or represent a transfusion-related lung injury (TRALI). Overall, there was an uncertain relationship to IMHA, and it was likely that this was not a critical finding in every case.

Similarly, as part of IMHA screening and due to concerns for immunosuppression in dogs with bactiuria, a urine culture is often performed. In our cohort, urine screening was common (159/222) with cultures in 77/222. Positive findings were infrequent, with 8 having a positive culture, of which 1 had evidence of inflammation. Recent evidence supports the notion that subclinical bactiuria exists without consequence [22], and might not require treatment [23]. It remains contentious whether or not immunosuppressed dogs with bactiuria should receive antibiotics, with evidence in dogs with diabetes mellitus that antibiotic therapy might not be necessary [24]. Although not strictly meeting the criteria set by recent guidelines, we considered pyuria as associated with IMHA given the potential as an inflammatory focus [25]. Nevertheless, there is a need for improved understanding on the role of bactiuria in the development and treatment of IMHA. Finally, other infectious diseases were identified and included endocarditis and pyometra. The quality of evidence following systematic review (integrated metric of evidence, IME) for these infections as causes for secondary IMHA was low [2], but these systemic infections are especially pertinent as immunosuppression could prove life-threatening.

Neoplasia was infrequent ($n = 16$, 7%) in our cohort, although it was the 3rd most common cause for associative IMHA. IMHA is a recognized paraneoplastic syndrome in humans [11], although there is negligible evidence in veterinary species for a direct causal link [2]. Nevertheless, where a dog has neoplasia, it is clearly important in decision making. Three of these were suspected round cell neoplasia. Dogs with an adrenal mass were included ($n = 6$); although we noted a prevalence lower than in a previous cohort having incidentalomas undergoing abdominal imaging [26]. The importance of this for dogs with IMHA, therefore, remains an open question, but in any case, would be valuable information to advise clients on monitoring.

Pancreatitis has been considered a possible trigger for IMHA, although a causal link has not been demonstrated [2, 12]. Diagnosis of pancreatitis can be challenging and is typically based on a constellation of findings [27]. A total of 18/222 dogs in our study had likely or possible pancreatitis (8.1%) based on clinical signs, blood tests, and imaging findings. Our prevalence is within the range of previous reports (1/65, 1.5% to 6/50, 12%), which could differ by diagnostic criteria [12, 28]. IMHA itself is an inflammatory condition with activation of proinflammatory pathways and

consequent oxidative damage. Furthermore, anemia and thromboembolic complications contribute to tissue hypoxia. The pancreas, at least in people, is sensitive to such injury, which raises questions of the plausibility of concurrent pancreatitis being a complication of IMHA [29, 30]. Irrespective of cause or effect, identification of pancreatitis might facilitate prompt management of an important comorbidity.

The role for toxins and drugs in the development of IMHA in dogs is similarly controversial. After review, an unequivocal role for vaccination and IMHA failed to emerge [2], with studies attempting to unpick this having opposing conclusions [10, 31]. In the current study, the frequency of vaccination was less than could be expected given the random likelihood of being vaccinated in the preceding month (1/12) and so this cohort would not support vaccination as a cause for secondary IMHA. There is stronger evidence for specific drugs causing IMHA in people, and in dogs [9]. Assessment of cause and effect of antimicrobials in this study was challenged by the common use of empirical therapy in the acute presentation prior to referral. Notably, dogs with pigmenturia were treated as a suspected urinary tract infection and were therefore considered contemporaneous to, rather than a trigger for IMHA. A total of seven dogs received antibiotics, mostly of the beta-lactam class, before a clear clinical sign of IMHA developed, or where the timing could not be clearly established from the clinical notes. Secondary IMHA could not be excluded in these cases. Two cases receiving long-term biologic therapy were included in our possible secondary IMHA group given their relatively new appearance in veterinary medicine. That these dogs were on these long-term and given the low frequency (2/222) in our group, the likelihood of these resulting in secondary IMHA was considered negligible.

To contextualize diagnostic testing to the dog, it would be advantageous to identify factors that increase the likelihood of associative IMHA. To this end, multivariable analysis was performed. Only age was associated with IMHA. This was unsurprising, given the increase in co-morbidities with aging. Nevertheless, whether these findings are simply coincidental or become triggers during aging will require further investigation. Indeed, a range of comorbidities was identified in this group for which secondary IMHA was considered unlikely. These included findings such as gall bladder mucocele, which could benefit from monitoring or specific management, particularly in the context of immunosuppressive corticosteroids, although no rational link between these and IMHA was likely. Finally, in contrast to previous reports [16], we did not find that the confidence of IMHA diagnosis, as per consensus criteria, was likely to predict the identification of secondary IMHA.

Ultimately, defining contextualized diagnostics for individual dogs remains challenging. Overall, our data presents a conservative estimate for secondary IMHA as it includes findings such as vaccination or pancreatitis which, on balance, are probably co-incidental; the true values are therefore likely lower. Moreover, of dogs with associative IMHA, only 46 (21%) were identified during investigations, although other co-incidental findings were pertinent. Overall, there is a clear group that will benefit from investigations at the time of IMHA diagnosis, but despite this, there is clear scope for enhancing stewardship of diagnostic testing in IMHA.

Our work has some important limitations. Notably, although it does reflect the cohort presented to clinicians, by its retrospective and multicenter nature, not all dogs received exhaustive diagnostic testing. To mitigate, all included cases had minimum screening performed to identify at least 1 associative finding. Ideally, more cases would have undergone infectious disease testing, particularly in those cases that had traveled. Similarly, not all dogs had needle aspirate performed (22%), which is lower than in previous studies (27/50, 54%) [12], and likely reflects different working practices, highlighting the need for clearer understanding of the dogs likely to benefit. Additionally, our search criteria might have omitted specific cases of IMHA that were not investigated/defined as such (e.g., secondary a profound primary condition such as lymphoma), although we did capture many associative IMHA cases, and so we suspect the omitted number would be low. We carefully considered what could be plausible triggers; but importantly, the retrospective nature of the study does not allow for confirmation by cessation of immunosuppressive medication after removal of such a trigger in all cases, and what constitutes an IMHA trigger will remain a controversial area until more mechanistic evidence is available. In keeping with this, the final classification for dogs in this study was based on the clinical judgment by the authors upon retrospective review of the clinical data and not an a priori assessment by the primary clinician. Finally, our study might not reflect cases in primary care where the likelihood of associative IMHA could be different.

In conclusion, associative IMHA in dogs is relatively common; although the benefit of the blanket application of a number of diagnostic tests remains uncertain for individual dogs. Nevertheless, diagnostic screening remains important for those dogs in which notable findings exist.

**Acknowledgments**

Some of the data included in this publication was presented at the British Small Animal Veterinary Association (BSAVA) conference March 2024.

**Disclosure**

Authors declare no off-label use of antimicrobials.

**Ethics Statement**

Approval from the University of Edinburgh (VERC 160.22). Authors declare that human ethics approval was not needed.

**Conflicts of Interest**

The authors declare no conflicts of interest.

**References**

1. J. W. Swann, S. Tayler, H. Hall, R. Sparrow, B. J. Skelly, and B. Glanemann, "Cross-Sectional Study of Approaches to Diagnosis and Management of Dogs With Immune-Mediated Haemolytic Anaemia in Primary Care and Referral Veterinary Practices in the United Kingdom," *PLoS One* 16, no. 9 (2021): e0257700.

2. O. A. Garden, L. Kidd, A. M. Mexas, et al., "ACVIM Consensus Statement on the Diagnosis of Immune-Mediated Hemolytic Anemia in Dogs and Cats," *Journal of Veterinary Internal Medicine* 33, no. 2 (2019): 313–334.

3. G. Garratty, "Drug-Induced Immune Hemolytic Anemia," *Hematology* 2009, no. 1 (2009): 73–79.

4. W. Barcellini, "New Insights in the Pathogenesis of Autoimmune Hemolytic Anemia," *Transfusion Medicine and Hemotherapy* 42, no. 5 (2015): 287–293.

5. K. Adachi, A. Yoshimoto, T. Hasegawa, T. Shimizu, Y. Goto, and S. Makimura, "Anti-Erythrocyte Membrane Antibodies Detected in Sera of Dogs Naturally Infected With Babesia Gibsoni," *Journal of Veterinary Medical Science* 54, no. 6 (1992): 1081–1084.

6. K. Adachi, M. Tateishi, Y. Horii, H. Nagatomo, T. Shimizu, and S. Makimura, "Elevated Erythrocyte-Bound IgG Value in Dogs With Clinical Babesia Gibsoni Infection," *Journal of Veterinary Medical Science* 56, no. 4 (1994): 757–759.

7. M. T. Antognoni, F. Veronesi, G. Morganti, V. Mangili, G. Fruganti, and A. Miglio, "Natural Infection of *Anaplasma platys* in Dogs From Umbria Region (Central Italy)," *Veterinaria Italiana* 50, no. 1 (2014): 49–56.

8. P. Ciaramella, G. Oliva, R. De Luna, et al., "A Retrospective Clinical Study of Canine Leishmaniasis in 150 Dogs Naturally Infected by Leishmania Infantum," *Veterinary Record* 141, no. 21 (1997): 539–543.

9. J. C. Bloom, P. A. Thiem, T. S. Sellers, A. Deldar, and H. B. Lewis, "Cephalosporin-Induced Immune Cytopenia in the Dog: Demonstration of Erythrocyte-, Neutrophil-, and Platelet-Associated IgG Following Treatment With Cefazedone," *American Journal of Hematology* 28, no. 2 (1988): 71–78.

10. D. Duval and U. Giger, "Vaccine-Associated Immune-Mediated Hemolytic Anemia in the Dog," *Journal of Veterinary Internal Medicine* 10, no. 5 (1996): 290–295.

11. M. Tsang and S. A. Parikh, "A Concise Review of Autoimmune Cytopenias in Chronic Lymphocytic Leukemia," *Current Hematologic Malignancy Reports* 12, no. 1 (2017): 29–38.

12. N. De Laet, C. Fina, M. Dhumeaux, and A. Hrovat, "Diagnostic Imaging Findings in a Referral Population of Dogs Diagnosed With Immune-Mediated Haemolytic Anaemia: 50 Cases (2015–2018)," *Journal of Small Animal Practice* 63, no. 12 (2022): 890–896.

13. M. L. Jackson and S. A. Kruth, "Immune-Mediated Hemolytic Anemia and Thrombocytopenia in the Dog: A Retrospective Study of 55 Cases Diagnosed From 1979 Through 1983 at the Western College of Veterinary Medicine," *Canadian Veterinary Journal* 26, no. 8 (1985): 245–250.

14. A. A. Duclos, E. L. Bailén, K. Barr, K. Le Boedec, and B. Cuq, "Clinical Presentation, Outcome and Prognostic Factors in Dogs With Immune-Mediated Haemolytic Anaemia: A Retrospective Single-Centre Study of 104 Cases in Ireland (2002–2020)," *Irish Veterinary Journal* 77, no. 1 (2024): 16.

15. M. Andres, E. Hostnik, E. Green, et al., "Diagnostic Utility of Thoracic Radiographs and Abdominal Ultrasound in Canine Immune-Mediated Hemolytic Anemia," *Canadian Veterinary Journal* 60, no. 10 (2019): 1065–1071.

16. G. Woodward and J. White, "The Utility of Screening Diagnostic Tests in Identifying Associative Immune-Mediated Haemolytic Anaemia in Dogs," *Australian Veterinary Journal* 98, no. 12 (2020): 586–590.

17. A. Matsuu, A. Kawabe, Y. Koshida, H. Ikadai, S. Okano, and S. Higuchi, "Incidence of Canine Babesia Gibsoni Infection and Subclinical Infection Among Tosa Dogs in Aomori Prefecture, Japan," *Journal of Veterinary Medical Science* 66, no. 8 (2004): 893–897.

18. A. Chirek, C. Silaghi, K. Pfister, and B. Kohn, "Granulocytic Anaplasmosis in 63 Dogs: Clinical Signs, Laboratory Results, Therapy and Course of Disease," *Journal of Small Animal Practice* 59, no. 2 (2018): 112–120.

19. E. B. Breitschwerdt, K. R. Blann, M. E. Stebbins, et al., "Clinicopathological Abnormalities and Treatment Response in 24 Dogs Seroreactive to *Bartonella vinsonii* (Berkhoffii) Antigens," *Journal of the American Animal Hospital Association* 40, no. 2 (2004): 92–101.

20. L. L. Werner, R. E. W. Halliwell, R. F. Jackson, T. C. Needham, and M. Limpach, "An Investigation of the Role of Immunologic Factors in Anemia Associated With Canine Heartworm Disease," *Veterinary Immunology and Immunopathology* 7, no. 3 (1984): 285–292.

21. P. Silvestrini, B. Lloyd-Bradley, B. Glanemann, et al., "Clinical Presentation, Diagnostic Investigations, Treatment Protocols and Outcomes of Dogs Diagnosed With Tick-Borne Diseases Living in the United Kingdom: 76 Cases (2005–2019)," *Journal of Small Animal Practice* 64, no. 6 (2023): 392–400.

22. F. S. Moberg, R. Langhorn, P. V. Bertelsen, et al., "Subclinical Bacteriuria in a Mixed Population of 179 Middle-Aged and Elderly Cats: A Prospective Cross-Sectional Study," *Journal of Feline Medicine and Surgery* 22, no. 8 (2020): 678–684.

23. L. E. Nicolle, S. Bradley, R. Colgan, et al., "Infectious Diseases Society of America Guidelines for the Diagnosis and Treatment of Asymptomatic Bacteriuria in Adults," *Clinical Infectious Diseases* 40, no. 5 (2005): 643–654.

24. V. Nelson, A. Downey, S. Summers, and S. Shropshire, "Prevalence of Signs of Lower Urinary Tract Disease and Positive Urine Culture in Dogs With Diabetes Mellitus: A Retrospective Study," *Journal of Veterinary Internal Medicine* 37, no. 2 (2023): 550–555.

25. J. S. Weese, J. Blondeau, D. Boothe, et al., "International Society for Companion Animal Infectious Diseases (ISCAID) Guidelines for the Diagnosis and Management of Bacterial Urinary Tract Infections in Dogs and Cats," *Veterinary Journal* 247 (2019): 8–25.

26. A. K. Cook, K. A. Spaulding, and J. F. Edwards, "Clinical Findings in Dogs With Incidental Adrenal Gland Lesions Determined by Ultrasonography: 151 Cases (2007–2010)," *Journal of the American Veterinary Medical Association* 244, no. 10 (2014): 1181–1185.

27. H. Cridge, D. C. Twedt, A. J. Marolf, L. C. Sharkey, and J. M. Steiner, "Advances in the Diagnosis of Acute Pancreatitis in Dogs," *Veterinary Internal Medicne* 35, no. 6 (2021): 2572–2587.

28. S. M. Warman, J. K. Murray, A. Ridyard, J. Eastwood, S. Silva, and M. J. Day, "Pattern of Coombs' Test Reactivity Has Diagnostic Significance in Dogs With Immune-Mediated Haemolytic Anaemia," *Journal of Small Animal Practice* 49, no. 10 (2008): 525–530.

29. L. Gullo, L. Cavicchi, P. Tomassetti, C. Spagnolo, A. Freyrie, and M. D'Addato, "Effects of Ischemia on the Human Pancreas," *Gastroenterology* 111, no. 4 (1996): 1033–1038.

30. G. Gianesini, M. Drigo, and A. Zoia, "Immune-Mediated Hemolytic Anemia and Clinically Suspected Acute Pancreatitis in Dogs, a Pilot Study," *Topics in Companion Animal Medicine* 56-57 (2023): 100821.

31. A. P. Carr, D. L. Panciera, and L. Kidd, "Prognostic Factors for Mortality and Thromboembolism in Canine Immune-Mediated Hemolytic Anemia: A Retrospective Study of 72 Dogs," *Journal of Veterinary Internal Medicine* 16, no. 5 (2002): 504–509.

**Supporting Information**

Additional supporting information can be found online in the Supporting Information section. **Data S1:** Supporting Information. **Table S1:** Breed distribution of dogs presenting with IMHA. **Table S2:** Results of the univariable analysis.