Journal of Veterinary Internal Medicine

Journal of Veterinary Internal Medicine Open Access

ACVIM American College of Veterinary Internal Medicine

CASE REPORT OPEN ACCESS

Small Animal Internal Medicine Endocrinology

Pituitary Dwarfism and Adrenocorticotropic Hormone Deficiency in a White Swiss Shepherd Dog With LHX3 Mutation

Gaëlle Schils[1,2] | Lisa Stammeleer[1,3] | Sylvie Daminet[1,2]

[1]Small Animal Department, Ghent University, Ghent, Belgium | [2]Small Animal Department, Liege University, Liège, Belgium | [3]Pride Veterinary Referrals, Derbyshire, UK

Correspondence: Gaëlle Schils (gschils@uliege.be)

Received: 29 April 2025 | **Revised:** 1 July 2025 | **Accepted:** 18 July 2025

Funding: The authors received no specific funding for this work.

Keywords: ACTH | dwarf | endocrinology | hypocortisolism | pituitary gland

ABSTRACT

LHX3 mutation in dogs is associated with combined pituitary hormone deficiency. However, ACTH secretion is usually preserved. A 9-week-old female White Swiss Shepherd dog presented with growth retardation and was diagnosed with pituitary dwarfism due to LHX3 mutation. In the 2 years after diagnosis, the dog developed persistent lymphocytosis and eosinophilia. Endogenous ACTH measurement, ACTH stimulation test, and CRH stimulation test confirmed pituitary hypocortisolism. The dog was administered physiological doses of prednisolone, with improvement of activity levels. These findings are similar to scarce human reports and suggest that corticotrope function might decline over time in dogs with LHX3 mutations. Awareness and screening for ACTH deficiency in dwarf dogs is important in light of compatible clinical signs and laboratory abnormalities, as treatment with glucocorticoids improves the quality of life of these dogs.

1 | Introduction

Pituitary dwarfism is most common in German Shepherd dogs [1]. LHX3, a LIM homeobox gene, codes for a transcription factor essential for pituitary development [2]. Molecular defects in the LHX3 gene are responsible for pituitary dwarfism in German Shepherd dogs and crossbreeds, such as the Saarloos wolfdogs and Czechoslovakian wolfdogs [3, 4]. Recently, the same mutation has been identified in Tibetan Terrier dwarfs [5]. German Shepherd dogs with the LHX3 mutation display a combined deficiency of growth hormone (GH), thyroid stimulating hormone (TSH), prolactin, and impaired release of gonadotropins. However, ACTH secretion is preserved [6].

1.1 | Case Report

A 9-week-old female White Swiss Shepherd dog was referred to the Small Animal Clinic, Faculty of Veterinary Medicine, Ghent University, Belgium, for growth retardation. The most common causes for growth retardation had already been ruled out by the referring veterinarian. Blood examination performed

Abbreviations: EDTA, ethylenediaminetetraacetic acid; GH, growth hormone; oCRH, ovine corticotropin-releasing hormone; TSH, thyroid stimulating hormone.

This is an open access article under the terms of the Creative Commons Attribution-NonCommercial-NoDerivs License, which permits use and distribution in any medium, provided the original work is properly cited, the use is non-commercial and no modifications or adaptations are made.

© 2025 The Author(s). *Journal of Veterinary Internal Medicine* published by Wiley Periodicals LLC on behalf of American College of Veterinary Internal Medicine.

before presentation showed a low circulating IGF-1 (38 ng/mL; reference range, 137–425) and a borderline low serum TT4 (1 μg/dL; reference range, 1–3.2) in combination with a low TSH (< 0.03 ng/mL; reference range, < 0.55).

On physical examination, the dog was smaller than expected for her age and was proportionate. Based on these results, signalment, and clinical presentation, pituitary dwarfism was suspected. Ethylenediaminetetraacetic acid (EDTA) blood sample was analyzed for LHX3 mutation and revealed that the dog was homozygous for the 7 bp deletion, which confirmed the diagnosis of pituitary dwarfism. Levothyroxine 10 μg/kg PO q12h was initiated and bi-annual follow-up was advised. A mild lymphocytosis (4.5X1000/μL; reference range, 1.1–3.6) was noticed at the first control and was still present at the second control. As the dog was doing clinically well, and no other relevant abnormal laboratory results were present, no further examinations were performed. However, 18 months after diagnosis, the lymphocytosis progressed (5.5X1000/μL; reference range, 1.1–3.6), and mild eosinophilia (1.2X1000/μL; reference range, < 0.8) appeared. The electrolytes were within normal limits. Basal cortisol was measured and was < 0.1 μg/dL. An ACTH stimulation test was performed using 5 μg/kg of synthetic ACTH (Synachten, Novartis Pharma Schweiz AG, Bern, Switzerland) IV. Pre- and post-ACTH values were < 0.1 and 0.7 μg/dL, respectively.

To differentiate primary from secondary hypoadrenocorticism, endogenous ACTH was measured (frozen EDTA plasma, tubes cooled down before sampling, analyzed at Universitair Veterinair Diagnostisch Laboratorium, Utrecht, by solid phase sandwich chemiluminescent immunoassay). A low value of 5 pg/mL (13–46 pg/mL) confirmed secondary hypoadrenocorticism. A CRH stimulation test was performed to further evaluate ACTH secretion and response. The CRH stimulation test was done according to previously

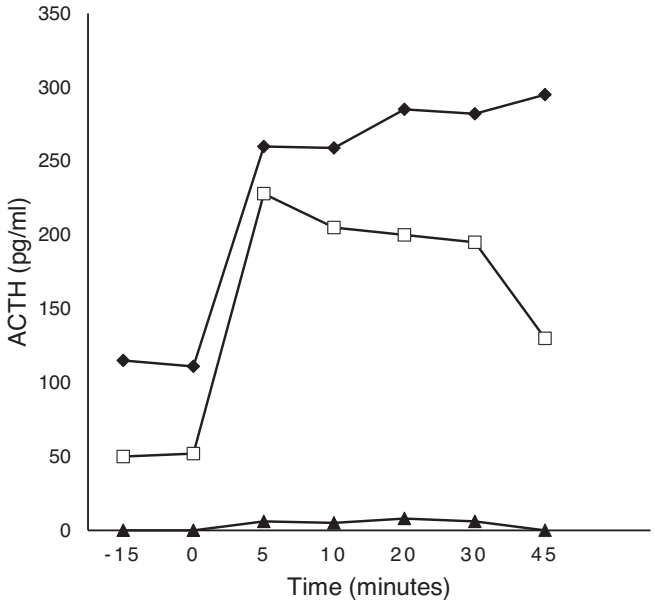

GRAPH 1 | ACTH values during CRH stimulation test in a dwarf White Swiss Shepherd dog (▲) with hypocortisolism compared to previously published data of eight German Shepherd dwarfs (◆) and eight healthy Beagle dogs (□) [6, 7]. On the bottom axes, 0 represents the moment of CRH injection.

described protocols [6]. Briefly, 1 μg/kg of ovine corticotropin-releasing hormone (oCRH, Ferring Pharmaceuticals, Saint-Prex, Switzerland) was administered IV. Basal ACTH was measured 15 min before the injection of oCRH. Blood was subsequently sampled 5, 10, 20, 30, and 45 min after oCRH injection. ACTH values were low before and after stimulation (flat line, Graph 1). During the CRH stimulation test, the patient who was initially stressed and difficult to sample became lethargic, raising concerns about the inability to cope with the stress of the procedure. Immediately after the last sampling, an injection of dexamethasone was administered. The dog was then started on PO prednisolone 0.13 mg/kg q24h. According to the owner, this led to increased activity levels and better general demeanor within a few days of corticosteroids supplementation. Three years later, she is still doing well.

2 | Discussion

This is a report of a case of a dog with dwarfism due to LHX3 mutation and concurrent endogenous ACTH deficiency.

In mice homozygous for LHX3 mutation, Rathke's pouch forms but fails to grow and differentiate. Except for the corticotropes, determination of all pituitary cell lineages is affected. This suggests the existence of an LHX3-independent ontogenetic pathway for corticotroph cells initial specification [2]. Similarly, of eight German shepherd dwarfs, all had combined deficiency of GH, TSH, and prolactin together with impaired release of gonadotropins, whereas ACTH secretion was preserved. Basal and stimulated plasma ACTH concentrations did not differ between the dwarfs and the control group in one study [6]. Consequently, it is generally accepted that dogs with LHX3 mutation do not lack ACTH and do not present with secondary hypoadrenocorticism.

In this case, the presence of lethargy, the development of lymphocytosis, and later eosinophilia triggered the decision to measure basal cortisol. The low value did not rule out primary or secondary hypoadrenocorticism, and secondary eunatraemic eukaliaemic hypoadrenocorticism was confirmed after the ACTH stimulation test and measurement of endogenous ACTH. Congenital hypocortisolism is unlikely as, in the fetus, glucocorticoids and cortisol induce a wide range of enzymes on which survival after birth is dependent [8]. Research on LHX3 engineered null mice showed that LHX3 is necessary for complete differentiation of four of the five anterior pituitary cell lineages, but also for establishing a normal cohort of corticotropes by birth [2]. In alignment with these results, proopiomelanocortin was severely reduced in mice LHX3 null pituitaries. The mice had less differentiated corticotrophs, together with decreased expression of the corticotrope transcription factors TPIT and NEUROD1 [9]. The increase in cell death happened early in pituitary development, and dying cells were localized to regions of TPIT expression, indicating that apoptosis might contribute to the pronounced reduction in the number of corticotrope cells. The mice also had hypoplastic adrenal glands. The authors concluded that LHX3 is necessary for normal expression of TPIT and NEUROD1 and for survival of pre-corticotrope cells [2, 9].

In human medicine, mutations in the LHX3 gene underlie complex diseases featuring combined pituitary hormone deficiency [10]. If some clinical features are consistent with the phenotype

of the LHX3 null murine models, mice die as neonates while human LHX3 null patients survive into adulthood. In people, ACTH secretion is usually preserved, but anecdotical reports of ACTH deficiency do exist [11–13].

This is a report of a dog with LHX3 mutation and hypoadrenocorticism due to ACTH deficiency. Our findings suggest that ACTH deficiency might develop in pituitary dwarfs with LHX3 mutations. These patients could benefit from longitudinal screening for hypocortisolism in front of compatible clinical signs and laboratory abnormalities. Indeed, vague symptoms of secondary hypoadrenocorticism could be mistakenly imputed to progressive renal disease and/or hypothyroidism in this population. Consequently, clinicians should be aware of hypocortisolism as another possible differential diagnosis in front of compatible symptoms and laboratory findings.

Acknowledgments

Acknowledgments to the Faculty of Veterinary Medicine of Utrecht University for providing us the oCRH.

Disclosure

Authors declare no off-label use of antimicrobials.

Ethics Statement

Authors declare no institutional animal care and use committee or other.

Conflicts of Interest

The authors declare no conflicts of interest.

References

1. A. Voorbij and H. Kooistra, "Pituitary Dwarfism in German Shepherd Dogs," *Journal of Veterinary Clinical Science* 2 (2009): 4–11.

2. H. Sheng, A. Zhadanov, B. Mosinger, et al., "Specification of Pituitary Cell Lineages by the LIM Homeobox Gene Lhx3," *Science* 272, no. 5264 (1996): 1004–1007.

3. A. Voorbij, F. Van Steenbeek, M. Vos-Loohuis, et al., "A Contracted DNA Repeat in LHX3 Intron 5 Is Associated With Aberrant Splicing and Pituitary Dwarfism in German Shepherd Dogs," *PLoS One* 6, no. 11 (2011): e27940.

4. A. Voorbij, P. Leegwater, and H. Kooistra, "Pituitary Dwarfism in Saarloos and Czechoslovakian Wolfdogs Is Associated With a Mutation in LHX3," *Journal of Veterinary Internal Medicine* 28, no. 6 (2014): 1770–1774.

5. T. Thaiwong, S. Corner, S. La Forge, S. Forge, and M. Kiupel, "Dwarfism in Tibetan Terrier Dogs With an LHX3 Mutation," *Journal of Veterinary Diagnostic Investigation* 33, no. 4 (2021): 740–743.

6. H. Kooistra, G. Voorhout, J. Mol, H. S. Kooistra, J. A. Mol, and A. Rijnberk, "Combined Pituitary Hormone Deficiency in German Shepherd Dogs With Dwarfism," *Domestic Animal Endocrinology* 19, no. 3 (2000): 177–190.

7. B. Meij, J. Mol, H. Hazewinkel, et al., "Assessment of a Combined Anterior Pituitary Function Test in Beagle Dogs: Rapid Sequential Intravenous Administration of Four Hypothalamic Releasing Hormones," *Domestic Animal Endocrinology* 13, no. 2 (1996): 161–170.

8. G. Liggins, "The Role of Cortisol in Preparing the Fetus for Birth," *Reproduction, Fertility and Development* 6, no. 2 (1994): 141–150.

9. B. Ellsworth, D. Butts, and S. Camper, "Mechanisms Underlying Pituitary Hypoplasia and Failed Cell Specification in Lhx3-Deficient Mice," *Developmental Biology* 313, no. 1 (2008): 118–129.

10. I. Netchine, M. Sobrier, H. Krude, et al., "Mutations in LHX3 Result in a New Syndrome Revealed by Combined Pituitary Hormone Deficiency," *Nature Genetics* 25, no. 2 (2000): 182–186.

11. A. Rajab, D. Kelberman, S. De castro, et al., "Novel Mutations in LHX3 Are Associated With Hypopituitarism and Sensorineural Hearing Loss," *Human Molecular Genetics* 17, no. 14 (2008): 2150–2159.

12. W. Bonfig, H. Krude, and H. Schmidt, "A Novel Mutation of LHX3 Is Associated With Combined Pituitary Hormone Deficiency Including ACTH Deficiency, Sensorineural Hearing Loss, and Short Neck—A Case Report and Review of the Literature," *European Journal of Pediatrics* 170, no. 8 (2011): 1017–1021.

13. R. Pfaeffle, J. Savage, C. Hunter, et al., "Four Novel Mutations of the LHX3 Gene Cause Combined Pituitary Hormone Deficiencies With or Without Limited Neck Rotation," *Journal of Clinical Endocrinology and Metabolism* 92, no. 5 (2007): 1909–1919.