Journal of Veterinary Internal Medicine

Journal of Veterinary Internal Medicine
Open Access
ACVIM
American College of Veterinary Internal Medicine

CASE REPORT OPEN ACCESS

Small Animal Internal Medicine Hepatology

Isolation of *Campylobacter upsaliensis* From an Abscessed Hepatic Mass in a Dog

Tahj A. Boston[1] | Sara D. Lawhon[1] | Genna F. Aitee[2] | Katie Como[2] | Kimberley Sannajust[3] | Christine L. Gremillion[3] | Haley E. Dodson[1] | Laura K. Bryan[1] | Karen E. Russell[1]

[1]Department of Veterinary Pathobiology, College of Veterinary Medicine & Biomedical Sciences, Texas A&M University, College Station, Texas, USA | [2]Department of Small Animal Clinical Sciences, College of Veterinary Medicine & Biomedical Sciences, Texas A&M University, College Station, Texas, USA | [3]Department of Large Animal Clinical Sciences, College of Veterinary Medicine & Biomedical Sciences, Texas A&M University, College Station, Texas, USA

Correspondence: Tahj A. Boston (tahjboston@yahoo.com)

Received: 4 November 2024 | **Revised:** 27 June 2025 | **Accepted:** 22 July 2025

Funding: The authors received no specific funding for this work.

Keywords: canine | cytology | extraintestinal infection | hepatocellular carcinoma | microaerophilic | oclacitinib

ABSTRACT

An 11-year-old male castrated Boston Terrier dog presented with acute onset lethargy and vomiting. On examination, the dog was febrile, tachycardic, and thought to have generalized abdominal pain. Abdominal ultrasonography identified a fluid-filled hepatic mass with suspected surrounding steatitis. Cytology from the hepatic mass indicated septic neutrophilic inflammation with extracellular and intracellular curved to spiral small bacterial organisms consistent with *Campylobacter* spp. The cytology results prompted appropriate isolation techniques composed of microaerophilic culture methods, which resulted in isolation of *Campylobacter upsaliensis*. Anaerobic and aerobic cultures also were performed and yielded no growth. Because of prognosis, the owner elected euthanasia, and necropsy identified a hepatocellular carcinoma as the underlying lesion for the abscessed hepatic mass.

1 | Introduction

Campylobacter spp. are microaerophilic, Gram-negative, curved, 0.5–5 μm long bacterial rods that appear gull-or spiral-shaped when in pairs or chains, respectively [1–4]. In dogs, *Campylobacter jejuni* is mostly known for its association with gastrointestinal disease causing diarrhea, but most dogs with *Campylobacter* infections are subclinical [1]. *Campylobacter* spp. also have zoonotic potential and are a common cause of gastroenteritis in humans [1–3]. Extraintestinal manifestations of *Campylobacter* spp. are rare. In dogs, cholecystitis, bacteremia, and abortion have been reported with *C. jejuni* infections [1]. One study linked *Campylobacter upsaliensis* and *C. jejuni* infections to acute polyradiculoneuritis (APN) in dogs [5]. *Campylobacter upsaliensis* is a thermotolerant, catalase negative to weak positive *Campylobacter* species that is commonly isolated from the feces of both healthy dogs and dogs with signs of gastroenteritis [1, 2]. In human medicine, *C. upsaliensis* has been isolated from a hepatic cyst and a breast abscess [6, 7]. Other extraintestinal diseases in humans associated with *C. upsaliensis* are bacteremia, abortion, Guillain-Barré syndrome, and hemolytic uremic syndrome [1, 2, 6]. Apart from APN, extraintestinal diseases have not been reported in association with *C. upsaliensis*

Abbreviations: APN, acute polyradiculoneuritis; CLSI, Clinical and Laboratory Standards Institute; H&E, hematoxylin and eosin; NARMS, National Antimicrobial Resistance Monitoring System; RI, reference interval; USG, urine specific gravity.

This is an open access article under the terms of the Creative Commons Attribution-NonCommercial-NoDerivs License, which permits use and distribution in any medium, provided the original work is properly cited, the use is non-commercial and no modifications or adaptations are made.

© 2025 The Author(s). *Journal of Veterinary Internal Medicine* published by Wiley Periodicals LLC on behalf of American College of Veterinary Internal Medicine.

infections in dogs. Herein, we describe *C. upsaliensis* isolated from an abscessed hepatocellular carcinoma in a dog.

2 | Case Description

An 11-year-old male castrated Boston Terrier dog was presented to the Texas A&M Small Animal Teaching Hospital for acute onset of lethargy and vomiting. The morning of presentation, the dog failed to rise and would not leave its crate. Two episodes of vomiting were noted that day.

On presentation, the dog had dull mentation. Physical examination identified dehydration, fever of 103.2°F, and tachycardia with no murmurs auscultated. On palpation, the abdomen was tense and appeared painful. The dog was ambulatory, but weak, with normal muscle tone and reflexes. Cervical pain was noted. The remainder of the physical examination was normal.

A CBC indicated mild inflammation, and a stress leukogram with mild thrombocytosis was noted. Serum biochemistry identified mild hyperkalemia (4.7 mmol/L; RI, 3.3–4.6 mmol/L), mildly decreased bicarbonate concentration (20 mmol/L; RI, 21–28 mmol/L), mildly increased alkaline phosphatase activity (178 U/L; RI, 24–147 U/L), and mild hypercholesterolemia (265 mg/dL; RI, 120–247 mg/dL). On urinalysis, urine specific gravity (USG) was 1.040 and pH was 8.5, with mild proteinuria, mild bilirubinuria, moderate pyuria (12–15 WBC/high powered field [hpf]), and mild hematuria (7–10 RBC/hpf). A urine culture was not performed.

The dog was treated with IV fluids (lactated Ringer's solution) and maropitant (1 mg/kg), and methadone and dexmedetomidine were used for analgesia and sedation as needed at variable doses. Ampicillin/sulbactam (30 mg/kg) was administered after sample collection.

Abdominal ultrasonographic examination was performed and identified a large, well-circumscribed, loculated, approximately 2.8 cm by 3.8 cm thin-walled mass arising from the caudal aspect of the right hepatic division (Figure 1). The mass contained a large volume of echogenic fluid and an internal accumulation of clumped echogenic material that did not display color Doppler signal upon interrogation. A small volume of echogenic peritoneal effusion and hyperechoic mesenteric fat was identified adjacent to the mass. The remainder of the hepatic parenchyma was diffusely heterogeneous with multifocal variably sized hypoechoic nodules and cavitated regions. The primary differential diagnoses for the hepatic mass included an atypical abscess, abscessed hepatic cyst, complex hepatic cyst with internal hemorrhage or hematoma formation, or a neoplastic mass with internal necrosis. The peritoneal effusion was thought to represent either a modified transudate secondary to regional inflammation or exudate associated with mass rupture and leakage. Differential diagnoses for the diffusely heterogeneous and nodular hepatic parenchyma included both benign (e.g., vacuolar hepatopathy, chronic hepatitis with nodular regeneration) and malignant causes. Ultrasound-guided abdominocentesis followed by fine needle aspirates of the general liver parenchyma and large fluid-filled hepatic mass were performed. Approximately 4.0 mL of brown opaque fluid was obtained from the liver mass, and samples were submitted for cytologic evaluation. Point-of-care testing on the peritoneal fluid identified a lactate concentration of 4.1 mmol/L and glucose concentration of 179 mg/dL. Peripheral blood glucose concentration was 104 mg/dL (RI, 60–135 mg/dL).

Insufficient peritoneal fluid was available to perform physical analysis and quantitation of protein and cells. Cytologic evaluation of the smears made from the peritoneal fluid showed a moderately to markedly increased cellularity with a predominance of nondegenerate to mildly degenerate neutrophils (98%). The peritoneal fluid was interpreted as a neutrophilic exudate. Cytologic evaluation of the liver parenchyma sample disclosed normal hepatocytes with a subjective mild increase in the proportion of neutrophils compared to the amount of blood and was interpreted as mild neutrophilic inflammation. No infectious agents were observed cytologically in the peritoneal fluid or liver parenchyma samples.

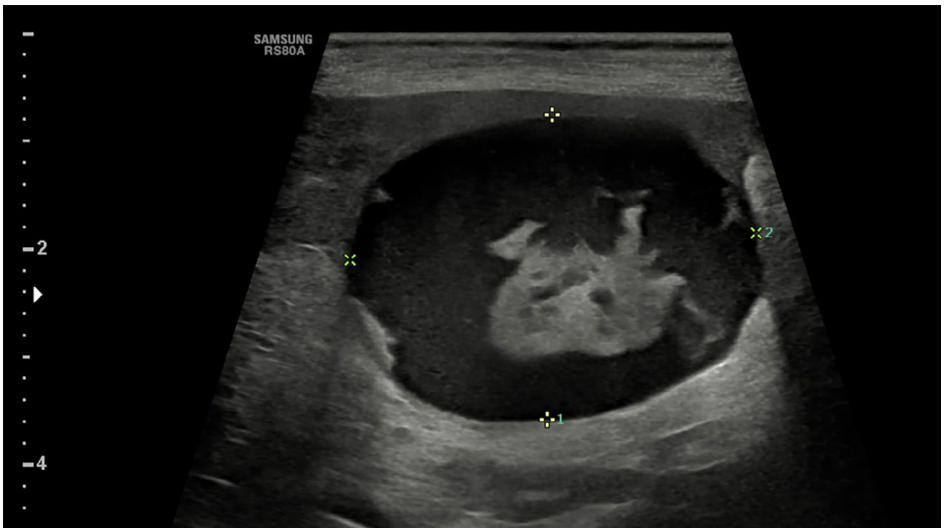

FIGURE 1 | Transverse B-mode ultrasonographic image showing a large, thin-walled, 2.8 cm × 3.8 cm fluid-filled mass (demarcated by calipers) with internal echogenic foci arising from the caudal margin of the right hepatic division with regional hyperechoic mesenteric fat. Images were acquired using a linear transducer, 4–18 MHz frequency range, with the patient in dorsal recumbency.

Cytologic evaluation of fluid from the liver mass identified a nucleated cell population of markedly degenerate and poorly preserved neutrophils and numerous extracellular and rare intracellular curved to spiral-shaped bacterial organisms that were approximately 1–2 μm in length (Figure 2A,B). The total nucleated cell count of the fluid was deemed inaccurate because of the poorly preserved nature of the cells. The total protein concentration of the fluid was 4.3 g/dL. The fluid from the liver mass was interpreted as indicating moderate to marked neutrophilic inflammation with intracellular and extracellular spiral-shaped bacterial organisms consistent with a septic process. *Campylobacter* was considered likely given the size and morphology of the bacteria.

A specimen from the liver mass submitted to the laboratory via swab (BBL CultureSwab Plus; BD, Franklin Lakes, NJ) and a specimen of abdominal fluid were used to inoculate three sets of plates for aerobic, microaerophilic, and anaerobic cultures. For each aerobic culture, one plate of trypticase soy agar supplemented with 5% sheep blood (blood agar plate hereafter; BD), one MacConkey agar plate (BD), and a tryptose broth enrichment culture (BD) were inoculated. The blood agar plate and tryptose broth were incubated at 37°C in a 5% carbon dioxide atmosphere, whereas the MacConkey agar plate was incubated at 37°C in an air atmosphere. For the microaerophilic cultures, two blood agar plates and two Brucella agar plates (Hardy Diagnostics; Santa Maria, CA) were inoculated,

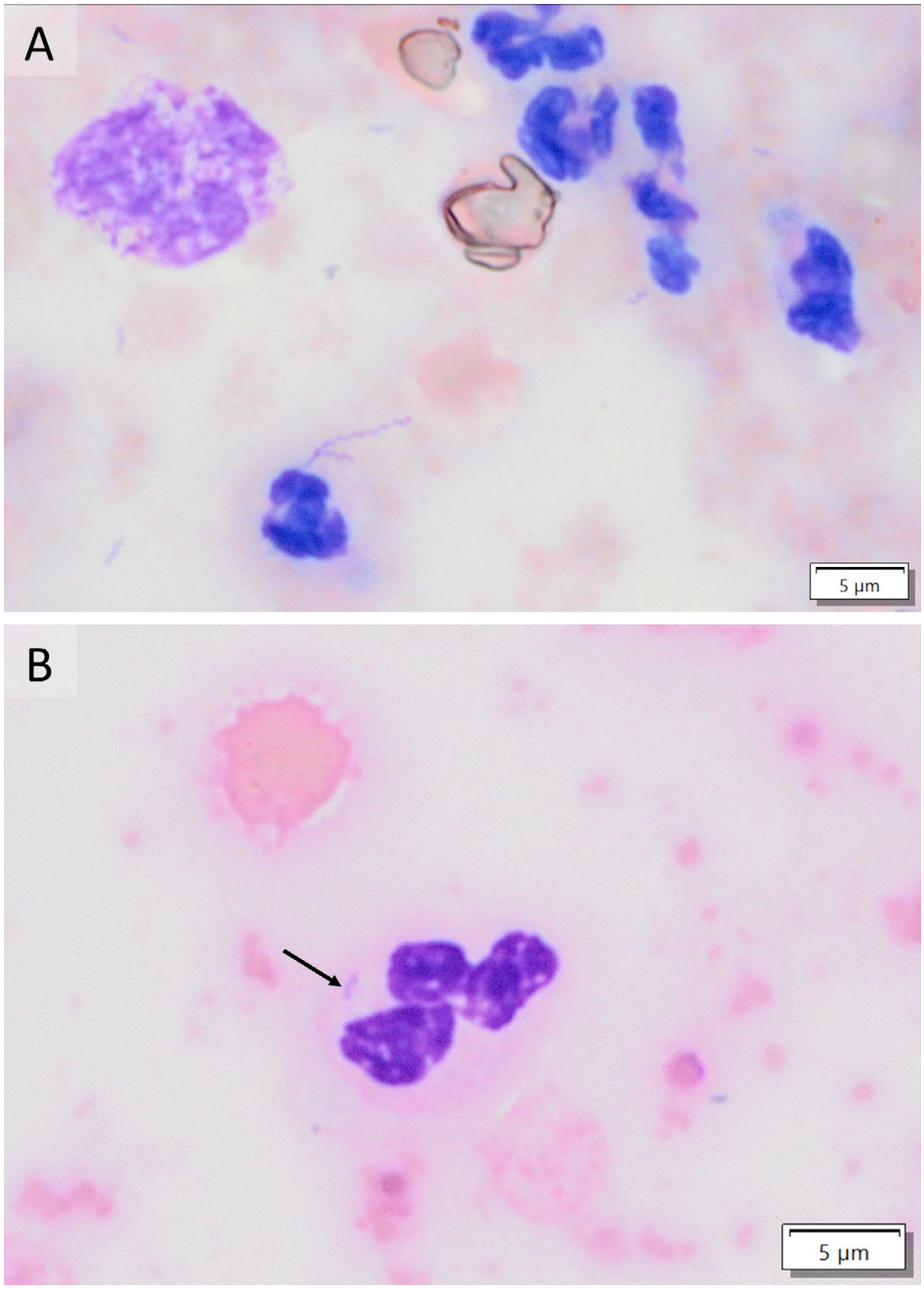

FIGURE 2 | (A and B): Photomicrographs of fluid from the hepatic mass. (1000×, Wright-Giemsa stain). There is neutrophilic inflammation with degenerate neutrophils and extracellular and intracellular curved to spiral bacterial rods. The arrow indicates intracellular bacteria.

TABLE 1 | Antimicrobial susceptibility of the *C. upsaliensis* isolate.

Antimicrobial	MIC (μg/mL)	CLSI human breakpoints for *C. coli* (μg/mL)[a]	CLSI human breakpoints for *C. jejuni* (μg/mL)[a]
Azithromycin	0.06 (S)	1	0.5
Erythromycin	0.12 (S)	16	8
Ciprofloxacin	0.12 (S)	1	1
Nalidixic acid	≤4 (S)	32	32
Clindamycin	0.5 (S)	2	1
Florfenicol	0.5 (S)	8	8
Gentamicin	0.12 (S)	4	4
Tetracycline	0.25 (S)	4	2

Abbreviations: MIC, Minimum inhibitory concentration; S, susceptible.
[a]There are currently no veterinary breakpoints for *Campylobacter* spp. Therefore, CLSI breakpoints for humans and NARM guidelines were used [8, 9].

and one plate of each type was incubated at 37°C and 42°C in a microaerophilic environment that was established using an anaerobe jar with a microaerophilic gas sachet (Mitsubishi AnaeroPouch-MicroAero Gas Generator, Mitsubishi Gas Company, Japan). For the anaerobic cultures, one Brucella agar, one Columbia CNA agar with 5% sheep blood plate (BD), and a broth enrichment consisting of a 5 mL brain-heart infusion broth supplemented with 0.1 mL of Oxyrase (Oxyrase Inc., Mansfield, OH) were inoculated and incubated in an anaerobic environment generated in an anaerobe jar using an anaerobic gas sachet (Mitsubishi AnaeroPouch-MicroAero Gas Generator, Mitsubishi Gas Company, Japan) at 37°C. The specimen from the liver mass yielded 3+ growth of *Campylobacter upsaliensis* at 37°C under microaerophilic conditions and light growth of the organism at 42°C under microaerophilic conditions, but not under the aerobic or anaerobic conditions. The abdominal fluid did not yield any organisms.

Minimum inhibitory concentrations of azithromycin, erythromycin, ciprofloxacin, nalidixic acid, clindamycin, florfenicol, gentamicin, and tetracycline were measured using an antimicrobial susceptibility test panel (Sensititre CAMPY AST Plate; Thermo Scientific, Cleveland, OH) and cation-adjusted Mueller-Hinton broth supplemented with lysed horse blood (Thermo Scientific) according to the manufacturer's recommendations and following the Clinical and Laboratory Standards Institute (CLSI) guidance of incubating the antimicrobial susceptibility test panel under microaerophilic conditions at 37°C for 48 h [8]. The minimum inhibitory concentrations are presented in Table 1. The CLSI breakpoints for *C. jejuni* for erythromycin and tetracycline were used [8]. Categories of susceptible or resistant for the remaining tested antibiotics were determined using the National Antimicrobial Resistance Monitoring System for Enteric Bacteria (NARMS) guidelines [9]. No veterinary breakpoints currently are available for *Campylobacter* species. Based on the CLSI breakpoints used in humans and the NARMS guidelines, the isolate was considered susceptible to all of the antimicrobial drugs tested (Table 1) [9].

The dog was euthanized after preliminary cytology results and before bacterial identification by culture because of concern for hepatic abscessation and poor prognosis. At necropsy, the right lateral liver lobe contained a single, pale tan to brown, soft 5×4.5×4 cm mass and the pancreas was multifocally firm and shrunken. On section of the liver mass, the tissue exuded abundant tan to brown, caseous material. There were no clinically relevant findings in other organs.

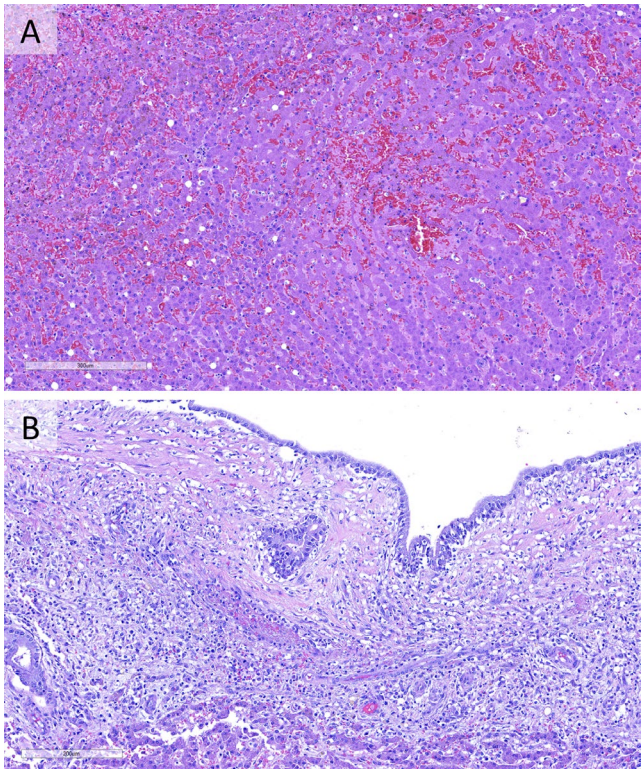

FIGURE 3 | (A and B): Photomicrograph of hepatocellular carcinoma (A) and gallbladder (B) (H&E stain). Neoplastic hepatocytes are arranged in trabeculae and cords (A). The gallbladder is expanded by a mixed inflammatory cell population (B).

Histologically, the hepatic parenchyma was expanded by an unencapsulated, poorly demarcated, moderately cellular epithelial neoplasm arranged in multi-cell layer thick trabeculae and cords within a fine to moderate fibrovascular stroma

(Figure 3A). Neoplastic cells had variably distinct cell borders, abundant amounts of eosinophilic cytoplasm, and round to ovoid nuclei with finely stippled chromatin and single nucleoli. Anisocytosis and anisokaryosis were mild. One mitotic figure was seen in ten 400× fields (2.37 mm^2 equivalent). The neoplasm contained a well-demarcated, centrally-located area with necrosis lined with granulation tissue and fibrosis consistent with a capsule. Within the surrounding liver parenchyma, hepatocytes showed changes consistent with necrosis and vacuolar degeneration. The portal areas were expanded by mild to moderate lymphoplasmacytic and neutrophilic inflammation and mild multifocal ductular reaction, and fibrin thrombi were observed multifocally within blood vessels. A section consistent with the gallbladder was similarly disrupted by inflammation and necrosis (Figure 3B). The pancreas showed mild chronic inflammation.

A separate, firm section of tissue of undetermined origin was observed on histologic evaluation. It was surrounded by adipose tissue (interpreted as mesentery) and composed of an unencapsulated, poorly demarcated, densely cellular neoplasm completely effacing the tissue. Neoplastic cells were arranged in packets and nests within a moderate fibrovascular stroma. Neoplastic cells had distinct cell borders, moderate to large amounts of finely granular eosinophilic cytoplasm, and round to ovoid nuclei with finely stippled chromatin and single distinct nucleoli. Anisocytosis and anisokaryosis were moderate. One mitotic figure was seen in ten 400× fields (2.37 mm^2 equivalent). Multifocal areas of necrosis were present within the neoplasm.

The liver mass was a low-grade hepatocellular carcinoma with a central abscess. Bacteria were not apparent in the neoplasm on hematoxylin and eosin (H&E), Gram stain, and immunohistochemistry for *Campylobacter* spp. (University of Georgia histology laboratory). The mass of unknown origin (covered with adipose tissue) was diagnosed as a neuroendocrine tumor. Given the suspicion of an anatomic location near the liver, gallbladder, and pancreas, immunohistochemistry for insulin was performed to rule out insulinoma, and the neoplasm was immunonegative. A non-chromaffin paraganglioma was considered the most likely diagnosis for this neoplasm. Its clinical relevance was not apparent.

3 | Discussion

Hepatic abscesses are uncommon in dogs. They may be caused by ascending biliary tract infections, hematogenous spread, traumatic events, ischemia, or extension of infection [4, 10]. The most common bacterial species isolated from hepatic abscesses in dogs are *Escherichia coli*, *Clostridium* spp., *Staphylococcus* spp., and *Enterococcus* spp., which all are considered normal enteric microflora and can be isolated in anaerobic or aerobic (for facultative anaerobes) environments [4, 11]. Although *Campylobacter* spp. commonly are isolated from feces of dogs with diarrhea and enteritis, they rarely are associated with extraintestinal diseases. In this case, it was presumed that the liver mass sampled during ultrasonography and the liver mass examined on necropsy were the same mass, based on location and size. Therefore, the conclusion of an abscessed hepatocellular carcinoma was made.

Campylobacter spp. require a microaerophilic atmosphere and incubation at 37°C or 42°C for isolation [12]. Selective media including Campy-CVA, Campy-BAP, Skirrow medium, charcoal cefoperazone deoxycholate agar (CCDA), and charcoal-based selective medium (CSM) may be used to enhance isolation in feces [12]. However, *C. upsaliensis* is inconsistently recovered with *Campylobacter* selective media because some strains of *C. upsaliensis* are more sensitive to cefoperazone, an antibiotic used in the media [12]. Therefore, *C. upsaliensis* may go undetected when using standard *Campylobacter* selective media. A filtration method and use of CAT agar media, which contains a smaller concentration of cefoperazone, have been recommended as techniques for enhancing *C. upsaliensis* isolation [12]. In one study, CAT agar was shown to be more effective for recovering more strains of *C. upsaliensis* compared with CCDA when spiking samples with the bacteria [13].

In our case, *Campylobacter* spp. was suspected because of the morphology of the bacteria on cytologic evaluation, which led to an appropriate method of isolation with incubation in a microaerophilic environment. No growth was observed with aerobic and anaerobic conditions, demonstrating the requirement of a microaerophilic atmosphere for isolation of *C. upsaliensis*. Unfortunately, immunohistochemical staining for *Campylobacter* spp. did not confirm the presence of the bacteria in the abscessed hepatocellular carcinoma. However, exudates from suspected neoplastic lesions are often routinely removed before processing for histologic examination, which may explain this failure to identify the organism. The patient also was treated with antibiotics after identification of the bacteria and before euthanasia, which may have contributed to false negative results.

The cause of the infection in this case is uncertain, but ascending infection or translocation of bacteria was suspected. The gallbladder had changes consistent with cholecystitis on histopathology, which may support ascending infection. The hepatocellular carcinoma likely was a predisposing factor causing ischemia secondary to outgrowth of blood supply and allowing bacterial colonization. Although unlikely, an additional consideration is that the *C. upsaliensis* infection may have stimulated malignant transformation, causing the hepatocellular carcinoma. Studies suggest an association between *Campylobacter* spp. and gastrointestinal tumors in humans, but not with *C. upsaliensis* specifically [14].

The dog described here was chronically treated with oclacitinib. Oclacitinib inhibits Janus kinase 1 (JAK1) enzymes, which modify the production of several interleukins (IL), including IL-2, IL-4, IL-6, and IL-13 [15]. Oclacitinib may increase susceptibility to infection and exacerbate neoplastic conditions [16]. The dog of our report had an unusual infection, and two neoplasms were identified at necropsy (hepatic carcinoma and neuroendocrine tumor).

Considering the common bacterial agents isolated from hepatic abscesses in dogs, anaerobic or aerobic environments would be indicated for bacterial isolation. However, *Campylobacter* spp. require microaerophilic conditions and would go undetected using anaerobic and aerobic conditions. Consequently, *Campylobacter* may go underdetected in hepatic abscesses.

Campylobacter upsaliensis also may go undetected with *Campylobacter* selective media. Failure of *C. upsaliensis* to grow at 42°C is not uncommon [17]. Clinicians should be aware that *C. upsaliensis* has been identified in a hepatic abscess because this organism can be challenging to grow using conventional methods. Cytology can be helpful in aiding the diagnosis of *Campylobacter* infection and, if timing allows, optimization of culture methods for its growth.

Disclosure

Authors declare no off-label use of antimicrobials.

Ethics Statement

Authors declare no institutional animal care and use committee or other.

Conflicts of Interest

The authors declare no conflicts of interest.

References

1. E. Acke, "Campylobacteriosis in Dogs and Cats: A Review," *New Zealand Veterinary Journal* 66 (2018): 221–228.

2. B. Bourke, V. L. Chan, and P. Sherman, "*Campylobacter Upsaliensis*: Waiting in the Wings," *Clinical Microbiology Reviews* 11 (1998): 440e449.

3. J. E. Sykes and S. L. Marks, "Campylobacteriosis," in *Canine and Feline Infectious Diseases*, ed. J. E. Sykes (Elsevier Saunders, 2014), 452–457.

4. J. E. Sykes and C. E. Greene, *Infectious Diseases of the Dog and cat*, 4th ed. (Elsevier, 2012).

5. L. Martinez-Anton, M. Marenda, S. M. Firestone, et al., "Investigation of the Role of Campylobacter Infection in Suspected Acute Polyradiculoneuritis in Dogs," *Journal of Veterinary Internal Medicine* 32 (2018): 352–360.

6. Y. Ohkoshi, T. Sato, H. Murabayashi, et al., "*Campylobacter upsaliensis* Isolated From a Giant Hepatic Cyst," *Journal of Infection and Chemotherapy* 26 (2020): 752–755.

7. C. Gaudreau and F. Lamothe, "*Campylobacter upsaliensis* Isolated From a Breast Abscess," *Journal of Clinical Microbiology* 30 (1992): 1354–1356.

8. CLSI, *Methods for Antimicrobial Susceptibility Testing of Infrequently Isolated or Fastidious Bacteria Isolated From Animals*, 1st ed. (Clinical and Laboratory Standards Institute, 2017).

9. CDC, National Antimicrobial Resistance Monitoring System (NARMS) Now: Human Data. In. Atlanta, GA: U.S. Department of Health and Human Services, CDC.

10. E. T. Farrar, R. J. Washabau, and M. Saunders, "Hepatic Abscesses in Dogs: 14 Cases (1982-1994)," *Journal of the American Veterinary Medical Association* 208 (1996): 243–247.

11. J. E. Burke, R. S. Hess, E. P. McEntee, M. A. Griffin, S. M. Harmon, and D. C. Silverstein, "Hepatic Abscessation in Dogs: A Multicenter Study of 56 Cases (2010–2019)," *Journal of Veterinary Emergency and Critical Care* 33 (2023): 665–675.

12. J. H. Jorgensen, M. A. Pfaller, K. C. Carroll, et al., *Manual of Clinical Microbiology*, 11th ed. (ASM Press, 2015).

13. S. T. Aspinall, D. R. A. Wareing, P. G. Hayward, D. R. Wareing, and D. N. Hutchinson, "Selective Medium for Thermophilic Campylobacters Including *Campylobacter Upsaliensis*," *Journal of Clinical Pathology* 46 (1993): 829–831.

14. I. Kato, J. Minkevitch, and J. Sun, "Oncogenic Potential of *Campylobacter* Infection in the Gastrointestinal Tract: Narrative Review," *Scandinavian Journal of Gastroenterology* 58 (2023): 1453–1465.

15. A. J. Gonzales, J. W. Bowman, G. J. Fici, M. Zhang, D. W. Mann, and M. Mitton-Fry, "Oclacitinib (APOQUEL) is a Novel Janus Kinase Inhibitor With Activity Against Cytokines Involved in Allergy," *Journal of Veterinary Pharmacology and Therapeutics* 37 (2014): 317–324.

16. M. G. Papich, "Oclacitinib Maleate," in *Saunders Handbook of Veterinary Drugs*, 4th ed. (Elsevier Saunders, 2016), 574–576.

17. A. M. Carnahan, J. Beadling, D. Watsky, and N. Ford, "Detection of *Campylobacter upsaliensis* From a Blood Culture by Using the BacT/Alert System," *Journal of Clinical Microbiology* 32 (1994): 2598–2599.