Journal of Veterinary Internal Medicine

Journal of Veterinary Internal Medicine
Open Access
ACVIM
American College of Veterinary Internal Medicine

CASE REPORT OPEN ACCESS

Food & Fiber Animal Hepatology

Hepatopathy in a 4-Month-Old Holstein Calf After Transfusion With Plasma Containing Bovine Bosavirus

Simon F. Peek[1] | Chelsea L. Holschbach[1] | Alexandra J. Burton[1] | Zuzanna W. Sikorska[1] | LaTasha K. Crawford[2] | Christopher D. Dunn[2] | Tony L. Goldberg[2]

[1]Department of Medical Sciences, School of Veterinary Medicine, University of Wisconsin-Madison, Madison, Wisconsin, USA | [2]Department of Pathobiological Sciences, School of Veterinary Medicine, University of Wisconsin-Madison, Madison, Wisconsin, USA

Correspondence: Chelsea L. Holschbach (cholschbach@wisc.edu)

Received: 17 April 2025 | **Revised:** 28 July 2025 | **Accepted:** 29 July 2025

Funding: The authors received no specific funding for this work.

Keywords: diarrhea | hypoproteinemia | liver biopsy | next-generation sequencing

ABSTRACT

We report on the identification of bovine bosavirus associated with a post-transfusion hepatopathy in a 4-month-old Holstein bull calf that was referred for enteritis and fever of unknown origin. Next-generation sequencing (NGS) of post-transfusion blood and liver tissue from the calf, alongside NGS of plasma from the donor, identified a bovine bosavirus. This virus has been previously identified in bovine calf serum, calves with mucosal disease, and the blood of bison but was of uncertain clinical importance. These findings have biosecurity implications for clinicians using bovine whole blood or plasma therapeutically and suggest the need for pre- or postharvest donor screening or biologic processing to prevent infection of recipients. The calf made a full clinical recovery.

1 | Case Description

A 4-month-old Holstein bull calf was referred to the large animal hospital at the University of Wisconsin School of Veterinary Medicine on October 27, 2022, for evaluation of mild fever and worsening diarrhea over the preceding week. The diarrhea was noted intermittently to contain frank blood. The calf had been weaned and was fed hay and calf grain, although its appetite was notably reduced in the 36 h preceding referral.

At presentation, the calf was dull, but normothermic (38.5°C), eupneic (20 breaths/min) and had a normal heart rate (68 bpm). Bodyweight was 136 kg. Mucous membranes were light pink, but with a capillary refill time of 3 s, alongside a cervical skin tent of 4 s. During the initial examination, the calf passed watery diarrhea with frank blood present; the perineum and hindlimbs were stained with fecal material of a similar consistency and character. Rumen and intestinal hypomotility were present. Transabdominal ultrasound examination[1] revealed thickened, enteritic small intestine, but additional abnormalities were not detected, with the abomasum and pylorus both normal in appearance and anatomic location, and a normal volume of scant free abdominal fluid present. Abnormalities were not detected on ultrasound examination of the liver.

A complete blood count and serum biochemistry profile revealed marked neutrophilia with a degenerative left shift (segmented neutrophil count $42.9 \times 10^3 \mu L$ (normal 1.6–6.1), 6.9 bands $\times 10^3 \mu L$ (normal 0.0–0.1)), hemoconcentration (hematocrit 42%, normal 20%–30%), alongside panhypoproteinemia, hyponatremia, hypochloremia, hypokalemia, hypocalcemia, hyperglycemia, hyperbilirubinemia, and elevated serum activities

Abbreviations: ALP, alkaline phosphatase; AST, aspartate aminotransferase; BVDV, bovine viral diarrhea virus; CK, creatine kinase; EqPV-H, equine parvovirus; GGT, gamma-glutamyl transferase; GLDH, glutamate dehydrogenase; NCBI, National Center for Biotechnology Information; NGS, next-generation sequencing; RTqPCR, quantitative real-time polymerase chain reaction.

This is an open access article under the terms of the Creative Commons Attribution-NonCommercial-NoDerivs License, which permits use and distribution in any medium, provided the original work is properly cited, the use is non-commercial and no modifications or adaptations are made.

© 2025 The Author(s). *Journal of Veterinary Internal Medicine* published by Wiley Periodicals LLC on behalf of American College of Veterinary Internal Medicine.

for creatine kinase (CK), aspartate aminotransferase (AST), and alkaline phosphatase (ALP). Treatment over the first 6 h of hospitalization included 2 L of a commercial bovine plasma product IV, combined with crystalloid therapy; initially comprising 500 mL of a 7.2% hypertonic saline solution by bolus, followed by PlasmaLyte with added calcium gluconate (125 mL of a 23% calcium gluconate solution total volume) and potassium chloride (30 mEq/L) at 250 mL/h. Additional treatments included ceftiofur sodium[2] (2.2 mg/kg sq q24h for 5 days), potassium penicillin (22 000 IU/kg iv q6h for 5 days), amprolium (10 mg/kg po q24h for 5 days) and thiamine (20 mg/kg sq once). During the second 12 h of hospitalization, the calf became brighter and started to consume small amounts of hay and grain. An increasing amount of cool, pitting non-painful submandibular edema was noted on the second day of hospitalization, which, combined with persistent hypoalbuminemia (1.8 mg/dL, normal 2.3–3.2 mg/dL), prompted a second transfusion with another liter of bovine plasma. This second transfusion had an identical batch number to the previous one.

Transabdominal ultrasound on Day 5 of hospitalization revealed subjective hepatomegaly, although the echogenic appearance of the liver appeared normal and homogenous. Based upon publications by Braun and Kruger [1, 2], the liver was enlarged beyond the margins identified in similarly aged Holstein calves, rounded contours extending dorsocaudally beyond the 13th rib, and as far as ventral midline in the sixth and seventh intercostal spaces on the right. The gall bladder was of appropriate diameter (3 cm diameter) and contained anechoic content. No other abnormalities were visualized during ultrasound examination of the abdomen. Repeat serum biochemistry also performed on Day 5 of hospitalization showed resolution of previous hyponatremia, hypochloremia, hypocalcemia, and hyperbilirubinemia but marked elevations in gamma-glutamyl transferase (GGT; 987 IU/L, normal 28–81 IU/L) and glutamate dehydrogenase (GLDH; 276 IU/L, normal 8–126 IU/L). Repeat transabdominal ultrasound on Day 7 revealed a persistently enlarged liver with a subjectively heterogenous appearance caudally.

2 | Biopsy of Liver

Three pieces of liver were obtained from the area of heterogenous echogenicity under ultrasound guidance by percutaneous biopsy on Day 10 of hospitalization. The biopsy procedure was performed with the calf standing, using only local anesthetic infiltration (2% lidocaine) of the skin and body wall in the right 9th and 10th intercostal spaces at the level of the mid-paralumbar fossa under ultrasound guidance, using a commercial 14 G, 15 cm Trucut biopsy device.[3] Formalin-fixed tissue was conventionally processed for histopathology and fresh liver was immediately frozen for later metagenomic analysis by NGS; simultaneously, a serum sample was obtained for comparative NGS analysis at the time of liver biopsy.

3 | Plasma NGS

An aliquot of the same batch number of plasma used for both transfusion events was obtained by sterile technique from a thawed 1 L bag. The plasma administered to the calf, as well as that used for NGS investigation, came from the same individual donor.

4 | Metagenomic NGS

Samples were subjected to metagenomic NGS. Briefly, solid samples (feces and liver) were homogenized, viral particles were concentrated, total nucleic acids were isolated (~20 mg of solid tissue, feces, or 200 μL plasma), and RNA was converted into double-stranded cDNA. cDNA was then prepared for sequencing on an Illumina MiSeq machine using a 150 × 150 cycle MiSeq Reagent Nano Kit, v2.[4] Resulting sequence data (reads) were trimmed (Phred score ≥ 30, length ≥ 50) and host reads were subtracted in silico with reference to the assembled *Bos taurus* genome (assembly ARS-UCD1.3) using CLC Genomics Workbench.[5] Reads were then assembled into contiguous sequences (contigs) using metaSPAdes [3], and resulting contigs were queried for similarity to known viruses in the National Center for Biotechnology Information (NCBI) nucleotide and protein sequence databases using blastn and blastp, respectively [4, 5]. These methods are useful for identifying unknown viruses and are similar in sensitivity to quantitative real-time polymerase chain reaction (RTqPCR) [6]. Reads from each sample were then mapped to the longest contig representing an identified virus using CLC Genomics Workbench,[5] as a measure of relative virus concentration.

5 | Bosavirus Polymerase Chain Reaction (PCR)

To assess the bull's viremic status 175 days post-admission from the hospital, plasma was obtained and a PCR was conducted targeting the bosavirus capsid gene, with primers BOSAV_F (5′-CAGCCACCAGATACAGATTCCGG-3′) and BOSAV_R (5′-CTGTTGCATACCTAAGATCGTG-3′) modified from Hause [7] to match the bosavirus sequence found using metagenomics. Viral nucleic acids were extracted using the QIAamp UltraSens Virus Kit[6] following the manufacturer's protocol. PCR was then performed on plasma and a kit extraction negative control using HotStarTaq Master Mix[7] and 2 μL of extracted nucleic acid as template. Reactions were run with the following thermocycling profile: 95°C for 15 min; 35 cycles of 94°C for 30 s, 50°C for 30 s, 72°C for 30 s; 72°C for 10 min; and a 12°C indefinite soak. PCR products were electrophoresed on a 2% agarose gel stained with ethidium bromide and visualized under ultraviolet light.

6 | Results

The relevant histopathologic findings included diffuse, moderate glycogen vacuolation of hepatocytes (as appreciated by Periodic Acid Schiff staining) alongside acute, mild neutrophilic portal hepatitis accompanied by mild biliary hyperplasia (Figure 1). Overall, however, the lobular architecture was well preserved with normal centrilobular veins.

A total of 1 907 197 reads of average length 129 bp were generated after quality and length trimming. In sample 2 (plasma from the calf), the complete genome of bosavirus (Parvoviridae: *Copiparvovirus ungulate5*) was recovered with deep coverage

(Table 1; Figure 2; GenBank PV491922.1). This virus is nearly identical (99.57% nucleotide residues) to bosavirus MS-2016a (NCBI Reference Sequence NC_031959.2) identified in commercial bovine serum from the USA collected in 2015 and nearly as similar (≥99.43%) to bosaviruses from commercial bovine serum from the USA collected in 2018 (GenBank MN180054.1) and 2020 (GenBank MZ502234.1) and from commercial bovine serum from New Zealand collected in 2020 (GenBank MZ502235.1). No other viruses were identified in the calf's plasma, liver, or the inoculum. In feces, short contigs corresponding to partial genomes of various bacteriophages, small circular DNA viruses, and picobirnaviruses were identified, as is typical in feces. These are likely incidental.

Follow-up serum biochemical analysis through the remainder of hospitalization and at 35 and 97 days after admission was performed. GLDH and albumin were the first to normalize by Day 12. Total protein and GGT values returned to normal by Day 35. No bands appeared on the gel for the serum sample obtained 175 days after admission, showing that the bull was negative or that the virus was below the limit of detection of the assay.

The calf was reported to be normal clinically at 35, 97, and 175 days after admission and entered commercial semen collection at approximately 12 months of age. He has since been culled for production reasons (at approximately 19 months).

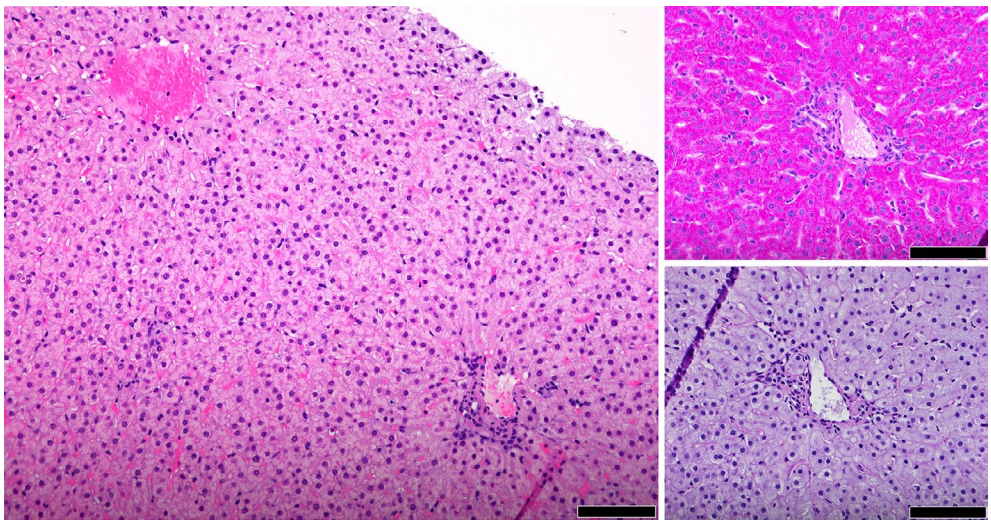

FIGURE 1 | Histology of the liver biopsy obtained from a bull with hepatic disease. The image on the left (×200 magnification, hematoxylin and eosin stain) shows diffuse glycogen vacuolation and minimal portal hepatitis. The upper and lower right-sided images are the PAS and PAS-diastase stains, respectively, verifying the presence of glycogen in the hepatocytes (×400 magnification). Scale bars are 100 μm.

TABLE 1 | Sequencing and mapping statistics of bosavirus (5371 nt) identified in bull with hepatic disease.

Sample	Reads after trim	Reads after *Bos taurus* genome subtraction	Reads mapping to bosavirus (‰ nonhost)	Average sequence coverage of bosavirus
1. Blank	28 060	21 733	0 (0)	n/a
2. Feces	418 839	358 196	2 (0.006)	0.056
3. Plasma	354 096	277 012	25 008 (90.278)	646.660
4. Liver	680 298	24 195	42 (1.736)	1.044
5. Inoculum	425 904	356 316	21 (0.059)	0.562

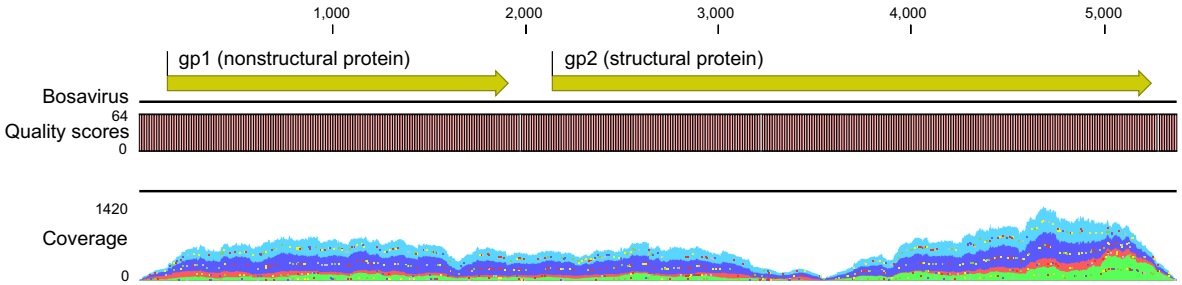

FIGURE 2 | Genome map of bosavirus (5371 nt) identified in plasma from a bull with hepatic disease. Arrows represent open reading frames encoding the nonstructural protein gp1 and the structural protein gp2. Quality scores and coverage map are shown.

7 | Discussion

Previous metagenomic and phylogenetic studies have placed bovine bosavirus within the *Copiparvovirus* genus, which also includes porcine and equine parvoviruses (EqPV-H) [6–8], within the family Parvoviridae. It has been identified in commercial bovine calf serum from several parts of the world [6, 8, 9], but previous reports have always referred to it as being of unknown clinical importance. The seroprevalence of bosavirus infection in cattle populations worldwide is unknown, but a closely related sister copiparvovirus has been identified as a coinfection with BVDV in Bison in the United States [7]. Examples of copiparvovirus infection can be found in many mammals worldwide, and in many instances, their clinical importance is unknown; however, much recent attention has been focused in equine medicine on the EqPV-H and its association with serum hepatitis. Acute serum hepatitis, also known as Theiller's disease, is the only disease entity proven to be associated with the EqPV-H, and it can be transmitted through contaminated biologics and plasma [10]. However, prevalence studies from multiple countries in recent years document that between 3% and 20% of horses are positive for EqPV-H nucleic acid in serum [11–13], suggesting a background level of circulating infection and viremia in normal, asymptomatic animals.

The demonstration of high concentrations of bovine bosavirus within the serum and liver tissue of this calf, coincident with the development of biochemical and histologic evidence of hepatopathy, raises the possibility of copiparvovirus-associated liver disease in the bovine species. The additional finding of the same virus by NGS in the plasma of the donor, from whom the calf had received 3 L of plasma by transfusion only 3 days before hepatopathy had been revealed by blood work, provides further strong circumstantial evidence of a link between the virus and the liver insult. Although pre-transfusion blood samples from the calf were not available for metagenomics analysis, blood work before transfusion had not demonstrated elevations in highly specific biochemical markers of hepatobiliary or hepatocellular injury, namely GGT or GLDH. Admission blood work did demonstrate elevations in serum activities for AST and ALP (using the adult reference range for our internal hospital laboratory). The concurrent elevation in CK was suggestive of a myopathy likely related to increased recumbency, poor perfusion, and transportation, probably also driving the AST increase. ALP values in young cattle can be elevated compared to adults due to increased bone metabolism; in fact, the values obtained from this calf would be within an age-matched normal reference range for total ALP activity as reported in a recent publication [14]. The hyperbilirubinemia at presentation was probably related to inappetence and bile stasis associated with enteropathy and, interestingly, actually normalized during the period of GGT and GLDH elevations post-transfusion. This is in contrast to the classic hyperbilirubinemia and marked jaundice seen with the severest form of EqPV-H associated Theiler's disease [10].

The histopathologic appearance of the liver biopsy tissue from this calf differed from those in classic descriptions of Theiller's disease in horses; the latter being characterized by profound centrilobular necrosis and loss of lobar architecture, although the lobular periphery can exhibit cytoplasmic vacuolization and mixed inflammatory infiltrates [15, 16]. The most remarkable histologic finding in the biopsy of this calf was diffuse glycogen deposition, with only minimal neutrophilic portal hepatitis being identified. Admittedly, any biopsy only samples a very small piece of liver and therefore could fail to identify changes present elsewhere within the liver parenchyma; but the clinical course and full recovery of this individual suggests that the severity of hepatocellular injury, at least in this case, did not mimic that seen with the more severe versions of hepatic parvovirus injury in horses [17].

The infrequency with which plasma or whole blood administration occurs in bovine practice implies that the risk of transfusion-related bosavirus-associated hepatopathy in cattle is probably low. However, it would still be prudent for those hospitals that use their own donors or commercial enterprises that market blood-derived products for therapeutic use to consider screening animals prior to use for bosavirus or other lesser-known infectious agents.

Disclosure

Authors declare no off-label use of antimicrobials.

Ethics Statement

Authors declare no institutional animal care and use committee or other approval was needed. Authors declare human ethics approval was not needed.

Conflicts of Interest

The authors declare no conflicts of interest.

Endnotes

[1] LOGIQe NEXTGen ultrasound system, GE Healthcare, Wauwatosa, WI 53226, USA.

[2] Naxcel, Zoetis Animal Health, Parsipanny, NJ 07054, USA.

[3] Trucut biopsy device, Jorgensen Laboratories LLC, Loveland, CO 80538, USA.

[4] MiSeq Reagent Nano Kit, v2, Illumina, San Diego, CA, USA.

[5] CLC Genomics Workbench, Qiagen, Hilden, Germany.

[6] QIAamp UltraSens Virus Kit, Qiagen, Hilden, Germany.

[7] HotStarTaq Master Mix Qiagen, Hilden, Germany.

References

1. U. Braun, "Ultrasonographic Evaluation of the Reticulum, Rumen, Omasum, Abomasum and Liver in Calves," *Veterinary Clinics of North America. Food Animal Practice* 32 (2016): 85–107.

2. U. Braun and S. Kruger, "Ultrasonography of the Spleen, Liver, Gallbladder, Caudal Vena Cava and Portal Vein in Healthy Calves From Birth to 104 Days of Age," *Acta Veterinaria Scandinavica* 55, no. 1 (2013): 55–68.

3. S. Nurk, D. Meleshko, A. Korobeynikov, and P. A. Pevzner, "MetaSPAdes: A New Versatile Metagenomic Assembler," *Genome Research* 27 (2017): 824–834.

4. S. F. Altschul, T. L. Madden, A. A. Schaffer, et al., "Gapped BLAST and PSI-BLAST: A New Generation of Protein Database Search Programs," *Nucleic Acids Research* 25 (1997): 3389–3402.

5. S. F. Altschul, W. Gish, W. Miller, E. W. Myers, and D. J. Lipman, "Basic Local Alignment Search Tool," *Journal of Molecular Biology* 215 (1990): 403–410.

6. K. Toohey-Kurth, S. D. Sibley, and T. L. Goldberg, "Metagenomic Assessment of Adventitious Viruses in Commercial Bovine Sera," *Biologicals* 47 (2017): 64–68.

7. B. M. Hause, A. Pillatzki, T. Clement, et al., "Persistent Infection of American Bison With Bovine Viral Diarrhea Virus and Bosavirus," *Veterinary Microbiology* 252 (2021): 108 949, https://doi.org/10.1016/vetmic2020.108949.

8. P. Zhang, L. Cao, Y. Y. Ma, et al., "Metagenomic Analysis Reveals Presence of Different Animal Viruses in Commercial Fetal Bovine Serum and Trypsin," *Zoological Research* 43, no. 5 (2022): 756–766.

9. M. Sadeghi, B. Kapusinszky, D. M. Yugo, et al., "Virome of US Bovine Calf Serum," *Biologicals* 46 (2017): 64–67.

10. T. J. Divers, J. E. Tomlinson, and B. C. Tennant, "The History of Theiller's Disease and the Search for Its Aetiology," *Veterinary Journal* 287 (2022): 105878, https://doi.org/10.1016/j.tvjl.2022.105878.

11. M. V. D. S. De Moraes, C. R. S. Salgado, T. L. O. S. Godoi, et al., "Equine Parvovirus Hepatitis Is Detected in South America, Brazil," *Transboundary and Emerging Diseases* 69, no. 5 (2022): 3022–3027, https://doi.org/10.1111/tbed.14226.

12. G. Lu, L. Wu, J. Ou, et al., "Molecular Presence of Equine Parvovirus Hepatitis in China: Characterization of Its Genetic Diversity and Evidence for Natural Recombination Events Between the Chinese and American Strains," *Frontiers in Veterinary Science* 7 (2020): 121.

13. C. Fortier, C. El-Hage, E. Hue, et al., "Hepatitis Viruses: Prevalence of Equine Parvovirus-Hepatitis Virus and Equine Hepacivirus in France and Australia," *Equine Veterinary Journal* 53, no. S56 (2021): S68.

14. A. Chiba, K. Hatate, R. Onomi, et al., "Consecutive Changes in Serum Alkaline Phosphatase Isoenzyme 3 Activities in Holstein Heifers During the First 18 Months of Life," *Journal of Veterinary Medical Science* 82, no. 11 (2020): 1643–1647, https://doi.org/10.1292/jvms.20-0306.

15. C. Qualls and D. Gribble, "Equine Serum Hepatitis: A Morphologic Study," *Laboratory Investigation* 34 (1976): 330.

16. M. Robinson, C. Gopinath, and D. Hughes, "Histopathology of Acute Hepatitis in the Horse," *Journal of Comparative Pathology* 85 (1975): 111–118.

17. T. J. Divers, B. C. Tennant, A. Kumar, et al., "New Parvovirus Associated With Serum Hepatitis in Horses After Inoculation of Common Biological Product," *Emerging Infectious Diseases* 24, no. 2 (2018): 303–310.