Journal of Veterinary Internal Medicine
Open Access
ACVIM
American College of Veterinary Internal Medicine

CASE REPORT OPEN ACCESS

Small Animal Internal Medicine Neurology

Neurolymphomatosis of T-Cell Origin in a Dog

Marie-Kerstin Müller[1,2] | Michaela Irmscher[1] | Nadja Goldbach[3] | Alexander F. H. Haake[4] | Olivia Kershaw[4] | Penelope A. Baloi[5]

[1]AniCura Potsdam GmbH, Potsdam, Germany | [2]IDEXX Vet Med Labor GmbH, Kornwestheim, Germany | [3]Tierarztpraxis Dr. Soerensen GmbH, Berlin, Germany | [4]Institut für Tierpathologie, Freie Universität Berlin, Berlin, Germany | [5]Vet-CT, Cambridge, UK

Correspondence: Marie-Kerstin Müller (marie.mueller@anicura.de; marie-kerstin-mueller@idexx.com)

Received: 30 October 2024 | **Revised:** 20 June 2025 | **Accepted:** 27 June 2025

Funding: The authors received no specific funding for this work.

Keywords: canine | histopathology | peripheral nervous system | T-cell lymphoma

ABSTRACT

A 10-year-old mixed-breed dog was presented with progressive neurological deficits suggestive of polyneuropathy. CT and MRI revealed no relevant abnormalities, whereas the CSF analysis showed a marked lymphocytic pleocytosis, immunocytochemically classified as T-cell lymphoma. Chemotherapy ensued with no improvement of clinical signs. Cerebrospinal fluid reanalysis still revealed a mild lymphocytic pleocytosis. MRI of the brain and spinal cord solely showed a reduced ventral subarachnoid and epidural space (Th11-L2) and mild enlargement of the central canal in this area. Postmortem examination revealed thickening of the spinal nerve roots and ganglia. Histologically, a marked intraspinal-subdural and intraneural, as well as intra-ganglionic, infiltration by large lymphocytes in the peripheral nervous system was visible. Immunohistochemically, the infiltrating lymphoblasts were CD3 positive, confirming T-cell origin. Neurolymphomatosis is a rarely described neoplastic disease in dogs. The present case highlights the importance of analysis of CSF in neurologically abnormal dogs.

1 | Introduction

Neurolymphomatosis is a condition where peripheral nerves, nerve roots, cranial nerves, and plexus are infiltrated by neurotropic neoplastic cells. In human medicine, this disease is mainly associated with an extranodal variant of non-Hodgkin lymphoma or leukemia [1]. Both lymphoma and leukemia are also well recognized diseases in veterinary medicine, with lymphoma being one of the most common diagnosed neoplasms in cats and dogs. Even though the brain and central nervous system (CNS) are occasionally affected by this condition (either primary or secondary), the involvement of the peripheral nerves is rarely reported [2]. In dogs, 61.5% of the cases with neurolymphomatosis present as primary lymphomas, with 53.8% of these being of B-cell lineage [3].

The case presented here describes a rare case of primary T-cell neurolymphomatosis affecting the nerve roots, plexus, and spinal nerves. Diagnostic imaging showed no abnormalities, though cytologic analysis of the cerebrospinal fluid (CSF) revealed a high-grade pleocytosis with predominantly intermediate and large lymphocytes and rare mitotic figures, highlighting the importance of this examination in cases of peripheral nerve disease.

2 | Case Description

A 10-year-old mixed-breed dog presented with a 4-week history of lameness of the left pelvic limb. Radiographs of the limbs performed by the referring veterinarian revealed no abnormalities.

Abbreviations: AE, adverse events; CHOP, cyclophosphamide, hydroxydaunomycin, vincristine sulfate, prednisolone; CNS, central nervous system; CRP, c-reactive protein; CSF, cerebrospinal fluid; CT, computed tomography; MRI, magnetic resonance imaging; PNS, peripheral nervous system; PNSL, peripheral nervous system lymphoma; TNCC, total nucleated cell count.

This is an open access article under the terms of the Creative Commons Attribution-NonCommercial License, which permits use, distribution and reproduction in any medium, provided the original work is properly cited and is not used for commercial purposes.

© 2025 The Author(s). *Journal of Veterinary Internal Medicine* published by Wiley Periodicals LLC on behalf of American College of Veterinary Internal Medicine.

Analgesic treatment did not alleviate any clinical signs, which further progressed.

The initial clinical examination revealed high-grade lameness of both the left thoracic and pelvic limbs, as well as severe generalized atrophy of the skeletal muscles. Due to a known *Leishmania* infection, which was treated in accordance with the guidelines for treatment of leishmaniasis in dogs [4], serological (*Borrelia burgdorferi*, *Ehrlichia canis*, *Anaplasma phagocytophilum*, *Babesia canis*, and *Leishmania infantum*) and molecular (*Ehrlichia* spp., *Anaplasma* spp., *Babesia* spp., and *Leishmania* spp.) blood examinations were performed. Apart from a positive titer for *A. phagocytophilum* (28.7 test units; reference range < 8 test units), neither PCR nor serology (ELISA) revealed any abnormalities. The complete blood cell count, clinical blood chemistry, including a c-reactive protein (CRP) measurement and urine analysis were normal. Therefore, a relapse of leishmaniasis or other vector-borne disease as a potential cause of the lameness was ruled out.

Upon neurological examination 10 days later, there was non-ambulatory tetraparesis with emphasis on the left side; slightly reduced proprioception in all four limbs; markedly reduced segmental reflexes in both pelvic limbs; slightly reduced segmental reflexes in the left and normal in the right thoracic limb; reduced, but triggerable panniculus reflex; pain on palpation of the thoracic and lumbar spine. Besides mydriasis of the right pupil with a negative pupillary light reflex (suspected internal ophthalmoplegia), the examination of the cranial nerves did not reveal any abnormalities. According to these findings, generalized polyneuropathy was suspected, although a multifocal CNS disease could not be ruled out.

Magnetic resonance imaging (MRI—Esaote Vet-MR Grande 0.25 Tesla) of head (T2 transverse and sagittal, FLAIR transverse, T1 transverse before and after intravenous administration of contrast medium, GRE transverse) and cervical spine (T2 sagittal) solely showed mildly deepened sulci, which was most likely age-related. Otherwise, the examined structures did not show any morphological abnormalities.

On computed tomography (CT—Siemens SOMATOM Emotion 16 slice; reconstructed in high and low frequency algorithm, before and after intravenous administration of contrast medium), the thoracic structures did not show any abnormalities. The abdominal CT revealed a mildly enlarged spleen with rounded margins, but normal parenchymal attenuation. The adrenal glands were mildly enlarged (left 8.2 mm, right 7.4 mm). The mesenteric lymph nodes were marginally enlarged with 5.5 mm in short axis diameter and enhanced inhomogeneous after contrast. All other abdominal organs were normal on CT.

Distinct muscle atrophy of the left pelvic limb and gluteal muscles was noted, as well as mild contrast enhancement within the spinal canal at the lumbosacral region and at the enlarged left L7 nerve root (Figure 1). Thus, inflammation of the left spinal nerve at L7/S1 was suspected, with resulting neurogenic muscle atrophy.

The analysis of the CSF obtained by lumbar puncture showed marked lymphocytic pleocytosis (TNCC 837 cells/μL, protein content 14 843.8 mg/L) with predominantly intermediate and large lymphocytes, a low number of small, mature lymphocytes (< 20%), and rare mitotic figures (Figures 2 and 3). These findings were indicative of an intermediate to large-cell lymphoma. Immunocytochemical examination revealed > 95% of the cells with moderate membranous and cytoplasmic staining for CD3, whereas < 3% of cells were moderately positive for PAX5 with a nuclear staining pattern. Therefore, T-cell origin was considered most likely and the diagnosis of T-cell lymphoma was made.

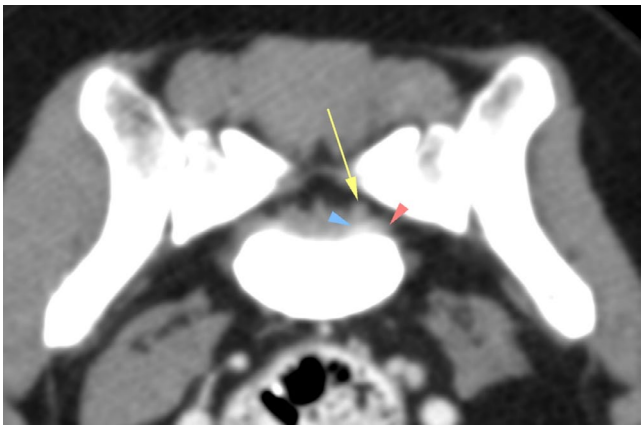

FIGURE 1 | Computer tomography image of the spine at L7-S1 (transverse section, soft tissue recon, after contrast) showing the enlarged nerve (arrow) and mild contrast enhancement of the surrounding tissue (arrowheads).

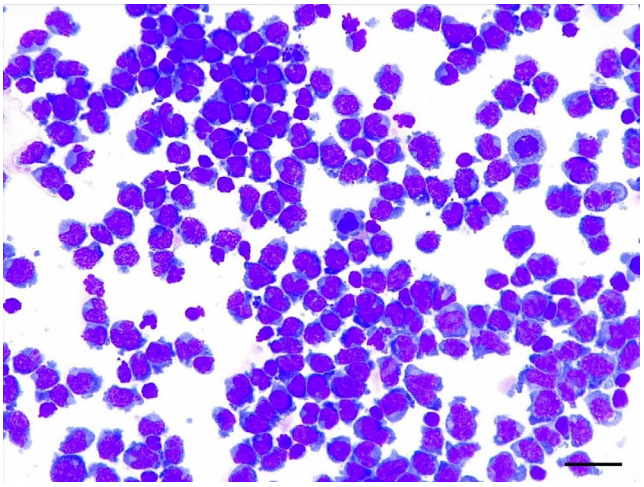

FIGURE 2 | Cytologic analysis of the cerebrospinal fluid revealing a high-grade pleocytosis (TNCC 837 cells/μL, protein content 14 843.8 mg/L) with predominantly intermediate and large lymphocytes and a low number of small, mature lymphocytes (Diff Quick, bar = 30 μm, ×400 magnification).

Chemotherapy with prednisolone, vincristine, cytarabine, and lomustine was initiated [5]. As L-asparaginase is currently not readily available in Germany, the protocol was started with cytarabine (Cytarabin Accord, Accord Healthcare GmbH, Munich, Germany) at 150 mg/m^2 every 12 h subcutaneously for the following 48 h and prednisolone (Prednisolon, CP-Pharma Handelsgesellschaft mbH, Burgdorf, Germany) per os at 40 mg/m^2 every 24 h. After 7 days of initial treatment,

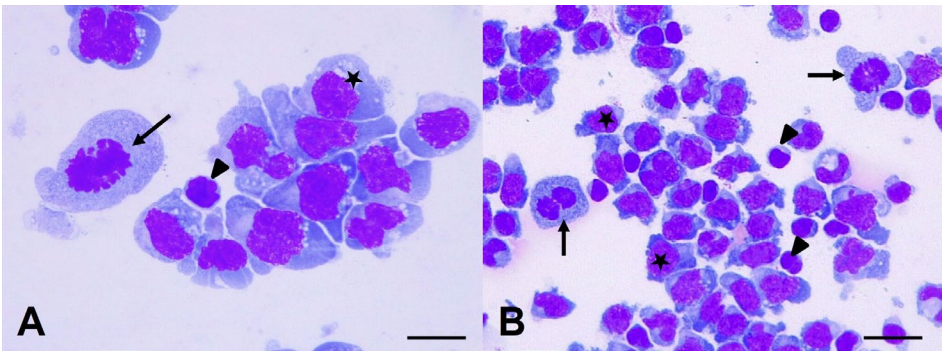

FIGURE 3 | Cerebrospinal fluid showing large round cells (star) with a small amount of moderately basophilic, partly vacuolated cytoplasm. Mitotic figures are also seen (arrow), as well as small lymphocytes (arrow heads; A. Diff Quick, bar = 15 μm, ×1000 magnification; B. Diff Quick, bar = 20 μm, ×400 magnification).

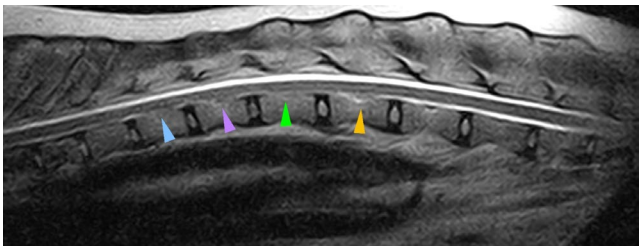

FIGURE 4 | Sagittal T2-weighted magnetic resonance image of the spinal cord (thoracolumbar region) showing a reduced ventral epidural space of Th11-L2 (arrowheads) and a mild enlargement of the central canal in this area.

vincristine (Vincristinsulfat-TEVA, TEVA GmbH, Ulm, Germany) as an intravenous bolus at 0.7 mg/m^2 was administered and prednisolone was reduced to 30 mg/m^2 every 24 h. Seven days later, the dog received lomustine (Cecenu, medac GmbH, Wedel, Germany) at 60 mg/m^2 and a reduced dosage of prednisolone (20 mg/m^2 every 24 h, PO). Maropitant (vetEmex, CP-Pharma Handelsgesellschaft mbH, Burgdorf, Germany) at 1 mg/kg was given either subcutaneously or intravenously with the application of every cytostatic agent. Additionally, maropitant (Cerenia, Zoetis Inc. Kalamazoo, MI 49007, USA) was prescribed for use at home for an extra 2–3 days (2 mg/kg orally every 24 h). During the course of treatment, the dog developed diarrhea in the first (Veterinary Cooperative Oncology group—VCOG grade II) and second week (grade I). The owner administered psyllium (0.5 g/kg/day) and probiotics (SivoMixx, Ormendes SA, Jouxtens-Mézery, Switzerland, 1.5 g/day) until the clinical signs subsided. No neutropenic or thrombocytopenic events were recorded.

At follow-up examination 3 weeks after the start of chemotherapy and 1 week after lomustine administration, the dog showed a clinical deterioration with additional facial paralysis and Horner's syndrome on the left side. Furthermore, the segmental reflexes on the left thoracic limb and both pelvic limbs were completely absent. Due to the progression of the disease, the dog was euthanized.

Postmortem MRI of the brain did not show any additional changes. The spinal cord showed a reduced ventral epidural space from Th11 to L2 and mild enlargement of the central canal in this area (Figures 4 and 5). The CSF cytology showed a mild lymphocytic pleocytosis (TNCC 22/μL, protein content 1840.3 mg/L) with predominantly large, round cells with a medium amount of blue cytoplasm and medium to large, oval nuclei with granulated chromatin (Figure 6).

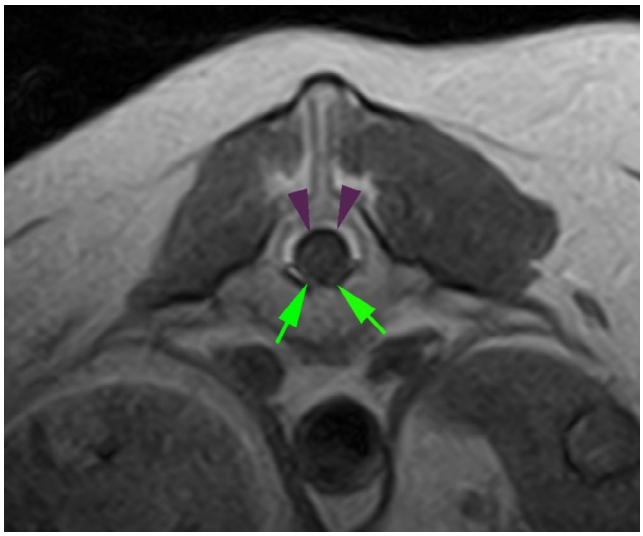

FIGURE 5 | Transversal T1-weighted magnetic resonance image of the first lumbar vertebra showing a reduced ventral epidural space (arrows) in comparison to the dorsal aspect of that space (arrowheads).

The postmortem examination revealed diffuse thickening of the spinal nerve roots and ganglia, as well as a subdural beige mass (0.4 × 0.3 × 0.2 cm) located by the ventral root of the right L6 spinal nerve (Figure 7). Histologically, in the second and third segments of the cervical spinal cord (C2, C3) a moderate subdural infiltration by large lymphocytes was detected. Additionally, a severe to complete subdural and intraneural and intra-ganglionic, diffuse to multifocal, nodular infiltration by lymphoblasts was present in the cervical segments C6 and C7 and the lumbar segments L2, L3, and L6. Representative sections of the sciatic nerve exhibited axonal swellings (spheroids) and Wallerian degeneration of the myelin sheaths. Similar findings were visible in the right brachial plexus, whereas the left brachial plexus showed a diffuse intraneural infiltration by lymphoblasts. These findings were in line with a peripheral nervous system lymphoma (PNSL). Thus, the diagnosis of neurolymphomatosis was confirmed.

The cerebrum had only a few focal lymphocytic perivascular cuffs and mild hemosiderosis. Additionally, multifocal perivascular edema and oligofocal glial nodules, as well as multifocal neuronophagia and satellitosis were visible. Infiltration by large lymphocytes in the leptomeninges, cranial nerves, or brain parenchyma of the cerebrum and cerebellum was not present. Immunohistochemistry for CD3 and PAX5 was performed using a normal lymph node from a dog as a positive biological control and irrelevant antibodies as negative technical controls. The infiltrating large lymphocytes expressed CD3, with no PAX5 immunolabeling. Thus, a T-cell origin was confirmed (Figure 7).

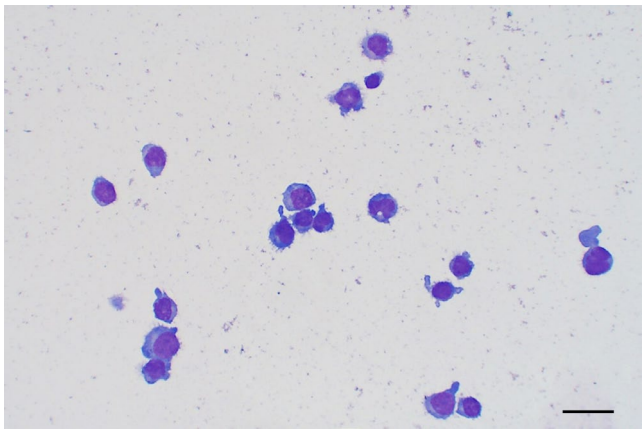

FIGURE 6 | Cerebrospinal fluid tap taken 3 weeks after initiation of chemotherapy showing a low to moderate pleocytosis (TNCC 22/μL, protein content 1840 mg/L) with predominantly large, round cells with a moderate amount of blue cytoplasm and medium to large, round to irregular nuclei with finely granular chromatin (May-Grünwald Giemsa, bar = 25 μm, ×400 magnification; provided by IDEXX Vet Med Labor GmbH, Kornwestheim, Germany).

3 | Discussion

According to the literature, lymphoma of the peripheral nervous system (PNS; neurolymphomatosis) is rarer than the primary, central nervous form in dogs. In the present case, the neoplasm seems to have arisen primarily in the subdural space of spinal nerves and dorsal nerve root ganglia, as no other organ manifestations—in the sense of multicentricity—were identified. The neoplastic cells did not appear to show any tropism for the CNS (spinal cord and brain) and the findings in the cerebrum were likely reactive. The neoplastic cells, however, seem to have spread along the peripheral nerves, as is seen in the example from the left brachial plexus. Additional peripheral nerves showed no infiltration in the segments examined but had lesions (spheroids, Wallerian degeneration) consistent with more proximal nerve damage. It can be assumed that similar histologic changes would have been found in the corresponding nerve roots as well. The diffuse intraneural infiltration by lymphoblasts within the left brachial plexus explains Horner's syndrome, which the dog developed as the disease progressed. Though only speculative in nature, one can assume that the neoplastic cells also invaded the left facial nerve and thereby caused the facial paralyses seen during the course of the disease, as these nerves were not examined histologically.

Neurolymphomatosis is regarded as a rare form of lymphoma affecting peripheral and cranial nerves, as well as spinal nerve

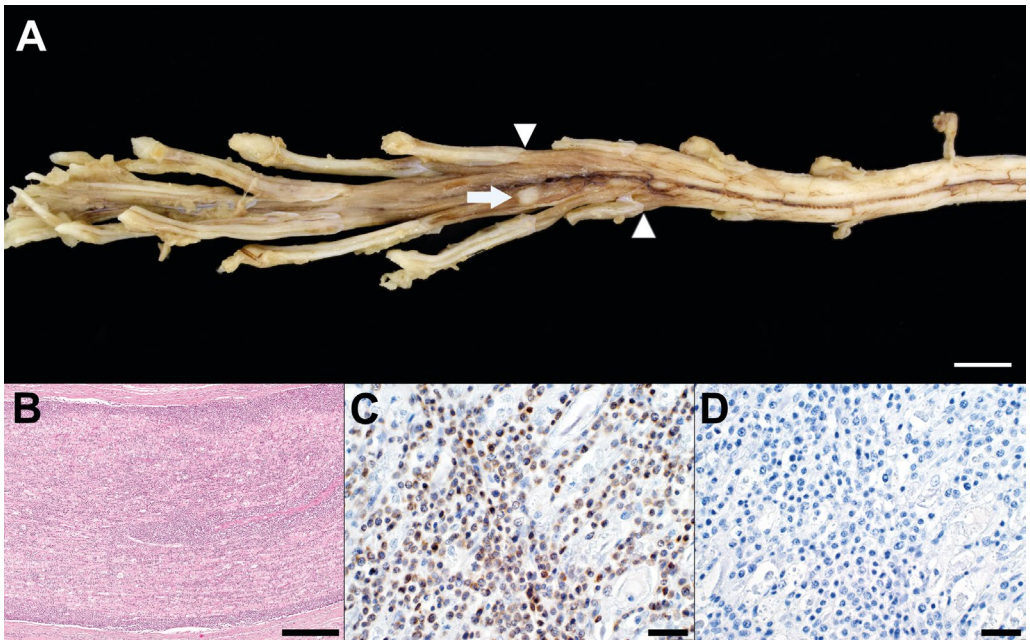

FIGURE 7 | Peripheral nervous system lymphoma (neurolymphomatosis), spinal nerves, dog. (A) The lumbar spinal cord exhibited diffuse thickening of the spinal nerve roots and ganglia. A subdural beige mass (0.4 × 0.3 × 0.2 cm) was located by the ventral root of the right L6 spinal nerve (white arrow). Arrowheads mark the transition from central to peripheral nerve tissue with sudden thickening and beige discoloration of the tissue correlating with the histopathologically detectable tumor cell infiltration, bar = 1 cm. (B) Pathohistology of neoplastic intermediate to large round cells (lymphoblasts) arranged in sheets infiltrating into and expanding the C6 spinal nerve, bar = 500 μm, ×50 magnification. (C) Positive immunhistochemical staining for CD3 (T-cells), bar = 40 μm, ×400 magnification. (D) Negative immunhistochemical staining for PAX5 (B-cells), bar = 40 μm, ×400 magnification.

roots. In humans, it is mainly associated with non-Hodgkin lymphoma or leukemia [1]. However, the canine case described here did not show any abnormalities during the clinical examinations or in the complete blood cell count. Clinical chemistry (including CRP) was also normal. The changes in spleen and abdominal lymph nodes seen on CT scan were non-specific and considered unrelated to the clinical signs. This is also supported by the histopathologic examination of these structures, where no neoplastic cells were detected. Therefore, it is assumed that the PNSL presented here was primary in origin.

The dog was treated with prednisolone, vincristine, cytarabine, and lomustine, according to a chemotherapy protocol successfully applied in the literature in a single case of T-cell lymphoma with spinal involvement [5]. Chemotherapy was overall well tolerated, and the dog did not have to be hospitalized due to adverse events (AEs). The chemotherapy drugs included in this protocol were chosen based on their documented ability of crossing the blood–brain barrier in dogs [6]. In the current case, L-asparaginase was not used due to its unavailability. Previous studies have not shown a survival benefit when using this drug at the time of induction in dogs with multicentric lymphoma as part of a CHOP-based protocol [7]. Cytarabine was used as a 48-h subcutaneous injection, rather than a continuous infusion due to logistic problems concerning the owner [5]. However, plasma levels of this drug are affected by its route of administration, and its steady state and excretion appear to be more rapid after subcutaneous administration [8]. The authors assumed that the steady state achieved with the cytarabine continuous infusion might produce a more prolonged exposure of cytarabine at cytotoxic levels compared to the concentrations after subcutaneous administration. Unfortunately, the clinical signs progressed, and the owners decided not to continue therapy. However, since the CSF findings improved (TNCC and protein content), one could speculate whether a longer treatment period might have led to clinical improvement over time. Additionally, other treatment options such as methotrexate and intrathecal administration of chemotherapeutics, as described in human medicine [1] and recently in a dog with CNS lymphoma [9], might potentially show a more favorable prognosis and should be subjects for future studies.

With a prevalence of 12%–30% in dogs, lymphoma of the CNS as part of a multicentric disease is well known [3]. However, the PNS is less frequently affected [3]. Neurolymphomatosis as a primary disease is uncommon in dogs, with only a few case reports available [2, 3, 10]. When comparing these, the sciatic nerve including its branches seems to be the most affected part of the PNS, followed by spinal roots, spinal nerves, and spinal ganglia [2, 3, 10–12], which is in line with the case presented here.

Electrophysiological assessment including electromyography, nerve conduction studies, and F waves would have been beneficial in examining the structures of the PNS. Unfortunately, the required diagnostical equipment was not readily available. To rule out a multifocal CNS disease, imaging studies were performed. Initial CT and MRI did not reveal any abnormalities that could have explained the clinical presentation of this dog. Except for the thickened left L7 nerve root, CT and MRI did not reveal relevant changes of the nervous system that would explain all the neurological deficits of the dog. This is contrary to the case reports found in the literature, where enlarged nerve roots [10], thickened peripheral nerves, and swollen plexus [10] with contrast enhancement are described. High-field MRI might yield more accurate and precise results; however, the abnormalities described above were found on low-field MRI scans at 0.25 Tesla, similar to the modality used in the present case. The postmortem MRI of the spinal cord showed a reduced ventral subarachnoid and epidural space (Th11-L2) and a mild enlargement of the central canal in this area, which could explain the progression of clinical signs and the severe to complete subdural infiltration by large lymphocytes and partial nodular aggregation in that area. However, no enlargement of the spinal nerves was detectable.

A small number of case reports of neurolymphomatosis in cats are available [13–19]. All cats presented with acute or progressive neurological signs, including lameness, paresis, cranial nerve deficits, ataxia, and seizures. The infiltrating neoplastic cells primarily affected the spinal nerve roots and ganglia, brachial plexus, and cranial nerves. In a case series of 24 feline lymphomas of the nervous system, five were diagnosed as neurolymphomatosis, of which one exhibited both leptomeningeal lymphomatosis and neurolymphomatosis. Here, the optic chiasm was often affected, with B-cell phenotype being the most common. Different immunophenotypes were diagnosed, including T-cell lymphomas [13–15], B-cell lymphomas [15, 16, 19], as well as a lymphoplasmacytic lymphoma [15] and a double-reactive lymphoma [15]. When performed, MRI usually confirmed enlargement of affected nerves, while one case also described CSF cytology as diagnostically useful [14].

In conclusion, neurolymphomatosis is a rare neoplastic disease in dogs and other animals and should be considered as a differential diagnosis for polyneuropathies, even when imaging results are mostly normal. CSF cytology is a useful antemortem diagnostic test which can easily be performed by trained veterinarians without the need for cost-intense equipment.

Disclosure

Authors declare no off-label use of antimicrobials.

Ethics Statement

Approval was given by Anicura Potsdam GmbH for the presentation of one of the clinics patients. Approval was given by IDEXX Vet Med Labor GmbH for the use of Figure 6 provided by them. Authors declare human ethics approval was not needed.

Conflicts of Interest

The authors declare no conflicts of interest.

References

1. S. Grisariu, B. Avni, T. T. Batchelor, et al., "Neurolymphomatosis: An International Primary CNS Lymphoma Collaborative Group Report," *Blood* 115, no. 24 (2010): 5005–5011.

2. P. A. Schaffer, J. B. Charles, L. Tzipory, et al., "Neurolymphomatosis in a Dog With B-Cell Lymphoma," *Veterinary Pathology* 49 (2012): 771–774.

3. N. Fonti, F. Parisi, Ç. Aytaş, S. Degl'Innocenti, and C. Cantile, "Neuropathology of Central and Peripheral Nervous System Lymphoma in Dogs and Cats: A Study of 92 Cases and Review of the Literature," *Animals (Basel)* 13, no. 5 (2023): 862.

4. O. Gaetano, X. Roura, A. Crotti, et al., "Guidelines for Treatment of Leishmaniasis in Dogs," *Journal of the American Veterinary Medical Association* 236, no. 11 (2010): 1192–1198.

5. E. Treggiari and L. P. Arrol, "Clinical Response to a Lomustine/Cytarabine-Based Chemotherapy Protocol in a Case of Canine Large Granular Lymphocyte T-Cell Lymphoma With Spinal Involvement," *Open Veterinary Journal* 8, no. 2 (2018): 154–159.

6. J. C. Scott-Moncrieff, T. C. Chan, M. L. Samuels, et al., "Plasma and Cerebrospinal Fluid Pharmacokinetics of Cytosine Arabinoside in Dogs," *Cancer Chemotherapy and Pharmacology* 29 (1991): 13–18.

7. V. S. MacDonald, D. H. Thamm, I. D. Kurzman, M. M. Turek, and D. M. Vail, "Does L-Asparaginase Influence Efficacy or Toxicity When Added to a Standard CHOP Protocol for Dogs With Lymphoma?," *Journal of Veterinary Internal Medicine* 19 (2005): 732–736.

8. K. I. Crook, P. J. Early, K. M. Messenger, K. R. Muñana, R. Gallagher, and M. G. Papich, "The Pharmacokinetics of Cytarabine in Dogs When Administered via Subcutaneous and Continuous Intravenous Infusion Routes," *Journal of Veterinary Pharmacology and Therapeutics* 36 (2013): 408–411.

9. F. L. S. Lyseight, C. O. C. Dupont, and G. B. Cherubini, "Intrathecal Chemotherapy for the Management of Lymphoblastic Lymphoma in a 4-Year-Old Dog: A Case Report," *Frontiers in Veterinary Science* 10 (2023): 1209935.

10. A. Rupp, E. Ives, H. Rudorf, and F. Constantino-Casas, "Sciatic T-Cell Neurolymphomatosis in a Dog," *Veterinary Record Case Reports* 2 (2014): e000050.

11. H. Uneo, K. Miyoshi, S. Fukui, et al., "Extranodal Lymphoma With Peripheral Nervous System Involvement in a Dog," *Journal of Veterinary Medical Science* 76, no. 5 (2014): 723–727.

12. S. Siso, P. Marco-Salazar, P. F. Moore, et al., "Canine Nervous System Lymphoma Subtypes Display Characteristic Neuroanatomical Patterns," *Veterinary Pathology* 54, no. 1 (2017): 53–60.

13. L. Mandrioli, M. Morini, R. Biserni, F. Gentilini, and M. E. Turba, "A Case of Feline Neurolymphomatosis: Pathological and Molecular Investigations," *Journal of Veterinary Diagnostic Investigation* 24, no. 6 (2012): 1083–1086.

14. Q. Koulil, K. M. Santifirt, M. Beukers, et al., "Neurolymphomatosis in a Cat With Diffuse Neuromuscular Signs Including Cranial Nerve Involvement," *Veterinary Record Case Reports* 10 (2022): e482.

15. M. T. Mandara, A. Domini, and G. Giglia, "Feline Lymphoma of the Nervous System. Immunophenotype and Anatomical Patterns in 24 Cases," *Frontiers in Veterinary Science* 9 (2022): 959466.

16. M. Sakurai, K. Azuma, A. Nagai, et al., "Neurolymphomatosis in a Cat," *Journal of Veterinary Medical Science* 78, no. 6 (2016): 1063–1066.

17. M. J. Beasley, E. C. Hiebert, D. N. Daw, K. J. Alexander, and J. M. Gambino, "Neurolymphomatosis Caused by T-Cell Lymphosarcoma in a Cat: Imaging Description and Treatment Review," *Journal of Feline Medicine and Surgery Open Reports* 5 (2019): 1.

18. C. S. Hsueh, C. Y. Tsai, J. C. S. Lee, et al., "$CD56^+$ B-Cell Neurolymphomatosis in a Cat," *Journal of Comparative Pathology* 169 (2019): 2529.

19. H. Linzmann, L. Brunnberg, A. D. Gruber, and R. Klopfleisch, "A Neurotropic Lymphoma in the Brachial Plexus of a Cat," *Journal of Feline Medicine and Surgery* 11, no. 6 (2009): 522–524.