Journal of Veterinary Internal Medicine

Journal of Veterinary Internal Medicine
Open Access
ACVIM
American College of Veterinary Internal Medicine

STANDARD ARTICLE OPEN ACCESS

Equine Cardiology

Orthodromic Atrioventricular Reentry Bradycardia and Tachycardia Caused by an Accessory Pathway in Horses

Eva Buschmann[1] | Charlotte Easton-Jones[2] | Glenn Van Steenkiste[1] | Hans De Wilde[3] | Veronica Roberts[4] | Mary Durando[5] | Annelies Decloedt[1] | Celia Marr[2] | Gunther van Loon[1]

[1]Equine Cardioteam Ghent, Department of Internal Medicine, Reproduction and Population Medicine, Faculty of Veterinary Medicine, Ghent University, Ghent, Belgium | [2]Rossdales Equine Hospital and Diagnostic Centre, Suffolk, UK | [3]Department of Cardiology, UZ Gent, Ghent University, Ghent, Belgium | [4]Bristol Veterinary School, University of Bristol, Bristol, UK | [5]Rood and Riddle Equine Hospital, Wellington, Florida, USA

Correspondence: Eva Buschmann (eva.buschmann@ugent.be)

Received: 21 February 2025 | **Revised:** 3 June 2025 | **Accepted:** 5 June 2025

Funding: This work was supported by the Bijzonder Onderzoeksfonds UGent (01B05818) and Fonds Wetenschappelijk Onderzoek (1SE9122N).

Keywords: arrhythmias | bypass tract | electrophysiology | equine cardiology

ABSTRACT

Background: Accessory pathways (APs) are muscular bundles directly connecting the atria and ventricles, bypassing the atrioventricular (AV) node-His-Purkinje system. Anterograde conduction along the AP results in ventricular preexcitation. A retrograde conducting AP allows ventriculo-atrial (VA) conduction, creating a reentry circuit that mediates orthodromic atrioventricular reentry tachycardia (OAVRT). This condition is well described in humans and small animals, but has not been reported previously in horses.

Objectives: Describe clinical and electrocardiographic findings of horses with retrograde AP conduction and reporte mapping and radiofrequency ablation results in one horse.

Animals: Six horses with retrograde AP conduction.

Methods: Records from six horses with retrograde AP conduction were reviewed.

Results: Resting ECGs showed P′ waves in the ST segment with fixed coupling intervals to the preceding QRS complexes. In five of six horses, P′ waves were conducted back to the ventricles along the AV node, resulting in OAVRT. All horses had episodes where P′ waves were blocked at the AV node, which resulted in orthodromic atrioventricular reentry bradycardia (OAVRB). In one horse, the AP conducted bidirectionally resulting in ventricular preexcitation. An electrophysiological study in one horse identified a left-atrial AP insertion by the shortest VA interval. Radiofrequency ablation using an impedance-based mapping system could not eliminate the AP.

Conclusions: Retrograde conducting APs in horses caused OAVRT and OAVRB. APs in horses behaved differently compared to those in humans and dogs. Further research is necessary to elucidate AP behavior, evaluate risk and effect on performance, and assess treatment by ablation.

Abbreviations: AP, accessory pathway; AV, atrioventricular; AVNRT, atrioventricular nodal reentry tachycardia; Bpm, beats per minute; ECG, electrocardiogram; OAVRB, orthodromic atrioventricular reentry bradycardia; OAVRT, orthodromic atrioventricular reentry tachycardia; VA, ventriculo-atrial; VCG, vectorcardiogram.

This is an open access article under the terms of the Creative Commons Attribution-NonCommercial-NoDerivs License, which permits use and distribution in any medium, provided the original work is properly cited, the use is non-commercial and no modifications or adaptations are made.

© 2025 The Author(s). *Journal of Veterinary Internal Medicine* published by Wiley Periodicals LLC on behalf of American College of Veterinary Internal Medicine.

1 | Introduction

An accessory pathway (AP) is a strand of functional myocardial cells that connects the atrial and ventricular myocardium across the electrically insulating annulus fibrosus, thereby bypassing the atrioventricular (AV) node-His-Purkinje system [1]. These additional pathways can conduct unidirectionally or bidirectionally in anterograde or retrograde direction [2]. When anterograde conduction along the AP occurs, sinus impulses are conducted from the atria to the ventricles along the AP in addition to the normal conduction over the AV node, resulting in ventricular preexcitation. This conduction is characterized by a short PR interval, abnormal QRS morphology and duration, and a slurred upstroke of the QRS complex, known as a delta wave [3]. Retrograde conduction means that after normal activation and depolarization of the ventricles, the electrical impulse is conducted back to the atria along the AP. This transmission creates a reentry circuit formed by the AV node and AP, which is the substrate for orthodromic atrioventricular reentry tachycardia (OAVRT), a regular, narrow QRS complex tachyarrhythmia [4]. A unidirectional retrograde conducting AP is called a concealed AP and does not result in ventricular preexcitation. Wolff–Parkinson–White syndrome refers to the combination of ventricular preexcitation during sinus rhythm and a tachyarrhythmia [2].

In humans and dogs, the risk of APs is a consequence of the associated arrhythmias, such as pre-excited atrial fibrillation and OAVRT. Humans and dogs with an AP have a higher tendency to develop atrial fibrillation than does the general population. When atrial fibrillation occurs, patients may develop preexcited atrial fibrillation in the presence of an anterograde conducting AP. In this situation, rapid anterograde conduction of fibrillatory waves along the AP can cause a high ventricular response rate, which can deteriorate into ventricular fibrillation and sudden cardiac death [4–7]. Retrograde conducting APs mediate OAVRT, which, in a persistent form, is responsible for tachycardia-induced cardiomyopathy, resulting in congestive heart failure [4, 8]. Intermittent OAVRT leads to episodic weakness and (pre)syncope [2, 8, 9].

Little is known about APs and the associated risk in horses, and only a few cases of anterograde conducting APs have been described [10–13]. Atrial fibrillation with anterograde conduction along an AP was found in one horse and resulted in a markedly increased heart rate at rest [11]. Retrograde conduction along an AP however has not yet been described in horses.

Radiofrequency catheter ablation is the treatment of choice for APs and associated arrhythmias in humans and dogs, with a high success rate and a low complication rate [4, 6, 7, 14]. In equine medicine, radiofrequency ablation has been successfully used to treat atrial tachycardia [15–17] and an AP [10].

Our aims were (1) to describe the clinical and ECG findings of six horses with retrograde conduction along an AP and (2) to report electrophysiological characteristics and radiofrequency ablation results in one horse.

2 | Material and Methods

Medical records of horses with a retrograde conducting AP that were examined in 2010 (Case 1) and between 2017 and 2024 (Cases 2–6) at Strömsholm Equine Referral Hospital, Rossdales Equine Hospital, Rood and Riddle Equine Hospital, Wellington, and the Equine Cardioteam Ghent were reviewed.

If available, data from the general clinical examination, standard echocardiographic examination and serum cardiac troponin I concentration were reported. Retrograde conduction along an AP was diagnosed from a base-apex ECG [18], using the Delta Einthoven configuration [19] or the Dubois lead system [20]. A 24-h ECG was recorded in every horse. During normal sinus rhythm, the PR interval and RR interval of 50 complexes were measured. During OAVRT, the P′R interval, RP′ interval and the RR interval of 50 complexes were measured and during relative bradycardia, the PR interval, RP′ interval and the RR interval of 50 complexes were measured (Figure 1). The number of 50 complexes was chosen arbitrarily. Morphology of the P and P′ waves and QRS complexes was assessed. An exercise test was performed to evaluate the effect of sympathetic tone on AP conduction. Exercise tests were not standardized.

If available, a 12-lead ECG [21] (TLC 5000 or TLC 6000, Contec, Qinhuangdoa, China) was recorded and the derived vectorcardiogram (VCG) of the retrograde conducted P′ waves was calculated (custom made software, Matlab R2018b, Mathworks, Eindhoven, the Netherlands) to identify the approximate origin of the AP [22].

Three-dimensional electroanatomical mapping and radiofrequency catheter ablation using the EnSite Precision Cardiac Mapping System (Abbot, Zaventem, Belgium) were performed in one horse as previously described [16].

3 | Data Analysis

Normality of the continuous variables was evaluated by inspection of histograms and Q-Q plots. Nonnormally distributed data are reported as median (range). Related-samples Friedman's two-way analysis of variance was used to compare the PR interval in sinus rhythm and bradycardia and P′R interval during tachycardia. A p value < 0.05 was considered significant. Statistical analyses were performed using SPSS (SPSS Statistics 25, IBM).

4 | Results

4.1 | Case Histories and Clinical Findings

General information of the horses is presented in Table S1. Horses included a Swedish Warmblood, four Thoroughbreds, and one Arabian, five geldings and one mare, with a median age of 9 (range, 2–13) years and a median weight of 508 (range, 450–640) kg. In all six cases, an irregularly irregular rhythm was noted on auscultation as an incidental finding during either evaluation by a veterinarian at an endurance competition,

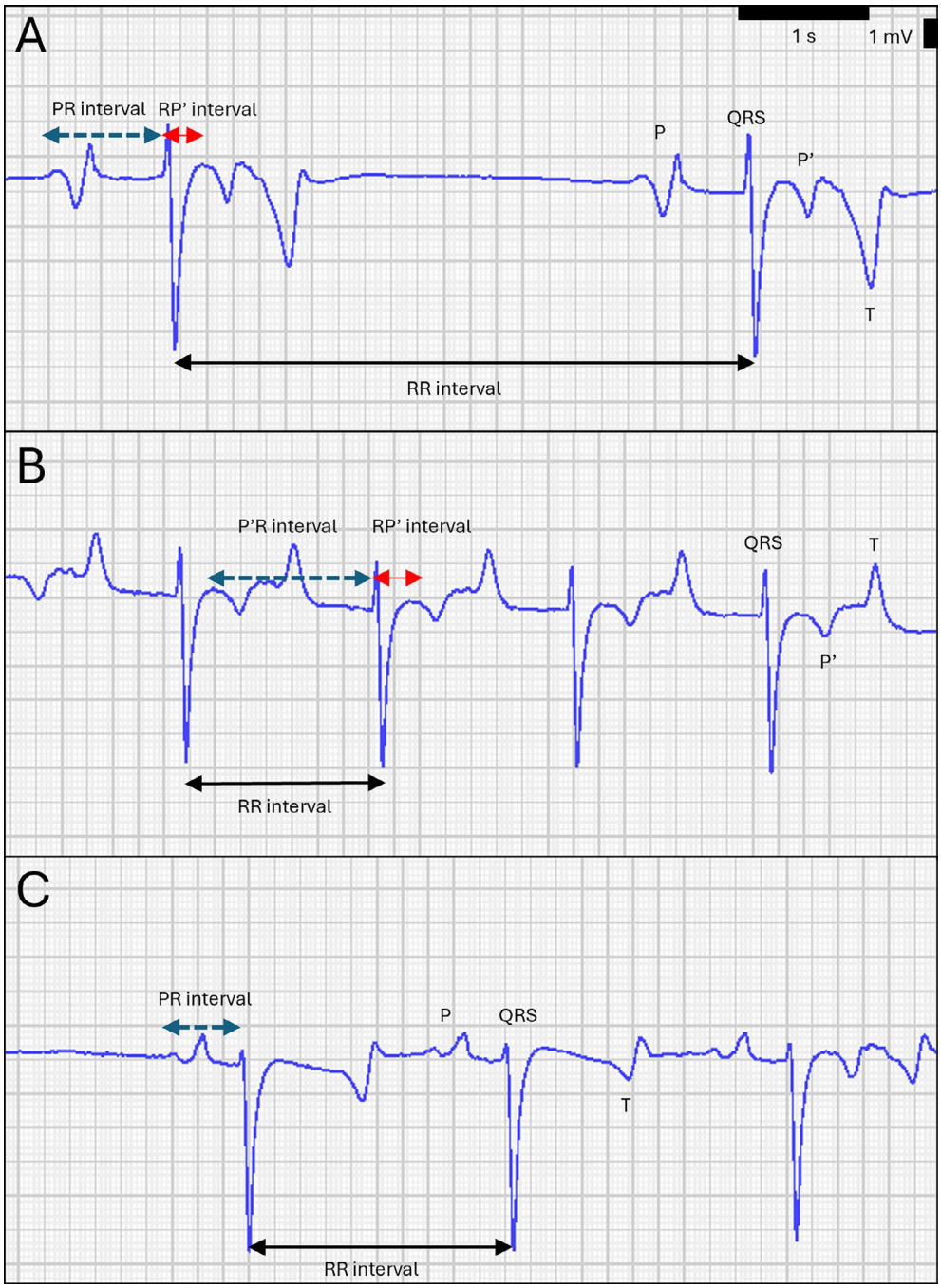

FIGURE 1 | Measurements performed during orthodromic atrioventricular reentry bradycardia (A), orthodromic atrioventricular reentry tachycardia (B) and sinus rhythm (C) are shown.

cardiology teaching session, or a lameness, preanesthetic, or prepurchase examination. Five of six horses did not show any clinical signs, such as exercise intolerance or poor performance. One horse (Case 1) had episodes of agitation and sweating during exercise. In this horse, atrial fibrillation had been diagnosed 2 years earlier as an incidental finding and treated successfully with quinidine sulfate. The ECG tracings after cardioversion were found to be unusual, but no further examinations were performed at that time.

Upon arrival at the clinic, auscultation disclosed an irregularly irregular rhythm in all horses with a heart rate between 30 and 60 beats per minute (bpm). A 2/6 left-sided systolic murmur was noted in three horses (Cases 2, 5, and 6), and a 2/6 right-sided systolic murmur in one horse (Case 6), whereas no murmurs were detected in the other three horses.

Serum cardiac troponin I concentration was determined in four horses (Cases 1, 2, 5, and 6) and was within normal limits for all (< 0.060 ng/mL).

4.2 | Echocardiography

Echocardiographic examination was performed in five of six horses. In four horses, cardiac dimensions and function were

TABLE 1 | Electrocardiographic measurements from all horses, reported as overall median [range], during orthodromic atrioventricular reentry tachycardia (OAVRT), orthodromic atrioventricular reentry bradycardia (OAVRB) and sinus rhythm (SR).

Rhythm	P(′)R interval (ms)	RP′ interval (ms)	RR interval (ms)	HR (beats per minute)
OAVRT	482 [214–598]	182 [110–254]	636 [414–806]	94 [74–145]
OAVRB	408 [254–538]	184 [104–263]	2250 [1190–2930]	27 [21–37]
SR	380 [226–450]	NA	1350 [1010–1830]	45 [33–59]

Note: The P(′)R interval represents conduction through atrioventricular (AV) node, while the RP′ interval represents conduction through the accessory pathway. The PR interval is shown during SR and OAVRB, while the P′R interval is shown for OAVRT. An RP′ interval is not present during SR. Note the shorter RP′ interval compared to the P(′)R interval due to conduction delay in the AV node. RR interval and heart rate (HR) are shown for the three rhythms.

normal. Horse 6 had enlargement of the left atrium and left ventricle, with mild-to-moderate mitral valve regurgitation. Mild pulmonic valve regurgitation, trivial tricuspid, aortic and mitral valve regurgitation were noted in Horse 2, mild mitral valve and trivial aortic valve regurgitation in Horse 3, and moderate aortic valve regurgitation, mild tricuspid and mitral valve and trivial pulmonic regurgitation in Horse 5.

4.3 | Electrocardiography

The resting ECG showed episodes with different conduction patterns. The QRS complexes had normal morphology and duration, except in Horse 6 during occasional episodes of ventricular preexcitation. The P′ waves were inscribed in the ST segment with a fixed coupling interval to the preceding QRS complex. In the majority of horses, the polarity of the P′ waves was opposite to the normal P wave, being negative in lead II. However, in Horse 2, the P′ waves were positive in lead II. Electrocardiographic measurements are shown in Table 1. In five of six horses, these P′ waves were conducted back to the ventricles along the AV node, which resulted in episodes of OAVRT. The RR intervals during periods of OAVRT were regular in all horses (Figure 2A). During episodes of OAVRT, horses did not show any clinical signs. On the other hand, all horses had episodes where the retrograde atrial activation was blocked at the AV node. During these episodes, RR intervals were longer than during sinus rhythm, which can be explained by the fact that the retrograde P′ wave affected the timing of the sinus node discharge. Although in most cases heart rate was not <27 bpm, this resulted in a relative bradycardia (i.e., a slower heart rate in relation to the sinus rate at that moment), and therefore we refer to these episodes as orthodromic atrioventricular reentry bradycardia (OAVRB; Figure 2B). The RR intervals during OAVRB were regular in four horses but varied in the other two. Episodes of OAVRT and OAVRB alternated with normal sinus rhythm, without retrograde P′ waves in the ST segment. Horses 1, 3, and 5 had resting heart rates ≥ 50 bpm during sinus rhythm, which was higher than expected. The P′R interval during OAVRT was significantly longer than the PR interval during sinus rhythm ($p < 0.01$). Alternation between tachycardia, relative bradycardia, and normal sinus rhythm resulted in an irregular rhythm (Figures 2C,D and 3). Duration of the episodes with different conduction patterns was very variable. Normal sinus rhythm, OAVRB or OAVRT occurred as single complexes or episodes varying between several seconds to minutes. Horses 1, 5, and 6 had QRS complexes with abnormal morphology and duration, associated with a preceding P wave (Figure 4). In Horse 1, four abnormal QRS complexes occurred during OAVRT with a P′R interval ranging from 366 to 402 ms. The P′R interval was shortened, no delta wave could be detected and each abnormal QRS complex terminated the tachycardia episode. Therefore, these QRS complexes were most likely ventricular premature complexes. In Horse 5, three abnormal QRS complexes with a PR interval that prolonged progressively from 352, 360, to 436 ms, were noted during normal sinus rhythm. Because of the AV dissociation, these were classified as ventricular premature complexes. However, it remained difficult to be absolutely certain about the origin of these abnormal QRS complexes. In Horse 6, abnormal QRS complexes with a median duration of 177 (range, 164–198) ms (normal QRS duration 131 [range, 116–140 ms]) were noted, with shortened PR interval and PR segment of 310 (range, 302–330) and 42 (range, 34–50) ms, respectively. Delta waves were present, visible as a slurred upstroke of the QRS complex (Figures 2E and 4C). This was classified as ventricular preexcitation because of anterograde conduction along an AP, meaning that the AP in this horse was capable of bidirectional conduction. On average, 148 preexcitation complexes were counted per hour, but these were present in clusters of continuous preexcitation and were interspersed with periods without ventricular preexcitation.

An exercise ECG was performed in four of six horses. In Horse 2, periods of sinus tachycardia alternated with OAVRT at a maximum rate of 167 bpm. In Horses 3 and 5, AP conduction disappeared when heart rate was >51 and 56 bpm, respectively, and reappeared during recovery when heart rate decreased below 66 and 56 bpm, respectively. Maximum heart rate during exercise was 202 bpm in Horse 3 (Thoroughbred on the race track) and 125 bpm in Horse 5 (lunging exercise of an endurance horse). In Case 6, ventricular preexcitation was present at walk and transitioned above a heart rate of 54 bpm into OAVRT with a heart rate of 116 bpm. During trot and canter, OAVRT transitioned into sinus tachycardia with a maximum heart rate of 139 bpm. In Horse 1, an exercise ECG was not obtained because of orthopedic disease. However, any slight stress or exercise, such as walking back from the stocks to the stable, induced OAVRT up to a maximum heart rate of 142 bpm.

To localize the AP, a 12-lead ECG was recorded and a VCG of the retrograde conducted P′ waves was calculated in three horses. In Horse 2, the VCG identified a dorsal, caudal, and right direction of the atrial wavefront, suggesting an AP localized

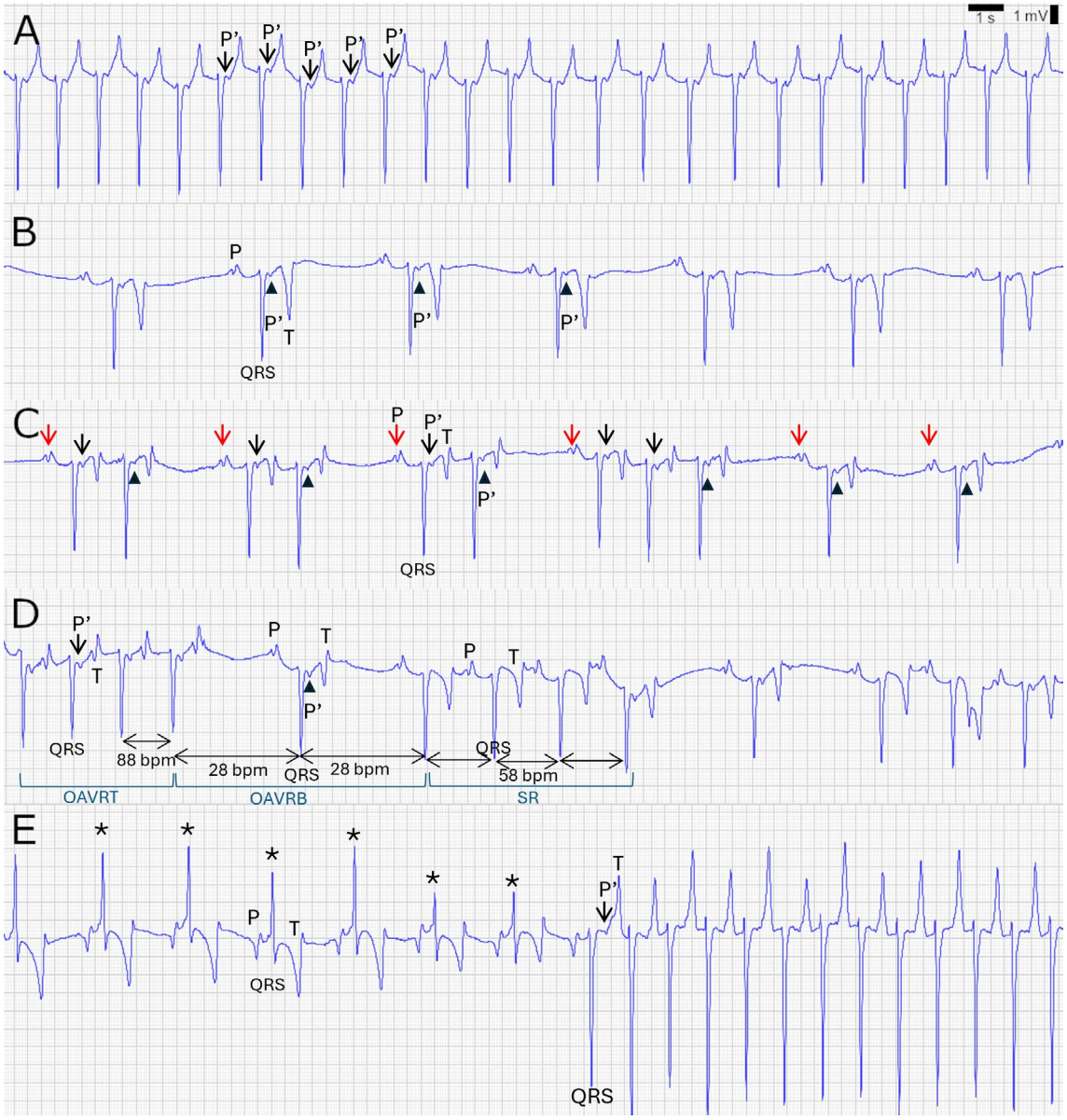

FIGURE 2 | Resting electrocardiogram (A–D) are recorded in Case 5 using the Delta configuration [19], ECG (E) is recorded in Case 6 using the Dubois lead system. (A) ECG during orthodromic atrioventricular reentry tachycardia (OAVRT) at a heart rate of 90 beats per minute (bpm). A reentry circuit is formed by the atrioventricular (AV) node and accessory pathway. The ventricles are depolarized normally (orthodromic) along the AV node, leading to QRS complexes with normal morphology and duration. After ventricular activation, the impulse is conducted back to the atria along the accessory pathway (retrograde conduction). Retrograde conducted P′ waves (black arrows) are visible in the ST segment, have a short and fixed coupling interval with the preceding QRS complex, and conduct via the AV node back to the ventricles. (B) ECG during orthodromic atrioventricular reentry bradycardia (OAVRB) at a heart rate of 28 beats per minute (bpm). Retrograde conducted P′ waves in the ST segment (black arrowheads) are blocked at the level of the AV node. These P′ waves affect sinus node discharge which slows down the heart rate. (C) Irregular rhythm caused by normal sinus depolarizations (P waves: red arrows) that conduct to the ventricles, with retrograde P′ waves (black arrows) that conduct back to the ventricles and retrograde P′ waves (black arrowheads) that do not conduct back to the ventricles because they are blocked at the AV node. (D) On this trace, sinus rhythm (SR) and conduction along the accessory pathway are intermittently present. In the first four complexes, ventricular impulses are conducted to the atria via the accessory pathway and immediately conducted back to the ventricles (black arrow), resulting in OAVRT at a rate of 88 bpm. In the next two complexes, retrograde P′ waves are blocked at the AV node (black arrowhead), causing a relative bradycardia of 28 bpm, which is slower than during SR. The next three complexes are normal SR, without retrograde accessory pathway conduction. During normal sinus rhythm, a heart rate of 58 bpm is present. The relatively high sinus rate might be a compensatory mechanism due to reduced cardiac output or blood pressure during OAVRB. (E) Anterograde conduction along the accessory pathway was present in case 6 and resulted in ventricular preexcitation. The typical ECG characteristics are present in the complexes marked with an asterisk: a shortened PR interval and segment, abnormal QRS morphology and duration with a slurred upstroke of the QRS complex (delta wave). The degree of ventricular preexcitation gradually decreases and changes into orthodromic atrioventricular reentry tachycardia due to retrograde accessory pathway conduction.

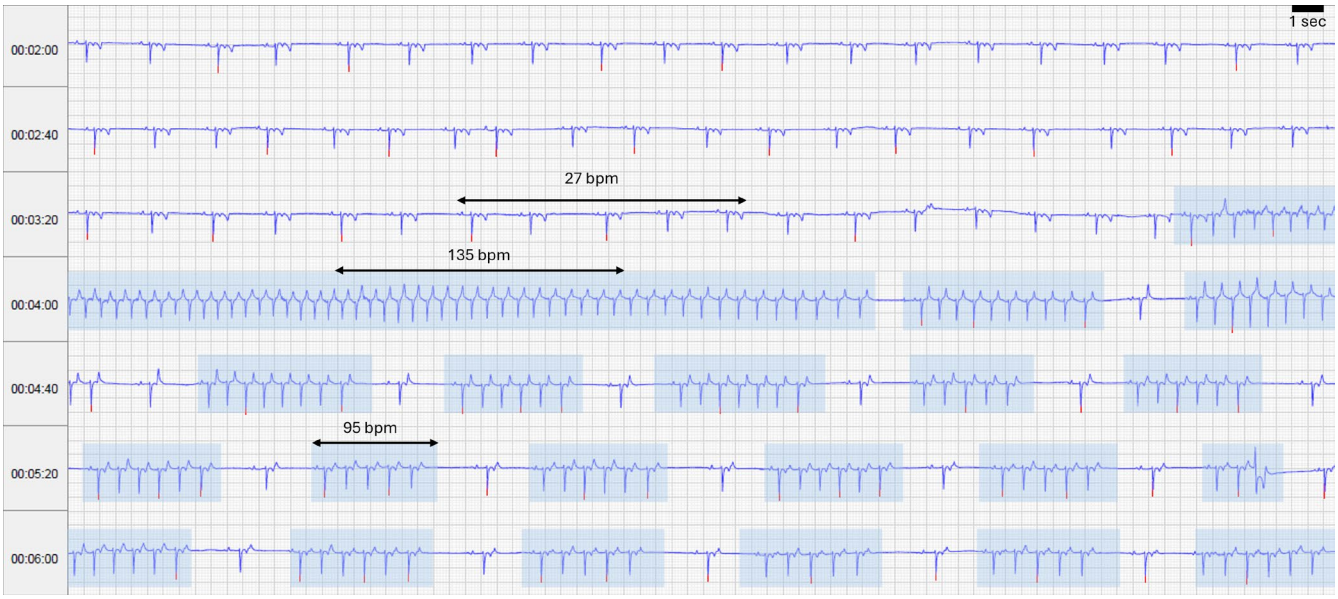

FIGURE 3 | Extract from a 24-h ECG, lead II is shown over a time period of 4 min, at a paper speed of 10 mm/s and gain of 2.5 mm/mV. Retrograde conduction along the accessory pathway is present and results in orthodromic atrioventricular reentry bradycardia or tachycardia. Episodes of relative bradycardia and tachycardia are alternated. Episodes of tachycardia are marked by the blue boxes. Note the sudden onset and offset of tachycardia. Bpm: beats per minute.

ventrally, cranially, and to the left. The VCG of Cases 3 and 5 showed dorsal, cranial, and right depolarization, suggesting a ventral, caudal, and left origin of the AP.

4.4 | Follow-Up

Because of the lack of information regarding APs in horses, in most horses, negative advice was given for riding and competition. Horse 1 was retired and euthanized 6 months after the diagnosis because of worsening lameness and multiple episodes of sweating and agitation. Horse 2 was retired from racing to be a brood mare; Horse 4 was euthanized because it was considered unsafe to race, and Horse 6 was retired. Lower-level ridden exercise with regular monitoring, including auscultation, echocardiography, and exercise ECGs, was allowed only in Horse 3.

In Horse 5, it was decided to perform three-dimensional electroanatomical mapping for localization of the AP, and to attempt radiofrequency catheter ablation using the EnSite Precision Cardiac Mapping System (Abbot, Zaventem, Belgium). Because the VCG suggested a left-sided origin of the AP, 2 days before the ablation procedure, a short electrophysiological study was performed followed by a transseptal puncture under general anesthesia to access the left atrium. The short electrophysiological study consisted of insertion of a decapolar steerable catheter (WEBSTER CS Bi-Directional Catheter, Biosense Webster, Diegem, Belgium) in the coronary sinus and one at the intervenous tubercle in the right atrium. The coronary sinus catheter was inserted deep into the great cardiac vein, thereby measuring left atrial signals. Timing of atrial retrograde signals on the coronary sinus catheter was earlier than on the catheter in the right atrium and was at the onset of the P′ wave, suggesting a left-sided origin. In addition, the electrodes of the coronary sinus catheter showed a proximal-to-distal activation, suggesting a caudal position in the left atrium (Figure 5). After confirmation of the left-sided origin, an intracardiac ultrasound-guided transseptal puncture was performed as previously described [23]. The transseptal puncture opening was dilated using a percutaneous transluminal angioplasty balloon catheter (Mustang PTA Balloon Dilatation Catheter, Boston Scientific) to ensure it remained open for the mapping and ablation procedure. Recovery from general anesthesia was uneventful and 2 days after the transseptal puncture, mapping, and radiofrequency ablation were performed as previously described [16]. Retrograde conduction was not continuously present during anesthesia. Therefore, a decapolar steerable pacing catheter was placed in the right ventricular apex to perform pacing with 15 mA and 2 ms pulse width at a rate of 45 bpm. This resulted in 1:1 ventriculoatrial (VA) conduction via the AP (Figure 6). An 8.5 F bidirectional steerable guiding sheath (Senovo Bi-Flex, Biotronik, Vilvoorde, Belgium) was inserted into the right jugular vein and advanced over a 0.035″ J-tipped guidewire through the previously made transseptal puncture into the left atrium, guided by intracardiac echocardiography. Subsequently, a 7 F loop electrophysiology catheter (Inquiry Optima, Abbott, Zaventem, Belgium) was inserted through the sheath to map the anatomy and activation of the left atrium, focused on the region where the AP was determined by VCG. The region of earliest atrial activation, which indicates atrial AP insertion, could be identified at the left caudo-ventral free wall of the left atrium, as expected from the VCG findings. To localize the AP in more detail, the loop catheter was replaced by an irrigated, bidirectional deflectable ablation catheter (FlexAbility, Abbott, Zaventem, Belgium). The ablation catheter was used to map the earliest atrial electrogram along the mitral annulus in more detail. Correct position on the mitral annulus was confirmed by a VA signal. Subsequently, the

FIGURE 4 | Lead II of the resting electrocardiogram showing QRS complexes with an abnormal QRS morphology recorded in Case 1 (A), Case 5 (B), and Case 6 (C). (A) A QRS complex with abnormal QRS morphology occurs during orthodromic atrioventricular reentry tachycardia and was preceded by the retrograde conducting P′ wave with a shortened P′R interval. No delta wave could be detected. The abnormal QRS complex terminates the tachycardia episode. It is therefore likely that this is a ventricular premature complex. (B) Three abnormal QRS complexes, marked by an asterisk, were preceded by a P wave. The PR intervals were 352, 360, and 436 ms and no delta wave could be identified. Therefore, the complexes were thought to be ventricular premature complexes. (C) Abnormal QRS complexes, associated with a preceding P wave, a short PR interval and PR segment, and a delta wave (slurred upstroke of the QRS complex) indicated ventricular preexcitation due to anterograde conduction along the accessory pathway.

shortest local VA interval was sought, which indicates the AP location and is considered the target for ablation (Figure 7). At this location, with a VA interval of 38 ms, radiofrequency ablation was performed in power-controlled mode and started at a power of 35 W. After 15 s of energy delivery, retrograde AP conduction was not eliminated. Subsequently, multiple catheter repositionings to optimize catheter-tissue contact and locate the shortest VA interval were performed and ablation energy at 40 W was delivered. Twenty-five radiofrequency applications were administered with a median power of 40 (range, 35–40) W for a median duration of 20 (range, 10–59) s. Median impedance drop during the first 10 s of radiofrequency application was 12 (range, 7–54) Ω, indicating effective lesion formation. Despite multiple attempts, AP conduction could not be interrupted. Attempts to perform ablation from the ventricular side were not made because the risk for induction of ventricular fibrillation is currently unknown. The procedure therefore was terminated and all catheters and introducers were carefully withdrawn. The horse recovered well using rope assistance. Because AP conduction was still present, advice was given to avoid competition and only perform low level ridden exercise by an experienced adult rider, and to avoid stressful situations and strenuous effort.

5 | Discussion

Our case series describes OAVRT and OAVRB associated with the presence of an AP in six horses. The effect of vagal tone on the conduction velocity causes different responses in horses compared to humans and small animals because retrograde conduction could result in a relative bradycardia in addition to tachycardia.

In five horses, conduction of electrical impulses along the AP was unidirectional in the retrograde (VA) direction, whereas in one horse bidirectional conduction was present. In dogs, the majority of APs conduct unidirectionally in retrograde fashion [7, 24], whereas bidirectional conduction is more common in people and cats [6, 25]. With a concealed AP, the AP

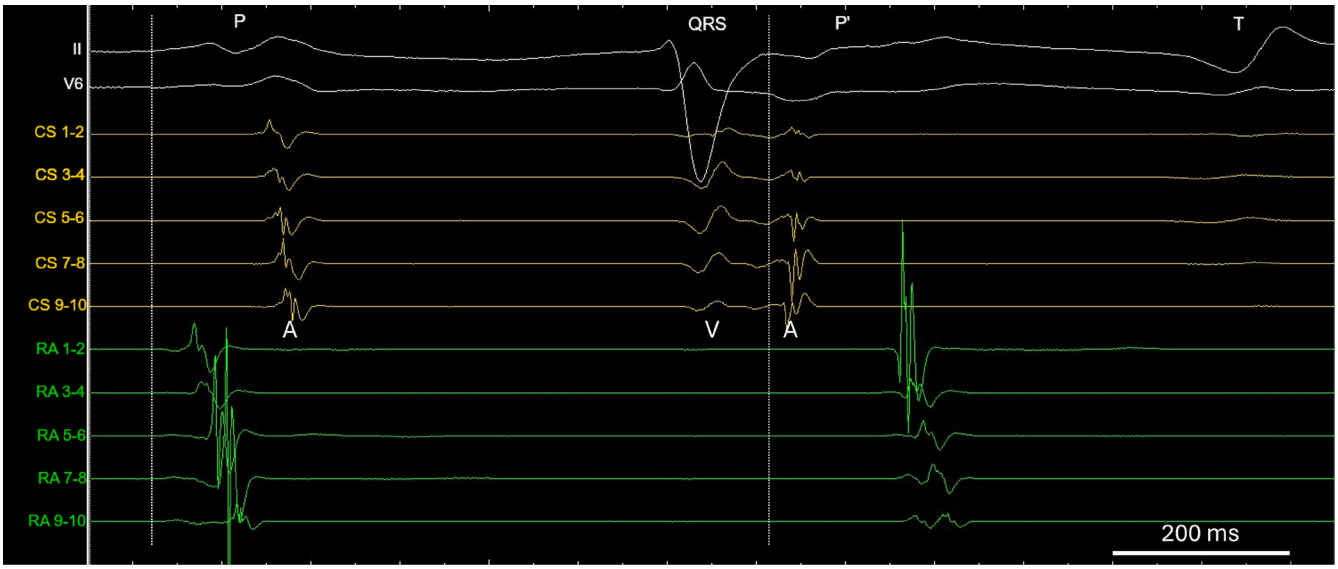

FIGURE 5 | Surface 12-lead ECG lead II and V6 (top white traces), five bipolar electrograms recorded within the coronary sinus (yellow traces) and five bipolar electrograms recorded in the right atrium at the intervenous tubercle (green traces) during a normal (orthodromic) conducted P wave (P wave) and during retrograde accessory pathway conduction (P′ wave) are shown. The coronary sinus catheter is placed deep into the coronary sinus and vena cordis magna, thereby measuring left atrial signals. This catheter records the ventricular activation (V) followed by the retrograde atrial activation (A). Onset of the P and P′ wave are marked by the dashed line. During the normal sinus depolarization, right atrial activation occurs before the coronary sinus activation, and the latter activates from distal (Electrode 1–2) toward proximal (Electrodes 9–10). For the retrograde conducted P′ wave, the coronary sinus activation occurs from proximal to distal and all signals occur much earlier than the right atrial signal. This activation pattern suggests a left-sided origin of the accessory pathway, probably in the caudal left atrium.

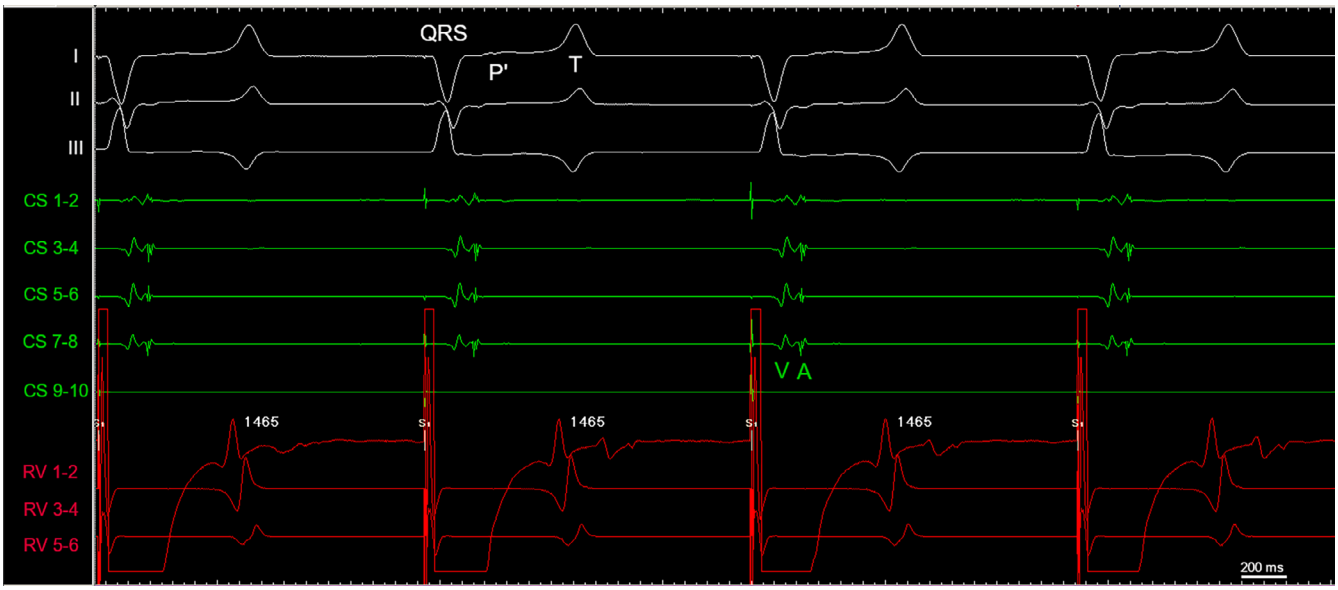

FIGURE 6 | Surface ECG lead I, II, and III (white traces), electrograms recorded within the coronary sinus (five green traces) and electrograms recorded in the right ventricle (three red traces) are shown during ventricular pacing at 15 mA, 2 ms pulse width and a rate of 45 bpm (1465 ms). Electrodes 9–10 from the coronary sinus catheter were still positioned inside the guiding sheath and therefore no electrograms are recorded from these electrodes. Pacing in the right ventricle induced 1:1 ventriculo-atrial conduction along the accessory pathway, which can be noticed on the coronary sinus catheter since the ventricular (V) signal is immediately followed by an atrial (A) signal.

can only conduct retrogradely, meaning that no ventricular preexcitation is present during sinus rhythm. Retrograde conduction is critical for the formation of an anatomical macroreentry circuit by the AP and the AV node. This typically leads to OAVRT, which is the most common arrhythmia associated with APs in humans and dogs. This supraventricular tachycardia results in an ECG pattern characterized by P′ waves with an opposite polarity and a short RP′ interval, typically in the ST segment, a normal QRS morphology, and regular RR intervals. In five cases, retrograde AP conduction resulted in OAVRT, with a median heart rate of 94 bpm. All horses had episodes of relative bradycardia, which occurred

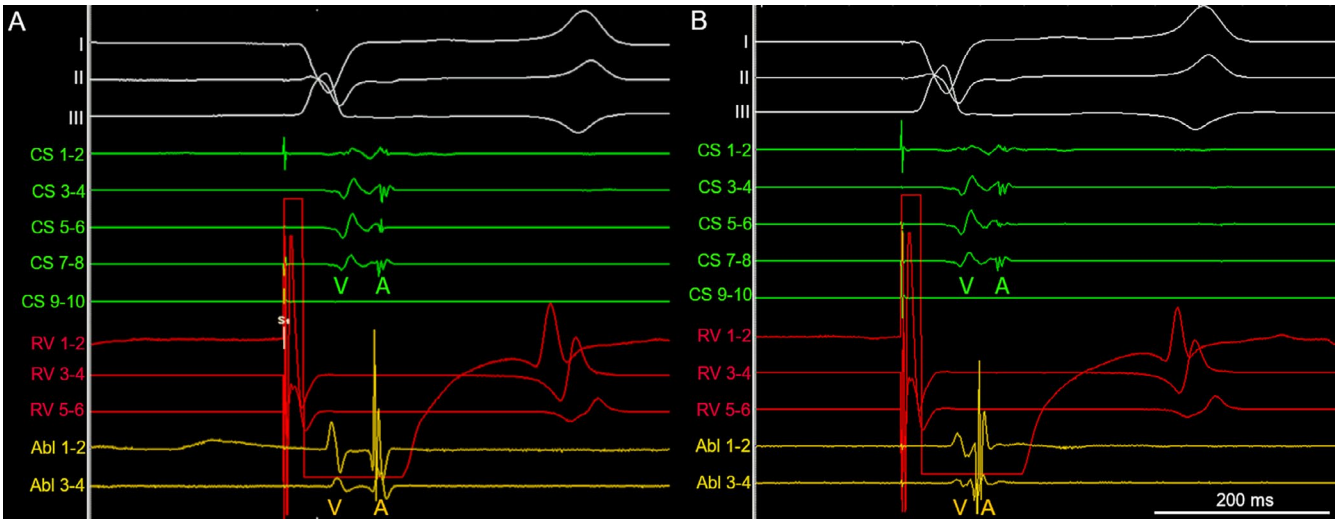

FIGURE 7 | Surface ECG lead I, II and III, electrograms from the coronary sinus catheter (green traces), electrograms from the catheter in the right ventricle (red traces) and electrograms from the ablation catheter (yellow traces) during right ventricular pacing are shown in (A) and (B). The electrograms of the coronary sinus catheter show a ventricular (V) and atrial (A) signal. Electrodes 9–10 from the coronary sinus catheter are positioned in the guiding sheath and therefore no electrograms are recorded from these electrodes. (A) To identify the accessory pathway, the earliest atrial signal is sought, in other words the shortest distance between the ventricular and atrial electrogram. The electrograms recorded by the ablation catheter show a VA signal, which confirms a location on the mitral annulus. The VA interval measures 100 ms. The atrial signal occurs approximately at the same time as the atrial signal recorded in the coronary sinus. (B) The VA interval recorded by the ablation catheter is markedly shorter than in (A) and measures now 40 ms. The atrial signal occurs earlier than the atrial signal recorded in the coronary sinus. The shortest VA interval and earliest atrial signal indicates the accessory pathway location.

when retrograde conducted P′ waves were blocked at the AV node while affecting sinus node discharge. The RR intervals during such periods of OAVRB were regular in four horses but irregular in the other two because of the presence or absence of an effect on sinus node discharge. Relative bradycardia because of retrograde AP conduction has not been reported in humans and dogs. It seems to be a unique feature for APs in horses and can be explained by their high vagal tone. During episodes of sinus rhythm, the sinus rate was ≥ 50 bpm in three horses. This finding might have been a compensatory mechanism because of decreased cardiac output and blood pressure during OAVRB.

Retrograde P′ waves were inscribed in the ST segment, with an RP′ interval that is shorter than the PR interval. The PR interval reflects AV nodal conduction, which undergoes conduction delay because of the decremental properties of the AV node. The RP′ interval is the result of retrograde impulse conduction along the AP, which has a high conduction velocity and therefore results in a short RP′ interval. In people, the RP′ interval remains constant, regardless of the tachycardia cycle length, because of the nondecremental conduction properties of the AP. Such was also the case in these horses, where the RP′ interval remained constant during episodes of tachycardia and relative bradycardia (182 and 184 ms, respectively).

Only a few cases of anterograde conducting APs have been reported in horses [10–13], but ours is the first case series describing APs capable of retrograde conduction. There is, however, one case report describing P′ waves in the ST segment with a fixed coupling interval with the preceding QRS complex [26]. These P′ waves also resulted in episodes of tachycardia and relative bradycardia. The authors attributed this finding to retrograde VA conduction along the AV node, but a concealed AP also might be present in this case. This finding demonstrates that this condition can be difficult to recognize and might be more common than currently thought. Conduction along the AP can be intermittent, which makes it easy to miss on an ambulatory ECG. The mechanism of intermittent AP conduction is poorly understood in human medicine and several hypotheses have been proposed related to the AP refractory period and cellular connectivity within the AP. Potential mechanisms include a Phase 3 (tachycardia-dependent) or Phase 4 (bradycardia-dependent) block in the AP, a long effective refractory period of the AP, or the effect of autonomic tone [2]. A regular rhythm on auscultation is possible because RR intervals during tachycardia or relative bradycardia episodes are mostly regular. The alternation between sinus rhythm, tachycardia, and relative bradycardia causes the irregular rhythm. Retrograde P′ waves in the ST segment can be mistaken for frequent atrial premature depolarizations. Distinction can be made based on the short and fixed coupling interval with the preceding QRS complex, which is not typical for atrial premature beats. Another differential diagnosis in our horses was atrioventricular nodal reentry tachycardia (AVNRT). This arrhythmia develops along an anatomical reentry circuit that includes the AV node and surrounding atrial tissue. The circuit is formed by a fast AV nodal pathway with a long refractory period and a slow pathway with a short refractory period [3]. This condition has not yet been described in horses and has not been clinically identified in dogs [3]. In human medicine, typical ECG characteristics of AVNRT include a regular narrow QRS tachycardia and a P′ wave constantly related to the QRS complex. In the majority of cases, the P′ wave is indiscernible and masked by the QRS complex, or seen as a distortion of

the terminal portion of the QRS complex [27, 28]. Differentiation between AVNRT and OAVRT can be difficult and VCG analysis or an electrophysiology study might be required.

A VCG was available in three horses and showed a left origin of the AP in all three. Two horses had a similar VCG and indicated a left, cranioventral origin, whereas in the other horse a left, caudoventral origin was indicated. In dogs, most of the APs are located in the right free wall and postero-septal areas [24], whereas in human patients APs are most often located in the left free wall and postero-septal areas [29].

In humans and dogs, OAVRT manifests as a rapid tachycardia with rates ranging from 150 to > 250 bpm [2, 3]. Incessant OAVRT causes tachycardia-induced cardiomyopathy, resulting in congestive heart failure [4, 8]. Intermittent OAVRT leads to episodic weakness and (pre)syncope [2, 8, 9]. The tachycardia rate is largely determined by conduction time and functional refractory period of the AV node [30]. In our horses, a rapid tachycardia was prevented because of AV nodal delay, leading to a significantly longer P′R interval of 482 ms, compared with 380 ms in sinus rhythm ($p < 0.01$). This difference probably prevented clinical signs in five of six horses. One horse, however, showed episodes of agitation and sweating during exercise. This horse had a median heart rate of 85 bpm during OAVRT at rest, but slight stress or exercise led to OAVRT at a rate of 142 bpm. The episodes of sweating and agitation could have been associated with OAVRT at higher rates, possibly caused by increased AV nodal conduction. However, ECG recordings during such episodes were not available.

People and dogs with APs have a higher tendency to develop atrial fibrillation than the general population, particularly, in anterograde conducting APs [5, 7, 31, 32]. The mechanisms of AF in patients with APs are not well understood. A possible explanation is that the rapid atrial rate during OAVRT can cause disruption in atrial activation and reactivation, creating a substrate for atrial fibrillation [2, 24]. Most patients with an AP and atrial fibrillation who undergo ablation of the AP are cured of both the AP and atrial fibrillation [2]. The presence of atrial fibrillation with rapid anterograde conduction along an AP has been described in horses [11] and one of the horses in our case series had a history of atrial fibrillation. Anterograde conduction of atrial fibrillation along the AP may be life-threatening because it can result in a very rapid ventricular response rate, degenerating into ventricular fibrillation and sudden cardiac death [5]. Concealed APs are not associated with an increased risk of sudden cardiac death, because rapid anterograde conduction is not possible [14]. Nonetheless, OAVRT in human athletes may cause dizziness and exhaustion that require cessation of exercise. Athletes with OAVRT should stop exercise in the event of palpitations because rapid heart rates may cause (pre)syncope. If OAVRT is only sporadic and without hemodynamic consequences, exercise is only allowed when there is no increased risk of fatality from potential loss of consciousness [9]. If there is an increased risk, treatment by ablation is advised, as well as if competitive athletic activity is desired or in patients with symptomatic and recurrent OAVRT [6–9]. The risk of concealed APs in horses is not known yet, but the median heart rate during OAVRT in these horses was limited to 94 bpm and increased during stress or exercise to 167 and 142 bpm in two horses. Horses can show large changes in autonomic tone as part of their flight response, which might enhance conduction velocity and influence the conduction pattern of the AP, AV node, or both. Whether or not such changes could result in (pre)syncope in horses and the risks for horse and rider are currently unknown. Horse 6 had a bidirectional conducting AP, showing ventricular preexcitation in addition to OAVRT and OAVRB. This horse therefore likely has an increased risk of sudden cardiac death in the event that preexcited atrial fibrillation were to occur. Careful consideration should be given in every case as to whether ventricular preexcitation is present because it has an impact on estimating the risk for horse and rider.

Mapping and ablation of the AP only was attempted in one horse. Ventricular pacing induced continuously retrograde atrial activation along the AP, allowing identification of the atrial insertion of the AP as the site with the shortest VA interval. Catheter ablation is the treatment of choice for OAVRT in humans and dogs, with a high success rate and a low complication rate [4, 6, 7, 14]. An anterograde conducting AP has been successfully treated in a horse by radiofrequency ablation [10]. The AP in our horse however could not be eliminated. Failure of ablation in human patients occurs in 1%–5% of cases [33, 34]. The main reasons for failure are inaccurate mapping and catheter instability [33–36]. Accessory pathway conduction should be interrupted after 5–6 s of radiofrequency energy delivery. If no effect is observed, energy delivery is discontinued and a site with better timing is sought, or the catheter is adjusted to achieve better catheter-tissue contact [2, 37]. Contact force-sensing catheters allow real-time assessment of the catheter-tissue contact [38, 39]. They have been used successfully in horses [10, 16, 17, 40] and had an advantage in achieving sufficient contact. Because contact force could not be monitored in our case, poor catheter-wall contact could have impaired energy delivery to the myocardium and resulted in failure to destroy the AP. However, indirect parameters that assess contact force, such as impedance decrease during energy delivery, suggested sufficient wall contact. Indeed, a large impedance decrease, such as 8–10 Ω within the first 10 s, indicates good wall contact [41] and for our horse, a median impedance decrease of 12 Ω was reached. Another explanation for treatment failure is that the AP could have had a deep myocardial or epicardial location. Because of the atrial wall thickness in horses, the ablation lesions might not have reached a deeply located AP. Ablation from the ventricular side might have been an option to reach the AP, but this approach can be a risk for inducing ventricular fibrillation and was therefore not performed. Other causes of ablation failure are inaccurate localization of an oblique course of the AP, a broad atrial insertion, or the presence of multiple APs [2]. However, the AP in our case could be identified by the shortest local VA interval, indicating good catheter position.

Limitations of our study are related to its retrospective design, lack of standardization in the diagnostic evaluation by different clinicians and small sample size. More advanced electrophysiological studies were not performed at the time of presentation but would have been useful to confirm absence of anterograde AP conduction and to measure effective refractory periods of the AP and AV node. Additional electrophysiological studies, including pharmacological stress testing and exercise tests, are needed to gain better insight into AP

behavior in horses and to provide proper risk assessment and advice to the owner.

In conclusion, we present six cases of retrograde conduction along an AP in horses resulting in episodes of OAVRT but also in episodes of relative bradycardia, which seems to be a unique finding in horses. In one horse, bidirectional conduction was present, resulting in episodes of ventricular preexcitation, OAVRT and OAVRB. In one horse, the AP could be localized by mapping the mitral annulus and was identified at the site with the shortest local VA interval. However, ablation of the AP from the atrial side failed to eliminate AP conduction.

Acknowledgments

Eva Buschmann is a PhD fellow funded by the Research Foundation Flanders (FWO Vlaanderen; Grant 1SE9122N). Funding was received for ultrasound equipment by the Special Research Fund Ghent University (Grant 01B05818).

Disclosure

Authors declare no off-label use of antimicrobials.

Ethics Statement

Based on retrospective data from cases authors declare no institutional animal care and use committee or other approval was needed. Authors declare human ethics approval was not needed.

Conflicts of Interest

The authors declare no conflicts of interest.

References

1. R. H. Anderson, S. Y. Ho, P. C. Gillette, and A. E. Becker, "Mahaim, Kent and Abnormal Atrioventricular Conduction," *Cardiovascular Research* 31 (1996): 480–491.

2. Z. M. Issa and D. P. Zipes, "Typical Atrioventricular Bypass Tracts," in *Clinical Arrhythmiology and Electrophysiology*, 3th ed., ed. J. M. Issa (Elsevier, 2019), 599–676.

3. R. A. Santilli, S. Moïse, R. Pariaut, et al., *Electrocardiography the Dog and Cat: Diagnosis of Arrhythmias*, 2nd ed. (Edra S.p.A., 2018), 347.

4. K. N. Wright, C. E. Connor, H. M. Irvin, T. K. Knilans, D. Webber, and P. H. Kass, "Atrioventricular Accessory Pathways in 89 Dogs: Clinical Features and Outcome After Radiofrequency Catheter Ablation," *Journal of Veterinary Internal Medicine* 32 (2018): 1517–1529.

5. O. A. Centurión, A. Shimizu, S. Isomoto, et al., "Mechanisms for the Genesis of Paroxysmal Atrial Fibrillation in the Wolff—Parkinson—White Syndrome: Intrinsic Atrial Muscle Vulnerability vs. Electrophysiological Properties of the Accessory Pathway," *EP Europace* 10 (2008): 294–302.

6. J. Brugada, D. G. Katritsis, E. Arbelo, et al., "2019 ESC Guidelines for the Management of Patients With Supraventricular Tachycardia," *European Heart Journal* 41 (2020): 655–720.

7. R. A. Santilli, M. M. Pañero, D. M. P. Vázquez, et al., "Radiofrequency Catheter Ablation of Accessory Pathways in the Dog: The Italian Experience (2008-2016)," *Journal of Veterinary Cardiology* 20 (2018): 384–397.

8. R. A. Santilli, G. Spadacini, P. Moretti, et al., "Radiofrequency Catheter Ablation of Concealed Accessory Pathways in Two Dogs With Symptomatic Atrioventricular Reciprocating Tachycardia," *Journal of Veterinary Cardiology* 8 (2006): 157–165.

9. A. Pelliccia, S. Sharma, S. Gati, et al., "2020 ESC Guidelines on Sports Cardiology and Exercise in Patients With Cardiovascular Disease," *European Heart Journal* 42 (2021): 17–96.

10. E. Buschmann, G. Van Steenkiste, T. Boussy, et al., "Three-Dimensional Electro-Anatomical Mapping and Radiofrequency Ablation as a Novel Treatment for Atrioventricular Accessory Pathway in a Horse: A Case Report," *Journal of Veterinary Internal Medicine* 37 (2023): 728–734.

11. S. A. Jesty, M. S. Kraus, A. L. Johnson, A. R. M. Gelzer, and J. Bartol, "An Accessory Bypass Tract Masked by the Presence of Atrial Fibrillation in a Horse," *Journal of Veterinary Cardiology* 13 (2011): 79–83.

12. W. W. Muir and S. M. Mcguirk, "Ventricular Preexcitation in 2 Horses," *Journal of the American Veterinary Medical Association* 183 (1983): 573–576.

13. J. Viu, L. Armengou, A. Decloedt, and E. Jose-Cunilleras, "Investigation of Ventricular Pre-Excitation Electrocardiographic Pattern in Two Horses: Clinical Presentation and Potential Causes," *Journal of Veterinary Cardiology* 20 (2018): 213–221.

14. L. W. M. Leung and M. M. Gallagher, "Review Paper on WPW and Athletes: Let Sleeping Dogs Lie?," *Clinical Cardiology* 43 (2020): 897–905.

15. G. Van Steenkiste, T. Boussy, M. Duytschaever, et al., "Detection of the Origin of Atrial Tachycardia by 3D Electro-Anatomical Mapping and Treatment by Radiofrequency Catheter Ablation in Horses," *Journal of Veterinary Internal Medicine* 36 (2022): 1481–1490.

16. E. Buschmann, G. Van Steenkiste, I. Vernemmen, et al., "Lesion Size Index-Guided Radiofrequency Catheter Ablation Using an Impedance-Based Three-Dimensional Mapping System to Treat Sustained Atrial Tachycardia in a Horse," *Equine Veterinary Journal* 57 (2024): 1009–1016.

17. E. Buschmann, G. Van Steenkiste, I. Vernemmen, et al., "Caudal Vena Cava Isolation Using Ablation Index-Guided Radiofrequency Catheter Ablation (CARTO 3) to Treat Sustained Atrial Tachycardia in Horses," *Journal of Veterinary Internal Medicine* 39 (2025): 39, https://doi.org/10.1111/jvim.17251.

18. T. Verheyen, A. Decloedt, D. De Clercq, et al., "Electrocardiography in Horses—Part 1: How to Make a Good Recording," *Vlaams Diergen Tijds* 79 (2010): 331–336.

19. E. Paulussen, G. Van Steenkiste, B. M. Hermans, et al., "Einthoven's Triangle Adapted for Horses: Proposal for the Delta Configuration," *Journal of Veterinary Internal Medicine* 38 (2024): 2698–2706.

20. C. F. da Costa, N. Samesima, and C. A. Pastore, "Cardiac Mean Electrical Axis in Thoroughbreds—Standardization by the Dubois Lead Positioning System," *PLoS One* 12 (2017): e0169619.

21. G. van Loon and A. Decloedt, "Arrhythmias and Abnormalities of the Cardiac Conduction System in Athletic Horses," in *Equine Sports Medicine and Surgery*, 3rd ed., ed. K. Hinchcliff, A. Kaneps, R. Geor, and E. van Erck-Westergem (Elsevier, 2024), 831–865.

22. G. Van Steenkiste, T. Delhaas, B. Hermans, et al., *An Exploratory Study on Vectorcardiographic Identification of the Site of Origin of Focally Induced Premature Depolarizations in Horses, Part I: The Atria* (Atria. Animals, 2022), 12.

23. I. Vernemmen, G. Van Steenkiste, E. Buschmann, et al., "Development of an Atrial Transseptal Puncture Procedure in Horses to Access the Left Heart: An Ultrasound-Guided Jugular Vein and Transhepatic Approach," *Equine Veterinary Journal* 57 (2025): 243–255.

24. R. A. Santilli, G. Spadacini, P. Moretti, et al., "Anatomic Distribution and Electrophysiologic Properties of Accessory Atrioventricular Pathways in Dogs," *Journal of the American Veterinary Medical Association* 231 (2007): 393–398.

25. E. A. Gavic, C. D. Stauthammer, A. K. Masters, et al., "Clinical, Electrocardiographic, and Diagnostic Imaging Features and Outcomes

in Cats With Electrocardiographic Diagnosis of Ventricular Pre-Excitation: A Retrospective Study of 23 Cases (2010-2022)," *Journal of Veterinary Cardiology* 56 (2024): 97–109.

26. T. Senta, A. Amada, and Y. Hirano, "A Case Report on Atrial Return Extrasystole (Atrial Echo) in the Thoroughbred," *Experimental Reports of Equine Health Laboratory* 7 (1970): 75–83.

27. D. G. Katritsis and F. Morady, "Atrioventricular Junctional Tachycardias," in *Clinical Cardiac Electrophysiology: A Practical Guide*, 1st ed., ed. D. G. Katritsis and F. Morady (Elsevier, 2021), 252–275.

28. Z. F. Issa, J. M. Miller, and D. P. Zipes, "Atrioventricular Nodal Reentrant Tachycardia," in *Clinical Arrhythmiology and Electrophysiology*, 3th ed., ed. D. P. Zipes (Elsevier, 2019), 560–598.

29. D. J. Fox, G. J. Kein, A. C. Skanes, et al., "How to Identify the Location of an Accessory Pathway by the 12-Lead ECG," *Heart Rhythm* 5 (2008): 1763–1766.

30. D. R. Holmes, G. O. Hartzler, and J. D. Maloney, "Concealed Retrograde Bypass Tracts and Enhanced Atrioventricular Nodal Conduction—An Unusual Subset of Patients With Refractory Paroxysmal Supraventricular Tachycardia," *American Journal of Cardiology* 45 (1980): 1053–1060.

31. M. Chen, X. Feng, J. Sun, et al., "Risk Factors Responsible for Atrial Fibrillation Development Between Symptomatic Patients With Concealed or Manifest Atrioventricular Accessory Pathways," *IJC Heart & Vasculature* 7 (2015): 69–75.

32. L. Ma, Y. Li, Y. Wang, X. Wang, J. Kong, and L. Wang, "Relationship Between Accessory Pathway Location and Occurrence of Atrial Fibrillation in Patients With Atrioventricular Re-Entrant Tachycardia," *Experimental and Clinical Cardiology* 9 (2004): 196–199.

33. F. Sacher, M. Wright, U. B. Tedrow, et al., "Wolff-Parkinson-White Ablation After a Prior Failure: A 7-Year Multicentre Experience," *Europace* 12 (2010): 835–841.

34. T. Yamane, P. Jaïs, D. C. Shah, et al., "Efficacy and Safety of an Irrigated-Tip Catheter for the Ablation of Accessory Pathways Resistant to Conventional Radiofrequency Ablation," *Circulation* 102 (2000): 2565–2568.

35. M. L. Chen, B. Yang, W. Z. Ju, et al., "Right-Sided Free Wall Accessory Pathway Refractory to Conventional Catheter Ablation: Lessons From 3-Dimensional Electroanatomic Mapping," *Journal of Cardiovascular Electrophysiology* 21 (2010): 1317–1324.

36. F. Morady, S. A. Strickberger, K. C. Man, et al., "Reasons for Prolonged or Failed Attempts at Radiofrequency Catheter Ablation of Accessory Pathways," *Journal of the American College of Cardiology* 27 (1996): 683–689.

37. K. N. Wright, T. K. Knilans, and H. M. Irvin, "When, Why, and How to Perform Cardiac Radiofrequency Catheter Ablation," *Journal of Veterinary Cardiology* 8 (2006): 95–107.

38. S. A. Virk, J. Ariyaratnam, R. G. Bennett, and S. Kumar, "Updated Systematic Review and Meta-Analysis of the Impact of Contact Force Sensing on the Safety and Efficacy of Atrial Fibrillation Ablation: Discrepancy Between Observational Studies and Randomized Control Trial Data," *Europace* 21 (2019): 239–249.

39. A. Natale, V. Y. Reddy, G. Monir, et al., "Paroxysmal AF Catheter Ablation With a Contact Force Sensing Catheter Results of the Prospective, Multicenter SMART-AF Trial," *Journal of the American College of Cardiology* 64, no. 7 (2014): 647–656.

40. E. Buschmann, G. Van Steenkiste, M. Duytschaever, et al., "Successful Caudal Vena Cava and Pulmonary Vein Isolation in Healthy Horses Using 3D Electro-Anatomical Mapping and a Contact Force-Guided Ablation System," *Equine Veterinary Journal* 56 (2023): 1068–1076.

41. T. Reichlin, S. Knecht, C. Lane, et al., "Initial Impedance Decrease as an Indicator of Good Catheter Contact: Insights From Radiofrequency Ablation With Force Sensing Catheters," *Heart Rhythm* 11 (2014): 194–201.

Supporting Information

Additional supporting information can be found online in the Supporting Information section.