Journal of Veterinary Internal Medicine

Journal of Veterinary Internal Medicine
Open Access
ACVIM
American College of Veterinary Internal Medicine

CASE REPORT OPEN ACCESS

Food & Fiber Animal Hematology

Clinical Presentation and Diagnosis of Multisystemic Eosinophilic Epitheliotropic Disease in a Miniature Donkey: A Case Report

Carla K. Enriquez | Alicia E. Long | Cristobal Navas de Solis | Perry L. Habecker | Rose Nolen-Walston

Department of Clinical Studies, University of Pennsylvania New Bolton Center Hospital for Large Animals, Kennett Square, Pennsylvania, USA

Correspondence: Carla K. Enriquez (cenriqu@vet.upenn.edu)

Received: 7 January 2025 | **Revised:** 3 June 2025 | **Accepted:** 4 June 2025

Funding: The authors received no specific funding for this work.

Keywords: eosinophilia | eosinophilic disorder | hepatopathy | MEED | pruritus

ABSTRACT

A 21-year-old miniature donkey gelding was evaluated for pruritus, inappetence, hypertriglyceridemia, and alopecia of 2 weeks' duration. Hematology showed moderate eosinophilia, severe hypertriglyceridemia, and moderately increased liver enzyme activities. Cytologic evaluation of peritoneal fluid identified an eosinophilic transudate. The donkey was treated with antihistamines, anthelmintics, IV fluids with dextrose as a constant rate infusion, and insulin. The miniature donkey was euthanized because of the development of laminitis. Lesions associated with multisystemic eosinophilic epitheliotropic disease (MEED) were identified at necropsy.

1 | Case Description

1.1 | History

A 21-year-old miniature donkey gelding was presented on emergency to the New Bolton Center Widener Hospital for Large Animals at the University of Pennsylvania for pruritus, inappetence, hypertriglyceridemia, and increased liver enzyme activities. Pruritus with secondary alopecia had been first identified 2 weeks earlier. Ten days earlier, pruritus prompted evaluation on the farm, and cetirizine was initiated for suspected atopic dermatitis, and resulted in no improvement. Thereafter, the donkey had developed progressive inappetence. Hematology and serum biochemistry results on the day of presentation disclosed leukocytosis (17.42×10^3 cells/μL; reference interval [RI], 5.00–12.00×10^3 cells/μL), marked eosinophilia (8.91×10^3 cells/μL; RI, 0.1–0.9×10^3 cells/μL) [1], markedly increased gamma glutamyl transferase activity (GGT, 796 U/L; RI, 14–69 U/L), mildly increased aspartate aminotransferase activity (AST, 612 U/L; RI, 238–536 U/L) and severe hypertriglyceridemia (970 mg/dL; RI, 52.5–245 mg/dL) [1]. The donkey had been diagnosed with pars pituitary intermedia dysfunction (PPID) a year earlier based on a positive thyrotropin-releasing hormone stimulation test (ACTH pre-stimulation, 38.4 pg/mL and post-stimulation, 203 pg/mL). The PPID was reportedly untreated because of the inability to administer medications PO.

1.2 | Clinical Findings

Upon presentation, the donkey was quiet, responsive, mildly tachycardic (60 beats per minute [bpm]), and tachypneic (48 breaths per minute) with short and shallow breathing. Rectal temperature (98.7 F) was normal. Cardiopulmonary and abdominal auscultation were unremarkable. The donkey had a body condition score of 9/9 (weight, 172 kg) with large areas of

Abbreviations: AST, aspartate aminotransferase; GGT, gamma-glutamyl transferase; MEED, multisystemic eosinophilic epitheliotropic disease; PPID, pars pituitary intermedia dysfunction; RI, reference interval; SDH, sorbitol dehydrogenase.

This is an open access article under the terms of the Creative Commons Attribution-NonCommercial-NoDerivs License, which permits use and distribution in any medium, provided the original work is properly cited, the use is non-commercial and no modifications or adaptations are made.

© 2025 The Author(s). *Journal of Veterinary Internal Medicine* published by Wiley Periodicals LLC on behalf of American College of Veterinary Internal Medicine.

regional adipose accumulation. Focal areas of alopecia were present on the left flank, right cervical region, right shoulder, and right ventrum (Figure 1). A round swelling was identified in the right cervical region adjacent to the right jugular vein. Manure was normal, and the donkey remained inappetent.

1.3 | Diagnostic Aids

Ultrasonographic evaluation showed a liver with increased echogenicity (isoechoic to the spleen), faint vascular markings, and rounded margins (Figure 2). A homogenously echoic triangular structure approximately 3 × 6 cm was imaged medial to the right kidney, right lobe of the liver, and adjacent to the portal vein in the right 17th, 16th, and 15th intercostal spaces (Figure 3). A thick layer of retroperitoneal fat made the image suboptimal. A small amount of hypo- to anechoic peritoneal fluid was visible. The triangular echoic structure was interpreted as the pancreas, and the presence of echoic fat or a mass could not be ruled out. The primary differential diagnosis for the liver appearance in a donkey with severe hypertriglyceridemia was fat infiltration, although other infiltrative diseases or chronic hepatitis could not be ruled out.

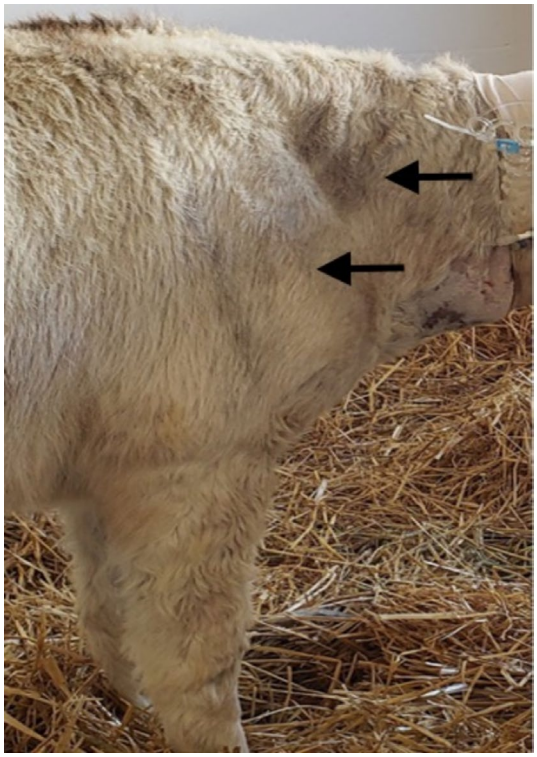

FIGURE 1 | Photograph of a 21-year-old miniature donkey with multisystemic eosinophilic epitheliotrophic disease (MEED) showing focal areas of alopecia (arrows) on the cervical region and shoulder.

Abdominocentesis yielded a yellow, slightly cloudy fluid with a normal total white cell count (2460 cells/μL; equine RI, < 5000 cells/μL), mildly increased total protein concentration (2.5 g/dL; equine RI, < 2.5 g/dL) and a markedly abnormal leukocyte distribution (35% eosinophils, 49% macrophages, 13% non-degenerate neutrophils, 3% small lymphocytes) consistent with an eosinophilic transudate.

A CBC showed leukocytosis (17.65×10^3 cells/μL; RI, 5.00–12.00×10^3 cells/μL) [1], eosinophilia (7.59×10^3 cells/μL; RI, 0.1–0.9×10^3 cells/μL) [1] and mild neutrophilia (7.06×10^3 cells/μL; RI, 2.4–6.3×10^3 cells/μL [Element HT5, Heska, USA]). Serum biochemistry showed hypertriglyceridemia (591 mg/dL; RI, 52.5–245 mg/dL) [1], increased GGT activity (872 U/L; RI, 14–69 U/L) [1], increased sorbitol dehydrogenase activity (SDH; 10 U/L; RI, 1–6 U/L), increased total bile acids concentration (TBA; 21 μmol/L; RI, 2.6–18.6 μmol/L) [1] and increased AST activity (736 U/L; RI, 238–536 U/L) [1]. The remaining serum biochemistry results, plasma fibrinogen concentration, packed cell value, total solids concentration, and lactate concentration were normal.

Initial treatment consisted of 0.7 mg/kg/min of dextrose in crystalloid IV fluids at a maintenance rate (2 mL/kg/h; Veterinary Plasma-lyte A Injection, Baxter, USA) with 50% dextrose [VetOne MWI Animal Health, USA] and potassium chloride 20 mEq/L [Fresenius Kabi, USA] supplementation as a constant rate infusion. Cetirizine hydrochloride was continued (0.4 mg/kg PO q12h; Dr. Reddy's Laboratories, USA). The day after admission, severe hypertriglyceridemia (865 mg/dL; RI, 52.5–245 mg/dL; Vitros, XT 3400 Chemistry System, QuidelOrtho Corporation, USA) [1] prompted an increase in the rate of dextrose infusion

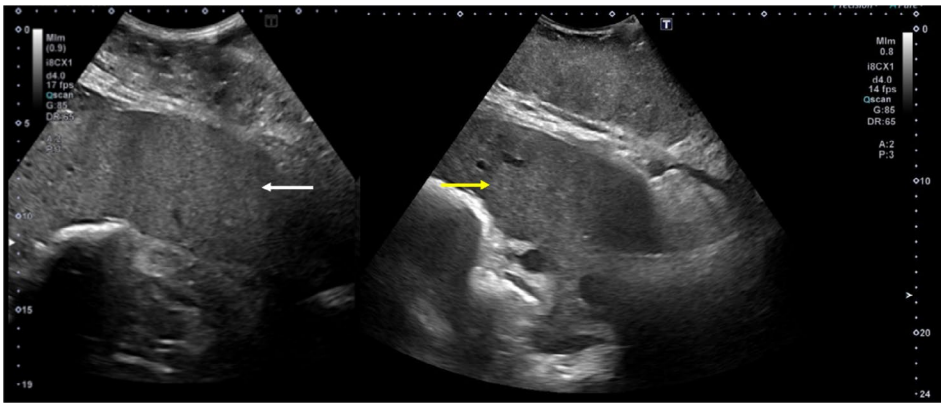

FIGURE 2 | Sonographic images of the spleen in the left 14th intercostal space (left image white arrow and right lobe of the liver in the right 13th intercostal space (right image yellow arrow), (Canon, Aplio i700, USA).

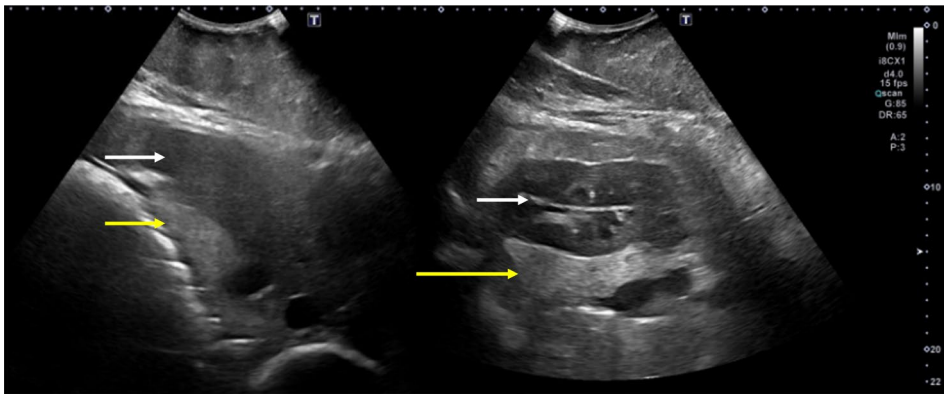

FIGURE 3 | Sonographic images of the right lobe of the liver in the right 15th intercostal space (left image white arrow), right kidney in the right 17th intercostal space (right image white arrow), and pancreas (left and right images yellow arrows). (Canon, Aplio i700, USA).

(3.5 mg/kg/min). Tachycardia resolved, and fever developed (101.5°F–102.7°F).

On the fourth day of hospitalization, antimicrobial treatment was initiated with ceftiofur crystalline-free sodium (6.6 mg/kg IM; Excede, Zoetis, USA) along with flunixin meglumine (1.1 mg/kg IV q12–24h; Flunixin Injection, Covetrus, USA) because of persistent fever. Empirical treatment with ivermectin (0.2 mg/kg PO once; Duramectin, Durvet, USA) was administered because of concern for a potential gastrointestinal parasitic infection and larval migration. Trazodone hydrochloride (2.5 mg/kg PO q12h; generic, Teva, USA) was started to decrease perceived anxiety related to hospitalization. Because of persistent hypertriglyceridemia, the donkey was treated with insulin (0.1–0.2 U/kg IV q8h; Humulin R regular insulin, Lilly USA). Intravenous fluids were continued with 3.5 mg/kg/min dextrose supplementation.

On the seventh day of hospitalization, the donkey became moderately tachycardic (68 bpm), exhibited lameness, and had increased digital pulses in all four limbs. Despite treatment, the donkey remained febrile (maximum temperature, 103.4°F), inappetent with improved but persistent hypertriglyceridemia (179 mg/dL; RI, 52.5–245 mg/dL) [1], leukocytosis (eosinophilia, 9.92×10^3 cells/μL; RI, $0.1–0.9 \times 10^3$ cells/μL; neutrophilia, 9.92×10^3 cells/μL; RI, $2.4–6.3 \times 10^3$ cells/μL) [1] and worsened liver enzyme activities (GGT, 1024 U/L; RI, 14–69 U/L; AST, 849 U/L; RI, 238–536 U/L) [1]. Because of continued clinical decline, euthanasia was elected and a necropsy was performed.

2 | Pathological Findings

2.1 | Gross Findings

Necropsy identified lesions associated with multisystemic eosinophilic epitheliotropic disease (MEED). The donkey had lesions affecting multiple organs, including mesenteric lymph nodes, pancreas, liver, heart, kidneys, intestines, lungs, and skin. Mildly increased intraperitoneal fluid, small intestinal mesenteric lymphadenopathy, and peripancreatic edema were identified. The donkey also had a yellow-brown liver with discrete tan foci and poorly defined tan foci on the left ventricular epicardial surface. The contents of the large intestine were liquid, with normal fecal balls present in the descending colon. The intestines, kidneys, lungs, and skin appeared grossly normal.

2.2 | Histopathology

The mesenteric lymph nodes were surrounded by fibrous tissue infiltrated with dense neutrophilic and lymphoplasmacytic aggregates, incorporating nerves and small arteries (Figure 4). The mesenteric root had chronic and severe eosinophilic inflammation (Figure 4). The pancreas had coalescing eosinophil infiltrates and moderate acinar atrophy. The liver had severe chronic eosinophilic portal hepatitis with eosinophilic granulomas (Figure 5). The epicardium of the left ventricle featured marked eosinophilic myocarditis with cardiomyocyte atrophy and necrosis (Figure 6). The kidneys had mild multifocal eosinophilic tubulointerstitial nephritis (Figure 7). Marked diffuse lymphoplasmacytic enterocolitis was identified. Lymphoplasmacytic infiltrates admixed with eosinophils were observed in the adventitia of large pulmonary blood vessels. The alopecic skin had sparse lymphocytic and eosinophilic infiltrates, along with mild multifocal superficial dermal fibrosis. The adnexa remained intact, and the hair follicles were in the telogen phase.

3 | Discussion

Multisystemic eosinophilic epitheliotropic disease is a rare disease in equids characterized by the infiltration of eosinophils into the tissues of multiple organs. Affected organs include the skin, gastrointestinal tract, lymph nodes, kidneys, lungs, pancreas, liver, heart, and biliary system [2, 3]. In horses, descriptions of MEED are limited to case reports, case series, and reviews [3–16]. In the first reported series, five horses with chronic progressive dermatitis and severe weight loss with lymphoplasmacytic and eosinophilic infiltrates in other organs were described [16]. Several case series and reviews of MEED in horses have been reported since the original description with variation of affected organs [17]. Three donkeys with chronic MEED identified on necropsy were previously described [17]. Herein, we provide additional details on clinical disease presentation, hematology, progression, and necropsy findings in a donkey with MEED.

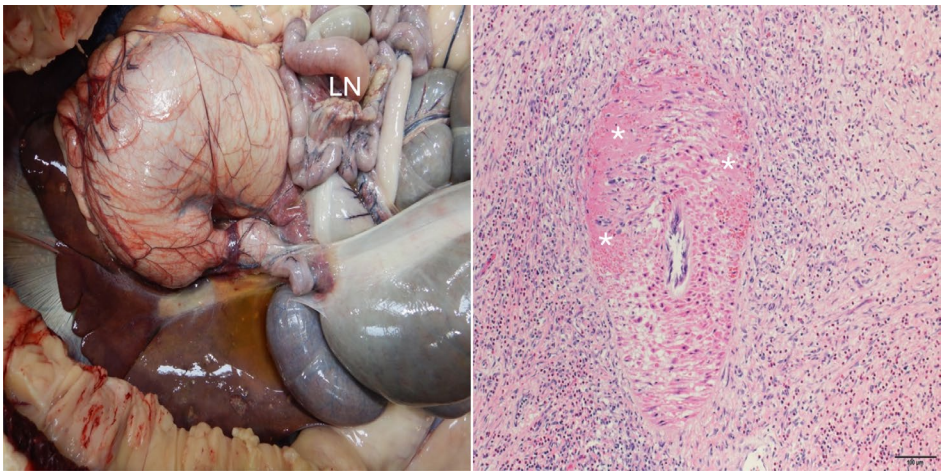

FIGURE 4 | Left: Root of the small intestine mesentery. Lymph nodes (LN) are effaced by homogenously white firm tissue. Right: Photomicrograph of the mesenteric artery reveals fibrinoid necrosis (asterisks) and diffuse periarterial eosinophilic infiltrates. Hematoxylin and eosin stain. Scale bar = 100 μm.

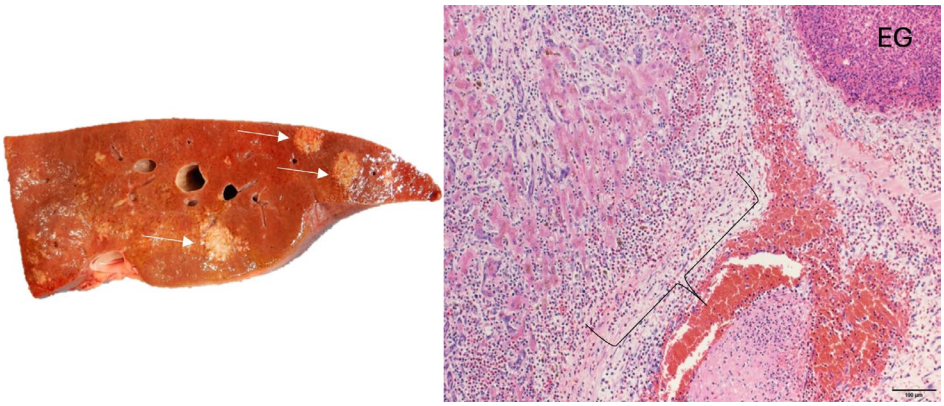

FIGURE 5 | Left: Cut surface section of the liver with discrete tan foci (arrow). Foci were up to 4 cm in diameter. Right: Photomicrograph of the liver. Partial effacement of the hepatic parenchyma by fibrosis, eosinophilic infiltrates (bracket), and an eosinophilic granuloma (EG). A thrombus is in a venule (asterisk). Hematoxylin and eosin stain. Scale bar = 100 μm.

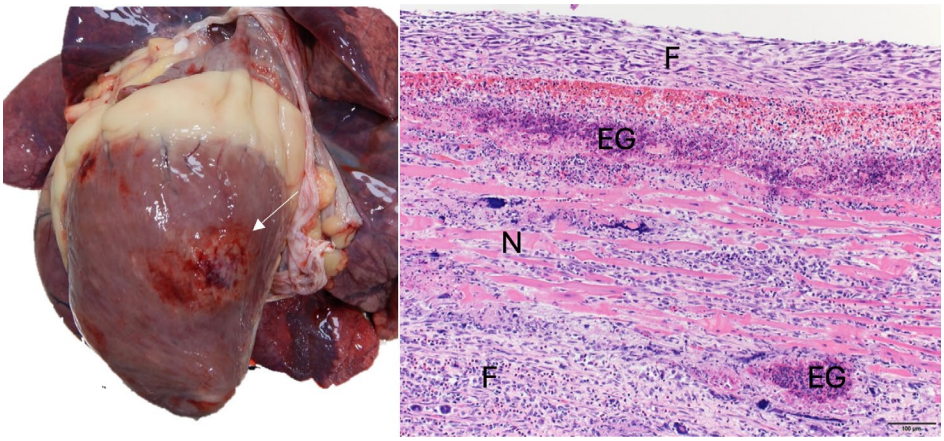

FIGURE 6 | Left: Left ventricular epicardium has poorly defined tan foci (arrow). Right: Photomicrograph reveals epicardial fibrosis (F), epicardial necrosis (N), and fibrosis (F) with severe eosinophilic inflammation and eosinophilic granuloma (EG) are present. Hematoxylin and eosin stain. Scale bar = 100 μm.

Multisystemic eosinophilic epitheliotropic disease is a chronic disorder that generally affects young horses, usually under 5 years old. Standardbreds and Quarter Horses are over-presented in the reported affected breeds [4, 14]. Although more common in younger horses, MEED has been identified in horses up to 17 years of age [3, 15]. In the

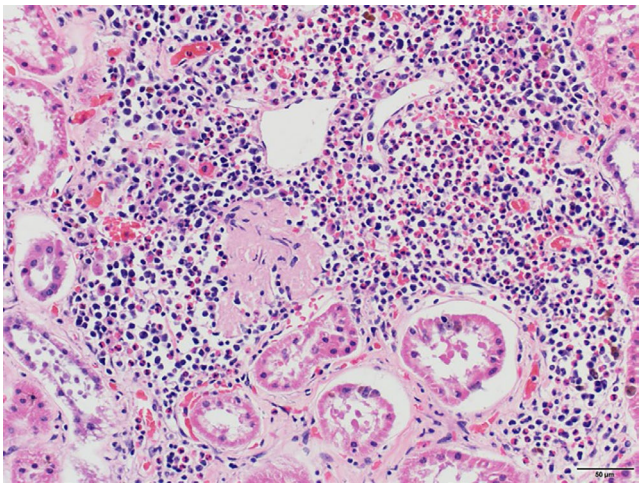

FIGURE 7 | Photomicrograph reveals interstitial nephritis. Eosinophilic infiltrates (EII) expand the interstitium. Hematoxylin and eosin stain. Scale bar = 50 μm.

previously reported cases of MEED, affected donkeys ranged in age from 15 to 17 years of age [17].

The clinical presentation of MEED in horses can be variable and nonspecific, with clinical signs dependent on the organ systems affected [6]. As a result, the clinical diagnosis of MEED in equids is challenging. The skin, gastrointestinal tract, and liver seem to be the organs affected most frequently, resulting in a presenting complaint of chronic weight loss, diarrhea, and/or pruritic exfoliative dermatitis [6, 9, 12, 16, 18–20]. In our case, weight loss and diarrhea were not observed despite histopathologic evidence of diffuse lymphoplasmocytic enterocolitis with marked eosinophil infiltration. The donkey's obesity may have hindered the ability to recognize weight loss by the owner, as it was not reported as a presenting complaint. No weight loss was observed during hospitalization. Horses with MEED, presenting primarily with respiratory signs such as chronic cough, nasal discharge, tachypnea, dyspnea, epistaxis, airway obstruction, or respiratory distress, have been described [3, 9, 10, 13]. Fever, anorexia, lethargy, signs of colic, peripheral lymphadenopathy, oral ulcerations, ocular discharge, vulvovaginitis, and distal limb and ventral abdominal edema also have been reported [4, 7, 10, 13, 15]. Pruritic dermatitis and alopecia were the only recognized clinical signs in the donkey of our case report, until its condition worsened, leading to inappetence within a 2-week period. Reported cases of MEED in equids have a variable duration of progression, from 5 days [20] to 4.5 months [3], with the majority of cases having a chronic course of 2–4 months [5, 6, 8, 10, 15, 18]. Although MEED likely was chronic in the donkey of our report, the manifestation of clinical signs seemed acute.

The hematological abnormalities of MEED in horses also are variable. Moderate to severe leukocytosis characterized by eosinophilia [9, 13] or neutrophilia [3, 4, 15, 19] has been reported frequently. However, leukopenia [10] and normal total white cell count [8, 16, 19] have been described. Increased liver enzyme activity [4], hyperfibrinogenemia [3, 13] hypoalbuminemia [6–8, 13], hypergammaglobulinemia [13] and mild anemia [6, 15] are common clinicopathologic findings in horses with MEED. Electrolyte abnormalities, including hyponatremia, hypochloremia, hypokalemia, and hypocalcemia also have been described [8, 14]. Additional diagnostic results, including glucose absorption tests, may show moderate to severe malabsorption [11, 13] or may be normal [8, 10]. A sternal bone marrow biopsy and aspirate in a horse with MEED showed mild erythroid hypoplasia and myeloid hyperplasia, which primarily consisted of eosinophils [8]. Abdominocentesis may disclose a modified exudate with the presence of eosinophils [8]. Cytologic evaluation of transtracheal wash fluid may identify eosinophilic inflammation [5]. Overall, biopsy samples of skin lesions, rectum, stomach, duodenum, or other affected organs may aid in diagnosing MEED by identifying eosinophilic infiltrates.

Based on the three reported cases of MEED in donkeys and our case, dermatitis (3 of 4 donkeys), chronic weight loss or weight fluctuation (2 of 4 donkeys), fever (1 donkey), increased liver enzyme activity (all 4 donkeys) and peripheral eosinophilia (all 4 donkeys) appear to be common findings [17]. On necropsy, tan masses affecting the liver, lungs, myocardium, kidneys, colon, cecum, lymph nodes, and pancreas were observed [17]. Histopathology identified multifocal infiltration of these organs with eosinophils, macrophages, multinucleated giant cells, lymphocytes, and plasma cells.

The prognosis of MEED in horses is poor. Overall mortality in equids with MEED is high, as most reported cases progressed despite attempted treatment, resulting in death or euthanasia. Four horses have shown clinical improvement after prolonged treatment with dexamethasone [5, 10, 19]. Only one horse remained asymptomatic after dexamethasone was discontinued and was reported to perform as a pleasure horse 8 months after discharge from the hospital [10]. Two horses remained on low-dose dexamethasone indefinitely because clinical signs reoccurred upon withdrawal from corticosteroid treatment [5, 19]. One horse showed an initial favorable response to treatment with corticosteroids but was euthanized 3 months later because of severe colic associated with hemorrhagic colitis with diffuse eosinophilic infiltrates [19]. Additional treatments used in reported cases of horses with suspected MEED include anthelmintics, antihistamines, antibiotics, nonsteroidal anti-inflammatory drugs, and supportive care with IV fluids.

Hypereosinophilic syndrome (HES) is a group of rare disorders in humans, characterized by eosinophilia and tissue infiltration by eosinophils, similar to MEED in equids [21]. Corticosteroids remain the first-line or adjunctive treatment for most humans with clinical HES, unless the disease is associated with a gene mutation, as in the case of PDGFRA-associated HES [21]. Cytotoxic treatment with hydroxyurea or vincristine and immunotherapy with interferon alpha are second-line treatments for humans with HES refractory to corticosteroids [21]. Adjunctive treatment with hydroxyurea resulted in partial clinical improvement in a horse that had not responded to treatment with corticosteroids alone; the horse was eventually euthanized [20]. Monoclonal antibodies against interleukin-5 and the interleukin-5 receptor are used in human patients with HES with variable success [2, 21]. The tyrosine kinase inhibitor imatinib mesylate

is used for treatment of humans with PDGFRA-associated HES [21]. Nonmyeloablative allogeneic bone marrow transplantation is reserved for humans with HES once standard treatments have been exhausted or resulted in end-organ damage [21]. The usefulness of these treatment protocols in equids remains unknown and warrants further research.

Because MEED in donkeys is a rare disease and potentially underdiagnosed, no comments can be made regarding the response to the treatment. The use of corticosteroids in donkeys with MEED is controversial because these animals can rapidly develop negative energy balance and hypertriglyceridemia when sick and anorexic. Hypertriglyceridemia requires dextrose supplementation and treatment with insulin in refractory cases. Treatment of hypertriglyceridemia alone can result in the development of laminitis [22]. Treatment with corticosteroids adds the risk of the development of laminitis, especially if an underlying metabolic disease is present [23]. Clinical suspicion for MEED was high in the donkey described here, based on pruritic dermatitis, marked peripheral eosinophilia, and hepatopathy. Treatment with corticosteroids was avoided because of overcondition and underlying undiagnosed metabolic disease. Treatment of non-responsive hypertriglyceridemia using insulin and dextrose supplementation resulted in the development of laminitis, in this case leading to euthanasia.

The cause of MEED in horses and donkeys remains unknown. A case of a horse with MEED associated with severe lymphoproliferation and hyperplasia of T lymphocytes suggests a potential association of these features in the disease process [6]. T lymphocytes secrete interleukin-5, which triggers the activation and differentiation of eosinophils. This conclusion is further supported by a report of MEED with underlying T cell intestinal lymphosarcoma in a 13-year-old Paso Fino mare [8]. This association requires further investigation. Parasitic migration may play a role in the pathogenesis of MEED, based on the report of a mare that developed MEED a year after larval migrans was identified in a reactive lymph node without other clinical signs [15]. Further research is necessary to determine the pathogenesis of MEED and guide treatment protocols in equids.

We described the clinical presentation, progression, and pathological findings of a case of MEED in a donkey. Despite being a rare disease in equids and with variable forms of presentation, diverse clinical signs and hematologic and pathologic findings may be observed in donkeys with MEED.

Disclosure

Authors declare no off-label use of antimicrobials.

Ethics Statement

Authors declare no institutional animal care and use committee or other approval was needed. Authors declare human ethics approval was not needed.

Conflicts of Interest

The authors declare no conflicts of interest.

References

1. F. A. Burden, E. Hazell-Smith, G. Mulugeta, V. Patrick, R. Trawford, and H. W. Brooks Brownlie, "Reference Intervals for Biochemical and Haematological Parameters in Mature Domestic Donkeys (*Equus asinus*) in the UK," *Equine Veterinary Education* 28 (2016): 134–139.

2. M. M. Brosnahan, "Eosinophils of the Horse: Part II: Eosinophils in Clinical Diseases," *Equine Veterinary Education* 32 (2020): 590–602.

3. K. Singh, T. C. Holbrook, L. L. Gilliam, R. J. Cruz, J. Duffy, and A. W. Confer, "Severe Pulmonary Disease due to Multisystemic Eosinophilic Epitheliotropic Disease in a Horse," *Veterinary Pathology* 43 (2006): 189–193.

4. L. Bosseler, K. Verryken, C. Bauwens, et al., "Equine Multisystemic Eosinophilic Epitheliotropic Disease: A Case Report and Review of Literature," *New Zealand Veterinary Journal* 61 (2013): 177–182.

5. J. Carmalt, "Multisystemic Eosinophilic Disease in a Quarter Horse," *Equine Veterinary Education* 16 (2004): 231–234.

6. H. Gehlen, A. Cehak, Z. Bagó, et al., "Multisystemic Eosinophilic Disease in a Standardbred Mare Combined With Generalized Lymphadenitis," *Journal of Equine Veterinary Science* 23 (2003): 216–219.

7. T. Higuchi, H. Hata, S. Inoue, et al., "Multisystemic Eosinophilic Epitheliotropic Disease in a Horse," *Journal of the Japan Veterinary Medical Association* 61 (2008): 858–861.

8. K. M. D. La Perle, R. J. Piercy, J. F. Long, et al., "Multisystemic, Eosinophilic, Epitheliotropic Disease With Intestinal Lymphosarcoma in a Horse," *Veterinary Pathology* 35 (1998): 144–146.

9. K. S. Latimer, D. I. Bounous, C. Collatos, K. P. Carmichael, and E. W. Howerth, "Extreme Eosinophilia With Disseminated Eosinophilic Granulomatous Disease in a Horse," *Veterinary Clinical Pathology* 25 (1996): 23–26.

10. M. E. McCue, E. G. Davis, B. R. Rush, et al., "Dexamethasone for Treatment of Multisystemic Eosinophilic Epitheliotropic Disease in a Horse," *Journal of the American Veterinary Medical Association* 223 (2003): 1320–1323.

11. D. A. Pass and J. R. Bolton, "Chronic Eosinophilic Gastroenteritis in the Horse," *Veterinary Pathology* 19 (1982): 486–496.

12. S. E. Sanford, "Multisystemic Eosinophilic Epitheliotropic Disease in a Horse," *Canadian Veterinary Journal* 30 (1989): 253–254.

13. L. Stucchi, C. M. Lo Feudo, C. Valli, et al., "Equine Multisystemic Eosinophilic Epitheliotropic Disease in Two Horses in Italy," *Equine Veterinary Education* 34 (2022): e413–e417.

14. C. C. Villagrán, D. Vogt, A. Gupta, et al., "Inflammatory Bowel Disease Characterized by Multisystemic Eosinophilic Epitheliotropic Disease (MEED) in a Horse in Saskatchewan, Canada," *Canadian Veterinary Journal* 62 (2021): 1190–1194.

15. V. Vitale, L. Troya-Portillo, I. Corradini, B. Serrano, and L. Armengou, "Multisystemic Eosinophilic Epitheliotropic Disease Subsequent to Parasitic Lymphadenopathy in a Mare," *Veterinary Record Case Reports* 11 (2023): e711.

16. J. S. N. Wilkie, J. A. Yager, P. N. Nation, E. G. Clark, H. G. G. Townsend, and J. D. Baird, "Chronic Eosinophilic Dermatitis: A Manifestation of a Multisystemic, Eosinophilic, Epitheliotropic Disease in Five Horses," *Veterinary Pathology* 22 (1985): 297–305.

17. G. Paraschou PEV, A. M. Lee, R. F. Trawford, and S. L. Priestnall, "Multisystemic Eosinophilic Epitheliotropic Disease in Three Donkeys," *Journal of Comparative Pathology* 201 (2023): 105–108.

18. C. M. Pucheu-Haston and F. Del Piero, "Equine Multi-Systemic Eosinophilic Epitheliotropic Disease," *Equine Veterinary Education* 25 (2013): 614–617.

19. K. T. Gibson and R. G. Alders, "Eosinophilic Enterocolitis and Dermatitis in Two Horses," *Equine Veterinary Journal* 19 (1987): 247–252.

20. M. H. Hillyer and T. S. Mair, "Multisystemic Eosinophilic Epitheliotropic Disease in a Horse: Attempted Treatment With Hydroxyurea and Dexamethasone," *Veterinary Record* 130 (1992): 392–395.

21. A. D. Klion, B. S. Bochner, G. J. Gleich, et al., "Approaches to the Treatment of Hypereosinophilic Syndromes: A Workshop Summary Report," *Journal of Allergy and Clinical Immunology* 117 (2006): 1292–1302.

22. K. E. Asplin, M. N. Sillence, C. C. Pollitt, and C. M. McGowan, "Induction of Laminitis by Prolonged Hyperinsulinaemia in Clinically Normal Ponies," *Veterinary Journal* 174 (2007): 530–535.

23. K. Potter, K. Stevens, and N. Menzies-Gow, "Prevalence of and Risk Factors for Acute Laminitis in Horses Treated With Corticosteroids," *Veterinary Record* 185 (2019): 82.