Pulmonary Hypertension

Introduction

Pulmonary hypertension (PH) is a hemodynamic and pathophysiologic state that can be found in multiple clinical conditions. It is defined as a mean pulmonary arterial pressure (mPAP) of 25 mmHg or greater at rest. Symptoms typically include shortness of breath, decreased exercise tolerance, and eventual heart failure. The focus in this lesson is to give a glimpse into the clinical diagnosis and management of pulmonary hypertension, provide an advanced organizer for working through the causes of elevated mean pulmonary artery pressure, and then review the five different groups of pulmonary hypertension (as classified by the World Health Organization). These five groups are separated by the pathophysiologic and histologic differences seen in each group.

The main emphasis will be on group 1, pulmonary arterial hypertension, and a subgroup called idiopathic pulmonary arterial hypertension. We will also discuss the pathogenesis and histology of group 2 (left ventricular heart failure induced), group 3 (hypoxic lung disease induced), and group 4 (chronic thromboembolic pulmonary hypertension), and will touch on group 5 ("other").

Diagnosing Pulmonary Hypertension

Pulmonary hypertension is a progressive disease, eventually resulting in right ventricular impairment, and is associated with symptoms of exertional chest pain, syncope, and edema. Findings on physical examination depend on the severity of disease. The physical finding associated with pulmonary hypertension is a **loud S_2.** A prominent jugular venous a wave and a parasternal heave reflect right ventricular hypertrophy. As the right ventricle dilates, a holosystolic tricuspid regurgitant murmur may be detected. Right ventricular failure leads to a backup of the fluid before the broken pump, leading to venous congestion—**jugular venous distention**, hepatomegaly, ascites, and **peripheral edema**. Pulmonary findings reflect underlying lung disease. Accelerated **pulmonary artery atherosclerosis** exacerbates the hypertension.

The thing is, pulmonary hypertension is rarely the primary diagnosis. When someone has COPD, we get concerned about pulmonary hypertension, monitor their oxygen saturation, and provide oxygen. When someone has left ventricular dysfunction and pulmonary edema, we focus on diuresis and improving hemodynamics. So, often, a patient with pulmonary hypertension is diagnosed with it because of something else. But when the symptoms of right heart failure begin in a patient without obvious disease, there is a fairly simple algorithmic process to follow in order to rule out various causes, before arriving at the diagnosis of pulmonary arterial hypertension.

If pulmonary hypertension is suspected, **transthoracic echocardiography** is the first step. It allows for an estimation of pulmonary arterial pressure (emphasis on "estimation") and assessment of right ventricular size and function. It also allows for the assessment of left ventricular size and function—the first diagnosis to rule out when working up pulmonary hypertension. Ultimately, the best test to confirm pulmonary hypertension is **right heart catheterization**. Between the echo and the heart cath is where you look for an underlying etiology by getting a series of tests to sequentially rule out secondary causes of pulmonary hypertension.

The WHO has subdivided pulmonary hypertension into five groups. We'll explore those groups. But this advanced organizer will help remind you of the common causes, help you keep a clinical perspective to the five groups, and provide a quick reference for working the patient up.

© OnlineMedEd. http://www.onlinemeded.org

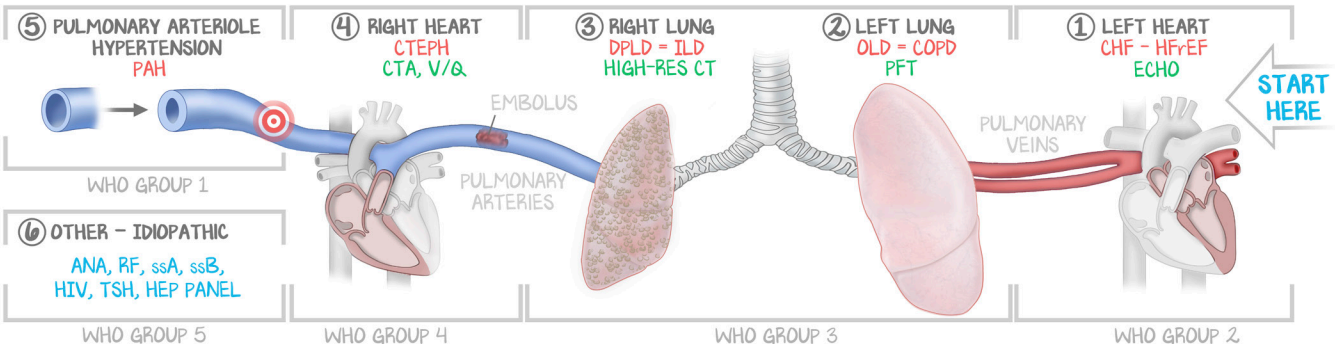

Figure 3.1: Pulmonary Hypertension Advanced Organizer
Starting at the right, the left of the patient, we work backward. We start at the left heart because the most common cause of pulmonary hypertension, the most common cause of right heart failure, is left-sided failure (WHO group 2). To evaluate heart failure, we get an echocardiogram. The second step is the left lung, poofed out like a cloud to indicate emphysema. COPD is the second most common cause of pulmonary hypertension (WHO group 3). To evaluate for COPD, we get PFTs. The third step is the right lung, with hash marks to symbolize a scarred, fibrotic lung, indicating restrictive lung disease. This is still hypoxemic lung disease (WHO group 3), but it's less common than COPD. The scarred down lung is evaluated (because you already got PFTs for COPD) with high-resolution CT for the fibrotic lung disease, and a sleep study is used to screen for obstructive sleep apnea. The fourth step is the blood clot at the end of the pulmonary artery, indicative of chronic thromboembolic pulmonary hypertension (WHO group 4). Chronic PEs are evaluated with a spiral CT or VQ study if contrast is not available. Finally, the last step is pulmonary arterial hypertension (WHO group 1), the only 1 out of order. PAH is evaluated with a biopsy, looking for a thickening of the intima and plexiform lesions. Other causes of pulmonary hypertension, whether or not they are morphologically dissimilar to PAH, are evaluated at the same time (WHO group 5).

Brief Review of Blood Vessels

Both arteries and veins have three layers, three tunicae: intima, media, adventitia. The **tunica intima** is where the endothelial cells are. It is supposed to be only one cell thick. The endothelium is a simple squamous epithelium that lines the lumen of the blood vessels. That layer is separated from the tunica media by an **inner elastic lamina**. The **tunica media** (the "middle" of the three layers) is the most variable and its content changes based on the function and size of the vessel. The key ingredients of this layer are **smooth muscle cells, elastin,** and **collagen**. Smooth muscle cells contract, elastin is elastic, and collagen helps the vessel resist deformation. The tunica media is a variable number of cells thick depending on the size of the vessel. The tunica media is separated from the tunica adventitia by the **external elastic lamina.** The tunica adventitia of very large arteries carries a vasa vasorum. In most arteries, it serves no purpose or is nonexistent.

Arteries appear as concentric rings on histology, their tunica media filled with smooth muscle cells. Arteries are high-pressure vessels and their lumens are always filled with blood; thus, they have that circular appearance on histology. Veins are loose and floppy, have very little tunica media, and often have much larger lumens than their arterial counterparts. Every tunica intima of every vessel should only be endothelium. Every tunica media varies based upon how big the vessel is and what it does. For our discussion here in pulmonary hypertension, every tunica adventitia doesn't matter.

The tunica media undergoes hyperplasia and hypertrophy, a physiologic response to high pressures, when the vessel must contend with increased pressures from the heart. The tunica intima should never be more than one endothelial cell thick. Any addition of cells or extracellular matrix is pathologic. Regardless, a narrowed lumen is going to increase pulmonary vascular resistance. The right heart will feel an ever-increasing resistance and will need to get stronger to fight against it. Even though not all vessels are affected by the primary pathology, any healthy vessels unaccustomed to these increased pressures will now feel more force from the right ventricle. They adapt to the higher pressures and higher flow. Universally, there will be some degree of hypertrophy and hyperplasia of the tunica media of pulmonary arteries. But what we want to teach you are the unique findings of each of the WHO groups. We are removing overlap, ambiguity, and commonalities.

© OnlineMedEd. http://www.onlinemeded.org

Group 1: Primary Pulmonary Hypertension

In what is now called **pulmonary arterial hypertension** (PAH, formerly known as primary pulmonary hypertension), pulmonary hypertension occurs as a result of **intimal thickening**. Intimal thickening means that the tunica intima, the innermost layer, the one that should be just one-cell thick (the endothelium) on the inner elastic membrane, becomes thicker than just one-cell thick. The tunica intima is infiltrated by myofibroblasts. They proliferate and lay down collagen. The lumen narrows because the intima continues to grow into the lumen, eventually impinging the vessel entirely.

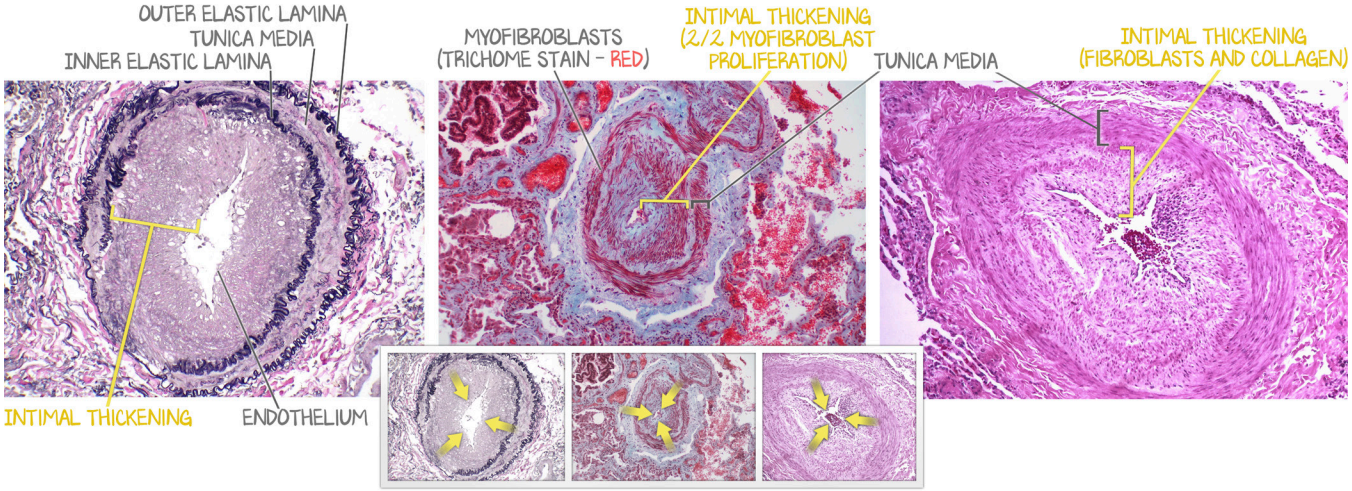

Figure 3.2: Pulmonary Arterial Hypertension Changes
Each of the three images demonstrates a different element of the underlying pathology. In the image on the far left, which is stained for elastin, you can see the separation of the tunica media from the adventitia and intima by the two elastic laminae on either side. The endothelium (only one cell thick) cannot be easily discerned at this magnification. But certainly, what is encroaching on this vessel's lumen is inside the inner elastic lamina, pushing the endothelial cells closer together as the lumen collapses. This is called intimal thickening, an increase in the size of the tunica intima. In the middle image, Mason trichrome stain stains for myofibroblasts (the spindly red things), the tunica media's vascular smooth muscle cells. Their concentric pattern denotes their normal location in the tunica media. Their presence (and radial orientation to the lumen) suggests that the lumen's narrowing is caused by the proliferation of myofibroblasts and the deposition of collagen. On the right is an H&E stain of a large artery demonstrating a nearly occluded lumen (this lumen has RBCs in it) and an apparent leading edge of nuclei. Again, radially oriented fibroblasts can be seen proliferating from the concentric orientation of the media into the intima (although the barrier between the intima and media is not clearly discernable, the cells' orientation denotes the change).

There are many subtypes of pulmonary arterial hypertension. Learn two: PAH and iPAH. One is the generic histologic appearance of intimal fibrosis (fibroblasts and collagen) with no plexiform lesions. It is secondary to an underlying rheumatologic condition. It is just "PAH."

The other is **idiopathic pulmonary arterial hypertension** (iPAH). iPAH is PAH because it presents with intimal thickening. It is separated from all other group 1 PAH because it has its own demographic and the additional histologic finding of **plexiform lesions**. iPAH occurs in young women who are negative for the entire work-up explored above and then have a biopsy that reveals intimal thickening and fibrosis in addition to **plexiform lesions.** Plexiform lesions are described just like thrombosis later—recanalization of a lesion in a large arterial vessel. Idiopathic PAH is associated with a gene mutation in about 20% of cases. That gene encodes bone morphogenetic receptor protein 2 (**BMRP2**), which was discovered in a subset of individuals with familial iPAH. BMRP2 normally **inhibits the proliferation** of fibroblasts and smooth muscle cells. The loss of this gene leads to their proliferation into the tunica intima. Given that the pathogenesis of cancer is unregulated growth, there is speculation that this is actually more of a malignancy than an autoimmune condition. This is the first insight into the pathogenesis of iPAH. Until the 2010s, this diagnosis had a histologic appearance and was given oxygen and an apology. There is still much to learn, but iPAH has become a hot topic in the world of pulmonary research.

© OnlineMedEd. http://www.onlinemeded.org

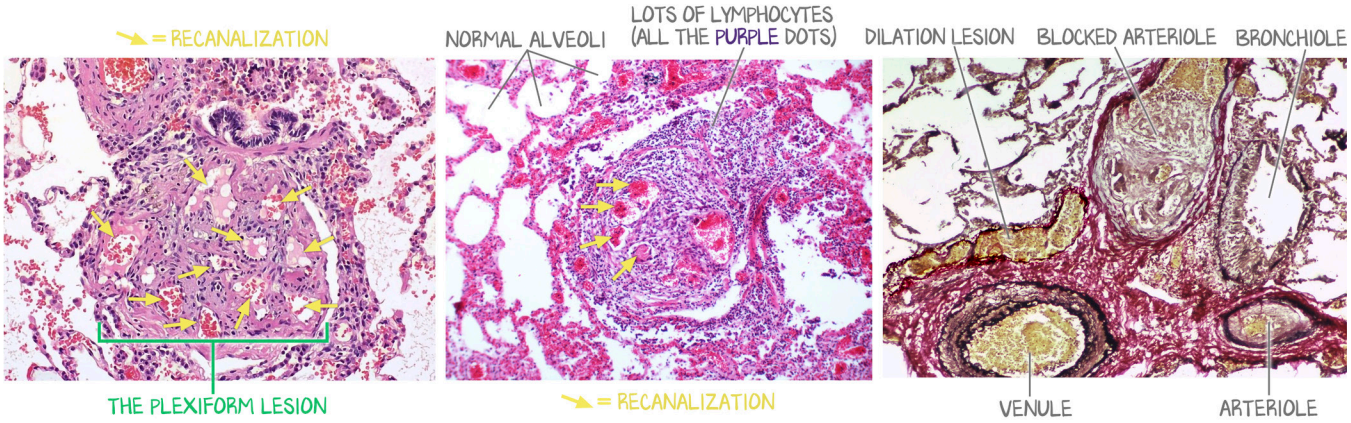

Figure 3.3: Plexiform Lesions
Plexiform lesions are the characteristic feature of iPAH. They occlude small arteries and become canalized, and can easily be mistaken for recanalized thromboemboli. However, the presence of numerous lymphocytes and the normal nearby alveoli give them away. Each histology slide shows a different stain, chosen to demonstrate the lesions in multiple ways.

The drugs that have been developed for the treatment of pulmonary hypertension were developed for use in patients with PAH. The goal is to promote the dilation of the vessels to reduce pulmonary vascular resistance and sometimes target fibroblast proliferation. When right heart catheterization shows elevated pulmonary arterial pressure, a **vasoreactivity sensitivity** study is done. A calcium channel blocker is administered. Approximately 5% of patients with pulmonary vascular hypertension respond with a drop in pulmonary vascular resistance. These patients benefit from a substantial improvement in morbidity and mortality when treated with oral calcium channel blockers. For the 95% of patients who do not react to calcium channel blockers during the vasoreactivity study, there are three other classes that target three pathways.

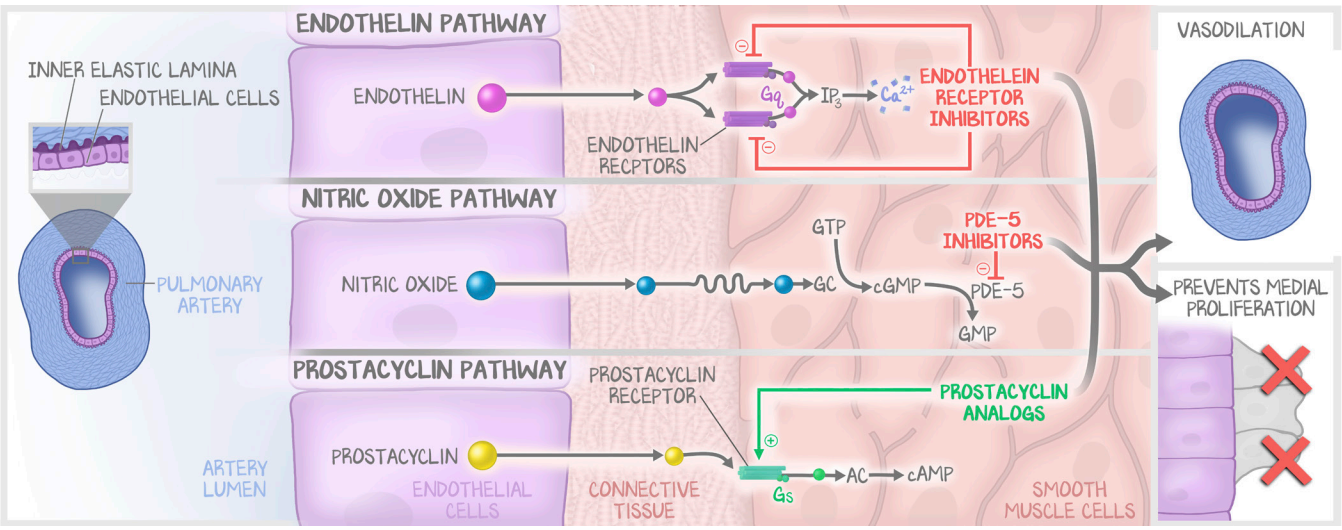

Figure 3.4: Pulmonary Arterial Hypertension Treatment
There are three main therapeutic targets. Inhibition of the endothelin pathway mitigates the proliferation signals on myofibroblasts. It also reduces vasoconstriction. Stimulation of the prostacyclin pathway takes advantage of the vasodilatory effect of prostacyclin receptors, increasing cAMP levels through the G_s cascade, resulting in vasodilation. Treatment involving the nitric oxide pathway involves the inhibition of phosphodiesterase 5, allowing the endogenously produced nitric oxide to stimulate guanylyl cyclase, generating cGMP, leading to vasodilation.

Endothelin-1 receptor antagonists (bosentan). Endothelin-1 receptor blockers are the first class of medication that targets both vasodilation and fibroblast proliferation. Endothelin is normally produced by the endothelial cells, and acts on the myofibroblasts in the tunica media. Endothelin-1 induces proliferation (activation of the -fibroblast part of myofibroblast) and vasoconstriction (the myo- part of myofibroblast). Bosentan is an **oral** medication and is both **hepatotoxic** and **teratogenic**.

Prostanoids (epoprostenol, iloprost) are prostacyclin analogues that are given as **continuous intravenous infusions** and only for the most severe disease or when oral agents have failed. Prostanoids supplement prostacyclin levels. Prostacyclins activate a G_s–adenylyl cyclase–cAMP signal, which promotes the vasodilation of the pulmonary arteries. They are also thought to have an antiproliferative effect, although the mechanism has not been elucidated.

Phosphodiesterase-5 inhibitors (sildenafil, tadalafil) are used to treat erectile dysfunction. They were discovered while researching treatments for pulmonary hypertension. The idea is the same: attempt to induce vasodilation to reduce pulmonary vascular resistance. The smooth muscle cells of arteries relax when there is cGMP. Endothelial cells secrete nitric oxide, which diffuses into the myofibroblasts and induces guanylyl cyclase to make cGMP from GTP. Phosphodiesterase-5 silences the cGMP by converting it to GMP. Nitrates do not seem to be as beneficial in pulmonary hypertension as they are in systemic hypertension. Phosphodiesterase 5 inhibitors do little for proliferation.

Group 2: Left Ventricle Failure

In **congestive heart failure**, the classic finding of hemosiderin-laden macrophages in the alveoli as evidence of pulmonary edema indicates only that there was heart failure. Because the back pressure comes from the left atrium into the pulmonary veins, LV failure causes pulmonary venous hypertension. To withstand high pressures, the veins develop their muscular layer, the tunica media. There will be **venous thickening of the tunica media** and subsequent **arterialization** (the thickening of the tunica media results in the internal and external elastic lamina being obviously distinct from one another), similar to how a saphenous vein graft undergoes arterialization.

One does not tend to biopsy the lungs of patients with left-sided heart failure, because what should be done is to manage the heart failure. Both systolic and diastolic failure can produce this form of pulmonary hypertension. Pulmonary hypertension drugs do not work, at all, for CHF-induced pulmonary hypertension. Treat the CHF, treat the pulmonary hypertension.

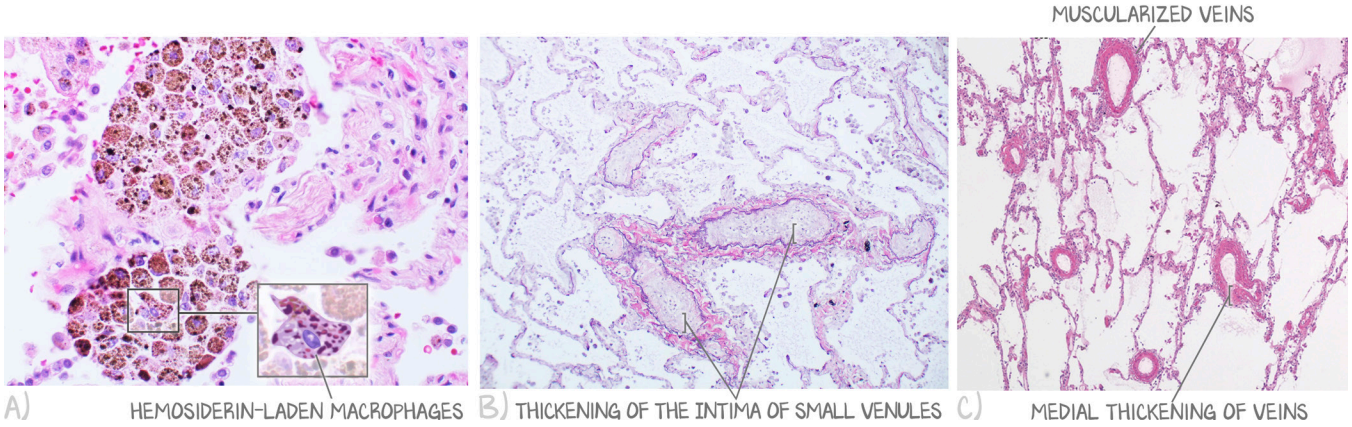

Figure 3.5: CHF-Induced Pulmonary Hypertension
(a) High-magnification H&E stain showing numerous hemosiderin-laden macrophages (the cells with speckles of brown) within alveoli, indicative of congestive heart failure (but not pathognomonic). (b) Other pulmonary venous diseases result in the intimal thickening and occlusion of small veins (similar to what happens in pulmonary arterial hypertension), but this finding is an overlapping feature of CHF and the diseases we are intentionally not teaching you. The nearby small alveoli give you an idea of how small these vessels are. (c) Unique to the increased pulmonary venous resistance caused by backpressure from the left heart (primarily CHF and mitral stenosis) is the thickening and sometimes even arterialization of pulmonary veins.

© OnlineMedEd. http://www.onlinemeded.org

Group 3: Hypoxemic Lung Disease

Group 3 is pulmonary hypertension caused by **hypoxia-induced vasoconstriction.** Sustained vasoconstriction induces both hyperplasia and hypertrophy of the **tunica media** of arteries. The lumen is narrowed by an increasingly thick tunica media. When the arteries constrict, pulmonary pressures increase. Increased pulmonary pressures are met with increased right ventricular contractions, strengthening the right ventricle. To sustain the increased pressure from a bigger, stronger right ventricle, the artery must constrict even more. The original signal is hypoxia-induced vasoconstriction. The sustained signal from the ongoing hypoxemia puts the arteries (trying to stop blood flow by contracting, hypertrophying the tunica media) and the heart (trying to increase blood flow by contraction, hypertrophying the right ventricular wall) in a never-ending arms race of hypertrophy. Eliminating the vasoconstriction signal (by providing oxygen to alveoli) stops this battle but cannot reverse the hypertrophy of the RV or the arteries.

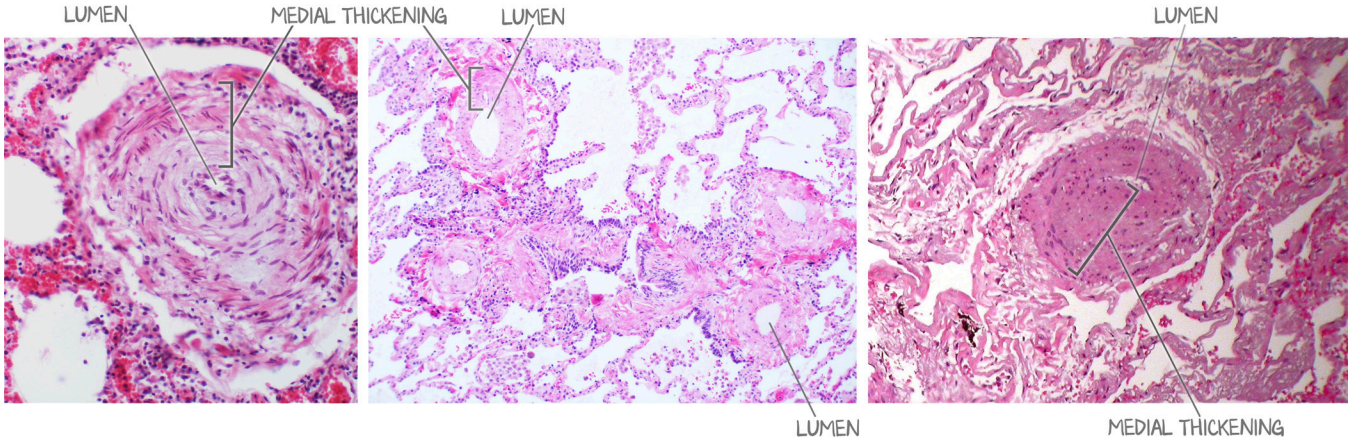

Figure 3.6: Hypoxemic Lung Disease and Arteriolar Media Hypertrophy
Small arteries and arterioles become better at constriction, hypertrophying their "muscles" by proliferating the vascular smooth muscle cells to better reduce the pressure delivered to the capillaries they are responsible for. This occurs when the right ventricle must fight harder to get blood through the vasculature due to something after the arterioles, such as the loss of alveolar septa in COPD, or an impaired diffusion barrier, like interstitial fibrosis in DLPD. This is also the response to a VSD or ASD and the pathophysiology behind Eisenmenger's syndrome.

Emphysema and bronchitis. The inability to oxygenate the alveoli due to chronic bronchitis leads to lung-wide vasoconstriction, with resultant thickening of the tunica media. The loss of septa in emphysema is the definition of loss of capillaries as the capillaries are in septa. This loss of capillaries in parallel with hypoxic alveoli further exacerbates the increased resistance. A biopsy of a pulmonary arteriole may be able to show evidence of emphysematous changes (loss of septa). Administration of supplemental oxygen to keep the saturation between 88% and 92% both staves off pulmonary hypertension and sustains the patient's hypoxic drive.

Restrictive lung disease. RLD also causes lung-wide hypoxia that results in vasoconstriction. The restrictive lung diseases of import are the fibrotic ones. This means that on the biopsy, in addition to the blood vessels' tunica media thickening, there should be evidence of alveolar fibrosis—either large swathes of collagen or at least septal thickening. The administration of supplemental oxygen to keep saturation above 92% both alleviates symptoms and avoids pulmonary hypertension. Because hypercapnia is not present in fibrotic RLD, there is no risk of losing the hypoxic drive as in OLD.

© OnlineMedEd. http://www.onlinemeded.org

Obstructive sleep apnea. Obstructive sleep apnea affects patients at night while they sleep. Their airway closes, and they stop breathing. This cessation of airflow induces a brief awakening that the patient does not remember. When not ventilating, they are not oxygenating, which provokes hypoxic vasoconstriction and pulmonary hypertension. These patients will snore (someone else tells them this) and suffer **daytime somnolence** (because they are not able to enter REM sleep due to frequent awakenings). Obesity is the largest risk factor. After being diagnosed by a sleep study and treated with a continuous positive airway pressure (CPAP) mask, the patient's breathing will remain constant, and the sleep interruptions (awakening after periods of not breathing) stop. Without treatment, irreversible pulmonary hypertension may set in.

Obesity hypoventilation syndrome. Obesity is the biggest risk factor for obstructive sleep apnea. OSA comes with chronic hypoxemia that leads to pulmonary hypertension. OSA's cousin is OHS. OHS is a mechanical failure of ventilation. The patient's chest wall is too heavy, laden with adipose, for the muscles of the chest wall to properly inhale and exhale. As a result, **carbon dioxide accumulates**. OHS causes CO_2 retention, whereas OSA causes hypoxemia. OHS often presents with both hypercapnia and hypoxemia, which can also result in hypoxic vasoconstriction.

Group 4: Pulmonary Embolism

In **chronic thromboembolic pulmonary hypertension,** there is no enlargement of any tunica. The right ventricle might have felt the damage, but the other arteries don't. Instead, what you will see is evidence of thrombosis that has been recanalized. An acute pulmonary embolism occludes the lumen. Endothelial cells and macrophages work their way into the thrombus, chewing their way through and creating multiple small lumens in the thrombus. No matter how much time passes, this endogenous management of recanalization never removes the entire thrombus. Thus, an overall narrowed lumen and increased pulmonary artery pressures remain. This is the condition for which **thrombectomy** is indicated.

We have no figures for Group 4 because they would be the same as Figure 2.8 and Figure 2.9 in the last lesson.

Group 5: Other

Other causes of pulmonary hypertension are specific to the given syndrome. **Sarcoid**, for example, has hilar (central)-growing granulomas. Over time, they continue to grow and enlarge. Eventually, these central granulomas may collide and obstruct central arteries. Don't spend too much time here, other than to understand that there is an "other" bucket. Others in this "other" bucket are mixed connective tissue disease, HIV, scleroderma, and other autoimmune processes. If intimal thickening is the cause of the stenosis and it is autoimmune, it is classified as group 1. Anything else, group 5.

© OnlineMedEd. http://www.onlinemeded.org