# Comparison of Image Enhancement and Sharpening Technique for Magnetic Resonance Image Quality Improvement

[1]Nur 'Ulya Nasuha Zakaria
Electrical Engineering Studies,
Universiti Teknologi MARA,
Cawangan Pulau Pinang,
Permatang Pauh Campus, 13500
Seberang Prai, Pulau Pinang,
Malaysia
2024674728@student.uitm.edu.my

[2,*]Muhammad Khusairi Osman
Electrical Engineering Studies,
Universiti Teknologi MARA,
Cawangan Pulau Pinang,
Permatang Pauh Campus, 13500
Seberang Prai, Pulau Pinang,
Malaysia
khusairi@uitm.edu.my

[3]Siti Noraini Sulaiman
Electrical Engineering Studies,
Universiti Teknologi MARA,
Cawangan Pulau Pinang,
Permatang Pauh Campus, 13500
Seberang Prai, Pulau Pinang,
Malaysia
sitinoraini@uitm.edu.my

[4]Dayang Suhaida Awang Damit
Electrical Engineering Studies,
Universiti Teknologi MARA,
Cawangan Pulau Pinang,
Permatang Pauh Campus, 13500
Seberang Prai, Pulau Pinang,
Malaysia
dayang671@uitm.edu.my

[5]Nor Ashidi Mat Isa
School of Electrical and Electronic
Engineering, Engineering Campus,
Universiti Sains Malaysia, 14300 Nibong
Tebal, Penang, Malaysia
ashidi@usm.my

[6]Noor Khairiah A. Karim
Department of Biomedical Imaging,
Advanced Medical and Dental Institute,
Universiti Sains Malaysia, Kepala Batas,
Pulau Penang, 13200, Malaysia
drkhairiah@usm.my

[7]Zakaria Hussain
Electrical Engineering Studies,
Universiti Teknologi MARA, Cawangan
Pulau Pinang,
Permatang Pauh Campus, 13500 Seberang
Prai, Pulau Pinang, Malaysia
zakaria183@uitm.edu.my

***Abstract*-In medical imaging, clear and detailed images are important to help doctors detect and analyze diseases accurately. However, medical images such as magnetic resonance image (MRI) often have low contrast and unclear edges, which can make diagnosis difficult. To improve this, image enhancement and image sharpening techniques are used as preprocessing steps. Image enhancement and sharpening play a pivotal role in medical image processing, where the clarity and contrast of anatomical structures directly impact diagnostic accuracy. Image enhancement focuses on improving the overall brightness and contrast of an image to make hidden areas more visible. Meanwhile, image sharpening aims to highlight fine details and edges, making the boundaries between tissues clearer. This study compares both types of techniques—enhancement and sharpening—to understand their strengths and weaknesses when applied to MR images. Four image enhancement techniques are examined in this paper: Histogram Equalization (HE), Contrast-Limited Adaptive Histogram Equalization (CLAHE), Morphological Residual (MPR) and Type-II Fuzzy Set (T2FS) Contrast Enhancement. For image sharpening, five techniques are considered: Unsharp Masking, High-Boost Filtering, Laplacian Filtering, Nimble Filtering, and Adaptive Sharpening. Finally, the techniques are analyzed using both qualitative and quantitative methods. Based on the results, MPR and Nimble Filtering emerged as the top-performing techniques, yielding PSNR values of 45.0865 dB and 51.6507 dB, SSIM scores of 0.9712 and 0.9979, and MSE values of 0.0027 and 0.1515, respectively. These two approaches were subsequently integrated to form a hybrid method, which achieved superior results with a PSNR of 56.3271 dB, SSIM of 0.9994, and MSE of 0.0071. The proposed hybrid preprocessing strategy offers a promising preprocessing strategy with demonstrated improvement in MRI interpretation.**

***Keywords*—Image Enhancement, Image Sharpening, MRI.**

Corresponding Author: Muhammad Khusairi Osman

## I. Introduction

Medical imaging is essential in providing doctors with clear images of the inside of a person's body. The use of MRI, CT scans, and ultrasound technology allows doctors to identify issues, monitor disease progression, or prepare for treatment without the need for surgery [1, 2]. However, the raw images produced by these modalities often suffer from issues such as low contrast, blurred edges, and background noise [3, 4]. These problems can pose difficulties in identifying significant body parts, which can impact the precision of diagnosis and image processing. A common issue in grayscale medical images—particularly in MRI—is the presence of low contrast between tissues, where the intensity values of the foreground and background are very close. This can result in poor visibility of fine structures such as lesions or organ boundaries. Additionally, the edges separating different anatomical regions may appear blurry or indistinct, complicating the tasks of radiologists and computer-aided diagnosis systems. Therefore, image preprocessing is necessary to enhance the visual quality of medical images before they are interpreted or analysed [5, 6].

Two widely used preprocessing approaches are image enhancement and image sharpening. Image enhancement involves techniques that make an image brighter, more contrasted, and easier to see. Techniques like Histogram Equalization (HE) and Contrast Limited Adaptive Histogram Equalization (CLAHE) are often used in medical imaging [7]. These techniques help make dark or hard-to-see areas more visible, especially in images with low contrast. In recent years, newer enhancement techniques have been developed that use spatial contextual similarity histograms and gamma correction. These techniques improve contrast by looking at how each pixel relates to the pixels around it.

2025 IEEE 15th International Conference on Control System, Computing and Engineering (ICCSCE) | 979-8-3315-1527-0/25/$31.00 ©2025 IEEE | DOI: 10.1109/ICCSCE65566.2025.11182657



Authorized licensed use limited to: University of Zagreb: Faculty of Electrical Engineering and Computing. Downloaded on March 27,2026 at 15:01:32 UTC from IEEE Xplore. Restrictions apply.

In contrast, image sharpening focuses on improving the clarity of edges and fine details. This is particularly useful in highlighting tissue boundaries, edges of tumours, and other structural information critical for accurate diagnosis [8]. Common sharpening techniques include Unsharp Masking, which enhances high-frequency components by subtracting a blurred version of the image; Laplacian filtering, which emphasizes rapid intensity changes; and High-Boost filtering, which boosts fine details while retaining the original image structure.

While both enhancement and sharpening play crucial roles in improving medical images, they serve different purposes and may have different effects on image quality. Enhancement techniques are generally better for improving global visibility and brightness, whereas sharpening techniques are more effective at making edges and structures clearer. However, using these techniques without understanding their effects may introduce unintended artifacts, amplify noise, or distort important anatomical features [9].

This study addresses that gap by performing a systematic comparison between image enhancement and image sharpening techniques for grayscale medical images. The main objective is to evaluate the strengths and weaknesses of each approach in improving image quality for better visibility and diagnostic support. The performance of each technique is assessed through both visual analysis and quantitative metrics, including Peak Signal-to-Noise Ratio (PSNR) and Structural Similarity Index (SSIM). By providing a clear understanding of the capabilities and limitations of enhancement versus sharpening techniques, this study aims to guide researchers and medical professionals in selecting the most suitable preprocessing strategy for specific clinical or research needs..

## II. Methodology

This section presents the detailed steps of the proposed technique for enhancing MRI images. The approach comprises five key stages: data collection, image enhancement, image sharpening, integration of enhancement and sharpening, and performance evaluation. Each stage is elaborated in the following subsections.

### *A. Data Collection*

This study followed the ethical guidelines and was approved by the institutional ethics committee. The data used in this study came from 40 anonymized patient cases collected by the Imaging Department at the Advanced Medical and Dental Institute (AMDI), Universiti Sains Malaysia (USM). The patients were adults (18 years) male and female. All the data was gathered between 2018 and 2021 as part of regular clinical check-ups for those suspected of or confirmed to have had a myocardial infarction (MI). A total of 176 cardiac MRI images, including both scar and normal cases, were extracted from these patient datasets for image enhancement and sharpening analysis.

### *B. Image Enhancement Techniques*

Image enhancement refers to the process of improving the perceptual quality of an image by modifying its pixel intensities or structure in a way that makes important features more discernible [7]. The focus in medical imaging is often to improve the visibility of soft tissues, lesions, and boundaries that might be hard to detect in raw scans. This is especially important in grayscale MRI, where low contrast and subtle intensity differences can obscure critical diagnostic features. To address this, image enhancement was implemented as it was one of the techniques that is widely use that aim to improve visual clarity while preserving anatomical accuracy. Four techniques are examined in this paper: Histogram Equalization (HE), Contrast-Limited Adaptive Histogram Equalization (CLAHE), Morphological Residual Enhancement and Type-II Fuzzy Contrast Enhancement (T2FS).

Histogram Equalization (HE) is a global contrast enhancement technique that redistributes the intensity values of an image to span the entire available grayscale range . It uses the cumulative distribution function (CDF) of the image histogram to transform pixel intensities such that frequently occurring intensity values are spread out, thereby increasing contrast. In medical imaging, HE is often applied to MRI scans with poor global contrast, helping to improve the visibility of soft tissue regions [10]. However, as a global method, it may over-enhance certain areas while under-enhancing others, sometimes leading to the loss of local detail or the amplification of noise in homogeneous regions.

Contrast-Limited Adaptive Histogram Equalization (CLAHE) improves upon traditional HE by operating on small image tiles instead of the entire image, allowing for localized contrast enhancement. Each tile undergoes histogram equalization with a clip limit to prevent over-amplification of noise. The tiles are then merged using bilinear interpolation to ensure smooth transitions. CLAHE is especially effective in grayscale medical images such as MRI, where the intensity of tissues varies across regions. It enhances subtle local features like lesion boundaries or soft tissue structures, making them more distinguishable without compromising overall image quality.

Type-II Fuzzy Set (T2FS) is an adaptive technique designed to enhance image contrast by managing uncertainty in pixel intensity values. It uses interval Type-II fuzzy sets to model a range of membership values, allowing more precise handling of ambiguous regions often found in grayscale medical images such as MRI. Fuzzy inference rules guide the contrast adjustment process, improving visibility in low-contrast areas while preserving important anatomical structures. This technique was effectively applied by Zohair Al-Ameen in his proposed contrast enhancement algorithm based on an improved Type-II fuzzy set, demonstrating strong results in medical image clarity [2].

Morphological Residual Enhancement (MPR) is a structural enhancement technique that focuses on fine details in medical images by processing the residual component. Morphological operations such as dilation and erosion are applied to enhance these features. The enhanced residual is then added back to the base layer to reconstruct a sharper image. This technique enhances anatomical boundaries without amplifying background noise. A notable approach based on this concept is the medical image enhancement strategy using morphologically processed residuals with a special kernel, proposed by Lepcha,



Authorized licensed use limited to: University of Zagreb: Faculty of Electrical Engineering and Computing. Downloaded on March 27,2026 at 15:01:32 UTC from IEEE Xplore. Restrictions apply.

which further refines detail enhancement while preserving structural consistency [11].

### C. Image Sharpening Techniques

Image sharpening techniques aim to improve the clarity of edges and fine structural details within an image by emphasizing high-frequency components. In medical imaging, particularly MRI, sharpening is essential to highlight anatomical boundaries that may appear blurred due to noise, resolution limits, or soft tissue overlap. Effective sharpening helps in better delineation of organs, tissues, and lesions, thus supporting accurate diagnosis. This section discusses five image sharpening techniques: Unsharp Masking, High-Boost Filtering, Laplacian Filtering, Nimble Filtering, and Adaptive Sharpening.

Unsharp Masking is a classical sharpening technique that operates by subtracting a blurred version of the image from the original [8]. This produces a high-frequency mask that is then added back to the original to enhance edge contrast. The technique is simple, computationally efficient, and widely used in medical imaging for highlighting tissue boundaries and internal features. However, overuse can cause unnatural halo effects around edges, so careful parameter tuning is required.

High-Boost Filtering is a generalization of Unsharp Masking, where the original image is multiplied by a scaling factor ($A > 1$) before subtracting the blurred version. The result retains the original image's intensity while enhancing high-frequency components. This technique is suitable when both edge sharpening and preservation of overall brightness are needed, making it useful for clinical scans with low inherent contrast. By adjusting the high-boost factor, the balance between detail enhancement and original content preservation can be fine-tuned to match diagnostic requirements.

Laplacian filtering uses a second-order derivative operator to highlight regions of rapid intensity change, effectively enhancing edges in all directions. It is applied by convolving the image with a Laplacian kernel, which responds strongly to edges and less to flat regions. In medical imaging, Laplacian filtering helps emphasize thin tissue boundaries and can be useful in segmentation or detection tasks. However, it is sensitive to noise and often requires preprocessing or combination with smoothing filters to avoid amplifying unwanted details.

The Nimble Filter, introduced by Zohair Al-Ameen, is an adaptive sharpening technique designed specifically for medical images [12]. It enhances structural clarity by extracting spatial detail from the original image and reinjecting it using a tuneable weight factor, allowing control over the sharpening intensity. Unlike conventional filters, the Nimble Filter minimizes common artifacts such as halos and overshoot by relying on fuzzy logic principles to guide localized enhancement. It has been shown to outperform traditional techniques such as Unsharp Masking and Laplacian filtering, particularly in MRI and CT images, delivering higher PSNR and visual quality. Its adaptive behaviour ensures that fine anatomical structures are sharpened without amplifying noise, making it highly suitable for clinical diagnostics.

Adaptive Sharpening techniques dynamically adjust sharpening strength based on local image information such as edge magnitude and texture, enabling selective enhancement of important structures while avoiding noise amplification in flat regions. In medical imaging, this ensures that diagnostically relevant features like tissue boundaries and lesion edges are emphasized without introducing artifacts.

### D. Combination of Image Enhancement and Sharpening Techniques

In this study, the combination of the best-performing image enhancement and sharpening techniques was applied to improve the visual quality of grayscale medical images, particularly MRI. The combination of image enhancement and sharpening is expected to improve contrast, structural clarity, and minimal distortion, making the output image more suitable for medical diagnosis. The process was applied to multiple MRI images to evaluate its consistency and effectiveness across varying conditions and anatomical regions.

### E. Performance Evaluation

To validate the effectiveness of the proposed techniques, a comprehensive evaluation was conducted using both qualitative and quantitative analyses. These evaluations were performed separately for three categories: (i) image enhancement only, (ii) image sharpening only, and (iii) the combined enhancement and sharpening technique. This separation allowed for a direct comparison of each technique's individual impact and the benefits of their integration.

Qualitative evaluation was performed by visually comparing the output images generated from each technique. Key visual characteristics such as brightness, contrast, clarity of tissue boundaries, and presence of artifacts were analysed.

The quantitative evaluation of image quality was based on three well-established metrics: Peak Signal-to-Noise Ratio (PSNR), Mean Squared Error (MSE), and the Structural Similarity Index Measure (SSIM). Each of these metrics provides a different perspective on how well the processed image preserves the fidelity of the original medical image. Together, these three metrics provide a comprehensive evaluation of the enhancement and sharpening techniques, balancing numerical accuracy with visual fidelity.

## III. Results and Discussion

This section presents the findings of the study based on both qualitative and quantitative evaluations. All results were obtained using grayscale MRI images, and comparisons were made across various enhancement, sharpening, and combined preprocessing techniques. The discussion highlights the strengths and limitations of each technique based on visual quality and objective metrics.

### A. Qualitative Evaluation

Figure 1 shows the comparison of different image enhancement techniques applied to a grayscale cardiac MRI image. The techniques include (a) the original image, (b) Histogram Equalization (HE), (c) Contrast Limited Adaptive Histogram Equalization (CLAHE), (d) Type-II Fuzzy Set-based enhancement (T2FS), and (e) Morphological Residual Processing (MPR).

The original image Fig. 1(a) has visibly low contrast, especially in the soft tissue and myocardial regions, which



Authorized licensed use limited to: University of Zagreb: Faculty of Electrical Engineering and Computing. Downloaded on March 27,2026 at 15:01:32 UTC from IEEE Xplore. Restrictions apply.

makes it harder to distinguish finer anatomical structures. After applying Histogram Equalization Fig. 1(b), a significant increase in global contrast is observed. However, the enhancement is excessive — resulting in saturation and overexposed regions that obscure subtle tissue details, making the image appear unnatural.

The CLAHE technique shown in Fig. 1(c) offers more balanced contrast enhancement. It improves visibility in dark and bright regions by working on localized areas. The soft tissue around the ventricle and cavity boundaries becomes clearer, while overall brightness remains well distributed. However, some local noise is still present, especially in homogeneous regions.

Fig. 1(d) demonstrates T2FS a well-optimized enhancement result, improving contrast without introducing visual artifacts. It better preserves structural consistency and highlights subtle differences between tissues. The boundaries between the ventricle wall and surrounding tissues appear more defined, and the overall image texture remains natural — making it one of the most visually effective techniques.

Lastly, the MPR technique, Fig. 1(e) shows strong enhancement in structural regions by emphasizing edges through morphological residuals. It maintains a sharper anatomical appearance and preserves edge detail, but in some areas, the contrast improvement is less pronounced than T2FS. However, it successfully avoids over-enhancement and retains the natural grayscale appearance, which is critical in medical diagnosis.

Figure 2 presents the visual results of various image sharpening techniques applied to a grayscale cardiac MRI image, including (a) the original image, and the outputs of (b) Unsharp Masking, (c) High-Boost Filtering, (d) Laplacian Filter, (e) Nimble Filter, and (f) Adaptive Sharpening.

Visually, the original image Fig. 2(a) appears slightly soft, with boundaries and tissue interfaces that are not well distinguished. In Unsharp Masking Fig. 2(b), the edges are moderately enhanced, but halo artifacts can be noticed around some high-contrast regions, which may reduce clinical reliability.

High-Boost Filtering Fig. 2(c) offers stronger edge definition, particularly around the left ventricle and surrounding tissues, but introduces slight over-enhancement, resulting in an unnatural sharpness in homogeneous areas.

The Laplacian Filter Fig. 2(d) shows a higher level of contrast in edges, but it also introduces more noticeable noise, especially in darker regions, making fine details harder to interpret. Nimble Filter Fig. 2(e) demonstrates a strong balance between edge enhancement and noise suppression. The anatomical boundaries, such as those of the myocardial wall and internal structures, appear clearer and more natural, with minimal artifact amplification. This makes it the most visually pleasing and diagnostically reliable sharpening technique in the set.

Finally, Adaptive Sharpening Fig. 2(f) adjusts its enhancement based on local image content, producing results that are sharper than the original but more controlled than Laplacian or High-Boost. However, it sometimes fails to enhance very subtle edges effectively, especially in low-contrast zones.

The combination of Morphological Residual Processing (MPR) and the Nimble Filter, as shown in Figure 3(d), delivers a visually superior result compared to using either method alone. This technique enhances soft tissue contrast while sharpening fine anatomical edges, particularly around the myocardial wall and vascular structures. The image exhibits clear intensity balance, with improved visibility of regions that were previously indistinct.

The combination successfully maintains structural clarity without introducing noticeable noise or artifacts, which is essential in medical imaging. Fine textures and lesion borders appear more defined, supporting accurate interpretation. This visual improvement aligns with the quantitative metrics, where the combined technique achieved the highest PSNR and SSIM values, confirming its effectiveness in producing high-quality diagnostic images.

### *A. Quantitative Evaluation*

Table 1 presents the comparative performance of four image enhancement techniques applied to grayscale MRI. The results show that Histogram Equalization (HE) performed the weakest, with a PSNR of 11.94 dB, SSIM of 0.3481, and a high MSE of 0.0639, suggesting that global enhancement approaches may distort image brightness unevenly and fail to preserve essential anatomical detail. These limitations make HE unsuitable for clinical MRI where subtle contrast variations are diagnostically relevant.

CLAHE, which operates locally, demonstrated significant improvement with PSNR of 21.47 dB, SSIM of 0.7265, and MSE of 0.0071. This technique adjusts contrast more precisely and enhances visibility in homogeneous regions; however, it still introduces some amplification of background noise, which is a concern for diagnostic imaging. The Type-II Fuzzy Set (T2FS) technique delivered better performance, as reflected in PSNR of 39.05 dB, SSIM of 0.8208, and MSE of 0.0041. Its fuzzy logic approach allows it to handle grayscale ambiguity and adjust pixel intensity based on uncertainty, resulting in clearer tissue differentiation without introducing harsh transitions. Among all, the MPR achieved the highest enhancement quality, with a PSNR of 45.09 dB, SSIM of 0.9712, and MSE of 0.0027, as shown in Table 1. By focusing on residual detail and reinforcing structural information through morphological operations, MPR preserved anatomical edges while improving overall image contrast.

Referring to Table 2, sharpening results varied across five techniques. High-Boost Filtering performed poorly with a PSNR of 27.67 dB, SSIM of 0.6731, and MSE of 0.0571, indicating excessive sharpening that likely introduced visual artifacts and degraded structural fidelity. Such results suggest that this technique is too aggressive for sensitive medical images.

Unsharp Masking, while achieving a high SSIM of 0.9975 and PSNR of 43.57 dB, showed an unacceptably high MSE of 0.7023, which implies significant pixel-level deviations despite visual sharpness. This makes it unreliable for diagnostic imaging where pixel accuracy is essential.



Authorized licensed use limited to: University of Zagreb: Faculty of Electrical Engineering and Computing. Downloaded on March 27,2026 at 15:01:32 UTC from IEEE Xplore. Restrictions apply.

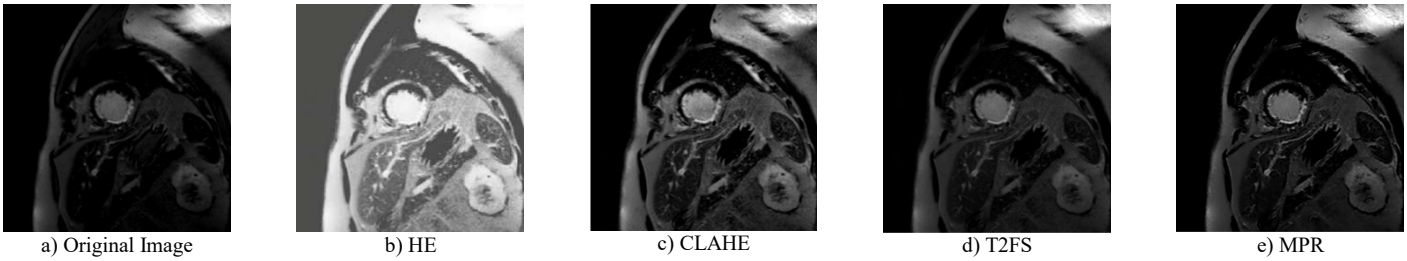

a) Original Image b) HE c) CLAHE d) T2FS e) MPR

Fig. 1. Visual results of different image enhancement techniques on a grayscale MRI image: (a) Original image, (b) Histogram Equalization (HE), (c) Contrast Limited Adaptive Histogram Equalization (CLAHE), (d) Type-II Fuzzy Set-based Enhancement (T2FS), and (e) Morphological Residual Processing (MPR)

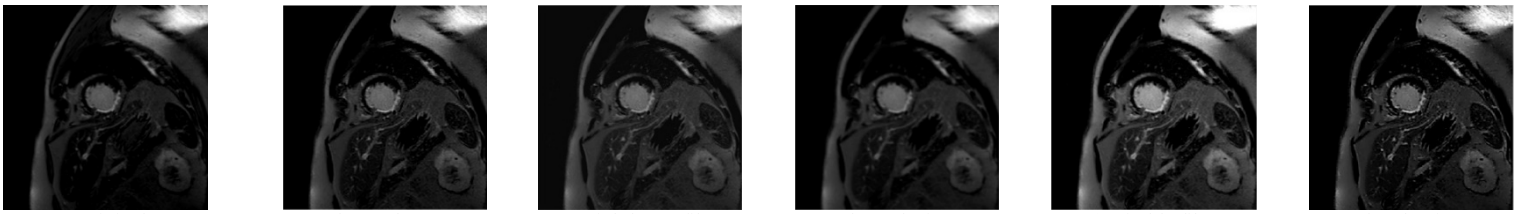

a) Original Image b) Unsharp Masking c) High-boost filter d) Laplacian Filter e) Nimble filter f) Adaptive Sharpening

Fig. 2. Visual comparison of sharpening techniques applied to a grayscale MRI image: (a) Original image, (b) Unsharp Masking, (c) High-Boost Filter, (d) Laplacian Filter, (e) Nimble Filter, and (f) Adaptive Sharpening.

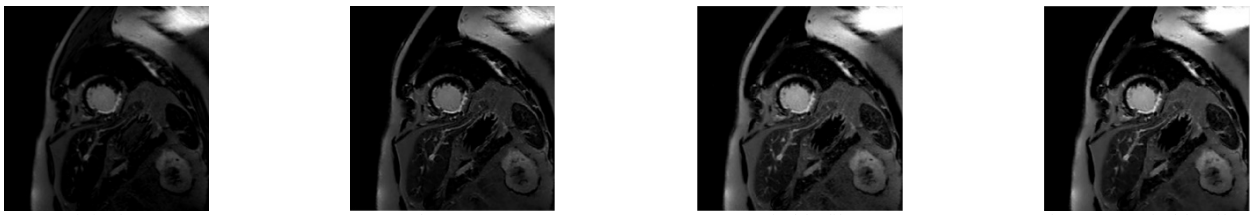

a) Original Image b) MPR c) Nimble filter d) MPR + Nimble Filter

Fig. 3. Visual comparison of the combined image processing approach: (a) Original image, (b) Image enhanced using Morphological Residual Processing (MPR), (c) Image sharpened using Nimble Filter, and (d) Final combined output using hybrid MPR + Nimble Filter.

TABLE I. EVALUATION RESULTS FOR FOUR ENHANCEMENT TECHNIQUES ON MRI IMAGES.

| **Image Enhancement Technique** | **Evaluation Metrics** | | |
|---|---|---|---|
| | **PSNR (dB)** | **SSIM** | **MSE** |
| **HE** | 11.9411 | 0.3481 | 0.0639 |
| **CLAHE** | 21.4705 | 0.7265 | 0.0071 |
| **T2FS** | 39.0471 | 0.8208 | 0.0041 |
| **MPR** | **45.0865** | **0.9712** | **0.0027** |

TABLE II. EVALUATION RESULTS FOR FIVE SHARPENING TECHNIQUES ON MRI IMAGES.

| **Image Sharpening Technique** | **Evaluation Metrics** | | |
|---|---|---|---|
| | **PSNR (dB)** | **SSIM** | **MSE** |
| **Unmask Sharpening** | 43.5684 | 0.9975 | 0.7023 |
| **High-boost Filter** | 27.6741 | 0.6731 | 0.0571 |
| **Laplacian Filter** | 38.9175 | 0.9752 | 0.0012 |
| **Nimble Filter** | **51.6507** | **0.9979** | 0.1515 |
| **Adaptive Sharpening** | 49.6854 | 0.9933 | 0.0014 |

TABLE III. EVALUATION RESULTS OF COMBINED IMAGE ENHANCEMENT AND SHARPENING TECHNIQUES.

| **Combined Technique** | **Evaluation Metrics** | | |
|---|---|---|---|
| | **PSNR (dB)** | **SSIM** | **MSE** |
| **Laplacian Filter** | 45.0865 | 0.9712 | 0.0027 |
| **Nimble Filter** | 51.6507 | 0.9979 | 0.1515 |
| **MPR + Nimble** | **56.3271** | **0.9994** | **0.0071** |



Authorized licensed use limited to: University of Zagreb: Faculty of Electrical Engineering and Computing. Downloaded on March 27,2026 at 15:01:32 UTC from IEEE Xplore. Restrictions apply.

More stable performance was achieved with Laplacian Filtering, which provided PSNR of 38.92 dB, SSIM of 0.9752, and a very low MSE of 0.0012. Similarly, Adaptive Sharpening yielded PSNR of 49.69 dB, SSIM of 0.9933, and MSE of 0.0014. Both techniques preserved edge structures while minimizing distortion, with Adaptive Sharpening adapting well to different regions in the image.

The Nimble Filter, however, recorded the best sharpening result in Table 2, achieving the highest PSNR of 51.65 dB, SSIM of 0.9979, and a moderate MSE of 0.1515. Despite not having the lowest MSE, its strong perceptual quality, guided by fuzzy inference, makes it particularly useful for refining fine anatomical edges in MRI. It demonstrates how intelligent, rule-based sharpening can outperform traditional filters when preserving both visual quality and structure.

The combined techniques shown in Table 3 evaluate the synergy between enhancement and sharpening. The Laplacian Filter, when evaluated independently, maintained its base metrics (PSNR of 45.09 dB, SSIM of 0.9712, MSE of 0.0027) without added enhancement.

The Nimble Filter alone recorded PSNR of 51.65 dB, SSIM of 0.9979, and MSE of 0.1515, consistent with Table 2. These results affirm its strength as a standalone sharpening technique, though pixel error remains noticeable.

The most effective combination was the MPR + Nimble Filter, producing a PSNR of 56.33 dB, SSIM of 0.9994, and MSE of 0.0071, as listed in Table 3. This pairing leverages MPR's ability to enhance soft tissue boundaries and the Nimble Filter's capacity to sharpen edge structures without creating artifacts. The combined performance surpassed any single technique, demonstrating a synergistic effect where enhancement and sharpening reinforce each other to yield superior image clarity and diagnostic quality.

## IV. Conclusion

The conclusion of this study highlights the effectiveness of evaluating various image enhancement and sharpening techniques to improve grayscale medical images, particularly cardiac MRI. The primary objective was to determine the most effective combination of methods that enhance both contrast and structural clarity. Several enhancement methods (HE, CLAHE, T2FS, and MPR) and sharpening methods (Unsharp Masking, High-Boost, Laplacian, Nimble Filter, and Adaptive Sharpening) were implemented and assessed. Among these, Morphological Residual Processing (MPR) and the Nimble Filter produced the most promising individual outcomes, and their combination delivered the highest image quality with a PSNR of 56.33 dB and SSIM of 0.9994. This demonstrates that a hybrid approach effectively enhances brightness, contrast, and edge definition for better diagnostic interpretation. For future work, the combined method can be integrated into deep learning pipelines to support automated myocardial infarction detection or segmentation, and further validated across larger datasets and additional imaging modalities.

## Acknowledgment

The authors gratefully acknowledge the Imaging Department of AMDI, Universiti Sains Malaysia (USM), for providing access to the LGE-CMR datasets. Special thanks to the radiologists involved in the manual annotation process. The authors also thank UiTM Cawangan Pulau Pinang for providing the necessary facilities and support throughout the research process. This study was supported by the Ministry of Higher Education through FRGS grant FRGS/1/2023/SKK06/UITM/02/12. Ethical clearance was obtained from the Human Research Ethics Committee of USM (JEPeM Code: USM/JEPeM/21090623).

## References

[1] Z. Chen, K. Pawar, M. Ekanayake, C. Pain, S. Zhong, and G. F. Egan, "Deep Learning for Image Enhancement and Correction in Magnetic Resonance Imaging—State-of-the-Art and Challenges," Journal of Digital Imaging, vol. 36, no. 1, pp. 204-230, 2023/02/01 2023, doi: 10.1007/s10278-022-00721-9.

[2] Z. Al-Ameen, "Contrast Enhancement of Digital Images Using an Improved Type-II Fuzzy Set-Based Algorithm," Traitement du Signal, vol. 38, pp. 39-50, 02/28 2021, doi: 10.18280/ts.380104.

[3] A. S. Fahmy, E. J. Rowin, R. H. Chan, W. J. Manning, M. S. Maron, and R. Nezafat, "Improved Quantification of Myocardium Scar in Late Gadolinium Enhancement Images: Deep Learning Based Image Fusion Approach," Journal of Magnetic Resonance Imaging, vol. 54, no. 1, pp. 303-312, 2021/07/01 2021, doi: https://doi.org/10.1002/jmri.27555.

[4] Y. Jiang, L. Cui, B. Jiang, X. Zhao, and S. Chai, "Cardiac MRI Image Enhancement Based on GAN Network," in 2024 43rd Chinese Control Conference (CCC), 28-31 July 2024 2024, pp. 8309-8315, doi: 10.23919/CCC63176.2024.10661588.

[5] K. Srinivas, A. K. Bhandari, and A. Singh, "Low-contrast image enhancement using spatial contextual similarity histogram computation and color reconstruction," Journal of the Franklin Institute, vol. 357, no. 18, pp. 13941-13963, 2020/12/01/ 2020, doi: https://doi.org/10.1016/j.jfranklin.2020.10.013.

[6] X. Yu, L. Bo, and C. Xin, "Low light combining multiscale deep learning networks and image enhancement algorithm," Современные инновации, системы и технологии - Modern Innovations, Systems and Technologies, vol. 2, pp. 0215-0232, 11/28 2022, doi: 10.47813/2782-2818-2022-2-4-0215-0232.

[7] K. Shi, "Comparison of Image Enhancement Algorithms Based on Denoising and Edge Detection," Applied and Computational Engineering, vol. 133, pp. 174-184, 02/08 2025, doi: 10.54254/2755-2721/2025.20700.

[8] V. Bogdan, C. Bonchiş, and C. Orhei, An Image Sharpening Technique based on Dilated Filters and 2D-DWT Image Fusion. 2024.

[9] J. L. Clark, C. P. Wadhwani, K. Abramovitch, D. D. Rice, and M. T. Kattadiyil, "Effect of image sharpening on radiographic image quality," The Journal of Prosthetic Dentistry, vol. 120, no. 6, pp. 927-933, 2018/12/01/ 2018, doi: https://doi.org/10.1016/j.prosdent.2018.03.034.

[10] M. Mukaida, Y. Ueda, and N. Suetake, "Low-Light Image Enhancement Method Using a Modified Gamma Transform and Gamma Filtering-Based Histogram Specification for Convex Combination Coefficients," IEICE Transactions on Fundamentals of Electronics, Communications and Computer Sciences, vol. E106.A, no. 11, pp. 1385-1394, 2023, doi: 10.1587/transfun.2023SMP0003.

[11] D. Lepcha, B. Goyal, A. Dogra, S. H. Wang, and J. Chohan, "Medical image enhancement strategy based on morphologically processing of residuals using a special kernel," Expert Systems, 12/04 2022, doi: 10.1111/exsy.13207.

[12] Z. Al-Ameen, "Sharpness Improvement for Medical Images Using a New Nimble Filter," 3D Research, vol. 9, 04/04 2018, doi: 10.1007/s13319-018-0164-0.



Authorized licensed use limited to: University of Zagreb: Faculty of Electrical Engineering and Computing. Downloaded on March 27,2026 at 15:01:32 UTC from IEEE Xplore. Restrictions apply.