Cureus
Part of SPRINGER NATURE

Open Access Case Report

Infective Endocarditis Revealed by Ischemic Stroke in a Young Patient

Ismail Bouzekraoui [1], Myriam Lahraoui [2], Abdelkader Benhlima [3], Mouhssine Doumiri [1], Mourad Amor [1]

1. Neurocritical Care, Ibn Sina University Hospital, Mohammed V University, Rabat, MAR 2. Cardiology B, Ibn Sina University Hospital, Mohammed V University, Rabat, MAR 3. Neurocritical care, Ibn Sina University Hospital, Mohammed V University, Rabat, MAR

Corresponding author: Ismail Bouzekraoui, ismail.bouzekraoui@gmail.com

Review began 10/23/2025
Review ended 11/05/2025
Published 11/15/2025

© Copyright 2025
Bouzekraoui et al. This is an open access article distributed under the terms of the Creative Commons Attribution License CC-BY 4.0., which permits unrestricted use, distribution, and reproduction in any medium, provided the original author and source are credited.

DOI: 10.7759/cureus.96935

Abstract

Ischemic stroke is commonly caused by emboli of cardiac or atherosclerotic origin. In young adults, embolic cardiopathies, especially infective endocarditis, are a significant though rare cause. Infective endocarditis represents a contraindication to thrombolysis and therapeutic anticoagulation due to the high risk of hemorrhagic transformation. We report the case of a 26-year-old man who presented an ischemic stroke in the right middle cerebral artery territory due to an infective endocarditis.

Categories: Neurology, Cardiology
Keywords: hemodynamic instability (hdi), infective endocarditis , : ischemic stroke, neurology and critical care, young adult male

Introduction

Ischemic strokes represent 90% of all cerebrovascular events and represent the main cause of acquired adult disability, followed by dementia, and death worldwide [1,2]. Among the etiological mechanisms, large artery atherosclerosis, cardioembolic events, and small vessel disease dominate [3,4].

Infective endocarditis is a rare and severe cause of ischemic stroke, especially in young individuals with no history of cardiovascular disease. Neurological complications can happen in 20-60% of patients and can be the main presentation in 10-20% [5,6]. These complications carry a high risk of morbidity and mortality, necessitating early diagnosis and management. We report the case of a young man who presented for ischemic stroke caused by infective endocarditis.

Case Presentation

A 26-year-old male patient, with a history of recurrent untreated childhood tonsillitis, presented with a sudden-onset left hemiparesis, facial asymmetry, and dysarthria six hours before his admission to the hospital. Upon admission to the emergency department, he was conscious (GCS 15). The motor assessment found left-sided weakness graded 0/5 in the upper limb and 2/5 in the lower limb, the National Institutes of Health Stroke Scale (NIHSS) score was at 10, and the modified Rankin Scale (mRS) at 4. Blood pressure was 150/70 mmHg, heart rate 90 bpm, oxygen saturation was 97% in ambient air, and blood glucose was 1.35 g/l. Cardiovascular auscultation revealed a systolic murmur at the mitral focus.

Brain CT and cerebral MRI angiography (Figure *1*) showed an infarction of the deep territory of the right middle cerebral artery without perfusion mismatch (Diffusion+, FLAIR+), contraindicating thrombolysis or mechanical thrombectomy. He was admitted to the neurology department.

How to cite this article
Bouzekraoui I, Lahraoui M, Benhlima A, et al. (November 15, 2025) Infective Endocarditis Revealed by Ischemic Stroke in a Young Patient. Cureus 17(11): e96935. DOI 10.7759/cureus.96935

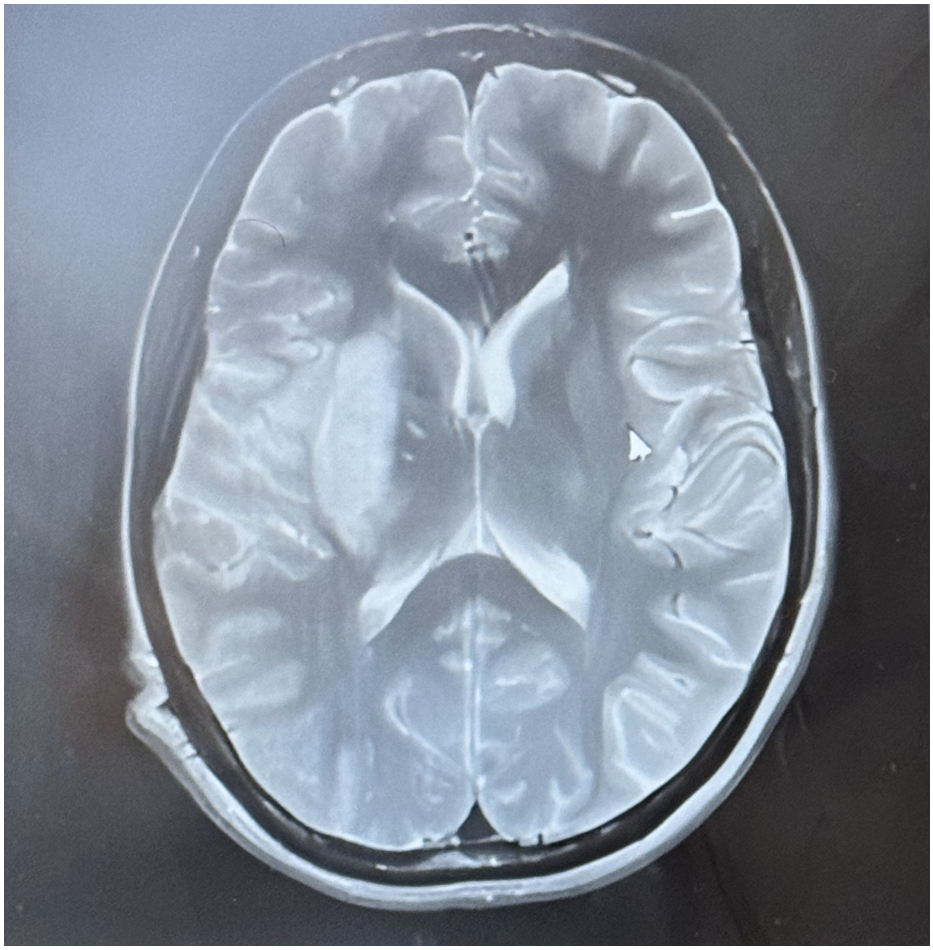

FIGURE 1: Brain MRI showing an ischemic stroke in the deep territory of the right middle cerebral artery

On Day 1, he developed hypotension (BP 80/60 mmHg), not responding to fluid resuscitation, requiring ICU transfer. Upon admission to the intensive care unit, we started norepinephrine for a systolic blood pressure target of 140 mmHg. EKG showed sinus rhythm and no conduction disturbance; Doppler ultrasound of the vascular axes of the neck does not reveal any carotid stenosis. Transthoracic echocardiography revealed mitral regurgitation with suspicion of mobile structures on the posterior leaflet. Transesophageal echocardiography confirmed a prolapsed, shredded P2 segment of the mitral valve with mobile vegetations (largest 17 mm) and a patent foramen ovale (Figures *2*-*3*).

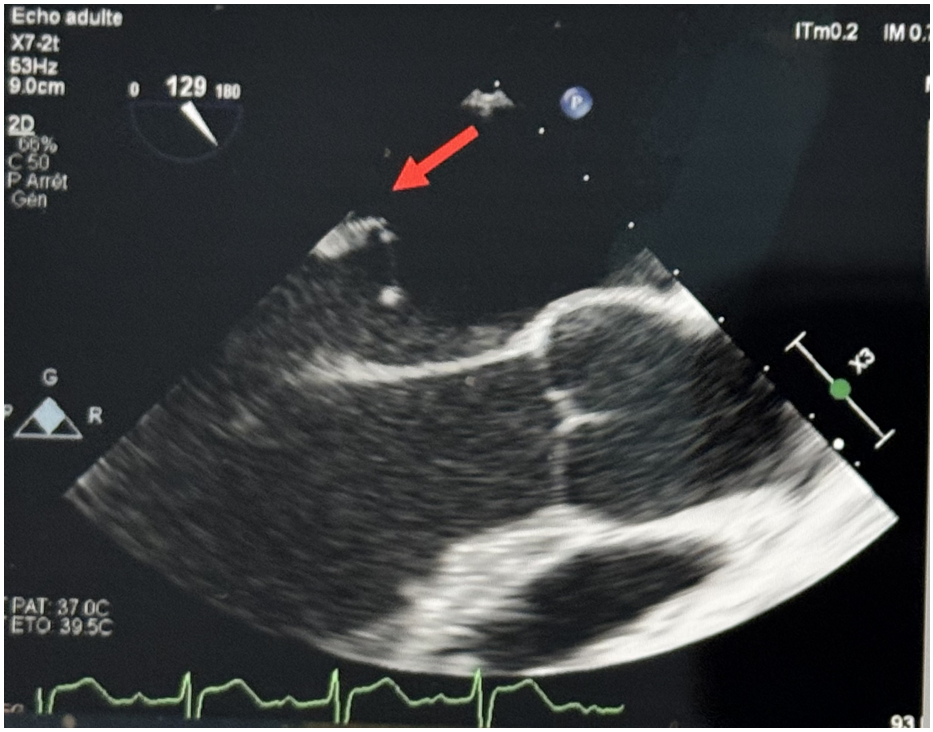

FIGURE 2: Transoesophageal echocardiography 3 chamber view showing a mobile, filiform structure measuring 17 mm attached to the atrial side of the P2 scallop of the mitral valve

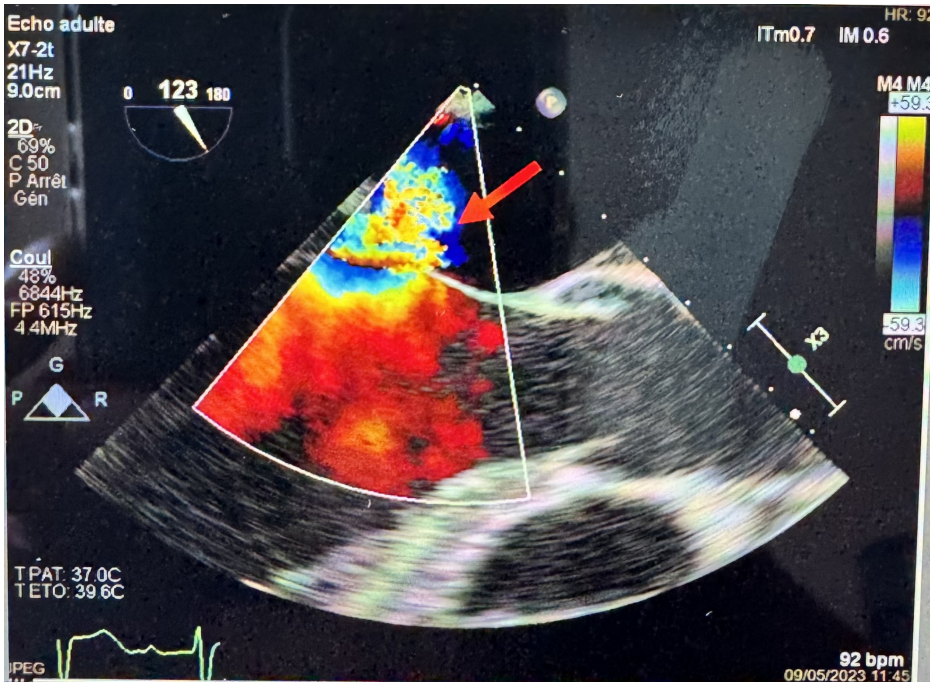

FIGURE 3: Transoesophageal echocardiography 3 chamber view demonstrating the severity of the mitral regurgitation

Based on the modified Duke criteria (one major: vegetations; three minor: fever >38°C, cardiac predisposition, vascular embolism), the diagnosis of infective endocarditis was established. Empiric antibiotic therapy with amoxicillin at the rate of 2g per 8h (100mg/kg/day) and gentamicin 180mg per day (3mg/kg/day) was initiated after doing blood cultures.

Given the hemodynamic instability and persistent mitral insufficiency, the patient underwent early mitral valve replacement surgery on Day 10 post-stroke. Postoperative evolution was favorable.

Discussion

Neurological complications are frequent in IE. Ischemic stroke may precede diagnosis, particularly in younger patients. MRI is preferred over CT due to its higher sensitivity [7]. In left-sided IE, silent cerebral infarcts occur in 30% of cases, and neurological complications in up to 65% [7].

Intravenous thrombolysis is contraindicated because of the high risk of hemorrhagic transformation [8,9]. A 2019 meta-analysis found no hemorrhagic events after thrombectomy, compared with 61% with IV thrombolysis and 45% with combined therapy [10]. However, recanalization rates are lower in IE-related stroke (74%) than in other etiologies (87.5%) [11].

The efficacy of antithrombotic therapy remains a subject of debate. Antiplatelet agents may reduce embolic events and are usually continued, while anticoagulation increases hemorrhagic risk, especially after stroke [12,13].

Surgery is indicated in severe valvular regurgitation with heart failure, uncontrolled infection, or fungal IE [14]. Early surgery does not increase perioperative stroke risk [11,12] and significantly reduces embolic events (0% vs. 21% with medical therapy) [14].

Conclusions

Ischemic stroke may be the initial manifestation of infective endocarditis, particularly in younger patients. Optimal management requires a multidisciplinary approach, including comprehensive cardiac evaluation and prompt neuroimaging. In carefully selected cases, early surgical intervention improves prognosis and significantly reduces the risk of recurrence.

Additional Information

Author Contributions

All authors have reviewed the final version to be published and agreed to be accountable for all aspects of the work.

Concept and design: Ismail Bouzekraoui, Myriam Lahraoui , Abdelkader Benhlima

Drafting of the manuscript: Ismail Bouzekraoui, Myriam Lahraoui , Abdelkader Benhlima

Acquisition, analysis, or interpretation of data: Mouhssine Doumiri, Mourad Amor

Critical review of the manuscript for important intellectual content: Mouhssine Doumiri, Mourad Amor

Disclosures

Human subjects: Informed consent for treatment and open access publication was obtained or waived by all participants in this study. **Conflicts of interest:** In compliance with the ICMJE uniform disclosure form, all authors declare the following: **Payment/services info:** All authors have declared that no financial support was received from any organization for the submitted work. **Financial relationships:** All authors have declared that they have no financial relationships at present or within the previous three years with any organizations that might have an interest in the submitted work. **Other relationships:** All authors have declared that there are no other relationships or activities that could appear to have influenced the submitted work.

References

1. Sarti C, Rastenyte D, Cepaitis Z, Tuomilehto J: International trends in mortality from stroke, 1968 to 1994. Stroke. 2000, 31:1588-601. 10.1161/01.str.31.7.1588
2. Bonita R, Solomon N, Broad JB: Prevalence of stroke and stroke-related disability. Estimates from the Auckland stroke studies. Stroke. 1997, 28:1898-902. 10.1161/01.str.28.10.1898
3. Schulz UG, Rothwell PM: Differences in vascular risk factors between etiological subtypes of ischemic stroke: importance of population-based studies. Stroke. 2003, 34:2050-9. 10.1161/01.STR.0000079818.08343.8C
4. Kolominsky-Rabas PL, Weber M, Gefeller O, Neundoerfer B, Heuschmann PU: Epidemiology of ischemic stroke subtypes according to TOAST criteria: incidence, recurrence, and long-term survival in ischemic stroke subtypes: a population-based study. Stroke. 2001, 32:2735-40. 10.1161/hs1201.100209
5. Habib G: Management of infective endocarditis. Heart. 2006, 92:124-30. 10.1136/hrt.2005.063719
6. Le Guillou V, Perot G, Triquenot-Bagan A: Endocardites infectieuses et complications neurologiques:

stratégie opératoire [article in French]. Chirurgie Thoracique Cardio-Vasculaire. 2010, 15:97-103.
7. Snygg-Martin U, Gustafsson L, Rosengren L, Alsiö A, Ackerholm P, Andersson R, Olaison L: Cerebrovascular complications in patients with left-sided infective endocarditis are common: a prospective study using magnetic resonance imaging and neurochemical brain damage markers. Clin Infect Dis. 2008, 47:23-30. 10.1086/588663
8. Tornos P, Almirante B, Mirabet S, Permanyer G, Pahissa A, Soler-Soler J: Infective endocarditis due to Staphylococcus aureus: deleterious effect of anticoagulant therapy. Arch Intern Med. 1999, 159:473-5. 10.1001/archinte.159.5.473
9. Baddour LM, Wilson WR, Bayer AS, et al.: Infective endocarditis: diagnosis, antimicrobial therapy, and management of complications: a statement for healthcare professionals from the Committee on Rheumatic Fever, Endocarditis, and Kawasaki Disease, Council on Cardiovascular Disease in the Young, and the Councils on Clinical Cardiology, Stroke, and Cardiovascular Surgery and Anesthesia, American Heart Association: endorsed by the Infectious Diseases Society of America. Circulation. 2005, 111:e394-434. 10.1161/CIRCULATIONAHA.105.165564
10. Anavekar NS, Tleyjeh IM, Anavekar NS, et al.: Impact of prior antiplatelet therapy on risk of embolism in infective endocarditis. Clin Infect Dis. 2007, 44:1180-6. 10.1086/513197
11. Barsic B, Dickerman S, Krajinovic V, et al.: Influence of the timing of cardiac surgery on the outcome of patients with infective endocarditis and stroke. Clin Infect Dis. 2013, 56:209-17. 10.1093/cid/cis878
12. Gaca JG, Sheng S, Daneshmand MA, et al.: Outcomes for endocarditis surgery in North America: a simplified risk scoring system. J Thorac Cardiovasc Surg. 2011, 141:98-106.e1-2. 10.1016/j.jtcvs.2010.09.016
13. Yanagawa B, Pettersson GB, Habib G, Ruel M, Saposnik G, Latter DA, Verma S: Surgical management of infective endocarditis complicated by embolic stroke: practical recommendations for clinicians. Circulation. 2016, 134:1280-92. 10.1161/CIRCULATIONAHA.116.024156
14. Kang DH, Kim YJ, Kim SH, et al.: Early surgery versus conventional treatment for infective endocarditis . N Engl J Med. 2012, 366:2466-73. 10.1056/NEJMoa1112843