Cureus
Part of SPRINGER NATURE

Open Access Case Report

Published via The Florida Medical Student Research Publications

# Anesthetic Considerations in Sturge-Weber Syndrome: A Case Report

Neslida Kodra [1], Karina Escalona [1], Peter Hsin [2], Gerald Rosen [1], Jonathan Tuman [1], Miguel E. Perez-Viloria [1]

1. Anesthesiology, Mount Sinai Medical Center, Miami Beach, USA 2. Anesthesiology, Florida International University, Herbert Wertheim College of Medicine, Miami, USA

**Corresponding author:** Neslida Kodra, neslidakodra@gmail.com

**Received** 02/07/2026
**Review began** 03/22/2026
**Review ended** 03/30/2026
**Published** 04/02/2026

**© Copyright** 2026
Kodra et al. This is an open access article distributed under the terms of the Creative Commons Attribution License CC-BY 4.0., which permits unrestricted use, distribution, and reproduction in any medium, provided the original author and source are credited.

**DOI:** 10.7759/cureus.106331

## Abstract

Sturge-Weber syndrome (SWS) is a rare congenital neurocutaneous disorder presenting unique anesthetic challenges due to extensive vascular malformations. Key considerations include difficult airway management due to extensive facial and oral angiomas, seizure control, and maintaining stable intracranial and intraocular pressures. This case report discusses the perioperative management of a 57-year-old female with SWS undergoing dental surgery under general anesthesia and synthesizes the current literature on anesthetic considerations and management. Preoperative examination revealed a facial port-wine stain covering more than 75% of the face, extensive oral angiomas, macroglossia, and severe lip hypertrophy, raising concerns for difficult airway management and risk of hemorrhage. A rapid sequence induction was performed following upright preoxygenation, and video laryngoscopy provided a grade I view of the glottis. Endotracheal intubation was accomplished atraumatically, and the case proceeded uneventfully. The patient was extubated but experienced mild desaturation in the post-anesthesia care unit, prompting overnight observation before discharge at baseline oxygenation. This case highlights the importance of anticipating and planning for difficult airway management, maintaining vigilance for perioperative seizure control, and implementing strategies to minimize elevations in intracranial and intraocular pressures.

**Categories:** Neurology, Internal Medicine, Anesthesiology
**Keywords:** airway vascular malformations, anesthetic management, difficult airway, intracranial pressure, intraocular pressure, neurocutaneous disorder, seizure disorder, sturge-weber syndrome

## Introduction

Sturge-Weber syndrome (SWS) is a rare congenital neurocutaneous disorder characterized by cutaneous, ocular, and cerebral vascular malformations. It is caused by sporadic mutations in the *GNAQ* gene and, less commonly, the *GNA11* gene, leading to abnormal blood vessel development, with an incidence of 1 in 20,000 to 50,000 live births [1]. The hallmark port-wine stain, a facial capillary malformation, occurs in over 90% of patients [2]. Neurological involvement is often present due to leptomeningeal angiomas on the pia and arachnoid layers of the brain, which can trigger seizure activity and impair venous drainage, potentially contributing to increased intracranial pressure (ICP) [2,3]. Ocular disease is also common, with up to 70% of patients developing glaucoma as well as choroidal angiomas, which can lead to retinal detachment and vision loss [1]. From an anesthetic standpoint, SWS presents significant challenges due to vascular malformations involving the face, oral cavity, and airway, which increase the risk of bleeding, distortion of anatomy, and difficulty with mask ventilation or intubation [4]. Additionally, these patients may be on long-term antiepileptic therapy, requiring careful perioperative drug selection and seizure prophylaxis. The presence of leptomeningeal and ocular vascular malformations further necessitates strategies to minimize elevations in intracranial and intraocular pressures [4]. Although individual case reports have described anesthetic considerations in patients with SWS, standardized management guidelines remain limited. We present the anesthetic management of a 57-year-old female with SWS undergoing dental surgery and provide a review of key perioperative considerations to highlight practical strategies for optimizing outcomes in this complex patient population.

## Case Presentation

A 57-year-old female with a body mass index (BMI) of 27 kg/m² and a history of SWS, glaucoma, and epilepsy presented to our hospital for elective dental surgery under general anesthesia. A physical examination revealed a port-wine stain covering >75% of the face and large oral angiomas involving the lips and buccal mucosa with severe edema and lip protrusion (Figure *1A*). Macroglossia and facial hypertrophy were also noted (Figure *1B*). Preoperatively, vitals were within normal limits with oxygen saturation at 99-100%. There were clinical signs or a history of increased ICP preoperatively.

**How to cite this article**
Kodra N, Escalona K, Hsin P, et al. (April 02, 2026) Anesthetic Considerations in Sturge-Weber Syndrome: A Case Report. Cureus 18(4): e106331. DOI 10.7759/cureus.106331

**FIGURE 1: (A) Preoperative photograph demonstrating extensive facial port-wine stain with large angiomas covering the lips and buccal mucosa. (B) Intraoperative view following induction and endotracheal intubation.**

Rapid sequence induction (RSI) was planned due to the inability to mask ventilate in the setting of extensive oral vascular involvement and facial edema. Midazolam was administered, and the patient was pre-oxygenated in an upright position with a loose mask. RSI was performed with lidocaine, fentanyl, propofol, and succinylcholine. The patient was then laid supine, and GlideScope-assisted video laryngoscopy was used to visualize the airway. A Grade 1 view of the vocal cords was obtained despite edematous soft tissue and epiglottis (Figure *2*). No angiomas were visualized in the pharyngo-larynx, and intubation with a lubricated 7.0 cuffed endotracheal tube (ETT) was successful without bleeding. Care was taken to avoid pressure on facial lesions when securing the tube.

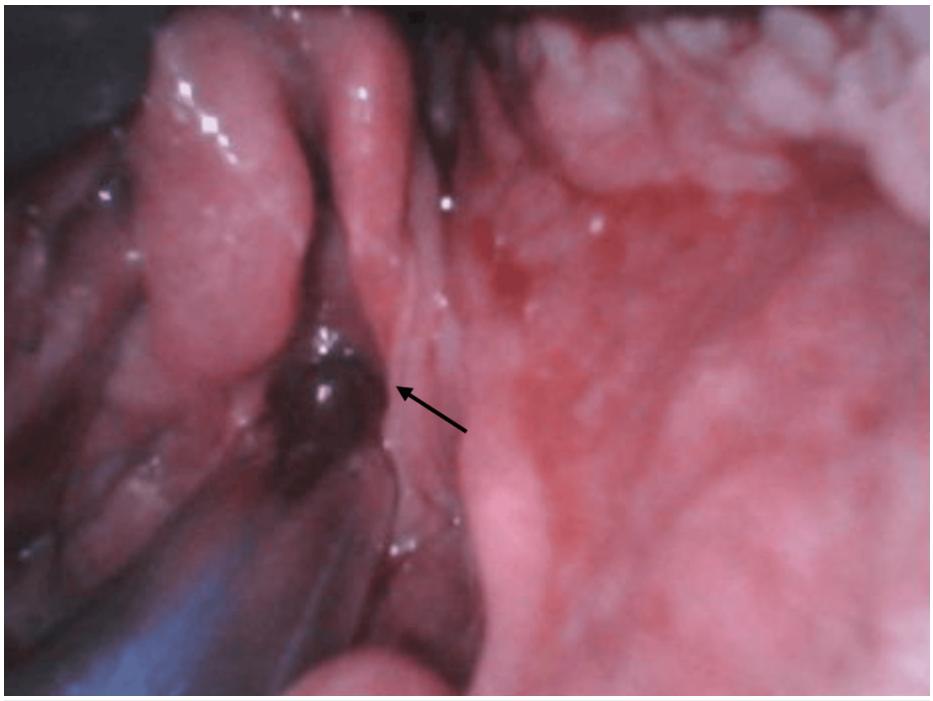

**FIGURE 2: GlideScope-assisted Grade 1 view of the glottis.**

General anesthesia was maintained with sevoflurane at a minimum alveolar concentration (MAC) of 0.8 to 1, supplemented with small boluses of fentanyl and dexmedetomidine. The patient remained hemodynamically stable throughout the procedure with oxygen saturation of 99-100% throughout the procedure. There were no concerns for increased intracranial or intraocular pressures. At the end of the 80-minute procedure, the patient was extubated smoothly but developed mild desaturation with oxygen saturation between 94% and 96% in the post-anesthesia care unit (PACU). Given the risk of potential airway edema, she was admitted for overnight observation and discharged the next morning at baseline oxygenation.

# Discussion

## Airway challenges and considerations

Airway management in patients with SWS is complicated by vascular malformations of the lips, buccal mucosa, tongue, gingiva, and, occasionally, the larynx or trachea [4]. The extent of airway involvement may be difficult to assess preoperatively. Although not routinely performed, preoperative magnetic resonance imaging (MRI) may be considered to assess the degree of airway involvement, particularly in cases where significant intraoral or pharyngeal involvement is suspected [2].

Mask ventilation is often difficult due to edema, lip protrusion, and facial asymmetry, which compromise seal and risk angioma rupture. Strategies include preoxygenation with a loose mask or RSI to avoid bag-mask ventilation [4]. Difficult mask ventilation in SWS patients is well documented in the literature, with one case report detailing ventilation using a full-sized face mask that covers the entire face; however, success is variable, as airway seal may still be less than ideal [4].

Laryngoscopy must be approached cautiously as these vascular lesions can cause uncontrolled bleeding, even with minor injury during airway manipulation. Additionally, anesthetic agents induce vasodilation, which can expand these vascular lesions, causing obstruction [2]. Alternative airway management strategies are often necessary to minimize trauma, such as video laryngoscopy or fiberoptic intubation, which offers the additional advantage of visualizing subglottic structures. In select oral and maxillofacial procedures, submental intubation has also been described as a technique to avoid transoral manipulation [4]. Some literature also supports the use of smaller ETTs to minimize pressure on fragile airway tissues [5]. Lubrication of both the tube and blade with jelly can minimize friction, and tubes should be secured without compressing angiomas [6]. Laryngeal mask airways have been safely used in pediatric cases [6].

Postoperatively, patients are at risk for airway edema and vascular engorgement, potentially contributing to hypoxemia and delayed respiratory compromise. While most cases of mild desaturation resolve spontaneously, as it did in this patient, patients with a history of progressive disease may be at higher risk for unexpected airway compromise and respiratory deterioration [5,7]. Given our patient did not have a history of lung disease, smoking, or obesity, her mild desaturation of 94% to 96% was potentially due to transient airway edema that resolved in the 24-hour postoperative period. A summary of the airway management in SWS is presented in Table *1*.

| Airway considerations | Challenges | Management |
|---|---|---|
| Extent of airway involvement | Vascular malformations of the lips, buccal mucosa, tongue, gingiva, and, occasionally, the larynx or trachea | Preoperative MRI is not routinely performed, but potentially useful in cases where significant intraoral or pharyngeal involvement is suspected |
| | The extent of airway involvement may be difficult to assess preoperatively | |
| Mask ventilation | Edema, lip protrusion, and facial asymmetry compromise the seal and risk angioma rupture | Preoxygenation with a loose mask or full-sized face mask RSI to avoid bag-mask ventilation |
| Laryngoscopy | Risk of uncontrolled bleeding during airway manipulation | Video laryngoscopy or fiberoptic intubation (allows for visualization of subglottic structures) |
| | Anesthetic-induced vasodilation can expand the vascular lesions, causing obstruction | Smaller ETTs and lubricated blades/ETTs can minimize pressure on fragile airway tissue |
| Delayed respiratory compromise | Postoperatively, patients are at risk for airway edema and vascular engorgement | Most cases of mild desaturation resolve spontaneously. Close postoperative monitoring for hypoxemia and airway compromise |

**TABLE 1: Airway challenges and management specific to Sturge-Weber syndrome.**

MRI: magnetic resonance imaging; ETT: endotracheal tube; RSI: rapid sequence intubation

## Seizure prevention and management

Seizures are the most common neurologic manifestation in SWS, initially presenting as focal seizures in infancy and progressing to more frequent generalized seizures that can be difficult to control with antiepileptics and are associated with cognitive decline [2,3]. Surgical stress, metabolic changes, and drug interactions can trigger breakthrough seizures. Many antiepileptics can induce hepatic enzymes and alter the metabolism of volatile anesthetics, opioids, and neuromuscular blockers [2]. Twitch monitors can be useful in titrating muscle relaxants, while BIS monitors can help titrate sedation in the setting of potentially altered drug metabolism [2]. Antiepileptics should be continued perioperatively, and restarting oral medications or intravenous alternatives should be considered in prolonged fasting [8]. Standard induction agents such as midazolam and propofol have antiepileptic properties and have been used safely in SWS patients undergoing anesthesia. While studies have shown that sevoflurane has stronger epileptogenic properties compared to isoflurane and nitrous, these epileptiform discharges are typically observed at greater than 1.5 MAC anesthesia. Therefore, sevoflurane is generally considered safe at clinical concentrations in patients with epilepsy [9]. Additionally, factors that can precipitate seizures, such as hypoglycemia, hypotension, hypoxemia, and hyperthermia, should be avoided [2].

## Managing intracranial and intraocular pressures

Patients with SWS are at increased risk of developing elevated ICP due to leptomeningeal angiomatosis, which can impair venous drainage of the brain and lead to chronic venous hypertension and progressive cerebral atrophy. Inhalational agents, while generally safe, can increase cerebral blood flow at higher concentrations. Both sevoflurane and nitrous oxide have been safely used for maintenance of anesthesia in SWS patients [6,10]. Propofol and midazolam are often used for their ICP-lowering effects, and ketamine, which was historically avoided due to concerns of increasing ICP, has more recently been shown to be safe in controlled settings [6]. Strategies to minimize ICP include head elevation, normocapnia to mild hypocapnia, and careful fluid administration to prevent excessive volume expansion. Mannitol or hypertonic saline may be considered if there is concern for acute intraoperative ICP elevation [6].

Glaucoma and choroidal hemangiomas also predispose to elevated intraocular pressure (IOP). Several perioperative factors can increase IOP, including positioning (trendelenburg, prone, or lateral positioning), insufflation of gas during laparoscopic or robotic surgeries, endotracheal intubation, coughing and gagging on extubation, and excessive administration of intravenous fluids [11]. Succinylcholine can raise IOP, while inhaled anesthetics and propofol can lower IOP [11]. However, the majority of these factors, with the exception of prolonged positioning, typically only cause short transient spikes in IOP with limited clinical consequence [11]. Therefore, succinylcholine is still routinely used, especially in cases where there is low concern for increased ICP or IOP, such as in this patient.

## Considerations for regional anesthesia

Specific guidelines on the use of regional anesthesia in SWS are lacking in the literature. A literature review did not reveal any documented cases of peripheral nerve blocks performed in patients with SWS; however, neuraxial techniques have been described in obstetric patients [12]. While the majority of these cases (8 out of 11) described cesarean sections under general anesthesia (the majority being elective cases), several cases reported the safe use of epidural and spinal anesthesia [12,13]. While neuraxial anesthesia is not contraindicated, caution is advised due to the potential risk of spinal cord angiomas. While leptomeningeal angiomas primarily affect cerebral tissue, spinal hemangiomas have been reported in overlap syndromes (i.e., Klippel-Trenaunay syndrome), creating a theoretical risk [14]. MRI may be useful to assess for spinal involvement, but its use is limited by contrast contraindications during pregnancy. Choosing between general and neuraxial anesthesia in obstetric patients is challenging and lacks consensus. General anesthesia carries the risk of airway difficulty as well as increases in ICP and IOP, particularly during airway maneuvers, while neuraxial anesthesia risks trauma to potential spinal hemangiomas [13].

# Conclusions

Anesthetic management of SWS requires a tailored approach and incorporating strategies for difficult airway management, seizure control, and regulation of ICP and IOP. This case report highlights the importance of a detailed preoperative evaluation, strategic application of advanced airway techniques, including video laryngoscopy and RSI, and vigilant postoperative monitoring. Our literature review further underscores the need for continuation of antiepileptics and cautious selection of anesthetic agents. Awareness of these considerations can optimize perioperative outcomes in this rare but complex patient population.

# Additional Information

## Author Contributions

All authors have reviewed the final version to be published and agreed to be accountable for all aspects of the work.

**Concept and design:** Peter Hsin, Neslida Kodra, Karina Escalona, Miguel E. Perez-Viloria

**Acquisition, analysis, or interpretation of data:** Peter Hsin, Neslida Kodra, Karina Escalona, Gerald Rosen, Miguel E. Perez-Viloria, Jonathan Tuman

**Drafting of the manuscript:** Peter Hsin, Neslida Kodra, Karina Escalona, Miguel E. Perez-Viloria

**Critical review of the manuscript for important intellectual content:** Peter Hsin, Neslida Kodra, Karina Escalona, Gerald Rosen, Miguel E. Perez-Viloria, Jonathan Tuman

**Supervision:** Miguel E. Perez-Viloria

## Disclosures

**Human subjects:** Informed consent for treatment and open access publication was obtained or waived by all participants in this study. **Conflicts of interest:** In compliance with the ICMJE uniform disclosure form, all authors declare the following: **Payment/services info:** All authors have declared that no financial support was received from any organization for the submitted work. **Financial relationships:** All authors have declared that they have no financial relationships at present or within the previous three years with any organizations that might have an interest in the submitted work. **Other relationships:** All authors have declared that there are no other relationships or activities that could appear to have influenced the submitted work.

# References

1. Sánchez-Espino LF, Ivars M, Antoñanzas J, Baselga E: Sturge-Weber syndrome: a review of pathophysiology, genetics, clinical features, and current management approache. Appl Clin Genet. 2023, 16:63-81. 10.2147/TACG.S363685
2. Kurian R, Lionel KR, Mariappan R: Anesthetic challenges of a child with Sturge-Weber syndrome for epilepsy surgery: a case report. J Neuroanaesthesiol Crit Care. 2019, 6:37-9. 10.1055/s-0038-1675892
3. Lo W, Marchuk DA, Ball KL, Juhász C, Jordan LC, Ewen JB, Comi A: Updates and future horizons on the understanding, diagnosis, and treatment of Sturge-Weber syndrome brain involvement. Dev Med Child Neurol. 2012, 54:214-23. 10.1111/j.1469-8749.2011.04169.x
4. Oda A, Yoshida M, Imamura S, et al.: Anesthetic management of a patient with Sturge-Weber syndrome in sagittal split ramus osteotomy surgery. Clin Case Rep. 2024, 12:e8747. 10.1002/ccr3.8747
5. Gandhi M, Iyer H, Sehmbi H, Datir K: Anaesthetic management of a patient with sturge-weber syndrome undergoing oophorectomy. Indian J Anaesth. 2009, 53:64-7.
6. Khanna P, Ray BR, Govindrajan SR, Sinha R, Chandralekha, Talawar P: Anesthetic management of pediatric patients with Sturge-Weber syndrome: our experience and a review of the literature. J Anesth. 2015, 29:857-61. 10.1007/s00540-015-2042-8
7. Iyer HR, Khatavkar SS, Vyas VH, Patil SS: Intraoral hemangiomas in Sturge-Weber syndrome. Med J DY Patil

Univ. 2014, 7:773-6. 10.4103/0975-2870.144879
8. Wichards WS, Schobben AF, Leijten FS: Perioperative substitution of anti-epileptic drugs . J Neurol. 2013, 260:2865-75. 10.1007/s00415-013-7067-z
9. Iijima T, Nakamura Z, Iwao Y, Sankawa H: The epileptogenic properties of the volatile anesthetics sevoflurane and isoflurane in patients with epilepsy. Anesth Analg. 2000, 91:989-95. 10.1097/00000539-200010000-00041
10. Schiøtz HA, Tanbo TG: Postoperative voiding, bacteriuria and urinary tract infection with Foley catheterization after gynecological surgery. Acta Obstet Gynecol Scand. 2006, 85:476-81. 10.1080/00016340500409877
11. Roth S, Moss HE, Vajaranant TS, Sweitzer B: Perioperative care of the patient with eye pathologies undergoing nonocular surgery. Anesthesiology. 2022, 137:620-43. 10.1097/ALN.0000000000004338
12. Olson J, McKee H: Pregnancy and refractory epilepsy in Sturge-Weber syndrome: challenges and outcomes . Epileptic Disord. 2023, 25:87-93. 10.1002/epd2.20058
13. Byrne B, O'Carroll RF, Doherty C: Sturge-Weber syndrome: case report, literature review and proposed pregnancy care plan. Obstet Med. 2022, 15:276-9. 10.1177/1753495X211002696
14. Aziz AS, Hui D, Chinnappa V, Aviv RI, Swartz RH: Successful pregnancy, epidural anaesthesia, labour, and delivery in a woman with Sturge-Weber syndrome and previous hemispherectomy. J Obstet Gynaecol Can. 2013, 35:917-9. 10.1016/S1701-2163(15)30814-8