Shrestha *et al. BMC Neurology* (2025) 25:470
https://doi.org/10.1186/s12883-025-04487-9

BMC Neurology

CASE REPORT Open Access

A case report of CLIPPERS syndrome with gait and cognitive impairment

Abhishek Man Shrestha[1*], Subodh Bashyal[2], Naresh Kharbuja[3], Ram Chandra Subedi[3] and Raju Paudel[3]

Abstract

Background Chronic Lymphocytic Inflammation with Pontine Perivascular Enhancement Responsive to Steroids (CLIPPERS) syndrome is a rare, chronic inflammatory central nervous system (CNS) disorder. It primarily involves the brainstem and cerebellum, presenting with subacute neurological symptoms.

Case presentation A 44-year-old male presented with progressive gait imbalance, cognitive dysfunction, and behavioral changes over six weeks. Neurological examination revealed a wide-based unsteady gait, cerebellar dysmetria, and mild cognitive deficits. Cerebrospinal fluid (CSF) analysis showed lymphocytic pleocytosis and elevated protein, while infectious and neoplastic causes were ruled out. Brain MRI demonstrated nodular and patchy lesions involving the cerebellum, brainstem, and thalamus, with characteristic pepper-like post-contrast enhancement consistent with CLIPPERS syndrome.

Treatment and outcome High-dose intravenous methylprednisolone (1 g/day for 5 days) led to significant clinical improvement, including resolution of gait disturbance and cognitive deficits. Follow-up MRI showed a marked reduction in lesion size. Maintenance therapy with oral methotrexate was initiated to sustain remission.

Conclusion CLIPPERS syndrome should be considered in patients presenting with subacute pontocerebellar dysfunction and characteristic MRI findings. Early diagnosis and prompt corticosteroid therapy can lead to favorable outcomes. Long-term immunosuppressive treatment is essential to prevent relapse. Careful follow-up is required to monitor for recurrence and potential malignant transformation.

Keywords CLIPPERS, Corticosteroids, Pontocerebellar, Inflammation, Cognitive impairment

Introduction

Chronic lymphocytic inflammation with pontine perivascular enhancement responsive to steroids (CLIPPERS) syndrome is a rare, chronic inflammatory disorder of the central nervous system, predominantly affecting the perivascular regions of the pons, midbrain, and cerebellum [1]. It is characterized by lymphocytic infiltration of these areas, leading to a range of clinical manifestations. The most common symptoms include gait ataxia and dysarthria, which vary depending on the location and extent of the lesions. CLIPPERS syndrome was first described by Pittock in 2010 [2], and despite its recognition, only a limited number of cases have been reported

*Correspondence:
Abhishek Man Shrestha
drabhisth@gmail.com
[1]National Neuro Center, Maharajgunj, Kathmandu 44600, Nepal
[2]Manmohan Memorial Medical College & Teaching Hospital, Swoyambhu, Kathmandu 44620, Nepal
[3]Department of Neuro Medicine, Grande International Hospital, Dhapasi, Kathmandu 44600, Nepal

© The Author(s) 2025. **Open Access** This article is licensed under a Creative Commons Attribution-NonCommercial-NoDerivatives 4.0 International License, which permits any non-commercial use, sharing, distribution and reproduction in any medium or format, as long as you give appropriate credit to the original author(s) and the source, provide a link to the Creative Commons licence, and indicate if you modified the licensed material. You do not have permission under this licence to share adapted material derived from this article or parts of it. The images or other third party material in this article are included in the article's Creative Commons licence, unless indicated otherwise in a credit line to the material. If material is not included in the article's Creative Commons licence and your intended use is not permitted by statutory regulation or exceeds the permitted use, you will need to obtain permission directly from the copyright holder. To view a copy of this licence, visit http://creativecommons.org/licenses/by-nc-nd/4.0/.

in the literature. The pathophysiology and underlying mechanisms of CLIPPERS remain poorly understood, and diagnosis can be challenging, particularly in patients with atypical presentations or vague neurological symptoms. In such cases, MRI plays a pivotal role in diagnosis, often revealing the distinctive pepper-like speckles, with curvilinear enhancement patterns involving the brainstem, cerebellum, and in some cases, the spinal cord [3]. Steroid therapy, particularly corticosteroids, has proven to be highly effective in managing CLIPPERS, leading to significant clinical improvement in most cases. Recent case studies and trials have also highlighted the potential utility of steroid-sparing agents, such as azathioprine and hydroxychloroquine, in maintaining remission [4]. Ongoing researches are also exploring the role of antitubercular medications and immunotherapy in the treatment of CLIPPERS [5, 6]. This report presents a case of CLIPPERS syndrome diagnosed both clinically and radiologically, with successful treatment using steroids followed by maintenance therapy with methotrexate, resulting in sustained remission.

Clinical report

A 44-year-old male presented to the outpatient neurology clinic with complaints of progressive imbalance while walking over the past six weeks. Initially, the gait disturbance manifested as mild unsteadiness, but it progressively worsened to the point where the patient required assistance to walk. Alongside these symptoms, he experienced episodes of forgetfulness and occasional disorientation, regarding time and recent events. His family members also noticed behavioral changes, such as irritability, decreased verbal interaction, and a growing dependency on assistance for daily tasks. The patient denied any history of fever, headache, seizures, or loss of consciousness. He had no focal weakness, sensory loss, visual disturbances, or cranial nerve symptoms. The patient recalled experiencing similar symptoms approximately two years prior, including gait unsteadiness and cognitive impairment, which resolved spontaneously after a period of supportive care. No definitive diagnosis was made at that time. Since then, he remained asymptomatic until the current presentation. Past medical history was unremarkable, with no significant illnesses such as hypertension, diabetes, or chronic infections. He had no known exposure to toxins or drugs and reported no history of alcohol or substance abuse. Family history was negative for neurological or autoimmune disorders.

Clinical examination revealed that his vital signs were within normal limits, and general systemic examinations were unremarkable. Neurological examination showed a wide-based, unsteady gait consistent with cerebellar ataxia. Romberg's test was positive, indicating postural instability. Finger-nose and heel-to-shin tests revealed mild dysmetria, more pronounced on the left side. Cranial nerve examination was normal, with no signs of facial asymmetry, diplopia, or bulbar dysfunction. Motor strength and tone were preserved in all four limbs, and deep tendon reflexes were symmetrical and normal. Sensory examination was unremarkable. Higher cognitive function testing demonstrated deficits in attention, short-term memory, and time orientation, but comprehension, language, and long-term memory were intact.

To further investigate, lumbar puncture and cerebrospinal fluid (CSF) analysis were performed. The results revealed lymphocytic pleocytosis with a total leukocyte count of 15 cells per cubic millimeter. CSF biochemistry showed elevated protein at 56.8 mg/dL and low glucose at 44 mg/dL. Microbiological studies, including Gram staining, bacterial and fungal cultures, acid-fast bacilli (AFB) staining, and India ink staining for cryptococcal meningitis, were negative. These findings supported a diagnosis of a non-infectious inflammatory or autoimmune CNS disorder.

Neuroimaging with magnetic resonance imaging (MRI) of the brain revealed ill-defined altered signal intensity lesions localized to the left inferior cerebellar peduncle, extending into the cerebellar hemisphere, vermis, dorsal pons, left medulla oblongata, and anterior aspect of the right thalamus, along with bilateral hypothalamus. Post-contrast images showed patchy and nodular enhancement in the cerebellum, pons, and vermis, as well as diffuse gyriform and punctate enhancements in the bilateral cerebellar hemispheres and scattered punctate foci in the cerebral cortex. These imaging findings were consistent with the CLIPPERS syndrome, Fig. 1.

Given the patient's clinical presentation, CSF findings, and MRI abnormalities, infectious causes such as tuberculosis, fungal meningitis, or viral encephalitis were considered but deemed unlikely due to negative CSF studies. Neoplastic conditions, including CNS lymphoma, were ruled out based on imaging findings and the absence of mass-like lesions. Demyelinating conditions like multiple sclerosis were also considered; however, the diffuse, patchy enhancements and recurrent nature of symptoms suggested an inflammatory autoimmune disorder, such as CNS vasculitis or autoimmune encephalitis.

The patient was promptly admitted for management. He was started on high-dose intravenous glucocorticosteroids to control the inflammation. Specifically, methylprednisolone was administered at a dose of 1 gram per day for 5 days. This high-dose steroid therapy was aimed at rapidly suppressing the inflammatory process and halting disease progression. Following the acute phase of treatment, the patient was transitioned to maintenance therapy consisting of oral glucocorticoids combined with an immunosuppressive agent, methotrexate. Methotrexate was chosen to ensure long-term disease

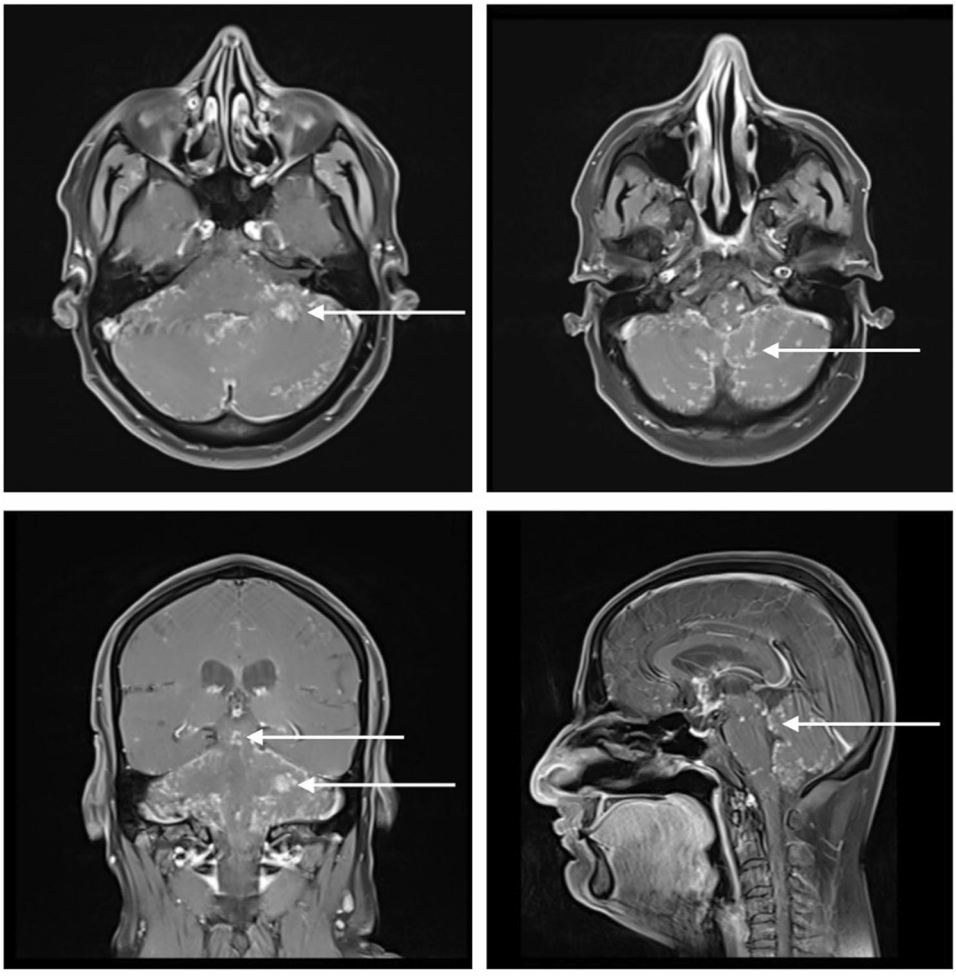

Fig. 1 MRI showing nodular and patchy enhancement in the cerebellum, pons, and thalamus, consistent with CLIPPERS syndrome

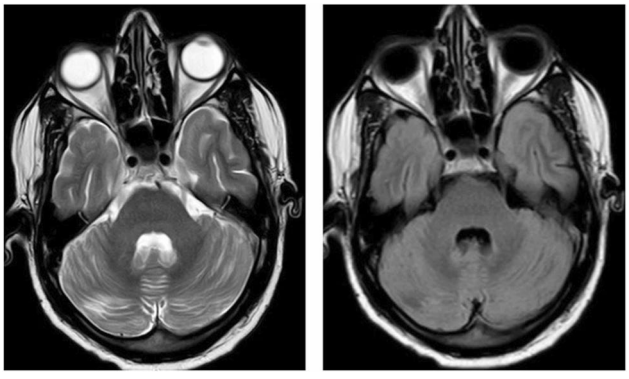

Fig. 2 Follow-up MRI revealing a significant reduction in lesion size after corticosteroid therapy

control while minimizing the need for prolonged high-dose steroids, thereby reducing the risk of steroid-related complications.

On follow-up at 1 month, the patient demonstrated significant clinical improvement. The gait disturbance resolved, and he regained the ability to walk independently without support. Cognitive functions also improved substantially, with family members reporting a return to his baseline cognitive and behavioral status. Repeat MRI imaging revealed a marked reduction in the size and extent of the previously noted inflammatory lesions, confirming a positive response to treatment, Fig. 2. The patient continues to receive oral glucocorticoids and methotrexate as maintenance therapy under close supervision. Regular follow-up with neurological assessments and serial imaging is being conducted to monitor for any signs of relapse or recurrence of inflammation.

Discussion and literature review

CLIPPERS syndrome predominantly affects the brainstem, particularly the pons, but can also involve other regions, including the cerebellum, midbrain, basal ganglia, corpus callosum, and spinal cord. While it can occur across all age groups, CLIPPERS most commonly affects young to middle-aged adults, with a slight predominance in males [7]. Cases in children have also been reported,

Table 1 Proposed updated diagnostic criteria for CLIPPERS by Tobin et al. in 2017 [10], modified from prior proposed criteria by Simon et al. in 2012 [14]

Proposed diagnostic criteria for CLIPPERS		
1.	Clinical	a. Subacute pontocerebellar dysfunction, with or without other CNS symptoms such as cognitive dysfunction and myelopathy. b. CNS symptoms responsive to corticosteroid therapy. c.Absence of peripheral nervous system disease. d. Lack of alternative better explanation for clinical presentation.
2.	Radiological (MRI)	a. Homogenous, gadolinium enhancing nodules without ring enhancement or mass effect predominating in the pons and cerebellum, measuring < 3 mm in diameter. b. Marked improvement in abnormal gadolinium enhancement with corticosteroid treatment. c. Homogenous T_2 signal abnormality where degree of T_2 does not significantly exceed the size of the area of post gadolinium enhancement. d. Spinal cord lesions with similar T_2 and gadolinium enhancing lesions as above.
3.	Neuropathology	a. Dense lymphocytic inflammation with perivascular predominance and parenchymal diffuse infiltration; both white matter and grey matter could be involved. b. T cells predominating infiltration (CD4 >CD8) with variable macrophage components. c. Absence of myelin loss or focal secondary myelin loss. d. Lack of alternative better explanation for pathological presentation.
Diagnostic criteria		**Definite CLIPPERS**: Patient fulfilling all clinical, radiological criteria, neuropathological criteria. **Probable CLIPPERS**: Patients fulfilling all clinical and radiological criteria without available neuropathology

Adopted from [10]

including a pediatric case with long-term follow-up [8]. The CLIPPERS syndrome typically presents with subacute onset and progressive symptoms, such as ataxia, dysarthria, diplopia, sensory disturbances, and, in some cases, cognitive impairment. The clinical manifestations are closely associated with the location of the inflammatory lesions, and symptoms can vary widely from one patient to another [9].

In this case, the patient, a 44-year-old male, presented with progressive gait imbalance, forgetfulness, and mild cognitive dysfunction. These symptoms, combined with the findings of CSF lymphocytic pleocytosis and characteristic brain MRI abnormalities were consistent with the signs and symptoms of CLIPPERS syndrome. Diagnosis of CLIPPERS syndrome relies on clinical, radiological, and sometimes pathological criteria. Clinically, the condition manifests as subacute pontocerebellar dysfunction (e.g., ataxia, dysarthria, and diplopia) often accompanied by cognitive symptoms. Radiologically, MRI findings are crucial for diagnosis, showing gadolinium-enhancing nodular or pepper-like lesions measuring less than 3 mm in the brainstem and cerebellum. Spinal cord involvement has also been reported. Histopathology, if available, confirms perivascular lymphocytic inflammation. The diagnostic criteria proposed by Tobin et al. emphasize a combination of clinical, radiological, and, when feasible, neuropathological findings to classify cases as "definite" or "probable" CLIPPERS, Table 1 [10].

In the present case, the patient fulfilled the clinical and radiological criteria for CLIPPERS. Neuropathological confirmation was not performed due to the eloquent CNS regions affected, the clinical and imaging findings were sufficient to diagnose probable CLIPPERS syndrome. Treatment for CLIPPERS syndrome primarily involves high-dose corticosteroids, which lead to rapid improvement in clinical symptoms and radiological lesions [4]. In this case, the patient was treated with intravenous methylprednisolone at a dose of 1 g/day for five days, followed by oral corticosteroids combined with methotrexate as a steroid-sparing immunosuppressive agent. The patient showed significant clinical improvement within a month, with resolution of gait ataxia and cognitive symptoms. Repeat MRI also demonstrated a reduction in lesion size and enhancement, further confirming the effectiveness of corticosteroid therapy.

Long-term management of CLIPPERS is critical, as the disease has a tendency to relapse if corticosteroids are tapered too quickly or discontinued. Maintenance therapy with steroid-sparing immunosuppressive agents, such as methotrexate, azathioprine, or cyclophosphamide, is recommended to prevent recurrence. Methotrexate, in particular, has been found to be effective in maintaining long-term remission with fewer adverse effects. In this case to prevent disease recurrence, methotrexate was introduced as a steroid-sparing agent as a long term management [11]. Other reported therapies include hydroxychloroquine and rituximab, a CD20 monoclonal antibody, which have shown efficacy in some patients [12]. Trials with tocilizumab, an IL-6 receptor antagonist, have also been explored, though evidence remains limited [13].

Cognitive impairment in CLIPPERS syndrome is also increasingly recognized as a clinically significant feature. While disruption of the cortico-pontocerebellar pathways provides an acceptable anatomical explanation, emerging evidence suggests broader mechanisms may contribute. Neuropathological studies have demonstrated neuro-axonal injury, Purkinje cell loss, and reactive

gliosis, which may underlie both pontocerebellar and supratentorial atrophy associated with cognitive decline [14]. Furthermore, a reported case have shown diffuse cerebral involvement on imaging, extending beyond the brainstem and cerebellum, reinforcing the concept of widespread inflammatory and degenerative processes in CLIPPERS rather than an isolated hindbrain disorder [2].

It is important to differentiate CLIPPERS from mimics, such as infections (e.g., tuberculosis, viral encephalitis), inflammatory demyelinating diseases (e.g., multiple sclerosis, neuromyelitis optica), paraneoplastic syndromes, and CNS vasculitis. The characteristic MRI findings combined with the absence of systemic disease and the dramatic steroid response, help distinguish CLIPPERS from these conditions. However, given the possibility that CLIPPERS may represent a pre-lymphomatous state, careful long-term follow-up is essential to monitor for signs of malignant transformation [7]. Recent advancements, including genetic studies, have provided new insights into the pathogenesis of CLIPPERS syndrome. Whole-exome sequencing in some cases has identified mutations in genes involved in immune regulation, such as ADCYAP1, LRP1, and RAB5. These findings suggest that genetic predisposition may play a role in the development of CLIPPERS, although further research is needed to establish the significance of these mutations and their contribution to disease pathophysiology [15].

Conclusion

This case highlights the importance of recognizing CLIPPERS syndrome as a potential cause of subacute pontocerebellar dysfunction with cognitive symptoms. The combination of clinical features, characteristic MRI findings, and rapid response to corticosteroids is the key to diagnosis. Long-term management with steroid-sparing immunosuppressive agents is essential to prevent relapse and minimize steroid-related side effects. Ongoing research into the pathogenesis and genetics of CLIPPERS may pave the way for more targeted and effective therapies in the future.

Abbreviations

CLIPPERS	Chronic Lymphocytic Inflammation with Pontine Perivascular Enhancement Responsive to Steroids
CNS	Central Nervous System
CSF	Cerebrospinal Fluid
MRI	Magnetic Resonance Imaging
AFB	Acid-Fast Bacilli
IL-6	Interleukin-6
CD20	Cluster of Differentiation 20
ADCYAP1	Adenylate Cyclase Activating Polypeptide 1
LRP1	Low-Density Lipoprotein Receptor-Related Protein 1
RAB5	Ras-Related Protein Rab-5

Acknowledgements

The authors would like to thank the National Neuro Center for providing the space for this case report. We are grateful to Ms. Kritika Rana and Ms. Karuna Gautam for proofreading this case report.

Authors' contributions

A.M.S., S.B., and R.P. conceptualized the study. R.P., N.K., and R.C.S. approved, proofread, and guided the study. A.M.S. and S.B. collected the resources, wrote, proofread, and finalized the manuscript.

Funding

No funding of any kind was received for this article.

Data availability

All data generated or analyzed during this study are included in this article.

Declarations

Ethics approval and consent to participate

As the patient was an adult with cognitive impairment, consent was obtained from his legal guardian on his behalf. The study was carried out following the Helsinki Declaration.

Consent for publication

Written informed consent for the publication of personal and clinical details, including identifying images, was obtained from the patient's legal guardian.

Competing interests

The authors declare no competing interests.

Received: 7 February 2025 / Accepted: 21 October 2025
Published online: 17 November 2025

References

1. Khanduri S, Yadav H, Pandey N, Krishnam A, Nigam S. Chronic lymphocytic inflammation with Pontine perivascular enhancement responsive to steroids (CLIPPERS): a rare treatable neuroradiological spectrum. Cureus. 2019;*11*(4):e4438. https://doi.org/10.7759/cureus.4438.
2. Pittock SJ, Debruyne J, Krecke KN, Giannini C, van den Ameele J, De Herdt V, et al. Chronic lymphocytic inflammation with pontine perivascular enhancement responsive to steroids (CLIPPERS). Brain. 2010;133(9):2626–34. https://doi.org/10.1093/brain/awq164.
3. Korostyshevskaya AM, Stankevich JA, Vasilkiv LM, Bogomyakova OB, Korobko DS, Gornostaeva AM, Tulupov AA. Clippers: multiparametric and quantitative MRI features. Radiol Case Rep. 2023;18(1):368–76.
4. Taieb G, Allou T, Labauge P. Therapeutic approaches in CLIPPERS. Curr Treat Options Neurol. 2017;19(5):17.
5. Mélé N, Guiraud V, Labauge P, Oppenheim C, Mas JL, Taieb G. Effective antituberculous therapy in a patient with CLIPPERS: new insights into CLIPPERS pathogenesis. Neurol Neuroimmunol Neuroinflamm. 2014;1(1):e6. https://doi.org/10.1212/NXI.0000000000000006.
6. Gabilondo I, Saiz A, Graus F, Villoslada P. Response to immunotherapy in CLIPPERS syndrome. J Neurol. 2011;258(11):2090–2. https://doi.org/10.1007/s00415-011-6068-z.
7. Li E-C, Lai Q-L, Cai M-T, Fang G-L, Fang W, Zheng Y, et al. Chronic lymphocytic inflammation with Pontine perivascular enhancement responsive to steroids (CLIPPERS): contemporary advances and current controversies. J Neurol. 2024;271(4):1747–66.
8. Veerapandiyan A, Chaudhari A, Deo P, Ming X. Chronic lymphocytic inflammation with pontine perivascular enhancement responsive to steroids (CLIPPERS): a pediatric case report with six year follow-up. Mult Scler Relat Disord. 2017;17:95–8.
9. Al-Chalabi M, DelCimmuto NR, Beran A, Devarasetty PP, Mhanna A, Mahfooz N, et al. Clinical characteristics, management, and outcomes of CLIPPERS: a comprehensive systematic review of 140 patients from 100 studies. Mult Scler Relat Disord. 2022;68:104112.
10. Tobin WO, Guo Y, Krecke KN, Parisi JE, Lucchinetti CF, Pittock SJ, et al. Diagnostic criteria for chronic lymphocytic inflammation with pontine perivascular enhancement responsive to steroids (CLIPPERS). Brain. 2017;140(9):2415–25. https://doi.org/10.1093/brain/awx200.
11. Taieb G, Duflos C, Renard D, Audoin B, Kaphan E, Pelletier J, et al. Long-term outcomes of CLIPPERS (chronic lymphocytic inflammation with pontine perivascular enhancement responsive to steroids) in a consecutive series of 12 patients. Arch Neurol. 2012;69(7):847–55.

12. Cipriani VP, Arndt N, Pytel P, Reder AT, Javed A. Effective treatment of CLIPPERS with long-term use of rituximab. Neurol Neuroimmunol Neuroinflamm. 2018;5(3):e448.
13. Rempe T, Becktepe JS, Metz I, Brück W, Stürner KH, Deuschl G, et al. A case of CLIPPERS syndrome responsive to tocilizumab. Neurol Neuroimmunol Neuroinflamm. 2019;6(3):e545.
14. Simon NG, Parratt JD, Barnett MH, Buckland ME, Gupta R, Hayes MW, Reddel SW. Expanding the clinical, radiological and neuropathological phenotype of chronic lymphocytic inflammation with Pontine perivascular enhancement responsive to steroids (CLIPPERS). J Neurol Neurosurg Psychiatry. 2012;83(1):15–22.
15. Zhang L, Zhao D, Li J, Feng J, Zhang Q, Liu L, et al. A case report of CLIPPERS syndrome and literature review. Medicine (Baltimore). 2021;100(22):e26090.

Publisher's note

Springer Nature remains neutral with regard to jurisdictional claims in published maps and institutional affiliations.